

was inserted from the left subclavian artery and advanced to the common hepatic artery via the celiac artery. Then an indwelling catheter (Anthon P-U catheter; Toray Medical, Tokyo, Japan or W spiral catheter; PIOLAX, Yokohama, Japan) with a side hole was inserted using the catheter-exchange method. The catheter tip was inserted into the deep segment of the gastroduodenal artery so that the side hole was placed into the common hepatic artery. The gastroduodenal artery around the tip of the indwelling catheter was embolized using microcoils and a mixture (1:1.5) of *n*-butyl cyanoacrylate (NBCA; Histoacryl; Braun, Melsungen, Germany) and iodized oil (Lipiodol Ultrafluide; Laboratoire Guerbet, Roissy, France) through a microcatheter inserted coaxially via the 5 Fr angiographic catheter inserted from the right femoral artery. Finally, the proximal end of the indwelling catheter was connected to a port implanted in the subcutaneous pocket created in the left chest wall.

Digital subtraction angiography and CT were performed during injection of contrast medium through the implanted port-catheter system within a few days of implantation to confirm that the catheter was not dislodged and that the entire liver was perfused adequately. Thereafter, HAIC was administered through this system: 1,000 mg/m<sup>2</sup> of 5-fluorouracil (5-FU) weekly by continuous 5 hr infusion [7]. After administration of the chemotherapeutic agent, the implanted port-catheter system was flushed and filled with 2 ml of heparin solution (1,000 IU/ml).

#### Statistical Analysis

The success rate and the complications of the placement of the port-catheter system were evaluated. After starting HAIC the clinical course, including improvement in liver function tests, performance of surgery, and survival were evaluated. In patients who underwent surgical removal of the primary lesion, the frequency of HAIC administration, time between the placement of the port-catheter system and surgery, details of the surgery, postoperative therapy, and survival were evaluated. The Wilcoxon signed rank test was used to compare the liver functions before surgery with those before starting HAIC. The cumulative survival rate was calculated using the Kaplan-Meier method.

A *p* value of less than .05 was considered significant.

#### Results

After placement of the port-catheter system, patients were followed up for a median of 309 days (range 51–998 days).

#### Placement of the Port-Catheter System

The radiological placement of the port-catheter system was successful in all 21 patients. During and after the procedure, there were no complications such as hematoma, subclavian or vertebral artery thrombosis, infections, hepatic artery occlusions, and catheter malfunctions.

#### Clinical Course after Starting HAIC

After starting HAIC, no severe adverse events that caused drug loss and treatment postponement or suspension were observed in any of the patients. HAIC was performed a mean of 4.5 ± 3.0 times (range 1–15 times) and the liver function improved in all 21 patients. In particular, the AST, ALT, LDH, ALP, and GTP levels were improved significantly (Table 1). In 19 of 21 patients, curative (*n* = 18) or palliative (*n* = 1) surgical removal of the primary lesion was performed. In the remaining 2 patients, although the liver function had improved after HAIC was administered 15 times and 5 times, respectively, extrahepatic metastases in the lung, bone or peritoneum developed rapidly and their performance status worsened. Though systemic chemotherapy was administered with or instead of HAIC afterward, they died 186 and 51 days, respectively, after the placement of port-catheter system; thus, surgery could not be performed.

Among the 19 patients who underwent surgery, HAIC was administered a mean of 3.9 ± 1.8 times (range 1–9 times), and the median period between placement of the

**Table 1** Liver function before and after HAIC administration

		Before starting HAIC	After HAIC	<i>p</i> value
AST (IU/l)	Mean	110 ± 109	56 ± 55	0.0001*
	Range	21–549	21–273	
ALT (IU/l)	Mean	59 ± 43	31 ± 22	0.0005*
	Range	17–183	11–101	
T-BIL (mg/dl)	Mean	1.0 ± 0.5	1.2 ± 1.1	0.717
	Range	0.3–2.2	0.3–4.4	
LDH (IU/l)	Mean	1242 ± 1002	551 ± 501	<0.0001*
	Range	221–3870	174–2050	
ALP (IU/l)	Mean	874 ± 570	663 ± 526	0.0046*
	Range	416–2660	124–2335	
GTP (IU/l)	Mean	393 ± 433	207 ± 169	0.0061*
	Range	130–2023	9–602	

AST, aspartate aminotransferase; ALT, alanine aminotransferase; T-BIL, total bilirubin; LDH, lactate dehydrogenase; ALP, alkaline phosphatase; GTP, gamma-glutamyl transpeptidase; HAIC, hepatic arterial infusion chemotherapy

\*Significant at *p* < 0.05

patients who did not undergo resection [3]. However, patients with advanced liver dysfunction due to synchronous liver metastases are not good candidates for surgical removal of the primary lesion. In such circumstances, surgeons and anesthetists usually hesitate to perform surgical removal of the primary lesion, mainly because the patient's condition is too poor to perform surgery and the liver is seen to be the prognosis-limiting factor. As a result insufficient and palliative systemic chemotherapy might be selected without performing surgical removal of the primary lesion in many cases.

With the recent advances in interventional radiology techniques, radiological placements of port-catheter system are increasingly being used in Japan [4, 5]. Repeated hepatic arterial infusion chemotherapy (HAIC) that is performed through an implanted port-catheter system is an effective therapy employed for unresectable advanced liver malignancies [6–8]. In particular, many reports have indicated that HAIC is effective for liver metastases from colorectal cancer [6–8]. It reported that, compared with systemic chemotherapy, HAIC increased the possibility of tumor response and might improve liver function [6].

The purpose of this study was to retrospectively evaluate the safety and efficacy of the initial administration of HAIC through a port-catheter system in patients with advanced liver dysfunction due to synchronous and unresectable liver metastases from colorectal cancer. The aim of HAIC was to improve their clinical condition for the later surgical removal of the primary lesion.

## Materials and Methods

Approval from the institutional review board of our hospital and informed consent from all the patients were obtained before performing any procedure.

### Patients

Between January 2000 and October 2004, 212 patients with unresectable liver metastases from colorectal cancer underwent radiological placement of port-catheter systems at our institution. In this study, 21 of 212 patients (4 men, 17 women; age 39–77 years, mean  $58.6 \pm 8.1$  years) initially received HAIC through this system to prepare for the surgical removal of the primary lesion later; these patients had liver dysfunction due to synchronous liver metastases. The primary sites of malignancy were as follows: the cecum ( $n = 2$ ), ascending colon ( $n = 5$ ), transverse colon ( $n = 3$ ), sigmoid colon ( $n = 7$ ), and rectum ( $n = 4$ ). With the exception of 1 patient who had a large metastasis in the right lobe of the liver, all patients had diffuse or multiple

metastases in both the right and left lobes of the liver. All hepatic lesions were unresectable. All patients had advanced liver dysfunction due to liver metastases, with increased levels of aspartate aminotransferase (AST; mean  $110 \pm 109$  IU/l, range 21–549 IU/l), alanine aminotransferase (ALT; mean  $59 \pm 43$  IU/l, range 17–183 IU/l), total bilirubin (T-BIL; mean  $1.0 \pm 0.5$  mg/dl, range 0.3–2.2 mg/dl), lactate dehydrogenase (LDH; mean  $1242 \pm 1002$  IU/l, range 221–3,870 IU/l), alkaline phosphatase (ALP; mean  $874 \pm 570$  IU/l, range 416–2660 IU/l), and gamma-glutamyl transpeptidase (GTP; mean  $393 \pm 433$  IU/l, range 130–2,023 IU/l). Since the liver dysfunction in these patients had already progressed, we decided to initially administer HAIC instead of the standard systemic chemotherapy in order to improve their liver function. Even in patients with extrahepatic metastases, we initially administered HAIC because we judged that liver metastasis was the prognosis-limiting factor. In 6 of 21 patients, extrahepatic metastases were observed in organs such as the lung ( $n = 5$ ), bone ( $n = 1$ ), and lymph nodes ( $n = 1$ ). Only 1 patient showed evidence of hepatitis B and C virus infection; no other patient had a history of hepatitis. Usually, we consider T-BIL levels  $>3.0$  mg/dl or an Eastern Co-operative Oncology Group performance status [9] of 4 as the exclusion criteria for HAIC administration. However, in this retrospective study, despite conforming to the exclusion criteria, 4 of 212 patients underwent HAIC; these patients were not included in the analysis because these were not planned surgeries.

### Port-Catheter System Placement and HAIC

All procedures for the placement of port-catheter systems were performed by interventional radiologists in the angiography suite with the patients under local anesthesia. The procedure was performed as follows. All patients underwent angiography before catheter placement, which was performed using a 5 Fr angiographic catheter (Clinical Supply, Gifu, Japan) inserted from the right femoral artery to allow arterial mapping and to prevent extrahepatic influx of the anticancer agents. The extrahepatic arteries branching from the hepatic artery, such as the right gastric artery, posterior superior pancreaticoduodenal artery, and superior duodenal artery, were embolized with microcoils (Tornado; Cook, Bloomington, IN, USA or Trufill; Cordis, Miami Lakes, FL, USA) through a 2.5 Fr microcatheter (Jamiro; Kaneka, Osaka, Japan or Sniper; Clinical Supply, Gifu, Japan) inserted coaxially [10, 11]. In patients with more than two hepatic arteries, these arteries were converted into a single arterial supply by microcoil embolization so that drugs could be distributed to the entire liver using a single indwelling catheter [10]. Next, a 5 Fr angiographic catheter

as an initial therapy for such patients. Although it is doubtful whether the initial HAIC administration is effective in patients who have not undergone any therapy for the primary lesion, HAIC was administered initially in order to improve or control liver metastases. We judged that liver metastasis was the prognosis-limiting factor, because the liver dysfunction in these patients had already progressed due to liver metastases. Additionally, we aim to surgically remove the primary lesion later, if possible, because primary colorectal cancer may cause obstruction, perforation, bleeding, or pain [3]. Based on the results of this study, we believe that initial HAIC administration is effective because, in 19 of 21 patients, surgery was possible after the liver function had been improved by HAIC administration.

In the 19 patients who underwent surgery, HAIC administration was terminated 1 week before surgery to prevent its effect on surgery. The wide range of the frequency of HAIC administration was due to the fact that surgery was not performed until, in the surgeons' opinion, the patient's liver function had improved. We observed that the liver functions before surgery had improved significantly after HAIC administration compared with those before starting HAIC. It has been reported that HAIC has fewer side effects than systemic chemotherapy [13] and, in fact, we observed that surgeries could be performed without any adverse effects arising due to HAIC. We usually consider T-BIL >3.0 mg/dl or a performance status of 4 as the exclusion criteria for HAIC administration because, based on our experience, it is difficult to reduce such liver dysfunction and also improve performance status in patients. Further, the liver dysfunction of such patients may be adversely affected by HAIC administration. Based on our results, there were no severe adverse events after HAIC administration when these exclusion criteria were used for the selection of the candidates. In 2 of 21 patients, although the liver function improved after HAIC administration, surgery could not be performed because they developed extrahepatic metastases in the lung, bone or peritoneum, and their performance status worsened. Unfortunately, we cannot expect HAIC administration to have an anticancer effect on the entire body [7].

There were some limitations in our retrospective study. Firstly, the liver dysfunction of our patients was already advanced; therefore, we hesitated to administer systemic chemotherapy when malignancy was first identified. Secondly, in many patients, other distant metastases were present or developed and systemic chemotherapy was started after the surgery. We could not administer standard systemic chemotherapy such as FOLFIRI and FOLFOX, and our regimens of systemic chemotherapy were not established,

because it is only recently that such standard regimens have been employed in practice in Japan. The survival period might have been prolonged if we had employed the currently used standard systemic chemotherapy.

In conclusion, initial HAIC administration is a safe and efficacious method for improving liver function prior to operative resection of primary colorectal cancer in patients with liver dysfunction due to synchronous and unresectable liver metastases.

## References

1. Ferlay J, Bray F, Pisani P, Parkin DM (2004) GLOBOCAN 2002: Cancer incidence, mortality and prevalence worldwide. IARC CancerBase no. 5, version 2.0. IARC Press, Lyon, France
2. Alexander HR, Kemeny NE, Lawrence TS (2000) Metastatic cancer to the liver. In: DeVita VT (ed) *Cancer*, 7th edn. Williams & Wilkins, Baltimore, pp 2353–2368
3. Ruo L, Gougoutas C, Paty PB, et al. (2003) Elective bowel resection for incurable stage IV colorectal cancer: Prognostic variables for asymptomatic patients. *J Am Coll Surg* 196:722–728
4. Tanaka T, Arai Y, Inaba Y, et al. (2003) Radiologic placement of side-hole catheter with tip fixation for hepatic arterial infusion chemotherapy. *J Vasc Interv Radiol* 14:63–68
5. Yamagami T, Iida S, Kato T, et al. (2002) Using *n*-butyl cyanoacrylate and the fixed-catheter-tip technique in percutaneous implantation of a port-catheter system in patients undergoing repeated hepatic arterial chemotherapy. *AJR Am J Roentgenol* 179:1611–1617
6. Meta-Analysis Group in Cancer (1996) Reappraisal of hepatic arterial infusion in the treatment of nonresectable liver metastases from colorectal cancer. *J Natl Cancer Inst* 88:252–258
7. Arai Y, Inaba Y, Takeuchi Y, et al. (1997) Intermittent hepatic arterial infusion of high-dose 5FU on a weekly schedule for liver metastases from colorectal cancer. *Cancer Chemother Pharmacol* 40:526–530
8. Link KH, Sunelaitis E, Kormann M, et al. (2001) Regional chemotherapy of nonresectable colorectal liver metastases with mitoxantrone, 5-fluorouracil, folinic acid, and mitomycin C may prolong survival. *Cancer* 92:2746–2753
9. Oken MM, Creech RH, Tormey DC, et al. (1982) Toxicity and response criteria of the Eastern Cooperative Oncology Group. *Am J Clin Oncol* 5:649–655
10. Arai Y, Inaba Y, Takeuchi Y (1997) Interventional techniques for hepatic arterial infusion chemotherapy. In: Castaneda-Zuniga WR (ed) *Interventional radiology*, 3rd edn. Williams & Wilkins, Baltimore, pp 192–205
11. Inaba Y, Arai Y, Matsueda K, et al. (2001) Right gastric artery embolization to prevent acute gastric mucosal lesions in patients undergoing repeat hepatic arterial infusion chemotherapy. *J Vasc Interv Radiol* 12:957–963
12. Kelly H, Goldberg RM (2005) Systemic therapy for metastatic colorectal cancer: Current options, current evidence. *J Clin Oncol* 23:4553–4560
13. Collins JM (1984) Pharmacokinetic rationale for intra-arterial therapy. In: Howell SB (ed) *Intra-arterial and intracavitary cancer chemotherapy*. Martinus Nijhoff, Boston, pp 1–10

## Transcatheter Arterial Chemoembolization (TACE) with Lipiodol to Treat Hepatocellular Carcinoma: Survey Results from the TACE Study Group of Japan

Mituo Satake · Hideo Uchida · Yasuaki Arai · Hiroshi Anai · Hiroshi Sakaguchi · Takashi Nagata · Tomohiko Yamane · Kimihiko Kichikawa · Yukio Osaki · Masatoshi Okazaki · Hideyuki Higashihara · Hironobu Nakamura · Keigo Osuga · Norio Nakao · Shouzou Hirota

Received: 13 June 2007 / Accepted: 8 November 2007 / Published online: 4 April 2008  
© Springer Science+Business Media, LLC 2008

**Abstract** The purpose of this study was to retrospectively clarify the current status in Japan of TACE using Lipiodol together with anticancer agents to treat hepatocellular carcinoma (HCC). We retrospectively surveyed 4,659 (average annual total) procedures for HCC over the years 2002–2004 at 17 institutions included in the TACE Study Group of Japan. The survey included six questions that were related mainly to TACE and Lipiodol for HCC treatment. The most frequently applied among the 4,659 procedures at the 17 institutions were TACE (2,310; 50%) and local ablation (1,395; 30%). Five of the institutions applied 201–300 procedures and 4 applied 101–200. Lipiodol was used in “all procedures” and in “90% or more” at seven and nine institutions, respectively. Almost all institutions applied 4–6 (mean, 5) ml of Lipiodol during TACE

to treat tumors 5 cm in diameter. In conclusion, this survey clarified that TACE using Lipiodol and anticancer agents is a popular option for HCC treatment in Japan.

**Keywords** Hepatocellular carcinoma · Transcatheter arterial chemoembolization · Lipiodol · Survey results · Japan

### Introduction

The rate of hepatocellular carcinoma (HCC) is increasing and transcatheter arterial chemoembolization (TACE) seems to be becoming more important as a treatment strategy [1, 2]. Although much information about TACE

M. Satake · Y. Arai  
Department of Diagnostic Radiology, National Cancer Center,  
5-1-1 Tsukiji, Chuo-ku, Tokyo 104-0045, Japan

M. Satake  
e-mail: msatake@ncc.go.jp

H. Uchida (✉) · T. Nagata · T. Yamane  
IVR Center and Department of Radiology, Daiyukai General  
Hospital, 1-9-9 Sakura, Ichinomiya-shi, Aichi 491-0036, Japan  
e-mail: team-uchida@gamma.ocn.ne.jp

H. Anai · H. Sakaguchi · K. Kichikawa  
Department of Radiology, Nara Medical University,  
840 Shijo-cho, Kashihara-shi, Nara 634-8522, Japan

H. Anai  
e-mail: rad@naramad-u.ac.jp

Y. Osaki  
Department of Gastroenterology, Osaka Red Cross Hospital,  
5-30 Fudegasaki-cho, Tennoji-ku, Osaka 543-8555, Japan  
e-mail: yosk@osaka-med.jrc.or.jp

M. Okazaki · H. Higashihara  
Department of Radiology, School of Medicine, Fukuoka  
University, 7-45-1 Nanakuma, Jonan-ku,  
Fukuokashi, Fukuoka 814-0180, Japan

M. Okazaki  
e-mail: okazaki@fukuoka-u.ac.jp

H. Nakamura · K. Osuga  
Department of Radiology, Osaka University School of Medicine,  
2-2 Yamadaoka, Suita-shi, Osaka 565-0871, Japan

H. Nakamura  
e-mail: nakamura@radiol.med.osaka-u.ac.jp

N. Nakao · S. Hirota  
Department of Radiology, Hyogo College of Medicine,  
Mukogwa-cho, Nishinomiya-shi, Hyogo 663-8501, Japan

N. Nakao  
e-mail: n-nakao@hyo-med.ac.jp

for treating HCC has been published [1–36], we consider that to understand the current status of TACE for HCC would be valuable in Japan, where TACE has been applied for more than 20 years [3–22]. We also consider that the concomitant use of iodinated oil (Lipiodol; Lipiodol Ultra-Fluide; Guerbet Co.) for more than 20 years [3–23] should be reviewed [24–26, 32–36]. Although the efficacy of Lipiodol for hepatic TACE has been generally recognized for more than two decades, and segmental or subsegmental TACE using Lipiodol is considered a more effective and less invasive tool for treating localized HCC [9–17], Lipiodol (distributed by Terumo Co. in Japan) has not yet been approved for this application in Japan and other countries. We thus believe that urgent effort is required to obtain official permission from the Pharmaceuticals and Medical Devices Agency (PMDA) of the Japanese Ministry of Health, Labour and Welfare to apply Lipiodol in this manner, based on incontrovertible evidence of expansive usage and value. Therefore, we organized the TACE Study Group in Japan to retrospectively study the issue using a questionnaire at 17 institutions where TACE is frequently applied. We intended to gain fundamental data about TACE and other treatment options for patients with HCC that would reflect the actual use of Lipiodol in clinical practice and its benefits. Our findings should facilitate understanding of the current status of HCC therapy in Japan and establish a foothold for regulatory approval of Lipiodol not only in Japan, but also in other countries.

## Materials and Methods

The TACE Study Group distributed questionnaires to 20 institutions throughout Japan and 17 (85%) of them responded regarding 4,774 procedures for HCC including 2,264 TACE (average total per year) during the years 2002–2004. We analyzed the replies to six questions (Q1–Q6) regarding TACE and Lipiodol for the treatment of HCC.

**Q1** Annual approximate total of HCC procedures during the years 2002–2004 at the institution.

When 100 procedures were displayed as one average annual frequency unit for convenience in data comparisons, the replies were classified as number of procedures per year per institution as follows: 1,  $\leq 100$ ; 2, 101–200; 3, 201–300; 4, 301–400; 5, 401–500 and 6,  $\geq 501$ .

**Q2** Annual number of individual therapies selected for HCC treatment.

a, Surgery; b, local ablation comprising PEIT (percutaneous ethanol injection therapy), PMCT (percutaneous microwave coagulation therapy), RFA (radiofrequency ablation); c, TACE; d, TACI (transcatheter arterial chemoinfusion therapy); e, CAIC (continuous arterial infusion chemotherapy); f, Cx (systemic chemotherapy); g, RT (radiotherapy).

**Q3** Rate of use of Lipiodol in TACE.

**Q4** When Lipiodol was not used, reasons why, and methods of TACE.

**Q5** Rate of use of Lipiodol in TACI.

**Q6** Volume of Lipiodol applied during TACE to treat tumors 5 cm in diameter (clinical stage I).

a, 3–4 ml; b, 4–5 ml; c, 5–6 ml; d, 6–7 ml; e, Other ( ) ml.

## Results

Replies (R1–R6) to the questions (Q1–Q6) were as follows.

**R1** Four institutions each applied 101–200 and 201–300 procedures per year; three applied  $\leq 100$ , one applied 401–500 per year, two applied 301–400 per year, and one applied 501 or more per year.

**R2** Table 1 reports the annual total of HCC treatments and annual numbers (rate) of the top four individual therapies at 17 institutions. Of the treatments applied at the 17 institutions, the most frequent was TACE (2,264 of 4,774; 47%), followed by local ablation (1,443; 30%), TACI (898; 19%), and resection (341; 9%). The mean annual total of procedures was 281 at 17 institutes. The mean rates of each procedure at these institutions were as follows: TACE, 47%; ablation, 30%; and TACI, 19%.

The total average frequency of TACI in addition to TACE, which treats cancer using a catheter inserted into the hepatic artery, accounted for approximately 66% of the total HCC treatments at 17 institutes.

**R3** Regarding Lipiodol in TACE under the premise that Lipiodol is used to prepare a miscible liquid of anticancer drugs (usually Lipiodol emulsion is mixed with anticancer and nonionic contrast agents), seven and nine institutions replied that Lipiodol was used in “all procedures” and in “90% or more,” respectively. One institution claimed to

**Table 1** Annual total of HCC treatments and annual number (rate) of the top four individual therapies at 17 institutions

Institute	Total therapies/yr	Resections/yr	Ablations/yr	TACE/yr	TACI/yr
Total 17	4,774	391 (8%)	1,443 (30%)	2,264 (47%)	898 (19%)
Mean of 17	281	23 (8%)	85 (30%)	133 (47%)	53 (19%)

Note: TACI, transcatheter arterial chemoinfusion therapy

use "80% or more," but the exact rate was 89%. When the rate of Lipiodol use in TACE at all institutions was calculated simply from all reported TACE over 3 years at 17 institutions, the ratio reached 6,328 of a total of 6,740 TACE (94%) procedures.

**R4** Except for the 7 institutions (41%) that used Lipiodol in all TACE procedures, 5 of the 10 institutions that did not use Lipiodol for some TACE procedures replied that Lipiodol might impair hepatic function and 3 replied that they were considering other options. One respondent indicated that TACE did not include Lipiodol at their institution because the therapeutic effect was sometimes limited. Six institutions replied that only gelatin sponge particles are used with anticancer drugs in TACE when Lipiodol is not used.

**R5** The rates of Lipiodol use in TACE varied. Although six institutions (35%) used Lipiodol in more than 80% of TACE procedures and four institutions (24%) used it in 40–80%, three institutions (18%) used it in only 20–40 procedures and four institutions (24%) did not use Lipiodol in TACE at all.

**R6** The volume of Lipiodol used in TACE to treat tumors 5 cm in diameter in the absence of obviously disrupted liver function (clinical stage I) was 5–6 ml (c) at eight institutions (47%), 6–7 ml (d) at five (29%), 4–5 ml (b) at three (18%), and 3–4 ml (a) at one. The average volume (dose) of Lipiodol applied during TACE for HCC 5 cm in diameter (clinical stage I) essentially reflected the tumor volume as indicated by the diameter (cm) at many of the institutions.

Figure 1 shows an example of a HCC measuring 38 × 45 mm with typical CT patterns that was treated by subsegmental TACE for S5 using 4 ml (6 ml of Lipiodol emulsion) of Lipiodol mixed with 30 mg of doxorubicin (dissolved in 2 ml of nonionic contrast medium and saline) followed by injection with gelatin sponge particles.

## Discussion

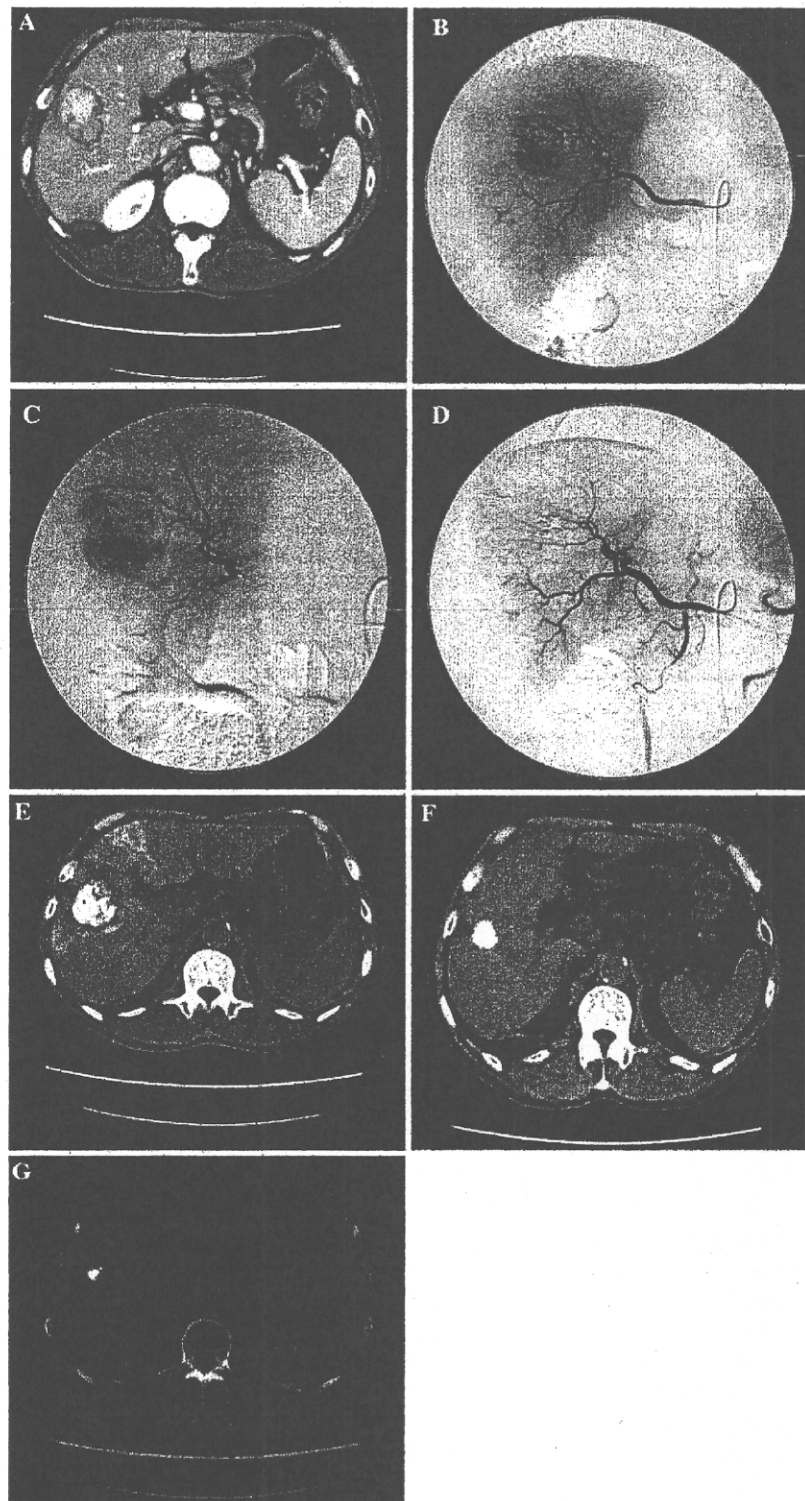
The rate of HCC is increasing worldwide including in Japan [1, 2]. As HCC frequently presents as multiple lesions, invades surrounding tissues, and is usually accompanied by liver dysfunction, indications for resection or local ablation are restricted even now when earlier stages of HCC are being increasingly diagnosed owing to advances in imaging technology. In addition, multiple lesions frequently recur not only after surgery but also after ablation therapy such as radiofrequency ablation. Therefore, TACE is an important option for HCC treatment and the procedure involves the use of iodized oil (Lipiodol) all over the world.

The efficacy of TACE using Lipiodol for HCC has remained controversial despite evaluations, long-term discussions, and various randomized trials. Whereas some

randomized control study findings have questioned the utility of TACE [25–27], more recent reports, also including some randomized studies [24, 30–32], have recognized the value of TACE using Lipiodol [5–23, 33–36]. The most important factors in choosing TACE are to obtain favorable therapeutic effects and to reduce adverse side effects. Thus, the dose of Lipiodol mixed with anticancer drugs should be individually adapted to the tumor size, number of tumors, and hepatic function of each patient. However, the dose of Lipiodol in most randomized control studies was uniform and not adapted to individual needs [25, 26, 31, 33, 36]. We believe that these studies missed the effect of TACE because the doses of Lipiodol and anticancer agents were not optimized, and furthermore, TACE was not repeated before recurrence was diagnosed by imaging, including CT, after the first TACE. However, TACE using Lipiodol is gradually becoming recognized worldwide and randomized control studies seem unnecessary since TACE already seems proven to confer a significant benefit on HCC [2, 24, 30–32].

The present retrospective study clarifies the current status of TACE including the use of Lipiodol for the treatment of HCC at representative institutions that participated in the TACE Study Group in Japan. The results obtained from 17 nationwide institutions showed that although the approximate annual total of HCC procedures over the past 3 years differs at each facility, several hundred HCC procedures per year are performed at the midsize to large leading institutions and >200 treatments are performed annually at more than half of all surveyed institutions. Thus, TACE accounts for 50–60% of all HCC procedures at institutions involved in the TACE Study Group of Japan. Focal radiofrequency ablation therapy is becoming widely prevalent in Japan for localized small HCC lesions. However, TACE has also become a popular strategy for such tumors owing to the use of microcatheters and Lipiodol mixed with anticancer agents, as well as gelatin sponge particles, which are popular for segmental or subsegmental Lipiodol TACE. The excellent effects of segmental or subsegmental Lipiodol TACE in terms of the absence of damage to surrounding normal hepatic tissue have already been proven by histopathological and clinical findings [9–14, 21]. Chemoembolization using Lipiodol combined with percutaneous radiofrequency thermal ablation therapy is becoming another treatment option for HCC, as a larger sphere of ablation can be induced [20]. Repeated TACE with Lipiodol for the recurrence with various collateral pathways is also very useful and important to positively impact the survival of patients with HCC [22]. Therefore, the results of this survey and of most published studies indicate that TACE is an indispensable therapeutic tool that is frequently applied worldwide to treat various types of HCC [2, 4–24, 28–36].

**Fig. 1** Hepatocellular carcinoma 38 × 45 mm in diameter showing typical CT profiles and treated with subsegmental TACE using Lipiodol. Subsegmental TACE was performed using 4 ml of Lipiodol (6 ml of Lipiodol emulsion) mixed with 30 mg of doxorubicin in 2 ml of nonionic contrast medium and saline, followed by injection of gelatin sponge particles. (A) CT shows hypervascular HCC in S5. (B) Hepatic angiogram also demonstrates hypervascular HCC in S5. (C) Superselective hepatic angiogram via the anterior-inferior branch (A5) shows hypervascular tumor in S5. (D) Hepatic angiogram after subsegmental TACE for S5 shows disappearance of tumor vessels and visualization of surrounding hepatic arteries. (E) CT 1 week after subsegmental TACE: Lipiodol is visualized in the embolized S5 area, as well as in the tumor. (F) CT 1 year after subsegmental TACE shows homogeneous tumor accumulation of Lipiodol. (G) Two years after subsegmental TACE, CT shows dense accumulation of Lipiodol and tumor shrinkage. This tumor did not recur



The efficacy of Lipiodol in TACE for HCC has been recognized by several investigators worldwide [4–24, 28–36], whereas only a few articles indicate contrary findings [25–27]. Although the rate of TACE for HCC differs slightly among institutions, this survey shows that >90% of HCCs treated by TACE included Lipiodol. However, although Lipiodol is generally used as a useful carrier of anticancer agents in Japan and elsewhere, it is not legally permitted for hepatic TACE in Japan. Legal permission to use Lipiodol must be based on clear evidence of expansive usage and value. Therefore, we retrospectively surveyed 17 leading Japanese institutions to generate some fundamental data about the use of hepatic TACE with Lipiodol for treating HCC. Seven institutes used Lipiodol in all TACE procedures, nine used Lipiodol in >90% of them, and one used it in >80%, indicating that Lipiodol/TACE is widely perceived as beneficial.

Under the premise that Lipiodol is used in miscible solutions of anticancer drugs, seven and nine institutions replied that Lipiodol was used in “all” and in “90% or more” of procedures, respectively. One institution replied that Lipiodol was used in “80% or more” of procedures, but the actual frequency was almost 90%.

Although Lipiodol is used in about 40% of all TACE procedures, it is not used at about 60% of institutions in <10% of TACE procedures. This is due to potential impairment of hepatic function among patients with poor liver function or a huge HCC that would require a large volume of Lipiodol. Therefore, TACE is occasionally performed with a reduced amount of Lipiodol mixed with anticancer agents, or a first TACE might use only gelatin sponge particles without Lipiodol and anticancer agents for HCC >10 cm in diameter. A second TACE might include a small volume of Lipiodol mixed with anticancer agent after the tumor has been reduced. When only gelatin sponge particles are used in TACE, some institutions nevertheless essentially agreed that TACE can include Lipiodol mixed with an anticancer agent.

This variable use of Lipiodol in TACE indicates that HCC treatment policies differ among institutions. The total frequency of transcatheter arterial therapy (total of TACE and TACE continuous arterial infusion therapy), which treats cancer using a catheter inserted into the hepatic artery, accounted for 60% of the total HCC procedures. The most frequently applied was TACE, followed by local ablation and TACE. These methods accounted for approximately 90% of all HCC therapies. The average volume of Lipiodol used for TACE for HCCs 5 cm in diameter was almost 5 ml, which reflected the tumor volume and was verified in this survey. Our basic criteria regarding the dose of Lipiodol used for TACE state that that average dose (ml) is roughly equal to the tumor diameter (cm). This is reflected in the tumor volume shown in Fig. 1. We already

proposed criteria to select the dose of injected Lipiodol for each patient based on tumor size [9–12, 14, 16]. These criteria have generally been agreed on and are applied in Japan. Therefore, we believe that the survey responses regarding the Lipiodol dose were quite uniform.

A recent article describing the mechanism of action of chemoembolization using Lipiodol in Japan helps to elucidate and support the present study [37].

A prospective cohort study of transarterial chemoembolization for unresectable hepatocellular carcinoma in 8,510 patients has been reported [38]. However, the focus of the contents of registration and the questionnaire of that report is completely different from that in the present study.

**Acknowledgments** We express our sincere appreciation to the following institutions for their valuable contributions to this study (Asahikawa-Kosei General Hospital, Mitsui Memorial Hospital, National Cancer Center Hospital, Niigata University, Kanazawa University, Aichi Cancer Center, Gifu University, Wakayama Medical College, Nara Medical University, Osaka University, Osaka Red Cross Hospital, Ogaki Municipal Central Hospital, Hyogo College of Medicine, Fukuoka University, Kagoshima University).

## References

1. El-Serag HB (2002) Hepatocellular carcinoma: an epidemiologic view. *J Clin Gastroenterol* 35(Suppl):72–78
2. Brown BD, Geschwind JF, Soulen MC, et al. (2006) Society of interventional radiology position statement on chemoembolization of hepatic malignancies. *J Vasc Interv Radiol* 17:217–223
3. Kanematsu T, Inokuchi K, Sugimachi K, et al. (1984) Selective effects of lipiodolized antitumor agents. *J Surg Oncol* 25:218–226
4. Ohishi H, Uchida H, Yoshimura H, et al. (1985) Hepatocellular carcinoma detected by iodized oil. *Radiology* 154:25–29
5. Sasaki Y, Imaoka S, Kasugai H, et al. (1987) A new approach to chemoembolization therapy for hepatoma using ethiodized oil, cisplatin, and gelatin sponge. *Cancer* 60:1194–1203
6. Ohishi H, Yoshimura H, Uchida H, et al. (1989) Transcatheter arterial embolization using iodized oil (Lipiodol) mixed with an anticancer drug for the treatment of hepatocellular carcinoma. *Cancer Chemother Pharmacol* 23(Suppl):S33–S36
7. Nakamura H, Hashimoto T, Oi H, et al. (1989) Transcatheter oily chemoembolization of hepatocellular carcinoma. *Radiology* 170:783–786
8. Konno T (1990) Targeting cancer chemotherapeutic agents by use of lipiodol contrast medium. *Cancer* 66:1897–1903
9. Uchida H, Ohishi H, Matsuo N, et al. (1990) Transcatheter hepatic segmental arterial embolization using lipiodol mixed with an anticancer drug and gelfoam particle for hepatocellular carcinoma. *CardioVasc Interv Radiol* 13:140–145
10. Uchida H, Matsuo N, Sakaguchi H, et al. (1993) Segmental embolotherapy for hepatic cancer: key to success. *CardioVasc Interv Radiol* 16:67–71
11. Uchida H, Matsuo N, Nishimine K, et al. (1993) Transcatheter arterial embolization for hepatoma with Lipiodol. Hepatic arterial and segmental use. *Semin Interv Radiol* 10:19–26
12. Matsuo N, Uchida H, Nishimine K, et al. (1993) Segmental transcatheter hepatic artery chemoembolization with iodized oil for hepatocellular carcinoma: antitumor effect and influence on normal tissue. *J Vasc Interv Radiol* 4:543–549



13. Matsui O, Kadoya Y, Yoshikawa J, et al. (1993) Small hepatocellular carcinoma: treatment with subsegmental transcatheter arterial embolization. *Radiology* 188:79–83
14. Nishimine K, Uchida H, Matsuo N, et al. (1994) Segmental transarterial chemoembolization with Lipiodol mixed with anticancer drugs for nonresectable hepatocellular carcinoma: follow-up CT and therapeutic results. *Cancer Chemother Pharmacol* 33(Suppl):S60–S68
15. Nakao N, Uchida H, Kamino K, et al. (1994) Determination of the optimum dose level of Lipiodol in transcatheter arterial embolization of primary hepatocellular carcinoma based on retrospective multivariate analysis. *CardioVasc Interv Radiol* 17:76–80
16. Sakaguchi H, Uchida H, Maeda, et al. (1995) Combined transjugular intrahepatic portosystemic shunt and segmental Lipiodol hepatic artery embolization for the treatment of esophagogastric varices and hepatocellular carcinoma in patients with cirrhosis: preliminary report. *CardioVasc Interv Radiol* 18:9–15
17. Matsuo N, Uchida H, Sakaguchi H, et al. (1997) Optimal lipiodol volume intracatheter arterial chemoembolotherapy for hepatocellular carcinoma: study based on Lipiodol accumulation pattern and histopathological findings. *Semin Oncol* 24(Suppl 6):61–70
18. Ueno K, Miyazono N, Inoue H, et al. (2000) transcatheter arterial chemoembolization therapy using iodized oil for patients with unresectable hepatocellular carcinoma: evaluation of three kinds of regimens and analysis of prognostic factors. *Cancer* 88:574–581
19. Takayasu K, Muramatsu Y, Maeda T, et al. (2001) Targeted transarterial oily chemoembolization for small foci of hepatocellular carcinoma using a unified helical CT and angiography system: analysis of factors affecting local recurrence and survival rates. *AJR* 176:681–688
20. Higashihara H, Okazaki M (2002) Transcatheter arterial chemoembolization of hepatocellular carcinoma: a Japanese experience. *Hepatogastroenterology* 49:72–78
21. Yamakado K, Nakatsuka A, Ohmori S, et al. (2002) Radiofrequency ablation combined with chemoembolization in hepatocellular carcinoma: treatment response based on tumor size and morphology. *J Vasc Interv Radiol* 13:1225–1232
22. Iwamoto S, Sanafuji H, Okuda K (2003) Angiographic subsegmentectomy for the treatment of patients with small hepatocellular carcinoma. *Cancer* 97:1051–1056
23. Miyayama S, Matsui O, Taki K, et al. (2004) Transcatheter arterial chemoembolization for hepatocellular carcinoma fed by the reconstructed inferior phrenic artery: anatomical and technical analysis. *J Vasc Interv Radiol* 15:815–823
24. Bronowicki JP, Vetter D, Dumas F, et al. (1994) Transcatheter oily chemoembolization for hepatocellular carcinoma: a 4-year study of 127 French patients. *Cancer* 74:16–24
25. Groupe d'Etude et de Traitement du Carcinome Hepatocellulaire (1995) A comparison of lipiodol chemoembolization and conservative treatment for unresectable hepatocellular carcinoma. *N Engl J Med* 332:1256–1261
26. Pelletier G, Ducreux M, Gay F, et al. (1998) Treatment of unresectable hepatocellular carcinoma with lipiodol chemoembolization: a multicenter randomized trial. *J Hepatol* 27:129–134
27. Bruix J, Llovet JM, Castells A, et al. (1998) Transarterial embolization versus symptomatic treatment in patients with advanced hepatocellular carcinoma: results of a randomized, controlled trial in a single institution. *Hepatology* 27:1578–1583
28. Solomon B, Soulen MC, Baum RA, et al. (1999) Chemoembolization of hepatocellular carcinoma with cisplatin, doxorubicin, mitomycin-C, Ethiodol, and polyvinyl alcohol: prospective evaluation of response and survival in a U.S. population. *J Vasc Interv Radiol* 10:793–798
29. Trevisani F, De Notariis S, Rossi C, et al. (2001) Randomized control trials on chemoembolization for hepatocellular carcinoma: Is there room for new studies? *J Clin Gastroenterol* 32: 383–389
30. Lo CM, Ngan H, Tso WK, et al. (2002) Randomized controlled trial of transarterial Lipiodol chemoembolization for unresectable hepatocellular carcinoma. *Hepatology* 35:1164–1171
31. Llovet JM, Real MI, Montana X, et al. (2002) Arterial embolization or chemoembolization versus symptomatic treatment in patients with unresectable hepatocellular carcinoma. *Lancet* 359: 1734–1739
32. Barone M, Ettore GC, Ladisa R, et al. (2002) Transcatheter arterial chemoembolization (TACE) in treatment of hepatocellular carcinoma. *Hepatogastroenterology* 50:183–187
33. Chen MS, Li JQ, Zhang YQ, et al. (2002) High-dose iodized oil transcatheter arterial chemoembolization for patients with large hepatocellular carcinoma. *World J Gastroenterol* 8:74–78
34. Saccheri S, Lovaria A, Sangiovanni A, et al. (2002) Segmental transcatheter arterial chemoembolization treatment in patients with cirrhosis and inoperable hepatocellular carcinoma. *J Vasc Interv Radiol* 13:995–999
35. Geshwind JF, Ramsely DE, Choti MA, et al. (2003) Chemoembolization of hepatocellular carcinoma: results of a meta-analysis. *Am J Clin Oncol* 26:344–349
36. Eurvilaichit C (2004) Outcome of transcatheter oily arterial chemoembolization in patients with hepatocellular carcinoma. *Hepatogastroenterology* 51:20–24
37. Bonneman B (2006) Lipiodol—mechanism of action for chemoembolization. *Jpn IVR* 21:64–68
38. Takayasu K, Arai S, Ikai I, et al. (2006) Prospective cohort study of transarterial chemoembolization for unresectable hepatocellular carcinoma in 8510 patients. *Gastroenterology* 131:461–469

## Percutaneous vertebroplasty performed by the isocenter puncture method

Shinjiro Sakaino · Kenji Takizawa  
Misako Yoshimatsu · Yukihisa Ogawa  
Kunihiro Yagihashi · Yasuo Nakajima

Received: July 17, 2007 / Accepted: October 9, 2007  
© Japan Radiological Society 2008

### Abstract

**Purpose.** The aim of this study was to clarify the usefulness of the isocenter puncture (ISOP) method.

**Materials and methods.** We investigated 73 vertebral bodies that had undergone percutaneous vertebroplasty (PVP) by the ISOP method, 118 vertebral bodies that had undergone the puncture simulation method, and 33 vertebral bodies that had undergone the conventional method. The items to be examined included the success rate (SR) of the median puncture of the vertebral body and the procedure time. The puncture accuracy and fluoroscopy time were also measured for the ISOP method. **Results.** The SR was significantly higher and the procedure time significantly shorter when using the ISOP method rather than the conventional method. However, no significant differences were observed between the ISOP method and the puncture simulation method. The errors between the puncture needle tip and the puncture target point in the ISOP method were an average of 1.52, 2.08, and 1.87 mm in each of the horizontal, ventrodorsal, and craniocaudal directions. The fluoroscopy time when operating on one vertebral body was an average of 5.8 min.

**Conclusion.** The ISOP method is considered to be a useful approach while also reducing the puncture time and the fluoroscopy time.

S. Sakaino (✉) · K. Takizawa · M. Yoshimatsu · Y. Ogawa ·  
K. Yagihashi · Y. Nakajima  
Department of Radiology, St. Marianna University School of  
Medicine, 2-16-1 Sugao, Miyamae, Kawasaki 216-8511, Japan  
Tel. +81-44-977-8111; Fax +81-44-589-9797  
e-mail: sakashin622@yahoo.co.jp

This article was presented at a Japan Radiological Society meeting  
in April 2007

**Key words** ISOP method · Percutaneous  
vertebroplasty · Unilateral transpedicular approach ·  
Isocenter marker · PVP

### Introduction

Percutaneous vertebroplasty (PVP), a rapidly acting treatment for pain caused by a compressed fracture of the vertebral body, is increasingly being used worldwide. PVP is generally performed using a C-arm radiographic system and puncturing the vertebral arch pedicle percutaneously under X-ray fluoroscopy. The puncture approach includes both the unilateral and bilateral transpedicular approaches. The unilateral transpedicular approach is relatively difficult to perform as it requires advancing the tip of a puncture needle to the midline of the vertebral body. Therefore, some institutions use the bilateral transpedicular approach. However, the unilateral transpedicular approach may decrease the number of punctures required during such surgery.<sup>1,2</sup>

We have therefore developed an isocenter puncture (ISOP) method<sup>3</sup>, which is a puncture support method for the unilateral transpedicular approach. The ISOP method allows pinpoint targeting and puncturing of a target within the vertebral body under X-ray fluoroscopy.

We herein describe the results of PVP using the ISOP method and compare the findings with those achieved with the puncture simulation method<sup>2</sup> using the puncture angle measured by the preoperative CT examination and those by the conventional puncture method, as a historical control, while also examining the usefulness of the ISOP method.

## Materials and methods

This study was approved by the ethics committee at our institution.

### ISOP method concept and procedures

The isocenter of the C-arm radiographic system is the center of the radiation field and the center of the C-arm rotation. Therefore, regardless of how the C-arm rotates, the isocenter always remains at the center of the radiation field and the center of the monitor screen. The ISOP method applies this principle, and therefore adjusting the puncture target to the position of the isocenter becomes essential with this method. For this purpose, we created a black dot-like isocenter marker (ICM; Toshiba Medical, Tokyo, Japan), which is constantly illuminated at the center of the fluoroscopic monitor screen (Fig. 1).<sup>2</sup> We set the anterior one-third median site of the vertebral body as a target point.

The procedures of the ISOP method start with positioning the puncture target point at the isocenter. The first step is a frontal view on the fluoroscopic monitor.

The examining table is moved as necessary to align it with the median of the vertebral body with the ICM (Fig. 2a). Next, the lateral view is used with the C-arm tilted 90° for guidance. The examining table is moved so that the anterior one-third median site of the vertebral


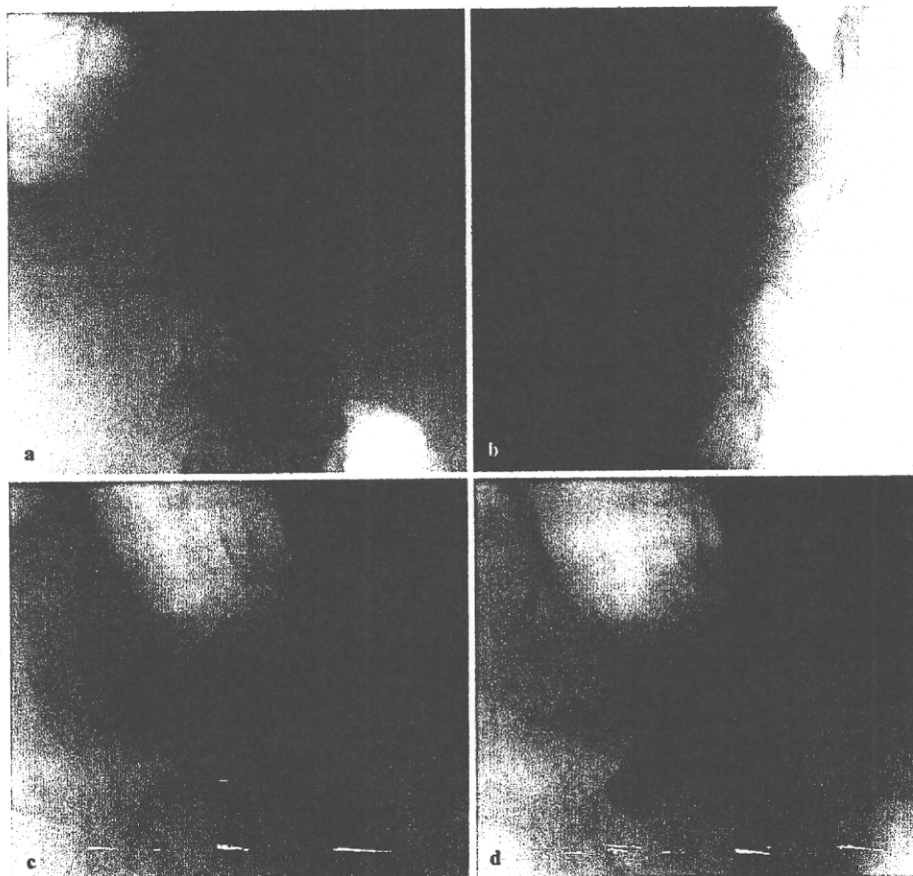


Fig. 1. Isocenter marker (ICM)

**Fig. 2. Positioning.** **a** In the frontal view, the ICM is aligned with the median of the vertebral body. **b** In the lateral view, the ICM is aligned with the anterior one-third median site of the vertebral body. **c** The C-arm is moved in a three-dimensional manner so the ICM is aligned with the center of the shadow of the vertebral arch pedicle. **d** The shadow of the puncture needle becomes a *dotted line* and is aligned with the ICM



body is aligned with the ICM (Fig. 2b). After carrying out these steps, the positioning of the isocenter marker in regard to the patient's position is completed. Consequently, regardless of how the C-arm rotates, the puncture target point is now aligned with the ICM at all times.

Next, the direction of the puncture direction is determined by rotating the C-arm in a three-dimensional manner so the ICM overlaps the center of the pediculus arcus vertebral image (Fig. 2c). With this step, the puncture direction is determined under fluoroscopy.

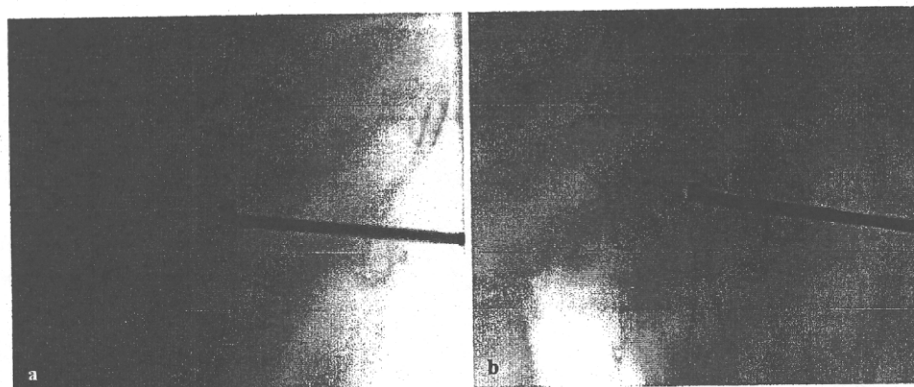
After confirming the cutaneous puncture site on the skin and administering local anesthesia, the puncture is performed while maintaining the puncture direction so the puncture needle overlaps the ICM in a point-like manner under fluoroscopy (Fig. 2d). When the needle reaches a depth of 1–2 cm in the vertebral arch pedicle, and the assistance of the needle is thus no longer required, the monitor is switched to the lateral fluoroscopic image, and the puncture needle is moved forward until the needle tip reaches the ICM (Fig. 3a). When moving the

needle forward, a hammer is used as required. After the puncture needle tip has reached the ICM in the lateral image, the monitor is returned to the frontal fluoroscopic image to confirm that the puncture needle tip is aligned with the ICM (Fig. 3b), thereby completing the puncture by the ISOP method.

#### Materials

A total of 122 patients (224 vertebral bodies) underwent fluoroscopic PVP. They were then divided into three groups. Table 1 represents the characteristics of those groups. The first (group A) comprised 41 patients (73 vertebral bodies) who had undergone PVP by the ISOP method from January 2006 to March 2007. The second group (group B) comprised 58 patients (118 vertebral bodies) who had undergone PVP by the puncture simulation method from September 2004 to January 2006. The third group (group C) comprised 23 patients (33 vertebral bodies) who had undergone PVP without using the ICM from June 2002 to May 2004.

**Fig. 3. Verification.**  
**a** Lateral view: the puncture needle tip overlaps the ICM.  
**b** Frontal view: the puncture needle tip overlaps the ICM



**Table 1. Summary of patients**

Characteristic	ISOP method (group A)	Puncture simulation (group B)	Conventional method (group C)
Cases (vertebrae)	41 (73)	58 (118)	23 (33)
Male/female	8/33	11/47	9/14
Age (years), average/range	68.3/37–90	67.2/33–91	73.9/30–87
Location (case)	Th7 (1), Th8 (2), Th10 (3), Th11 (2), Th12 (12), L1 (18), L2 (14), L3 (10), L4 (9), L5 (2)	Th5 (1), Th6 (3), Th7 (2), Th8 (6), Th9 (8), Th10 (4), Th11 (10), Th12 (14), L1 (12), L2 (16), L3 (18), L4 (18), L5 (6)	Th8 (2), Th11 (1), Th12 (4), L1 (4), L2 (6), L3 (4), L4 (5), L5 (7)
Underlying disease (cases/vertebrae)			
Osteoporosis	34/58	45/81	11/15
Bone metastasis	7/15	13/37	11/17
Multiple myeloma			1/1

## Methods

For all groups, we measured the success rate of the median puncture of the vertebral body (SR)<sup>1,2</sup> and the time required to perform a needle puncture successfully. The SR was evaluated by three radiologists during the procedure. It was judged by macroscopic evaluation of whether the needle tip reached the median of the vertebral body and by objective evaluation of whether the bone cement was distributed beyond the median of the vertebral body. These evaluations were done by using examples from previous observations of Kim et al.<sup>1</sup> For cases of failure, puncture was performed from the opposite side or from the same side after removing the needle. Fisher's exact test was used to evaluate all groups.

The procedure time for needle puncture was defined from the start of the positioning to puncture completion. The procedure time for needle puncture did not include the time needed to prepare the bone cement or the time needed to inject the cement. For a comparison of the puncture time, Mann-Whitney's U-test was used.

In group A, the puncture error, fluoroscopy time, and adverse events were further examined. Because the puncture target point with the ISOP method is determined by the operator's visual estimation during the procedure, it is not necessarily the anterior one-third median site of the vertebral body. When the patient is moved after the puncture direction is determined, a slight misalignment is likely to occur between the puncture target point and the ICM. Therefore, to evaluate the puncture error in the ISOP method, we verified where the puncture needle tip is located on the image obtained before the cement injection and measured the positional error between the puncture needle tip and the ideal puncture target point. For the error between the puncture needle tip and the ideal puncture target point, we measured the lateral direction of the axis in the frontal view and the craniocaudal direction of the axis in the lateral view.

For the fluoroscopy time during the procedure, the time between the positioning and rotation digital angiography immediately after the procedure was thus measured. The examination of adverse events was based on their presence or absence during the procedure.

A single plane C-arm of Infinix celeve VC (Toshiba Medical) was used for X-ray fluoroscopy. The puncture needle, an osteo-site bone biopsy needle (13 gauge, 15 cm; Cook, Spencer, IN, USA) was used. For injecting the cement preparation, Osteoject (Integra Neuro-Science, Plainsboro, NJ, USA) was used. PMMA (polymethylmethacrylate) was the bone cement, which was prepared by mixing 20 g of PMMA with 6 g of sterilized barium sulfate.

**Table 2.** Success rate ratio

Group	SR	Non-SR	Total
A	72	1	73
B	110	8	118
C	19	14	33
Total	201	23	224

SR, success rate

## Results

### Success rate of the median puncture of the vertebral body

The success rate (SR) for median puncture of the vertebral body was 98.6% (72/73) in group A, 93.2% (110/118) in group B, and 58% (19/33) in group C (Table 2). No significant differences were observed between groups A and B ( $P = 0.15$ ). When comparing groups A and C, the SR was significantly higher in group A ( $P < 0.05$ ).

In cases where a median puncture could not be successfully performed, either additional punctures were attempted from the opposite side or the same puncture was repeated. In all cases, satisfactory cement distribution to the lateral regions crossing the median was ultimately obtained.

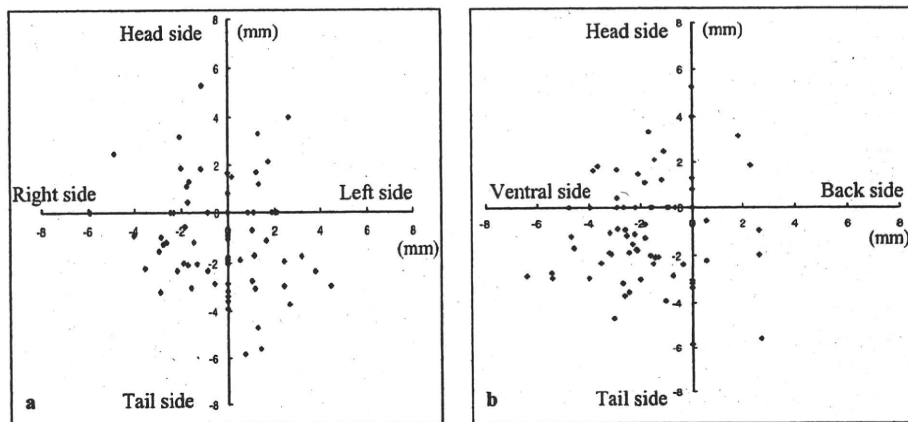
### Procedure time

The average procedure time for needle puncture for one vertebral body was  $9.3 \pm 3.8$  min in group A,  $11.2 \pm 4.6$  min in group B, and  $30.9 \pm 11.2$  min in group C. No significant differences between groups A and B were observed regarding the puncture time ( $P = 0.22$ ); however, the time was significantly shorter between groups A and C ( $P < 0.01$ ).

### Positional relation between the ideal puncture target point and the puncture needle tip—ISOP method

The average error in the horizontal direction was  $1.52 \pm 1.31$  mm (maximum 5.92 mm), the average error in the ventrodorsal direction was  $2.08 \pm 1.50$  mm (maximum 6.41 mm), and the average error in the craniocaudal direction was  $1.87 \pm 1.43$  mm (maximum 5.81 mm). Figure 4 shows the positional relation between the ideal puncture target point and the puncture needle tip to each axis. As shown in Fig. 4b, we detected a tendency for the puncture needle tip to go slightly deeper toward the abdominal side of the vertebral body.

Fig. 4. Positional relation between the puncture needle tip and the puncture target point. a frontal view. b lateral view



#### Fluoroscopy time during the procedure—ISOP method

In group A, the average fluoroscopy times during the procedure were  $5.8 \pm 0.9$  min for 23 cases of operating on one vertebral body,  $8.97 \pm 3.79$  min for 8 cases of operating on two vertebral bodies,  $9.33 \pm 3.79$  min for 4 cases of operating on three vertebral bodies, and  $11.8 \pm 2.83$  min for 6 cases of operating on four vertebral bodies.

#### Adverse events—ISOP method

Two patients in group A had a fever after the procedure. Although the hospitalization period of these patients was extended by approximately 1 week, the symptoms were alleviated by antibiotic administration. No technique-related complications were observed.

#### Discussion

There have been only a few reported evaluations of PVP procedures, and most of them reported on cement distribution and leakage.<sup>1–8</sup> Many institutions select PVP using the bilateral transpedicular approach, thus expecting an even cement distribution within the vertebral body. Kim et al.<sup>1</sup> noted that if the unilateral transpedicular approach can achieve cement distribution across the median there are no differences in treatment effects compared to the bilateral transpedicular approach. In our examination, it was confirmed that by using the ISOP method the PVP success rate was 98.6%, and that even with the unilateral vertebral transpedicular approach bilateral cement distribution can be achieved if puncture is successfully performed with a target point of the anterior one-third median site of the vertebral body.

In group A, puncture had to be repeated in one case. In this case, it was attributed to body movement after positioning, whereby the ICM was misaligned from the puncture target point during the puncture. In this case, the ISOP method was applied again after removing the puncture needle. Favorable treatment effects were then obtained.

The puncture times were significantly shorter in group A than in group C, suggesting that the ISOP method contributes to a reduction of the puncture time in comparison to the conventional method.

In our hospital, before introducing the ISOP method, PVP had been implemented using the puncture simulation method.<sup>2</sup> With both the ISOP method and the puncture simulation method, there were no significant differences in the SR or the puncture time. Based on the above results, we speculate that no substantial differences exist between the ISOP method and the puncture simulation method. However, the puncture simulation method requires a preoperative CT examination and measurement of the puncture angle. Considering the labor hours and complexity, it is obvious that the ISOP method is a simpler, more useful puncture method.

Puncture accuracy in the ISOP method was an average of 2 mm in each of the horizontal, ventrodorsal, and craniocaudal directions. With this examination, except for case in which a second puncture was required owing to the patient's body movement (group A), the puncture needle tip reached the ICM in all cases, which is thus regarded as high puncture accuracy.

Reports on the amount of exposure and fluoroscopy time in the PVP are scarce.<sup>10–12</sup> Komemushi et al. have performed PVP by using the IVR-CT system and reported that the fluoroscopy time was  $6.66 \pm 2.45$  min.<sup>11</sup> We used only a fluoroscopy device. The average fluoroscopy time for one vertebral body was  $5.8 \pm 0.9$  min,

which was short, on average. In addition, Mehdizade et al. reported that the PVP fluoroscopy time under fluoroscopy was 10–60 min.<sup>10</sup> Compared to these reports, PVP under fluoroscopy by means of the ISOP method is believed to contribute to a significant reduction in the fluoroscopy time.

### Conclusion

Compared to the conventional method, the ISOP method is thought to be a useful approach as it improves the PVP completion rate by using the unilateral vertebral arch pedicle approach; it also reduces the puncture time and fluoroscopy time. Thus, we speculate that the ISOP method is a more convenient technique than the puncture simulation method.

### References

1. Kim AK, Jensen ME, Dion JE, Schweickert PA, Kaufmann TJ, Kallmes DF. Unilateral transpedicular percutaneous vertebroplasty: initial experience. *Radiology* 2002;222:737–41.
2. Kobayashi K, Takizawa K, Koyama M, Yoshimatsu M, Sakaino S, Nakajima Y. Unilateral transpedicular percutaneous vertebroplasty using puncture simulation. *Radiat Med* 2006;24:187–94.
3. Takizawa K, Yoshimatsu M, Nakajima Y, Sakaino S, Yagihashi K, Ogawa Y, et al. Development of a new support method for transpedicular punctures of the vertebral body: the isocenter puncture method. *Cardiovasc Intervent Radiol* 2007;30:757–60.
4. Koyama M, Takizawa K, Kobayashi K, Sasaka K, Hoshikawa Y, Nakaji S, et al. Initial experience of percutaneous vertebroplasty using single plane C-arm fluoroscopy for guidance. *Radiat Med* 2005;23:256–60.
5. Jensen ME, Evans AJ, Mathis JM, Kallmes DF, Cloft HJ, Dion JE. Percutaneous polymethylmethacrylate vertebroplasty in the treatment of osteoporotic vertebral body compression fractures: technical aspects. *AJNR Am J Neuroradiol* 1997;18:1897–904.
6. Cotton A, Boutry N, Cortet B, Assaker R, Demondion X, Leblond D, et al. Percutaneous vertebroplasty: state of the art. *Radiographics* 1998;18:311–20.
7. Tohmeh AG, Mathis JM, Fenton DC, Levine AM, Belkoff SM. Biomechanical efficacy of unipedicular versus bipedicular vertebroplasty for the management of osteoporotic compression fractures. *Spine* 1999;24:1772–6.
8. Deramond H, Depriester C, Galibert P, LeGars D. Percutaneous vertebroplasty with polymethylmethacrylate: technique, indications, and results. *Radiol Clin North Am* 1998;36:533–46.
9. Do HM, Kim BS, Marcellus ML, Curtis L, Marks MP. Prospective analysis of clinical outcomes after percutaneous vertebroplasty for painful osteoporotic vertebral body fractures. *AJNR Am J Neuroradiol* 2005;26:1623–8.
10. Mehdizade A, Lovblad KO, Wilhelm KE, Somon T, Wetzell SG, et al. Radiation dose in vertebroplasty. *Neuroradiology* 2004;46:243–5.
11. Komemushi A, Tanigawa N, Kariya S, Kojima H, Shomura Y, Sawada S. Radiation exposure to operators during vertebroplasty. *J Vasc Interv Radiol* 2005;16:1327–32.
12. Kallmes DF, O E, Roy SS, Piccolo RG, Marx WF, Lee JK, et al. Radiation dose to the operator during vertebroplasty: prospective comparison of the use of 1-cc syringes versus an injection device. *AJNR Am J Neuroradiol* 2003;24:1257–60.

