

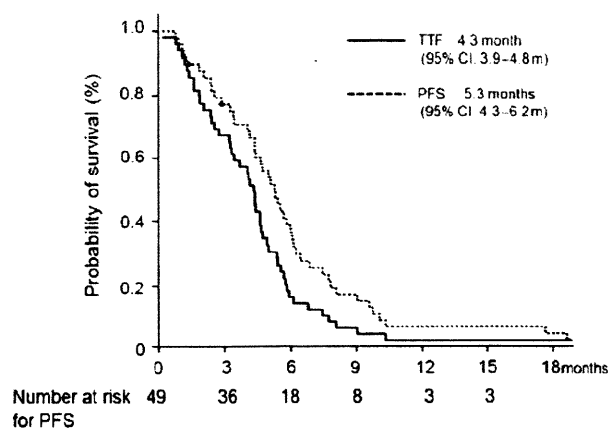Figure 1. Progression-free survival (PFS) and time to treatment failure (TTF).

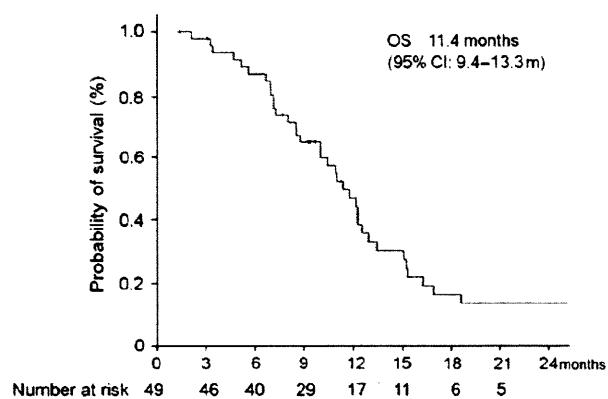


Figure 2. Overall survival.

One patient died within 28 days of the last dose of study medication due to liver failure caused by rapid tumour progression.

All patients ($n = 51$) experienced at least one adverse event during the study, most of which were mild to moderate in severity (Table 3). The most common adverse events with FOLFOX6 were peripheral sensory neuropathy (82%), anorexia (78%), leukopenia (75%), neutropenia (73%), thrombocytopenia (69%), nausea (61%) and stomatitis (31%). The most common grade 3/4 adverse events were neutropenia (43%) and leukopenia (12%).

DISCUSSION

FOLFOX4 was the gold standard regimen for colorectal cancer in first- and second-line therapy, but the frequent hospital visits were problematic. FOLFOX6 uses the new, simplified, biweekly LV + 5-FU regimen, with a disposable pump for outpatient therapy (8). An oxaliplatin dose of 100 mg/m² was chosen because the results obtained in previous studies suggest a possible dose intensity effect on the

Table 3. Toxicity ($n = 51$)

Adverse event CTC-AE v.3.0	Grade 1-4		Grade 3-4	
	No.	%	No.	%
Neutropenia	37	72.5	22	43.1
Leukopenia	38	74.5	6	11.8
Anaemia	22	43.1	4	7.8
Thrombocytopenia	35	68.6	2	3.9
Anorexia	40	78.4	2	3.9
Nausea	31	60.8	2	3.9
Stomatitis	16	31.4	0	0
Febrile neutropenia	2	3.9	2	3.9
Hand-foot syndrome	7	13.7	1	2.0
Pigmentation	10	19.6	—	—
Sensory neuropathy ^a	42	82.4	2	3.9

^aSensory neuropathy was evaluated by Debiopharm neurotoxicity criteria.

RR and because the toxicity profile was very similar except for a higher neutropenia occurrence with FOLFOX4. FOLFOX4 showed an RR of 21.2% and OS of 11.5 months in 5-FU refractory patients (7). An RR of 9.9% and TTF of 4.6 months was observed in patients who failed to respond to irinotecan-based therapy (5). On the other hand, FOLFOX6 showed an RR of 27% in 5-FU pretreated colorectal cancer patients and 15% in patients who failed to respond to FOLFIRI therapy (8,9). Our results were almost the same, with an RR of 12.9% for irinotecan pretreated patients and 20% for no-irinotecan patients.

In this prospective trial, we evaluated the efficacy and safety of FOLFOX6 in Japanese patients with metastatic colorectal cancer (MCRC). The administration schedule and doses selected for our study were identical to those used in the Tournigand study (7). The major common grade 3/4 adverse events evident in our patient population were neutropenia (43.1%), leukocytopenia (11.8%) and anaemia (7.8%). All other grade 3/4 adverse events occurred in 5% of patients or less. It is notable that the rate of grade 3 sensory neuropathy was only 3.9% in our study population, which is considerably lower than the rates reported with FOLFOX in other Phase-III studies (9.2–20%) (5,7,9,12). This may be due to the short duration of treatment. In the second line, many patients failed to respond to treatment before cumulative toxicity developed. Moreover, there were many criteria for evaluating sensory neuropathy. Some studies used the Debiopharm criteria, while others used CTC-AE v.3.0, so it was difficult to compare sensory neuropathy between studies in detail. Nevertheless, FOLFOX6 demonstrated a predictable and manageable safety profile in Japanese patients.

The recent use of five active drugs, such as 5-FU, irinotecan, oxaliplatin, bevacizumab and cetuximab, appears

to be of major importance in prolonging the survival of MCRC patients (13). Sensory neuropathy can be treatment-limiting with oxaliplatin-based regimens. In our study, three patients discontinued treatment due to neuropathy. In such cases, oxaliplatin discontinuation and reintroduction using the OPTIMOX (stop-and-go) strategy (14) proves useful. The aim of chemotherapy for metastatic cancer is not to cure the disease, but to prolong the patient's survival and to continue the treatment as long as possible. From this viewpoint, the oxaliplatin starting dose has been decreased to 85 mg/m², which is the so-called modified FOLFOX6 regimen. The modified FOLFOX6 has not been directly compared with FOLFOX6, but its efficacy and safety profile is similar to that of FOLFOX6. It showed an RR of 41%, PFS of 8.7 months and low peripheral neuropathy (18%: Grade 3) among first-line colorectal cancer patients (15). In another retrospective study, the RR of mFOLFOX6 was reported to be 8.7% for irinotecan pretreated patients (16). Our results seemed to be slightly better (12.8%), but the number of patients was too small to compare the efficacy between FOLFOX6 and mFOLFOX6. In this study, the dose of oxaliplatin needed to be reduced in 20 patients (40%) and the relative dose intensity for oxaliplatin was 0.845. It was considered that the total dose of oxaliplatin was not significantly different between the starting dose of 100 mg/m² or 85 mg/m². The modified FOLFOX6 is becoming the community standard for FOLFOX.

Molecular-targeted drugs, such as bevacizumab or cetuximab, have an added effect on cytotoxic agents (12,17,18), and are built in as standard treatment in all lines. However, quite a few patients are unable to use bevacizumab or cetuximab due to complications or efficacy. Hypertension or thrombotic events were limiting the toxicity for bevacizumab treatment (19), and KRAS mutation, which occurs in about 40% of the patients, was a negative predictive factor for cetuximab treatment (20). Thus, it remains important to evaluate the regimen of cytotoxic agents and to manage them in our clinical practice.

In conclusion, this study suggests that FOLFOX6 had an acceptable profile in terms of both efficacy and safety in previously treated Japanese colorectal cancer patients. The efficacy and safety profile of FOLFOX6 in this study was consistent with that observed in Western patients. The FOLFOX6 regimen can therefore be considered as one of the standard treatments for Japanese patients with MCRC.

Acknowledgements

We thank Ms. Makiko Shinogi and Hiromi Orita for data collection. This study was supported by Grants-in-Aid for Cancer Research from the Ministry of Health, Labour and Welfare of Japan.

Funding

This work was supported by Ministry of Health, Labour and Welfare.

Conflict of interest statement

None declared.

References

1. Jemal A, Tiwari RC, Murray T, Ghafoor A, Samuels A, Ward E, et al. American Cancer Society, Cancer Statistics 2004. *CA Cancer J Clin* 2004;54:8–29.
2. Parkin DM. Global cancer statistics in the year 2000. *Lancet Oncol* 2001;2:533–43.
3. Cancer Statistics in Japan Editorial Board. Cancer Statistics in Japan 2008. Foundation for Promotion of Cancer Research. 2008 (in Japanese).
4. Tsukuma H, Ajiki W, Ioka A, Oshima A. Research Group of Population-Based Cancer Registries of Japan. Survival of cancer patients diagnosed between 1993 and 1996: a collaborative study of population-based cancer registries in Japan. *Jpn J Clin Oncol* 2006;36:602–7.
5. Rothenberg ML, Oza AM, Bigelow RH, Berlin JD, Marshall JL, Ramanathan RK, et al. Superiority of oxaliplatin and fluorouracil-leucovorin compared with either therapy alone in patients with progressive colorectal cancer after irinotecan and fluorouracil-leucovorin: interim results of a phase III trial. *J Clin Oncol* 2003;21:2059–69.
6. Goldberg RM, Sargent DJ, Morton RF, Fuchs CS, Ramanathan RK, Williamson SK, et al. A randomized controlled trial of fluorouracil plus leucovorin, irinotecan, and oxaliplatin combinations in patients with previously untreated metastatic colorectal cancer. *J Clin Oncol* 2004;22:23–30.
7. Rougier P, Lepille D, Bennouna J, Marre A, Ducreux M, Mignot L, et al. Antitumour activity of three second-line treatment combinations in patients with metastatic colorectal cancer after optimal 5-FU regimen failure: a randomised, multicentre phase II study. *Ann Oncol* 2002;13:1558–67.
8. Maindrault-Goebel F, Louvet C, André T, Carola E, Lotz JP, Molitor JL, et al. Oxaliplatin added to the simplified bimonthly leucovorin and 5-fluorouracil regimen as second-line therapy for metastatic colorectal cancer (FOLFOX6). GERCOR. *Eur J Cancer* 1999;35:1338–42.
9. Tournigand C, André T, Achille E, Lledo G, Flesh M, Mery-Mignard D, et al. FOLFIRI followed by FOLFOX6 or the reverse sequence in advanced colorectal cancer: a randomized GERCOR study. *J Clin Oncol* 2004;22:229–37.
10. Therasse P, Arbuck S, Eisenhauer E, Wanders J, Kaplan R, Rubinstein L, et al. New guidelines to evaluate the response to treatment in solid tumors. *J Natl Cancer Inst* 2000;92:205–16.
11. National Cancer Institute—Common Toxicity Criteria. (NCI-CTC Version 3.0, March 31, 2003).
12. Giantonio BJ, Catalano PJ, Meropol NJ, O'Dwyer PJ, Mitchell EP, Alberts SR, et al. Bevacizumab in combination with oxaliplatin, fluorouracil, and leucovorin (FOLFOX4) for previously treated metastatic colorectal cancer: results from the Eastern Cooperative Oncology Group Study E3200. *J Clin Oncol* 2007;25:1539–44.
13. Kopetz S, Chang GJ, Overman MJ, Eng C, Sargent DJ, Larson DW, et al. Improved survival in metastatic colorectal cancer is associated with adoption of hepatic resection and improved chemotherapy. *J Clin Oncol* 2009;27:3677–83.
14. Tournigand C, Cervantes A, Figuer A, Lledo G, Flesch M, Buyse M, et al. OPTIMOX1: a randomized study of FOLFOX4 or FOLFOX7 with oxaliplatin in a stop-and-go fashion in advanced colorectal cancer – a GERCOR study. *J Clin Oncol* 2006;24:394–400.
15. Hochster HS, Hart LL, Ramanathan RK, Childs BH, Hainsworth JD, Cohn AL, et al. Safety and efficacy of oxaliplatin and fluoropyrimidine regimens with or without bevacizumab as first-line treatment of

Phase II of FOLFOX6 for second-line colon cancer

- metastatic colorectal cancer: results of the TREE Study. *J Clin Oncol* 2008;26:3523–9.
16. Shimizu T, Satoh T, Tamura K, Ozaki T, Okamoto I, Fukuoka M, et al. Oxaliplatin/fluorouracil/leucovorin (FOLFOX4 and modified FOLFOX6) in patients with refractory or advanced colorectal cancer: post-approval Japanese population experience. *Int J Clin Oncol*. 2007;12:218–23.
 17. Saltz LB, Clarke S, Diaz-Rubio E, Scheithauer W, Figer A, Wong R, et al. Bevacizumab in combination with oxaliplatin-based chemotherapy as first-line therapy in metastatic colorectal cancer: a randomized phase III study. *J Clin Oncol* 2008;26:2013–9.
 18. Van Cutsem E, Köhne CH, Hitre E, Zaluski J, Chang Chien CR, Makhson A, et al. Cetuximab and chemotherapy as initial treatment for metastatic colorectal cancer. *N Engl J Med* 2009; 360:1408–17.
 19. Kozloff M, Yood MU, Berlin J, Flynn PJ, Kabbinavar FF, Purdie DM, et al. Clinical outcomes associated with bevacizumab-containing treatment of metastatic colorectal cancer: the BRiTE observational cohort study. *Oncologist* 2009;14:862–70.
 20. Karapetis CS, Khambata-Ford S, Jonker DJ, O'Callaghan CJ, Tu D, Tebbutt NC, et al. K-ras mutations and benefit from cetuximab in advanced colorectal cancer. *N Engl J Med* 2008;359:1757–65.

This Provisional PDF corresponds to the article as it appeared upon acceptance. Fully formatted PDF and full text (HTML) versions will be made available soon.

Vesicocutaneous fistula formation during treatment with sunitinib malate: Case report

BMC Gastroenterology 2010, **10**:128 doi:10.1186/1471-230X-10-128

Koichiro Watanabe (kwata@oita-u.ac.jp)
Satoshi Otsu (ootu@oita-u.ac.jp)
Ryotaro Morinaga (rmorinaga@oita-u.ac.jp)
Sakura Kawano (sakura@oita-u.ac.jp)
Yoshinori Hirashima (hira@oita-u.ac.jp)
Hiroyuki Sakashita (hsakpulg@yahoo.co.jp)
Kuniaki Shirao (kshirao@oita-u.ac.jp)

ISSN 1471-230X

Article type Case report

Submission date 1 June 2010

Acceptance date 1 November 2010

Publication date 1 November 2010

Article URL <http://www.biomedcentral.com/1471-230X/10/128>

Like all articles in BMC journals, this peer-reviewed article was published immediately upon acceptance. It can be downloaded, printed and distributed freely for any purposes (see copyright notice below).

Articles in BMC journals are listed in PubMed and archived at PubMed Central.

For information about publishing your research in BMC journals or any BioMed Central journal, go to

<http://www.biomedcentral.com/info/authors/>

© 2010 Watanabe *et al.*, licensee BioMed Central Ltd.

This is an open access article distributed under the terms of the Creative Commons Attribution License (<http://creativecommons.org/licenses/by/2.0>), which permits unrestricted use, distribution, and reproduction in any medium, provided the original work is properly cited.

Vesicocutaneous fistula formation during treatment with sunitinib malate:

Case report

Koichiro Watanabe¹, Satoshi Otsu¹, Ryotaro Morinaga¹, Sakura Kawano¹, Yoshinori Hirashima¹, Hiroyuki Sakashita², and Kuniaki Shirao¹

¹Department of Medical Oncology, Oita University Faculty of Medicine

1-1 Idaigaoka, Hasama-machi, Yufu-shi, Oita 879-5593, Japan

²Department of Integrated Pulmonology, Tokyo Medical and Dental University

1-5-45 Yushima, Bunkyo-ku, Tokyo 113-8510, Japan

Email addresses:

Koichiro Watanabe <kwata@oita-u.ac.jp>, Satoshi Otsu <ootu@oita-u.ac.jp>,

Ryotaro Morinaga <rmorinaga@oita-u.ac.jp>, Sakura Kawano

<sakura@oita-u.ac.jp>, Yoshinori Hirashima <hira@oita-u.ac.jp>, Hiroyuki

Sakashita <hsakpulm@yahoo.co.jp>, Kuniaki Shirao <kshirao@oita-u.ac.jp>,

Corresponding author: Kuniaki Shirao, M.D., PhD.

Department of Medical Oncology, Oita University, Faculty of Medicine

1-1 Idaigaoka, Hasama-machi, Yufu-shi, Oita 879-5593, Japan

Tel: +81-97-586-6275; Fax: +81-97-586-6276

Email: kshirao@oita-u.ac.jp

Reprint requests to: Koichiro Watanabe, M.D., PhD.

Department of Medical Oncology, Oita University, Faculty of Medicine

1-1 Idaigaoka, Hasama-machi, Yufu-shi, Oita 879-5593, Japan

Tel: +81-97-586-6275; Fax: +81-97-586-6276

Email: kwata@oita-u.ac.jp

Abstract

Background: The oral multi-kinase inhibitor sunitinib malate improves the survival of patients with gastrointestinal stromal tumors (GIST) after the disease progresses or intolerance to imatinib mesylate develops. Urinary fistulae arising during treatment with sunitinib for GIST have not been described.

Case presentation: We describe a 62-year-old female patient diagnosed with unresectable GIST that involved the abdominal wall, urinary bladder wall, bowel, mesentery and peritoneum in the pelvic cavity. Intestinocutaneous fistulae developed on a surgical lesion after orally administered imatinib was supplemented by an arterial infusion of 5-fluorouracil. Sunitinib was started after the patient developed resistance to imatinib. On day 4 of the fourth course of sunitinib, a widely dilated cutaneous fistula discharged large amounts of fluid accompanied by severe abdominal pain. Urinary communication was indicated based on the results of an intravenous injection of indigo carmine. Computed tomography findings suggested a small opening on the anterior urinary bladder wall and fistulous communication between the bladder and abdominal walls bridged by a subcutaneous cavity. The fistula closed and the amount of discharge

decreased when sunitinib was discontinued. Therefore, sunitinib might have been associated with the development of the vesicocutaneous fistula in our patient.

Conclusion: This is the first description of a vesicocutaneous fistula forming while under sunitinib treatment. Clinicians should be aware of the possible complication of vesicocutaneous fistula formation during treatment with molecular targeting agents in patients with extravesical invasion and peritoneal dissemination of GIST.

Background

Sunitinib malate is a multi-kinase inhibitor of platelet-derived growth factor receptors (PDGFR α , PDGFR β), vascular endothelial growth factor receptors (VEGFR1, VEGFR2, VEGFR3), stem cell factor receptor (KIT), Fms-like tyrosine kinase-3 (FLT3), colony-stimulating factor receptor Type 1 (CSF-1R), and the neurotrophic factor receptor (RET) derivative of a glial cell line [1]. Sunitinib has improved clinical outcomes for patients with progressive unresectable gastrointestinal stromal tumors (GIST) or who develop intolerance to imatinib mesylate and it is reasonably well tolerated [1] [2] [3] [4] [5]. A Phase III GIST study found objective response rates in sunitinib and placebo groups of 7% and 0%, respectively ($p = 0.006$) [6]. Only 9% of patients discontinued sunitinib therapy due to adverse events compared with 8% in the control group. The most common adverse reactions that occurred in over 20% of patients were fatigue (34%), diarrhea (29%), skin discoloration (25%), nausea (24%) and anorexia (19%), and all were typically of mild to moderate intensity.

An adjacent organ is usually displaced by GIST. Fistula formation is rare in patients with untreated GIST and in those treated with sunitinib for intra-abdominal malignancies [7].

We describe the clinical aspects of a rare vesicocutaneous fistula that was associated with sunitinib therapy.

Case presentation

A 62-year-old woman was diagnosed with c-kit-positive GIST of the ascending colon with a single hepatic lesion. She was surgically treated by right hemicolectomy and partial hepatectomy. A histological assessment of a specimen of the hepatic lesion revealed GIST metastasis. Therefore, imatinib mesylate (400 mg/day) was started. After 2 years of imatinib treatment, the disease recurred in the liver, mesentery and peritoneum. Increasing the dose of imatinib to 600 mg/day did not prevent disease progression, so an arterial infusion of 5-fluorouracil (5-FU) was added to the imatinib treatment for 3 months. Thereafter, intestinocutaneous fistulae developed on the previous surgical wound and she was referred to our hospital for further treatment for recurrence.

Her baseline performance status was excellent. A physical examination revealed right-sided abdominal tenderness. A small amount of a fetid discharge exuded from the cutaneous fistulae, suggesting communication with the intestine. An ostomy bag was

therefore placed around the fistulae. Contrast-enhanced computed tomography (CT) images revealed that an abdominal mass involved the abdominal wall, urinary bladder wall, bowel, mesentery and peritoneum in the pelvic cavity (Fig. 1A and E) and that a 1.3-cm low-density lesion was located in the right lobe of the liver. Signs of active infection had been absent.

Sunitinib was initiated as a standard regimen (50 mg/day for 4 weeks, every 6 weeks) for the peritoneal and liver metastases. The patient developed mild diarrhea (NCI Common Terminology Criteria for Adverse Events; grade 2) accompanied by mild abdominal pain, fever and leukocytosis on day 11 of the first course of sunitinib. No obvious signs of infection sign were evident on CT images or in culture samples of urine, stool, blood and sputum. Sunitinib was re-administered at a dose of 37.5 mg/day. The patient developed grade 2 hypothyroidism on day 8 and grade 3 vomiting with severe dehydration on the day 18 of the second course. Therefore, sunitinib was discontinued until recovery. During the third course of sunitinib, the patient tolerated a reduced dose of 25 mg/day, despite the presence of grade 1 non-hematological toxicities such as hand-foot syndrome, nausea and diarrhea. At the end of the third course, she had frequent urination with micro-hematuria.

Leukocytopenia and elevated C-reactive protein were not found. The symptoms disappeared during antibiotic therapy.

On day 4 of the fourth course of sunitinib, the abdominal mass was reduced on CT images (Fig. 1B and F) and the hepatic mass decreased in density but not in size. Immediately after this CT examination, the patient developed severe abdominal pain with moderate muscle defense. A large amount of fluid material was concomitantly discharged from the cutaneous fistulae. Urinary communication was indicated from the results of an intravenous indigo carmine injection. The fistula orifice was markedly dilated on CT images (Fig. 1C and Fig. 2A) and a small opening in the anterior bladder wall was evident (Fig. 1G). Urinary leakage was localized in the subcutaneous cavity and pan-peritonitis was not evident. The abdominal symptoms gradually improved with decreased fluid drainage after sunitinib was discontinued. One month later, the size of the fistula had also obviously decreased (Fig. 1D and H) and the fistula orifice was closed (Fig. 2B). The clinical course indicated that sunitinib might have been associated with formation of the vesicocutaneous fistula in our patient.

Discussion

Sunitinib is reasonably well tolerated and patients with GIST seldom develop fistulae while under treatment with this drug [3] [6]. The GIST in our patient involved a cutaneous fistula on a previous surgical wound and another on the urinary bladder wall. Vesicocutaneous fistulae developed while she was under treatment with sunitinib, and healed upon discontinuing the drug. These findings indicated that sunitinib might be associated with the fistula formation.

Sunitinib reduced the tumor at the onset of vesicocutaneous fistula formation (Fig. 1B and 1F). A multi-centre phase II study (NCIC CTG Trial IND.184) evaluated the activity of sunitinib in 19 women with locally advanced or metastatic cervical carcinoma [8]. The patients enrolled in that study, including four who developed fistulae, did not achieve objective responses. On the other hand, notable tumor shrinkage resulted in the complete healing of a fistula in a patient with GIST under imatinib therapy [9]. Taken together, tumor reduction alone might not be sufficient for fistula formation and other mechanisms are suggested.

Sunitinib has potent anti-angiogenic effects and it exerts anti-tumor activities by

inhibiting blood vessel growth via inhibition of the VEGF-VEGFR pathway [5] [6].

These anti-angiogenic properties play a critical role in impaired mucosal homeostasis and wound healing. Sunitinib causes tumors to shrink and tumor cell necrosis results as a consequence of a decrease in the number of vessels and reduced blood flow in the center of tumors [6] [10]. Urinary leakage in our patient was localized to the cavity that formed between a potentially fragile urinary bladder wall and the part of the abdominal wall that involved GIST. Rapid degradation in the center of a tumor contrasting with a sustained rim of well-vascularized tumor tissue in the surrounding area can form a pseudo-capsule at the interface between a tumor and normal tissue [6].

Conclusions

This is the first description of a vesicocutaneous fistula forming while under sunitinib treatment in a patient with GIST. The anti-tumor effect of the drug might be associated in part with the development of vesicocutaneous fistulae. The tumor involved the abdominal wall, urinary bladder wall, bowel, mesentery and peritoneum in the pelvic cavity.

Clinicians should be aware of the possibility of vesicocutaneous fistula formation in

patients with peritoneal metastasis of GIST during treatment with molecular targeting agents.

Consent

Written informed consent was obtained from the patient to publish this case report and accompanying images. A copy of the written consent is available for review by the Editor-in-Chief of this journal.

Abbreviations

CT: computed tomography

NCIC CTG: National Cancer Institute of Canada Clinical Trials Group

Competing interests

The authors declare that they have no competing interests.

Authors' contributions

KW was involved in writing, reviewing, editing and finalizing the manuscript. SO and RM were involved in writing, editing and reviewing the manuscript. SK, YH and HS participated in the care of the patient and assisted in drafting the manuscript. KS was the chief oncologist involved with the case and also reviewed, edited and finalized the manuscript. All authors have read and approved the final version.

References

1. Faivre S, Delbaldo C, Vera K, Robert C, Lozahic S, Lassau N, Bello C, Deprimo S, Brega N, Massimini G, Armand JP, Scigalla P, Raymond E: **Safety, pharmacokinetic, and antitumor activity of SU11248, a novel oral multitarget tyrosine kinase inhibitor, in patients with cancer.** *J Clin Oncol* 2006, **24**(1):25-35.
2. Nishida T, Takahashi T, Nishitani A, Doi T, Shirao K, Komatsu Y, Nakajima K, Hirota S: **Sunitinib-resistant gastrointestinal stromal tumors harbor cis-mutations in the activation loop of the KIT gene.** *Int J Clin Oncol* 2009, **14**:143-149.
3. Shirao K, Nishida T, Doi T, Komatsu Y, Muro K, Li Y, Ueda E, Ohtsu A: **Phase I/II study of sunitinib malate in Japanese patients with gastrointestinal stromal tumor after failure of prior treatment with imatinib mesylate.** *Invest New Drugs* 2009, **28**(6):866-75.
4. Quek R, George S: **Update on the treatment of gastrointestinal stromal tumors (GISTs): role of imatinib.** *Biologics* 2010, **4**:19-31.
5. Faivre S, Demetri G, Sargent W, Raymond E: **Molecular basis for sunitinib efficacy and future clinical development.** *Nat Rev Drug Discov* 2007, **6**:734-745.

6. Demetri GD, van Oosterom AT, Garrett CR, Blackstein ME, Shah MH, Verweij J, McArthur G, Judson IR, Heinrich MC, Morgan JA, Desai J, Fletcher CD, George S, Bello CL, Huang X, Baum CM, Casali PG: **Efficacy and safety of sunitinib in patients with advanced gastrointestinal stromal tumour after failure of imatinib: a randomised controlled trial.** *Lancet* 2006, **368**(9544):1329-1338.
7. Judson I: **Gastrointestinal stromal tumours (GIST): biology and treatment.** *Ann Oncol* 2002, **13 Suppl 4**:287-289.
8. Mackay HJ, Tinker A, Winkvist E, Thomas G, Swenerton K, Oza A, Sederias J, Ivy P, Eisenhauer EA: **A phase II study of sunitinib in patients with locally advanced or metastatic cervical carcinoma: NCIC CTG Trial IND.184.** *Gynecol Oncol* 2010, **116**:163-167.
9. Ng EK, Wong SK, Mok TS, Chan WY, Chung SC: **Imatinib (STI-571) heals a gastrocutaneous fistula resulting from a malignant gastric stromal tumor.** *Gastric Cancer* 2003, **6**:122-126.
10. Ghanem N, Althoefer C, Furtwangler A, Winterer J, Schafer O, Springer O, Kotter E, Langer M: **Computed tomography in gastrointestinal stromal tumors.** *Eur Radiol*

2003, 13:1669-1678.

Figure Legends

Figure 1. CT findings.

U, urinary bladder; T, tumor (GIST); C, subcutaneous cavity. Tumor was located between abdominal wall (A) and urinary bladder (E) before sunitinib therapy.

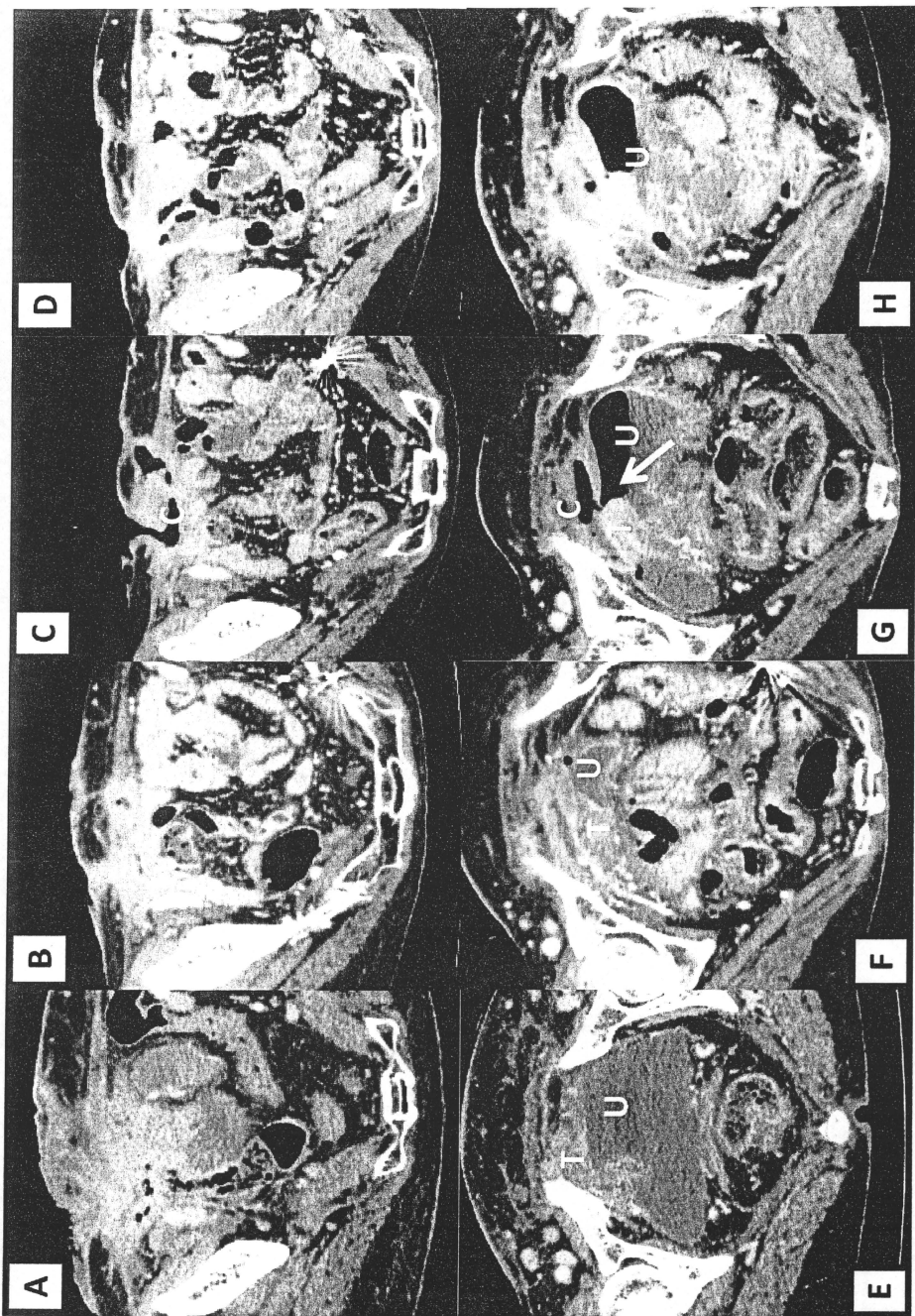
Abdominal tumor was smaller on day 4 of fourth course of sunitinib (B and F).

Vesicocutaneous fistula bridged by subcutaneous cavity at onset of abdominal pain (C and G). Small opening (arrow) at anterior bladder wall. Air collected in urinary bladder.

Fistula healed after sunitinib discontinuation (D and H) and subcutaneous cavity became smaller.

Figure 2. Gross findings on day 4 of fourth course of sunitinib (A) and after its discontinuation (B).

Cutaneous fistula orifice closed after sunitinib discontinuation.



Prior to sunitinib treatment **Before the onset of abdominal pain** **After the onset of abdominal pain** **After discontinuation of sunitinib treatment**
 Figure 1