

magnifying WLI and magnifying NBI for gastric SDLs. All lesions were examined with WLI followed by NBI sequentially, and then this study provided a comparison of the diagnostic yield of WLI and WLI followed by NBI. From this perspective, we could conclude that adding NBI to the WLI examination markedly improved the diagnostic accuracy of gastric SDLs compared with magnifying WLI alone.

This study may have other limitations in that the two modalities were compared by using magnifying endoscopy. The current global standard is to use nonmagnifying WLI. Therefore, as the next step, we should investigate whether magnifying NBI is superior to the conventional nonmagnifying WLI. We are now conducting a multicenter, randomized, controlled trial to compare magnifying NBI with nonmagnifying WLI (UMIN Clinical Trials Registry ID C000001072).

In summary, we demonstrated that adding NBI to the WLI examination is essential for making an accurate diagnosis of gastric SDLs compared with magnifying WLI alone and demonstrated the high reliability of DL and IMVP as diagnostic criteria for gastric SDLs. The excellent diagnostic capacity of magnifying NBI should allow the diagnosis of most SDLs without the need for a biopsy, which should decrease the number of unnecessary biopsy specimens. In addition, magnifying NBI should enhance the early detection of gastric cancer, which should facilitate endoscopic treatments such as EMR and endoscopic submucosal dissection. Magnifying NBI will also benefit the patient because its examination time is no longer than that of magnifying WLI despite its excellent performance.

## REFERENCES

1. Parkin DM, Bray FI, Devesa SS. Cancer burden in the year 2000. The Global Picture. *Eur J Cancer* 2001;37(Suppl 8):S4-66.
2. Muto M, Katada C, Sano Y, et al. Narrowband imaging: a new diagnostic approach to visualize angiogenesis in the superficial neoplasm. *Clin Gastroenterol Hepatol* 2005;3:S16-20.
3. Ugumori T, Muto M, Hayashi R, et al. Prospective study of early detection of pharyngeal superficial carcinoma with the narrowband imaging laryngoscope. *Head Neck* 2009;31:189-94.
4. Yoshida T, Inoue H, Usui S, et al. Narrow-band imaging system with magnifying endoscopy for superficial esophageal lesions. *Gastrointest Endosc* 2004;59:288-95.
5. Inoue H, Honda T, Nagai K, et al. Ultra-high magnification endoscopic observation of carcinoma in situ of the oesophagus. *Dig Endosc* 1997;9:16-18.
6. Hamamoto Y, Endo T, Noshio K, et al. Usefulness of narrow-band imaging endoscopy for diagnosis of Barrett's esophagus. *J Gastroenterol* 2004;39:14-20.
7. Kara MA, Peters FP, Rosmolen WD, et al. High-resolution endoscopy plus chromoendoscopy or narrow-band imaging in Barrett's esophagus: a prospective randomized crossover study. *Endoscopy* 2005;37:929-36.
8. Uedo N, Ishihara R, Iishi H, et al. A new method of diagnosing gastric intestinal metaplasia: narrow band imaging with magnifying endoscopy. *Endoscopy* 2006;38:819-24.
9. Tamai N, Kaise M, Nakayoshi T, et al. Clinical and endoscopic characterization of depressed gastric adenoma. *Endoscopy* 2006;38:391-4.
10. Sumiyama K, Kaise M, Nakayoshi T, et al. Combined use of a magnifying endoscope with a narrow band imaging system and a multibending endoscope for en bloc EMR of early stage gastric cancer. *Gastrointest Endosc* 2004;60:79-84.
11. Machida H, Sano Y, Hamamoto Y, et al. Narrow-band imaging in the diagnosis of colorectal mucosal lesions: a pilot study. *Endoscopy* 2004;36:1094-8.
12. Sano Y, Muto M, Tajiri H, et al. Optical/digital chromoendoscopy during colonoscopy using narrow-band imaging system. *Dig Endosc* 2005;17: S43-8.
13. Yao K, Ohishi T, Matsui T, et al. Novel magnified endoscopic findings of microvascular architecture in intramucosal gastric cancer. *Gastrointest Endosc* 2002;56:279-84.
14. Yao K, Iwashita A, Tanabe H, et al. Novel zoom endoscopy technique for diagnosis of small flat gastric cancer: a prospective, blind study. *Clin Gastroenterol Hepatol* 2007;7:869-78.
15. Gono K, Yamazaki K, Doguchi N, et al. Endoscopic observation of tissue by narrow band illumination. *Opt Rev* 2003;10:1-5.
16. Gono K, Obi T, Yamaguchi M, et al. Appearance of enhanced tissue feature in narrow-band endoscopic imaging. *J Biomed Opt* 2004;9:568-77.
17. Nakayoshi T, Tajiri H, Matsuda K, et al. Magnifying endoscopy combined with narrow band imaging system for early gastric cancer: correlation of vascular pattern with histopathology. *Endoscopy* 2004;36:1080-4.
18. Schlemper RJ, Riddell RH, Kato Y, et al. The Vienna classification of gastrointestinal epithelial neoplasia. *Gut* 2000;47:251-5.

Official Organ of the European Society of Gastrointestinal Endoscopy (ESGE) and affiliated societies

# Endoscopy

## Editor-In-Chief

T. Rösch, Germany

## Co-Editors

G. Costamagna, Italy  
J. Devière, Belgium  
P. Fockens, The Netherlands  
H. Neuhaus, Germany  
T. Ponchon, France  
N. Vakil, USA  
K. Yasuda, Japan

## Section Editors

J. Baillie, USA (Clinical Case Conference)  
J. Bergman, The Netherlands (Expert Approach and Innovation Forum Sections)  
J-F. Rey, France, T. Sauerbruch, Germany (Guidelines)

## Assistant Editor

H. Pohl, Germany

## Managing Editor

H. Hamilton-Gibbs, Germany

## Chief Copy Editor

T. Brady, UK

## Editorial Assistants

T. Michelberg, Germany  
F. Heidenreich, Germany

## Statistical Advisors

Principal Advisor:  
K. Ulm, Germany  
Advisors:  
S. Wagenpfeil, Germany  
R. Hollweck, Germany

## Advisory Board

M. Classen, Germany  
M. Cremer, Belgium  
J. Geenen, USA  
G. A. Lehman, USA  
N. Soehendra, Germany  
H. Suzuki, Japan  
G. Tytgat, The Netherlands  
C. Williams, UK

## ESGE

### European Society of Gastrointestinal Endoscopy (ESGE)

J. Devière, Belgium (President)  
G. Costamagna, Italy (President Elect)  
J-F. Rey, France (Past President)  
S. D. Ladas, Greece (Vice President)  
P. Fockens, The Netherlands (Secretary General)  
H. Neuhaus, Germany (Treasurer)  
L. Aabakken, Norway (Chairman, Education Committee)  
C. Gheorghe, Romania  
J. Morris, UK  
I. Mostafa, Egypt  
M. Muñoz, Spain  
I. Rácz, Hungary  
S. Rejchrt, Czech Republic  
T. Rösch, Germany (Endoscopy Journal)

Address  
European Society of Gastrointestinal Endoscopy (ESGE)  
HG Editorial & Management Services  
Mauerkircher Str. 29  
81679 Munich  
Germany  
Tel. + 49-89-20 14856  
Fax + 49-89-20 20 64 59  
Email: secretariat@esge.com

## Former Editors

L. Demling, Germany  
M. Classen, Germany

## Publishers

**Georg Thieme Verlag KG**  
Ruedigerstraße 14  
D-70469 Stuttgart  
P.O. Box 30 11 20  
70451 Stuttgart  
Germany

**Thieme Medical Publishers, Inc.**  
333 Seventh Avenue  
USA, New York, NY 10001

For subscription information  
please contact: [endoscopy@thieme.de](mailto:endoscopy@thieme.de)

## Reprint

Volume 42 · 2010

© Georg Thieme Verlag KG

Reprint with the permission  
of the publishers only

# Narrow band imaging for detecting superficial squamous cell carcinoma of the head and neck in patients with esophageal squamous cell carcinoma

## Authors

C. Katada<sup>1</sup>, S. Tanabe<sup>1</sup>, W. Koizumi<sup>1</sup>, K. Higuchi<sup>1</sup>, T. Sasaki<sup>1</sup>, M. Azuma<sup>1</sup>, N. Katada<sup>2</sup>, T. Masaki<sup>3</sup>, M. Nakayama<sup>3</sup>, M. Okamoto<sup>3</sup>, M. Muto<sup>4</sup>

## Institutions

<sup>1</sup> Department of Gastroenterology, Kitasato University School of Medicine, Sagami-hara, Japan

<sup>2</sup> Department of Surgery, Kitasato University School of Medicine, Sagami-hara, Japan

<sup>3</sup> Department of Otorhinolaryngology, Kitasato University School of Medicine, Sagami-hara, Japan

<sup>4</sup> Department of Gastroenterology and Hepatology, Graduate School of Medicine Kyoto University, Kyoto, Japan

## submitted

4 September 2009

accepted after revision

23 December 2009

## Bibliography

DOI <http://dx.doi.org/10.1055/s-0029-1243963>

Endoscopy 2010; 42:

185–190 © Georg Thieme

Verlag KG Stuttgart · New York

ISSN 0013-726X

## Corresponding author

C. Katada, MD

Department of  
Gastroenterology  
Kitasato University School of  
Medicine

1-15-1 Kitasato

Sagami-hara 228-8555, Japan

Fax: +81-42-7498690

ckatada@med.kitasato-u.ac.jp

**Background and study aims:** Narrow band imaging combined with magnifying endoscopy (NBI-ME) is useful for the detection of superficial squamous cell carcinoma (SCC) within the oropharynx, hypopharynx, and oral cavity. The risk of a second primary SCC of the head and neck is very high in patients with esophageal SCC. This prospective study evaluated the detection rate of superficial SCC within the head and neck region (superficial SCCHN) with NBI-ME in patients with esophageal SCC.

**Patients and methods:** Between March 2006 and February 2008, 112 patients with a current or previous diagnosis of esophageal SCC were enrolled. All patients underwent endoscopic screening of the head and neck by NBI-ME. The primary end point was the detection rate for superficial SCCHN. Secondary end points were to compare

demographic characteristics between patients with and without superficial SCCHN and to assess the clinical course of patients with superficial SCCHN.

**Results:** The detection rate for superficial SCCHN was 13% (15/112). The prevalence of multiple Lugol-voiding lesions, observed endoscopically throughout the esophageal mucosa after application of Lugol dye solution, was significantly higher in patients with superficial SCCHN than in those without (100% vs. 24%,  $P < 0.0001$ ). Minimally invasive curative treatment with organ preservation was feasible without severe complications in patients with superficial SCCHN after curative treatment of esophageal SCC.

**Conclusions:** In patients with esophageal SCC, NBI-ME is useful for detecting superficial SCCHN, thereby facilitating minimally invasive treatment.

## Introduction

Gastrointestinal endoscopy is an essential technique for the diagnosis of esophageal and gastrointestinal lesions. Narrow band imaging (NBI) is a novel optical technique that enhances the diagnostic capability of gastrointestinal endoscopy by highlighting the intraepithelial papillary capillary loops of the squamous cell mucosa by means of light passed through filters that narrow the spectral bandwidths, incorporated into a red–green–blue sequential illumination system [1]. It has previously been reported that NBI combined with magnifying endoscopy (NBI-ME) could detect superficial squamous cell carcinoma (superficial SCC) within the oropharynx, hypopharynx, and oral cavity [2–5]. Muto et al. reported that NBI-ME had higher rates for both detection and diagnostic accuracy for superficial SCC within the head and neck region (superficial SCCHN) than did conventional white light observation with magnifying endoscopy on back-to-back endoscopic examination [6].

Since in patients with esophageal cancer the most common site for synchronous and metachronous second primary malignancies is the head and neck [7–9], we prospectively studied the ability of NBI-ME to detect superficial SCCHN in patients with a current or previous diagnosis of esophageal SCC.

## Patients and methods

Between March 2006 and February 2008, 112 patients were enrolled who met the following criteria: (i) a current or previous diagnosis of esophageal SCC; (ii) age of at least 20 years; (iii) no history of head and neck cancer; (iv) no symptoms of the head and neck; (v) no previous surgical treatment or radiotherapy of the head and neck; and (vi) no previous endoscopic screening of the head and neck by NBI-ME. The study protocol and informed consent form were approved by our institutional review board in February 2006.

Written informed consent was obtained from all patients.

The patients underwent endoscopic screening of the head and neck by NBI-ME. In this study, we performed NBI using a high definition video endoscopy system (CV-260SL, processor, CLV-260SL light source; Olympus Optical Co., Tokyo, Japan) and an optical magnifying endoscope with a system that could magnify objects up to 80 times (GIF Q240Z video endoscope; Olympus). The diameter of the GIF Q240Z video endoscope was 10.2 mm, and the flexibility was similar to that of a conventional gastrointestinal endoscope. Screening was done in the following order: (i) observation with shifting of the tongue to create sufficient space for screening the oral cavity without mouth gear, and (ii) observation with vocal exercise to create sufficient space for screening the oropharyngeal, hypopharyngeal, and laryngeal regions with mouth gear.

The primary end point was the detection rate of superficial SCCHN by endoscopic screening using NBI-ME in patients with a current or previous diagnosis of esophageal SCC. Secondary end points were: (i) to compare demographic characteristics between patients with and those without superficial SCCHN, and (ii) to assess the clinical course of patients with superficial SCCHN.

Because prospective studies assessing the ability of NBI to detect early, superficial SCCHN have not been reported previously, it was difficult to estimate the required sample size. We therefore set the study period at 2 years, during which we estimated that at least 100 patients could be enrolled.

Only superficial cancers, that is, microinvasive SCC and high grade intraepithelial neoplasia as defined by the World Health Organization classification of tumors, were studied [10]. An NBI diagnosis of superficial SCC required the presence of both (i) a well-demarcated brownish area, and (ii) an irregular microvascular pattern [2–4]. Examples of superficial SCC in the left piriform sinus, the left superior wall of the oropharynx, and the left side of the tongue are shown in **○ Figs. 1–3**. Conventional white light observation showed a slightly reddish area with mild mucosal irregularity (**○ Figs. 1 a, 2 a, and 3 a**). NBI showed a well-demarcated brownish area (**○ Figs. 1 b, 2 b, and 3 b**). NBI combined with maximum magnification ( $\times 80$ ) showed an irregular microvascular pattern (**○ Figs. 1 c, 2 c, and 3 c**).

Biopsy specimens were taken after the completion of screening for all superficial cancers in the head and neck region. Before biopsy in the laryngeal region, 4% lidocaine solution was sprayed through the endoscope to attenuate the gag reflex. Resected specimens, biopsy specimens, or both, were evaluated histopathologically. The histological characteristics of neoplasms were classified according to the World Health Organization criteria for esophageal tumors [10]. We used the histological diagnosis as the gold standard diagnosis. Although the results of endoscopy were not blinded, the histological diagnosis was confirmed by two gastrointestinal pathologists.

Lugol chromoendoscopy of the esophageal mucosa was carried out in all patients, using the Lugol dye staining method [11]. A 1.5% solution of Lugol dye was used in this study. Multiple Lugol-voiding lesions (LVLs) were defined to be numerous, well-defined, irregularly shaped lesions that appeared throughout the entire esophageal mucosa after the application of Lugol dye solution [12, 13].

Because the oral cavity and superior wall of the oropharynx could easily be accessed by a surgical device, transoral surgical mucosectomy (TSM) of lesions in such regions was done by a head and neck surgeon, with the patient under general anesthesia. Lesions were removed using an electric surgical knife or carbon di-

oxide laser, without injecting saline beneath the epithelium to lift the lesion above the surrounding mucosa [4]. If a transoral direct surgical approach was difficult, endoscopic mucosal resection (EMR) was performed by a gastrointestinal endoscopist with the patient under general anesthesia; lesions were removed using a transparent, soft plastic cap [2, 14]. We used an orotracheal route for intubation at the time of EMR. However, in patients who underwent TSM because a transoral direct surgical approach was possible, a nasotracheal route was used for intubation to secure a good operative field.

In patients with superficial SCCHN treated with curative intent, follow-up examinations by NBI-ME and computed tomography (CT) examination were repeated at least every 6 months after treatment. The duration of follow-up was longer than 1 year in this study.

All statistical analyses were carried out using the StatView software package for Macintosh (Version 5; Abacus Concepts, Inc., Berkeley, California, USA). The significance of differences was assessed with Fisher's exact test. *P* values of  $< 0.05$  were considered to indicate statistical significance.

## Results

### ▼

#### Patient characteristics

Patient characteristics are shown in **○ Table 1**. The study group comprised 100 men (89%) and 12 women (11%), with a mean age ( $\pm$  SD) of  $67 \pm 7.5$  years. The clinical stage of esophageal cancer was stage I in 42 patients (38%), stage II in 26 (23%), stage III in 32 (29%), and stage IV in 12 (11%).

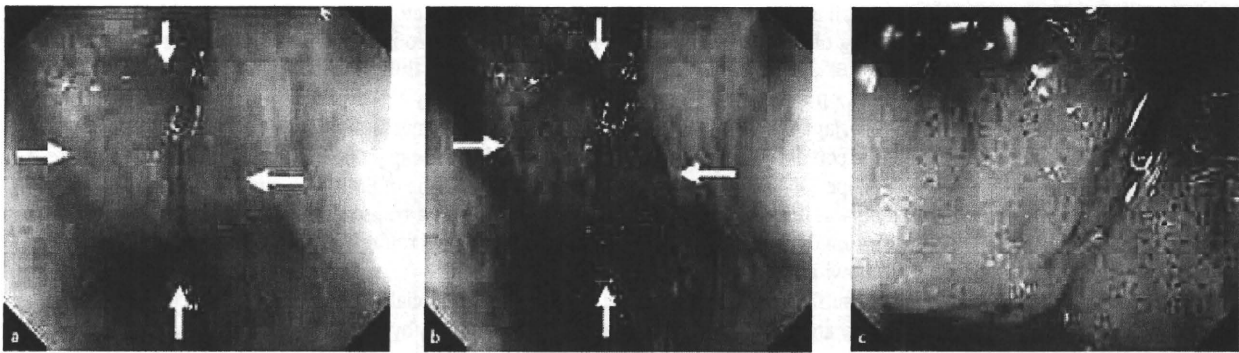
Of the patients, 80 (71%) had a current diagnosis of esophageal SCC and it had been previously diagnosed in 32 (29%). There was a history of cancer in other organs in 12 patients (11%): gastric cancer in 7 (6%), lung cancer in 2 (2%), liver cancer in 1 (1%), bladder cancer in 1 (1%), and leukemia in 1 (1%). The remaining 100 patients (89%) had no history of cancer in other organs.

Habitual alcohol use was reported by 101 patients (90%), and 98 (88%) were smokers. Multiple LVLs of esophageal mucosa were found in 38 patients (34%).

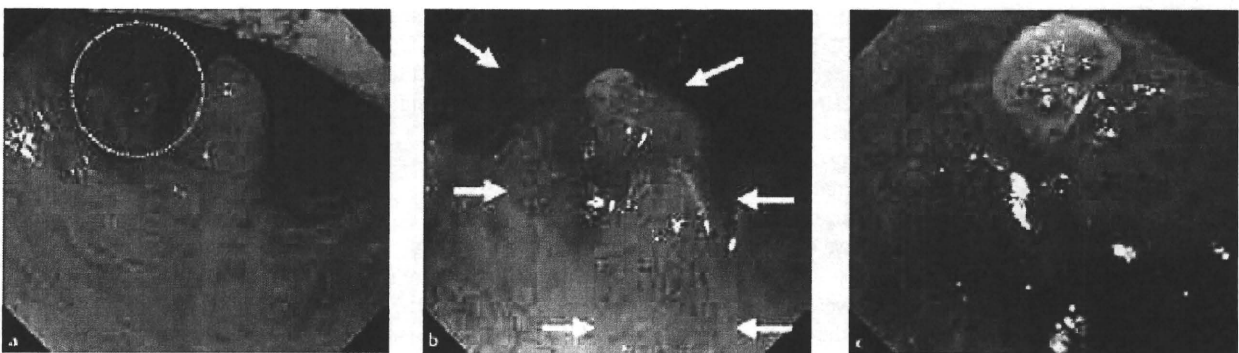
#### Detection of superficial SCCHN

The detection rate for superficial SCCHN was 13% (15/112), with 16 lesions detected in 15 patients. One patient had two lesions, 1 each in oropharyngeal and hypopharyngeal mucosal sites. No advanced cancer was detected. The 16 lesions comprised 3 (19%) detected in the oral cavity, 4 (25%) in the oropharynx, and 9 (56%) in the hypopharynx (**○ Table 2**); no laryngeal cancer was detected. For 8 of the 16 lesions, biopsy specimen and resection specimens were available for histological evaluation; for the remaining 8 lesions, only biopsy specimens were available since these patients were treated with techniques other than surgical or endoscopic resection. All 16 superficial SCCHNs were diagnosed endoscopically and confirmed histopathologically.

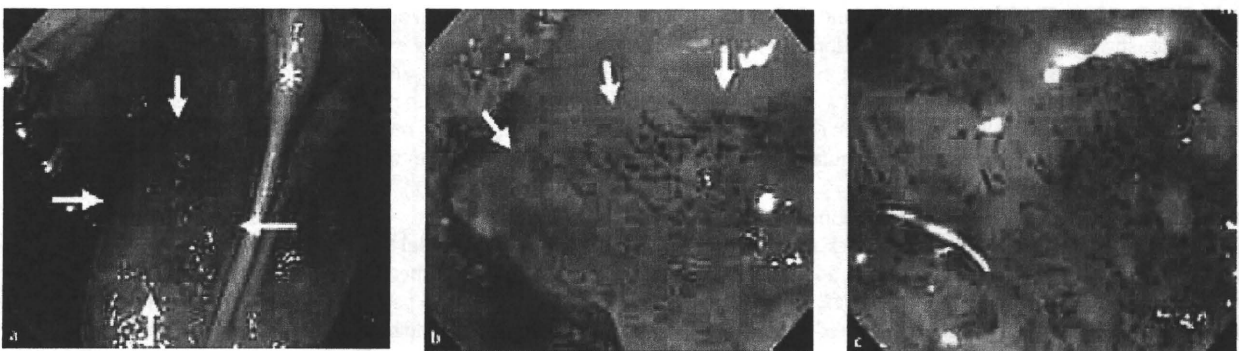The characteristics of patients with and without superficial SCCHN are compared in **○ Table 3**. The prevalence of multiple LVLs of the background esophageal mucosa was significantly higher in patients with superficial SCCHN (100% vs. 24%,  $P < 0.0001$ ). Other characteristics did not differ significantly between the groups.



**Fig. 1** Superficial squamous cell carcinoma in the left piriform sinus of the hypopharynx. **a** Conventional white light observation showed a slightly reddish area with mild mucosal irregularity (arrows). **b** Narrow band imaging (NBI) showed a well-demarcated brownish area (arrows). **c** NBI combined with maximum magnification ( $\times 80$ ) showed an irregular microvascular pattern.



**Fig. 2** Superficial squamous cell carcinoma in the left superior wall of the oropharynx. **a** Conventional white light observation showed a slightly reddish area with mild mucosal irregularity (dotted line). **b** Narrow band imaging (NBI) showed a well-demarcated brownish area (arrows). **c** NBI combined with maximum magnification ( $\times 80$ ) showed an irregular microvascular pattern.



**Fig. 3** Superficial squamous cell carcinoma in the left side of the tongue. **a** Conventional white light observation showed a slightly reddish area with mild mucosal irregularity (arrows). **b** Narrow band imaging (NBI) showed a well-demarcated brownish area (arrows). **c** NBI combined with maximum magnification ( $\times 80$ ) showed an irregular microvascular pattern.

### Treatment and course

In the 15 patients with superficial SCCHN, their esophageal cancer had been previously diagnosed in 3 and had been currently (at the time of the present study) diagnosed in 12. Because 10 patients were transiently disease-free after treatment for esophageal cancer, their superficial SCCHNs were treated with curative intent.

○ **Fig. 4** summarizes the clinical courses of the ten patients in whom 11 superficial SCCHNs were treated with curative intent. Of the 11 lesions, 8 were resected (TSM 4, EMR 4; see below for further details); 2 lesions arising in the piriform sinus were treated by chemoradiotherapy [15]; and another 1 lesion in the piriform sinus by radiotherapy. The patient receiving radiotherapy

for this hypopharyngeal SCCHN had two lesions and underwent TSM for an oropharyngeal lesion.

All of these patients were followed up every 6 months for at least 1 year. The average follow-up period ( $\pm$  SD) was  $25 \pm 6.3$  months (range 14–33), and the average number of examinations per patient ( $\pm$  SD) was  $4.8 \pm 1$  (range 3–6). No recurrent or newly diagnosed superficial SCCHN was detected during follow up.

One patient had synchronous advanced esophageal cancer and superficial SCC of the oral cavity, which were treated by chemoradiotherapy and TSM, respectively. However, this patient died because of recurrence of the esophageal cancer. The superficial SCC of the oral cavity was unrelated to the cause of death. With a median follow-up period of 29 months (range 14–33), all of

**Table 1** Characteristics of patients (n = 112) and lesions.

Men, n (%)	100 (89%)
Age, mean $\pm$ SD, years	67 $\pm$ 7.5
Clinical stage of esophageal cancer, n (%)	
I	42 (38%)
II	26 (23%)
III	32 (29%)
IV	12 (11%)
Esophageal cancer	
Current	80 (71%)
Previous	32 (29%)
History of cancer in other organs, n (%)	
None	100 (89%)
Stomach	7 (6%)
Lung	2 (2%)
Liver	1 (1%)
Bladder	1 (1%)
Leukemia	1 (1%)
Habitual alcohol use, n (%)	
Yes	101 (90%)
No	11 (10%)
Smoking, n (%)	
Yes	98 (88%)
No	14 (13%)
Multiple Lugol-voiding lesions, n (%)	
Yes	38 (34%)
No	74 (66%)

the other patients have remained disease-free without severe complications.

**Resections.** Regarding the 8 resected superficial SCCHNs, 2 lesions arose in the oral cavity, and 2 in the oropharynx, and these were removed by TSM; the remaining 4, in the hypopharynx, were all removed by EMR.

The average resected tumor size ( $\pm$ SD) was 18  $\pm$  5 mm (range 10–25). No lesion was <10 mm in diameter, 3 were  $\geq$  10 to <20 mm in diameter, and 5 were  $\geq$  20 to <30 mm in diameter.

Histologically, 4 of these lesions were high grade intraepithelial neoplasia, and 4 were microinvasive SCC. Two of the microinvasive SCCs were treated by EMR, and the deep resection margins in both patients were free of tumor. Lymphatic or vessel invasion was not found in any resected specimen.

In two patients with hypopharyngeal lesions, laryngeal edema developed during the EMR procedure. This complication was treated by temporary tracheotomy. No patient had bleeding, stenosis, or perforation as a complication of resection. The median follow-up period was 27 months (range, 14–33 months), and, as noted above, 1 of the 8 patients died of recurrent esophageal cancer.

**Table 2** Detection rate and location of superficial squamous cell carcinomas in the head and neck region (superficial SCCHN) in 112 patients with a previous or current diagnosis of esophageal cancer.

Detection rate per-patient, % (n/n)	13% (15/112)
Detected lesions, n	16
<b>Tumor location</b>	
Oral cavity	3 (19%)
Tongue	2 (13%)
Hard palate	1 (6%)
Oropharynx	4 (25%)
Superior wall	3 (19%)
Posterior wall	1 (6%)
Hypopharynx	9 (56%)
Piriform sinus	5 (31%)
Postcricoid area	4 (25%)
Larynx	0 (0%)

## Discussion

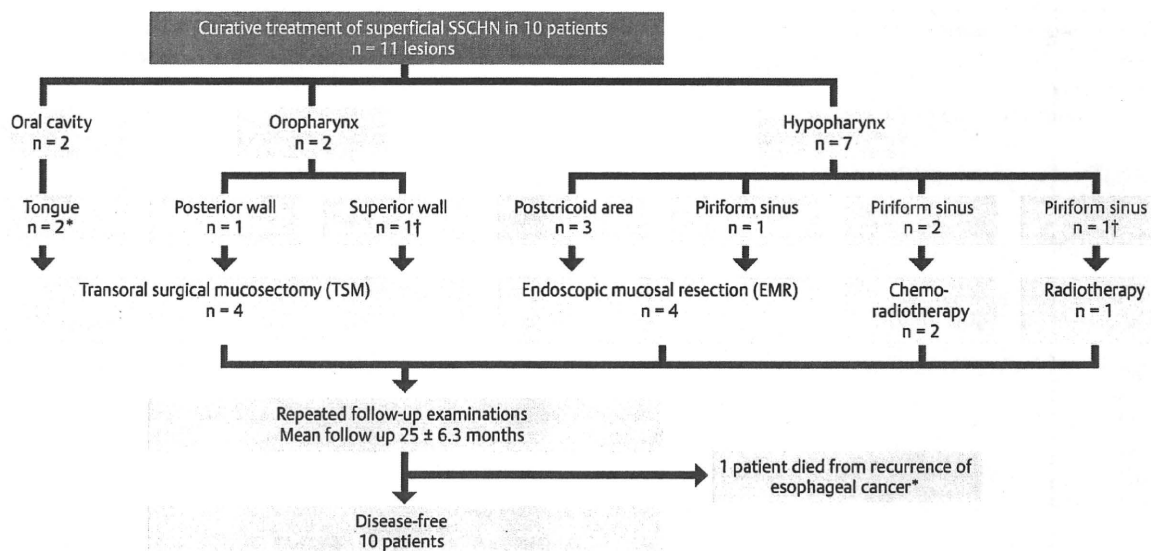
Annually, about 50000 cases of SCCHN are newly diagnosed worldwide annually. Tumors of the hypopharynx are particularly problematic because they are usually diagnosed at an advanced stage and carry a poor prognosis [16–19]. Recent studies have reported that NBI-ME is useful for the detection of superficial SCCHN [2–5]. In patients with esophageal cancer, synchronous and metachronous second primary malignancies most commonly arise in the upper aerodigestive organs, including the head and neck, stomach, and lung [7–9,20–22]. An exceptionally strong association of esophageal cancer with head and neck cancer has been reported [7–9,23,24]. Matsubara et al. reported that the risk of head and neck cancer markedly increases after esophagectomy (relative risk 34.9; 95%CI 24.3–48.6). The 5-year cumulative risk of developing head and neck cancer was estimated to be 7% [9]. Consistent with these results, the detection rate of a second head and neck cancer in patients who had previously had esophageal cancer was 9% (3/32) in our study. These findings suggest that endoscopic screening of the head and neck region by NBI-ME may substantially contribute to the early detection of head and neck cancer in patients with esophageal SCC. In the future, large prospective follow-up studies are needed to establish the optimal interval for surveillance by NBI-ME after treatment for esophageal SCC.

In the esophagus and head and neck region, the development of multiple primary SCCs and widespread epithelial oncogenic alterations, including carcinoma in situ, dysplasia, and hyperkeratosis, have long been a recognized phenomenon [25]. Clinically, Lugol chromoendoscopy can be used to visualize epithelial changes such as multiple LVLs, since dysplastic or hyperkeratotic epithelium does not stain with Lugol iodine solution and appears white or pink, whereas normal epithelium is stained brown

	With superficial SCCHN n = 15	Without superficial SCCHN n = 97	P value
Males	15 (100%)	85 (88%)	0.36
Older ( $\geq$ 70 years)	3 (20%)	35 (36%)	0.26
Current esophageal cancer	12 (80%)	68 (70%)	0.55
History of cancer in other organs	3 (20%)	9 (9%)	0.2
Habitual alcohol use	15 (100%)	86 (89%)	0.35
Smoking	15 (100%)	83 (86%)	0.21
Habitual alcohol use with smoking	15 (100%)	83 (86%)	0.21
Multiple Lugol-voiding lesions (LVLs)	15 (100%)	23 (24%)	<0.0001

\* P values were calculated using Fisher's exact test.

**Table 3** Comparison of demographic characteristics between those with and those without superficial squamous cell carcinomas in the head and neck region (superficial SCCHN), in 112 patients with a previous or current diagnosis of esophageal cancer.



**Fig. 4** Clinical course of curative treatment of 11 lesions in 10 patients with superficial squamous cell carcinoma within the head and neck region (superficial SCCHN). \* One patient died of recurrent esophageal cancer; † one patient had 2 lesions, 1 each in oropharyngeal and hypopharyngeal mucosal sites.

[11, 12]. Multiple LVLs of esophageal mucosa are considered precursors for a second primary esophageal cancer in patients with head and neck cancer [12], and have also been associated with a very high risk of multiple cancers in the esophagus, as well as the head and neck [13, 26, 27]. In our study, the prevalence of multiple LVLs of esophageal mucosa was significantly increased in patients with superficial SCCHN. The presence of multiple LVLs of esophageal mucosa may therefore be a powerful biomarker for detecting a second primary superficial SCCHN. The Lugol dye staining method cannot be used in the head and neck region because it causes severe mucosal irritation, leading to pain and discomfort; the dye solution may even be aspirated into the airway. Therefore, patients with esophageal cancer who have multiple LVLs of the esophageal mucosa should undergo careful endoscopic screening of the head and neck by NBI-ME.

Effective treatment of superficial SCCHN is considered essential for cure in patients with esophageal SCC, but definitive studies are lacking. The safety and efficacy of follow-up treatment for superficial SCC thus remains unclear. In our series, curative treatment of superficial SCCHN was possible without severe complications in all patients in whom the esophageal SCC was successfully treated. Although 2 of 4 patients (50%) had laryngeal edema during the EMR procedure, which was treated by temporary tracheotomy, the incidence of laryngeal edema can be lowered by minimizing mechanical stimulation caused by contact with surgical devices and chemical stimulation caused by Lugol dye solution on the laryngeal and hypopharyngeal regions at the time of treatment. All patients who underwent curative treatment remained disease-free and retained their larynx. Our results suggest that minimally invasive curative treatment with organ preservation is possible in patients with superficial SCCHN. Since EMR or TSM of head and neck region is less invasive than chemoradiotherapy or radiotherapy, expected benefits should be weighed against potential risks when selecting the treatment strategy. If superficial SCCHN is detected in patients with esophageal SCC, our results may suggest important clues for disease management. In the future, more definitive studies are needed

to clarify the safety and efficacy of follow-up treatment for superficial SCCHN.

In conclusion, our results suggest that endoscopic screening by NBI-ME is useful for the detection of superficial SCCHN in patients with esophageal SCC. In particular, patients with multiple LVLs of the esophageal mucosa should be closely monitored to facilitate early detection of superficial SCCHN and permit minimally invasive curative treatment with organ preservation.

**Competing interests:** None

#### References

- Gono K, Obi T, Yamaguchi M et al. Appearance of enhanced tissue feature in narrow-band endoscopic imaging. *J Biomed Opt* 2004; 9: 568–577
- Muto M, Nakane M, Katada C et al. Squamous cell carcinoma in situ at oropharyngeal and hypopharyngeal mucosal sites. *Cancer* 2004; 101: 1375–1381
- Muto M, Katada C, Yasushi S et al. Narrow band imaging: a new diagnostic approach to visualize angiogenesis in superficial neoplasia. *Clin Gastroenterol Hepatol* 2005; 3: 16–20
- Katada C, Nakayama M, Tanabe S et al. Narrow band imaging for detecting superficial oral squamous cell carcinoma. *Laryngoscope* 2007; 117: 1596–1599
- Nonaka S, Saito Y. Endoscopic diagnosis of pharyngeal carcinoma by NBI. *Endoscopy* 2008; 40: 347–351
- Muto M, Saito Y, Ohmori T et al. Multicenter prospective randomized controlled study on the detection and diagnosis of superficial squamous cell carcinoma by back-to-back endoscopic examination of narrow band imaging and white light observation. *Gastrointest Endosc* 2007; 65: AB110–0
- Shibuya H, Wakita T, Nakagawa T et al. The relation between an esophageal cancer and associated cancers in adjacent organs. *Cancer* 1995; 76: 101–105
- Begg CB, Zhang ZF, Sun M et al. Methodology for evaluating the incidence of second primary cancers with application to smoking-related cancers from the surveillance, epidemiology, and end results (SEER) program. *Am J Epidemiol* 1995; 142: 653–665
- Matsubara T, Yamada K, Nakagawa A. Risk of second primary malignancy after esophagectomy for squamous cell carcinoma of the thoracic esophagus. *J Clin Oncol* 2003; 21: 4336–4341

- 10 Hamilton SR, Aaltonen LA. World Health Organization classification of tumors. Pathology and genetics of tumors of the digestive system. Lyon: IARC Press, 2000: 9–30
- 11 Inoue H, Rey JF, Lightdale C. Lugol chromoendoscopy for esophageal squamous cell cancer. *Endoscopy* 2001; 33: 75–79
- 12 Muto M, Hironaka S, Nakane M et al. Association of multiple Lugol-voiding lesions with synchronous and metachronous esophageal squamous cell carcinoma in patients with head and neck cancer. *Gastrointest Endosc* 2002; 56: 517–521
- 13 Muto M, Takahashi M, Ohtsu A et al. Risk of multiple squamous cell carcinomas both in the esophagus and the head and neck region. *Carcinogenesis* 2005; 26: 1008–1012
- 14 Inoue H, Endo M, Takeshita K et al. A new simplified technique of endoscopic mucosal resection using a capfitted panendoscope (EMRC). *Surg Endosc* 1992; 6: 264–265
- 15 Ohtsu A, Yoshida S, Boku N et al. Concurrent chemotherapy and radiation therapy for locally advanced carcinoma of the esophagus. *Jpn J Clin Oncol* 1995; 25: 261–266
- 16 Kraus DH, Zelefsky MJ, Brock HA et al. Combined surgery and radiation therapy for squamous cell carcinoma of the hypopharynx. *Otolaryngol Head Neck Surg* 1997; 116: 637–641
- 17 Wahlberg PC, Andersson KE, Biorklund AT et al. Carcinoma of the hypopharynx: analysis of incidence and survival in Sweden over a 30-year period. *Head Neck* 1998; 20: 714–719
- 18 Johansen LV, Grau C, Overgaard J. Hypopharyngeal squamous cell carcinoma – treatment results in 138 consecutively admitted patients. *Acta Oncol* 2000; 39: 529–536
- 19 Eckel HE, Staar S, Volling P et al. Surgical treatment for hypopharynx carcinoma: feasibility, mortality, and results. *Otolaryngol Head Neck Surg* 2001; 124: 561–569
- 20 Poon RTP, Law SYK, Chu KM et al. Multiple primary cancers in esophageal squamous cell carcinoma: Incidence and implications. *Ann Thorac Surg* 1998; 65: 1529–1534
- 21 Hoar SK, Wilson J, Blot WJ et al. Second cancer following cancer of the digestive system in Connecticut, 1935–82. *Natl Cancer Inst Monogr* 1985; 68: 49–82
- 22 Fogel TD, Harrison LB, Son YH. Subsequent upper aerodigestive malignancies following treatment of esophageal cancer. *Cancer* 1985; 55: 1882–1885
- 23 Petit T, Georges C, Jung GM et al. Systematic esophageal endoscopy screening in patients previously treated for head and neck squamous-cell carcinoma. *Ann Oncol* 2001; 12: 643–646
- 24 Dubuc J, Legoux JL, Winnock M et al. Endoscopic screening for esophageal squamous-cell carcinoma in high risk patients: a prospective study conducted in 62 French endoscopy centers. *Endoscopy* 2006; 38: 690–695
- 25 Slaughter DP, Southwick HW, Smejkal W. Field cancerization in oral stratified squamous epithelium: clinical implications of multicentric origin. *Cancer* 1953; 6: 963–968
- 26 Shimizu Y, Tsukagoshi H, Fujita M et al. Head and neck cancer arising after endoscopic mucosal resection for squamous cell carcinoma of the esophagus. *Endoscopy* 2003; 35: 322–326
- 27 Urabe Y, Hiyama T, Tanaka S et al. Metachronous multiple esophageal squamous cell carcinomas and Lugol-voiding lesions after endoscopic mucosal resection. *Endoscopy* 2009; 41: 304–309



## Usefulness of Narrow-band Imaging for Detecting the Primary Tumor Site in Patients with Primary Unknown Cervical Lymph Node Metastasis

Tomomasa Hayashi<sup>1,2,3</sup>, Manabu Muto<sup>4</sup>, Ryuichi Hayashi<sup>3</sup>, Keiko Minashi<sup>5</sup>, Tomonori Yano<sup>5</sup>, Seiji Kishimoto<sup>2</sup> and Satoshi Ebihara<sup>1</sup>

<sup>1</sup>Department of Head and Neck Surgery, Kyoundo Hospital Sasaki Foundation, <sup>2</sup>Department of Head and Neck Surgery, Tokyo Medical and Dental University Graduate School of Medicine, Tokyo, <sup>3</sup>Department of Head and Neck Surgery, National Cancer Center Hospital East, Chiba, <sup>4</sup>Department of Gastroenterology and Hepatology, Kyoto University Graduate School of Medicine, Kyoto and <sup>5</sup>Department of Gastroenterology, National Cancer Center Hospital East, Chiba, Japan

For reprints and all correspondence: Tomomasa Hayashi, Department of Head and Neck Surgery, Kyoundo Hospital Sasaki Foundation, Tokyo, Japan. E-mail: hayashi@po.kyoundo.jp

Received October 29, 2009; accepted December 24, 2009

**Objective:** We sometimes experienced patients with primary unknown cervical lymph node metastasis. In such cases, if computed tomography, magnetic resonance imaging, laryngoscopy and gastrointestinal endoscopy cannot detect a primary site, there is no other effective method to identify a possible primary tumor. We investigated whether narrow-band imaging can detect a possible primary tumor in such.

**Methods:** Forty-six patients with primary unknown cervical lymph node metastasis were surveyed about primary tumors, from January 2003 to December 2006. All cervical lymph nodes were histologically proved to be squamous cell carcinoma by fine-needle aspiration cytology. Narrow-band imaging combined with magnifying endoscopy was used to identify the primary site in the head and neck region and cervical esophagus. Histological analysis was performed for all suspicious lesions by a biopsy specimen.

**Results:** Twenty-six lesions were suspected to be cancerous lesions by narrow-band imaging in the head and neck region. Sixteen lesions in 16 (35%, 16/46) patients were squamous cell carcinoma. Ten lesions were located in the hypopharynx and the remaining six lesions were located in the oropharynx. White light endoscopy could not point out any lesion.

**Conclusions:** Narrow-band imaging endoscopy can detect possible primary cancer in patients with primary unknown cervical lymph node metastasis.

*Key words:* NBI – pharynx – primary unknown cancer – neck lymph node metastasis

### INTRODUCTION

In the head and neck region, we sometimes treat patients with cervical lymph node metastasis where a primary tumor cannot be identified by laryngoscopy, computed tomography (CT) and magnetic resonance imaging (MRI). Primary unknown cervical lymph node metastasis (PUCLNM) is reported in 2–9% of metastases in the head and neck region. Additional work-up including upper gastrointestinal endoscopy can detect possible primary lesions in about 10% of

the patients, but the possible primary site is not identified in 90% of the patients with PUCLNM.

The inability to find the primary tumor makes it difficult to decide on the most appropriate treatment for the patient, and the clinician must consider different options for the initial treatment. In some cases, the primary tumor is detected during treatment for the lymph node metastasis, but the primary site remains unidentified in some. In cases where the primary tumor is detected after the start of

© 2010 The Author(s)

This is an Open Access article distributed under the terms of the Creative Commons Attribution Non-Commercial License (<http://creativecommons.org/licenses/by-nc/2.5/uk/>) which permits unrestricted non-commercial use, distribution, and reproduction in any medium, provided the original work is properly cited.

treatment, it is impossible to switch the treatment. Thus, to stage and evaluate the treatment strategy, the clinician should be able to detect the primary site before starting treatment.

To find a primary lesion, blind biopsy (1–3) or tonsillectomy (4) is sometimes used in patients with PUCLNM. However, these surveillance methods do not always detect the primary lesion. In the case of PUCLNM, whole-neck irradiation will be indicated after cervical lymph node excision because we cannot pinpoint the primary cancer-based treatment strategy (5–7). Whole-neck irradiation causes adverse events such as salivary gland disorder, severe mucositis and taste disorder. In addition, if primary cancer could be detected after irradiation, re-irradiation would not be needed; this is important because surgery after irradiation increases the risk of leakage of the anastomosis.

Muto et al. (8,9) reported that narrow-band imaging (NBI) can detect superficial cancer in the oropharynx and hypopharynx. Although NBI is expected to help identify the primary lesion in patients with PUCLNM, there are no reports on this issue. We surveyed primary lesions in such patients using NBI endoscopy of the gastrointestinal tract.

## PATIENTS AND METHODS

From January 2003 to December 2006, 46 consecutive patients with PUCLNM were surveyed about the primary site using a gastrointestinal NBI endoscope in National Cancer Center Hospital East, Chiba, Japan. Written informed consent for the examination was obtained from all patients.

The definition of PUCLNM was in accordance with the report by Greenberg (10) as follows.

- It is proven to have malignant cells histologically.
- We cannot identify a primary tumor using ocular inspection or pharyngolarynx fiberoscopy.
- We cannot identify a primary tumor by CT or MRI.
- Other organs except the head and neck do not show a carcinoma.

In all patients, the possible primary tumor could not be detected by examination using CT, MRI, pharyngolaryngoscopy and standard white-light gastrointestinal endoscopy.

We used a magnifying videoendoscope (Q240Z, Olympus Medical Systems, Tokyo, Japan) and sequential RGB light source with NBI function (CLV-Q260SL, Olympus Medical Systems). The magnifying endoscope had a capability of  $\times 80$  optical magnification. The NBI system has been described in detail in previous studies (8,9). In this system, the central wavelengths of NBI were 415 and 540 nm, and each had a bandwidth of 30 nm.

During the survey of the primary site in the head and neck region including the cervical esophagus, if the lesions showed both a well-demarcated brownish area and an irregular microvascular pattern (11), we diagnosed cancer. After

this examination, we took a biopsy specimen to confirm the histological diagnosis.

## RESULTS

The patients' characteristics are shown in Table 1. Thirty-eight patients were men and eight were women. Their median age was 66 years (range, 38–81 years). Twenty-eight cases were N2 and 18 cases were N3. Thirty-one patients had metastatic lymph nodes in the upper jugular area (Level II), 13 had middle jugular lymph node metastasis (Level III) and 2 had lower jugular lymph node metastasis (Level IV).

Twenty-six lesions were suspected to be the cancerous site in 25 patients. Sixteen lesions in 16 patients were confirmed histologically as squamous cell carcinoma. Histological assessment of all of the possible primary lesions showed the similar feature of squamous cell carcinoma. Thus, primary cancer in the head and neck region was detected in 16 patients (35%) by NBI endoscopy. The patients' characteristics are shown in Table 2. Ten patients had metastatic lymph nodes in the upper jugular area, five had middle jugular lymph node metastasis and one had lower jugular lymph node metastasis. Nine cases were N3 and seven cases were N2. All of the lesions detected were superficial neoplasia. Ten lesions were located in the hypopharynx and the remaining six lesions were located in the oropharynx (three were tonsil). All lesions were T1 stage or Tis, and all lesions were  $< 2$  cm in size. Biopsy specimens revealed that one lesion was intraepithelial cancer and the other had invaded to the subepithelial layer.

Table 1. Patient characteristics

	Patients
Age (years)	66 (38–81)
Gender	
Male	38
Female	8
N stage	
N2a	4
N2b	20
N2c	4
N3	18
Levels of cervical metastasis	
Upper jugular (II)	31
Middle jugular (III)	13
Lower jugular (IV)	2

Thirty-eight patients were males and eight were females. Median age was 65 years (range, 38–81 years). Twenty-eight cases were N2 and 18 cases were N3. Thirty-one patients had metastatic lymph node in the upper jugular area (Level II), 15 had middle jugular lymph node metastasis (Level III) and 2 cases had lower jugular lymph node metastasis (Level IV).

**Table 2.** Characteristics of possible primary lesions detected by NBI

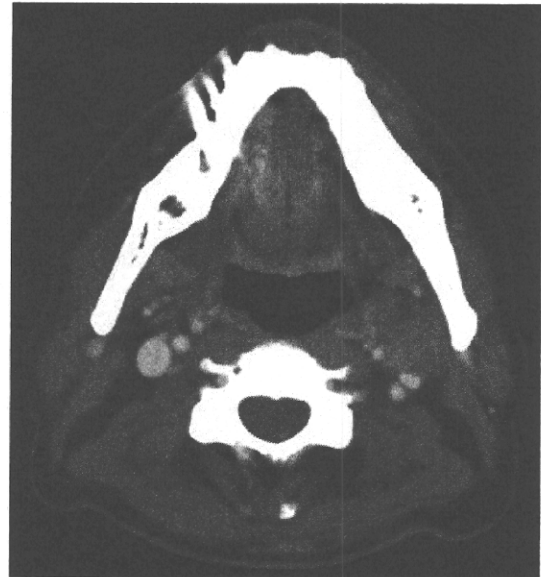	Primary	Endoscopic findings	n (levels)	Treatment
1	Oropharynx	Superficial	3 (II)	CRT
2	Oropharynx	T1	3 (II)	CRT
3	Hypopharynx	Superficial	3 (II)	RT
4	Oropharynx	Superficial	3 (III)	CRT
5	Hypopharynx	Superficial	3 (II)	CRT
6	Hypopharynx	Superficial	3 (II)	EMR + ND
7	Hypopharynx	Superficial	3 (II)	CRT
8	Hypopharynx	Superficial	3 (II)	Surgery + ND
9	Oropharynx	Superficial	2b (III)	Surgery + ND
10	Oropharynx	T1	2a (II)	Surgery + ND
11	Hypopharynx	Superficial	2b (IV)	Surgery + ND
12	Hypopharynx	T1	2a (II)	Surgery + ND
13	Hypopharynx	Superficial	2b (II)	EMR + ND
14	Hypopharynx	Superficial	3 (III)	RT
15	Oropharynx	Superficial	2c (II)	Surgery + ND
16	Hypopharynx	Superficial	2b (III)	EMR + ND

Nine cases were N3 and seven cases were N2. Five cases were treated by concurrent chemoradiation therapy and in nine cases, primary site was removed by surgery or endoscopic resection and they underwent neck dissection for lymph node metastasis. NBI, narrow-band imaging; CRT, chemoradiation therapy; EMR, endoscopic mucosal resection; ND, neck dissection.

Five patients were treated by concurrent chemoradiation therapy (CRT). Two patients were treated with a chemotherapy regimen comprising 5-fluorouracil (800 mg/m<sup>2</sup>, days 1–5) and cisplatin (80 mg/m<sup>2</sup>, day 1). Two patients were treated with tegafur-gimeracil-oteracil potassium (60 mg/m<sup>2</sup>, days 1–14) and cisplatin (20 mg/m<sup>2</sup>, day 1). One patient was treated with cisplatin (80 mg/m<sup>2</sup>, day 1). The irradiation field covered the whole neck, and the total radiation dose was 70 Gy (2 Gy/fr). Two patients were treated by radiation therapy (total 70 Gy) alone. For the other nine patients, the primary site was removed by surgery or endoscopic resection, followed by neck dissection of the lymph node metastasis. No patient received whole-neck irradiation after neck dissection.

Treatment of the 20 patients who cannot detect cancer lesion were CRT (for N3 or N2b), and neck dissection and close follow-up with NBI endoscopy (for N2a or N2b).

Figure 1 shows a representative case where the primary cancer was detected by NBI. This patient had a swollen lymph node (2.5 cm in size) on the left side of the upper jugular area (Level II) (Fig. 1). The specimen taken using a fine-needle aspiration method from the swollen lymph node revealed squamous cell carcinoma, which was confirmed later as metastatic. CT scan, MRI, laryngoscopy and standard gastrointestinal endoscopy could not detect any primary site. NBI detected easily a well-demarcated brownish area in the uvula to the right anterior palatine arch (Fig. 2B). In contrast, the conventional white-light image made it difficult to

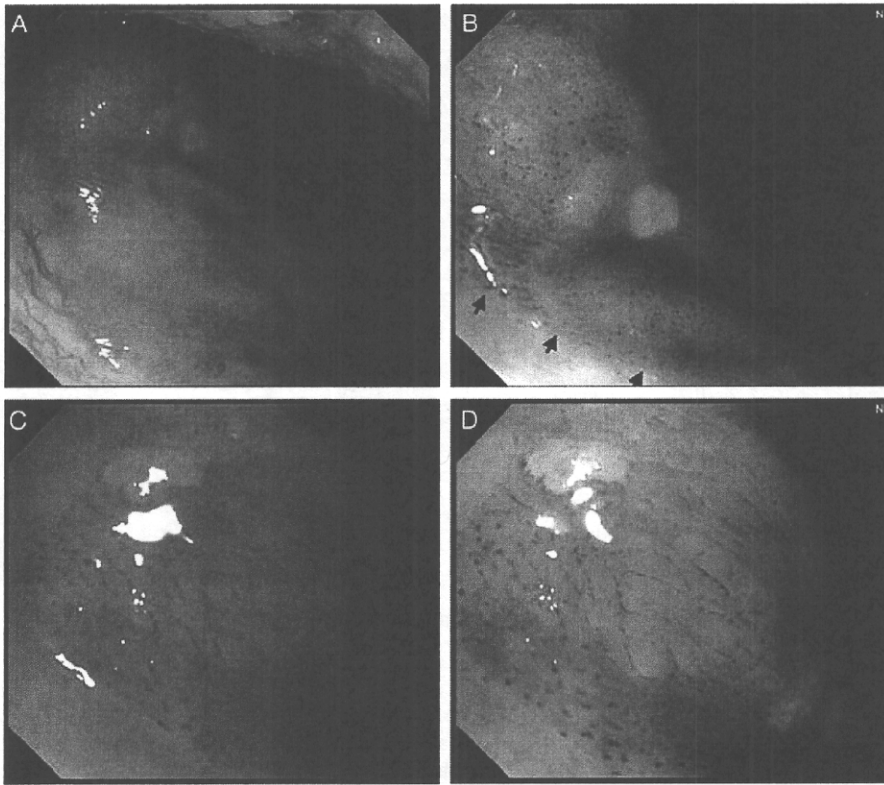
**Figure 1.** Computed tomographic scan shows lymph node metastasis at left upper jugular area.

visualize the cancerous lesion (Fig. 2A). Magnifying the observation with NBI revealed easily an irregular microvascular pattern inside the lesion (Fig. 2D), but magnifying the observation with white light made it difficult to see this irregular microvascular pattern (Fig. 2C). We diagnosed cancer for this lesion. The biopsy specimen revealed squamous cell carcinoma, which was similar histologically to that of the metastatic lymph node. Treatment of this patient involved neck dissection and resection for primary disease, and we were able to avoid irradiation of the whole neck.

## DISCUSSION

We report for the first time that NBI endoscopy can detect possible primary cancer in patients with PUCLNM. Information about the primary site is very important for deciding on the appropriate treatment because the treatment strategy may differ for each primary site. Our data indicate that NBI can be helpful to the clinician when deciding on the treatment.

According to Greenberg (10), primary unknown carcinoma is defined when primary tumor cannot be detected by an autopsy. However, this definition cannot be applied in clinical decision-making. We defined a PUCLNM as one for which we could not detect any primary site by CT, MRI, laryngoscopy and gastrointestinal endoscopy (11). Although recent advance in technologies of CT, MRI and PET makes it possible to detect a small lesion precisely, the primary cancer is detected in only 2–9% of the patients with PUCLNM (1,2,12,13). Positron emission tomography (PET) or CT is also useful to detect occult cancer, but this primary site is too small to point out with PET. Random biopsy in the head and



**Figure 2.** (A–D) Endoscopic findings. Conventional white-light image (A), narrow-band imaging (NBI) image (B), magnifying conventional white-light image (C) and magnifying the NBI images (D). NBI detected a well-demarcated brownish area in the uvula to right anterior palatine arch (B). In contrast, conventional white-light image was difficult to visualize the cancerous lesion (A). Magnifying the observation with NBI revealed an irregular microvascular pattern inside the lesion (D).

neck region may be useful for detecting possible primary cancer in patients with PUCLNM, but the detection rate is only around 10% (1,2). However, tonsillectomy is very useful to detect the primary cancer but tonsillectomy can detect only tonsil cancer. Because only 3 of 16 cases have a cancerous lesion on tonsil in this study, NBI endoscopy was better than tonsillectomy to detect occult tumor.

In the esophagus, Lugol chromoendoscopy is useful for detecting superficial squamous cell carcinoma. However, Lugol's solution cannot be applied in the head and neck region because of the risk of aspiration into the airway. NBI is now recognized as a useful and safe method for detecting superficial squamous cell carcinoma in the head and neck region because it uses no solution and improves the visibility. Muto et al. (8,9,16) reported that both a well-demarcated brownish area and an irregular microvascular pattern are typical characteristics of the superficial squamous cell carcinoma in the head and neck region. In this study, we evaluated the lesion according to these two endoscopic characteristics, and we were able to confirm 64% (16/25) of the lesions in the suspicious cancerous area as squamous cell carcinoma. This positive rate is better than that from a random biopsy (~10%). Finally, possible primary cancer could be detected in 35% (16/46) of the patients. These

results indicate that NBI should be applied when surveying the primary site in patients with PUCLNM. Moreover, it is not impossible to detect cancerous lesion only using white-light endoscopy by trained endoscopist but NBI endoscopy is very easy for beginners to detect lesion.

Nine of 16 patients underwent surgery or endoscopic resection of the primary site and subsequent lymph node dissection. In such cases, post-operative whole-neck radiation is one treatment option (13–15). However, the indications for post-operative radiation therapy for PUCLNM are still controversial because these patients are at high risk for developing metachronous multiple cancers in the head and neck region (16). If they received radiation therapy as a post-operative radiation therapy, there is no radiotherapy treatment option for the later appearance of a metachronously developed second primary cancer in the head and neck region (14–16). The clinician must thus plan the post-operative radiation therapy carefully.

We cannot conclude with certainty whether the lesions detected by NBI were the true primary sites unless we identify their clonality. As a next step, we will compare the clonality of both primary sites and metastatic lymph nodes. In this study, at least, histological assessment showed the same histological features of the primary site and metastatic lymph

node. Clinically, histological accordance would be enough to consider whether the lesion is primary.

Although we could not evaluate the depth of invasion in all patients, we know that micro-invasive cancer can metastasize to the lymph node. The risk of lymph node metastasis of superficial squamous cell carcinoma is unknown, but collection of data from a large number of cases should help clarify this.

In conclusion, our data indicate that NBI has the potential to identify primary cancer in patients with PUCLNM. Identification of the primary site provides helpful information for deciding on the treatment strategy.

### Conflict of interest statement

None declared.

### References

1. Coker D, Casterline P, Chambers R, Jaques D. Metastases to lymph nodes of the head and neck from an unknown primary site. *Am J Surg* 1977;134:517–22.
2. Gluckman J, Robbins K, Fried M. Cervical metastatic squamous carcinoma of unknown or occult primary source. *Head Neck* 1990;12:440–3.
3. Jones A, Cook J, Phillips D, Roland N. Squamous carcinoma presenting as an enlarged cervical lymph node. *Cancer* 1993;72:1756–61.
4. Righi P, Sofferman R. Screening unilateral tonsillectomy in the unknown primary. *Laryngoscope* 1995;105:548–50.
5. Medini E, Medini A, Lee C, Gapany M, Levitt S. The management of metastatic squamous cell carcinoma in cervical lymph nodes from an unknown primary. *Am J Clin Oncol* 1998;21:121–5.
6. Jesse R, Perez C, Fletcher G. Cervical lymph node metastasis: unknown primary cancer. *Cancer* 1973;31:854–9.
7. McCuniff A, Raben M. Metastatic carcinoma of the neck from an unknown primary. *Int J Radiat Oncol Biol Phys* 1986;12:1849–52.
8. Muto M, Ugumori T, Sano YI, Otsu A, Yoshida S. Narrow-band imaging combined with magnified endoscopy for cancer at the head and neck region. *Dig Endosc* 2005;17:S23–4.
9. Muto M, Nakane M, Katada C, Sano Y, Ohtsu A, Esumi H, et al. Squamous cell carcinoma *in situ* at oropharyngeal and hypopharyngeal mucosal sites. *Cancer* 2004;101:1375–81.
10. Greenberg B. Cervical lymph node metastasis from unknown primary sites. An unresolved problem in management. *Cancer* 1966;19:1091–5.
11. Muto M, Katada C, Sano Y, Yoshida S. Narrow band imaging: a new diagnostic approach to visualize angiogenesis in superficial neoplasia. *Clin Gastroenterol Hepatol* 2005;3(7 Suppl 1):S16–20.
12. Nguyen C, Shenouda G, Black M, Vuong T, Donath D, Yassa M. Metastatic squamous cell carcinoma to cervical lymph nodes from unknown primary mucosal sites. *Head Neck* 16:58–63.
13. Mendenhall W, Million R, Cassisi N. Squamous cell carcinoma of the head and neck treated with radiation therapy: the role of neck dissection for clinically positive neck nodes. *Int J Radiat Oncol Biol Phys* 1986;12:733–40.
14. Freeman D, Mendenhall W, Parsons J, Million R. Unknown primary squamous cell carcinoma of the head and neck: is mucosal irradiation necessary? *Int J Radiat Oncol Biol Phys* 1992;23:889–90.
15. Coster J, Foote R, Olsen K, Jack S, Schaid D, DeSanto L. Cervical nodal metastasis of squamous cell carcinoma of unknown origin: indications for withholding radiation therapy. *Int J Radiat Oncol Biol Phys* 1992;23:743–9.
16. Muto M, Takahashi M, Ohtsu A, Ebihara S, Yoshida S, Esumi H. Risk of multiple squamous cell carcinomas both in the esophagus and the head and neck region. *Carcinogenesis* 2005;26:1008–12.

# Microvascular irregularities are associated with composition of squamous epithelial lesions and correlate with subepithelial invasion of superficial-type pharyngeal squamous cell carcinoma

Satoshi Fujii, Manabu Yamazaki, Manabu Muto<sup>1</sup> & Atsushi Ochiai

Pathology Division, Research Centre for Innovative Oncology, National Cancer Centre at Kashiwa, Chiba, and <sup>1</sup>Department of Gastroenterology and Hepatology, Kyoto University Graduate School of Medicine, Kyoto, Japan

Date of submission 30 April 2009

Accepted for publication 25 July 2009

Fujii S, Yamazaki M, Muto M & Ochiai A

(2010) *Histopathology* 56, 510–522

## Microvascular irregularities are associated with composition of squamous epithelial lesions and correlate with subepithelial invasion of superficial-type pharyngeal squamous cell carcinoma

**Aims:** Superficial squamous epithelial lesions of the pharynx are increasingly recognized by architectural changes in the intraepithelial papillary capillary loop (IPCL) assessed by narrow-band imaging (NBI). The aim was to explore the histology of squamous epithelial precursor lesions and superficial-type pharyngeal squamous cell carcinoma (STPSCC), including squamous cell carcinoma (SCC) *in situ* and early invasive SCC, by focusing on microvascular irregularities to investigate the composition of those lesions and to explore the pathological characteristics of STPSCCs.

**Methods and results:** Several pathological factors including thickness of intraepithelial squamous cell carcinoma (IESCC) and tumour thickness and micro-

vascular density (MVD) were examined in 104 STPSCCs from 69 patients. The results show that architectural change of IPCL was recognized in precursor lesions in parallel with architectural disturbance and cytological atypia for criteria of diagnosing dysplasia. In 104 STPSCCs, the MVD of IESCC was correlated with the thickness of IESCC ( $P = 0.0115$ ). Moreover, invasive SCC showed significantly higher MVD of IESCC ( $P = 0.0078$ ) and there was significant correlation between the thickness of IESCC and subepithelial invasion ( $P < 0.0001$ ).

**Conclusions:** Microvascular irregularities are an important pathological factor in carcinogenesis and early invasiveness of SCC of the pharynx.

**Keywords:** intraepithelial papillary capillary loop, microvascular density, microvascular irregularities, narrow-band imaging, superficial-type pharyngeal squamous cell carcinoma

**Abbreviations:** EMR, endoscopic mucosal resection; ESCC, oesophageal squamous cell carcinoma; ESD, endoscopic submucosal dissection; H&E, haematoxylin and eosin; IESCC, intraepithelial squamous cell carcinoma; IPCL, intraepithelial papillary capillary loop; mLVL, multiple Lugol-voiding lesion; MVD, microvascular density; NBI, narrow-band imaging; SCC, squamous cell carcinoma; STPSCC, superficial-type pharyngeal squamous cell carcinoma; UADT, upper aerodigestive tract

## Introduction

In Japan, the estimated number of new cancer cases of the mouth/pharynx per 1000 is <5.0 and the

estimated age-standardized rates of cancer incidence of the mouth/pharynx per 100 000 is <5.0.<sup>1</sup> Formerly, clinicians had difficulty in detecting pharyngeal cancer until it had progressed to the advanced stage.

Address for correspondence: A Ochiai, Pathology Division, Research Centre for Innovative Oncology, National Cancer Centre at Kashiwa, 651 Kashiwanoha, Kashiwa, Chiba 277 8577, Japan. e-mail: aochiai@east.ncc.go.jp

Therefore, it was necessary to detect pharyngeal cancer at an early stage to avoid extensive surgical resection, causing a loss of function with respect to swallowing and/or speaking, and cosmetic deformities. Recently, the advent of narrow-band imaging (NBI) endoscopy with magnification has dramatically improved the detection of squamous precursor lesions and early-stage SCC of the pharynx.<sup>2</sup> NBI is a novel optical technique that uses reflected light to visualize the superficial structure of an organ surface.<sup>3</sup> It has previously been reported that the morphological changes in microvascular structure are useful in the diagnosis of superficial oesophageal carcinomas.<sup>4,5</sup> NBI utilizes the structural change of microvessels referred to as the intraepithelial papillary capillary loop (IPCL) in mucosal lesions of early-stage SCC of the pharynx.<sup>2</sup> This microvascular structural change is enhanced by NBI and an image allowing a conclusive diagnosis can be obtained.

Most pharyngeal cancer is SCC. It has been accepted that dysplasia may progress to SCC *in situ*

and eventually to invasive SCC. The pathological assessment of precursor lesions in oropharynx and hypopharynx is similar throughout the upper aerodigestive tract (UADT).<sup>6</sup> Precursor lesions have been grouped under the term dysplasia (mild, moderate

**Table 1.** Patient population treated with EMR/ESD

Gender	
Male	67 (97.1%)
Female	2 (2.9%)
Age	
Median/mean (range)	62/62.2 (42–88)
mLVLS	
Presence	60 (87.0%)
None	7 (10.1%)
Unknown	2 (2.9%)
Multiple STPSCC	
Presence	30 (43.5%)
None	39 (56.5%)
Overlapping ESCC	
Presence	62 (89.9%)
None	7 (10.1%)
Multiple HNSCC	
Presence	24 (34.8%)
None	45 (65.2%)

mLVLS, multiple Lugol-voiding-lesions; STPSCC, superficial type pharyngeal squamous cell carcinoma; ESCC, oesophageal squamous cell carcinoma; HNSCC, head & neck squamous cell carcinoma.

**Table 2.** Clinicopathological factors of 104 STPSCCs treated with EMR/ESD

Primary site	
Oropharynx	13 (12.5%)
Upper wall	2 (1.92%)
Anterior wall	2 (1.92%)
Posterior wall	4 (3.85%)
Lateral wall	5 (4.81%)
Hypopharynx	91 (87.5%)
Pyriform sinus	75 (72.1%)
Postcricoid	6 (5.8%)
Posterior wall	6 (5.8%)
Arytenoid	4 (3.8%)
Tumour size (mm)	
≤5	20 (19.2%)
5< and ≤10	40 (38.5%)
10< and ≤20	31 (29.8%)
20< and ≤30	10 (9.6%)
30< and ≤40	3 (2.9%)
Subepithelial invasion	
Presence	29 (27.9%)
None	75 (72.1%)
Vessel infiltration	
Presence	6 (5.8%)
None	98 (94.2%)
Lymph node metastasis*	
Presence	1 (0.96%)
None	103 (99.04%)
Local recurrence	
Presence	3 (2.9%)
None	101 (97.1%)

\*Metachronous lymph node metastasis.

and severe dysplasia). In order to make a precise pathological diagnosis of squamous epithelial lesions detected by NBI endoscopy, it is necessary to understand the pathological findings by focusing on the irregularities of the microvasculature, i.e., IPCL. Detecting pharyngeal SCC *in situ* would clearly be of benefit to patients. It is also necessary to detect those pathological features that reflect the potential for subepithelial invasion and metastasis to lymph nodes, thus leading to selecting optimal therapy for early-stage SCC.

There is a specific characteristic of the pharynx, i.e. it has no lamina muscularis mucosae; this implies that evaluations such as 'invasion of the lamina propria mucosae' or 'invasion of the submucosal layer', as in oesophageal cancer specimens, are impossible in the pharynx. The invasive depth of oesophageal SCC correlates with risk factors such as vessel infiltration and lymph node metastasis.<sup>7</sup> Thus, it is essential to identify critical risk factors such as these in early-stage SCC. In organs such as the tongue, which has no lamina muscularis mucosae,

tumour thickness has been reported to be a risk factor for cervical lymph node metastasis.<sup>8,9</sup> In our institution, SCC *in situ* of the oropharynx and hypopharynx have previously been detected using the NBI system.<sup>10</sup> We have now accumulated >100 patients with superficial-type pharyngeal squamous cell carcinoma (STPSCC) resected by endoscopic resection [endoscopic mucosal resection (EMR) or endoscopic submucosal dissection (ESD)] who have an extended clinical follow-up period to enable us to investigate the clinicopathological features and clinical course of STPSCC.

## Materials and methods

### PATIENT POPULATION

One hundred and four lesions from 69 patients (67 male and two female, median age 62 years) were consecutively collected for the present study. These patients underwent EMR or ESD between June 2002 and September 2006 at the National Cancer Centre

**Table 3.** Histological findings of squamous epithelial lesions of the pharynx based on microvascular irregularities

	Normal	Inflammation	Mild dysplasia	Severe dysplasia	SCC- <i>in-situ</i>	Invasive SCC
IPCL extension upward	(-)	Mid zone	Superficial zone	Superficial zone	Superficial zone	Superficial zone
IPCL dilatation and branching	(-)	(-) ~ Slight	(+)	(+)	(+)	(+); Complicated
IPCL diameter expansion	(-)	(-)	Mild ~ severe	Severe	Severe	Severe
Proliferative cell distribution	AB	(-)	LI ~ LH	S	S	D
Basal cell palisading	(+)	(+/-), Edematous	(+)	(+)	(+/-)	-
Basal cell enlargement	(-)	(-)	(-)	(+/-)	(+)	(+)
Spinous layer retention	(+)	(+)	(+)	(-)	(-)	(-)
Superficial layer retention	(+)	(+)	(+)	(+)	(-)	(-)
Nuclear arrangement	PP	PP	PP	PL	PL	PL
Nuclear density	NI	NI	IM	IS	IS	IS
Subepithelial solitary cell nest	(-)	(-)	(-)	(-)	(-)	(+)

SCC, squamous cell carcinoma; IPCL, intra-epithelial papillary capillary loop; Proliferative cell, cells labelled immunohistochemically by MIB-1 AB, arranged in the basal layer; LI, localized at the peri-IPCL; LH, limited to the lower third of intra-epithelial layer; S, scattered in intra-epithelial layer; D, distributed densely in the intra-epithelial layer; PP, polarity preserved; PL, polarity lost; NI, not increased; IM, increased mildly at the peri-IPCL or the lower third of intra-epithelial layer; IS, increased severely throughout the intra-epithelial layer.



Hospital East. Pre-operative examinations identified no metastasis, including lymph node metastasis, in any of the patients, and none had received prior anticancer treatment. These 69 cases are summarized in Table 1. Eighty-seven percent of patients in the current study had multiple Lugol-voiding lesions (mLVLs) in the background oesophageal mucosa. The presence of mLVLs in background oesophageal mucosa was evaluated by Lugol's iodine staining clinically. Multiple STPSCCs at oropharyngeal and hypopharyngeal mucosal sites were identified in 30 patients (43.5%). Furthermore, 62 patients (89.9%) had overlapping oesophageal SCC, and 24 (34.8%) had multiple head and neck SCCs apart from STPSCC. Multiple STPSCC or overlapping oesophageal squamous cell carcinoma (ESCC) or multiple head and neck squamous cell carcinoma were managed until the end of the follow-up period.

All informed consent processes were conducted in accordance with the guidelines of the National Cancer Centre Hospital East institutional review board authorization for this study.

CLINICOPATHOLOGICAL FACTORS OF STPSCCS TREATED WITH EMR/ESD

One hundred and four consecutive STPSCCs were detected by conventional endoscopy and NBI endoscopy with magnification and a pathological diagnosis of SCC was made by biopsy specimen before EMR/ESD. The clinicopathological factors of the 104 STPSCCs treated with EMR/ESD are summarized in Table 2. The pyriform sinus was the most common primary site (72.1%). Tumour diameters ranged from 1.3 to 40 mm and median and average tumour diameters were 10 and 12.23 mm, respectively.

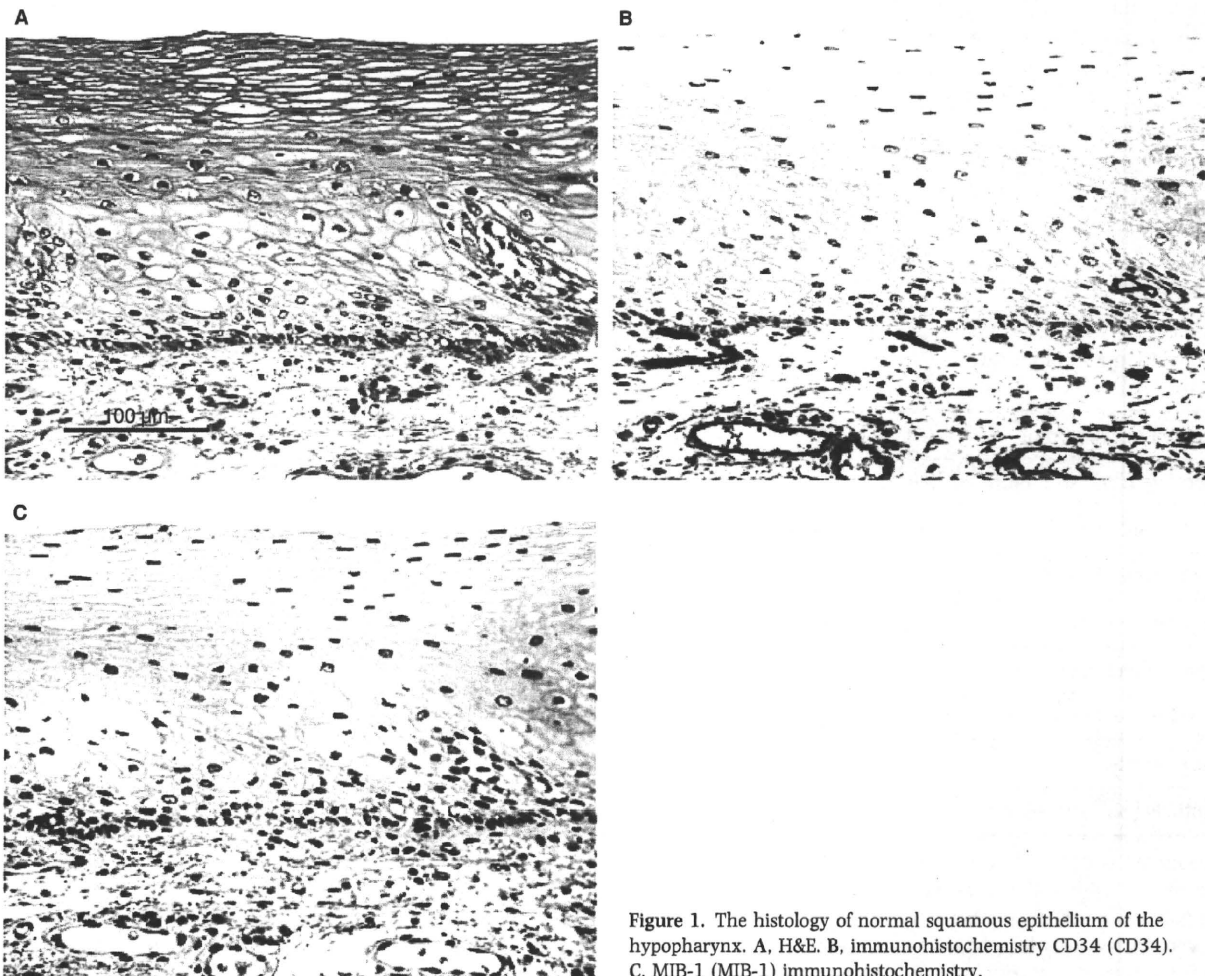


Figure 1. The histology of normal squamous epithelium of the hypopharynx. A, H&E. B, immunohistochemistry CD34 (CD34). C, MIB-1 (MIB-1) immunohistochemistry.

Tumour size was measured after mapping of the SCC tissue by histological evaluation. Twenty-nine lesions (27.9%) were pathologically confirmed to be invasive SCC. Subepithelial invasion was defined as at least one solitary carcinoma cell nest being observed in the subepithelial region. Only six lesions (5.8%) showed blood vessel infiltration identified by elastic staining and only one case (0.96 %) showed lymphatic vessel infiltration by haematoxylin and eosin (H&E) staining. Vessel infiltration included lymphatic and/or blood vessel infiltration. Only one (0.96%) had metachronous lymph node metastasis and only

three STPSCCs recurred locally. The average follow-up period was 826 days (median 726 days, SD 464.6 days).

#### INDICATIONS FOR BIOPSY

Biopsy specimens collected by endoscopists on suspicion of or to rule out SCC were also used to examine diagnostic histological findings on the basis of microvascular irregularities in non-neoplastic lesions, dysplasia, SCC *in situ* and invasive SCC together with magnified NBI images.

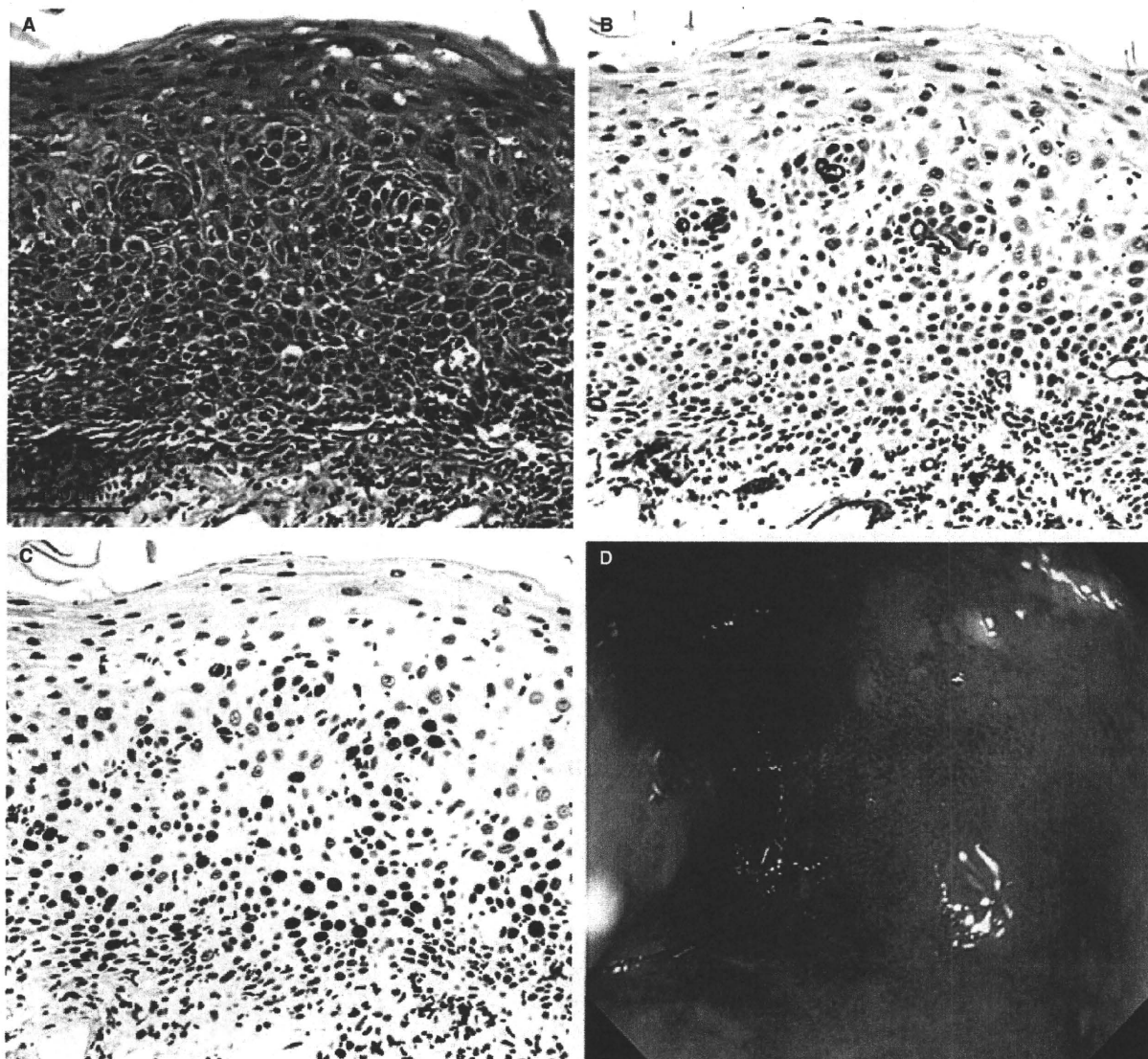


Figure 2. The histology of an inflammatory lesion from a biopsy specimen. A, H&E. B, CD34. C, MIB-1. D, Narrow-band imaging (NBI) endoscopy with magnification of the hypopharynx (right arytenoid).

## HISTOLOGICAL METHODS

All specimens resected by EMR/ESD were fixed in 10% formalin and embedded in paraffin wax. The tissue specimens were cut at a thickness of 2  $\mu\text{m}$  and all sections were routinely evaluated for pathological diagnosis. The pathological parameters for each case were then profiled and used for further analyses. The section with the thickest tumour diameter measured from the tumour surface to the base of the malignant tissue was selected for further immunohistochemical analysis, and serial 4- $\mu\text{m}$  thick sections were used for immunohistochemistry to detect IPCL and calculate microvascular density (MVD). To calculate the MVD, blood vessels were displayed using anti-CD34 antibody (Dako, Carpinteria, CA, USA) (dilution 1:50) on 4  $\mu\text{m}$  thick sections. Antigen retrieval was carried out using microwave treatment in citrate buffer (pH 6.0). Sections were processed immunohistochemically using the Dako Envision system. Diaminobenzidine was used as the chromogen and haematoxylin as the counter-stain.

## CRITERIA FOR PATHOLOGICAL DIAGNOSIS

For the diagnosis of dysplasia and SCC *in situ* and invasive SCC, the criteria proposed by the World Health Organization were used.<sup>6</sup> These criteria are used for diagnosing dysplasia, based on architectural and cytological abnormalities. However, endoscopists have recently discovered early-stage lesions in pharynx using the NBI system. NBI utilizes change in the IPCL in squamous epithelium. That is, the change in IPCL should be accompanied by the architectural and cytological criteria for diagnosing dysplasia. Therefore, the morphological changes seen as microvascular irregularities in intraepithelial lesions should be considered in the pathological diagnosis together with architectural and cytological abnormalities.

In UADT, the general guideline for measuring the invasive component is from the basement membrane.<sup>11</sup> However, relative to head and neck superficial invasive carcinomas, there are varying views as to which lesion does or does not qualify as microinvasive. Moreover, the pharynx has no lamina muscularis mucosae. Therefore,

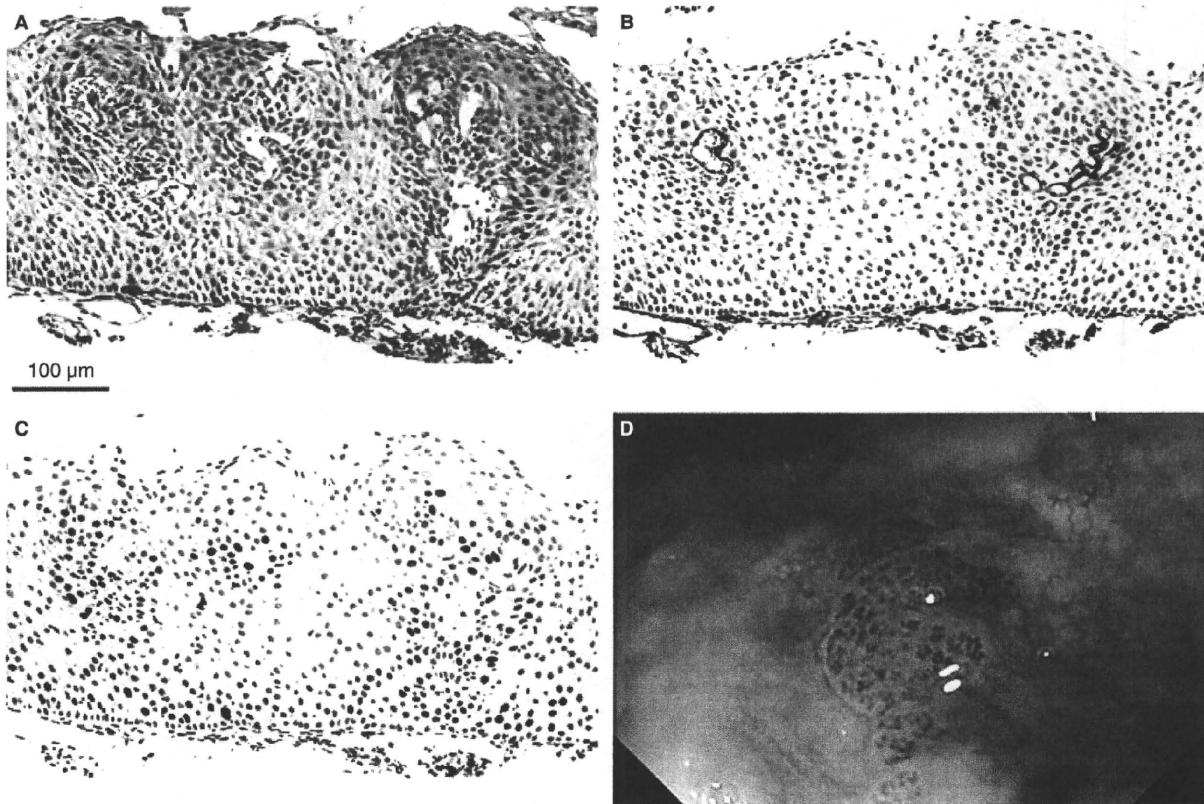


Figure 3. The histology of basal cell hyperplasia from a biopsy specimen. A, H&E. B, CD34. C, MIB-1. D, Narrow-band imaging of the oropharynx (posterior wall).

in the current study, only those cases in which at least one solitary carcinoma cell nest was observed in the subepithelial region were designated as invasive SCC of the pharynx. Usually, more than a solitary carcinoma cell nest was recognized but when a solitary carcinoma cell nest was recognized, it had to be distinguished from the involvement of minor salivary glands.

The thickness of IESCC was measured from the surface to the bottom of the thickest portion of IESCC. In order to minimize overestimation of epithelial thickness caused by tangential sectioning, resected specimens by EMR or ESD were unfolded on a plastic plate and fixed in 10% formalin overnight. The whole tissue specimen was then cut vertically and parallel at a thickness of <2 mm before embedding in paraffin. Then sections at a thickness of 2 µm were made and routinely evaluated. The epithelial thickness of whole area was measured in each case and the area of tissue without diathermy artefact was measured to register the thickness of IESCC.

To evaluate the depth of invasion in pharyngeal invasive SCC, the distance measured from the surface of the intraepithelial carcinoma to the bottom of the

deepest portion of the invasive carcinoma tissue was regarded as tumour thickness.

#### MEASUREMENT OF MVD

The most densely vascularized area in the intraepithelial lesion that had the highest number of microvessels stained immunohistochemically by CD34 monoclonal antibody was selected as the hot spot. The area was photographed at a magnification of ×100. The intraepithelial microvascular area and carcinoma cell area were quantitatively determined on the image using ImageJ software (National Institute of Health, Bethesda, MD, USA). The percentage of microvascular area to tumour cell area was calculated and defined as MVD.

#### STATISTICAL ANALYSIS

Continuous variables, evaluated and recorded in detail, included means, medians, SDs, and maximum and minimum values. The mean values of variables with a normal distribution were compared with Student's

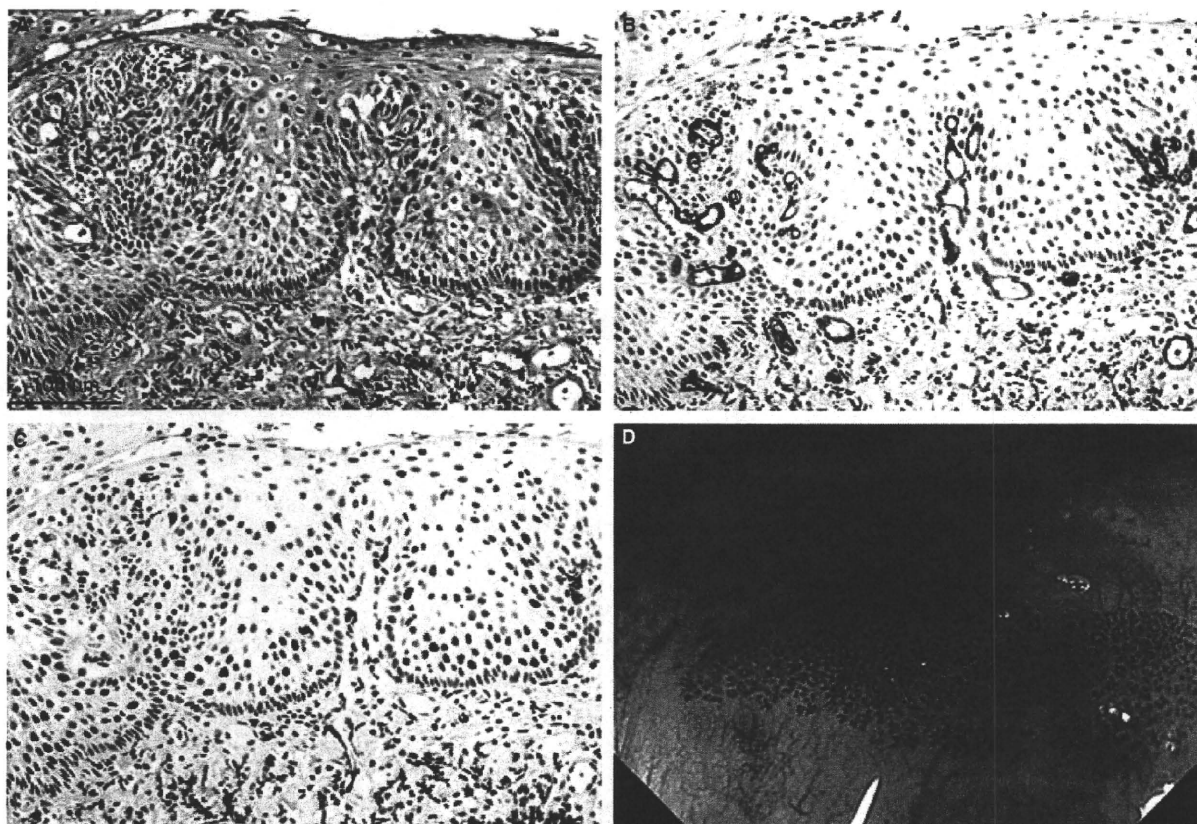


Figure 4. The histology of mild dysplasia from a biopsy specimen. A, H&E. B, CD34. C, MIB-1. D, Narrow-band imaging of the oropharynx (posterior wall).