

201019003A ($\frac{2}{2}$)

厚生労働科学研究費補助金

第3次対がん総合戦略研究事業

幹細胞制御によるがん治療法開発のための基盤研究

平成22年度 総括・分担研究報告書

研究代表者 落谷 孝広

平成23(2011)年5月

(2/2冊)

***TDGF1* is a novel predictive marker for metachronous metastasis of colorectal cancer**

NORIKATSU MIYOSHI¹, HIDESHI ISHII^{1,2}, KOSHI MIMORI²,
MITSUGU SEKIMOTO¹, YUICHIRO DOKI¹ and MASAKI MORI¹

¹Department of Gastroenterological Surgery, Osaka University Graduate School of Medicine, Suita, Yamadaoka 2-2, Osaka 565-0871; ²Department of Molecular and Cellular Biology, Division of Molecular and Surgical Oncology, Kyushu University, Medical Institute of Bioregulation, Tsurumihara 4546, Beppu, Ohita 874-0838, Japan

Received September 30, 2009; Accepted November 16, 2009

DOI: 10.3892/ijo_00000530

Abstract. Teratocarcinoma-derived growth factor 1 (*TDGF1*) is a member of the epidermal growth factor-*FRL1* cryptic protein family and is involved in the activation of several different signaling pathways during embryonic development and cellular transformation. Previous reports show that *TDGF1* regulates the activation of several signaling pathways and controls cellular transformation in embryonic status, whereas its significance in colorectal cancer (CRC) is not yet fully understood. The present study comprised 55 patients who underwent surgery for CRC, as well as two cell lines derived from human CRC. The correlation of gene expression with clinical parameters in patients was assessed. The biological significance of *TDGF1* expression was evaluated by knock-down experiments in the cell lines. Seventeen of 55 (30.9%) cases exhibited a higher *TDGF1* expression in cancerous regions than in marginal non-cancerous regions. Patients with high *TDGF1* expression were statistically susceptible to a recurrence of the disease, and showed poorer disease-free survival than those with low expression. The assessment of *TDGF1* knock-down in the 2 cell lines demonstrated that the siRNA inhibition resulted in a statistically significant reduction in cell growth and invasion. In conclusion, the present data strongly suggest the usefulness of *TDGF1* as a predictive marker for metachronous metastasis in CRC patients.

Introduction

Cancer is a prominent malignancy in many developed countries, including the United States and Japan (1,2). The incidence of colorectal cancer (CRC) has increased significantly in recent years in concert with the changing lifestyle (3). The major cause of death from CRC is liver

metastases (4). Although treatment has recently improved, it fails in approximately one-third of patients, who require an alternative strategy (2). Thus, useful predictive markers are needed for CRC patients.

Tumor-promoting oncogenes and tumor suppressors control cell proliferation through CRC cell cycle arrest (1,5,6). Identifying additional genes responsible for the development and progression of CRC, as well as understanding their clinical significance would improve diagnosis and treatment of the disease. The characterization of key molecules is particularly promising for the development of novel approaches to treat gastrointestinal tumors.

The human teratocarcinoma-derived growth factor 1 (*TDGF1*) gene is a member of the epidermal growth factor-*FRL1* cryptic gene family and was initially isolated from human teratocarcinoma (7). *TDGF1* is expressed in several types of human tumors and has been detected by immunohistochemistry in the breast, stomach, colon, pancreas, and lung (8-16). For gastric cancer, the combined expression of *TDGF1* and E-cadherin is reported as a prognostic factor (16).

We investigated the importance of the *TDGF1* gene by analyzing it in 55 consecutive paired cases of CRC and non-cancerous regions as well as in 2 CRC cell lines. We propose that *TDGF1* expression is important for prognostic evaluation and suggest that *TDGF1* could be a novel marker for CRC prognosis.

Materials and methods

Clinical tissue samples. The study comprised 55 consecutive patients who underwent surgery for CRC at Osaka University from 2003 to 2004. Primary CRC specimens and adjacent normal colorectal mucosa were obtained from patients after written, informed consent was confirmed in accordance with the institutional ethics guidelines. The surgical specimens were fixed in formalin, processed through graded ethanol, embedded in paraffin, and sectioned with hematoxylin and eosin. All specimens were frozen immediately in liquid nitrogen after resection and kept at -80°C until RNA extractions. After surgery, patients were followed up with a blood examination including the tumor markers serum carcinoembryonic antigen (CEA) and cancer antigen (CA19-9), as well as imaging modalities, such as abdominal ultrasonography, computed

Correspondence to: Dr Masaki Mori, Department of Gastroenterological Surgery, Osaka University, Yamadaoka, Suita 2-2, Osaka 565-0871, Japan
E-mail: mmori@gesurg.med.osaka-u.ac.jp

Key words: teratocarcinoma-derived growth factor 1, metastasis, colorectal cancer

tomography, and chest X-ray every 3-6 months. Clinicopathological factors were assessed according to the tumor-node-metastasis (TNM) criteria classification of the International Union Against Cancer (UICC) (17).

Cell lines and culture. Two cell lines derived from human CRC, HCT116 and LoVo, were used in this study (18,19). They were maintained in Dulbecco's minimal essential medium containing 10% fetal bovine serum and antibiotics at 37°C in a 5% humidified CO₂ atmosphere. For siRNA inhibition, double-stranded RNA duplexes targeting human *TDGF1*, (5'-AAGACUUUAGAAAUGGCCAUGAUCC-3'/5'-GGAUCAUGGCCAUUUCUAAAGUCUU-3', 5'-UUUACUGGUCAUGAAAUUUGCAUGA-3'/5'-UCAUGCAAUUAUGAUGACAGUAAA-3', and 5'-UGGACGAGCAAUUCUGAUGGCC-3'/5'-GGGCCAUCAGGAAUUUGCUCGUCCA-3'), as well as negative control siRNA (NC) were purchased in the Stealth RNAi kit (Invitrogen, Carlsbad, CA, USA). CRC cell lines were transfected with siRNA at a concentration of 20 µmol/l using lipofectamine RNAiMAX (Invitrogen), incubated in glucose-free Opti-MEM (Invitrogen), treated in accordance with the manufacturer's protocols, and analyzed by proliferation assay. All siRNA duplexes were used together as a triple transfection. The number of cell cultures was measured by counting cells with a CellTac kit (Nihon Koden, Tokyo, Japan). siRNA knockdowns were performed in the two CRC cell lines to evaluate proliferation and invasion under *TDGF1* suppression. Each cell line with siRNA was compared to the wild-type and a negative control. Values were expressed as the mean ± standard error of mean (SEM) from five independent experiments.

RNA preparation and quantitative real-time reverse transcriptase-polymerase chain reaction (RT-PCR). Total RNA was prepared using TRIzol reagent and a PureLink RNA Mini kit (Invitrogen) in accordance with the manufacturer's protocols. RNA was reverse transcribed with SuperScriptIII (Invitrogen), and a 119-bp *TDGF1* fragment was amplified. Two human *TDGF1* oligonucleotide primers for the PCR reaction were designed as follows: 5'-AGATGGCCCGCTTCTTAC-3' (forward), 5'-CAGGTATCCCCGAGATGGAC-3' (reverse). The forward primer is located in exon 1 and the reverse primer is located in exon 2. PCR was performed with primers specific to the glyceraldehyde-3-phosphate dehydrogenase (*GAPDH*) gene. The *GAPDH* primers 5'-TTGGTATCGTGGAAGGAC TCA-3' (forward) and 5'-TGTCATCATATTGGCAGGTT-3' (reverse) produced a 270-bp amplicon. cDNA from the human reference total RNA (Clontech, Palo Alto, CA, USA) was used as a source of positive controls. Real-time PCR monitoring was performed using the Light Cycler FastStart DNA Master SYBR-Green I kit (Roche Diagnostics, Tokyo, Japan) for *TDGF1* and *GAPDH* cDNA amplification. The amplification protocol consisted of 35 cycles of denaturation at 95°C for 10 sec, annealing at 60°C for 10 sec, and elongation at 72°C for 10 sec. The products were then subjected to a temperature gradient from 55 to 95°C at 0.1°C s⁻¹ with continuous fluorescence monitoring to produce product melting curves. The expression ratio of mRNA copies in tumor and normal tissues was calculated and normalized against *GAPDH* mRNA expression.

Proliferation and invasion assays. To assess the cell proliferation after 48 h of siRNA transfection, they were grown for another 48 h. The cell viability was determined utilizing Cell Counting kit consisted of WST-8 (Dojin, Tokyo, Japan). WST-8 (10 µl) was added to the 100 µl medium containing each supplement above, and the absorbance was read at 450 nm using Microplate Reader (Model 680XR, Bio-Rad Laboratories, CA). All the experiments were performed at 50-80% cell confluence, and the results were confirmed in five independent experiments. The values were expressed as a ratio/control (every parental cell).

Cell invasion were assessed with CytoSelect Cell Invasion Assay according to the protocol of the manufacture (Cell Biolabs, San Diego, CA) after 48 h of the transfection. Cells (1.0x10⁵) in DMEM were placed on each 8.0-µm pore size membrane insert in 96-well plates. DMEM with 10% FBS was placed in the bottom wells. After 24 h, cells that did not invade were removed from the top side of the membrane chamber and completely dislodge the cells from the underside of the membrane by tilting the membrane chamber in the Cell Detachment Solution (Cell Biolabs). Lysis Buffer/CyQuant GR dye solution (Cell Biolabs) were added to each well, the fluorescence of the mixture was read with a fluorescence plate reader at 480/520 nm. The values were expressed as a ratio/control (every parental cell).

Statistical analysis. The variable data are expressed as mean ± SEM. The relationship between *TDGF1* expression and clinicopathological factors was analyzed with the χ^2 test. Kaplan-Meier survival curves were plotted and compared with the generalized log-rank test. Univariate and multivariate analyses were performed to identify prognostic factors using a Cox proportional hazard regression model. The Wilcoxon rank test was used to compare differences in *TDGF1* siRNA among the cell lines. All tests were analyzed with JMP software (SAS Institute, Cary, NC, USA). Differences with $p < 0.05$ were considered statistically significant.

Results

Expression of *TDGF1* in clinical tissue specimens and clinicopathological characteristics. We performed quantitative real-time RT-PCR with paired primary and adjacent non-cancerous CRC regions. RT-PCR on 55 paired clinical samples showed that 17 of these cases (30.9%) exhibited higher levels of *TDGF1* mRNA in tumors than in paired normal tissues. *TDGF1* expression was calculated by dividing *TDGF1*/*GAPDH* expression. For clinicopathological evaluation the experimental samples were divided into 2 groups according to expression status. Patients with values more than the median *TDGF1* expression value (median, 1,960) were assigned to the high-expression group and the others were assigned to the low-expression group. Clinicopathological factors related to the *TDGF1* expression status of the 55 patients are summarized in Table I. The results indicated that *TDGF1* expression was correlated with lymphatic invasion ($p=0.041$), venous invasion ($p=0.010$), and metastasis ($p=0.052$). To examine the correlation with metastasis, which indicated a poor prognosis, the data were divided into monochronous and metachronous metastasis groups, and *TDGF1* expression was evaluated for

Table I. Clinicopathological factors and *TDGF1* mRNA expression in 55 colorectal cancers.

Factors	High expression n=27 (%)	Low expression n=28 (%)	P-value
Age (years)			
≥68	11 (40.7)	16 (57.1)	0.222
<68	16 (59.3)	12 (42.9)	
Gender			
Male	14 (51.8)	17 (60.7)	0.507
Female	13 (48.2)	11 (39.3)	
Histological grade			
Wel/Mod	23 (85.2)	25 (89.3)	0.648
Others	4 (14.8)	3 (10.7)	
Tumor size			
≥50 mm	10 (37.0)	17 (60.7)	0.079
<50 mm	17 (63.0)	11 (39.3)	
Tumor invasion			
Tis	1 (3.7)	6 (21.4)	0.051
T1	0 (0)	4 (14.3)	
T2	6 (22.2)	5 (17.9)	
T3	17 (63.0)	10 (35.7)	
T4	3 (11.1)	3 (10.7)	
Lymph node metastasis			
N0	17 (66.7)	20 (71.4)	0.702
N1-2	9 (33.3)	8 (28.6)	
Lymphatic invasion			
Absent	4 (14.8)	11 (39.3)	<u>0.041</u>
Present	23 (85.2)	17 (60.7)	
Venous invasion			
Absent	11 (40.7)	21 (75.0)	<u>0.010</u>
Present	16 (59.3)	7 (25.0)	
Metastasis			
M0	17 (63.0)	24 (85.7)	0.052
M1	10 (37.0)	4 (14.3)	
UICC stage			
0	1 (3.7)	6 (21.4)	0.133
I	4 (14.8)	8 (28.6)	
IIA	7 (25.9)	5 (17.8)	
IIB	2 (7.4)	1 (3.6)	
IIIA	1 (3.7)	0 (0)	
IIIB	2 (7.4)	2 (7.1)	
IIIC	0 (0)	2 (7.1)	
IV	10 (37.0)	4 (14.3)	

Statistically significant values are underlined. Wel, well differentiated adenocarcinoma; Mod, moderately differentiated adenocarcinoma; Others, poorly differentiated adenocarcinoma and mucinous carcinoma.

Table II. Metastasis and *TDGF1* mRNA expression in the 55 patients.

Factors	High expression n=27 (%)	Low expression n=28 (%)	P-value
Monochronous metastasis			
Absent	24 (88.9)	25 (89.3)	0.052
Present	3 (11.1)	3 (10.7)	
Metachronous metastasis			
Absent	17 (70.8)	24 (96.0)	<u>0.017</u>
Present	7 (29.2)	1 (4.0)	

Underlined values indicate statistical significance.

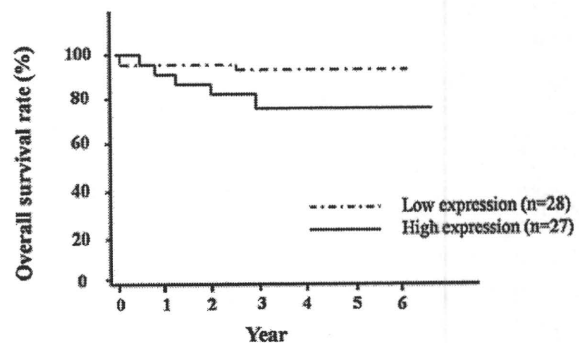


Figure 1. Overall survival rates of colorectal cancer patients based on *TDGF1* mRNA expression status. The overall survival rate was lower in the *TDGF1* high-expression group than the low-expression group ($p=0.144$).

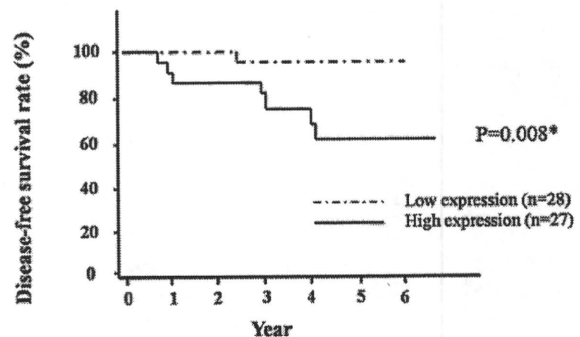


Figure 2. Disease-free survival rates of colorectal cancer patients, exclusive of monochronous metastasis, based on *TDGF1* mRNA expression status. The disease-free survival rate was significantly lower in patients whose samples highly expressed *TDGF1* mRNA than those with lower expression ($p=0.008$).

each factor (summarized in Table II). The results indicated that *TDGF1* expression was significantly correlated with metachronous metastasis ($p=0.017$).

Relationship between *TDGF1* expression and prognosis. Post-operative overall survival was shorter in patients with elevated *TDGF1* expression ($p=0.144$) than in those with lower expression. The median follow-up was 4.16 years (Fig. 1). We also evaluated disease-free survival based on the relationship between *TDGF1* expression and metachronous metastasis after

Table III. Univariate and multivariate analyses for disease-free survival in 49 patients with curative surgery (Cox proportional hazards regression model).

Factors	Univariate analysis			Multivariate analysis		
	RR	95% CI	P-value	RR	95% CI	P-value
Age (years)						
≤68/>68	1.84	0.45-9.01	0.391			
Gender						
Male/female	2.17	0.62-18.62	0.192			
Histological grade						
Por-others/well-mod	713.31	-	0.241			
Tumor size (mm)						
≥50/<50	3.34	0.76-22.91	0.110			
Tumor invasion						
T3-4/Tis-2	3.02	0.69-20.70	0.145			
Lymph node metastasis						
N1-2/N0	4.21	0.99-17.85	0.051			
Lymphatic invasion						
Present/absent	-	-	<u>0.014</u>	-	-	0.067
Venous invasion						
Present/absent	2.53	0.59-10.72	0.196			
<i>TDGF1</i> mRNA expression						
< Median/≥ median	10.42	1.84-195.08	<u>0.005</u>	7.78	1.37-146.02	<u>0.017</u>

Statistically significant values are underlined. RR, relative risk; CI, confidence interval; Wel, well differentiated adenocarcinoma; Mod, moderately differentiated adenocarcinoma; Por, poorly differentiated adenocarcinoma; Others, poorly differentiated adenocarcinoma and mucinous carcinoma.

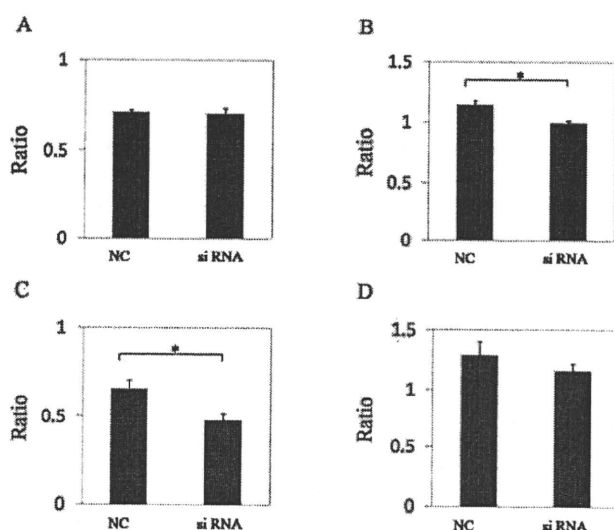


Figure 3. *In vitro* assays with siRNA inhibition in the two colorectal cancer cell lines. A proliferation assay was performed in two colorectal cancer cell lines (A, HCT116; B, LoVo). There were significant differences between NC and *TDGF1* siRNA in LoVo (n=5, *p=0.008). An invasion assay was performed in them (C, HCT116; D, LoVo). There were significant differences between NC and *TDGF1* siRNA in HCT116 (n=5, *p=0.009). *In vitro* assays showed differences in the ratio with control (untreated) cells. Values are means and SEM. NC, negative control.

curative surgery in 49 patients except stage IV at the time of primary operation. The disease-free survival rate was significantly lower in patients with elevated *TDGF1* expression (p=0.008; Fig. 2) than in those with lower expression. Table III shows the univariate and multivariate analyses of factors related to metastatic-free survival in 49 patients. The univariate analysis revealed that *TDGF1* expression (p=0.005) and lymphatic invasion (more than maximum repetition, p=0.014) were significantly correlated with post-operative metastasis. The multivariate regression analysis indicated that inclusion in the *TDGF1* high-expression group (relative risk, 7.78; 95% confidence interval, 1.37-146.02; p=0.017) was an independent predictor of metastatic-free survival.

In vitro assessment of *TDGF1* expression knock-down. Two CRC cell lines were chosen for the proliferation and invasion study. A significant reduction in *TDGF1* by siRNA was also confirmed by quantitative real-time RT-PCR. The proliferation study was confirmed by seeding the cells (1.0×10^5) in 6-well dishes and culturing them for 48 h to determine proliferation. The results showed significant differences in HCT116 and LoVo cell numbers between NC and *TDGF1* siRNA (n=5, p<0.05, Fig. 3A and B). In the invasion study, the results showed significant differences in DLD-1 and LoVo between NC and *TDGF1* siRNA (n=5, p<0.05, Fig. 3C and D).

Discussion

TDGF1, also known as *CRYPTO*, *Crypto-1*, or *CR-1*, is expressed in various cancer tissues of different species (16,20-23). Previous *in vitro* and *in vivo* reports show that *TDGF1* regulates signaling pathways and cellular mechanisms as an oncogene (23-26). In mammary tumor, *TDGF1* is associated with molecular mechanisms that contribute to the loss of adherent junctions, referred to as epithelial-mesenchymal transition, which plays an important role in cancer invasiveness and metastasis and might cause a poor prognosis (25-28). The combined expression of *TDGF1* and E-cadherin by immunohistochemistry indicates a poor prognosis in gastric cancer (16).

The present study showed that *TDGF1* expression is an independent predictive factor for metachronous CRC metastasis, and the siRNA inhibition experiment demonstrated the functional relevance of expressed *TDGF1* in the CRC cell lines. To the best of our knowledge, this is the first report to show that *TDGF1* is a predictive marker for CRC metastasis, supported by the functional relevance to cell growth and invasion.

It can be useful to identify the necessity for intensive follow-up and adjuvant therapy by predicting CRC recurrence and metastases after curative surgical resection (29-31). Our clinicopathological analysis revealed that CRC patients with high *TDGF1* expression had a poorer prognosis for disease-free survival than the low-expression group. The results indicated that *TDGF1* is a good predictor for metachronous metastasis, and patients can be followed-up by curative surgical intervention. It is essential to prevent metachronous metastasis during gastrointestinal cancer therapy. Several adjuvant chemotherapies are helpful in particular disease stages, especially in CRC, and indicate the usefulness of a less invasive surgical approach for CRC (31-36). For these cases, a predictive informative marker for tumor recurrence, which is independent from traditional TNM classification and collectively contributes to diagnoses and treatments is very important. While improvement in preoperative and postoperative treatments such as chemotherapy and radiotherapy combined with surgery have contributed to a reduction in the recurrence and metastasis of CRC, half of the cases ultimately metastasize despite systemic chemotherapy followed by surgery (37). Adjuvant chemotherapy for CRC is desirable in highly suspicious metastatic cases. In these cases, an analysis of *TDGF1* may be useful to predict and treat patients with a poor prognosis.

Acknowledgements

We would like to thank Kimie Kitagawa for the technical assistance.

References

- Jemal A, Siegel R, Ward E, *et al*: Cancer statistics, 2008. *CA Cancer J Clin* 58: 71-96, 2008.
- Jones OM, John SK, Horseman N, Lawrance RJ and Fozard JB: Cause and place of death in patients dying with colorectal cancer. *Colorectal Dis* 9: 253-257, 2007.
- Kohno SI, Luo C, Nawa A, *et al*: Oncolytic virotherapy with an HSV amplicon vector expressing granulocyte-macrophage colony-stimulating factor using the replication-competent HSV type 1 mutant HF10 as a helper virus. *Cancer Gene Ther* 14: 918-926, 2007.
- Yamasaki M, Takemasa I, Komori T, *et al*: The gene expression profile represents the molecular nature of liver metastasis in colorectal cancer. *Int J Oncol* 30: 129-138, 2007.
- Aliaga JC, Deschenes C, Beaulieu JF, Calvo EL and Rivard N: Requirement of the MAP kinase cascade for cell cycle progression and differentiation of human intestinal cells. *Am J Physiol* 277: G631-G641, 1999.
- Yamatodani T, Ekblad L, Kjellen E, Johnsson A, Mineta H and Wennerberg J: Epidermal growth factor receptor status and persistent activation of Akt and p44/42 MAPK pathways correlate with the effect of cetuximab in head and neck and colon cancer cell lines. *J Cancer Res Clin Oncol* 135: 395-402, 2009.
- Salomon DS, Bianco C and De Santis M: Cripto: a novel epidermal growth factor (EGF)-related peptide in mammary gland development and neoplasia. *Bioessays* 21: 61-70, 1999.
- Saeki T, Stromberg K, Qi CF, *et al*: Differential immunohistochemical detection of amphiregulin and cripto in human normal colon and colorectal tumors. *Cancer Res* 52: 3467-3473, 1992.
- Ciardiello F, Kim N, Saeki T, *et al*: Differential expression of epidermal growth factor-related proteins in human colorectal tumors. *Proc Natl Acad Sci USA* 88: 7792-7796, 1991.
- Tsutsumi M, Yasui W, Naito A, *et al*: Expression of cripto in human pancreatic tumors. *Jpn J Cancer Res* 85: 118-121, 1994.
- Friess H, Yamanaka Y, Buchler M, Koblin MS, Tahara E and Korc M: Cripto, a member of the epidermal growth factor family, is over-expressed in human pancreatic cancer and chronic pancreatitis. *Int J Cancer* 56: 668-674, 1994.
- Qi CF, Liscia DS, Normanno N, *et al*: Expression of transforming growth factor alpha, amphiregulin and cripto-1 in human breast carcinomas. *Br J Cancer* 69: 903-910, 1994.
- Fontanini G, De Laurentiis M, Vignati S, *et al*: Evaluation of epidermal growth factor-related growth factors and receptors and of neoangiogenesis in completely resected stage I-IIIa non-small-cell lung cancer: amphiregulin and microvessel count are independent prognostic indicators of survival. *Clin Cancer Res* 4: 241-249, 1998.
- D'Antonio A, Losito S, Pignata S, *et al*: Transforming growth factor alpha, amphiregulin and cripto-1 are frequently expressed in advanced human ovarian carcinomas. *Int J Oncol* 21: 941-948, 2002.
- Ertay D, Ayhan A, Sarac E, Karaagaoglu E, Yasui W and Tahara E: Clinicopathological implication of cripto expression in early stage invasive cervical carcinomas. *Eur J Cancer* 36: 1002-1007, 2000.
- Zhong XY, Zhang LH, Jia SQ, *et al*: Positive association of up-regulated Cripto-1 and down-regulated E-cadherin with tumour progression and poor prognosis in gastric cancer. *Histopathology* 52: 560-568, 2008.
- Sobin LH and Fleming ID: TNM Classification of Malignant Tumors, 5th edition. Union Internationale Contre le Cancer and the American Joint Committee on Cancer. *Cancer* 80: 1803-1804, 1997.
- Aznavorian S, Liotta LA and Kupchik HZ: Characteristics of invasive and noninvasive human colorectal adenocarcinoma cells. *J Natl Cancer Inst* 82: 1485-1492, 1990.
- Ishizu K, Sunose N, Yamazaki K, *et al*: Development and characterization of a model of liver metastasis using human colon cancer HCT-116 cells. *Biol Pharm Bull* 30: 1779-1783, 2007.
- Bianco C, Strizzi L, Ebert A, *et al*: Role of human cripto-1 in tumor angiogenesis. *J Natl Cancer Inst* 97: 132-141, 2005.
- Wechselberger C, Strizzi L, Kenney N, *et al*: Human Cripto-1 overexpression in the mouse mammary gland results in the development of hyperplasia and adenocarcinoma. *Oncogene* 24: 4094-4105, 2005.
- Sun Y, Strizzi L, Raafat A, *et al*: Overexpression of human Cripto-1 in transgenic mice delays mammary gland development and differentiation and induces mammary tumorigenesis. *Am J Pathol* 167: 585-597, 2005.
- Strizzi L, Bianco C, Normanno N, *et al*: Epithelial mesenchymal transition is a characteristic of hyperplasias and tumors in mammary gland from MMTV-Cripto-1 transgenic mice. *J Cell Physiol* 201: 266-276, 2004.
- Ebert AD, Wechselberger C, Nees M, *et al*: Cripto-1-induced increase in vimentin expression is associated with enhanced migration of human Caski cervical carcinoma cells. *Exp Cell Res* 257: 223-229, 2000.
- Savagner P: Leaving the neighborhood: molecular mechanisms involved during epithelial-mesenchymal transition. *Bioessays* 23: 912-923, 2001.

26. Behrens J, Lowrick O, Klein-Hitpass L and Birchmeier W: The E-cadherin promoter: functional analysis of a G.C-rich region and an epithelial cell-specific palindromic regulatory element. *Proc Natl Acad Sci USA* 88: 11495-11499, 1991.
27. Boyer B, Valles AM and Edme N: Induction and regulation of epithelial-mesenchymal transitions. *Biochem Pharmacol* 60: 1091-1099, 2000.
28. Mani SA, Guo W, Liao MJ, *et al*: The epithelial-mesenchymal transition generates cells with properties of stem cells. *Cell* 133: 704-715, 2008.
29. Wolpin BM and Mayer RJ: Systemic treatment of colorectal cancer. *Gastroenterology* 134: 1296-1310, 2008.
30. Kornmann M, Formentini A, Ette C, *et al*: Prognostic factors influencing the survival of patients with colon cancer receiving adjuvant 5-FU treatment. *Eur J Surg Oncol* 34: 1316-1321, 2008.
31. Bathe OF, Dowden S, Sutherland F, *et al*: Phase II study of neoadjuvant 5-FU + leucovorin + CPT-11 in patients with resectable liver metastases from colorectal adenocarcinoma. *BMC Cancer* 4: 32, 2004.
32. Andre T, Quinaux E, Louvet C, *et al*: Phase III study comparing a semimonthly with a monthly regimen of fluorouracil and leucovorin as adjuvant treatment for stage II and III colon cancer patients: final results of GERCOR C96.1. *J Clin Oncol* 25: 3732-3738, 2007.
33. Lacy AM, Garcia-Valdecasas JC, Delgado S, *et al*: Laparoscopy-assisted colectomy versus open colectomy for treatment of non-metastatic colon cancer: a randomised trial. *Lancet* 359: 2224-2229, 2002.
34. Weeks JC, Nelson H, Gelber S, Sargent D and Schroeder G: Short-term quality-of-life outcomes following laparoscopic-assisted colectomy vs open colectomy for colon cancer: a randomized trial. *JAMA* 287: 321-328, 2002.
35. Clinical Outcomes of Surgical Therapy Study Group: A comparison of laparoscopically assisted and open colectomy for colon cancer. *N Engl J Med* 350: 2050-2059, 2004.
36. Jayne DG, Guillou PJ, Thorpe H, *et al*: Randomized trial of laparoscopic-assisted resection of colorectal carcinoma: 3-year results of the UK MRC CLASICC Trial Group. *J Clin Oncol* 25: 3061-3068, 2007.
37. Koshariya M, Jagad RB, Kawamoto J, *et al*: An update and our experience with metastatic liver disease. *Hepatogastroenterology* 54: 2232-2239, 2007.

Overexpression of *SUGT1* in human colorectal cancer and its clinicopathological significance

MASAAKI IWATSUKI^{1,2}, KOSHI MIMORI¹, TETSUYA SATO³, HIROYUKI TOH³, TAKEHIKO YOKOBORI¹, FUMIAKI TANAKA¹, KOICHI ISHIKAWA¹, HIDEO BABA² and MASAKI MORI¹

¹Department of Surgical Oncology, Medical Institute of Bioregulation, Kyushu University, Beppu;

²Department of Gastroenterological Surgery, Graduate School of Medical Sciences, Kumamoto University,

Kumamoto; ³Division of Bioinformatics, Medical Institute of Bioregulation, Kyushu University, Fukuoka, Japan

Received June 17, 2009; Accepted August 4, 2009

DOI: 10.3892/ijo_00000531

Abstract. As recent technological innovations make it possible to clarify the concordant relationship between genomic alterations and aberrant gene expression during the progression of colorectal cancer (CRC), we aimed at identifying new overexpressing genes with genomic amplification on the responsible loci in CRC. The candidate gene was found using cDNA microarray and array-based comparative genomic hybridization (CGH) analysis after laser microdissection (LMD) in 132 Japanese CRC. We focused on *SUGT1*, which is associated with the assembling of kinetochore proteins at the metaphase of the cell cycle, with significant association between genetic alterations and expression. *SUGT1* mRNA expression was evaluated in 98 CRC cases to determine the clinicopathological significance of *SUGT1* expression. The mean level of *SUGT1* mRNA expression in tumor tissue specimens was significantly higher than in non-tumor tissue. The high *SUGT1* expression group was characterized by a significantly elevated frequency of recurrence and a significantly poorer prognosis than the low expression group. There was a significant association between poor prognosis of CRC cases and the overexpression of *SUGT1* with genomic amplification of the loci concordantly. The amplification of *SUGT1* might give rise to promote the transcription of the gene directly subsequent to the progression of CRC cases with worsening prognosis.

Introduction

The morbidity and mortality rates of colorectal cancer (CRC) in the United states and Europe have decreased recently

(1,2), yet further studies are required to better understand this disease. Recent technological innovations now permit us to clarify DNA copy number alterations in CRC by using high resolution, array-based comparative genomic hybridization (array CGH), resulting in the definition of a specific pattern of DNA gains or losses (3-7). Tsafir *et al* reported a correlation between gene expression and chromosomal aberrations in CRC using array CGH and cDNA microarray analysis (8). Their study focused on particular chromosomal regions and genes that are frequently gained and overexpressed (e.g., 7p, 8q, 13q and 20q) or lost and underexpressed (e.g., 1p, 4, 5q, 8p, 14q, 15q and 18). Based on these data, they identified genetic alterations which had prognostic significance.

From a technical point of view, it is easier to handle genomic DNA than mRNA, as the latter is fragile, and unstable. Therefore, we sought to identify genes whose impact could be determined by assessment of genomic copy number. We employed cDNA microarray analysis to identify candidate molecular markers that play a significant role in the progression of CRC by comparing resected cancer cells and the corresponding non-malignant cells extracted by means of laser microdissection (LMD) (9-11). Then, we performed cDNA microarray and array CGH analysis after LMD in a large scale study of Japanese CRC patients to identify new genomically amplified genes and determine the impact of their presence.

In the present study, we focused on a gene at 13q that is known to be frequently amplified (6,8,12) and shed light on the overexpression of *SUGT1* (suppressor of G2 allele of SKP1:13q14.3). We examined its expression and determined the correlation of gene with genomic amplification with CRC outcome. Originally, *SUGT1* was identified as a protein activating the kinetochore and SCF ubiquitin ligase complexes via interaction with Skp1 protein, which plays a crucial role in cell cycle regulation (13). The present study clarifies the clinical significance of the expression of *SUGT1* in human CRC cases.

Materials and methods

Laser micro-dissection. The tissues from a series of 132 patients with CRC were collected for laser micro-dissection

Correspondence to: Dr Masaki Mori, Department of Surgical Oncology, Medical Institute of Bioregulation, Kyushu University, 4546 Tsurumihara, Beppu 874-0838, Japan
E-mail: mmori@gesurg.med.osaka-u.ac.jp

Key words: *SUGT1*, colorectal cancer, CGH array, cDNA microarray, 13q

(LMD; Leica Laser Microdissection System, Leica Microsystems, Wetzlar, Germany) as previously described (14). For LMD, 5 μ m frozen sections were fixed in 70% ethanol for 30 sec, stained with hematoxylin and eosin and dehydrated as follows: 5 sec each in 70, 95 and 100% ethanol and a final 5 min in xylene. Sections were air-dried, then micro-dissected by LMD. Target cells were excised, ≥ 100 cells per section, and bound to the transfer film, and total DNA extracted.

cDNA microarray. We used the commercially available Human Whole Genome Oligo DNA Microarray Kit (Agilent Technologies, Santa Clara, CA, USA). A list of genes on this cDNA microarray is available from <http://www.chem.agilent.com/scripts/generic.asp?lpage=5175&indcol=Y&prodcol=N&indcol=Y&prodcol=N>. Cyanine (Cy)-labeled cRNA was prepared using T7 linear amplification as described in the Agilent Low RNA Input Fluorescent Linear Amplification Kit Manual (Agilent Technologies). Labeled cRNA was fragmented and hybridized to an oligonucleotide microarray (whole human genome 4x44K Agilent G4112F). Fluorescence intensities were determined with an Agilent DNA microarray scanner and were analyzed using G2567AA Feature Extraction Software Version A.7.5.1 (Agilent Technologies), which used the LOWESS (locally weighted linear regression curve fit) normalization method (15). This microarray study followed MIAME guidelines issued by the Microarray Gene Expression Data group (16). Further analyses were performed using GeneSpring version 7.3 (Silicon Genetics, San Carlos, CA, USA).

Array-CGH. Array-CGH was performed using the Agilent Human Genome Microarray Kit 244K (Agilent Technologies). The array-CGH platform is a high resolution 60-mer oligonucleotide-based microarray containing ~244,400 probes spanning coding and non-coding genomic sequences with median spacing of 7.4 and 16.5 kb, respectively. Labeling and hybridization were performed according to the protocol provided by Agilent (Protocol v4.0, June 2006). Arrays were analyzed using Agilent DNA microarray scanner.

Array-CGH data analysis. The raw signal intensities of tumor DNAs were measured with Human Genome CGH Microarray 244K (Agilent Technologies) which were then transformed into log ratios to reference DNA with 'Feature Extraction' software (v9.1) of Agilent Technologies. The log ratio was thereafter used as the signal intensity of each probe. One hundred and thirty samples from different patients were subjected to circular binary segmentation (CBS) after median normalization (17). An R script written by us was used for the median normalization, whereas an R program implemented in the 'DNA copy' package of the Bioconductor project (<http://www.bioconductor.org>) was used for the CBS analysis. Instead of all of the CGH probes, 13,403 probes from chromosome 4 (NCBI Build 35) were analyzed in this study. An absolute log₂ ratio >0.263 was used as the threshold for the gain or loss in DNA copy number for each probe.

Clinical samples. The tissues from another series of 98 CRC patients with information about clinicopathological features

including prognosis were collected at Kyushu University at Beppu and affiliated hospitals between 1993 and 1999. Resected tumor and paired non-tumor tissue specimens were immediately cut from resected colon and placed in RNA Later (Takara, Shiga, Japan) or embedded in Tissue Tek OCT medium (Sakura, Tokyo, Japan), frozen in liquid nitrogen and kept at -80°C until RNA extraction. The median follow-up period was 3.0 years. Written informed consent was obtained from all patients and the study protocol was approved by the local ethics committee.

Total RNA extraction and first-strand cDNA synthesis. Frozen tissue specimens were homogenized, and the total RNA was extracted using the modified acid-guanidine-phenol-chloroform method as described previously (18,19). Total RNA (8.0 μ g) was reverse transcribed to cDNA using M-MLV RT (Invitrogen Corp. Carlsbad, CA, USA).

Quantitative RT-PCR. The primer sequences for *SUGT1* mRNA were as follows: sense, 5'-CTG ACT AAG GCT TTG GAA CAG AA-3'; antisense, 5'-CTG TAA AAG TTT CTA GGG CAG CA-3'. Glyceraldehyde-3-phosphate dehydrogenase (*GAPDH*) was used as an internal control and *GAPDH* primers were as follows: sense, 5'-TTG GTA TCG TGG AAG GAC TCT A-3'; and antisense, 5'-TGT CAT ATT TGG CAG GTT-3'. Real-time monitoring of PCR reactions was performed using the LightCycler™ system (Roche Applied Science, Indianapolis, IN, USA) and SYBER-Green I dye (Roche). Monitoring was performed according to the manufacturer's instructions, as described previously (20). In brief, a master mixture was prepared on ice, containing 1 μ l of cDNA, 2 μ l of DNA Master SYBER-Green I mix, 50 ng of primers and 2.4 μ l of 25 mM MgCl_2 . The final volume was adjusted to 20 μ l with water. After the reaction mixture was loaded into glass capillary tubes, quantitative RT-PCR was performed with the following cycling conditions: initial denaturation at 95°C for 10 min, followed by 40 cycles of 95°C for 10 sec, annealing at 62°C for 10 sec and extension 72°C for 10 sec. After amplification, products were subjected to a temperature gradient from 67 to 95°C at $0.2^{\circ}\text{C}/\text{sec}$, under continuous fluorescence monitoring, to produce a melting curve of products.

Data analysis for quantitative RT-PCR. We used LightCycler Software version 3.5 program (Roche Molecular Biochemicals) to calculate the cycle numbers. After proportional baseline adjustment, the fit point method was employed to determine the cycle in which the log-linear signal was first distinguishable from the baseline. This cycle number was used as the crossing point value. A standard curve was produced by measuring the crossing point of each standard value and plotting it against the logarithmic value of concentration. Concentrations of unknown samples were calculated by plotting their crossing points against the standard curve and dividing by *GAPDH* content. *GAPDH* expression confirmed no differences between tumor and normal tissue.

Immunohistochemistry. Immunohistochemistry studies of *SUGT1* were performed on formalin-fixed, paraffin-embedded surgical sections obtained from patients with CRC. Tissue




Figure 1. Heat-map representation of *SUGT1* copy number aberrations in CRC specimens determined by CGH array. Each column represents CRC cases arranged according to TNM staging. *SUGT1* location is enclosed in lines. Copy number loss is indicated in green, gain in red.

sections were deparaffinized, soaked in 0.01 M sodium citrate buffer and boiled in a microwave for 5 min at 500 W to retrieve cell antigens. The primary rabbit polyclonal antibodies against *SUGT1* (Protein Tech Group Inc., Chicago, IL, USA) were used at a dilution of 1:150. Tissue sections were immunohistochemically stained using EnVision reagents (EnVision[®] Dual Link System-HRP, Dako Cytomation, Glostrup, Denmark). All sections were counterstained with hematoxylin.

Statistical analysis. For continuous variables, data were expressed as the means \pm SD. The relationship between *SUGT1* mRNA expression and clinicopathological factors was analyzed using a χ^2 test and Student's t-test. Overall survival curves were plotted according to the Kaplan-Meier method and the generalized log-rank test was applied to compare the survival curves. All tests were analyzed using JMP software (SAS Institute Inc., Cary, NC) and the findings were considered significant when p-value was <0.05 .

Results

Aberrations in *SUGT1* copy number in CRC specimens. We investigated copy number aberrations in 132 CRC specimens

using laser micro-dissection and CGH array. We focused on chromosome 13q which is reportedly amplified in CRC. Fig. 1 shows the heat map representation of copy number aberrations in 13q according to TNM staging classification. As shown in Fig. 2, there is a significant association between genetic alterations and expression of *SUGT1* (correlation coefficient: 0.665, $p<0.0001$). Therefore, gain of *SUGT1* expression was caused by genetic alteration in the flanking region of *SUGT1*. We noted copy number amplification in 44 cases (33.3%). The frequency of copy number amplification of *SUGT1* increased along with the progression of TNM stage.

Expression of *SUGT1* mRNA in CRC cases. *SUGT1* mRNA expression in 98 clinical tissue specimens was examined by reverse transcription-polymerase chain reaction (RT-PCR) and real-time quantitative RT-PCR, with quantified values used to calculate *SUGT1*/*GAPDH* ratios. Results indicated that the mean level of expression of *SUGT1* mRNA in tumor tissue specimens was significantly higher than that in non-tumor tissue ($p=0.0009$) (Fig. 3A).

Immunohistochemistry of *SUGT1* protein expression in CRC cases. Expression of *SUGT1* protein was evaluated by

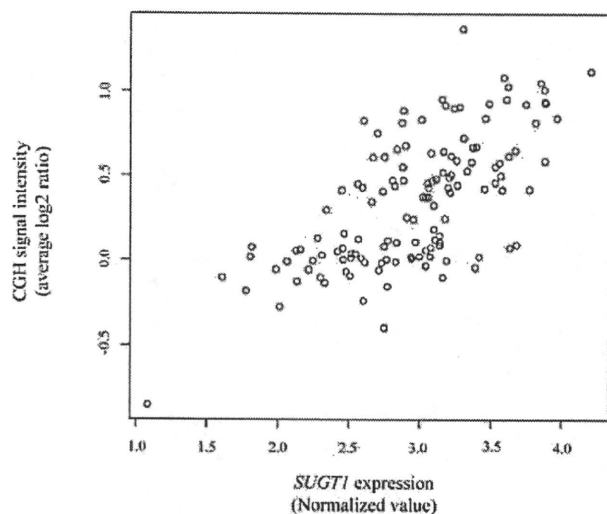


Figure 2. Concordant amplification of *SUGT1* expression and copy number alteration in the flanking regions of *SUGT1*. There is a significant association between genetic alterations and expression of *SUGT1* (correlation coefficient: 0.665, $p < 0.0001$). The x-axis indicates the normalized *SUGT1* expression value of cDNA microarray and y-axis CGH signal intensity (average log2 ratio) in the flanking regions of *SUGT1*.

immunohistochemistry of resected colon cancer specimens using an anti-SUGT1 antibody. SUGT1 staining was remarkably stronger in colon cancer tissues than in corresponding normal tissues. SUGT1 expression was localized to the cell cytoplasm (Fig. 3B and C).

Clinicopathological significance of *SUGT1* mRNA in CRC cases. We divided the 98 CRC cases into two groups according to the median tumor (T)/normal (N) ratio of *SUGT1* mRNA expression level as determined above. Thus, 49 cases were placed in the high *SUGT1* expression group and 49 cases in the low *SUGT1* expression group. The association between clinicopathological features and *SUGT1* mRNA expression is summarized in Table I. In the high *SUGT1* expression group, the frequency of recurrence was elevated compared to the low *SUGT1* expression group ($p = 0.03$). Univariate analysis identified *SUGT1* expression, tumor size, depth of tumor invasion, lymph node metastasis, lymphatic invasion and venous invasion as prognostic factors for 5-year overall survival following surgery. Variables with p -values < 0.05 by univariate analysis were selected for multivariate analysis using Cox's proportional hazards model. *SUGT1* expression [relative risk (RR): 1.55, confidence interval (CI) 1.00-2.47, $p = 0.04$] was found to be a significant factor affecting 5-year overall survival following surgery in multivariate analysis (Table II). Analysis of 5-year overall survival curves showed that patients in the high *SUGT1* expression group had a significantly poorer prognosis than those in the low expression group ($p = 0.04$) (Fig. 4).

Discussion

In the present study, we performed cDNA microarray and array CGH analysis after LMD in a large scale study of 132 Japanese CRC cases. Because chromosome 13q is reportedly amplified in CRC, we focused on the gene *SUGT1* that had

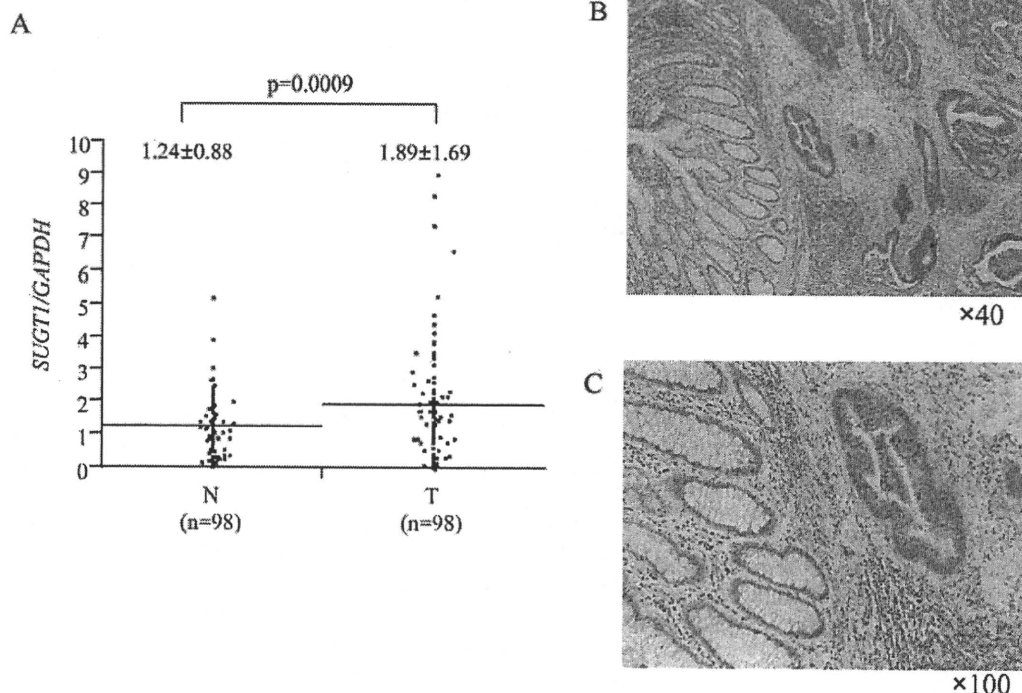


Figure 3. *SUGT1* expression in CRC. (A) *SUGT1* mRNA expression in cancer and non-cancer tissues from CRC patients as assessed by real-time quantitative PCR ($n = 98$). Horizontal lines indicate mean value in each group (T, cancer tissue; N, non-cancerous tissue) (B and C). Immunohistochemical analysis of CRC patient samples with SUGT1 antibody. The majority of staining occurred in cancer cells (original magnification: B, $\times 40$; C, $\times 100$).

Table I. *SUGT1* mRNA expression and clinicopathological factors.

Factors	Tumor low expression (n=49)		Tumor high expression (n=49)		p-value
	No.	%	No.	%	
Age (mean \pm SD)	65.7 \pm 1.8		67.1 \pm 1.8		0.58
Sex					
Male	31	63.3	28	57.1	0.53
Female	18	36.7	21	42.9	
Histological grade					
Well	14	28.6	23	46.9	0.08
Moderately, poorly	35	71.4	26	53.1	
Size					
<50 mm (small)	23	46.9	17	34.7	0.21
>51 mm (large)	26	53.1	32	65.3	
Depth of tumor invasion ^a					
m, sm, mp,ss	17	34.7	14	28.6	0.51
se, si	32	65.3	35	71.4	
Lymph node metastasis					
Absent	31	63.3	24	49.0	0.15
Present	18	36.7	25	51.0	
Lymphatic invasion					
Absent	32	65.3	28	57.1	0.41
Present	17	34.7	21	42.9	
Venous invasion					
Absent	42	85.7	42	85.7	1.00
Present	7	14.3	7	14.3	
Liver metastasis					
Absent	45	91.8	47	95.9	0.39
Present	4	8.2	2	4.1	
Peritoneal dissemination					
Absent	48	98.0	46	93.9	0.29
Present	1	2.0	3	6.1	
Distant metastasis					
Absent	44	89.8	44	89.8	1.00
Present	5	10.2	5	10.2	
Recurrence					
Absent	42	85.7	33	67.4	0.03
Present	7	14.3	16	32.6	
TNM staging					
I, II	31	63.3	23	46.9	0.10
III, IV	18	36.7	26	53.1	

^aTumor invasion of mucosa (m), submucosa (sm), muscularis propria (mp), subserosa (ss), penetration of serosa (se), and invasion of adjacent structures (si).

Table II. Results of univariate and multivariate analysis of clinicopathological factors for 5-year overall survival.

Factors	Univariate analysis			Multivariate analysis		
	RR ^a	95% CI ^b	p-value	RR	95% CI	p-value
Age (<65/>66)	0.81	0.54-1.18	0.26	-	-	-
Sex (male/female)	0.98	0.65-1.43	0.92	-	-	-
Histology grade (well/mod and poor)	1.23	0.83-1.91	0.33	-	-	-
Tumor size (<50 mm/>51 mm)	1.57	1.06-2.33	0.02	1.37	1.06-2.42	0.02
Depth of tumor invasion (m, sm, mp,ss/se, si) ^c	1.92	1.30-2.82	0.001	1.56	1.03-2.39	0.04
Lymph node metastasis (negative/positive)	2.30	1.51-3.80	<0.001	2.02	1.29-3.40	0.002
Venous invasion (negative/positive)	1.91	1.25-2.84	0.004	1.77	1.12-2.71	0.02
<i>SUGT1</i> mRNA expression (low/high)	1.47	1.00-2.21	0.04	1.55	1.00-2.47	0.04

^aRR, relative risk; ^bCI, confidence interval. ^cTumor invasion of mucosa (m), submucosa (sm), muscularis propria (mp), subserosa (ss), penetration of serosa (se), and invasion of adjacent structures (si).

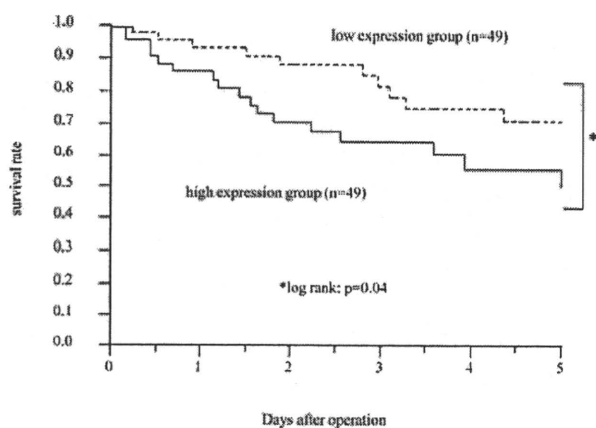


Figure 4. Kaplan-Meier 5-year overall survival curves for CRC patients according to the level of *SUGT1* mRNA expression. The overall survival rate for patients in the low expression group was significantly higher than that for patients in the high expression group ($p=0.04$, log-rank test). Low expression group (broken line, $N=49$). High expression group (unbroken line, $N=49$).

significant correlation between array CGH and cDNA microarray to determine its impact on progression of CRC. The ability to perform high-resolution genome-wide DNA copy number analysis on array CGH analysis allowed us to directly determine changes in DNA copy number in CRC. In a previous study, Platzer *et al* showed that chromosomal amplifications were observed frequently in CRC metastasis (7p, 8q, 13q and 20q), but increased expression of genes within these amplicons was rare (12). Tsafirir *et al* showed that particular chromosomal regions are frequently amplified and overexpressed (e.g., 7p, 8q, 13q and 20q) in the majority

of metastatic samples (8). The methodologies used in those studies might have caused the discrepancy between their results. In addition, we recommend that the microdissected cells extracted from CRC tumors should be applied for array CGH analysis to avoid bias in the quantity and quality (5,6). It is possible that the reported discrepancies between the amplified genetic regions and the transcriptional levels are not only characteristic of the genes themselves, but also due to technical errors. Lassmann *et al* and Kim *et al* used microdissected samples and demonstrated a positive association between array CGH and cDNA microarray data for *BRCA2* at the 13q locus (6) and *CAMTA1* at the 1p locus (5) ($p<0.0001$ and $p=0.009$, respectively). In our large scale study using microdissected samples, we confirmed their findings of a significant relationship between gene dosage and expression level.

Our focus on the *SUGT1* gene demonstrated a strong correlation between array CGH and cDNA microarray. The expression of *SUGT1* in CRC was significantly higher in tumor tissues compared to normal tissues, as demonstrated by both quantitative RT-PCR and immunohistochemical analysis (Fig. 3). Furthermore, we found that the frequency of disease recurrence after surgery in the high *SUGT1* expression group was significantly elevated in comparison to that in the low expression group ($p=0.03$) (Table I). Thus, the high *SUGT1* expression group had a significantly poorer prognosis than those in the low expression group ($p=0.04$) (Fig. 4). Furthermore, *SUGT1* expression was an independent and significant prognostic factor for survival (Table II).

The association between poor clinical outcome and overexpression of *SUGT1* may be explained as follows. Interaction of *SUGT1* with HSP90 is required for the assembly of the human kinetochore from late S phase to G2/M phase (21).

Furthermore, depletion of SUGT1 sensitizes HeLa cells to the HSP90 inhibitor, 17-allylaminogeldanamycin (17-AAG), which is currently in clinical trials (22). 17-AAG is thought to exert antitumor activity by simultaneously targeting several oncogenic signaling pathways. The study also revealed that overexpression of *SUGT1* might restore the localization of kinetochore proteins and chromosome alignment in cells treated by 17-AAG. Thus, overexpression of SUGT1 reduced tumor cell susceptibility to chemotherapy. In this regard, we performed adjuvant chemotherapy in half of the CRC patients with lymph node metastasis after the curative operation. We speculate that differing susceptibility to chemotherapy may correlate with *SUGT1* expression levels. Our data will be reported at the conclusion of clinical follow-up.

In conclusion, in a large scale study of Japanese CRC, array CGH analysis and cDNA microarray after LMD showed that the novel gene *SUGT1* can be useful for determining prognosis in CRC. Our results indicate that this method of analysis might uncover additional genes indicative of patient prognosis.

Acknowledgments

We thank Ms. T. Shimooka, Mrs. K. Ogata, Ms. M. Kasagi, Mrs. Y. Nakagawa, and Ms. T. Kawano for their excellent technical assistance. This work was supported in part by the following grants and foundations: Core Research for Evolutional Science and Technology, Grants-in-Aid for Scientific Research from the Ministry of Health, Labour and Welfare #17-15, and Grants-in-Aid for Scientific Research from the Ministry of Education, Culture, Sports, Science and Technology, # 20790960 and 19390336.

References

1. Jemal A, Siegel R, Ward E, Murray T, Xu J and Thun MJ: Cancer statistics, 2007. *CA Cancer J Clin* 57: 43-66, 2007.
2. Verdecchia A, Francisci S, Brenner H, *et al*: Recent cancer survival in Europe: a 2000-02 period analysis of Eurocare-4 data. *Lancet Oncol* 8: 784-796, 2007.
3. Diep CB, Kleivi K, Ribeiro FR, Teixeira MR, Lindgjaerde OC and Lothe RA: The order of genetic events associated with colorectal cancer progression inferred from meta-analysis of copy number changes. *Genes Chromosomes Cancer* 45: 31-41, 2006.
4. He QJ, Zeng WF, Sham JS, *et al*: Recurrent genetic alterations in 26 colorectal carcinomas and 21 adenomas from Chinese patients. *Cancer Genet Cytogenet* 144: 112-118, 2003.
5. Kim MY, Yim SH, Kwon MS, *et al*: Recurrent genomic alterations with impact on survival in colorectal cancer identified by genome-wide array comparative genomic hybridization. *Gastroenterology* 131: 1913-1924, 2006.
6. Lassmann S, Weis R, Makowicz F, *et al*: Array CGH identifies distinct DNA copy number profiles of oncogenes and tumor suppressor genes in chromosomal- and microsatellite-unstable sporadic colorectal carcinomas. *J Mol Med* 85: 293-304, 2007.
7. Rooney PH, Boonsong A, McKay JA, *et al*: Colorectal cancer genomics: evidence for multiple genotypes which influence survival. *Br J Cancer* 85: 1492-1498, 2001.
8. Tsafirir D, Bacolod M, Selvanayagam Z, *et al*: Relationship of gene expression and chromosomal abnormalities in colorectal cancer. *Cancer Res* 66: 2129-2137, 2006.
9. Kosaka Y, Mimori K, Tanaka F, Inoue H, Watanabe M and Mori M: Clinical significance of the loss of MATS1 mRNA expression in colorectal cancer. *Int J Oncol* 31: 333-338, 2007.
10. Ohmachi T, Tanaka F, Mimori K, Inoue H, Yanaga K and Mori M: Clinical significance of TROP2 expression in colorectal cancer. *Clin Cancer Res* 12: 3057-3063, 2006.
11. Yokoe T, Ohmachi T, Inoue H, *et al*: Clinical significance of growth differentiation factor 11 in colorectal cancer. *Int J Oncol* 31: 1097-1101, 2007.
12. Platzer P, Upender MB, Wilson K, *et al*: Silence of chromosomal amplifications in colon cancer. *Cancer Res* 62: 1134-1138, 2002.
13. Kitagawa K, Skowyra D, Elledge SJ, Harper JW and Hieter P: SGT1 encodes an essential component of the yeast kinetochore assembly pathway and a novel subunit of the SCF ubiquitin ligase complex. *Mol Cell* 4: 21-33, 1999.
14. Nishida K, Mine S, Utsunomiya T, *et al*: Global analysis of altered gene expressions during the process of esophageal squamous cell carcinogenesis in the rat: a study combined with a laser microdissection and a cDNA microarray. *Cancer Res* 65: 401-409, 2005.
15. Quackenbush J: Microarray data normalization and transformation. *Nat Genet* 32 (Suppl.): S496-S501, 2002.
16. Brazma A, Hingamp P, Quackenbush J, *et al*: Minimum information about a microarray experiment (MIAME)-toward standards for microarray data. *Nat Genet* 29: 365-371, 2001.
17. Venkatraman ES and Olshen AB: A faster circular binary segmentation algorithm for the analysis of array CGH data. *Bioinformatics* 23: 657-663, 2007.
18. Utsunomiya T, Hara Y, Kataoka A, *et al*: Cystatin-like metastasis-associated protein mRNA expression in human colorectal cancer is associated with both liver metastasis and patient survival. *Clin Cancer Res* 8: 2591-2594, 2002.
19. Utsunomiya T, Okamoto M, Hashimoto M, *et al*: A gene-expression signature can quantify the degree of hepatic fibrosis in the rat. *J Hepatol* 41: 399-406, 2004.
20. Ogawa K, Utsunomiya T, Mimori K, *et al*: Clinical significance of human kallikrein gene 6 messenger RNA expression in colorectal cancer. *Clin Cancer Res* 11: 2889-2893, 2005.
21. Niikura Y, Ohta S, Vandenbeldt KJ, Abdulle R, McEwen BF and Kitagawa K: 17-AAG, an Hsp90 inhibitor, causes kinetochore defects: a novel mechanism by which 17-AAG inhibits cell proliferation. *Oncogene* 25: 4133-4146, 2006.
22. Goetz MP, Toft D, Reid J, *et al*: Phase I trial of 17-allylaminogeldanamycin in patients with advanced cancer. *J Clin Oncol* 23: 1078-1087, 2005.

Minute liver metastases from a rectal carcinoid: A case report and review

Hirofumi Yamamoto, Hideyuki Hemmi, Jin-Yu Gu, Mitsugu Sekimoto, Yuichiro Doki, Masaki Mori

Hirofumi Yamamoto, Hideyuki Hemmi, Mitsugu Sekimoto, Yuichiro Doki, Masaki Mori, Department of Surgery, Gastroenterological Surgery, Graduate School of Medicine, Osaka University; Osaka 565-0871, Japan

Jin-Yu Gu, the 3rd Department of General Surgery, the 2nd Affiliated Hospital of Harbin Medical University, Baojian Road 246, Nangang District, Harbin 150086, Heilongjiang Province, China

Author contributions: All authors contributed to this work; Yamamoto H wrote the manuscript; Hemmi H examined the past references; Gu JY performed the English editing; Sekimoto M performed the operation surgery; Doki Y and Mori M designed the study and revised the manuscript.

Correspondence to: Hirofumi Yamamoto, MD, PhD, Department of Surgery, Gastroenterological Surgery, Graduate School of Medicine, Osaka University, 2-2 Yamada-oka, Suita City, Osaka, 565-0871, Japan. hyamamoto@gesurg.med.osaka-u.ac.jp
Telephone: +81-6-68793251 Fax: +81-6-68793259

Received: August 12, 2009 Revised: September 7, 2009

Accepted: September 14, 2009

Published online: March 27, 2010

Abstract

We here report a 43-year-old male patient with minute liver metastases from a rectal carcinoid. Hepatic nodules were diagnosed during surgery, although they were not diagnosed by preoperative computed tomography or ultrasound examination. The rectal carcinoid was resected together with liver metastases and the patient has had no disease recurrence for 5 years following postoperative treatment of hepatic arterial infusion chemotherapy (HAIC) using 5-fluorouracil (5-FU) and oral administration of 1-hexylcarbamoil-5-fluorouracil (HCFU). In 2003, a health check examination indicated presence of occult blood in his stool. Barium enema study revealed a rectal tumor in the lower rectum and colonoscopy showed a yellowish lesion with a size of 30 mm in diameter. Pathological examination of the biopsy specimen indicated that the rectal tumor was carcinoid. Although preoperative imaging examinations failed to detect liver metastases,

2 min nodules were found on the surface of liver during surgery. A rapid pathological examination revealed that they were metastatic tumors from the rectal carcinoid. Low anterior resection was performed for the rectal tumor and the pathological report indicated that there were 4 metastatic lymph nodes in the rectal mesentery. The patient received treatment by HAIC using 5-FU plus oral administration of HCFU and survived for 5 years. We also review world-wide current treatments and their efficacy for hepatic metastases of carcinoid tumors.

© 2010 Baishideng. All rights reserved.

Key words: Hepatic arterial infusion chemotherapy; Rectal carcinoid; Liver metastasis; 5-Fluorouracil

Peer reviewer: Francis Seow-Choen, MBBS, FRCS, FAMS, Seow-Choen Colorectal Centre Pte Ltd, 3 Mt Elizabeth #09-10, Mt Elizabeth Medical Centre, Singapore

Yamamoto H, Hemmi H, Gu JY, Sekimoto M, Doki Y, Mori M. Minute liver metastases from a rectal carcinoid: A case report and review. *World J Gastrointest Surg* 2010; 2(3): 89-94 Available from: URL: <http://www.wjgnet.com/1948-9366/full/v2/i3/89.htm> DOI: <http://dx.doi.org/10.4240/wjgs.v2.i3.89>

INTRODUCTION

It is reported that the incidence of liver metastasis from gastrointestinal carcinoids is 16.7% (155 of 928) and the mean life span is approximately 2 years once liver metastasis is diagnosed^[1-2]. With progress in treatments such as hepatic-artery embolization, radio-frequency thermal ablation, liver transplantation and others, the life span has been improved recently^[3]. We report here a case of rectal carcinoid in a 43-year-old male with minute liver metastases that were diagnosed during surgery although preoperative computed tomography (CT) and ultrasonography (US) examination did not detect them. We employed hepatic

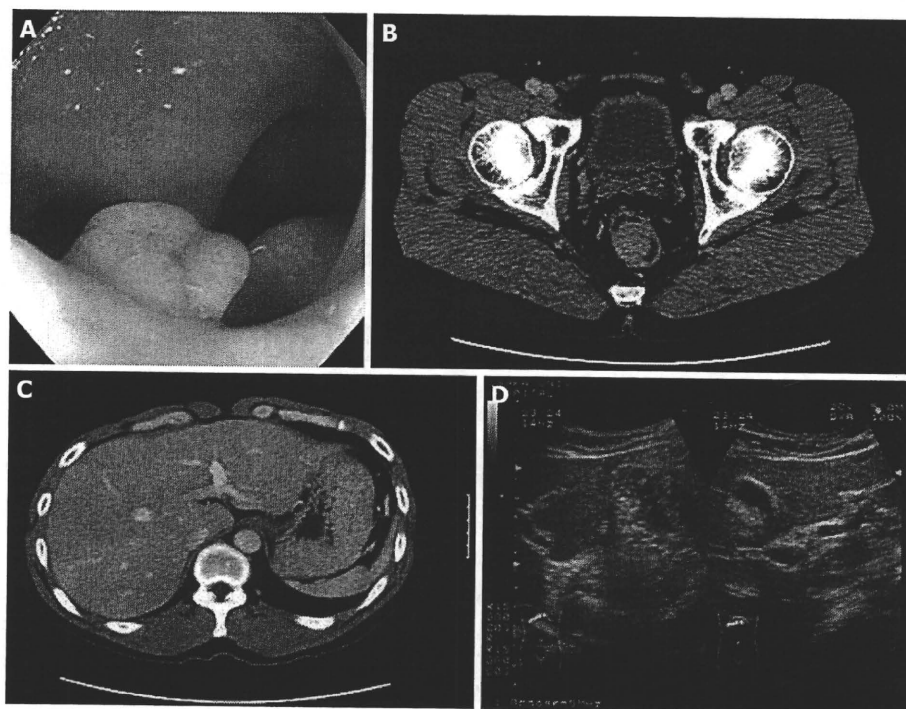


Figure 1 Preoperative colonoscopy and image examinations. A: Colonoscopy showed an elevated yellowish lesion with a slight central depression of which size was 30 mm in diameter, in the lower rectum; B: A tumor was present on the right wall of the lower rectum by computed tomography (CT) scan; C: Abdominal CT failed to show any obvious abnormalities in the liver; D: No obvious lesions were detected in the liver by ultrasonography.

Table 1 Blood test and urine 5-HIAA

WBC	6830/ μ L	AST	21 IU/L
RBC	506 $\times 10^4$ / μ L	ALT	21 IU/L
Hb	15.4 g/dL	T.Bil	0.4 mg/dL
Ht	44.4%	T.P.	6.7 g/dL
Plt	20.2 $\times 10^4$ / μ L	Alb	3.9 g/dL
		CRP	< 0.2 mg/dL
Na	140 mEq/L	CA19-9	< 5.0 U/mL
K	4.2 mEq/L	CEA	1.0 ng/mL
Cl	107 mEq/L		
BUN	14 mg/dL		
Cr	0.8 mg/dL	Urine 5-HIAA	1.3 mg/L

5-HIAA: 5-Hydroxy indole acetic acid.

arterial infusion chemotherapy (HAIC) using 5-fluorouracil (5-FU) and systemic administration of the oral 5-FU derivative 1-hexylcarbamoyl-5-fluorouracil (HCFU) as post-operative adjuvant therapy. The patient eventually survived 5 years after surgery without disease recurrence. Although the standard therapy for liver metastasis from carcinoid tumors has not been established in the world, several attractive strategies are currently provided, being reviewed together in this report.

CASE REPORT

A 43-year-old male patient entered our hospital in March 2003 because of a positive occult blood test on his stool samples. Through a barium enema study, a rectal tumor was suspected. He presented no carcinoid syndrome symptoms such as flushing, diarrhea, pellagra, cyanosis, and others. The results of blood test and level of 5-hydroxy indole acetic acid in the urine was within the normal range (Table 1).

Colonoscopy

Colonoscopy showed an elevated yellowish lesion in the lower rectum of 30 mm in diameter and with a slight central depression (Figure 1A). Pathological examination of biopsy samples revealed that this was a carcinoid tumor (data not shown).

Image examinations

CT scanning showed a tumor on the right wall of the lower rectum (Figure 1B). Abdominal CT failed to show any obvious abnormalities in the liver (Figure 1C). No obvious lesions were detected in the liver by abdominal US (Figure 1D).

Operation

During surgery, we perceived 2 min nodules through hand palpation of the surface of left liver lobe (S2 and S3). The nodules were hard and white and were both 2 mm in diameter. A rapid pathological examination revealed that the tumors were metastatic carcinoid (Figure 2A and 2B). Other hepatic abnormalities were not detected by intra-operative US. Low anterior resection of the rectum and partial resection of the liver (S2 and S3) were performed. The metastatic tumors were very small, indicating early phase metastases, and it was therefore likely that other latent metastases might be present in the liver. During surgery, we made preparation to carry out HAIC as a post-operative adjuvant chemotherapy, i.e. ligation of the right gastric artery and cholecystectomy to prevent the side effects such as gastric ulcer and cholecystitis, associated with HAIC.

Histopathological examination

Following staining of the primary rectal tumor with

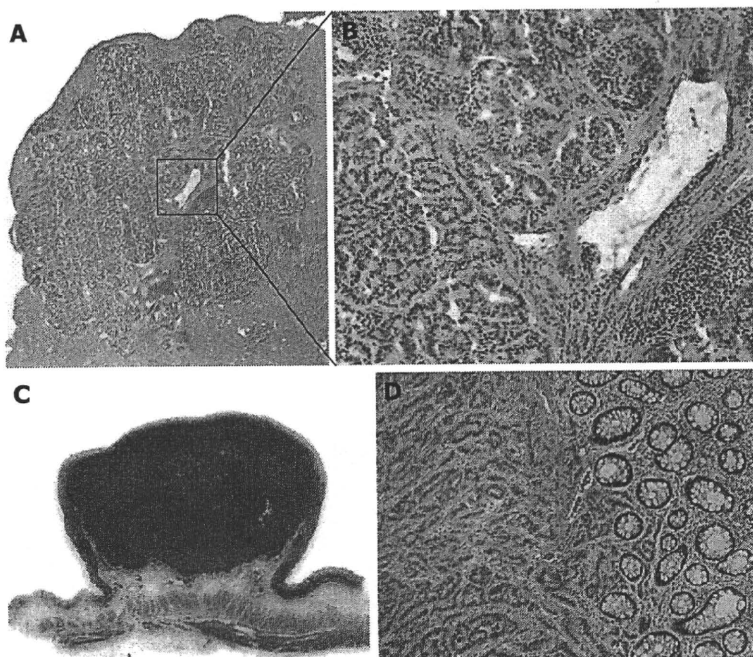


Figure 2 Histopathology of liver metastasis and primary tumor. A: Histopathology of a hepatic nodule (Magnification: $\times 20$). A section was stained by hematoxyline & eosin (H&E) solution; B: Magnified image of (A) (Magnification: $\times 100$): The tumor cells were homogeneous and spherical, forming ribbon-like structures, which was compatible with the carcinoid tumor; C: Resected rectal tumor. A loupe image; D: Histopathology of the rectal tumor (Magnification: $\times 100$): Identical histopathological features to that of liver metastasis were confirmed.

Table 2 Hepatic resection for gastrointestinal carcinoid tumors

Author	n	5-year survival rate (%)	Ref.
Chamberlain <i>et al</i> (2000)	14	78	[14]
Nave <i>et al</i> (2001)	21	48	[15]
Norton <i>et al</i> (2003)	13	77	[16]
Sarmiento <i>et al</i> (2003)	120	62	[17]

Table 3 Liver transplantation for gastrointestinal carcinoid tumors

Author	n	5-year survival rate (%)	Ref.
Le Treut <i>et al</i> (1997)	15	69	[18]
Lehnert (1998)	36	50	[19]
Coppa <i>et al</i> (2001)	9	70	[20]

hematoxyline and eosin, histopathological examination showed homogeneous spherical cells, forming ribbon-like structures, compatible with the carcinoid tumor (Figure 2C and D). The tumor penetrated into the muscular propria without evidence of venous invasion or lymph duct invasion. There were 4 lymph node metastases within the rectal mesentery.

Post-operative adjuvant therapy

On the 35th day after surgery, a catheter was inserted from the left subclavian artery and the tip was set along common hepatic artery by the radiologists. HAIC using 5-FU started via the subcutaneous port. A dose of 1250 mg 5-FU was administered every week, and a total of 21 HAICs were performed. In addition, oral 5-FU, HCFU (Carmofur: 300 mg/d) was administered for one and half years as the lymph node metastases were positive. The patient was alive after 5 years without disease recurrence.

Table 4 Hepatic artery chemoembolization and hepatic artery embolization for metastatic carcinoid tumors

Author	%	Chemotherapy	Ref.
HACE			
Hajarizadeh <i>et al</i> (1992)	50.0 (4/8)	5-FU	[23]
Ruszniewski <i>et al</i> (1993)	33.3 (6/18)	DOX	[24]
Therasse <i>et al</i> (1993)	35.2 (6/17)	DOX	[25]
Kim <i>et al</i> (1999)	25.0 (4/16)	CDDP, DOX	[26]
Roche <i>et al</i> (2003)	42.8 (6/14)	DOX	[27]
Total	35.6 (26/73)		
HAE			
Carrasco <i>et al</i> (1983)	83.3 (5/6)		[28]
Hanssen <i>et al</i> (1989)	71.4 (5/7)		[29]
Moertel <i>et al</i> (1994)	69.6 (16/23)		[30]
Wangberg <i>et al</i> (1996)	42.5 (17/40)		[31]
Eriksson <i>et al</i> (1998)	37.9 (11/29)		[32]
Loewe <i>et al</i> (2003)	72.7 (16/22)		[33]
Total	55.1 (70/127)		

HACE: Hepatic arterial chemoembolization; HAE: Hepatic arterial embolization, CR: Complete response; PR: Partial response; CDDP: cisplatin; DOX: Doxorubicin; HAIC: Hepatic arterial infusion chemotherapy.

DISCUSSION

The 5-year survival rate of colorectal carcinoid is 72%-98%. However, once distant metastasis occurs the prognosis becomes poor^[3-6]. In cases with liver metastasis, the 5-year survival rate is reported to be 19%-38%^[7]. In Japan, most colorectal carcinoids are located in the rectum, mainly within 10 cm from the dentate line (80% of rectal carcinoids)^[8]. Carcinoid tumors originate from the endocrine cells that produce certain amines and peptides. These cells are originally located in the deep mucosa. Once neoplastic changes occur, the tumor looks like a submucosal one following expansive growth.

Table 5 Reports of HAIC for hepatic metastasis of carcinoid tumor in Japan (1993–2006)

Age (yr)/ Gender	5FU	MMC	ADM	Agents CDDP	MTX	VP16	FAR	Combined therapy	Effects	Ref.
69/M	o	o					o	-	PR	[35]
70/F	o			o				-	IR	[36]
42/M	o		o					-	PR	[37]
65/F	o				o			-	PR	[38]
56/M		o						5-FU	CR	[39]
52/M	o			o				DSM	PR	[40]
42/F	o							MTX + 5-FU	CR	[41]
3 cases	o	o						DSM	PR	[42]
68/M						o		-	PR	[43]
57/M	o	o		o				DSM	PR	[44]
49/F	o							-	CR	[45]

5-FU: 5-Fluorouracil; MMC: Mitomycin; ADM: Adriamycin; CDDP: Cisplatin; MTX: Methotrexate; VP16: Etoposide; FAR: Farnarubicin; DSM: Degradable starch microspheres; CR: Complete response; PR: Partial response; IR: Incomplete response.

With deeper invasion, the metastatic rate becomes correspondingly higher. The most frequent metastatic sites are lymph nodes and liver, followed by bone and lung. It is reported that the frequency of lymph node metastasis was 0% when the tumor is localized in mucosa, 5.3% in T1, 53% in T2 and 85.7% in T3^[9]. Saito *et al.*^[10] also reported a relationship between tumor size and incidence of lymph node metastasis. When the tumor diameter is 6 to 10 mm, the metastasis rate is 0.7%, 11–15 mm: 23%, 16–20 mm: 55.6%, and > 21 mm: 66.7%.

There is a report that even 5mm-sized primary carcinoid tumor cause liver metastasis suggesting that a detailed examination of liver is essential before surgery^[11]. US and CT scans are both standard modalities for detection of liver metastasis. Chiti *et al.*^[12] reported that the diagnostic sensitivity and specificity was 82% and 92%, respectively for US, and 73% and 93% for CT scans. In the case of the current patient with 2mm-sized liver metastatic lesions, preoperative abdominal US and CT failed to detect them, although such minute nodules could be easily perceived by hand palpation owing to their solidity. Therefore, intra-operative palpation of the liver surface is particularly important and should be done very carefully.

If the liver metastases are completely resected, surgery is the most effective therapy. The surgical indications include uni-lobar hepatic metastases, and multiple tumors expanding to both hepatic lobes with assurance of complete respectability based on good liver function. However, as approximately 90% of hepatic metastases are found to be multiple lesions in both hepatic lobes, complete resection is a rare event in practice^[13]. The efficacy of hepatic resection for the gastrointestinal carcinoid tumors is summarized in Table 2^[14–17].

Liver transplantation is an alternative treatment and widely adopted in patients with liver metastases from carcinoid tumors. The 5-year overall survival rate ranges from 50%–70% (Table 3)^[18–20]. Lehnert^[19] reported that the 5-year survival rate was 50% in 36 patients undergoing liver transplantation. He pointed out that the patients with extra-hepatic disease worsened the whole prognosis. Coppa *et al.*^[20] proposed that selection of patients with

non-resectable metastatic neuroendocrine tumors for liver transplantation should be performed based on the Milan criteria: young patients < 50 years with confirmed by histology, with < 50% of the liver replaced by metastases, with a primary tumor (originating from the gastrointestinal tract) drained by the portal venous system, an absence of extrahepatic disease and stable disease during the pretransplantation period. They reported that the selected 9 cases who satisfied the criteria had a 70% 5-year overall survival rate and a 53% 5-year disease free survival rate.

Treatments by somatostatin analogues, such as interferon and octreotide have been reported. According to the findings, tumor shrinkage was a rare event although the systemic symptoms due to the carcinoid tumor were lessened^[21–22].

Since liver metastases from carcinoids display an abundant tumor vascularity, hepatic arterial chemoembolization (HACE) or hepatic arterial embolization (HAE) are employed in western countries. The efficacy of HACE, in which doxorubicin is often used as a principal drug, is 25%–50% (Table 4, upper column)^[23–27]. Partial response or complete response cases were reported with HACE treatment. On the other hand, HAE was able to achieve the higher efficacy of 70%–80%, and appears to confer better therapeutic effects than HACE as a whole (Table 4, the lower column)^[28–33].

In Japan, HAIC is often used^[34]. As shown in Table 5^[35–45], continuous 5-FU infusion accompanied by other chemotherapeutic drugs is the basic treatment scheme and conferred favorable effects. Based on these reports, we employed HAIC using 5-FU infusion for the current case. Recently, degradable starch microspheres (DSM) have also been used in combination with HAIC^[40,42,44]. The anti-tumor efficacy when using DSM is attributed to transient obstruction of hepatic artery and subsequent blood reperfusion, which causes high local concentration of chemo-agents during the early phase and induces free radical oxygen as a late effect^[46].

As well for primary hepatocellular carcinoma, radio-frequency ablation (RFA) therapy is also applicable to

liver metastatic lesions from carcinoid tumors. The most appropriate application is in cases where tumor size is less than 3 cm in diameter. Hellman *et al.*⁴⁷ reported that RFA treatment was performed in a group of 21 patients with a total of 43 carcinoid metastatic liver nodules. Therapeutic efficacy was observed in 15 patients, including 4 cases who attained complete ablation.

REFERENCES

- Soga J. Carcinoid tumors-an analysis of 1342 cases. *Geka* 1989; 12: 1397-1409
- Soga J, T Suzuki. Carcinoids and the carcinoid syndrome. *Nipponmishou* 1993; 51: 207-221
- Modlin IM, Sandor A. An analysis of 8305 cases of carcinoid tumors. *Cancer* 1997; 79: 813-829
- Thompson GB, van Heerden JA, Martin JK Jr, Schutt AJ, Ilstrup DM, Carney JA. Carcinoid tumors of the gastrointestinal tract: presentation, management, and prognosis. *Surgery* 1985; 98: 1054-1063
- Modlin IM, Lye KD, Kidd M. A 5-decade analysis of 13,715 carcinoid tumors. *Cancer* 2003; 97: 934-959
- Crocetti E, Paci E. Malignant carcinoids in the USA, SEER 1992-1999. An epidemiological study with 6830 cases. *Eur J Cancer Prev* 2003; 12: 191-194
- Dawes L, Schulte WJ, Condon RE. Carcinoid tumors. *Arch Surg* 1984; 119: 375-378
- Iwashita A, Hasegawa S, Haraoka S. Carcinoid tumors of the colon and rectum-including a standard for evaluating of curability of endoscopic resection. *Early Colorectal Cancer* 2002; 6: 249-258
- Kotake K, Yoneyama K, Miyata J. Carcinoid tumors of the rectum-Report of five cases a review of Japanese literature. *Daichoukoumongeka Gakkai Zasshi* 1984; 37:261-266
- Saito Y, Iwashita A, Iida M. A questionnaire survey concerning colorectal carcinoid tumors-Therapeutic strategy for colorectal carcinoid tumors. *Stomach and Intestine* 2005; 40: 200-213
- Tsuboi K, Shimura T, Suzuki H, Mochiki E, Haga N, Masuda N, Soda M, Yamamoto H, Asao T, Kuwano H. Liver metastasizes of a minute rectal carcinoid less than 5mm in diameter: A case report. *Hepatogastroenterology* 2004; 51: 1330-1332
- Chiti A, Fanti S, Savelli G, Romeo A, Bellanova B, Rodari M, van Graafeiland BJ, Monetti N, Bombardieri E. Comparison of somatostatin receptor imaging, computed tomography and ultrasound in the clinical management of neuroendocrine gastro-entero-pancreatic tumours. *Eur J Nucl Med* 1998; 25: 1396-1403
- Ihse I, Persson B, Tibblin S. Neuroendocrine metastases of the liver. *World J Surg* 1995; 19: 76-82
- Chamberlain RS, Canes D, Brown KT, Saltz L, Jarnagin W, Fong Y, Blumgart LH. Hepatic neuroendocrine metastases: does intervention alter outcomes? *J Am Coll Surg* 2000; 190: 432-445
- Nave H, Mössinger E, Feist H, Lang H, Raab H. Surgery as primary treatment in patients with liver metastases from carcinoid tumors: a retrospective, unicentric study over 13 years. *Surgery* 2001; 129: 170-175
- Norton JA, Warren RS, Kelly MG, Zuraek MB, Jensen RT. Aggressive surgery for metastatic liver neuroendocrine tumors. *Surgery* 2003; 134: 1057-1063; discussion 1063-1065
- Sarmiento JM, Heywood G, Rubin J, Ilstrup DM, Nagorney DM, Que FG. Surgical treatment of neuroendocrine metastases to the liver: a plea for resection to increase survival. *J Am Coll Surg* 2003; 197: 29-37
- Le Treut YP, Delpero JR, Dousset B, Cherqui D, Segol P, Manton G, Hannoun L, Benhamou G, Launois B, Boillot O, Domergue J, Bismuth H. Results of liver transplantation in the treatment of metastatic neuroendocrine tumors. A 31-case French multicentric report. *Ann Surg* 1997; 225: 355-364
- Lehnert T. Liver transplantation for metastatic neuroendocrine carcinoma: an analysis of 103 patients. *Transplantation* 1998; 66: 1307-1312
- Coppa J, Pulvirenti A, Schiavo M, Romito R, Collini P, Di Bartolomeo M, Fabbri A, Regalia E, Mazzaferro V. Resection versus transplantation for liver metastases from neuroendocrine tumors. *Transpl Proc* 2001; 33: 1537-1539
- di Bartolomeo M, Bajetta E, Buzzoni R, Mariani L, Carnaghi C, Somma L, Zilembo N, di Leo A. Clinical efficacy of octreotide in the treatment of metastatic neuroendocrine tumors. A study by the Italian Trials in Medical Oncology Group. *Cancer* 1996; 77: 402-408
- Bajetta E, Zilembo N, Di Bartolomeo M, Di Leo A, Pilotti S, Bochicchio AM, Castellani R, Buzzoni R, Celio L, Dogliotti L. Treatment of metastatic carcinoids and other neuroendocrine tumors with recombinant interferon-alpha-2a. A study by the Italian Trials in Medical Oncology Group. *Cancer* 1993; 72: 3099-3105
- Hajarizadeh H, Ivancev K, Mueller CR, Fletcher WS, Woltering EA. Effective palliative treatment of metastatic carcinoid tumors with intra-arterial chemotherapy/chemoembolization combined with octreotide acetate. *Am J Surg* 1992; 163: 479-483
- Ruszniewski P, Rougier P, Roche A, Legmann P, Sibert A, Hochlaf S, Ychou M, Mignon M. Hepatic arterial chemoembolization in patients with liver metastases of endocrine tumors. A prospective phase II study in 24 patients. *Cancer* 1993; 71: 2624-2630
- Therasse E, Breitmayer F, Roche A, De Baere T, Indushekar S, Ducreux M, Lasser P, Elias D, Rougier P. Transcatheter chemoembolization of progressive carcinoid liver metastasis. *Radiology* 1993; 189: 541-547
- Kim YH, Ajani JA, Carrasco CH, Dumas P, Richli W, Lawrence D, Chuang V, Wallace S. Selective hepatic arterial chemoembolization for liver metastases in patients with carcinoid tumor or islet cell carcinoma. *Cancer Invest* 1999; 17: 474-478
- Roche A, Girish BV, de Baere T, Baudin E, Boige V, Elias D, Lasser P, Schlumberger M, Ducreux M. Trans-catheter arterial chemoembolization as first-line treatment for hepatic metastases from endocrine tumors. *Eur Radiol* 2003; 13: 136-140
- Carrasco CH, Chuang VP, Wallace S. Apudomas metastatic to the liver: treatment by hepatic artery embolization. *Radiology* 1983; 149: 79-83
- Hanssen LE, Schrupf E, Kolbenstvedt AN, Tausjø J, Dolva LO. Recombinant alpha-2 interferon with or without hepatic artery embolization in the treatment of midgut carcinoid tumours. A preliminary report. *Acta Oncol* 1989; 28: 439-443
- Moertel CG, Johnson CM, McKusick MA, Martin JK Jr, Nagorney DM, Kvols LK, Rubin J, Kunselman S. The management of patients with advanced carcinoid tumors and islet cell carcinomas. *Ann Intern Med* 1994; 120: 302-309
- Wängberg B, Westberg G, Tylén U, Tisell L, Jansson S, Nilsson O, Johansson V, Scherstén T, Ahlman H. Survival of patients with disseminated midgut carcinoid tumors after aggressive tumor reduction. *World J Surg* 1996; 20: 892-899; discussion 899
- Eriksson BK, Larsson EG, Skogseid BM, Löfberg AM, Lörelus LE, Oberg KE. Liver embolizations of patients with malignant neuroendocrine gastrointestinal tumors. *Cancer* 1998; 83: 2293-2301
- Loewe C, Schindl M, Cejna M, Niederle B, Lammer J, Thurnher S. Permanent transarterial embolization of neuroendocrine metastases of the liver using cyanoacrylate and lipiodol: assessment of mid- and long-term results. *AJR Am J Roentgenol*. 2003; 180: 1379-1384
- Hoshino H, Ichikawa M, Onizuka A. A case of rectal carcinoid with multiple hepatic metastases. *Daichoukoumongeka Gakkai Zasshi* 1991; 44: 73-80
- Asai A, Ando M, Kushida T. A case of metastatic liver tumors of the rectal carcinoid treated with hepatic artery ligation and catheterization. *Rinshoeka Gakkai Zasshi* 1993; 54: 1862-1866

- 36 Kirisu Y, Kurayoshi K, Hoshino K. A case of carcinoid tumor of the rectum metastasizing to the liver and pancreas: *Shoikakigeka Gakkai Zasshi* 1994; 27: 1127-1131
- 37 Hisamitsu K, Makino M, Kimura O. A case of carcinoid of rectum in which intrahepatic chemotherapy was effective for multiple liver metastases. *Rinshoheka Gakkai Zasshi* 1996; 57: 918-921
- 38 Takeuchi I, Ishida H, Suzuki T. A case of liver metastases of rectal carcinoid successfully treated with hepatic arterial infusion of methotrexate and 5-fluorouracil. *Jpn J Cancer Chemother* 1999; 26: 1929-1932
- 39 Nakagawa K, Abe H, Momono S. A case of cecal carcinoid in which intrahepatic chemotherapy was effective for multiple liver metastases. *Daichoukoumongeka Gakkai Zasshi* 1999; 52: 342-346
- 40 Doi T, Homma H, Mezawa S. A case of multiple liver metastases from rectal carcinoid tumor successfully treated with arterial infusion chemotherapy using degradable starch microspheres (DSM). *Shokakibyō Gakkai Zasshi* 2001; 98: 410-415
- 41 Sumi K, Ataka M, Oka A. A case of rectal carcinoid tumor with hepatic and peritoneal metastases in which systemic CDDP+5FU and intrahepatic arterial infusion therapy with 5FU was successful. *Rinshoheka Gakkai Zasshi* 2001; 62: 2489-2493
- 42 Takanashi K, Homma H, Mezawa S, Doi T, Akiyama T, Machida T, Murakami K, Hirata K, Iyama S. [Three cases of multiple liver metastases of carcinoid tumor responding to hepatic arterial infusion chemotherapy using degradable starch microspheres] *Gan To Kagaku Ryōho* 2002; 29: 2358-2361
- 43 Murase K, Shimamoto T, Kondo T, Sugimoto T, Ozeki Y. [A long-term survival case of hepatic metastasis of rectal carcinoid in which etoposide was effective] *Nippon Shokakibyō Gakkai Zasshi* 2004; 101: 47-51
- 44 Shibutani Y, Tani S, Uchikaga O. A case of multiple liver metastasis of rectal carcinoid tumor which occurred 10 years after, responding to hepatic arterial infusion chemotherapy using Degradable Starch Microspheres. *Kounanbyōin Igaku Zasshi* 2005; 22: 1-4
- 45 Nishimura A, Hashizume T, Shibasaki I. Rectal carcinoid tumor with multiple liver metastases in which multidisciplinary therapy was successful-A case report-. *Rinshoheka Gakkai Zasshi* 2006; 67: 679-682
- 46 Yoshikawa T, Kokura S, Oyamada H, Iinuma S, Nishimura S, Kaneko T, Naito Y, Kondo M. Anti tumor effect of ischemia-reperfusion injury induced by transient embolization. *Cancer Res* 1994; 54: 5033-5035
- 47 Hellman P, Ladjevardi S, Skogseid B, Akerström G, Elvin A. Radiofrequency tissue ablation using cooled tip for liver metastases of endocrine tumors. *World J Surg* 2002; 26: 1052-1056

S- Editor Li LF L- Editor Hughes D E- Editor Yang C