

# Endoscopic Submucosal Dissection for Gastric Cancer

Mitsuhiro Fujishiro, MD, PhD

## Corresponding author

Mitsuhiro Fujishiro, MD, PhD  
Department of Gastroenterology, Graduate School of Medicine,  
University of Tokyo, 7-3-1, Hongo, Bunkyo-ku, Tokyo, 113-8655, Japan.  
E-mail: mtfujish-kkr@umin.ac.jp

**Current Treatment Options in Gastroenterology** 2008, 11:119-124

Current Medicine Group LLC ISSN 1092-8472

Copyright © 2008 by Current Medicine Group LLC

## Opinion statement

Endoscopic submucosal dissection (ESD) is a novel endoscopic treatment that enables a clinician to resect an early-stage gastric cancer in en bloc fashion. ESD is indicated for those cancers in which there is a high probability of en bloc resection and low probability of lymph node metastasis. The latter may be the limiting factor at institutions skilled at ESD. Several ESD techniques are available with similar outcomes. Thus, selection depends on operator preference and expertise. Gastrectomy with lymphadenectomy should be applied initially to those early gastric cancers with high probability of positive lymph nodes or as an additional treatment after ESD. Endoscopic mucosal resection (EMR) should be reserved for small, nonulcerated, intramucosal, differentiated cancers. Disadvantages of ESD in comparison with EMR are longer operation times and higher incidences of intraoperative bleeding and perforation, but the indication for ESD includes larger and ulcerative lesions not amenable to EMR.

## Introduction

Endoscopic resection is possible for localized gastric epithelial neoplasms without lymph node metastases. Because it may not be able to discern the latter preoperatively, the neoplasm should be resected en bloc to best evaluate the risk. Until recently, resection by endoscopic mucosal resection (EMR) was limited to small lesions (ie, < 2 cm) [1,2]. Endoscopic submucosal dissection (ESD) is a new technique that uses a cutting device to permit a larger resection and resection of ulcerative neoplasms. First, fluid is injected into the submucosa to elevate the lesion from the muscle layer. Next, the mucosa surrounding the lesion is precut. Finally, the connective tissue of the submucosa beneath the lesion is dissected.

## INDICATIONS FOR ESD

Based upon large numbers of surgically treated cases with and without lymph node metastasis, the following types of early gastric cancers may benefit from ESD: 1) intramucosal, differentiated adenocarcinoma with presence of ulcer when the lesion is less than or equal to 3 cm; 2) intramucosal, differentiated adenocarcinoma without ulceration of any size; 3) intramucosal, undifferentiated adenocarcinoma without ulceration when

the lesion is less than or equal to 2 cm; and 4) differentiated adenocarcinoma with minute submucosal penetration ( $\leq 500 \mu\text{m}$ ) when the lesion is less than or equal to 3 cm [3]. Also, the endoscopist's technical skill must be taken into consideration. For cases in which endoscopic ultrasonography reveals fusion of the muscle layer and the mucosal layer, which may occur in cancers that previously had a deep ulcer extending into the proper muscle layer, it is difficult to identify the gastric wall plane during submucosal dissection. Thus, in our opinion, these patients should not undergo ESD. Also, most Japanese investigators would not endoscopically resect an undifferentiated adenocarcinoma, as these lesions' margins are often indistinct, and even the small, undifferentiated carcinoma with ulcer finding has potential to spread to the regional lymph nodes.

## VARIOUS TECHNIQUES OF ESD

ESD requires special cutting knives, such as the needle knife [4], the insulation-tipped electrosurgical (IT) knife [5], the hook knife [6], the flex knife [7,8], and the triangle-tip (TT) knife [9]. It also requires submucosal injection to elevate the mucosa and separate it from the

**Table 1. Recent outcomes for endoscopic submucosal dissection of early gastric cancer**

Technique	En bloc resection rate	Local recurrence rate	Complication rate	
			Bleeding	Perforation
IT knife	93% (957/1033)	NA	6% (59/945)	4% (35/945)
Tip of thin snare/flex knife	95% (56/59)	NA	1.7% (1/59)	3.4% (2/59)
Sodium hyaluronate and small-caliber tip transparent hood	99% (69/70)	NA	1% (1/70)	0% (0/70)
Hook knife	95% (194/204)	0.5% (1/204)	NA	1.5% (3/204)
Hypertonic saline-epinephrine solution	79% (36/46)	0% (0/46)	4% (2/46)	8% (4/46)
Mixture of hyaluronic acid, glycerin, and sugar	100% (26/26)	0% (0/26)	3.8% (1/26)	0% (0/26)
TT knife	88% (14/16)	NA	NA	0% (0/16)
IT knife in the West	25% (6/24)	NA	12.5% (3/24)	0% (0/24)

IT—insulation-tipped electrosurgical; NA—not analyzed; TT—triangle-tip.

muscular layer. Although no one technique or injection solution has been shown to be superior to the others, hyaluronic acid alone or in combination with glycerin and sugar appears to make a longer-lasting cushion with less tissue damage [10–12,13•,14••] (Table 1). The less

favorable results achieved in Western case series compared with Japanese case series may be due to different biological activities of early gastric cancers, less experience with the techniques, and insufficient information about the techniques in detail.

## Treatment

### Concomitant pharmacologic treatment

#### Antibiotics

- No evidence exists for the use of prophylactic antibiotics before, during, or after ESD.
- In case of perforation, standard doses of second-generation cephalosporins and fasting for 2 days may be sufficient if the perforation is closed immediately and completely with endoclips [15•].
- Although rare, aspiration pneumonia should be treated with broad-spectrum cephalosporin and clindamycin according to the pneumonia's severity and the antibiotic sensitivity of the organisms in the hospital.

#### Acid suppressant

- ESD-induced ulceration heals in most cases after 8 weeks of empiric proton pump inhibitor administration [16].
- A proton pump inhibitor prevents delayed bleeding more effectively than a histamine 2-receptor antagonist [17•].

### Concomitant surgery

- Emergency surgery is rarely required to treat complications of ESD.
- Additional gastrectomy with lymphadenectomy is strongly recommended when histologic assessment reveals a high probability for lymph node metastasis as discussed previously.
- Histologic incomplete resection due to tumor extension into the lateral margin, or nonevaluable resection margin due to the effects of coagulation necrosis or multiple-piece resection does not always require additional surgery. These patients may be closely observed with endoscopy and biopsy, particularly if burn effect exists at the margin.

### Selection of various ESD techniques

- Several ESD techniques are named by the electrosurgical knives applied or injection solution used. The results obtained by each technique are similar, as shown in Table 1. Selection depends mainly on each operator's preference and expertise.
- The needle knife enables a sharp cut. When applied vertically from the wall plane, the knife can easily pass through the stomach wall, resulting in perforation. To mitigate perforation, it is advisable to use a transparent endoscopic hood and to use hyaluronic acid as the injection solution [18,19].
- The IT knife has a ceramic ball at the top of a needle knife. The ceramic ball is placed within the submucosal layer so as to hook the mucosa or the submucosal connective tissue. Then the knife is pulled to cut the tissue at the needle blade [20•].
- The hook knife has a bending part at a right angle on the top of a needle knife. The tip of the bending is placed within the submucosal layer so as to hook the mucosa or the submucosal connective tissue that is to be cut. Then the knife is pulled into the direction of the lumen or scope [21•].
- The TT knife has a triangular-shaped metal plate attached to the tip of a needle knife. It is used in a way similar to the hook knife. The triangular shape obviates the need to rotate the tip to hook the tissue that is to be cut [9].
- The flex knife has a soft, thick, and looped tip. The knife's softness may prevent perforation, even when it is used vertical to the wall plane [8•].
- Although no study has compared the relative efficacy and safety of the various knives used for ESD, we prefer to start with a flex knife. An IT knife may be selected in cases of coexisting fibrosis because it is difficult to recognize the wall plane within the fibrotic tissue under direct visualization but easy to recognize it from the plane of the exposed proper muscle layer [22]. We prefer a mixture of high-molecular weight hyaluronic acid, glycerin, and sugar as the submucosal injection solution [13•].

### Chemotherapy

- There is no evidence that chemotherapy is an efficient treatment for early gastric cancer.
- There is no evidence that chemotherapeutic agents used in the neoadjuvant or adjuvant setting lead to better survival than surgery or endoscopic treatment alone for early gastric cancer.

### Surgery

#### Laparoscopic surgery

- Laparoscopic wedge resection, laparoscopic intragastric mucosal resection, and laparoscopic gastrectomy may be used to treat early gastric cancer [23].
- The first two techniques can be applied to treat node-negative cancers.
- Laparoscopic gastrectomy enables partial or total stomach resection and resection of perigastric lymph nodes. It can be used to treat all early gastric cancers, with or without lymph node metastases.
- Using laparoscopic surgery to cure early gastric cancer remains controversial. For node-negative cancers, ESD may be preferred. For the rest of early gastric cancers, laparoscopic surgery may be minimally beneficial over open surgery in terms of short-term outcomes and cosmesis [23].

## Open surgery

- Open surgery is the gold standard for treating early gastric cancers not amenable to endoscopic resection.
- Most surgeons in Japan consider extended lymphadenectomy (D2 dissection) essential to remove possible lymph node metastases. However, several prospective studies conducted outside Japan have not reported any therapeutic benefit from a D2 over a D1 dissection [24].
- Less invasive surgical strategies, which consist of a reduced scope of lymphadenectomy and a reduced resection of the stomach, such as modified D1 dissection, modified D2 dissection, local resection with adjacent lymphadenectomy, pylorus-preserving gastrectomy, segmental gastrectomy, and proximal gastrectomy, are also treatment options for early gastric cancer [24].

## Other endoscopic modalities

### Tissue obliteration technique

- Laser vaporization [25,26], photodynamic therapy [27], microwave coagulation [28], argon plasma coagulation [29,30], and injection of anticancer agents [31] or ethanol [32] have been used.
- Tissue obliteration techniques should be applied only as palliative treatment in patients who cannot undergo endoscopic resection or surgery, because histology of the entire lesion, which is essential to judge curability, cannot be obtained.

### Polypectomy

- Polypectomy is applied to the resection of protruding intramucosal cancers with a narrow base or stalk. The technique is the easiest to perform, but only a few cancers are amenable.
- Because the resected margin is burned with thermocoagulation, protruding cancers suspicious for submucosal invasion should be resected by EMR or other appropriate resection techniques.

### EMR

- EMR can be accomplished by the inject, lift, and cut technique (eg, strip biopsy [1]) or by the inject, suck, and cut technique (eg, EMR with cap [2]).
- Indications for EMR include differentiated mucosal adenocarcinoma with elevation and size less than 2 cm and flat or depressed differentiated mucosal adenocarcinoma without ulcer and size less than 1 cm [33••].
- The inject, suck, and cut technique may obtain a large section more easily than the inject, lift, and cut technique [34].
- Retrospective analyses of the comparison between ESD and EMR showed that ESD increased en bloc and histologically complete resection rates compared with EMR but was associated with longer average operation times and a higher incidence of intraoperative bleeding and perforation [35,36•].

## Disclosure

---

No potential conflict of interest relevant to this article was reported.

## References and Recommended Reading

Papers of particular interest, published recently, have been highlighted as:

- Of importance
- Of major importance

1. Tada M, Murakami A, Karita M, et al.: Endoscopic resection of early gastric cancer. *Endoscopy* 1993, 25:445–450.
2. Inoue H, Takeshita K, Hori H, et al.: Endoscopic mucosal resection with a cap-fitted panendoscope for esophagus, stomach, and colon mucosal lesions. *Gastrointest Endosc* 1993, 39:58–62.
3. Gotoda T, Yanagisawa A, Sasako M, et al.: Incidence of lymph node metastasis from early gastric cancer: estimation with a large number of cases at two large centers. *Gastric Cancer* 2000, 3:219–225.
4. Hirao M, Masuda K, Asanuma T, et al.: Endoscopic resection of early gastric cancer and other tumors with local injection of hypertonic saline-epinephrine. *Gastrointest Endosc* 1988, 34:264–269.
5. Ono H, Kondo H, Gotoda T, et al.: Endoscopic mucosal resection for treatment of early gastric cancer. *Gut* 2001, 48:225–229.
6. Oyama T, Kikuchi Y: Aggressive endoscopic mucosal resection in the upper GI tract-hook knife EMR method. *Minim Invasive Ther Allied Technol* 2002, 11:291–295.
7. Yahagi N, Fujishiro M, Kakushima N, et al.: Endoscopic submucosal dissection for early gastric cancer using the tip of an electro-surgical snare (thin type). *Dig Endosc* 2004, 16:34–38.
8. Kodashima S, Fujishiro M, Yahagi N, et al.: Endoscopic submucosal dissection for gastric neoplasia: experience with the flex-knife. *Acta Gastroenterol Belg* 2006, 69:224–229.  
Describes the ESD technique using a flex knife and comparing it with other electrosurgical knives.
9. Inoue H, Sato Y, Kazawa T, et al.: Endoscopic submucosal dissection-using a triangle-tipped knife [in Japanese]. *Stomach Intestine* 2004, 39:53–56.
10. Yamamoto H, Yube T, Isoda N, et al.: A novel method of endoscopic mucosal resection using sodium hyaluronate. *Gastrointest Endosc* 1999, 50:251–256.
11. Fujishiro M, Yahagi N, Kashimura K, et al.: Comparison of various submucosal injection solutions for maintaining mucosal elevation during endoscopic mucosal resection. *Endoscopy* 2004, 36:579–583.
12. Fujishiro M, Yahagi N, Kashimura K, et al.: Tissue damage of different submucosal injection solutions for EMR. *Gastrointest Endosc* 2005, 62:933–942.
13. Fujishiro M, Yahagi N, Nakamura M, et al.: Successful treatment outcomes of a novel endoscopic resection for gastrointestinal tumors: endoscopic submucosal dissection using a mixture of high-molecular-weight hyaluronic acid, glycerin, and sugar. *Gastrointest Endosc* 2006, 63:243–249.  
Description of a new ESD technique with excellent outcomes.
14. Fujishiro M: Endoscopic submucosal dissection for stomach neoplasms. *World J Gastroenterol* 2006, 12:5108–5112.  
A review on the recent outcomes of ESD for early gastric cancer.
15. Minami S, Gotoda T, Ono H, et al.: Complete endoscopic closure of gastric perforation induced by endoscopic resection of early gastric cancer using endoclips can prevent surgery (with video). *Gastrointest Endosc* 2006, 63:596–601.  
Describes method to close perforation with endoclips during endoscopic resection for early gastric cancer.
16. Kakushima N, Fujishiro M, Yahagi N, et al.: Helicobacter pylori status and the extent of gastric atrophy do not affect ulcer healing after endoscopic submucosal dissection. *J Gastroenterol Hepatol* 2006, 21:1586–1589.
17. Uedo N, Takeuchi Y, Yamada T, et al.: Effect of a proton pump inhibitor or an H(2)-receptor antagonist on prevention of bleeding from ulcer after endoscopic submucosal dissection of early gastric cancer: a prospective randomized controlled trial. *Am J Gastroenterol* 2007, 102:1610–1616.  
This study shows that a proton pump inhibitor is more effective than a histamine 2-receptor antagonist in preventing delayed bleeding after gastric ESD.
18. Yamamoto H, Kawata H, Sunada K, et al.: Success rate of curative endoscopic mucosal resection with circumferential mucosal incision assisted by submucosal injection of sodium hyaluronate. *Gastrointest Endosc* 2002, 56:507–512.
19. Yamamoto H, Kawata H, Sunada K, et al.: Successful en-bloc resection of large superficial tumors in the stomach and colon using sodium hyaluronate and small-caliber-tip transparent hood. *Endoscopy* 2003, 35:690–694.
20. Gotoda T: A large endoscopic resection by endoscopic submucosal dissection procedure for early gastric cancer. *Clin Gastroenterol Hepatol* 2005, 3:S71–S73.  
This paper shows how to perform ESD using an IT knife.
21. Oyama T, Tomori A, Hotta K, et al.: Endoscopic submucosal dissection of early esophageal cancer. *Clin Gastroenterol Hepatol* 2005, 3:S67–S70.  
This paper shows how to perform ESD using a hook knife.
22. Fujishiro M, Goto O, Kakushima N, et al.: Endoscopic submucosal dissection of stomach neoplasms after unsuccessful endoscopic resection. *Dig Liver Dis* 2007, 39:566–571.
23. Shiraishi N, Yasuda K, Kitano S: Laparoscopic gastrectomy with lymph node dissection for gastric cancer. *Gastric Cancer* 2006, 9:167–176.
24. Shimoyama S, Seto Y, Yasuda H, et al.: Concepts, rationale, and current outcomes of less invasive surgical strategies for early gastric cancer: data from a quarter-century of experience in a single institution. *World J Surg* 2005, 29:58–65.
25. Hiki Y, Shimao J, Yamao Y, et al.: The concepts, procedures, and problems related in endoscopic laser therapy of early gastric cancer. A retrospective study on early gastric cancer. *Surg Endosc* 1989, 3:1–6.
26. Tajiri H, Oguro Y: Laser endoscopic treatment for upper gastrointestinal cancers. *J Laparoendosc Surg* 1991, 1:71–78.
27. Gossner L, Ell C: Photodynamic therapy of gastric cancer. *Gastrointest Endosc Clin N Am* 2000, 10:461–480.
28. Tabuse K, Katsumi M, Nagai Y, et al.: Microwave tissue coagulation applied clinically in endoscopic surgery. *Endoscopy* 1985, 17:139–144.
29. Sagawa T, Takayama T, Oku T, et al.: Argon plasma coagulation for successful treatment of early gastric cancer with intramucosal invasion. *Gut* 2003, 52:334–339.
30. Kitamura T, Tanabe S, Koizumi W, et al.: Argon plasma coagulation for early gastric cancer: technique and outcome. *Gastrointest Endosc* 2006, 63:48–54.
31. Ohta H, Takekoshi T, Takagi K, et al.: Intramural injection of anticancer emulsion by gastroendoscopy [in Japanese]. *Gan To Kagaku Ryoho* 1982, 9:1969–1975.
32. Otani T, Tatsuka T, Kanamaru K, Okuda S: Intramural injection of ethanol under direct vision for the treatment of protuberant lesions of the stomach. *Gastroenterology* 1975, 69:123–129.

- 33.●● Reshamwala PA, Darwin PE: **Endoscopic management of early gastric cancer.** *Curr Opin Gastroenterol* 2006, 22:541–545.

An excellent review on various techniques of endoscopic resection, including EMR and ESD.

34. Tanabe S, Koizumi W, Kokutou M, et al.: **Usefulness of endoscopic aspiration mucosectomy as compared with strip biopsy for the treatment of gastric mucosal cancer.** *Gastrointest Endosc* 1999, 50:819–822.

35. Watanabe K, Ogata S, Kawazoe S, et al.: **Clinical outcomes of EMR for gastric tumors: historical pilot evaluation between endoscopic submucosal dissection and conventional mucosal resection.** *Gastrointest Endosc* 2006, 63:776–782.

- 36.● Oka S, Tanaka S, Kaneko I, et al.: **Advantage of endoscopic submucosal dissection compared with EMR for early gastric cancer.** *Gastrointest Endosc* 2006, 64:877–883.

This paper highlights the differences in the treatment outcomes between EMR and ESD from a retrospective analysis of a large number of cases of early gastric cancer.



Digestive Endoscopy

Endoscopic submucosal dissection as a staging measure may not lead to worse prognosis in early gastric cancer patients with additional gastrectomy<sup>☆</sup>

O. Goto<sup>a</sup>, M. Fujishiro<sup>a,\*</sup>, N. Kakushima<sup>a</sup>, S. Kodashima<sup>a</sup>, S. Ono<sup>a</sup>,  
H. Yamaguchi<sup>b</sup>, S. Nomura<sup>b</sup>, M. Kaminishi<sup>b</sup>, M. Omata<sup>a</sup>

<sup>a</sup> Department of Gastroenterology, Graduate School of Medicine, University of Tokyo, 7-3-1, Hongo, Bunkyo-ku, Tokyo, Japan

<sup>b</sup> Department of Gastrointestinal Surgery, Graduate School of Medicine, University of Tokyo, Tokyo, Japan

Received 11 October 2007; accepted 21 November 2007

Available online 10 January 2008

Abstract

**Background.** Endoscopic submucosal dissection is a novel endoluminal technique that enables resection of early stage gastrointestinal malignancies in an *en bloc* fashion.

**Aim.** To assess whether preceding endoscopic submucosal dissection affected the prognoses of patients who underwent additional gastrectomy with lymph node dissection due to suspicion of nodal metastasis from endoscopic submucosal dissection specimens.

**Patients and methods.** Thirty-one patients with early gastric cancer who underwent gastrectomy after endoscopic submucosal dissection were retrospectively investigated in terms of their survival and tumour recurrence. Additional gastrectomy was performed when histology of the endoscopic submucosal dissection specimens revealed that the tumours did not meet the criteria for node-negative cancers.

**Results.** Twenty-three (74%) and eight (26%) patients had undergone endoscopic submucosal dissection previously due to clinical diagnoses of node-negative cancers and possible node-positive cancers, respectively. Histology of the resected stomachs and lymph nodes revealed residual carcinoma of the stomach in two (6.5%) patients and nodal metastases in four (13%) patients. All patients remain alive without recurrence (median follow-up, 3.4 years; range, 0.6–5.2 years).

**Conclusions.** Based on the histology of endoscopic submucosal dissection specimens, preceding endoscopic submucosal dissection itself had no negative influence on a patient's prognosis when additional gastrectomy was performed. It may be permissible to resect some early gastric cancers by endoscopic submucosal dissection as a first step to prevent unnecessary gastrectomy, if technically resectable.

© 2007 Editrice Gastroenterologica Italiana S.r.l. Published by Elsevier Ltd. All rights reserved.

**Keywords:** Endoscopic submucosal dissection; Gastrectomy; No-touch isolation; Stomach neoplasm

1. Introduction

Endoscopic submucosal dissection (ESD) is a recently developed endoscopic treatment for early stage gastrointestinal malignancies. It is characterized by circumferential mucosal incision and submucosal dissection of the lesion [1]. Because ESD enables endoluminal resection of the

lesion in a one-piece fashion, a pathological diagnosis, whether curative resection is achieved or not, has become easier and more precise than that of a lesion resected by endoscopic mucosal resection in 'piece-meal' fashion [2]. According to the pathological results of ESD specimens of early gastric cancer (EGC), which show, for example, deeper invasion into the submucosa, angiolymphatic invasion, coexistence of diffuse type adenocarcinoma, or ulcerative findings in a large tumour, an additional gastrectomy with lymph node dissection after ESD is performed in order to obtain complete eradication of possible cancer cells remaining in perigastric lymph nodes [3]. However, there is

<sup>☆</sup> This paper was presented in part at the 15th United European Gastroenterology Week Meeting, held October 27–31, 2007, in Paris, France.

\* Corresponding author. Tel.: +81 3 3815 5411; fax: +81 3 5800 8806.

E-mail address: mtfujish-kr@umin.ac.jp (M. Fujishiro).

no report showing whether preceding endoscopic treatment itself, such as ESD, influences the prognosis or survival of patients.

In the field of colorectal surgery, the 'no-touch' isolation technique is accepted in general [4,5]. This technique requires that no contact is made with the tumour itself until all of the surroundings, such as lymph nodes and blood vessels, are completely trimmed and resected in an *en bloc* fashion, so as not to stimulate and accelerate tumour progression or dissemination. The benefit of this concept has also been reported in other cancers such as pancreatic cancer [6], bile duct cancer, and ampullary cancer [7]. Relating this concept to ESD for EGC, the residual cancer cells on the ESD ulcer have already been "touched" by various endoscopic devices and a submucosal fluid cushion, which may lead not only to further tumour progression on the ESD ulcer, but also to tumour spread to angiolymphatic vessels and distant sites. Furthermore, the artificial stimulation on the primary site may influence possible cancer cells in the perigastric lymph nodes to acquire more malignant potential. Thus, in this study, we retrospectively assessed the impact of preceding ESD on the prognoses of patients with additional gastrectomy after ESD for EGC with possible nodal metastases.

## 2. Patients and methods

The subjects of this study were 31 consecutive patients who underwent additional gastrectomy with lymph node dissection after ESD for EGC at our hospital between September 2000 and September 2006 and were followed for more than six months at our hospital. The reasons for additional gastrectomy were the possibility of lymph node metastasis and/or the presence of residual carcinoma according to pathological findings of ESD specimens for EGC. Using the patients' reports, we investigated the reason for gastrectomy, the method of applied gastrectomy and lymph node dissection, the presence of residual carcinoma on the ESD ulcer, the gastric wall around the ESD ulcer, or lymph nodes, and recurrent-free survival.

In this study, carcinomas in a remnant stomach after gastrectomy or in a gastric tube after oesophagectomy were excluded because a previous operation might have changed the angiolymphatic flow and the previous carcinoma might have influenced the patient's survival. Carcinomas located in the oesophago-gastric junction were also excluded, because it was controversial whether the stomach or esophagus criteria were appropriate to be utilized for additional lymphadenectomy.

Lesions with an indication for ESD were determined by endoscopic features using chromoendoscopy with biopsy. When the lesions had a possibility of submucosal invasion, submucosal fibrosis due to ulcer findings, or diffuse-type histology from the above examinations, endoscopic ultrasonography and chest-abdominal computed tomography were additionally performed to investigate submucosal inva-

sion, submucosal fibrosis, and metastases to lymph nodes or distant organs. The criteria for node-negative carcinoma we adopted here were:

- intestinal-type intramucosal adenocarcinoma
- intestinal-type intramucosal adenocarcinoma with ulcer findings less than 3 cm in diameter
- intestinal-type adenocarcinomas with slight invasion into the submucosa (sm1, <500  $\mu$ m below the muscularis mucosa) less than 3 cm in diameter
- diffuse-type intramucosal adenocarcinoma less than 2 cm in diameter [3].

The cases of EGC that were preoperatively considered to be outside the criteria of node-negative carcinomas were not principally indicated for ESD. However, because of the fairly low diagnostic accuracy of depth of tumour invasion for submucosal invasive carcinoma [8], ESD was indicated as a staging measure for technically resectable carcinomas without radiologically proven metastases when the patient desired this procedure.

Techniques for ESD have been described elsewhere [9,10]. The main electrosurgical knife was a flex-knife (KD-630L; Olympus, Tokyo, Japan), and other knives, such as an insulation-tipped diathermic knife (IT knife) [11] and/or a hook-knife [12], were used in addition when required by the complexity of the lesion. In order to create a submucosal fluid cushion, a preparation of either 20% glucose or a mixture of 10% glycerine plus 5% fructose and 0.9% saline (Glycerol, Chugai Pharmaceutical Co., Tokyo, Japan) containing 0.005% indigo carmine and 0.0005% epinephrine was used [13]. Hyaluronic acid was added to the injection solution when the lesion had ulcerative findings or when it was located in the cardia. Hemostatic forceps (HDB2422W; Pentax, Tokyo, Japan) were used for bleeding during the procedure or for the treatment of visible vessels on the mucosal defect after resection.

In the evaluation of ESD specimens, the following criteria were used to recommend additional gastrectomy with lymph node dissection:

- diffuse-type intramucosal adenocarcinoma over 2 cm in diameter
- adenocarcinoma with angiolymphatic invasion
- adenocarcinoma with massive invasion into the submucosa (sm2 or deeper,  $\geq$ 500  $\mu$ m below the muscularis mucosa)
- intestinal-type adenocarcinoma with slight invasion into the submucosa (sm1, <500  $\mu$ m below the muscularis mucosa) over 3 cm in diameter
- intestinal-type intramucosal adenocarcinoma with ulcer findings over 3 cm in diameter
- diffuse-type adenocarcinoma which tested positive for surgical margins

Intestinal-type adenocarcinomas with positive surgical margins were endoscopically followed at two months, six months and 12 months after ESD, and then annually, because the margin of carcinoma was easily recognized in this sub-



**Table 1**  
Clinicopathologic characteristics of 31 patients who underwent gastrectomy with lymphadenectomy after endoscopic submucosal dissection because of the possibility of lymph node metastasis

	Number
<b>Sex</b>	
Male	26
Female	5
Age (years), mean $\pm$ S.D.	63.4 $\pm$ 7.58
<b>Location</b>	
Upper	5
Middle	18
Lower	8
<b>Pre-ESD diagnosis</b>	
Conventional criteria	5
Expanded criteria	18
Outside the criteria	8
<b>The reason for gastrectomy<sup>a</sup></b>	
Diffuse-type over 2 cm	7
Angiolymphatic invasion	13
sm2 invasion <sup>b</sup>	23
sm1 over 3 cm	2
Over 3 cm with ulceration	3
Diffuse-type of positive surgical margin	5

<sup>a</sup> Some patients fulfil more than one reason.

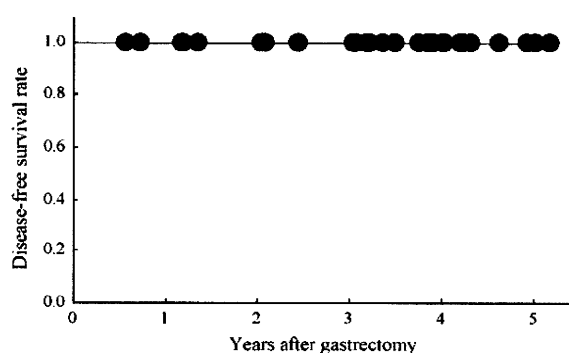
<sup>b</sup> sm: submucosa (cut-off line between sm1 and sm2 is 500  $\mu$ m).

group and burning of the tissue during mucosal cutting might result in tumour eradication, even if the pathology revealed a positive surgical margin. When the follow-up endoscopy revealed remnant carcinoma, ESD or gastrectomy was performed according to the status of the carcinoma in order to eradicate the entire lesion.

Additional gastrectomy was performed by gastrointestinal surgeons after confirmation of the histology of ESD specimens. The delay between ESD and gastrectomy was determined by the surgeons responsible for the patients' care, considering scheduled operations and patients' conditions. Surveillance after gastrectomy was also determined by the surgeons responsible for the patients' care. Chest-abdominal computed tomography, assay of tumour markers including CEA and CA19-9, and endoscopy of the remnant stomach were generally scheduled at least once a year.

### 3. Results

The tumour characteristics of the subjects are summarized in Table 1. As for the pre-ESD diagnoses, five lesions were considered to meet the conventional indication criteria [14] (intestinal-type adenocarcinoma  $\leq$ 2 cm in size without ulcer findings), 18 met the expanded indication criteria [3] (which were identical to the criteria for node-negative carcinoma except for the conventional indication criteria), and eight were outside the criteria for node-negative carcinoma, for which ESD was performed as a staging measure. Out of the six above criteria for additional gastrectomy, 13, 15, two and



**Fig. 1.** Disease-free survival curve of the patients who underwent additional gastrectomy with lymph node dissection after ESD. All patients survived without recurrences for a median of 3.4 years.

one patient(s) underwent gastrectomy due to the fulfillment of one, two, three or four criteria, respectively. According to the tumour location, total gastrectomy was performed in three patients, proximal gastrectomy in five patients and, distal gastrectomy in five patients, pylorus-preserving gastrectomy in 18 patients. The type of lymphadenectomy performed was D1 +  $\alpha$  in 11 patients, D1 +  $\beta$  in 19 patients, and D2 in one patient (median duration between ESD and gastrectomy, 62 days; range, 8–148 days). All surgical operations resulted in R0 resection. Histological evaluation of the resected stomachs and lymph nodes revealed residual carcinoma on the stomach in two (6.5%) patients and nodal metastases in four (13%) patients (Table 2). As shown in Fig. 1, all patients with additional gastrectomy survived without recurrences regardless of residual carcinoma on the stomach or nodal metastases (median follow-up, 3.4 years; range, 0.6–5.2 years).

### 4. Discussion

Due to the technical advancements of ESD, the indication criteria for ESD are now nearly equal to the criteria for node-negative carcinoma, which includes large carcinoma or carcinoma with ulcer findings. However, the more complex the lesion becomes, the more frequently misdiagnoses of depth of tumour invasion or identification of angiolymphatic invasion from ESD specimens occur. Thus, more lesions that are considered to be node-negative carcinomas preoperatively turn out to require additional gastrectomies with lymph node dissections in comparison to those treated by EMR. Another consideration is the application of ESD for lesions suspected of being outside the criteria for node-negative carcinomas preoperatively as a staging measure, because some of these lesions are technically resectable using ESD techniques. In this situation, incomplete resection becomes more frequent than when the indication criteria are strictly observed.

In daily practice, we are sometimes unable to conclusively diagnose node-negative carcinoma, even when endoscopic ultrasonography is used to determine the tumour depth.

Table 2  
Clinical and pathologic were findings of six patients who were revealed to have locally residual cancers or lymph node metastases on additional gastrectomy with lymph node dissection

Patient	Age	Sex	Pre-ESD diagnosis	The reason for gastrectomy	Location	Operation style <sup>a</sup>	LN dissection	Residual tumour	LN metastasis	Time after operation (years)	Survival	Recurrence
1	60	M	Expanded criteria	Diffuse type over 2 cm, angiolymphatic invasion, sm2 invasion <sup>b</sup> , and diffuse type with positive surgical margin sm2 invasion	M	DG	D2	No	Yes	4.0	Alive	No
2 <sup>c</sup>	62	M	Outside the criteria	Diffuse type over 2 cm, and diffuse type with positive surgical margin	M	TG	D1 + β	No	Yes	3.8	Alive	No
3	75	M	Expanded criteria	Diffuse type over 2 cm, and diffuse type with positive surgical margin	L	LAPPG	D1 + α	Yes	No	3.2	Alive	No
4	68	M	Expanded criteria	Diffuse type over 2 cm, sm2 invasion, and diffuse type with positive surgical margin	U	LATG	D1 + β	Yes	No	2.0	Alive	No
5 <sup>c</sup>	72	F	Expanded criteria	Angiolymphatic invasion and sm2 invasion	L	PPG	D1 + β	No	Yes	1.2	Alive	No
6	57	M	Outside the criteria	Angiolymphatic invasion and sm1 over 3 cm	M	LAPPG	D1 + β	No	Yes	1.2	Alive	No

<sup>a</sup> DG, distal gastrectomy; TG, total gastrectomy; LA, laparoscope-associated; PPG, pylorus-preserving gastrectomy.

<sup>b</sup> sm: submucosa (cut-off line between sm1 and sm2 is 500 μm).

<sup>c</sup> Piecemeal resection by ESD.

Because the patient never has an entire stomach after performing gastrectomy, challenges for curative resection by ESD in the above situation may be acceptable to some extent. It is impossible to overemphasize that one of the intrinsic benefits of ESD is the ability to evaluate an entire lesion of the primary site histologically. However, we have to elucidate the fact that the prognoses of patients with additional gastrectomy may not be worsened due to preceding ESD. If non-curative ESD causes the patient's prognosis to worsen, we must refrain from performing ESD as a staging measure. Therefore, we conducted this retrospective analysis concerning recurrent-free survival of the cases of additional gastrectomy with lymph node dissection after ESD.

The prognosis of EGC patients after gastrectomy is remarkably good, as demonstrated by the five-year survival rate of 99% in mucosal cancer groups and 96% in submucosal cancer groups [15]. If the survival rate of the patients who underwent non-curative ESD was below that of curative gastrectomy with lymph node dissection alone, challenging ESD procedure might not become acceptable as a staging measure. The favourable results of this study, that there was neither tumour-recurrence nor disease-related death as far as we observed, suggests that preceding ESD resulting in non-curative resection does not have an influence on the prognoses of EGC patients.

The limitation of this study, however, is that it is a non-controlled, retrospective study with a small number of cases. Further investigations with multi-centre studies are necessary to confirm our results. However, we consider that the shortcomings are partly counterbalanced by the findings of no recurrence in consecutive and unselected patients during the median follow-up period of more than three years. It has been reported that nearly 50% of deaths from recurrent gastric cancer occur in the first year of follow-up and that approximately 75% of tumour-related deaths occur within two years, even after curative gastrectomy [16,17]. Although the median follow-up of this study is not long enough to draw a final conclusion, we believe that the duration of this study is acceptable to indicate favourable results with high probability.

Additionally, this study does not suggest that further expansion of ESD indication is possible, because the majority of subjects in this study were preoperatively diagnosed with a node-negative carcinoma. The most important task is to perform precise histological evaluation of the ESD specimen and to refer patients with possible of nodal metastases to the gastrointestinal surgeon for additional gastrectomy. If patients with possible nodal metastases are followed without undergoing additional gastrectomy, they may not be cured. The use of staging ESD is only applicable when the patient agrees to additional gastrectomy when non-curative resection is revealed.

In summary, because preoperative diagnosis is not 100% and angiolymphatic invasion is impossible to identify preoperatively, the concept of staging ESD for EGC may be acceptable to prevent unnecessary gastrectomy when the

lesion has a possibility of curative resection by ESD alone. However, we have to stress the necessity for additional gastrectomy with lymph node dissection when the histology of an ESD specimen reveals non-curative resection with possible nodal metastases.

### Practice points

- Preceding endoscopic submucosal dissection (ESD) for early gastric cancer (EGC) resulting in non-curative resection does not have an influence on the prognoses of patients.
- ESD for EGC as a staging measure may be acceptable to prevent unnecessary gastrectomy when there is a possibility for curative resection of the lesion by ESD alone.

### Research agenda

- This study involves the analysis of a small number of cases with a median follow-up of 3.4 years. Further accumulation of cases and a longer follow-up period is necessary to confirm the results.
- This study had a retrospective, single-centre design. A prospective, multi-centre study will be more favourable in the future.

### Conflict of interest statement

None declared.

### References

- [1] Ono H, Kondo H, Gotoda T, Shirao K, Yamaguchi H, Saito D, Hosokawa K, Shimoda T, Yoshida S. Endoscopic mucosal resection for treatment of early gastric cancer. *Gut* 2001;48:225–9.
- [2] Eguchi T, Gotoda T, Oda I, Hamanaka H, Hasuike N, Saito D. Is endoscopic one-piece mucosal resection essential for early gastric cancer? *Dig Endosc* 2003;15:113–6.
- [3] Gotoda T, Yanagisawa A, Sasako M, Ono H, Nakanishi Y, Shimoda T, Kato Y. Incidence of lymph node metastasis from early gastric cancer: estimation with a large number of cases at two large centers. *Gastric Cancer* 2000;3:219–25.
- [4] Turnbull Jr RB, Kyle K, Watson FR, Spratt J. Cancer of the colon: the influence of the no-touch isolation technic on survival rates. *Ann Surg* 1967;166:420–7.
- [5] Wiggers T, Jeekel J, Arends JW, Brinkhorst AP, Kluck HM, Luyk CI, Munting JDK, Povel JACM, Rutten APM, Volovics A, Grep JM. No-touch isolation technique in colon cancer: a controlled prospective trial. *Br J Surg* 1988;75:409–15.
- [6] Hirota M, Shimada S, Yamamoto K, Tanaka E, Sugita H, Egami H, Ogawa M. Pancreatectomy using the no-touch isolation technique followed by extensive intraoperative peritoneal lavage to prevent cancer cell dissemination: a pilot study. *JOP* 2005;10:143–51.
- [7] Kobayashi S, Asano T, Ochiai T. A proposal of no-touch isolation technique in pancreatoduodenectomy for periampullary carcinomas. *Hepatogastroenterology* 2001;48:372–4.
- [8] Ono H, Yoshida S. Endoscopic diagnosis of the depth of cancer invasion for gastric cancer [in Japanese with English abstract]. *Stomach and Intestine* 2001;36(Suppl.):334–40.
- [9] Yahagi N, Fujishiro M, Kakushima N, Imagawa A, Iguchi M, Okawa A, Kobayashi K, Hashimoto T, Oka M, Omata M. Merits and demerits of endoscopic submucosal dissection using a flexknife [in Japanese with English abstract]. *Stomach and Intestine* 2004;39:39–43.
- [10] Kodashima S, Fujishiro M, Yahagi N, Kakushima N, Omata M. Endoscopic submucosal dissection using Flex-Knife. *J Clin Gastroenterol* 2006;40:378–84.
- [11] Gotoda T, Kondo H, Ono H, Saito Y, Yamaguchi H, Saito D, Yokota T. A new endoscopic mucosal resection procedure using an insulation-tipped electro-surgical knife for rectal flat lesions: report of two cases. *Gastrointest Endosc* 1999;50:560–3.
- [12] Oyama T, Tomori A, Hotta K, Morita S, Kominato K, Tanaka M, Miyata Y. Endoscopic submucosal dissection of early esophageal cancer. *Clin Gastroenterol Hepatol* 2005;3:S67–70.
- [13] Fujishiro M, Yahagi N, Kashimura K, Mizushima Y, Oka M, Enomoto S, Kakushima N, Kobayashi K, Hashimoto T, Iguchi M, Shimizu Y, Ichinose M, Omata M. Comparison of various submucosal injection solutions for maintaining mucosal elevation during endoscopic mucosal resection. *Endoscopy* 2004;36:579–83.
- [14] Japanese Gastric Cancer Association. Japanese classification of gastric carcinoma—2nd English edition. *Gastric Cancer* 1998;1:10–24.
- [15] Sakako M, Kinoshita T, Maruyama K. Prognosis of early gastric cancer [in Japanese with English abstract]. *Stomach and Intestine* 1993;28(Suppl.):139–46.
- [16] Shiraishi N, Inomata M, Osawa N, Yasuda K, Adachi Y, Kitano S. Early and late recurrence after gastrectomy for gastric carcinoma: univariate and multivariate analyses. *Cancer* 2000;89:255–61.
- [17] Saker B, Karagol H, Gumus M, Basaran M, Kaytan E, Argon A, Ustuner Z, Bavbek SE, Bugra D, Aykan FN. Timing of death from tumor recurrence after curative gastrectomy for gastric cancer. *Am J Clin Oncol* 2004;27:205–9.

# Efficacy and safety of endoscopic submucosal dissection for gastric cancer in patients with liver cirrhosis

## Authors

K. Ogura, M. Okamoto, T. Sugimoto, N. Yahagi, M. Fujishiro, N. Kakushima, S. Kodashima, T. Kawabe, M. Omata

## Institution

Department of Gastroenterology, University of Tokyo Graduate School of Medicine, Tokyo, Japan

## submitted

21 September 2007

## accepted after revision

11 February 2008

## Bibliography

DOI 10.1055/s-2007-995650

Published ahead of print

Endoscopy

© Georg Thieme

Verlag KG Stuttgart · New York

ISSN 0013-726X

## Corresponding author

**K. Ogura, MD, PhD**

Department of

Gastroenterology

University of Tokyo Graduate

School of Medicine

7-3-1 Hongo

Bunkyo

Tokyo 113-8655

Japan

Fax: + 81-3-3814-0021

keiji-tky@umin.ac.jp

Endoscopic submucosal dissection (ESD) has become a widely accepted method for treating gastrointestinal cancer. The aim of this study was to evaluate the efficacy and safety of ESD for gastric cancer in patients with liver cirrhosis. A total of 18 gastric cancers were treated by ESD in 15 patients with cirrhosis. The rate of en bloc resection was 88.9% (16/18). En bloc resection with tumor-free lateral/basal margins (R0 resection) was

77.8% (14/18). Three patients had postoperative bleeding and underwent emergency gastroscopy for hemostasis. No recurrence was observed during the median follow-up of 21.4 months, excluding three patients in whom additional endoscopic resection or surgery was carried out. ESD can be safely performed for gastric cancer in patients with cirrhosis, resulting in a high en bloc resection rate.

## Introduction

Endoscopic mucosal resection (EMR) is a less invasive treatment than surgical operation, but the lesions that can be treated by conventional EMR are limited by their shape and size. Endoscopic submucosal dissection (ESD) was developed to overcome the technical limits of conventional EMR and is capable of performing en bloc resection of large or ulcerative lesions [1]. However, the techniques of ESD are relatively difficult compared with those of conventional EMR, and complications are more likely to occur [2]. In the present study, we aimed to evaluate the efficacy and safety of ESD for gastric cancers in patients with liver cirrhosis, for whom surgery may cause severe postoperative complications [3].

## Case report

Patients with gastric cancer and liver cirrhosis who underwent ESD from April 2004 to October 2006 at the University of Tokyo Hospital, Japan, were included. The ESD indication criterion was differentiated early gastric cancer diagnosed by endoscopy.

The ESD procedure was carried out as previously reported [4]. The whole procedure was carried out under conscious sedation using diazepam (5–30 mg) and pentazocine (15–30 mg). Pro-

phylactic blood transfusion of platelets or fresh frozen plasma was not generally performed, except in one patient. All patients provided written informed consent before receiving the treatment. Endoscopic characteristics of the lesions were classified according to the Paris endoscopic classification [5]. Histological classification was done microscopically according to the revised Vienna classification of gastrointestinal epithelial neoplasia [6]. The location was described by UML (upper, middle, lower) classification [7]. Conditions for declaring the resection curative were en bloc resection with margins free of neoplasms (i.e. en bloc + R0 resection), with any of the following findings: intramucosal cancer, differentiated type, no angiolymphatic invasion, and no ulceration, irrespective of tumor size; intramucosal cancer, differentiated type, no angiolymphatic invasion, and tumor size < 3 cm, irrespective of ulceration findings; or minimally invasive submucosal cancer (invasion depth  $\leq$  500  $\mu$ m, SM1), differentiated type, no angiolymphatic invasion, and tumor size < 3 cm. Resection that did not meet the above conditions and that had margins positive for tumor were considered noncurative. A total of 15 patients (10 men and five women) were enrolled, and 18 gastric cancer lesions were resected endoscopically. Generally, patients were treated within 3 months of diagnosis. The mean age of the patients was 69.6 years (range 52–82 years). As shown in **Table 1**, one patient

**Table 1** Clinical characteristics of patients

Demography	
Mean age, years (range)	69.6 (52–82)
Men/women (%)	10/5 (66.7/33.3)
Cause of liver dysfunction	
HBV/HCV/non-B non-C (%)	1/9/5 (6.7/60.0/33.3)
No. of patients who had histological liver evaluation	
HBV/HCV/non-B non-C	0/6/2
Child–Pugh Class	
A/B/C (%)	9/6/0 (60/40/0)
Ascites	
Absent/present (%)	12/3 (80/20)
Encephalopathy	
Absent/present (%)	14/1 (93.3/6.7)
Laboratory data by mean (range)	
Platelet count ( $\times 10^{10}/L$ )	11.0 (4.3–28.2)
Prothrombin time (seconds)	12.7 (11.4–15.2)
INR	1.27 (1.10–1.76)
Bilirubin (mg/dL)	0.9 (0.4–1.8)
Albumin (g/dL)	3.6 (2.6–4.6)
Endoscopic findings related to portal hypertension	
Gastroesophageal varices (%)	7 (46.7)
Portal-hypertensive gastropathy (%)	2 (13.3)

HBV, hepatitis B virus; HCV, hepatitis C virus; INR, international normalized ratio.

was positive for hepatitis B virus and nine for hepatitis C virus. Among the five patients who were negative for viral hepatitis, four had a history of alcoholism and one was suspected of having nonalcoholic steatohepatitis. Histological evaluation of the liver was carried out in two of four patients suspected of alcoholic liver disease, but no specific signs were found. Nine patients were Child–Pugh class A and six were class B. No patient belonged to class C. Laboratory results and endoscopic findings related to cirrhosis are shown in **Table 1**. No patient received anticoagulants or antiplatelet agents.

Histopathological findings of the resected lesions are summarized in **Table 2**. The mean size of the lesions was 18.4 mm (range 5–34 mm) and 10 lesions were >20 mm in diameter. The size of resected specimens ranged from 18 to 51 mm. The en bloc resection rate was 88.9% (16/18) and the en bloc plus R0 resection rate was 77.8% (14/18).

Two lesions resulted in piecemeal resection and no residual tumor was found on follow-up. The lateral surgical margins of two resected specimens were diagnosed as positive for cancer. One patient with residual cancer successfully underwent additional endoscopic resection. In the other patient, no residual cancer was found on follow-up endoscopy. Other than these patients, five were considered for additional therapy because of the risk of lymph node metastasis. They had massive submucosal invasive cancer (>500  $\mu\text{m}$ ) and/or angiolymphatic invasion. Among these five patients, two underwent additional surgery with laparotomy. One had gastrectomy with lymph node dissection and the other had laparoscopy-assisted lymph node dissection without gastrectomy. Neither of the patients was revealed to have any detectable lymph node metastasis. For the other three patients, surgery was declined by the patients or surgeons because of age, general health, or liver function of the patients. Excluding three patients in whom additional endoscopic resection or surgery was performed, no recurrence was observed during the median follow-up of 21.4 months in the 12 remaining patients.

**Table 2** Pathological features of 18 gastric cancers treated by endoscopic submucosal dissection, and resection and complication rates

Mean lesion size, mm (range)	18.4 (5–34)
Location of the lesion	
Upper third of the stomach	4
Middle third of the stomach	10
Lower third of the stomach	4
Macroscopic type	
I	1
I+IIa	1
IIa	5
IIa+IIb	1
IIa+IIc	1
IIb+IIc	1
IIc	7
IIc+IIa	1
Histological depth	
Mucosa	11
SM1	3
SM2	4
Mean operation time, minutes (range)	70 (10–450)
En bloc resection (%)	16 (88.9)
En bloc resection + R0 resection (%)	14 (77.8)
Piecemeal resection (%)	2 (11.1)
Bleeding (%)	3 (20)
Perforation (%)	0 (0)
Death related to the operation (%)	0 (0)
Median waiting time before treatment, months (range)	1.5 (0.5–12.0)
Median follow-up duration, months (range)	22.0 (11.6–39.3)

Treatment-related complications are presented in **Table 2**. Postoperative bleeding was defined as evident bleeding (hematemesis or melena) or a decrease in hemoglobin of >2 g/dL. Three patients (20%) were considered to have postoperative bleeding and underwent emergency endoscopy. Active bleeding was confirmed in all three patients, and one of them needed blood transfusion for severe anemia. The bleeding was managed endoscopically in all patients. All three were Child–Pugh class B. The platelet count of these three patients was 43000, 73000, and 79000/ $\mu\text{L}$ , respectively. The international normalized ratio (INR) of prothrombin time was 1.33, 1.37, and 1.52, respectively. No perforation occurred, and no patient required laparotomy for complications. The mean procedure time was 70 minutes (range 20–450 minutes).

## Discussion

Gastric cancer is a major health problem and a leading cause of cancer mortality. Traditional surgical resection has been established as the principal treatment for gastric cancer, with a high overall survival rate of ~90% and a low 2–3% 10-year relapse rate for early gastric cancer [8]. However, liver cirrhosis is known to carry a high risk for abdominal surgery [3]. Concerning the risk of liver cirrhosis for gastric surgery, Isozaki et al. reported that they experienced hospital death in four of 39 patients who underwent surgery for gastric cancer accompanied by liver cirrhosis in 1997 [9]. Recently, Ryu et al. reported excellent results in 26 patients with gastric cancer and liver cirrhosis, all Child–Turcotte–Pugh classification grade A who underwent gastrectomy [10]. Paracentesis was needed in one patient and diuretics were administered in eight to control post-

operative ascites. There was no postoperative mortality. Another study showed death from hepatorenal failure with intractable ascites among two of 94 patients with hepatic cirrhosis after gastrectomy [11]. One patient who died was classified as Child's class B and the other as Child's class C. Thus, gastrectomy for Child's class A may not be a contraindication, although the clinical outcome still varies among the institutes. A curative but less radical treatment is required for patients with gastric cancer who have liver cirrhosis.

The major advantages of the ESD technique compared with conventional EMR are that larger lesions can be resected in an en bloc fashion, ulcerative lesions can be resected, and better pathological evaluation is achieved using en bloc specimens. In the present study, we treated 18 lesions of early gastric cancer in patients with liver cirrhosis. En bloc and R0 resection was achieved for 14 lesions (77.8%), which included eight that were > 20 mm in diameter. No recurrence was observed up to the end of 2007 for all but three patients who received additional treatment.

The disadvantages of ESD are its higher technical difficulty, severe complications, long operating time, and high cost compared with conventional EMR. When applied to patients with liver cirrhosis, complications and long operating time are of concern. In some cases, a long procedure time with sedation of up to 450 minutes is used because of the difficulties of tumor location and bleeding tendency. The average operation time in this study population was 94 minutes, which was longer than the 80 minutes described in a previous study that described ESD in the general population, even though the mean lesion size in the two studies was similar [2]. One possible reason for this difference in procedure time is that a bleeding tendency related to cirrhosis requires frequent hemostatic procedures. Postoperative bleeding was observed in three (20.0%) patients, which is high compared with the postoperative bleeding rate of 3.4 to 6.2% in previous studies [1,4]. This may also have been due to the bleeding tendency, such as a low platelet count or prolonged prothrombin time. All three who had postoperative bleeding were Child's class B. They were among seven with a platelet count < 80 000/ $\mu$ L and four with INR > 1.3. However, no increase in ascites, no

development of hepatic encephalopathy, and no worsening of liver function took place during the perioperative period. No perforation occurred during and after the procedure.

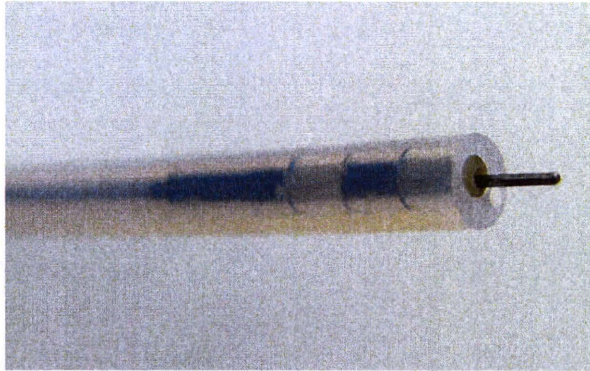
In conclusion, ESD can be safely performed for gastric cancer in patients with cirrhosis, and is expected to be effective with a high en bloc resection rate. However, a bleeding tendency in patients with cirrhosis may lead to longer procedure times and postoperative bleeding. Attention should be paid to these factors, and further improvement of the procedure will be helpful.

**Competing interests:** None

#### References

- 1 Oka S, Tanaka S, Kaneko I et al. Advantage of endoscopic submucosal dissection compared with EMR for early gastric cancer. *Gastrointest Endosc* 2006; 64: 877–883
- 2 Kakushima N, Fujishiro M, Kodashima S et al. A learning curve for endoscopic submucosal dissection of gastric epithelial neoplasms. *Endoscopy* 2006; 38: 991–995
- 3 Mansour A, Watson W, Shayani V et al. Abdominal operations in patients with cirrhosis: still a major surgical challenge. *Surgery* 1997; 122: 730–735
- 4 Kakushima N, Fujishiro M, Kodashima S et al. Histopathologic characteristics of gastric ulcers created by endoscopic submucosal dissection. *Endoscopy* 2006; 38: 412–415
- 5 *Participants in the Paris Workshop*. The Paris endoscopic classification of superficial neoplastic lesions: esophagus, stomach, and colon. *Gastrointest Endosc* 2003; 58: S3–S43
- 6 Dixon MF. Gastrointestinal epithelial neoplasia: Vienna revisited. *Gut* 2002; 51: 130–131
- 7 *Japanese Gastric Cancer Association*. Japanese classification of gastric carcinoma – 2nd English Edition. *Gastric Cancer* 1998; 1: 10–24
- 8 Sano T, Sasako M, Kinoshita T et al. Recurrence of early gastric cancer. Follow-up of 1475 patients and review of the Japanese literature. *Cancer* 1993; 72: 3174–3178
- 9 Isozaki H, Okajima K, Ichinona T et al. Surgery for gastric cancer in patients with cirrhosis. *Surg Today* 1997; 27: 17–21
- 10 Ryu KW, Lee JH, Kim YW et al. Management of ascites after radical surgery in gastric cancer patients with liver cirrhosis and minimal hepatic dysfunction. *World J Surg* 2005; 29: 653–656
- 11 Lee JH, Kim J, Cheong JH et al. Gastric cancer surgery in cirrhotic patients: result of gastrectomy with D2 lymph node dissection. *World J Gastroenterol* 2005; 11: 4623–4627

## Successful en bloc resection of superficial esophageal cancer treated by endoscopic submucosal dissection with a splash needle



**Fig. 1** Splash needle. The tip of the knife consists of a small channel for water irrigation and a thin needle.

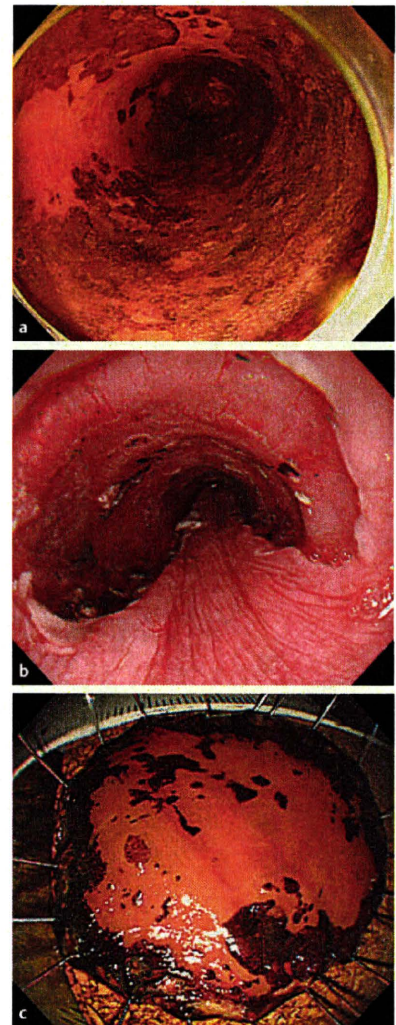
Endoscopic submucosal dissection (ESD) enables resection of large or nonlifting gastrointestinal epithelial neoplasms in an en bloc fashion. However, the high frequency of complications and the complexity of the procedure need to be improved [1–4]. In collaboration with the Pentax Corporation, Tokyo, Japan, we have therefore invented a novel electro-surgical knife for ESD, called the splash needle (DN-2618A; Pentax Corp.), which has an ultra-thin short needle with a water-jet function (● Fig. 1). The advantages are: (i) the short needle is adjustable in length (maximum 2.5mm); (ii) the thinness of the needle (0.3 mm diameter) makes it possible to resect using only coagulation current from mucosal incision to submucosal dissection, to reduce the risk of heavy bleeding, or to resect sharply with minimal tissue damage by using cutting or Endocut current; (iii) the water-jet function from the knife itself allows the endoscopic view field to be kept clean, bleeding vessels to be easily identified, and additional submucosal injection to be done without changing the device. A disadvantage could be that a sharper cutting ability could lead to perforation if the knife is used incorrectly. A 64-year-old gentleman with a semicircular non-Lugol-staining area diagnosed as squamous cell carcinoma in the lower esophagus was referred for ESD. With a preoperative diagnosis of type 0-IIc intramucosal squamous cell carcinoma (m2), 3 cm in size, ESD was performed with a splash needle without complications in an operating

time of 65 minutes, in a similar way to that described previously, with some modification [5] (● Fig. 2, ● Video 1). The main modifications were:

1. A single channel upper GI endoscope with a water-jet system was used (GIF-Q260J; Olympus Medical Systems Co., Ltd., Tokyo, Japan), which connected to a water-jet supplier (OFP; Olympus Medical Systems) containing sterile water to wash out blood and mucus from the target area, to keep the endoscopic view clean, and to identify bleeding points precisely during the procedure. The knife was connected to another water-jet supplier (SA-P2; Pentax) containing normal saline to make an immediate and sufficient submucosal fluid cushion in the area intended to be cut without changing the device.
2. The following electrocautery settings (VIO 300D; ERBE Elektromedizin, Tübingen, Germany) were used: forced coagulation mode (effect 2, output 30 W) for marking and submucosal dissection, and Endocut Q mode (effect 2, duration 1, interval 3) for circumferential mucosal incision. This case

### Video 1

Endoscopic submucosal dissection with a splash needle for superficial esophageal cancer. Using the splash needle, the marking, mucosal incision, additional submucosal fluid injection, and submucosal dissection are all possible without changing the device.



**Fig. 2** a–c Superficial esophageal cancer resected by endoscopic submucosal dissection with a splash needle. **a** Type 0-IIc intramucosal squamous cell carcinoma (m2), 3 cm in size, is located in the lower esophagus. **b** Mucosal defect after endoscopic submucosal dissection with a splash needle. **c** The lesion is completely resected in one piece with a tumor-free resected margin.

shows that this novel knife unquestionably has several functional advantages which enable a step forward in ESD techniques.

Endoscopy\_UCTN\_Code\_TTT\_1AO\_2AG

**M. Fujishiro, S. Kodashima, O. Goto, S. Ono, Y. Muraki, N. Kakushima, M. Omata**

Department of Gastroenterology, Graduate School of Medicine, The University of Tokyo, Tokyo, Japan

**References**

- 1 Fujishiro M. Endoscopic submucosal dissection for stomach neoplasms. *World J Gastroenterol* 2006; 12: 5108–5112
- 2 Fujishiro M, Yahagi N, Kakushima N et al. Endoscopic submucosal dissection of esophageal squamous cell neoplasms. *Clin Gastroenterol Hepatol* 2006; 4: 688–694
- 3 Fujishiro M, Yahagi N, Nakamura M et al. Endoscopic submucosal dissection for rectal epithelial neoplasia. *Endoscopy* 2006; 38: 493–497
- 4 Fujishiro M, Yahagi N, Kakushima N et al. Outcomes of endoscopic submucosal dissection for colorectal epithelial neoplasms in 200 consecutive cases. *Clin Gastroenterol Hepatol* 2007; 5: 678–683
- 5 Kodashima S, Fujishiro M, Yahagi N et al. Endoscopic submucosal dissection using flex-knife. *J Clin Gastroenterol* 2006; 40: 378–384

**Bibliography**

DOI 10.1055/s-2007-995538  
Endoscopy 2008; 40: E81–E82  
© Georg Thieme Verlag KG Stuttgart · New York ·  
ISSN 0013-726X

**Corresponding author**

**M. Fujishiro, MD, PhD**  
Department of Gastroenterology  
Graduate School of Medicine  
The University of Tokyo  
7-3-1, Hongo, Bunkyo-ku  
Tokyo  
113-8655 Japan  
Fax: +81-3-58008806  
mtfujish-kr@umin.ac.jp



## Endoscopic submucosal dissection for gastrointestinal neoplasms

Naomi Kakushima, Mitsuhiro Fujishiro

Naomi Kakushima, Mitsuhiro Fujishiro, Department of Gastroenterology, The University of Tokyo, Graduate School of Medicine, Tokyo 113-8655, Japan

**Author contributions:** Kakushima N and Fujishiro M contributed equally to this work; Kakushima N and Fujishiro M performed research, and wrote the paper.

**Correspondence to:** Naomi Kakushima, MD, PhD, Department of Gastroenterology, The University of Tokyo, Graduate School of Medicine, 7-3-1 Hongo, Bunkyo-ku, Tokyo 113-8655, Japan. [kakushin-ky@umin.ac.jp](mailto:kakushin-ky@umin.ac.jp)

Telephone: +81-3-38155411 Fax: +81-3-58008806

Received: February 22, 2008 Revised: March 26, 2008

### Abstract

Endoscopic submucosal dissection (ESD) is an advanced technique of therapeutic endoscopy for superficial gastrointestinal neoplasms. Three steps characterize it: injecting fluid into the submucosa to elevate the lesion, cutting the surrounding mucosa of the lesion, and dissecting the submucosa beneath the lesion. The ESD technique has rapidly permeated in Japan for treatment of early gastric cancer, due to its excellent results of en-bloc resection compared to endoscopic mucosal resection (EMR). Although there is still room for improvement to lessen its technical difficulty, ESD has recently been applied to esophageal and colorectal neoplasms. Favorable short-term results have been reported, but the application of ESD should be well considered by three aspects: (1) the possibility of nodal metastases of the lesion, (2) technical difficulty such as location, ulceration and operator's skill, and (3) organ characteristics.

© 2008 WJG. All rights reserved.

**Key words:** Endoscopic submucosal dissection; Gastric cancer; Esophageal cancer; Colorectal cancer; Endoscopic mucosal resection; Therapeutic endoscopy

**Peer reviewers:** Zvi Fireman, Professor, Department of Gastroenterology, Hillel- yaffe Medical Center, Hadera 38100, Israel; Chee Lim, Dr, Department of Gastroenterology, Good Hope Hospital, Heart of England Foundation NHS Trust, W Midlands B75 7RR, United Kingdom

Kakushima N and Fujishiro M. Endoscopic submucosal dissection for gastrointestinal neoplasms. *World J Gastroenterol* 2008; 14(19): 2962-2967 Available from: URL: <http://www.wjnet.com/1007-9327/14/2962.asp> DOI: <http://dx.doi.org/10.3748/wjg.14.2962>

### INTRODUCTION

Application of endoscopic resection (ER) to gastrointestinal (GI) neoplasms is limited to lesions with no risk of nodal metastasis. Either polypectomy or endoscopic mucosal resection (EMR) is beneficial for patients because of its low level of invasiveness. However, to ensure the curative potential of these treatment modalities, accurate histopathologic assessment of the resected specimens is essential because the depth of invasion and lymphovascular infiltration of the tumor is associated with considerable risk for lymph node metastasis. For accurate assessment of the appropriateness of the therapy, en bloc resection is more desirable than piecemeal resection. For a reliable en bloc resection of GI neoplasms, a new method of ER called endoscopic submucosal dissection (ESD) has been developed. In this article, an outline of the current status of ESD will be discussed.

### DEVELOPMENT OF ESD

The ESD technique has developed from one of the EMR techniques, namely endoscopic resection after local injection of a solution of hypertonic saline-epinephrine (ERHSE)<sup>[1]</sup>. Initially, the ESD technique was called by various names such as cutting EMR, exfoliating EMR, EMR with circumferential incision etc. However, a new name was proposed to this technique in 2003, as a treatment positioned between EMR and laparoscopic surgery, since this technique is innovative and enables complete resection of neoplasms that were impossible to resect en bloc by EMR.

At present, numerous electro-surgical knives such as insulation-tipped diathermic knife (IT-knife)<sup>[2-6]</sup>, needle knife<sup>[7]</sup>, hook knife<sup>[8]</sup>, flex knife<sup>[9-11]</sup>, triangle-tipped knife<sup>[12]</sup>, flush knife<sup>[13]</sup>, mucosectome<sup>[14]</sup>, splash needle<sup>[15]</sup> and a special device called a small-caliber tip transparent (ST) hood<sup>[7]</sup> are available for this technique. One or two of these electro-surgical knives are used in combination with a high frequency electro-surgical current (HFEC) generator with an automatically controlled system (Endocut mode, Erbotom ICC200, ICC350, VIO300D, ERBE, Tübingen, Germany) (PSD-60, Olympus, Tokyo, Japan). New types of endoscopes are available for ESD, such as an endoscope with a water jet system (EG-2931, Pentax, Tokyo, Japan, GIF-Q260J, Olympus, Tokyo, Japan), an endoscope with a multi-bending system (M-scope: XGIF-Q240M, R-scope: XGIF-2TQ240R, Olympus, Tokyo, Japan) to facilitate the ESD procedure<sup>[16-19]</sup>. As another approach to successful

ESD, investigations of submucosal injection solutions have been actively done. It was reported that a hyaluronic acid solution makes a better long-lasting submucosal cushion without tissue damage than other available solutions<sup>[7,20-23]</sup>. As a further improvement of hyaluronic acid solution, usefulness of a mixture of high-molecular-weight hyaluronic acid, glycerin, and sugar has also been reported<sup>[24,25]</sup>.

ESD is characterized by three steps: injecting fluid into the submucosa to elevate the lesion from the muscle layer, circumferential cutting of the surrounding mucosa of the lesion, and subsequent dissection of the connective tissue of the submucosa beneath the lesion. Major advantages of this technique in comparison with polypectomy or EMR are as follows. The resected size and shape can be controlled, en bloc resection is possible even in a large neoplasm, and neoplasms with submucosal fibrosis are also resectable. So this technique can be applied to the resection of complex neoplasms such as large neoplasms, ulcerative non-lifting neoplasms, and recurrent neoplasms. The disadvantages of this technique are the requirement of two or more assistants, it is time-consuming, there is a higher risk of bleeding and perforation than EMR. In Japan, ESD is now gaining acceptance as the standard endoscopic resection technique for stomach neoplasms in an early stage, especially for large or ulcerative neoplasms. Recently, the ESD technique is applied to esophageal or colorectal neoplasms in some institutions, although it is still controversial considering the technical difficulty, associated risks, and favorable outcomes by EMR.

## INDICATION FOR ENDOSCOPIC RESECTION

### **Gastric cancer**

Early gastric cancer (EGC) is defined to a mucosal or submucosal invasive cancer (T1 cancer) irrespective of the presence of lymph node metastasis. Lesions indicated for ER should be EGC with no risk of nodal metastasis and that can be resected in a single fragment. Using a large database of more than 5000 EGC patients who underwent gastrectomy with D2 lymph node dissection, a criteria of node negative cancer has been defined<sup>[26]</sup>. At present, lesions with preoperative endoscopic diagnosis of differentiated type intramucosal cancer without ulcer findings, differentiated type intramucosal cancer no larger than 3 cm in diameter with ulcer findings, differentiated type minute invasive submucosal (less than 500 micrometers below muscularis mucosa) cancer no larger than 3 cm in diameter are considered as expanding indication for ER<sup>[27]</sup>. Undifferentiated type cancer lesions are often difficult to delineate its margin, and preoperative diagnosis of ulcerative findings is difficult, so that ER for these lesions should be carefully considered.

### **Esophageal cancer**

Early esophageal cancer (EEC) involving the epithelium (m1: carcinoma in situ) or the lamina propria (m2) are candidates for ER because no lymph node metastasis have been reported in cancers limited to these two layers<sup>[28]</sup>. For EEC invading the muscularis mucosa (m3), the lymph

node metastasis rate is reported as 9%, and for cancer with minute submucosal invasion (< 200 micrometers below the muscularis mucosa; sm1) the rate is 19%<sup>[29]</sup>. The lymph node metastasis rate of m3 or sm1 cancer without lymphovascular infiltration of the tumor is reported as 4.7%<sup>[29]</sup>. Therefore, for patients unwilling for esophagectomy or patients with comorbid diseases not suited for surgery, ER may be a relative indication for m3 or sm1 cancer. Also, for lesions spreading more than three-quarter of circumference of the esophagus are considered as relative indication for ER because post-operative stricture occurs in a high rate.

### **Colorectal cancer**

Early colorectal cancer (ECC) limited to the mucosa or with slight submucosal invasion (< 1000 micrometers below the muscularis mucosa; sm1) are candidates for ER<sup>[30]</sup>. However, even for lesions that meet the criteria above, laparoscopic or open surgery may be selected in some institutions considering the location and size of the lesion. In institutions actively performing ESD for colorectal lesions, depressed lesions and laterally spreading tumors of non-granular type (LST-NG) are considered as good candidates for ESD because these lesions have a high possibility of submucosal invasion which may be difficult to diagnose preoperatively, and a thorough histopathological assessment of the resected specimen is essential.

### **Preoperative evaluation for candidates of ER**

Endoscopy with chromoendoscopy is essential to define the lesion. To evaluate the depth of the lesion, size, redness, presence or absence of ulceration, superficial structure of the lesion, and deformity of the wall of the organ in compliance with air-flow rate are carefully observed by endoscopy and chromoendoscopy. Magnification endoscopy with narrow band imaging technique (NBI) has been reported as a promising new modality to evaluate the depth of ECC. Magnification endoscopy with NBI is also useful to distinguish the border of EGC in case of lack of utility of chromoendoscopy with indigocarmine. Magnification endoscopy with crystal violet staining or NBI is useful in estimating the depth of colorectal lesions. Endoscopic ultrasonography is often performed to evaluate the depth of invasion, and computed tomography may be performed to detect lymph node metastasis if any, if the diagnosis of node negative cancer is difficult to judge even with multiple diagnostic modalities.

### **Pathological evaluation of the removed specimen**

Whether a lesion may be included into the criteria of node-negative neoplasms is considered before treatment. However, at present, it is impossible to make a definite diagnosis of a neoplasm regarding depth, histological type and lymphatic vessel invasion before treatment. It is often experienced that although a biopsy specimen shows adenoma/dysplasia of a lesion, a diagnosis of cancer is made after total resection of the lesion. Therefore, a precise pathological evaluation of the resected specimen is essential, and an en bloc resection of the lesion is desirable in this respect.

After removal, the specimen should be oriented immediately before it is immersed in formalin. Orientation of the specimen is accomplished by fixing the periphery with thin needles on a plate of rubber or wood. The submucosal side of the specimen is faced to the plate. After fixation, the specimen is sectioned serially at 2 mm intervals parallel to a line that includes the closest part between the margin of the specimen and of the neoplasm, so that both lateral and vertical margins are assessed. The depth of invasion is then evaluated microscopically along with the degree of differentiation and lymphovascular infiltration, if any.

In result of thorough pathological assessment, if the lesion is resected en bloc with negative margins of neoplasm and fulfills the criteria of node-negative neoplasms with no lymphovascular infiltration, the treatment is judged as curative resection. For lesions with piecemeal resection but being judged as node-negative neoplasms, or lesions with histologically non-evaluable areas due to artifact or tissue burning, a periodical endoscopic follow-up should be performed to detect residual neoplasm or local recurrence. On the other hand, for lesions that do not fulfill the criteria of node-negative neoplasms, additional surgery with nodal dissection should be strongly recommended.

## OUTCOMES OF ESD

### En bloc resection rate

Recent results of en bloc resection rate and local recurrence of ESD for neoplasms in the stomach, esophagus and colorectum are described in Table 1. For gastric neoplasms larger than 20 mm, en bloc resection rate is extremely low among conventional EMR methods, and local recurrence rates are around 10%<sup>[31]</sup>. Although ESD was considered as a difficult and complicated technique when it was first described in the stomach, after maturity of the techniques of ESD, en bloc resection rates became greater than 90%, regardless of size, and local recurrence rates became almost zero. Technical feasibility and favorable results of ESD have also been reported in recurrent neoplasms<sup>[32-34]</sup>, neoplasms of the esophago-gastric junction<sup>[35]</sup>, and duodenal neoplasms although the number of cases is small. Few reports of ESD for resection of subepithelial tumors have also been published<sup>[36]</sup>.

### Complication

Complications of ESD include pain, bleeding, perforation, and stricture. Pain after ESD is often mild and lasts one or two days after the procedure although the frequency is low. Patients of esophageal ESD are more likely to develop pain than gastric or colorectal ESD.

Complications of post-operative bleeding and perforation among various ESD methods in the stomach, esophagus and colorectum are described in Table 2. Bleeding is more frequent in the stomach cases, whereas perforation is more frequent in the colorectal cases. To prevent post-procedural bleeding, hemostasis of appearing vessels on the artificial ulcer after removing the specimen is essential. Hemostasis is performed by hemostatic forceps (HDB2422/HDB2418, Pentax), coagrasper (FD-410LR,

Table 1 Recent outcomes of various endoscopic submucosal dissection methods for stomach, esophagus and colorectum

Site	Author	Year	Method	En bloc resection rate (%)	Local recurrence rate (%)	
Stomach	Yamamoto <sup>[55]</sup>	2002	EMRSH	76 (53/70)	3 (2/67)	
	Ishigooka <sup>[56]</sup>	2004	s-ERHSE	79 (27/34)	0 (0/34)	
	Oda <sup>[57]</sup>	2005	ESD-IT knife	93 <sup>1</sup> (957/1033)	-	
	Kakushima <sup>[58]</sup>	2006	ESD-Flex knife	91 <sup>1</sup> (347/383)	-	
	Imagawa <sup>[58]</sup>	2006	ESD-Flex knife	84 <sup>1</sup> (181/195)	0 (0/164)	
	Oyama <sup>[59]</sup>	2006	ESD-Hook knife	94 (104/111)	0 (0/111)	
	Onozato <sup>[60]</sup>	2006	ESD-Flex knife	94 <sup>1</sup> (161/171)	0 (0/99)	
	Hirasaki <sup>[61]</sup>	2007	ESD-IT knife	96	-	
	Esophagus	Oyama <sup>[61]</sup>	2005	ESD-Hook knife	95 (95/102)	0 (0/102)
		Fujishiro <sup>[11]</sup>	2006	ESD-Flex knife	100 (58/58)	2.5 (1/40)
Colorectum		Fujishiro <sup>[39]</sup>	2007	ESD-Flex knife	91.5 (183/200)	1.8 (2/111)
	Saito <sup>[62]</sup>	2007	ESD several knives	84 (168/200)	0.5 (1/180)	
	Tanaka <sup>[63]</sup>	2007	ESD several knives	80 (56/70)	0 (0/62)	
	Tamegai <sup>[64]</sup>	2007	ESD-Hook knife	98.6 (33/42)	11 (4/36)	
	Onozato <sup>[66]</sup>	2007	ESD-Flex knife	77 (27/35)	0 (0/23)	

<sup>1</sup>En bloc resection + R0 resection rate

Olympus), hot biopsy forceps, argon plasma coagulation or endoclips. According to perforation, recent case series suggest that small perforation immediately recognized can be successfully sealed with endoclips and treated conservatively by nasogastric suction, fasting and antibiotics without emergency laparotomy<sup>[37,38]</sup>. However, there are rare cases of delayed perforation, which requires surgical rescue. Delayed perforation may occur in the esophagus, stomach, duodenum and colorectum<sup>[39-43]</sup>, mostly at two or more days after a successful ESD. The reason for delayed perforation is unknown, however patients with uncontrolled diabetes mellitus, patients on permanent hemodialysis, lesions located on surgical anastomosis, and too much coagulation are considered as possible risk factors.

Stricture after ESD may occur in esophageal ESD when the ESD ulcer is larger than two-third of circumference of the esophageal lumen, or in gastric ESD when the ESD ulcer involves more than three quarter of the pylorus or pre-pylorus area. In these cases, early intervention to avoid passage obstruction is required. Dilation using bougie or balloon are often applied one week after ESD and repeated several times until healing of the ESD ulcer<sup>[8,11,44]</sup>.

## MANAGEMENTS AFTER ESD

In Japan, ESD is performed on hospitalized patients. After ESD, eating is usually started on the next or 2 days after ESD if there is no complication, and the patient

**Table 2** Bleeding and perforation rate of various endoscopic submucosal dissection methods for stomach, esophagus and colorectum

Site	Author	Year	Method	Total cases	Bleeding (%)	Perforation (%)	
Stomach	Yamamoto <sup>[55]</sup>	2002	EMRSH	70	4	0	
	Ishigooka <sup>[56]</sup>	2004	s-ERHSE	34	0	12	
	Oda <sup>[57]</sup>	2005	ESD-IT knife	1033	6	4	
	Kakushima <sup>[53]</sup>	2006	ESD-Flex knife	383	3.4	3.9	
	Imagawa <sup>[58]</sup>	2006	ESD-Flex knife	159	0	6.1	
	Oyama <sup>[59]</sup>	2006	ESD-Hook knife	111	-	1	
	Onozato <sup>[60]</sup>	2006	ESD-Flex knife	171	7.6	3.5	
	Hirasaki <sup>[61]</sup>	2007	ESD-IT knife	112	4	1	
	Esophagus	Oyama <sup>[9]</sup>	2005	ESD-Hook knife	102	-	0
		Fujishiro <sup>[11]</sup>	2006	ESD-Flex knife	58	0	6.9
Colorectum	Fujishiro <sup>[9]</sup>	2007	ESD-Flex knife	200	1	6	
	Saito <sup>[62]</sup>	2007	ESD-several knives	200	2	5	
	Tanaka <sup>[63]</sup>	2007	ESD-several knives	70	1.4	10	
	Tamegai <sup>[64]</sup>	2007	ESD-Hook knife	74	-	1.4	
	Hurlstone <sup>[65]</sup>	2007	ESD-Flex knife	42	12	2.4	
	Onozato <sup>[66]</sup>	2007	ESD-Flex knife	35	0	2.9	

may be discharged within a few days. Antacids are usually administered to gastric and esophageal ESD patients to relieve pain, prevent postoperative bleeding and promote ulcer healing. A recent study showed that proton pump inhibitors more effectively prevented bleeding from the gastric ulcer created after ESD than did H2-receptor antagonists<sup>[45]</sup>. Ulcers after ESD are reported to heal within 6 to 8 wk in the esophagus, stomach and colorectum<sup>[46-50]</sup>.

Endoscopic surveillance should be carried out in patients after ESD not only to detect local recurrence but also metachronous cancer especially in the esophagus and stomach. A recent study showed that the average time to detect a first metachronous gastric cancer (MGC) was  $3.1 \pm 1.7$  years after EMR/ESD, and the cumulative 3-yr incidence was 5.9%<sup>[51]</sup>. In order to detect MGC at an early stage to perform a successful ER, annual endoscopic surveillance program may be practical for post-ER patients.

## LONG-TERM OUTCOMES AFTER ESD

Long-term outcomes after ESD for gastric cancers within the expanded indication are currently under investigation. Survival data is still lacking in the literature, however in the 2007 annual meeting of Japanese gastroenterological endoscopy society (JGES), a symposium was held upon long-term outcomes after gastric and esophageal ESD. For gastric ESD, 3-yr disease free survival rate was reported as 90%-92%, local recurrence rate was reported as 0.8%-12%. For lesions within the criteria of node negative cancers, there were no reports of distant metastasis. Metachronous gastric cancer detection rate during follow-up was reported as 3.4%-10.2%. In comparison, long-term outcomes after EMR for small differentiated mucosal EGC less than 20 mm in diameter have been reported as comparable to those after gastrectomy. The disease-specific 5- and 10-yr survival rates were 99% and 99%<sup>[52]</sup>. For esophageal ESD, in the 2007 JGES meeting, 3-yr survival rate for m1-2 cancer and m3-sm1 cancer were 95.1% and 86.7%, respectively. According to colorectal ESD, there is still no long-term data at present.

## FUTURE PERSPECTIVES

With the development of ESD, more than half of GI cancers in the early stage are removed by ER in advanced institutions in Japan. En bloc retrieval of lesions is essential for detailed histopathologic studies, which form the basis for stratification of treatment outcomes and patient's prognosis. ESD theoretically offers greater histopathological accuracy than conventional EMR methods or piecemeal resection. However, ESD requires highly skilled endoscopists, and a suitable training program is demanded for permeation of this technique. For trainees starting ESD, skills of routine endoscopy and colonoscopy, target biopsy, endoscopic hemostasis techniques and simple EMR techniques should be required. A trainee would gain early proficiency of ESD after 30 cases under supervision of a mentor<sup>[53,54]</sup>. On the other hand, serious complications such as delayed perforation have been reported, and a thorough patient care before and after ESD is essential. At present, selection of a lesion within the criteria for ER, selection of the patient with adequate general function should be well considered. It is important to share the information and experience among endoscopists to skill up and avoid serious complications. The ESD technique is still not a treatment at ease, and further refinements of the technique is required to popularize ESD as a safe and reliable, less invasive treatment for patients with GI neoplasms.

## REFERENCES

- Hirao M, Masuda K, Asanuma T, Naka H, Noda K, Matsuura K, Yamaguchi O, Ueda N. Endoscopic resection of early gastric cancer and other tumors with local injection of hypertonic saline-epinephrine. *Gastrointest Endosc* 1988; **34**: 264-269
- Ono H, Kondo H, Gotoda T, Shirao K, Yamaguchi H, Saito D, Hosokawa K, Shimoda T, Yoshida S. Endoscopic mucosal resection for treatment of early gastric cancer. *Gut* 2001; **48**: 225-229
- Ohkuwa M, Hosokawa K, Boku N, Ohtu A, Tajiri H, Yoshida S. New endoscopic treatment for intramucosal gastric tumors using an insulated-tip diathermic knife. *Endoscopy* 2001; **33**: 221-226