

Table 5 Median survival duration of defined patient populations with CUP

Variable	No. of Patients	Median survival (days)	p-value
Sex			
Female	9	712	0.2599
Male	19	186	
No. of organ sites			
1	12	709	0.1180
2-6	16	108	
Performance status			
0-1	17	673	0.0413
2-3	11	79	
Involved organ sites			
Lymph nodes			0.0310
+	18	673	
-	10	148	
Liver			0.0002
+	6	50	
-	22	673	
Bone			0.0380
+	10	108	
-	18	673	
Lung			0.0642
+	7	67	
-	21	604	
Pleura/pleural space			0.0040
+	4	31	
-	24	604	
Brain			0.3704
+	1	108	
-	27	306	
Peritoneum			0.1458
+	4	67	
-	24	306	
Adrenal			0.6633
+	2	33	
-	26	249	
Skin			0.1820
+	3	51	
-	25	306	
Therapy			
CDDP/TXT	16	681	<0.0001
Other	12	73	
Histology			
Adenocarcinoma	13	673	
Poorly differentiated carcinoma	9	306	
Squamous cell carcinoma	2	33	
Unknown or others	4	67	

Clinical subsets of patients who are sensitive to platinum-containing treatment have been identified in the last 2 decades [2]. In this study, one patient almost fit into a favorable subset. She was a 73-year-old woman with peritoneal adenocarcinoma, but no papillary serous carcinoma, so she did not completely conform to a favorable subset. She was given three courses of CDDP/TXT, attained good PR, and was still alive at the 23.6-month follow-up. Therefore, although no patients completely matched the subgroups with a favorable prognosis, the CDDP/TXT regimen in this study was found to be very beneficial.

We also analyzed the course and prognostic factors of the patients with CUP. Univariate analysis identified 4 factors predicting a poor prognosis: performance status 2-4, liver involvement, bone involvement, and pleural involvement. The one favorable prognostic factor was lymph node involvement. Abbruzzese *et al.* examined prognostic factors in 657 consecutive patients and found that male sex, increased numbers of involved organ sites, adenocarcinoma histology, and hepatic involvement were negative prognostic factors in a multivariate analysis [16]. They also reported that lymph node involvement,

peritoneal involvement, and neuroendocrine histology are favorable prognostic factors [16]. Our results confirm the reported analyses; *i.e.*, visceral metastasis, multiple metastatic sites, and poor performance status may predict shorter survival.

Recently, a new combination of chemotherapy has been reported that includes gemcitabine, etoposide, or irinotecan combined with platinum plus taxane; these studies have shown similar response and survival rates [17, 18]. New agents such as vascular endothelial growth factor (VEGF) inhibitors and epidermal growth factor receptor (EGFR) inhibitors are being tested to improve the prognosis of CUP. Hainsworth *et al.* have reported that bevacizumab plus erlotinib therapy has a response rate of 10%, leading to stable disease in 61%, a median OS of 7.4 months, and a 1-year OS of 33% [19]. Therapeutic trials involving platinum and taxane plus VEGF or EGFR inhibitors should be conducted to improve the survival of patients with CUP.

In conclusion, although this was a retrospective study, we observed an excellent response rate and survival with CDDP/TXT chemotherapy in Japanese patients with CUP, despite their being in unfavorable subgroups. Our results show that bone, liver, and pleural metastasis, and poor performance status may predict a shorter survival.

References

- Pavlidis N, Briasoulis E, Hainsworth J and Greco FA: Diagnostic and therapeutic management of cancer of an unknown primary. *Eur J Cancer* (2003) 39: 1990-2005.
- Briasoulis E, Kalofonos H, Bafaloukos D, Samantas E, Fountzilas G, Xiros N, Skarlos D, Christodoulou C, Kosmidis P and Pavlidis N: Carboplatin plus paclitaxel in unknown primary carcinoma: A phase II hellenic cooperative oncology group study. *J Clin Oncol* (2000) 18: 3101-3107.
- Culine S, Lortholary A, Voigt JJ, Bugat R, Theodore C, Priou F, Kaminsky MC, Lesimple T, Pivot X, Coudert B, Douillard JY, Merrouche Y, Allouache J, Goupil A, Negrier S, Viala J, Petrow P, Bouzy J, Laplanche A and Fizazi K: Cisplatin in combination with either gemcitabine or irinotecan in carcinomas of unknown primary site: Results of a randomized phase II study--trial for the French Study Group on Carcinomas of Unknown Primary (gefcapi 01). *J Clin Oncol* (2003) 21: 3479-3482.
- Guardiola E, Pivot X, Tchicknavorian X, Magne N, Otto J, Thyss A and Schneider M: Combination of cisplatin-doxorubicin-cyclophosphamide in adenocarcinoma of unknown primary site: A phase II trial. *Am J Clin Oncol* (2001) 24: 372-375.
- Mukai H, Watanabe T, Ando M and Katsumata N: Unknown primary carcinoma: A feasibility assessment of combination chemotherapy with cisplatin and docetaxel. *Int J Clin Oncol* (2003) 8: 23-25.
- Greco FA, Erland JB, Morrissey LH, Burris HA 3rd, Hermann RC, Steis R, Thompson D, Gray J and Hainsworth JD: Carcinoma of unknown primary site: Phase II trials with docetaxel plus cisplatin or carboplatin. *Ann Oncol* (2000) 11: 211-215.
- Miller AB, Hoogstraten B, Staquet M and Winkler A: Reporting results of cancer treatment. *Cancer* (1981) 47: 207-214.
- Trotti A, Colevas AD, Setser A, Rusch V, Jaques D, Budach V, Langer C, Murphy B, Cumberlin R, Coleman CN and Rubin P: CTCAE v3.0: Development of a comprehensive grading system for the adverse effects of cancer treatment. *Semin Radiat Oncol* (2003) 13: 176-181.
- Kaplan D: Pseudocyst of the pancreas. *Am J Surg* (1958) 95: 160-162.
- Mantel N: Evaluation of survival data and two new rank order statistics arising in its consideration. *Cancer Chemother Rep* (1966) 50: 163-170.
- Oken MM, Creech RH, Tormey DC, Horton J, Davis TE, McFadden ET and Carbone PP: Toxicity and response criteria of the eastern cooperative oncology group. *Am J Clin Oncol* (1982) 5: 649-655.
- Park YH, Ryoo BY, Choi SJ, Yang SH and Kim HT: A phase II study of paclitaxel plus cisplatin chemotherapy in an unfavorable group of patients with cancer of unknown primary site. *Jpn J Clin Oncol* (2004) 34: 681-685.
- Yakushiji S, Ando M, Yonemori K, Kohno T, Shimizu C, Katsumata N and Fujiwara Y: Cancer of unknown primary site: Review of consecutive cases at the national cancer center hospital of japan. *Int J Clin Oncol* (2006) 11: 421-425.
- Yokoyama Y, Shigeto T, Futagami M and Mizunuma H: Syndrome of inappropriate secretion of anti-diuretic hormone following carboplatin-paclitaxel administration in a patient with recurrent ovarian cancer. *Eur J Gynaecol Oncol* (2005) 26: 531-532.
- Kagawa K, Fujitaka K, Isobe T, Yamasaki M, Miyazaki M, Oguri T and Kohno N: Syndrome of inappropriate secretion of ADH (SIADH) following cisplatin administration in a pulmonary adenocarcinoma patient with a malignant pleural effusion. *Intern Med* (2001) 40: 1020-1023.
- Abbruzzese JL, Abbruzzese MC, Hess KR, Raber MN, Lenzi R and Frost P: Unknown primary carcinoma: Natural history and prognostic factors in 657 consecutive patients. *J Clin Oncol* (1994) 12: 1272-1280.
- Hainsworth JD, Erland JB, Kalman LA, Schreeder MT and Greco FA: Carcinoma of unknown primary site: Treatment with 1-hour paclitaxel, carboplatin, and extended-schedule etoposide. *J Clin Oncol* (1997) 15: 2385-2393.
- Greco FA, Burris HA 3rd, Litchy S, Barton JH, Bradof JE, Richards P, Scullin DC Jr, Erland JB, Morrissey LH and Hainsworth JD: Gemcitabine, carboplatin, and paclitaxel for patients with carcinoma of unknown primary site: A minnie pearl cancer research network study. *J Clin Oncol* (2002) 20: 1651-1656.
- Hainsworth JD, Spigel DR, Farley C, Thompson DS, Shipley DL and Greco FA: Phase II trial of bevacizumab and erlotinib in carcinomas of unknown primary site: The minnie pearl cancer research network. *J Clin Oncol* (2007) 25: 1747-1752.

Combination of morphological feature analysis and immunohistochemistry is useful for screening of EML4-ALK-positive lung adenocarcinoma

Ryu Jokoji,¹ Takashi Yamasaki,¹ Seigo Minami,² Kiyoshi Komuta,² Yasushi Sakamaki,³ Kengo Takeuchi,⁴ Masahiko Tsujimoto¹

¹Department of Pathology, Osaka Police Hospital, Tennouji-ku, Osaka, Japan

²Department of Respiratory Medicine, Osaka Police Hospital, Tennouji-ku, Osaka, Japan

³Department of Chest Surgery, Osaka Police Hospital, Tennouji-ku, Osaka, Japan

⁴Division of Pathology, The Cancer Institute, Japanese Foundation for Cancer Research, Ariake, Koto-ku, Tokyo, Japan

Correspondence to Masahiko Tsujimoto, Department of Pathology, Osaka Police Hospital, 10-31 Kitayama-cho, Tennouji-ku, Osaka 543-0035, Japan; patho@oph.gr.jp

Accepted 27 August 2010
Published Online First
9 October 2010

ABSTRACT

Background A subset of lung cancers harbours the fusion gene echinoderm microtubule-associated protein-like-4—anaplastic lymphoma kinase (EML4-ALK).

Recently, immunohistochemistry for ALK has shown sensitivity for the detection of EML4-ALK-positive lung adenocarcinoma almost equal to that of the fluorescence in situ hybridisation (FISH) assay.

Aims To study the clinicopathological features of EML4-ALK-positive lung adenocarcinoma in a large number of surgically resected samples using immunohistochemistry, in order to establish a useful screening method for EML4-ALK-positive lung adenocarcinoma.

Methods Immunohistochemistry for ALK was used to screen for EML4-ALK-positive lung adenocarcinomas in 254 cases of surgically resected samples.

Results EML4-ALK-positive cases were detected in 3.1% of lung adenocarcinomas (8/254). EML4-ALK-positive lung adenocarcinomas showed significant associations with intra- and/or extra-cytoplasmic mucin ($p=0.0001$), and cribriform pattern with excessive extracytoplasmic mucin ($p<0.0001$). Signet-ring cell appearance alone lacked significance ($p=0.149$).

Conclusion EML4-ALK-positive lung adenocarcinoma has a tendency to express a characteristic morphological pattern. The combined use of morphological feature analysis and immunohistochemistry may be a useful and cost effective screening method for EML4-ALK lung adenocarcinoma.

INTRODUCTION

Lung cancer is the major cause of cancer-related deaths in the world. It is known that some gene mutations are involved in carcinogenesis of the lung. Epidermal growth factor receptor (EGFR) is an example of a gene mutation in lung cancer. Activation of the mutation in EGFR defines a group of patients with sensitivity to the chemical inhibitor for the kinase activity of EGFR, accounting for about 10% of primary lung cancers.^{1,2} In 2007, Soda *et al* identified the fusion oncogene joining the echinoderm microtubule-associated protein-like-4 (EML4) and the anaplastic lymphoma kinase gene (ALK) in non-small-cell lung cancer (NSCLC).³ The detection of EML4-ALK-positive lung cancer is needed to identify lung cancer patients for molecular target therapy. Some authors recommend molecular cascade screening for the detection of EML4-ALK-positive lung cancer.⁴ The cascade is a stepwise approach to test for gene mutations in lung adenocarcinoma: first for KRAS, second for

EGFR, and third for EML4-ALK translocation. However, it is an expensive and time-consuming method. Moreover, EML4-ALK-positive lung cancer accounts for only about 5% of all NSCLC patients according to previous reports.^{5–8} To find a more efficient screening method for EML4-ALK-positive lung cancer, more precise clinical features and histopathological findings of EML4-ALK-positive lung cancer must be determined.

A previous report showed that EML4-ALK-positive lung cancers are characterised by smaller tumour size, and found in younger patients who are non-smokers or light smokers.⁶ Another study reported that EML4-ALK-positive lung cancer showed acinar morphology⁹ and signet-ring cell appearance.^{5,10}

Recently, immunohistochemistry for ALK has shown sensitivity for the detection of EML4-ALK-positive lung adenocarcinoma almost equal to that of the fluorescence in situ hybridisation (FISH) assay.¹¹ In this study, the clinicopathological features of EML4-ALK-positive lung adenocarcinoma were studied in a large number of surgically resected samples using immunohistochemistry, in order to establish a useful screening method for EML4-ALK-positive lung adenocarcinoma.

MATERIALS AND METHODS

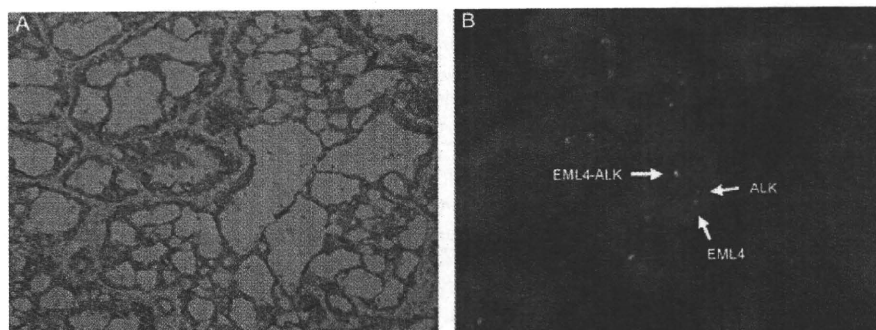
Patients and sample collection

This study included samples from 254 Japanese NSCLC patients with a diagnosis of lung adenocarcinoma who underwent surgery at Osaka Police Hospital (Osaka, Japan) between January 2000 and December 2009. Clinical data were collected from inpatient and outpatient medical records.

Histological analysis

All surgically resected lung tumour specimens were embedded in paraffin and serial 5 μ m thick sections were prepared. The pathological examination was based on standard H&E stained slides from all blocks of tissues. Pathological stage and differentiation were evaluated according to the current international tumour node metastasis (TNM) staging system and the World Health Organization classification. All tumour slides (consisting in each case of 1–25 slides, with a mean of six slides) were reviewed, and classified according to WHO histological types. In this study, bronchioloalveolar carcinoma is a pure type of carcinoma without invasion. The mixed subtypes category contained varied lesions. Therefore, in this study, an

Figure 1 (A) Anaplastic lymphoma kinase (ALK) protein was expressed in the cytoplasm with no nuclear staining. (B) Fluorescence in situ hybridisation assay of echinoderm microtubule-associated protein-like-4–ALK.



additional predominance classification was used, as described in a previous report.⁶ Regardless of percentage, the most dominant subtype was regarded as the predominant subtype. The remaining subtypes were regarded as minor components.

Three pathologists (R, TY, MT) reviewed all tumour slides of all cases. The decision on discrepant cases was made by consensus when two of the three pathologists agreed. All discrepant cases (10 cases) resulted in consensus.

Immunohistochemical analysis

Unstained paraffin-embedded sections were deparaffinised in xylene, hydrated through and rinsed in distilled water. Heat-

Table 1 Clinicopathological comparison between echinoderm microtubule-associated protein-like-4–anaplastic lymphoma kinase (EML4-ALK)-positive and -negative lung adenocarcinoma

		EML4-ALK (+) (n=8)	EML4-ALK (-) (n=246)	p Value
Age	Mean±SD	61.75±11.41	66.55±9.246	0.1524*
	Median	65.5	67.5	
	Range	44–77	42–87	
Sex	Male	4	126	1‡
	Female	4	120	
Smoking habit	Never smoker	2	49	0.114‡
	Ever smoker	5	79	
	Unknown	1	118	
Tumour size (mm)	Mean±SD	25.88±10.3	23.58±11.65	0.581*
	Median	26.5	21	
	Range	10–45	5–75	
Differentiation	Well (G1)	0	132	0.0025‡
	Less (G2, G3)	8	114	(G1 vs G2, G3)
Tumour status	pT1	6	169	1‡ (pT1 vs T2-4)
	pT2–pT4	2	77	
Lymph node metastasis	pN0	4	193	0.0782‡
	pN1–3	4	53	(pN0 vs pN1-3)
TNM stage	pStage I	4	175	0.2403‡
	pStage II–IV	4	71	(pStage I vs pStage II–IV)
EGFR mutation (n=67)	(+)	0	33	
	(-)	8	26	

*Student's t test b.

‡ χ^2 test.

‡Fisher's exact test.

EGFR, epidermal growth factor receptor.

induced epitope retrieval was performed with EnVision FLEX Target Retrieval Solution, High pH (Dako, Carpinteria, California, USA). Slides were then incubated at room temperature with antibody to ALK (clone 5A4, 1:100, Abcam) for 30 min. To increase the sensitivity of detection, the intercalated antibody-enhanced polymer (iAEP) method was used with minor modifications.¹² Slides were incubated at room temperature with EnVision FLEX+ Mouse Linker (Dako) for 15 min. The immune complexes were then detected with the dextran polymer reagent.

FISH assay

FISH was performed on formalin-fixed paraffin-embedded tumour tissues with use of fluorescently-labelled bacterial artificial chromosome clone probes specific to the ALK and the EML4 loci (EML4 RP11-996L7; ALK RP11-984I21, RP11-62B19) using a histology FISH accessory kit (Dako).

DNA extraction and mutation analysis of EGFR, KRAS

Because no fresh sample was available for this study, DNA was extracted from formalin-fixed paraffin-embedded tissues; mutations in the EGFR (exons 18–21) genes were analysed by the peptide nucleic acid locked nucleic acid PCR-clamp (PNA LNA PCR-clamp) technique¹³ and in the KRAS (codons 12,13) genes by direct sequencing.¹⁴ Mutation analysis was performed on 67 cases, for which informed consent was obtained from patients. The ethics committee of our institute approved the genetic analyses in the present study.

Statistical analysis

Statistical analysis for the tumour size and age was carried out using Student's t test. The values are shown as mean ± SD. The relationship between EML4-ALK expression and clinicopathological variables was analysed with the χ^2 test or Fisher's exact test. Statistical significance was defined as $p < 0.05$.

RESULTS

Clinical presentation

Using immunohistochemistry for ALK, the expression of ALK was studied in 254 lung adenocarcinomas. Eight of 254 cases showed homogeneous ALK protein in the cytoplasm without nuclear staining. The percentage of positive tumour cells ranged from 80% to 100%. Varied intensity of ALK expression was observed. The FISH assay confirmed the presence of the EML4-ALK fusion gene in the eight cases that showed the ALK protein (figure 1).

Table 1 summarises details of the clinicopathological features of all cases. All patients were Japanese, ranging in age from 42 to 87 years, with a mean age of 66.4 years. The maximum diameter of their tumours ranged from 0.5 to 7.5 cm. EML4-ALK-positive

Original article

lung adenocarcinomas were significantly less differentiated than the EML4-ALK-negative lung adenocarcinomas ($p=0.0025$). EML4-ALK-positive and EML4-ALK-negative lung adenocarcinomas showed no difference in age, sex, tumour size, smoking habit and TNM stage. However, EML4-ALK-positive lung adenocarcinomas showed a tendency for association with younger patients, positive lymph nodes, adverse pathological stage and smoking habit. All of the EML4-ALK-positive cases had no mutation of the EGFR and KRAS genes.

Pathological findings and immunohistochemistry

Histologically, the 254 adenocarcinomas were comprised of 153 mixed subtypes, 34 acinar, 30 papillary, 2 others and 35 bronchioloalveolar carcinomas based on the WHO classification. The mixed subtypes category contained varied lesions. Therefore an additional predominance classification was used, as described in a previous report.⁶ According to the predominance subtyping, the 254 adenocarcinomas were comprised of 85 acinar, 83 papillary, 74 bronchioloalveolar non-mucinous carcinomas, 7 bronchioloalveolar mucinous carcinomas and 5 others (table 2).

Table 2 also summarises the histological features of all cases. According to the predominance subtypes, six of eight EML4-ALK-positive lung adenocarcinomas (75%) were subclassified as acinar-predominant adenocarcinomas and the other two cases were papillary-predominant adenocarcinomas. When compared with EML4-ALK-negative lung adenocarcinoma, the association of EML4-ALK-positive lung adenocarcinoma and acinar morphology was statistically significant ($p=0.0184$, Fisher's exact test). In other words, six of 85 (7.0%) acinar-predominant adenocarcinomas were positive for EML4-ALK fusion.

Lung adenocarcinoma cells have intracytoplasmic mucin in varying degrees and sometimes have extracytoplasmic mucin. Some lung adenocarcinoma cells show signet-ring cell like appearance because of excessive intracytoplasmic mucin (figure 2). Also, other lung adenocarcinomas show a cribriform

Table 2 Subtypes by predominance classification

	Total	EML4-ALK (+)	EML4-ALK (-)
	254	8 (3.1%)	246
Papillary	83	2	81
Acinar	85	6	79*
Bronchioloalveolar carcinoma, non-mucinous	74	0	74
Bronchioloalveolar carcinoma, mucinous	7	0	7
Others	5	0	5

*Fisher's exact test, $p=0.0184$ (acinar predominant adenocarcinoma vs the other adenocarcinoma).
EML4-ALK, echinoderm microtubule-associated protein-like-4—anaplastic lymphoma kinase.

pattern with excessive extracytoplasmic mucin (figure 3). In the 254 cases examined, 36 had intracytoplasmic or extracytoplasmic mucin detected by Alcian blue stain.

EML4-ALK-positive lung adenocarcinomas showed significant associations with intra- and/or extra-cytoplasmic mucin ($p=0.0001$), and cribriform pattern with excessive extracytoplasmic mucin ($p<0.0001$). Signet-ring cell appearance alone lacked significance ($p=0.149$) (table 3).

Two of eight EML4-ALK-positive cases did not have a characteristic morphological feature, nor did they show any mucin production (tables 4 and 5).

DISCUSSION

A large-scale screening conducted for EML4-ALK-positive lung adenocarcinomas in our institute detected eight cases. In this study, the association of EML4-ALK-positive lung adenocarcinoma and acinar-predominant morphology, extra- and/or intracytoplasmic mucin production and cribriform pattern with excessive extracytoplasmic mucin was demonstrated. A previous report showed that EML4-ALK-positive lung cancers were characterised by smaller tumour size, younger patients and non-smokers or light smokers when compared against

Figure 2 (A) Echinoderm microtubule-associated protein-like-4—anaplastic lymphoma kinase (EML4-ALK)-positive lung adenocarcinoma cells showing signet-ring cell like appearance because of excessive intracytoplasmic mucin. (B) Alcian blue staining showing excessive intracytoplasmic mucin.

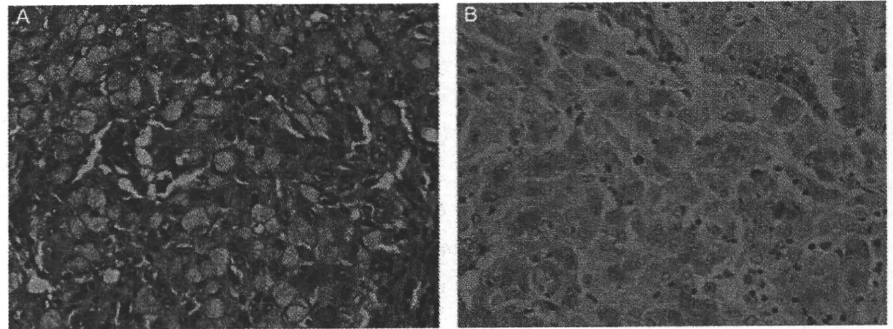


Figure 3 (A) Echinoderm microtubule-associated protein-like-4—anaplastic lymphoma kinase (EML4-ALK)-positive lung adenocarcinoma showing cribriform pattern with excessive extracytoplasmic mucin. (B) Alcian blue staining showing excessive extracytoplasmic mucin.

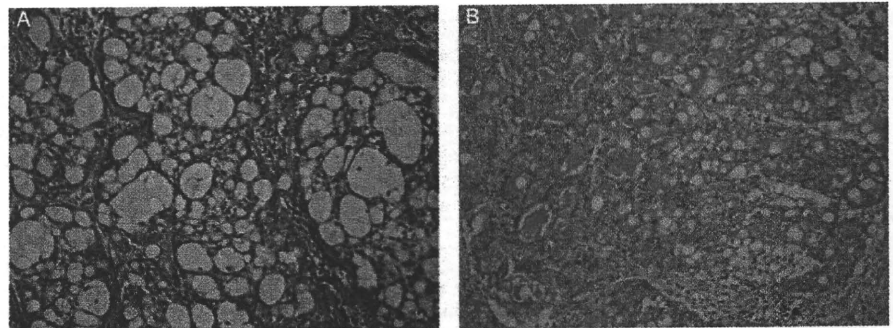


Table 3 Histological feature comparison between echinoderm microtubule-associated protein-like-4—anaplastic lymphoma kinase (EML4-ALK)-positive and -negative lung adenocarcinoma

		EML4-ALK (+)	EML4-ALK (-)	p Value*
Extra- and/or intra-cytoplasmic mucin production	(+)	6	30	0.0001
	(-)	2	216	
Cribriform pattern with extracytoplasmic mucin	(+)	5	8	<0.0001
	(-)	3	238	
Signet-ring cell appearance	(+)	1	4	0.149
	(-)	7	242	

*Fisher's exact test.

EML4-ALK-negative lung cancers.^{5 6 10 15} In this study EML4-ALK-positive lung adenocarcinoma was less differentiated, as described in a previous report.⁶ However, EML4-ALK-positive and -negative lung adenocarcinomas showed no difference in age, sex, tumour size, smoking habit and TNM stage. The screening was limited in this study to lung adenocarcinomas of Japanese patients. Previous reports showed that lung cancers harbouring the EML4-ALK fusion gene were mostly adenocarcinomas with a few exceptions.^{10 15} All EML4-ALK-positive lung adenocarcinomas had no mutation in the EGFR and KRAS genes, which concurred with previous reports.^{6 9 15}

A previous report revealed the association of EML4-ALK fusion and acinar-predominant morphology⁹ and signet-ring cell appearance.^{5 10} In this study, acinar-predominant morphology and cribriform pattern with excessive extracytoplasmic mucin

were useful factors, suggesting the presence of the EML4-ALK fusion gene, but signet-ring cell appearance by itself was not a useful factor. Previous reports revealed an association of EML4-ALK fusion and signet-ring cell appearance. However, the subjects screened were in a Western population or with limited clinical characteristics.^{5 10} There may be an underlying difference in the subject population by race and clinical characteristics. A recent report showed that primary signet-ring cell carcinoma of the lung shares many clinicopathologic characteristics with EML4-ALK-positive lung cancers.¹⁶ In point of fact, one case of EML4-ALK-positive lung adenocarcinoma in our study had signet-ring cell appearance. However, because the population of tumour cells appearing like signet-ring cells was very low, it was not a useful independent factor, suggesting the presence of the EML4-ALK fusion gene. It may however, be a clue in suggesting the presence of the EML4-ALK fusion gene because of excessive mucin production.

Previous reports have shown the utility of immunohistochemistry for EML4-ALK.^{11 12} Our study showed the usefulness of characteristic morphological features in screening for EML4-ALK-positive lung adenocarcinomas. The combined study of typical morphological features of EML4-ALK-positive lung adenocarcinomas by light microscopy followed by immunohistochemical confirmation may enable the screening for EML4-ALK-positive lung adenocarcinomas to be simple and cost effective.

Although light microscopic observations of specific morphological features and immunohistochemistry are very useful, two of our eight EML4-ALK-positive cases did not have characteristic morphological features. The two cases showed acinar-

Table 4 Clinical features of echinoderm microtubule-associated protein-like-4—anaplastic lymphoma kinase (EML4-ALK)-positive lung adenocarcinoma

Case no.	Age (y)	Sex	Smoking habit	Tumour size (mm)*	EGFR mutation	KRAS mutation	Lymph node metastasis	pStage	Prognosis
1	46	F	Never	16	(-)	(-)	Negative	IA	AN (11 mth)
2	64	M	Ever	45	(-)	(-)	Negative	IB	Recurrence at 12 mth alive (23 mth)
3	44	M	Ever	25	(-)	(-)	Positive (pN2)	IIIA	Recurrence at 29 mth alive (42 mth)
4	67	F	Never	28	(-)	(-)	Positive (pN1)	IIA	Recurrence at 20 mth alive (39 mth)
5	60	F	Ever	28	(-)	(-)	Negative	IA	AN (15 mth)
6	77	M	Ever	25	(-)	(-)	Negative	IA	AN (11 mth)
7	67	F	Unknown	10	(-)	(-)	Positive (pN2)	IIIA	DD (12 mth)
8	69	M	Ever	30	(-)	(-)	Positive (pN1)	IIA	DD (43 mth)

*Size is represented by the maximum width of the neoplasm.

AN indicates patient is alive with no evidence of disease; DD, died from disease; acinar, acinar adenocarcinoma; papillary, papillary adenocarcinoma; mixed, adenocarcinoma with mixed subtypes.

pStage, pathological stage; EGFR, epidermal growth factor receptor.

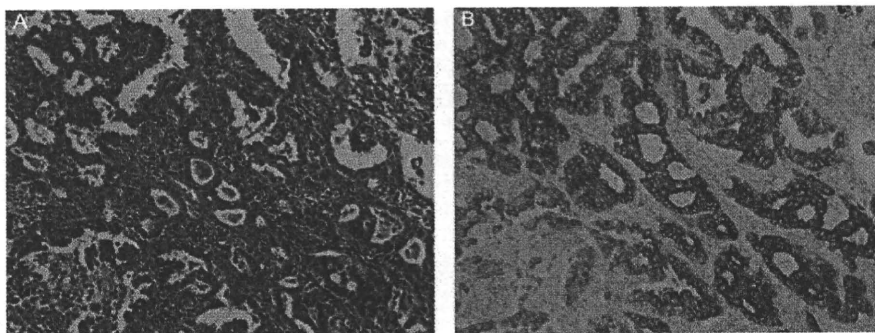
Table 5 Pathological features of echinoderm microtubule-associated protein-like-4—anaplastic lymphoma kinase (EML4-ALK)-positive lung adenocarcinoma

Case no.	WHO subtype	Predominant subtype	Minor component subtypes	ALK positive tumour cells (%)	Mucin production	Cribriform pattern	Signet-ring cell appearance
1	Mixed	Acinar	Papillary	100	(+)	(+)	(-)
2	Mixed	Papillary	Acinar	90	(+)	(+)	(-)
3	Acinar	Acinar	-	100	(+)	(+)	(-)
4	Acinar	Acinar	-	80	(+)	(+)	(-)
5	Mixed	Acinar	Solid	100	(+)	(-)	(+)
6	Mixed	Papillary	BAC, acinar, micropapillary	100	(+)	(+)	(-)
7	Acinar	Acinar	-	100	(-)	(-)	(-)
8	Acinar	Acinar	-	100	(-)	(-)	(-)

Mixed indicates adenocarcinoma with mixed subtypes; acinar, acinar adenocarcinoma; papillary, papillary adenocarcinoma; mixed, adenocarcinoma with mixed subtypes; solid, solid adenocarcinoma with mucin production; BAC, bronchioalveolar carcinoma, non-mucinous; micropapillary, micropapillary carcinoma; mucin production, extra- and/or intra-cytoplasmic mucin production; histological pattern, specific histological pattern; cribriform, cribriform pattern with excessive extracytoplasmic mucin; signet-ring cell, signet-ring cell appearance.

Original article

Figure 4 (A) One echinoderm microtubule-associated protein-like-4—anaplastic lymphoma kinase (EML4-ALK)-positive lung adenocarcinoma showing acinar pattern without mucin production. (B) ALK protein was expressed in the cytoplasm with no nuclear stain.



Take-home messages

- ▶ EML4-ALK-positive lung adenocarcinomas were significantly less differentiated than the EML4-ALK-negative lung adenocarcinomas.
- ▶ EML4-ALK-positive lung adenocarcinomas showed significant associations with intra- and/or extra-cytoplasmic mucin, and cribriform pattern with excessive extracytoplasmic mucin.
- ▶ The combined study of typical morphological features of EML4-ALK-positive lung adenocarcinomas by light microscopy followed by immunohistochemical confirmation may enable the screening for EML4-ALK-positive lung adenocarcinomas to be simple and cost effective.

predominant morphology but no mucin production (figure 4 and table 5). A large-scale, multi-institute study will be needed to offer more insight into EML4-ALK-positive lung adenocarcinomas.

In this study, the FISH assay was performed only on positive cases. Standard methods are not yet established for detection of the EML4-ALK fusion gene in lung cancers. As previous reports showed,^{5 17} both FISH and immunohistochemistry may have false negative results. However, to perform the FISH assay on all screening cases at any institute is a costly undertaking. Immunohistochemistry, on the other hand, has been used widely in the diagnostic laboratory. It is easy to perform and relatively inexpensive. Recently, immunohistochemistry for ALK has shown almost equal sensitivity to that of the FISH assay for the detection of EML4-ALK-positive lung adenocarcinomas.¹¹ In addition, the ALK fusion genes are recently discovered oncogenes in lung cancers. Conceivably, there is an unknown fusion partner of ALK, which cannot be detected by the FISH assay. Therefore, immunohistochemistry appears to be an appropriate screening method in the diagnostic laboratory.

In conclusion, we showed that EML4-ALK-positive lung adenocarcinomas had a tendency for expressing a characteristic morphological pattern. Continued investigations await the validation of the results presented in this study with respect to the potential usefulness of morphological analysis and immunohistochemistry in screening for EML4-ALK lung adenocarcinomas.

Acknowledgements The authors thank Drs Eiichi Morii and Ayumi Furumoto for helpful advice and discussion, and Mr Michihiko Noguchi, Ms Ayumi Tsukiya, Mr Yasuhiro Hashimoto, Ms Kumi Tanaka and Ms Saori Fukuda for technical assistance.

Competing interests None.

Ethics approval This study was conducted with the approval of the ethics committee of Osaka Police Hospital.

Provenance and peer review Not commissioned; externally peer reviewed.

REFERENCES

1. Paez JG, Janne PA, Lee JC, *et al.* EGFR mutations in lung cancer: correlation with clinical response to gefitinib therapy. *Science* 2004;**304**:1497–500.
2. Lynch TJ, Bell DW, Sordella R, *et al.* Activating mutations in the epidermal growth factor receptor underlying responsiveness of non-small-cell lung cancer to gefitinib. *N Engl J Med* 2004;**350**:2129–39.
3. Soda M, Choi YL, Enomoto M, *et al.* Identification of the transforming EML4-ALK fusion gene in non-small-cell lung cancer. *Nature* 2007;**448**:561–6.
4. Horn L, Pao W. EML4-ALK: honing in on a new target in non-small-cell lung cancer. *J Clin Oncol* 2009;**27**:4232–5.
5. Rodig SJ, Mino-Kenudson M, Dacic S, *et al.* Unique clinicopathologic features characterize ALK-rearranged lung adenocarcinoma in the western population. *Clin Cancer Res* 2009;**15**:5216–23.
6. Inamura K, Takeuchi K, Togashi Y, *et al.* EML4-ALK lung cancers are characterized by rare other mutations, a TTF-1 cell lineage, an acinar histology, and young onset. *Mod Pathol* 2009;**22**:508–15.
7. Takeuchi K, Choi YL, Soda M, *et al.* Multiplex reverse transcription-PCR screening for EML4-ALK fusion transcripts. *Clin Cancer Res* 2008;**14**:6618–24.
8. Rikova K, Guo A, Zeng Q, *et al.* Global survey of phosphotyrosine signaling identifies oncogenic kinases in lung cancer. *Cell* 2007;**131**:1190–203.
9. Inamura K, Takeuchi K, Togashi Y, *et al.* EML4-ALK fusion is linked to histological characteristics in a subset of lung cancers. *J Thorac Oncol* 2008;**3**:13–17.
10. Shaw AT, Yeap BY, Mino-Kenudson M, *et al.* Clinical features and outcome of patients with non-small-cell lung cancer who harbor EML4-ALK. *J Clin Oncol* 2009;**27**:4247–53.
11. Mino-Kenudson M, Chirieac LR, Law K, *et al.* A novel, highly sensitive antibody allows for the routine detection of ALK-rearranged lung adenocarcinomas by standard immunohistochemistry. *Clin Cancer Res* 2010;**16**:1561–71.
12. Takeuchi K, Choi YL, Togashi Y, *et al.* KIF5B-ALK, a novel fusion oncokine identified by an immunohistochemistry-based diagnostic system for ALK-positive lung cancer. *Clin Cancer Res* 2009;**15**:3143–9.
13. Nagai Y, Miyazawa H, Huqun, *et al.* Genetic heterogeneity of the epidermal growth factor receptor in non-small cell lung cancer cell lines revealed by a rapid and sensitive detection system, the peptide nucleic acid-locked nucleic acid PCR clamp. *Cancer Res* 2005;**65**:7276–82.
14. Tam IY, Chung LP, Suen WS, *et al.* Distinct epidermal growth factor receptor and KRAS mutation patterns in non-small cell lung cancer patients with different tobacco exposure and clinicopathologic features. *Clin Cancer Res* 2006;**12**:1647–53.
15. Wong DW, Leung EL, So KK, *et al.* The EML4-ALK fusion gene is involved in various histologic types of lung cancers from nonsmokers with wild-type EGFR and KRAS. *Cancer* 2009;**115**:1723–33.
16. Ou SH, Zizog A, Zell JA. Primary signet-ring carcinoma (SRC) of the lung: a population-based epidemiologic study of 262 cases with comparison to adenocarcinoma of the lung. *J Thorac Oncol* 2010;**5**:420–7.
17. Martelli MP, Sozzi G, Hernandez L, *et al.* EML4-ALK rearrangement in non-small cell lung cancer and non-tumor lung tissues. *Am J Pathol* 2009;**174**:661–70.

EML4-ALK Fusion Gene Assessment Using Metastatic Lymph Node Samples Obtained by Endobronchial Ultrasound-Guided Transbronchial Needle Aspiration

Yuichi Sakairi^{1,7}, Takahiro Nakajima^{1,2,7}, Kazuhiro Yasufuku², Dai Ikebe³, Hajime Kageyama⁴, Manabu Soda⁵, Kengo Takeuchi⁶, Makiko Itami³, Toshihiko Iizasa¹, Ichiro Yoshino⁷, Hiroyuki Mano⁵, and Hideki Kimura¹

Abstract

Purpose: Anaplastic lymphoma kinase (ALK) fusion genes represent novel oncogenes for non-small cell lung cancers (NSCLC). Several ALK inhibitors have been developed, and are now being evaluated in ALK-positive NSCLC. The feasibility of detecting ALK fusion genes in samples obtained by endobronchial ultrasound-guided transbronchial needle aspiration (EBUS-TBNA) was determined. The clinicopathologic characteristics of ALK-positive lung cancer were also analyzed.

Experimental Design: From April 2008 to July 2009, NSCLC cases with hilar/mediastinal lymph node metastases detected by EBUS-TBNA were enrolled. Positive expression of ALK fusion protein was determined using immunohistochemistry, and ALK gene rearrangements were further examined to verify the translocation between ALK and partner genes using fluorescent *in situ* hybridization and reverse transcription-PCR. Direct sequencing of PCR products was performed to identify ALK fusion variants.

Results: One hundred and nine cases were eligible for the analysis using re-sliced samples. Screening of these specimens with immunohistochemistry revealed ALK positivity in seven cases (6.4%), all of which possessed echinoderm microtubule-associated protein-like 4-ALK fusion genes as detected by fluorescent *in situ* hybridization and reverse transcription-PCR. All ALK-positive cases had an adenocarcinoma histology and possessed no EGFR mutations. Compared with ALK-negative cases, ALK-positive cases were more likely to have smaller primary tumors ($P < 0.05$), to occur at a younger age (< 60 years; $P < 0.05$), and to occur in never/light smokers (smoking index < 400 ; $P < 0.01$). Mucin production was frequently observed in ALK-positive adenocarcinomas (29.4%; $P < 0.01$).

Conclusions: EBUS-TBNA is a practical and feasible method for obtaining tissue from mediastinal and hilar lymph nodes that can be subjected to multimodal analysis of ALK fusion genes in NSCLC. *Clin Cancer Res*; 16(20); 4938-45. ©2010 AACR.

A small inversion within the short arm of human chromosome 2 leads to the generation of a fusion gene between the anaplastic lymphoma kinase (ALK) gene and the echinoderm microtubule-associated protein-like 4 (EML4) gene, the protein product of which is reported to function as an oncokine in non-small cell lung cancer (NSCLC); in fact, this was the first oncogenic trans-

location to be identified in lung cancer (1). The EML4-ALK fusion gene has been detected in ~5% of NSCLC cases, and several ALK fusion gene variants have been reported (2). Standard methods for the detection of ALK fusion genes include reverse transcription-PCR (RT-PCR) with primers flanking the fusion points, as well as fluorescent *in situ* hybridization (FISH). Previously, immunohistochemistry-based diagnosis of ALK fusion genes in lung cancer has proven to be difficult, most likely due to the low expression level of the fusion protein products (3). An intercalated antibody-enhanced polymer (iAEP) technique has recently been developed that enables reliable immunohistochemistry-based detection of ALK fusion products (4). However, this technique has only been performed in cell lines and in large, surgically resected specimens; thus, it remains unclear whether such methodology can be applied to small biopsy samples obtained from patients with advanced NSCLC.

Endobronchial ultrasound-guided transbronchial needle aspiration (EBUS-TBNA) is an established modality for the definitive diagnosis of mediastinal and hilar adenopathy in

Authors' Affiliations: ¹Division of Thoracic Diseases, Chiba Cancer Center, Chiba, Japan; ²Division of Thoracic Surgery, Toronto General Hospital, University Health Network, University of Toronto, Canada; ³Division of Surgical Pathology, Chiba Cancer Center, Chiba, Japan; ⁴Division of Genetic Diagnosis, Chiba Cancer Center, Chiba, Japan; ⁵Division of Functional Genomics, Jichi Medical University, Tochigi, Japan; ⁶Division of Pathology, The Cancer Institute, Japanese Foundation for Cancer Research, Tokyo, Japan; and ⁷Department of General Thoracic Surgery, Graduate School of Medicine, Chiba University, Chiba, Japan

Corresponding Author: Takahiro Nakajima, Division of Thoracic Diseases, Chiba Cancer Center, 666-2 Nitona-cho, Chuo-ku 260-8717, Chiba, Japan. Phone: 81-43-264-5431; Fax: 81-43-262-8680; E-mail: nakajii@tc.med.miyazaki-u.ac.jp.

doi: 10.1158/1078-0432.CCR-10-0099

©2010 American Association for Cancer Research.

Translational Relevance

Acquisition of proper tissue samples for molecular analysis is not always an easy task; however, information obtained from such specimens is essential for the selection of appropriately targeted cancer therapies. This study shows that endobronchial ultrasound-guided transbronchial needle aspiration (EBUS-TBNA) contributes to the resolution of this issue in lung cancer because tissue samples obtained by EBUS-TBNA can be successfully used to assess the presence of echinoderm microtubule-associated protein-like 4–anaplastic lymphoma kinase fusion genes. We have shown that EBUS-TBNA samples could be subjected to immunohistochemistry, fluorescent *in situ* hybridization, and reverse transcription-PCR analysis. EBUS-TBNA for the assessment of mediastinal and hilar adenopathy is a practical tool that can be used in the molecularly targeted treatment era for lung cancer.

patients with lung cancer (5, 6). EBUS-TBNA is generally accepted to be as safe as standard bronchoscopy, less invasive than mediastinoscopy, and of high diagnostic quality. Compared with conventional fine-needle aspiration, EBUS-TBNA is an outstanding procedure with respect to its extremely low morbidity and its repeatability; fine-needle aspiration could cause pneumothorax, and repeated sampling might be difficult to perform.

In this study, we analyzed the feasibility of EBUS-TBNA for the detection of *EML4-ALK* fusion genes. We also retrospectively analyzed the clinicopathologic characteristics of *ALK*-positive lung cancer cases with mediastinal and/or hilar lymph node metastasis.

Materials and Methods

Patients

From April 2008 to July 2009, 112 cases with proven hilar and/or mediastinal lymph node metastasis of NSCLC were enrolled; re-sliced specimens for histologic examination were available for 109 of these cases. Independent pathologists (D. Ikebe and M. Itami) reviewed all cases and histologically confirmed the presence of cancer cells in each specimen. Morphologic features detected with H&E staining were also recorded, and mucin production was evaluated by Alcian blue staining. First, samples were screened for *ALK* abnormalities using immunohistochemistry. Cases that were determined to be *ALK*-positive or suspicious by immunohistochemistry in our laboratory were subjected to additional evaluation by FISH and immunohistochemistry restaining by an independent pathologist (K. Takeuchi) at the Division of Pathology, The Cancer Institute, Japanese Foundation for Cancer Research. Final confirmation was performed by direct sequencing of *EML4-ALK* fusion cDNAs using EBUS-TBNA

histologic cores that had been preserved at -80°C . *EGFR* gene mutation status was also evaluated in all EBUS-TBNA samples. Associations between the presence of *ALK* fusion genes and clinicopathologic characteristics were retrospectively analyzed from medical records.

EBUS-TBNA

In all cases, chest computed tomography was performed prior to EBUS-TBNA. Brain magnetic resonance imaging, enhanced computed tomography, and bone scintigraphy were also performed for clinical staging of each case. EBUS-TBNA was performed for lymph nodes >5 mm in short axis on chest computed tomography. To obtain a histologic core, a dedicated 22-gauge needle equipped with an internal stylet was used. After the initial puncture, the internal stylet was used to clean out the internal lumen that was clogged with bronchial tissue (Fig. 1A). The internal stylet was removed, and negative pressure was applied using a syringe. The needle was then moved back and forth inside the lymph node. Finally, the needle was retrieved, and the internal stylet was used to push out the histologic core (6). Each histologic core was divided into two samples: one was fixed with formalin and used for histologic diagnosis, and the other was mixed with Allprotect Tissue Reagent (Qiagen) following the instructions of the manufacturer, and stored at -80°C .

ALK detection with immunohistochemistry

For detection of the *ALK* fusion gene, we applied the iAEP method, which incorporates an intercalating antibody between the primary antibody to *ALK* and dextran polymer-based detection reagents (4).

Histologic cores obtained by EBUS-TBNA were routinely fixed in 20% neutralized formalin and embedded in paraffin. Blocks were sliced at a thickness of $4\ \mu\text{m}$, and sections were placed on silane-coated slides. Antibody preparations specific for the intracellular region of *ALK* (5A4, Abcam) were subjected to immunohistochemical staining according to standard protocols using dextran polymer reagents (anti-mouse immunoglobulin, EnVision+DAB System; Dako). The *ALK* antibody (5A4) was used at a dilution of 1:50. For antigen retrieval and deparaffinization, slides were heated for 20 minutes at 98°C in Target Retrieval Solution (low pH; Dako) with PT-link (Dako). Pretreated slides were positioned in a programmable AutoStainer instrument (EnVision System; Dako). Following the immunohistochemical program, slides were incubated at room temperature first with Peroxidase Blocking Solution (Dako) for 5 minutes and then with *ALK* antibody (5A4, 1:50; Abcam) for 30 minutes. Following application of the iAEP method, which has been described in detail elsewhere (4), we included an incubation step of 15 minutes at room temperature with intercalated immunoglobulin (Mouse-LINKER; Dako) to increase the detection sensitivity. Immune complexes were then detected using the dextran polymer reagent for 30 minutes. 5A4-positive cells were stained with 3,3'-diaminobenzidine for 5 minutes, and nuclei were then stained with hematoxylin for 2 minutes.

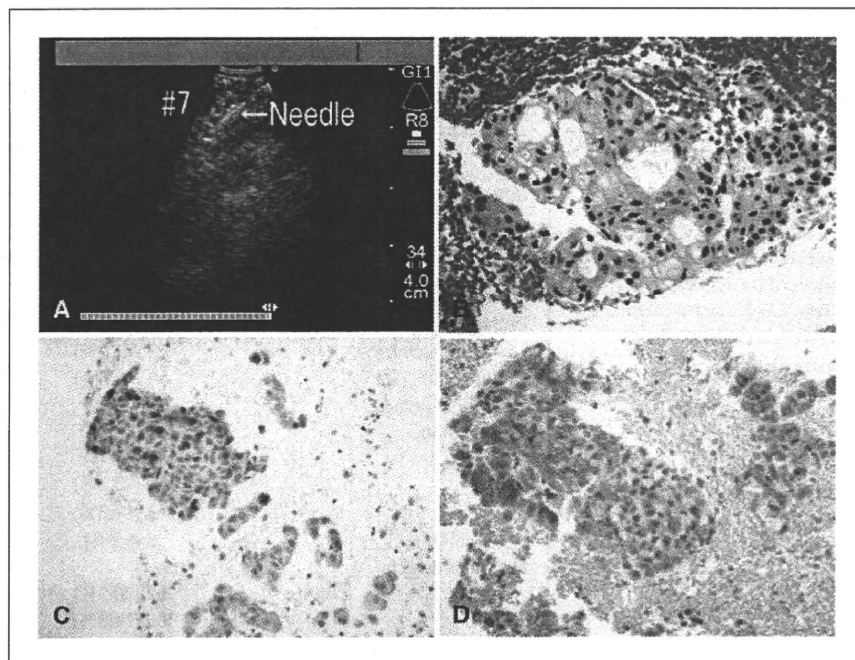


Fig. 1. Diagnosis of metastatic nodes by EBUS-TBNA. A, lymph node sampling by EBUS-TBNA. B, adenocarcinoma was revealed in the EBUS-TBNA sample. C, mucin production was observed by Alcian blue staining. D, immunohistochemistry with an anti-ALK antibody showed ALK fusion protein positivity in lung adenocarcinoma cells.

The samples obtained with EBUS-TBNA were small, paraffin-embedded biopsy specimens, which might limit the utility of immunohistochemistry. To avoid false-negative diagnosis, the first immunohistochemical procedure was used as a screening test to define three categories with which to judge the first run. Cancer cells were defined as "positive" if staining was as strongly positive as a positive control (clinical lung cancer tissues previously defined as positive by both molecular and immunohistochemistry analyses) and a fine, granular cytoplasmic staining pattern was observed. Cancer cells that showed no staining were classified as "negative." The "suspicious" classification was defined as the presence of weakly stained cells that were considered difficult to differentiate from background staining. While using these categories, we further subdivided the suspicious category into "probably positive" and "probably negative" categories. Probably positive meant that the tumor cells stained, but not strongly, whereas probably negative indicated very weak staining that was difficult to differentiate from background staining. After the screening immunohistochemistry, suspicious cases were re-tested by immunohistochemistry in addition to FISH by a second independent pathologist (K. Takeuchi).

Fluorescence *in situ* hybridization

To further confirm the ALK genomic rearrangement, two FISH assays were performed: an ALK split assay and an *EML4-ALK* fusion assay. Unstained sections were processed with a Histology FISH Accessory Kit (Dako), subjected to hybridization with fluorescently-labeled bacterial artificial chromosome clone probes for *EML4* and *ALK* (self-produced

probes; *EML4* RP11-996L7, *ALK* RP11-984I21, and RP11-62B19) or for genomic regions upstream and downstream of the ALK breakpoint (Dako), stained with 4,6-diamidino-2-phenylindole, and examined with a fluorescence microscope (BX51; Olympus; ref. 7). FISH analysis was performed at the Division of Pathology, The Cancer Institute, Japanese Foundation for Cancer Research (K. Takeuchi). The FISH positivity criteria for EBUS-TBNA samples were defined as "over 50% cancer cells." As EBUS-TBNA samples are small biopsy samples, entire tumor cells in the paraffin-embedded section were evaluated.

RT-PCR and direct sequencing

Frozen histologic cores obtained by EBUS-TBNA were used to extract RNA. All immunohistochemistry-positive or suspicious cases were subjected to direct sequencing of the fusion cDNAs. RNA was extracted from frozen samples using the AllPrep DNA/RNA mini kit (Qiagen), and cDNA cloning was performed with the High Capacity RNA-to-cDNA Kit (Applied Biosystems). For RT-PCR analysis of *EML4-ALK*, we used primer sequences that have been described previously (2). After PCR amplification, PCR products were analyzed using agarose gel electrophoresis. RT-PCR products were extracted from gel slices using the QIAquick Gel Extraction Kit (Qiagen). Purified products were then sequenced with a capillary sequencer. Resultant nucleotide sequences were compared with previously reported sequences for determination of the *EML4-ALK* variant. *EGFR* mutation status was also examined using the peptide nucleic acid/locked nucleic acid PCR clamp method for samples obtained with EBUS-TBNA (8).

Ethics committee approval

This research was approved by the Ethics Committee of Chiba Cancer Center (nos. 20-21 and 21-10). Written consent was obtained from all patients. All samples were coded and managed independently.

Statistical analysis

For clinical characteristics and genetic factors, frequency analysis was performed with Fisher's exact test (dichotomous factors) and χ^2 test (multinomial factors). Mann-Whitney *U* test was applied to continuous data. General data analysis was conducted with StatView 5.0 (SAS Institute, Inc.). All *P* values were based on a two-sided hypothesis, *P* < 0.05 was considered to have statistical significance.

Results

Patient characteristics

The clinical characteristics of all 109 patients are listed in Table 1; 82 patients (75.2%) were male. The median age was 64.4 years (range, 38–90 y). Histologic examination was performed in all cases, leading to a diagnosis of adenocarcinoma (Fig. 1B) in 82 cases (75.2%), squamous cell carcinoma in 18 cases, and "other" in 9 cases. With respect to smoking status, 22 cases (20.4%) were never-smokers, 15 (13.9%) were light smokers (defined as a smoking index score <400), and 72 were heavy smokers (smoking index score \geq 400). A total of 191 mediastinal lymph nodes and 84 hilar lymph nodes (2.52 lymph nodes/patient) were detected with EBUS, and 158 mediastinal lymph nodes and 71 hilar lymph nodes (2.10 lymph nodes/patient) were sampled. The median size of the sampled lymph nodes was 12.1 mm (range, 3.0–33.4 mm) in the short axis on ultrasound. According to criteria from the International Union Against Cancer, there were 9 stage II cases, 49 stage III cases, and 45 stage IV cases; the remaining 6 cases were defined as having recurrent lung cancer. *EGFR* gene mutations were detected in 25 cases (22.9%), which included 9 cases with in-frame deletions at exon 19, 9 cases with a point mutation at exon 21, 3 cases with a point mutation at exon 18, 2 cases with point mutations at exons 18 and 21, 1 case with a point mutation at exon 20, and 1 case with point mutations in exons 20 and 21.

ALK fusion gene assessment

Out of 109 cases examined by immunohistochemistry using the iAEP method, 6 *ALK*-positive cases and 17 suspicious cases (1 probably positive and 16 probably negative) cases were detected. The staining of the small histologic core did not show any heterogeneity.

FISH confirmed the existence of an *ALK* fusion gene in all six *ALK*-positive cases (Figs. 1D, 2A and B), and there were no false-positive cases for immunohistochemistry. Sixteen probably negative cases were determined to be negative for the *ALK* fusion gene by re-testing with immunohistochemistry and FISH. One probably positive case had too few tumor cells to be used for FISH analysis; however, RT-PCR assessment confirmed the presence of *EML4-ALK*

Table 1. Clinical characteristics of patients with NSCLC

Parameter	Number of cases (%)
	109
Age	
Mean (y)	64.4 (range, 38–90)
Gender	
Male	82 (75.2%)
Female	27 (24.8%)
Pathology	
Adenocarcinoma	82 (75.2%)
Squamous cell	18 (16.5%)
Other histology	9 (8.3%)
Clinical stage	
II	9 (8.3%)
III	49 (45.0%)
IV	45 (41.3%)
Recurrence	6 (5.5%)
Bone metastasis	
Yes	22 (20.2%)
No	87 (79.8%)
Brain metastasis	
Yes	16 (14.7%)
No	93 (85.3%)
Smoking	
Never (SI = 0)	22 (20.4%)
Light (SI < 400)	15 (13.9%)
Heavy (SI \geq 400)	70 (64.8%)
<i>EGFR</i> mutation status	25 (22.9%)
Exon 18	3
Exon 19	9
Exon 20	1
Exon 21	9
Exons 18 + 21	2
Exons 20 + 21	1

Abbreviation: SI, smoking index.

fusion cDNA. *EML4*, *ALK*, and fusion signals (arrows in Fig. 2A) are presented in the green, red, and merged image and a pair of split signals (arrow in Fig. 2B, downstream) shows rearrangement of *ALK*. In Fig. 2C, unique bands in each *ALK*-positive case reveal variant 1 and variant 3 *EML4-ALK* fusion genes. Thus, the *ALK* fusion gene was detected in a total of seven cases (6.4%). Direct sequencing of the PCR products revealed that four cases carried *EML4-ALK* variant 1, whereas three cases had variant 3. The fusion point of *ALK* and *EML4* is observed in the cDNA sequence (arrow in Fig. 2D).

Clinicopathologic characteristics of lung cancers possessing *ALK* fusion genes

Clinicopathologic characteristics were compared between the 7 *ALK*-positive cases and the 102 *ALK*-negative

cases (Table 2). All *ALK*-positive cases had an adenocarcinoma histology and lacked *EGFR* gene mutations. With respect to smoking habits, six out of the seven *ALK*-positive cases were either never-smokers or light smokers (smoking index score <400). No significant difference in gender was observed between *ALK*-positive and *ALK*-negative patients; however, *ALK*-positive patients were significantly younger than *ALK*-negative patients (55.4 versus 65.0 years; $P = 0.0408$). No significant differences in the incidence of bone metastasis (9.1% versus 5.7%; $P = 0.64$) or brain metastasis (12.5% versus 5.4%; $P = 0.30$) were observed. Overall, the mean primary tumor diameter was 40.4 mm; interestingly, the mean primary tumor diameter of *ALK*-positive cases was 28.6 mm, which was significantly smaller than that of *ALK*-negative cases (41.9 mm; $P < 0.05$). Mucin production was significantly more frequently observed in *ALK*-positive cases as shown by Alcian blue staining (Fig. 1C; $P < 0.01$). Finally, among the 84 cases expressing wild-type *EGFR*, 8.3% (7 of 84) were *ALK*-positive.

Discussion

This is the first attempt and report about using EBUS-TBNA samples in the detection of *ALK* fusion genes, and is expected to have a major effect on the management of patients with lung cancer. EBUS-TBNA is an established

procedure for the evaluation of mediastinal and hilar adenopathy in patients with lung cancer. It is as safe, as highly diagnostic, and less invasive than other diagnostic modalities (9–11). Biopsy samples obtained with EBUS-TBNA can be subjected to histologic as well as cytologic evaluation. Nonsurgical modalities for obtaining tumor specimens are particularly critical in lung cancer because many patients have advanced disease at the time of first presentation, and are therefore not eligible for radical surgery. In addition to histologic diagnosis and stage definition, EBUS-TBNA enables molecular analysis of biopsy samples, the clinical significance of which is growing as molecularly targeted strategies for NSCLC are becoming increasingly important. We have previously reported that metastatic lymph node samples obtained by EBUS-TBNA can be applied to multidisciplinary analyses (5), and the present study is the first report of successful analysis of *ALK* fusion genes, a newly identified genetic abnormality in NSCLC, with such specimens (2). However, the small size of the paraffin-embedded biopsy samples obtained from EBUS-TBNA might limit the utility of this methodology; thus, multidirectional analysis will be critical for microsampling methods such as EBUS-TBNA.

The reliability of the newly developed immunohistochemistry (iAEP) method for the detection of *ALK* fusion

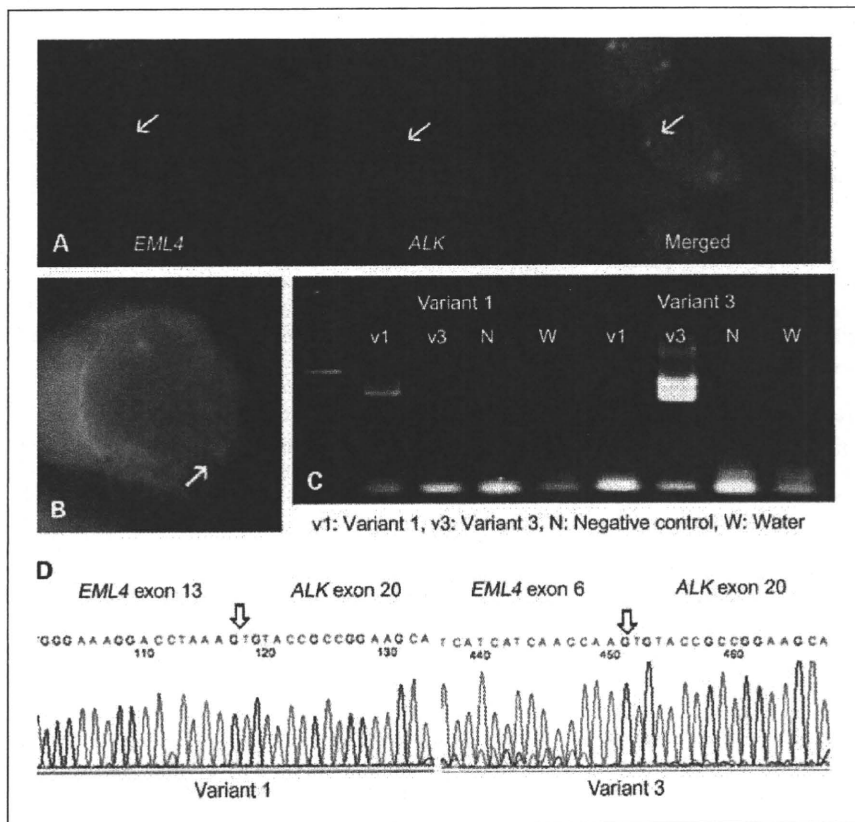


Fig. 2. Molecular analysis of *ALK* fusion genes. **A**, FISH *EML4-ALK* fusion assay with labeled probes for *EML4* (green, arrow) or *ALK* (red, arrow). The *EML4-ALK* fusion gene is observed (yellow, arrow). **B**, *EML4-ALK* split assay with labeled probes for the upstream (red, arrow) region of the *ALK* locus. **C**, RT-PCR detection of the *EML4-ALK* fusion gene. **D**, direct cDNA sequence of *EML4-ALK* variants 1 and 3.

Table 2. Clinical, pathologic, and genetic analysis of ALK-positive NSCLC

Characteristic	EML4-ALK fusion			P
	NSCLC	+	-	
Female gender	27	4	23	0.062
Mean age (y)	64.4	55.4	65.0	0.0408
<60	29	5	24	0.0139
Bone metastasis	22	2	20	0.6396
Brain metastasis	16	2	14	0.2973
Mean tumor diameter (mm)	40.4	28.6	41.9	0.0478
Smoking index (n = 107)	784	161	827	0.0071
Never/light smoker	37	6	31	0.0056
Adenocarcinoma	82	7	75	0.1896
Mucin production	17	5	12	0.0009
EGFR wild-type	84	7	77	0.3317
ALK variant 1		4		
ALK variant 3		3		

NOTE: Two cases without primary tumors and six cases of recurrence were excluded from the tumor diameter analysis. Smoking history was recorded in 107 patients.

genes is very precise (4). This method is expected to be more practical for the detection of ALK fusion genes compared with FISH because FISH can sometimes be very difficult to perform for ALK fusion genes due to the close proximity of the two fusion gene components. We performed both fusion and split assays for FISH, and FISH was performed to confirm the immunohistochemical results. In addition, the ALK fusion genes are novel oncogenes in lung cancer. There is a possibility of existing unknown fusion pattern which cannot be detected by FISH or RT-PCR. Immunohistochemistry has an advantage of detecting novel unknown fusion patterns (4). In this study, we performed immunohistochemistry using the iAEP methodology and an Autostainer instrument. This technique is convenient, highly reproducible, and enables accurate diagnosis even if only a small amount of specimen is available. These features are well-suited for the screening of ALK-positive lung cancers using small biopsy samples. The Autostainer instrument also allows uniform immunohistochemical analysis, which may lead to consistent results among different institutions/hospitals; such uniformity is essential for the standardization of diagnostic procedures that assess the presence of ALK fusion genes. Recently, a highly sensitive antibody directed against ALK fusion products that can possibly be used for immunohistochemistry has been reported, therefore representing a novel candidate for ALK fusion detection (12).

The median age of ALK-positive cases in the present study was 55.4 years. Patients <60 years represent approximately 10% of all lung cancer deaths (6,655 of 63,255 deaths) according to the Japanese National Cancer Center Cancer

Information Service Statistics published in 2008 (13). In the present study, a significant number of ALK-positive cases were <60 years of age (17.2%, 5 of 29; $P < 0.05$). ALK-positive cancer may therefore be more common in patients with early-onset NSCLC. However, it should be noted that two ALK-positive cases were >70 years of age (71 and 73 years); therefore, although patient age may become a predictor of ALK fusion gene positivity, ALK screening must also be performed in elderly individuals. The median diameter of primary lung tumors was significantly smaller in ALK-positive cases (28.6 versus 41.9 mm; $P < 0.05$), further emphasizing the importance of EBUS-TBNA because this technique does not require a large primary lesion. An additional advantage of EBUS-TBNA is that it can be used for lymph node sampling, which is relevant to the majority of advanced lung cancer cases. Although lung cancer is generally more common in smokers, most of the ALK-positive cases in this study (37 cases; 34.3%) were never-smokers or light smokers. The smoking index scores in the ALK-positive cohort were significantly lower than that of ALK-negative patients (161 versus 827; $P < 0.01$). Hence, being a never-smoker or light smoker seems to be a strong predictor of ALK positivity ($P < 0.01$).

Evaluation of the clinicopathologic characteristics of patients in our cohort indicated that ALK-positive lung cancer tends to have an adenocarcinoma histology, expresses wild-type EGFR, has an early age of onset (<60 y), manifests as a relatively small primary lesion, more frequently occurs in never-smokers or light smokers (smoking index score <400), and has a mucin-producing histology. However, as EBUS-TBNA samples are obtained from metastatic lymph nodes rather than the primary tumor, these clinical features are nearly compatible with previously reported features (14). Patients harboring one or more of these predictive factors may therefore derive the most benefit from ALK fusion gene screening.

Recently, ALK-positive NSCLC was reported to be a signet ring cell type adenocarcinoma (15, 16). We assume that this description also includes mucin production, i.e., mucin-producing tumors or tumors with >10% Alcian blue staining in the cytoplasm. Herein, we performed Alcian blue staining on suspected mucin-producing tumors as part of the histologic diagnosis. By this classification, 17 (15.6%) NSCLC cases were determined to be mucin-producing cancers. These cases were all adenocarcinomas and included five ALK-positive cases; thus, approximately 30% of the mucin-producing adenocarcinomas showed ALK positivity. This is a significantly high frequency compared with that of other NSCLCs ($P < 0.01$). This histologic feature, which can be assessed in cytologic samples, therefore seems to be useful for the prediction of ALK positivity.

The standard therapy for patients with advanced lung cancer at the time of presentation is chemotherapy and/or radiotherapy. However, standard platinum-based combined chemotherapy is not sufficient for disease eradication (17). Recently, lung cancer treatment strategies have become refined through the development of molecular markers and molecularly targeted agents. ALK inhibitors

have a high potential to become a definitive treatment for *ALK*-positive lung cancer, in a manner parallel to the exceptional therapeutic response of *EGFR*-positive lung cancers to *EGFR* tyrosine kinase inhibitors (18, 19). The efficacy of *ALK* inhibitors has been confirmed in cell lines (20, 21), and phase I clinical development of an oral *ALK* inhibitor for patients with lung cancer is currently under way (PF-02341066); two of the seven *ALK*-positive NSCLC cases from the present series have been enrolled in this trial (22, 23). As the background of *ALK*-positive lung cancer is similar to that of *EGFR*-positive lung cancer, and *ALK* tyrosine kinase inhibition is fundamentally similar to *EGFR* tyrosine kinase inhibition, *ALK* inhibitors might experience a similar progression of drug development and clinical and pathologic prediction of *ALK* positivity in lung cancer patients as *EGFR* tyrosine kinase inhibitors have for patients with *EGFR*-positive lung cancer. In this study, all *ALK*-positive lung cancers possessed wild-type *EGFR* and were therefore ineligible for *EGFR* tyrosine kinase inhibitor therapy (24). Therefore, *ALK* fusion gene assessment and administration of *ALK* inhibitors may become important for patients with *EGFR*-negative lung cancers.

Although some *ALK* inhibitors have already been developed and are currently being evaluated in clinical trials, it is important to establish a method for determining the existence of *ALK* fusion genes prior to the administration of *ALK* inhibitors. Both the presence of *ALK* fusion genes as well as *EGFR* gene mutations were successfully evaluated using histologic samples obtained by EBUS-TBNA of lung cancer regional lymph nodes. This diagnostic strategy allowed both pretreatment staging and evaluation of critical molecular markers to be definitively determined in a less invasive manner. There are some publications related with the genomic difference between primary tumor and metastatic site (25–29). EBUS-TBNA is a minimally invasive modality that allows the sampling of tumor cells from metastatic

lymph node with a very low morbidity. The possibility of genetic differences should be considered whenever the biomarker information is used for the selection of patients for molecular target therapies. EBUS-TBNA is an ideal approach in this aspect.

In conclusion, EBUS-TBNA sampling is feasible for *ALK* fusion gene assessment by immunohistochemistry, FISH, and RT-PCR, as well as for pathologic diagnosis. The development of a safe and highly precise modality that enables the acquisition of a sufficient amount of high-quality tissue without surgery will become increasingly important in the molecularly targeted therapy era. EBUS-TBNA is one of the best candidates for such a methodology.

Disclosure of Potential Conflicts of Interest

K. Yasufuku, recipient of an unrestricted grant from Olympus Medical Corporation for Continuing Medical Education; H. Mano, member of the scientific advisory board, Pfizer Inc.

Acknowledgments

We thank Yuko Noguchi and Tetsushi Hirata for technical assistance with immunohistochemistry. We thank Drs. Yukiko Matsui, Masato Shingyoji, and Meiji Itakura for clinical analysis support. All authors have read and approved the final version of this manuscript.

Grant Support

This research was supported, in part, by the Ministry of Education, Culture, Sports, Science and Technology, Grant-in-Aid for Young Scientists (B) no. 21791340 in 2009 (T. Nakajima) and Grant-in-Aid for Cancer Research from Ministry of Health, Labor and Welfare in 2009 (T. Nakajima).

The costs of publication of this article were defrayed in part by the payment of page charges. This article must therefore be hereby marked *advertisement* in accordance with 18 U.S.C. Section 1734 solely to indicate this fact.

Received 01/14/2010; revised 06/14/2010; accepted 07/11/2010; published OnlineFirst 10/05/2010.

References

- Mano H. Non-solid oncogenes in solid tumors: EML4-*ALK* fusion genes in lung cancer. *Cancer Sci* 2008;99:2349–55.
- Soda M, Choi YL, Enomoto M, et al. Identification of the transforming EML4-*ALK* fusion gene in non-small-cell lung cancer. *Nature* 2007; 448:561–6.
- Martelli MP, Sozzi G, Hernandez L, et al. EML4-*ALK* rearrangement in non-small cell lung cancer and non-tumor lung tissues. *Am J Pathol* 2009;174:661–70.
- Takeuchi K, Choi YL, Togashi Y, et al. KIF5B-*ALK*, a novel fusion oncokinase identified by an immunohistochemistry-based diagnostic system for *ALK*-positive lung cancer. *Clin Cancer Res* 2009;15: 3143–9.
- Nakajima T, Yasufuku K, Suzuki M, et al. Assessment of epidermal growth factor receptor mutation by endobronchial ultrasound-guided transbronchial needle aspiration. *Chest* 2007;132:597–602.
- Yasufuku K, Chiyo M, Koh E, et al. Endobronchial ultrasound guided transbronchial needle aspiration for staging of lung cancer. *Lung Cancer* 2005;50:347–54.
- Takeuchi K, Choi YL, Soda M, et al. Multiplex reverse transcription-PCR screening for EML4-*ALK* fusion transcripts. *Clin Cancer Res* 2008;14:6618–24.
- Nagai Y, Miyazawa H, Huqun, et al. Genetic heterogeneity of the epidermal growth factor receptor in non-small cell lung cancer cell lines revealed by a rapid and sensitive detection system, the peptide nucleic acid-locked nucleic acid PCR clamp. *Cancer Res* 2005;65: 7276–82.
- Yasufuku K, Chiyo M, Sekine Y, et al. Real-time endobronchial ultrasound-guided transbronchial needle aspiration of mediastinal and hilar lymph nodes. *Chest* 2004;126:122–8.
- Herth FJ, Ernst A, Eberhardt R, Vilmann P, Dienemann H, Krasnik M. Endobronchial ultrasound-guided transbronchial needle aspiration of lymph nodes in the radiologically normal mediastinum. *Eur Respir J* 2006;28:910–4.
- Herth FJ, Eberhardt R, Vilmann P, Krasnik M, Ernst A. Real-time endobronchial ultrasound guided transbronchial needle aspiration for sampling mediastinal lymph nodes. *Thorax* 2006;61:795–8.
- Mino-Kenudson M, Chirieac LR, Law K, et al. A novel, highly sensitive antibody allows for the routine detection of *ALK*-rearranged lung adenocarcinomas by standard immunohistochemistry. *Clin Cancer Res* 2010;16:1561–71.
- National Cancer Center Cancer Information Service. Available from: <http://ganjoho.ncc.go.jp/public/statistics/backnumber/odjrh3000000vdf1-att/date02.pdf>. Accessed on August 28, 2009.
- Takahashi T, Sonobe M, Kobayashi M, et al. Clinicopathologic features of non-small-cell lung cancer with EML4-*ALK* fusion gene. *Ann Surg Oncol* 2010;17:889–97.

15. Inamura K, Takeuchi K, Togashi Y, et al. EML4-ALK fusion is linked to histological characteristics in a subset of lung cancers. *J Thorac Oncol* 2008;3:13-7.
16. Inamura K, Takeuchi K, Togashi Y, et al. EML4-ALK lung cancers are characterized by rare other mutations, a TTF-1 cell lineage, an acinar histology, and young onset. *Mod Pathol* 2009;22:508-15.
17. Wakelee H, Belani CP. Optimizing first-line treatment options for patients with advanced NSCLC. *Oncologist* 2005;10:1-10.
18. Lynch TJ, Bell DW, Sordella R, et al. Activating mutations in the epidermal growth factor receptor underlying responsiveness of non-small-cell lung cancer to gefitinib. *N Engl J Med* 2004;350:2129-39.
19. Paez JG, Jänne PA, Lee JC, et al. EGFR mutations in lung cancer: correlation with clinical response to gefitinib therapy. *Science* 2004;304:1497-500.
20. Koivunen JP, Mermel C, Zejnullahu K, et al. EML4-ALK fusion gene and efficacy of an ALK kinase inhibitor in lung cancer. *Clin Cancer Res* 2008;14:4275-83.
21. Piva R, Chiarle R, Manazza AD, et al. Ablation of oncogenic ALK is a viable therapeutic approach for anaplastic large-cell lymphomas. *Blood* 2006;107:689-97.
22. Kwak EL, Camidge DR, Clark J, et al. Clinical activity observed in a phase I dose escalation trial of an oral c-met and ALK inhibitor, PF-02341066. *J Clin Oncol* 2009;27:15s.
23. Christensen JG, Zou HY, Arango ME, et al. Cytoreductive antitumor activity of PF-2341066, a novel inhibitor of anaplastic lymphoma kinase and c-Met, in experimental models of anaplastic large-cell lymphoma. *Mol Cancer Ther* 2007;6:3314-22.
24. Shaw AT, Yeap BY, Mino-Kenudson M, et al. Clinical features and outcome of patients with non-small-cell lung cancer who harbor EML4-ALK. *J Clin Oncol* 2009;27:4247-53.
25. Kalikaki A, Koutsopoulos A, Trypaki M, et al. Comparison of EGFR and K-RAS gene status between primary tumours and corresponding metastases in NSCLC. *Br J Cancer* 2008;99:923-9.
26. Gow CH, Chang YL, Hsu YC, et al. Comparison of epidermal growth factor receptor mutations between primary and corresponding metastatic tumors in tyrosine kinase inhibitor-naive non-small-cell lung cancer. *Ann Oncol* 2009;20:696-702.
27. Daniele L, Cassoni P, Bacillo E, et al. Epidermal growth factor receptor gene in primary tumor and metastatic sites from non-small cell lung cancer. *J Thorac Oncol* 2009;4:684-8.
28. Park S, Holmes-Tisch AJ, Cho EY, et al. Discordance of molecular biomarkers associated with epidermal growth factor receptor pathway between primary tumors and lymph node metastasis in non-small cell lung cancer. *J Thorac Oncol* 2009;4:809-15.
29. Schmid K, Oehi N, Wrba F, et al. EGFR/KRAS/BRAF mutations in primary lung adenocarcinomas and corresponding locoregional lymph node metastases. *Clin Cancer Res* 2009;15:4554-60.

Lymphomatoid gastropathy: a distinct clinicopathologic entity of self-limited pseudomalignant NK-cell proliferation

Kengo Takeuchi,^{1,2} Masahiro Yokoyama,³ Shin Ishizawa,⁴ Yasuhito Terui,³ Kimie Nomura,² Kousuke Marutsuka,⁵ Maki Nunomura,⁶ Noriyasu Fukushima,⁷ Takahiro Yagyu,⁸ Hirokazu Nakamine,⁹ Futoshi Akiyama,² Kazuei Hoshi,¹⁰ Kosei Matsue,¹¹ Kiyohiko Hatake,³ and Kazuo Oshimi^{1,2}

¹Pathology Project for Molecular Targets and ²Division of Pathology, The Cancer Institute, Japanese Foundation for Cancer Research, Tokyo, Japan; ³Division of Hematology, The Cancer Institute Hospital, Japanese Foundation for Cancer Research, Tokyo, Japan; ⁴Department of Pathology, Faculty of Medicine, University of Toyama, Toyama, Japan; ⁵Pathology Division, Miyazaki Medical College Hospital, University of Miyazaki, Miyazaki, Japan; ⁶Department of Pathology, Tachikawa Sougo Hospital, Tokyo, Japan; ⁷Department of Internal Medicine, Faculty of Medicine, Saga University, Saga, Japan; ⁸Department of Diagnostic Pathology, School of Medicine, Nara Medical University, Nara, Japan; ⁹Department of Immunopathology, Kansai University of Health Sciences, Nara, Japan; ¹⁰Department of Pathology, Kameda General Hospital, Chiba, Japan; ¹¹Division of Hematology/Oncology, Department of Medicine, Kameda General Hospital, Chiba, Japan; and ¹²Eisai Research Institute of Boston, Andover, MA

Diagnostic errors in distinguishing between malignant and reactive processes can cause serious clinical consequences. We report 10 cases of unrecognized self-limited natural killer-cell proliferation in the stomach, designated as lymphomatoid gastropathy (LyGa). This study included 5 men and 5 women (age, 46-75 years) without any gastric symptoms. Gastroscopy showed elevated lesion(s) (diameter, ~ 1 cm). Histologically, medium-sized to large atypical cells diffusely infiltrated the lamina propria and, occasion-

ally, the glandular epithelium. The cells were CD2^{+/+}, sCD3⁻, cCD3⁺, CD4⁻, CD5⁻, CD7⁺, CD8⁻, CD16⁻, CD20⁻, CD45⁺, CD56⁺, CD117⁻, CD158a⁻, CD161⁻, T cell-restricted intracellular antigen-1⁺, granzyme B⁺, perforin⁺, Epstein-Barr early RNA⁻, T-cell receptor $\alpha\beta$ ⁻, and T-cell receptor $\gamma\delta$ ⁻. Analysis of the 16 specimens biopsied from 10 patients led to a diagnosis of lymphoma or suspected lymphoma in 11 specimens, gastritis for 1 specimen, adenocarcinoma for 1 specimen, and LyGa or suspected LyGa for 3 specimens.

Most lesions underwent self-regression. Three cases relapsed, but none of the patients died. According to conventional histopathologic criteria, LyGa is probably diagnosed as lymphoma, especially as extranodal natural killer/T-cell lymphoma, nasal type. However, LyGa is recognized as a pseudomalignant process because of its clinical characteristics. The concept of LyGa should be well recognized. (Blood. 2010;116(25):5631-5637)

Introduction

The World Health Organization classification of tumors of hematopoietic and lymphoid tissues lists > 60 types of lymphomas.¹ Several reactive or borderline lesions related to these overt lymphomas are well known. Some benign lymphoproliferative disorders, including infectious mononucleosis, drug-induced lymphadenitis especially related to anticonvulsants, and histiocytic/subacute necrotizing lymphadenitis (Kikuchi-Fujimoto disease),^{2,3} are occasionally misdiagnosed as malignancy because these lesions histopathologically mimic lymphoma.⁴ They are basically self-limited and require no cytoreductive therapies. Lymphomatoid papulosis, lymphomatoid granulomatosis, and methotrexate-associated lymphoproliferative disorder⁵ are listed as borderline lesions with uncertain malignant potential according to the World Health Organization. These disorders may also be diagnosed as overt lymphoma. Moreover, even if they are properly diagnosed, selection of a treatment strategy is then a matter of discussion because some of these cases undergo spontaneous regression. Therefore, conservative therapies are primarily favored in such cases, and these lesions should be treated as lymphoma only if they are clinically malignant. In any case, at the time these lesions are evaluated with biopsy specimens, the possibility of

being benign should be well considered, and overtreatment must be carefully avoided.

Here, we report 10 cases of a pseudomalignant disorder caused by an unrecognized atypical natural killer (NK)-cell proliferation in the stomach; we have designated this disorder as lymphomatoid gastropathy (LyGa). According to conventional histopathologic criteria, such lesions are diagnosed as lymphoma, especially as extranodal NK/T-cell lymphoma, nasal type. However, considering its clinical characteristics, LyGa is recognized as a pseudomalignant process because it spontaneously regresses without any treatment.

Methods

Patients

During the 11-year period between 1998 and 2009, there were 10 cases of CD56-positive atypical lymphoid cell proliferation in the stomach (patients 1-3 presented at the Cancer Institute and patients 4-10 were referred to K.T. for consultation). The clinical records and pathology materials of the cases were reviewed.

Submitted June 15, 2010; accepted August 31, 2010. Prepublished online as *Blood* First Edition paper, September 9, 2010; DOI 10.1182/blood-2010-06-290650.

The publication costs of this article were defrayed in part by page charge

payment. Therefore, and solely to indicate this fact, this article is hereby marked "advertisement" in accordance with 18 USC section 1734.

© 2010 by The American Society of Hematology

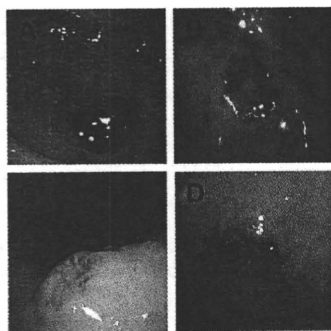


Figure 1. Gross appearance of LyGa. Cases 3 (A), 3 (B), 4 (C), and 10 (D) are shown.

Immunophenotyping and Epstein-Barr virus detection

Immunohistochemical examination was performed with Autostainer (Dako); dextran-polymer method (EnVision+; Dako); and antibodies against CD2, CD3, CD4, CD5, CD7, CD8, CD20, CD30, CD45, CD56, CD68 (KP1 or PGM1), T cell-restricted intracellular antigen-1 (TIA1), granzyme B, anaplastic lymphoma kinase, myeloperoxidase, Ki67, and T-cell receptor β F1 (TCR β F1). For flow cytometry, the following antibodies were used: CD2, CD3, CD7, CD56, TCR $\alpha\beta$, TCR $\gamma\delta$, TCRVa24, CD158a, and CD161. The presence of Epstein-Barr virus (EBV) was assessed by in situ hybridization for Epstein-Barr early RNA (EBER).

Polymerase chain reaction analysis for TCR γ gene rearrangement

DNA was extracted from the paraffin sections with the use of Recover All Total Nucleic Acid Isolation according to the manufacturer's instructions (Ambion). A seminested protocol involving 2 rounds of polymerase chain reaction (PCR) was used for the amplification of the rearranged TCR γ gene with the use of the primers TV γ , 5'-AGGGTTGTGTTGGAATCAGG-3'; TJ γ -out, 5'-CGTCGACAACAAGTGTGTCCAC-3'; and TJ γ -in, 5'-GGATCCACTGCCAAAGAGTTTCTT-3'. The 5' end of TJ γ -I was labeled by cyanine 5 for fragment analysis. In all the experiments, monoclonal (Jurkat cells) and polyclonal (placental tissue from a healthy person) controls were run in parallel with the samples. The PCR products were analyzed with CEQ8000 (Beckman Coulter Inc). DNA from each sample was amplified ≥ 6 times.

Results

Clinical history

Of the 10 patients in this study, 5 were men and 5 were women. The age of these patients ranged from 46 to 75 years. Three patients had a history of gastric cancer, of whom 1 had previously undergone endoscopic mucosal resection 2 times (case 1) and the other 2 had previously undergone partial gastrectomy (cases 3 and 8). At the time of the study, 3 patients had diabetes mellitus (cases 1, 2, and 9) and 4 had hypertension (cases 2, 7, 9, and 10). Blood cell counts and chemistry, including lactic dehydrogenase levels, were within the normal limits in all patients. There were no gastric symptoms at the time of gastroscopy. The 3 patients with history of gastric cancer underwent gastroscopy during a follow-up study for gastric cancer, and the procedure was performed on the other patients as a secondary checkup because gastric x-ray screening for cancer in these patients showed the presence of abnormal shadows. Gastroscopy showed ulcerative or elevated lesion(s) ~ 1 cm in diameter in the stomach (Figure 1A-D). The pathologists of the institutions where the biopsies of the patients with LyGa were first performed

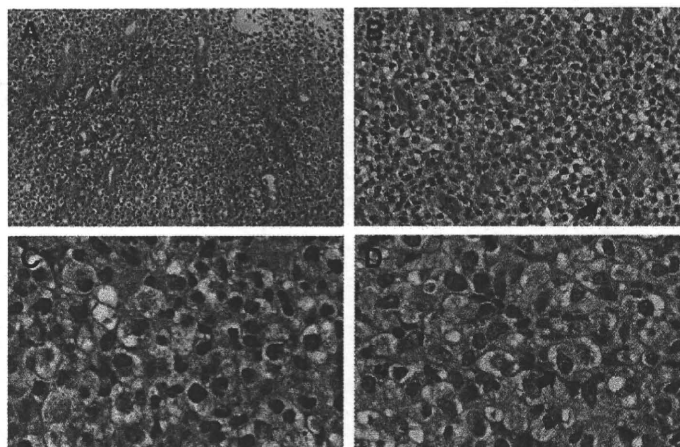
diagnosed the patients' conditions as lymphoma or suspected lymphoma (cases 1, 2, 5-8, and 10), gastritis with histiocytic infiltration (case 3), and poorly differentiated adenocarcinoma (case 4). In case 3, the specimen was biopsied again 11 months later, and the patient's condition was then diagnosed as NK/T-cell lymphoma. Cases 5 and 9 were suspected of having lymphoma, and the pathologist consulted with one of the authors (K.T.), leading to the diagnosis of LyGa. In case 5, another biopsy was performed 3 weeks after the first biopsy for flow cytometry.

An extensive workup, including ultrasonography (cases 1-4 and 9), computed tomographic (cases 1-4 and 6-9), and 2-[fluorine-18]fluoro-2-deoxy-D-glucose positron emission tomographic scans (cases 2, 4, 6, and 8); colonoscopy (cases 2, 4-6, and 9); and bone marrow biopsy (cases 1-4 and 7-9), was performed. The results showed no evidence of lymphoma in sites other than the stomach. Multiple serologic studies for celiac disease showed no evidence of high titers of anti-gliadin immunoglobulin A and immunoglobulin G antibodies in cases 2 and 4. Gastroscopy and biopsy were performed 1-4 months after the biopsies, which showed no evidence of lymphoma (cases 1, 2, 5, 7 and 10). Cases 4 and 6 underwent partial gastrectomy 1 month after the initial biopsy diagnosis, resulting in no evidence of carcinoma or lymphoma. All the patients were carefully watched and followed up without chemotherapy. Except in the case of patients 3, 8, and 9, none of the other patients had any recurrences. In case 3, the patient developed 3 lesions; on follow-up examination 11 months later, the lesions had regressed, and a new lesion was detected. The new lesion also regressed in 1 month from the second biopsy. In case 8, the patient developed another lesion 7 months after self-regression of the first lesion; this new lesion also regressed in 3 months without any treatment. In case 9, the first lesion could not be detected 4 months from the first biopsy; however, 2 new lesions were detected. After another 4 months, these 2 lesions could also not be detected, and 2 new lesions were identified. The consequence of the 2 lesions last detected is unknown because the patient refused further gastroscopic examination.

Morphology

Grossly, the lesions were flat elevations with or without a shallow depression and were approximately 1 cm in diameter (Figure 1A-D). The atypical cells diffusely infiltrated the lamina propria and occasionally into the glandular epithelium (Figure 2A), simulating the lymphoepithelial lesion seen in extranodal marginal zone lymphoma of mucosa-associated lymphoid tissue lymphoma, which was designated as lymphoepithelial-like lesion by NK cells (Figure 2B). In some cases, necrosis was present, but there were no angiocentric or angiodestructive growth patterns or apoptotic bodies. Mitotic figures were occasionally present. The atypical cells were medium to large with moderate to abundant clear or slightly eosinophilic cytoplasm. The nuclei were generally round to oval, but some were irregular and indented, with fine chromatin and a few inconspicuous nucleoli. These cytomorphologic features somewhat give a histiocyte-like impression. Interestingly, specimens for all the patients contained a variable proportion of cells (20%-90%) with eosinophilic granules in the cytoplasm (Figure 2C-D). In some cases, atypical cells with a prominent nucleolus were observed (Figure 2D). Small reactive lymphocyte aggregates and neutrophils may be occasionally found. Nine of the patients had *Helicobacter pylori* infection.

Figure 2. Histopathology of LyGa. The pattern of infiltration is diffuse (A; case 1; 20× objective). Atypical NK cells occasionally infiltrate the glandular epithelium (arrow), showing lymphoepithelial-like lesions by NK cells (B; case 10; 40× objective). Some atypical cells harbor large eosinophilic granules in the cytoplasm (C; case 3; 100× objective). In some cases, the nucleoli are prominent (arrow; D; case 5; 100× objective). Figures were taken with a microscope (BX51; Olympus) and a digital camera (KY-F75; Victor). Microsoft PowerPoint 2007 was used for image processing. Numeric apertures: 20×/0.40 (A), 40×/0.75 (B), 40×/0.95 (C), 60×/0.90 (D).



Immunophenotype and EBER in situ hybridization

The atypical cells were strongly positive for CD7, CD56, and cytotoxic molecule-associated proteins (TIA1, granzyme B, and perforin; Figure 3A-C). CD2 and CD45 were variably positive. CD3ε was positive in the cytoplasm, but a membrane-staining pattern was not observed (Figure 3D). Anaplastic large cell lymphoma-associated markers (CD30 and anaplastic lymphoma kinase) were negative. Other common lineage markers, including B-cell (CD20), T-cell (CD4, CD5, and CD8), and myelomonocytic (CD68 and myeloperoxidase) markers, were all negative. EBER in situ hybridization was negative. The results of immunohistochemistry for individual cases are listed in Table 1. For case 5, flow cytometric analysis was performed with the second specimen, which was obtained from a biopsy performed 3 weeks after the first biopsy (Figure 4). Grossly, although the lesion was regressing, it remained present. The atypical cells of this case expressed CD7 and CD56 (both aberrantly bright) and CD2 (negative or dim). Other T or NK cell-related markers were negative (CD3, CD16, TCRαβ, TCRγδ, TCRVa24, CD158a, and CD161).

PCR analysis for TCRγ gene rearrangement

PCR analysis for TCRγ gene rearrangement was performed 6 times per case for cases 1-4 and 8. No reproducible rearranged bands were observed (data not shown).

Discussion

Here, we report 10 cases of self-limited lymphoma-like lesions in the stomach, which we designated as LyGa. These cases were almost identical to each other in morphology and immunophenotype of atypical cells. Gross examination showed that the lesions were ulcers or flat elevations with a shallow depression, measuring approximately 1 cm in diameter. Microscopic observation showed that they were composed of sheets of large peculiar cells that showed indented nuclei and clear cytoplasm with eosinophilic granules. Immunohistochemical analysis of the atypical cells of LyGa showed that they were CD2⁻ or variably CD2⁺, CD3⁺ (cytoplasmic), CD4⁻, CD5⁻, CD7⁺, CD8⁻, CD16⁻, CD20⁻,

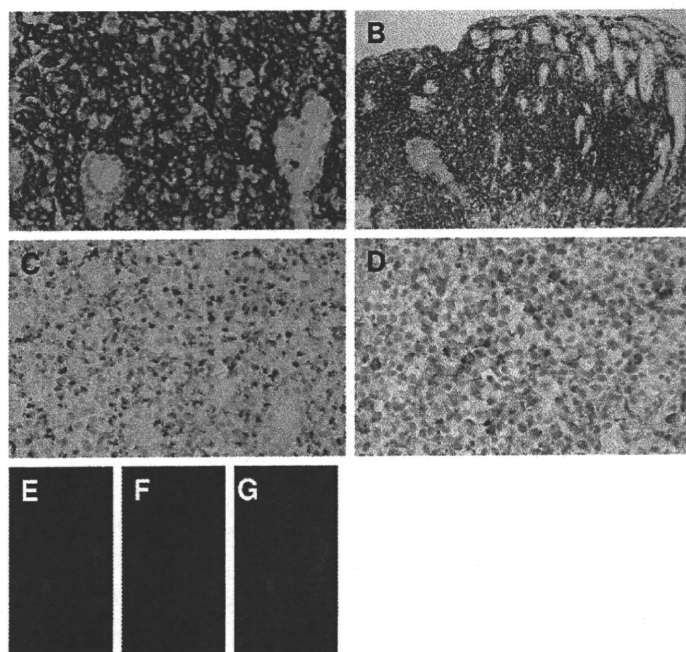


Figure 3. Immunophenotype of LyGa by immunohistochemistry. The atypical cells are positive for CD7 (A; case 5), CD56 (B; case 3), granzyme B (C; case 4), and cytoplasmic CD3ε (D; case 2). To confirm the cytoplasmic localization of CD3ε, fluorescein double immunohistochemistry for CD3ε (E) and CD56 (F) was performed (case 10). In the merged figure (G), the cytoplasmic localization of CD3ε is clearly shown, indicating that the atypical cells are of NK lineage. Figures were taken with a microscope (BX51; Olympus) and a digital camera (KY-F75; Victor). Microsoft PowerPoint 2007 was used for image processing. Numeric apertures: 40× (A,C,D), 10× (B), 60× (E-G).

Table 1. Patient characteristics and immunologic markers

	Case 1	Case 2	Case 3	Case 4	Case 5	Case 6	Case 7	Case 8	Case 9	Case 10	
Age, y	52	58	51	50	55	46	65	56	59	75	
Sex	Male	Male	Male	Female	Male	Male	Female	Female	Female	Female	
Past history	Two individual early gastric cancers at the ages of 48 and 51 y	NP	Advanced gastric cancer at the age of 47 y	NP	NP	NP	NP	Advanced gastric cancer at the age of 52	NP	NP	
<i>H pylori</i>	-	+	+	+	+	+	+	+	+	+	
Original pathologic diagnosis	NKT-cell lymphoma	NKT-cell lymphoma	Gastritis with histiocytosis. NKT-cell lymphoma*	Adenocarcinoma	Lymphoma, s/o LyGa*	NK/T-cell lymphoma; NK/T-cell lymphoma*	T-cell lymphoma	T-cell lymphoma; NK/T-cell lymphoma*	Lymphoma, s/o LyGa, s/o LyGa*	T-cell lymphoma	
Follow-up examinations, days from the initial biopsy	45, 73, 276, 577, 1165	55, 239, 442, 675, 896, 1121, 1497	336, 1, 365, 484, 701, 1065, 1429, 1793	41, 167, 1360	13, 1132	50, 156†	38, 81, 137, 207, 361, 515, 742, 1029, 1281, 1515	98, 154, 236, 256, 333, 462, 565, 790	113, 123†	30, 59, 143, 232, 354	
Patient status	Well at 145 mo	Well at 50 mo	Well at 60 mo	Well at 46 mo	Well at 33 mo	Well at 60 mo	Well at 56 mo	Well at 29 mo	Well at 18 mo	Well at 12 mo	
Treatment	Observation	Observation	Observation	Subtotal gastrectomy	Observation	Total gastrectomy	Observation	Observation	Observation	Observation	
CD2	-	+w	+w	+w	-	+	+w	-	+	+	
CD3	+	+	+	+	+	+	+	+	+	+	
CD4	ND	-	-	-	-	-	-	-	-	-	
CD5	-	-	-	-	+	+	-	-	+	+	
CD7	+	+	+	+	-	-	+	-	-	-	
CD8	ND	-	-	ND	-	-	-	-	-	-	
CD20	-	-	-	-	-	-	-	-	-	-	
CD56	+	+	+	+	+	+	+	+	+	+	
Cytotoxic molecules	TIA1*	TIA1*, granzyme B*, perforin*	TIA1*, granzyme B*, perforin*	TIA1*, granzyme B*, perforin*	Granzyme B*	TIA1*, Perforin*	Perforin*	TIA1*	Granzyme B*	Granzyme B*	
EBER	-	-	-	-	-	-	-	-	-	-	
Other markers	CD16 ⁺ , beta1F1 ⁻	CD16 ⁺ , CD30 ⁺ , CD45 ^w , CD57 ⁺ , CD68 ⁺ , CD123 ⁺ , beta1F1 ⁻ , ALK ⁻ , MIB1 index 10%	CD16 ⁺ , CD30 ⁺ , CD45 ^w , CD68 ⁺ , CD123 ⁺ , beta1F1 ⁻ , ALK ⁻ , MIB1 index 30%	CD16 ⁺ , CD45 ⁺ , CD68 ⁺ , CD123 ⁺ , beta1F1 ⁻ , CD43 ⁺	TCRαβ ⁺ , TCRγδ ⁺ , CD161 ⁺ , TCRVα24 ⁺ , CD16 ⁺ , CD158a ⁻				CD10 ⁻ , CD21 ⁻ , BCL2 ⁺ , CD45RO ⁺ , CD68 ⁺ , MIB1 index 20%		MIB1 index 20%, CD21 ⁻

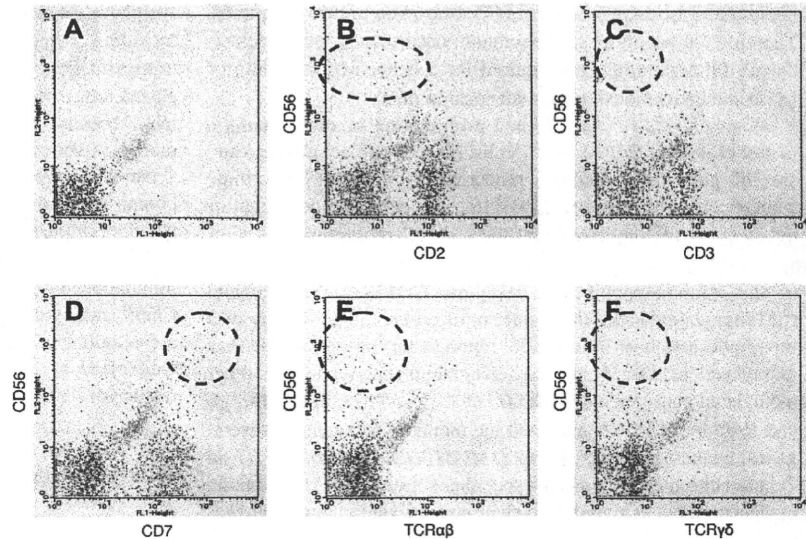
NP indicates nothing in particular; s/o, suspected of; ND, not done; and +w, weakly positive.

*In case 3, 5, 6, 8 and 9, multiple biopsies showed the presence of LyGa.

†LyGa is present on follow-up examination.

‡In follow-up examinations, days of gastrectomy or gastroscopy with or without biopsy from the initial biopsy are described.

Figure 4. Immunophenotype of LyGa by flow cytometry. Flow cytometry was performed for case 5. The atypical cells were CD56^{bright}, CD2^{dim} (B), CD3⁻ (C), CD7^{bright} (D), TCR $\alpha\beta$ ⁻ (E), and TCR $\gamma\delta$ ⁻ (F). (A) Negative control.



CD45⁺, CD56⁺, CD117⁻ and positive for cytotoxic molecule-related proteins (TIA1⁺, granzyme B⁺, and perforin⁺). This immunophenotype is highly suggestive of extranodal NK/T-cell lymphoma of the nasal type, which usually arises in extranodal sites, especially in the nasal cavity.^{1,6,7}

Extranodal NK/T-cell lymphoma of the nasal type is rarely seen in Western countries and is more common in Asia and in Central and South American countries.^{1,6,7} It accounts for ~2%,⁸ 6%,⁹ 8%,¹⁰ and 5%¹¹ of all newly diagnosed lymphoma cases in Japan, Hong Kong, Korea, and Taiwan, respectively. Histologically, the lymphoma often has an angiocentric and angiodestructive infiltrate of atypical lymphocytes of various sizes leading to extensive necrosis.¹ The immunophenotype of neoplastic cells usually indicates that they are of NK-cell lineage (surface CD3⁻, cytoplasmic CD3⁺, CD5⁻, and CD56⁺) but are occasionally of T-cell lineage by definition.¹ In previous studies, neoplastic cells in almost all the cases were found to be infected by EBV.^{12,13} In localized diseases, the survival rate has recently improved with a combination of upfront radiotherapy and chemotherapy, whereas almost all patients with extensive disease die within a year after diagnosis.¹⁴⁻¹⁶

Of the 16 biopsied specimens in this study, 11 were diagnosed with lymphoma or suspected lymphoma. Fortunately, however, LyGa has several characteristic features that are not consistent with extranodal NK/T-cell lymphoma. First, the stomach is not a common site of origin in the case of NK/T-cell lymphoma. To the best of our knowledge, there are 10 reported cases of extranodal NK/T-cell lymphoma involving the stomach, and the lesions were not limited to the stomach in any of these cases.¹⁷⁻²¹ Second, although some of the cases of LyGa showed necrosis, but angiocentric or angiodestructive growth patterns, and prominent apoptotic bodies, which are common features of extranodal NK/T-cell lymphoma,¹ were not observed. Third, LyGa may show epithelial invasion, that is, lymphoepithelial-like lesion by NK cells. Fourth, the cytomorphology of LyGa is atypical for extranodal NK/T-cell lymphoma. Although the cytologic spectrum of extranodal NK/T-cell lymphoma is broad,¹ to the best of our knowledge, large eosinophilic cytoplasmic granules seen in the atypical cells of LyGa have never been observed in the histopathology section of extranodal NK/T-cell lymphoma although finer granules can often be seen in Giemsa-stained cytologic preparations. Finally, EBER in situ hybridization, which is almost always positive in NK/T-cell

lymphoma of the nasal type,^{1,12,13} is consistently negative in LyGa. In addition, a differential diagnosis of CD56⁺ T-cell neoplasm with extensive loss of T-cell markers may be considered. In particular, the immunophenotype of LyGa overlaps the immunophenotype observed in some cases of enteropathy-associated T-cell lymphoma (type II).²² However, the negative PCR results for the TCR γ gene rearrangement (performed in cases 1-4 and 8; data not shown) were inconsistent with results obtained for T-cell lymphomas.

Vega et al²³ reported a similar case of atypical NK-cell proliferation probably related to gluten sensitivity mimicking NK-cell lymphoma. In that study, the 32-year-old male patient was positive for anti-gliadin antibody and had persistent multiple lesions in the stomach, small bowel, and large bowel for 3 years.²³ Two of our 10 patients were tested and found to be negative for anti-gliadin antibodies. Actually, gluten intolerance and celiac disease are extremely rare in Japan. However, the immunophenotype and morphology of the atypical cells of our patients were similar to those observed in the case of the 32-year-old man reported by Vega et al.²³ In addition, our cases shared a significant clinical feature with the case reported by Vega et al,²³ that is, "self regression." The lesions of the 32-year-old man persisted for 3 years until he was placed on a gluten- and lactose-free diet, whereas the lesions of our patients did not seem to persist for such an extended period of time. Furthermore, none of our patients were found to have intestinal lesions. These differences might be due to the different stimulants, if any, although we were unable to identify any stimulant(s) in our cases.

Two types of gastric malignant neoplasms, namely, adenocarcinoma and mucosa-associated lymphoid tissue lymphoma, are related to *H pylori* infection. Nine of the 10 cases were positive for *H pylori* infection, and 3 of the patients had a history of gastric adenocarcinoma. Normal NK cells were present in both *H pylori*-infected and uninfected gastric mucosa at approximately 6% and 15% of the infiltrating lymphocytes, respectively.²⁴ Several of our patients received *H pylori* eradication therapy, and their LyGa was observed to regress. There may be a pathogenetic relationship between *H pylori* and LyGa. However, ~82% of the Japanese population is infected with *H pylori*.²⁵ Moreover, even patients who did not undergo eradication therapy exhibited regression of LyGa. In terms of the relation of LyGa with adenocarcinoma, LyGa is more likely to be found in persons who have frequently