

Table I. Effect of TiO₂ on incidence and multiplicity of DHPN-induced alveolar hyperplasia and adenoma of the lung

Treatment	No. of rats	Alveolar hyperplasia		Lung adenoma	
		Incidence (%)	Multiplicity ## (no./cm ²)	Incidence (%)	Multiplicity # (no./cm ²)
Saline	9	9 (100)	5.91 \pm 1.19	0	0
nTiO ₂ 250 mg/ml	10	10 (100)	7.36 \pm 0.97*	1 (10)	0.10 \pm 0.10
nTiO ₂ 500 mg/ml	11	11 (100)	11.05 \pm 0.87**	4 (36)	0.46 \pm 0.21*

* $P < 0.05$, ** $P < 0.001$ versus saline control.

$P < 0.05$, ### $P < 0.001$ in trend test (Spearman's rank correlation test).

(Figure 5A). MIP1 α was slightly elevated in the mammary glands of these animals (Figure 5B); possibly, the elevated MIP1 α detected in the mammary tissue was due to contamination by MIP1 α in the serum. Recombinant MIP1 α promoted the proliferation of C3 cells in a dose-dependent manner; a slight induction could be seen at a dose of 400 pg/ml and became statistically significant at the dose of 50 ng/ml (Figure 5C). Expression of CCR1, the major receptor of MIP1 α , was observed in mammary tissue, and as in the lung, IPS of TiO₂ particles had little or no effect on CCR1 expression (data not shown). TiO₂ did not directly increase proliferation of C3 cells (supplementary Figure 3F is available at *Carcinogenesis* Online).

Discussion

To elucidate the mechanism underlying rat lung carcinogenesis by TiO₂ inhalation, we chose IPS. Although this method may be less physiological than the aerosol inhalation system, we observed that agglomerates and aggregates of TiO₂ particles from nano to micro size (mean diameter 107.4 nm) were diffusely distributed throughout the lung including peripheral alveoli, and they did not cause obstruction of the terminal bronchioles. Accordingly, IPS of TiO₂ particles can be expected to act similarly to aerosol inhalation of TiO₂.

Occupational exposure limits for TiO₂ in 13 countries or regions are 5–20 mg/m³ (20), which results in TiO₂ exposure limits of 0.27–1.07 mg/kg body wt/day; calculations based on the human respiratory volume. In the present study, a total of 1.75 mg was administered per rat for 12 weeks in the high-dose group, resulting in a dose of 0.104 mg/kg body wt/day. Therefore, the dose we used in the present study was lower than the occupational exposure limit.

TiO₂, nanoscale and larger sized is evaluated as a Group 2B carcinogen by World Health Organization/International Agency for Research on Cancer (4) based on 2 year animal aerosol inhalation studies (3). We conducted the present carcinogenesis study using a two-step initiation–promotion protocol as a surrogate for a 2 year long-term protocol. Our study demonstrated that TiO₂ particles increased the multiplicity of alveolar cell hyperplasia and adenoma in the two-step IPS-initiation–promotion protocol. We used these lesions as endpoints in carcinogenicity testing because chemically induced tumors appear to be derived from hyperplastic lesions that progress to adenoma and carcinoma (21).

Several bioassay protocols based on the two-step carcinogenesis theory have been developed as practical and sensitive assays, and the compounds that exhibit promotion activity are considered to be carcinogens (22–29). Thus, our experimental design may be a practical surrogate for the long-term lung carcinogenesis protocol.

It should be noted that proliferative lesions including alveolar cell hyperplasia and adenomas were not found in the groups subjected to TiO₂ particle administration without prior treatment of DHPN. This is due to the weak carcinogenic potential and short duration of exposure to TiO₂ particles. Using the two-step IPS-initiation–promotion protocol, however, we did observe carcinogenic activity by this weak carcinogen. Thus, the two-step IPS-initiation–promotion protocol is an appropriate system to study carcinogenesis of TiO₂ particles and approximates long-term TiO₂ inhalation studies (3,11).

We next conducted a mechanism analysis of TiO₂ particle carcinogenesis focusing on the initial events induced by exposure to TiO₂

particles. Treatment with TiO₂ resulted in a modest infiltration of inflammatory cells into the alveolar space and septal wall, but the primary effect was a marked increase in the number of macrophages in the alveoli, and many of these macrophages contained phagocytosed TiO₂ particles. Alveolar macrophages play an important role in deposition and clearance of mineral fibers/particles, and macrophage activity is known to be strongly associated with inflammatory reactions and carcinogenesis caused by fibers and particles in the lung, including asbestos (30–33). ROS are known to be produced by macrophages upon particle phagocytosis (34,35). Clinical and experimental studies indicate that ROS production and resultant oxidative stress play an important role in cellular and tissue damage, inflammation and fibrosis in the lung. In our study, a significant increase in the activity of SOD and 8-OHdG formation in the lung were observed, indicating increased ROS production and DNA damage. Because macrophages are unable to detoxify TiO₂ particles, the reaction against these particles would be continuous over an extended period of time. This condition is associated with high levels of ROS production (36) and tissue toxicity (37).

Cytokine analysis of the lung tissue indicated that among the 12 cytokines examined, expression of IL-6, GRO and MIP1 α were significantly higher in the TiO₂-treated group than in the vehicle group (supplementary Table 1 is available at *Carcinogenesis* Online). IL-6 is a pro-inflammatory cytokine that is involved in host defense as well as cancer development (38,39). IL-6 has been shown to be increased in lung tumor tissue (40,41) and in the sera of lung cancer patients (42). GRO, a member of the CXC chemokine family, has been shown to be involved in inflammatory responses, chemoattraction (43), carcinogenesis (44,45) and tumor progression (46). Thus, IL-6 and GRO may be involved in the promotion of lung carcinogenesis by TiO₂ (47).

Of the three cytokines induced by exposure to TiO₂ particles, however, we were particularly interested in MIP1 α . This cytokine was not only induced in the lung tissue of TiO₂-treated rats, but, unlike IL-6 and GRO, it was also found in the serum of these animals. MIP1 α is a member of the CC chemokine family and is primarily associated with cell adhesion and migration (17), proliferation and survival of myeloma cells (48). It is produced by macrophages in response to a variety of mineral particle-induced inflammatory stimuli (18). Our results indicate that expression of MIP1 α by alveolar macrophages enhances the proliferation of A549 cells. Expression of CCR1, the major receptor of MIP1 α , was observed in the lung tissue, rendering lung cells receptive to MIP1 α induction of proliferation. Lung damage and inflammation induced by TiO₂ particles has also been reported to be associated with increased cell proliferation of lung epithelium cells (49), which is consistent with our results.

The MEK1–ERK-signaling pathway has been shown to be involved in CCR1 signaling (48). In the present study, the MEK1-specific inhibitor PD98059 suppressed MIP1 α -induced cell proliferation and ERK phosphorylation. These results suggest that MEK1 is one of the downstream signaling molecules of MIP1 α and the MEK1–ERK-signaling pathway may be partially involved in MIP1 α signaling.

It should be noted that, in our IPS-initiation–promotion protocol, TiO₂ exposure also promoted DHPN-initiated mammary carcinogenesis. Our results suggest that MIP1 α secreted by alveolar macrophages and transported via the circulatory system caused

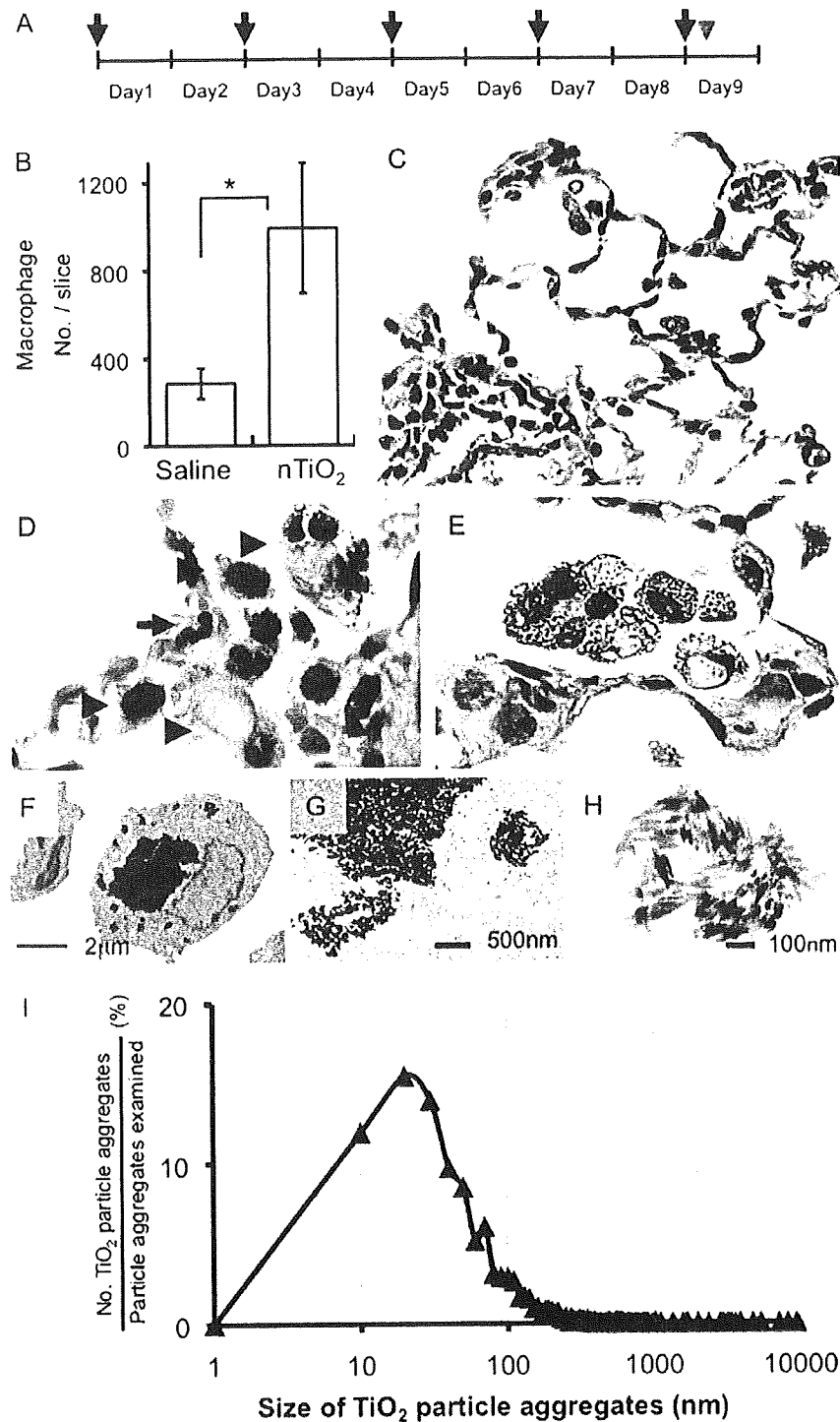


Fig. 2. TiO₂ particles in alveolar macrophages by light and electron microscopy (A) Twenty female SD rats (wild-type counterpart of *Hras128*) aged 10 weeks were treated by IPS with 0.5 ml suspension of 500 μg/ml TiO₂ particles in saline five times over a 9 day period. Arrows and arrowhead indicates IPS treatment and killing of the animals, respectively. (B) IPS of TiO₂ particles significantly increased the number of macrophages in the alveoli. (C) Inflammatory reactions were observed in the lung with slight infiltration of macrophages, neutrophils and lymphocytes. (D) TiO₂ particles were observed in alveolar macrophages (hematoxylin and eosin staining). Arrowheads indicate macrophages and the smaller cell indicated by the arrow is a neutrophil with its characteristic multilobular nucleus. (E) The multinucleated cells containing these particles were positive for the macrophage marker CD68 (Alkaline phosphatase reaction, red color). (F) TEM findings showed that TiO₂ particles of various sizes (~50 nm to 5 μm) were observed phagocytosed by alveolar macrophages. (G) Electron dense bodies were aggregates of TiO₂ particles. (H) TEM findings of TiO₂ particles in saline suspension before IPS. The shape of the TiO₂ particle aggregates was similar to those observed in macrophages. (I) The size distribution of TiO₂ particle aggregates: of 2571 particle aggregates examined, 1970 (77.1%) were <100 nm. The average size was 107.4 nm and the median size was 48.1 nm.

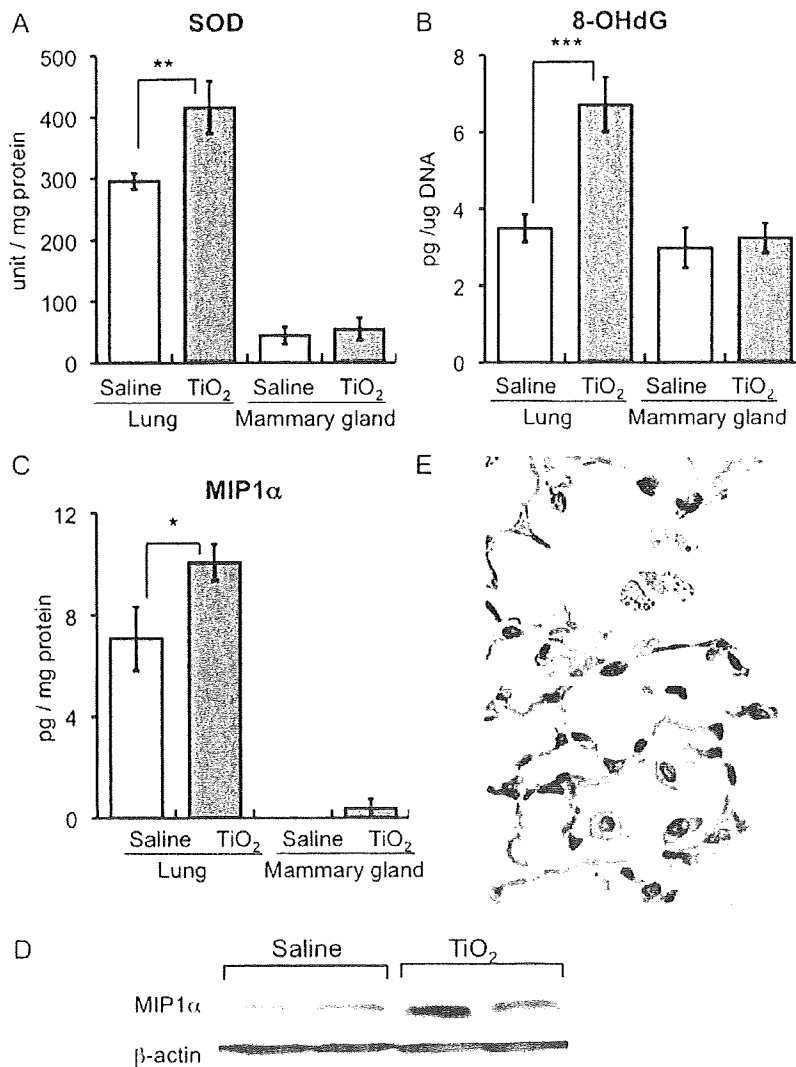


Fig. 3. Inflammatory factors upregulated in the lungs of wild-type rats by IT-spraying of TiO₂ particles in the IPS 9 day study (A) SOD activity and (B) 8-OHdG level in wild-type rats treated with TiO₂ particles or saline. (C) MIP1 α protein level was significantly increased (142%) in the lung tissue of wild-type rats treated with TiO₂ (suspension array analysis). MIP1 α was detected in the mammary gland of the TiO₂ group but not in the vehicle group. (D) In western blotting, expression of MIP1 α was increased in the TiO₂ group compared with vehicle group. (E) MIP1 α was immunohistochemically detected in alveolar macrophages containing TiO₂ particles (upper) but was not detected in macrophages of rats that were not exposed to TiO₂ particles (lower).

proliferation of mammary epithelial cells and thereby promoted mammary carcinogenesis. As with the lung, CCR1 was expressed by mammary cells, rendering these cells receptive to MIP1 α induction of proliferation. While MIP1 α secreted by alveolar macrophages would be diluted by the blood volume and while these levels may not be high enough to increase mammary cell proliferation in a short *in vitro* proliferation assay, it is possible that continuous low level stimulation over the course of 12 weeks could increase mammary cell proliferation in the environment of the mammary gland *in vivo*. Another possibility is that TiO₂ particles may act directly on the mammary gland after translocation to the mammary gland from the lung. However, TiO₂ exposure of mammary carcinoma cells did not induce proliferation *in vitro*. It must be understood that promotion of DHPN-induced mammary carcinogenesis by TiO₂ particles was observed in *Hras*128 female rats, and these animals are very highly susceptible to mammary carcinogenesis (50). Although, the effects we observed on promotion of mammary carcinogenesis in these animals may not be directly relevant to most humans, people at high risk for mammary

carcinogenesis, such as individuals harboring BRCA mutations, may be a relevant population as regards the risk presented by nanoscale TiO₂.

Although our observations are based on results obtained with a mixed population of nanoscale and larger sized particle aggregates, size analysis indicated that 80.1% of them were nanoscale (<100 nm in diameter) in the 16 week IPS-initiation-promotion study and 76.6% were nanoscale in the IPS 9 day study. Thus, the results can be interpreted as being strongly associated with nanoscale particle aggregates.

In conclusion, the IPS-initiation-promotion protocol detected TiO₂ carcinogenic activity in the rat lung and is therefore comparable, at least for TiO₂ inhalation, to a long-term whole body inhalation carcinogenesis study. We also elucidated a plausible mechanism for the carcinogenic effect of TiO₂ particles in the rat lung. Phagocytosis of TiO₂ particles by alveolar macrophages resulted in ROS production and DNA damage and increased expression of MIP1 α . MIP1 α in turn was able to enhance proliferation of lung epithelium cells. Thus, lung

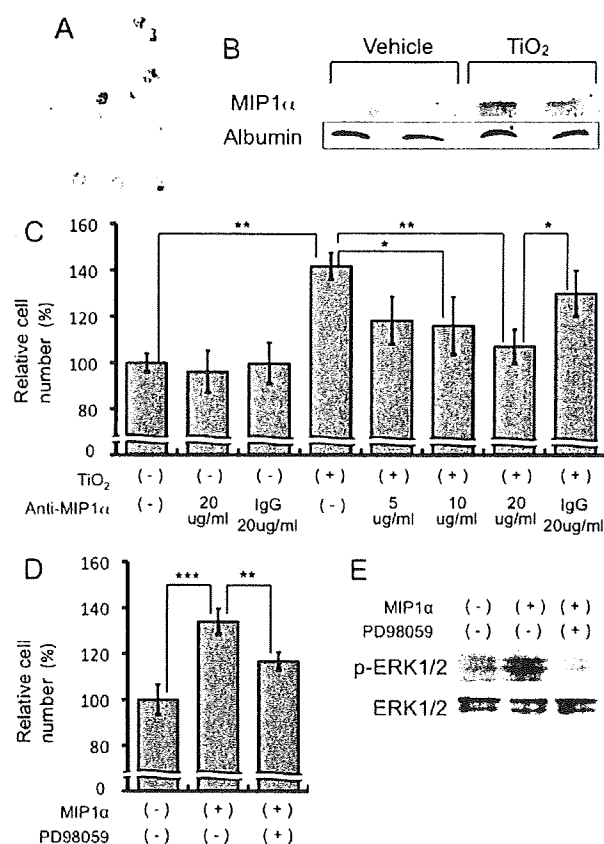


Fig. 4. Growth stimulation effects of conditioned medium from alveolar macrophages on human lung cancer cell lines. (A) Primary cultured alveolar macrophages of rats were treated with TiO₂ particles. (B) MIP1α was detected in the culture medium. (C) The number of A549 cells was significantly increased by addition of conditioned medium from alveolar macrophages treated with TiO₂ particles. MIP1α neutralizing antibody attenuated this effect in a dose-dependent manner. Irrelevant IgG was used as control antibody. (D) MIP1α-induced cell proliferation was significantly suppressed by the ERK inhibitor PD98059. (E) MIP1α increased ERK phosphorylation and PD98059 diminished this phosphorylation.

tissue exposed to TiO₂ particles exhibits increase in both DNA damage and proliferation. Importantly, a similar mechanism would function in humans in the promotion of lung carcinogenesis associated with inhalation of TiO₂ particles and other nanoparticles with the capacity to form aggregates. In addition, TiO₂ administered to the lung had carcinogenic activity in the *Hras*128 transgenic rat mammary gland; this carcinogenic activity is probably mediated via serum MIP1α resulting from expression of MIP1α by alveolar macrophages. This finding may indicate that exposure of TiO₂ particles is a risk factor for mammary carcinogenesis in predisposed populations, such as individuals with BRCA mutations.

Supplementary material

Supplementary Figures 1–3 and Tables 1 and 2 can be found at <http://carcin.oxfordjournals.org/>

Funding

Health and Labour Sciences Research Grants, Ministry of Health, Labour and Welfare, Japan (Research on Risk of Chemical Substance 21340601, H18-kagaku-ippan-007); a grant-in-aid for the Second

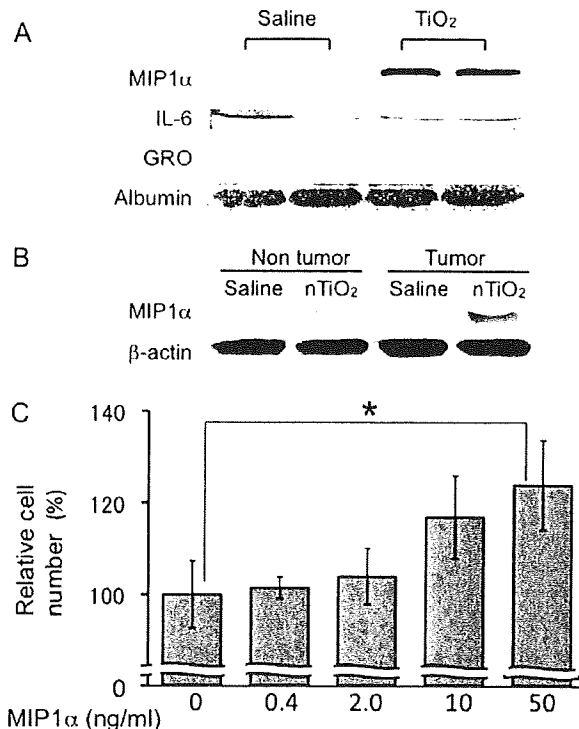


Fig. 5. Promotion effects of MIP1α on proliferation of a rat mammary cancer cell line, C3 (A) MIP1α was detected in the serum of the *Hras*128 rats treated with TiO₂ but not in vehicle control rats in the 16 week study. No difference in IL-6 in the serum was observed and GRO was not detected in the serum. (B) MIP1α levels are slightly elevated in non-tumor and tumor tissue of the mammary gland of animals treated by IPS with TiO₂ particles in the 16 week study. (C) Recombinant MIP1α increased the number of rat mammary carcinoma C3 cells in a dose-dependent manner ($P = 0.0127$).

Term Comprehensive 10 Year Strategy for Cancer Control, Ministry of Health, Labour and Welfare, Japan; grants-aid for Cancer Research, Ministry of Education, Culture, Sports, Science and Technology.

Acknowledgements

Conflict of Interest Statement: None declared.

References

- Oberdorster, G. (2002) Toxicokinetics and effects of fibrous and nonfibrous particles. *Inhal. Toxicol.*, **14**, 29–56.
- Romundstad, P. et al. (2001) Cancer incidence among workers in the Norwegian silicon carbide industry. *Am. J. Epidemiol.*, **153**, 978–986.
- Pott, F. et al. (2005) Carcinogenicity study with nineteen granular dusts in rats. *Eur. J. Oncol.*, **10**, 249–281.
- Baan, R. et al. (2006) Carcinogenicity of carbon black, titanium dioxide, and talc. *Lancet Oncol.*, **7**, 295–296.
- Schulte, P. et al. (2008) Occupational risk management of engineered nanoparticles. *J. Occup. Environ. Hyg.*, **5**, 239–249.
- Maynard, A.D. et al. (2006) Safe handling of nanotechnology. *Nature*, **444**, 267–269.
- Scheringer, M. (2008) Nanocotoxicology: environmental risks of nanomaterials. *Nat. Nanotechnol.*, **3**, 322–323.
- Borm, P. et al. (2006) Research strategies for safety evaluation of nanomaterials, part V: role of dissolution in biological fate and effects of nanoscale particles. *Toxicol. Sci.*, **90**, 23–32.
- Phalen, R.F. (1976) Inhalation exposure of animals. *Environ. Health Perspect.*, **16**, 17–24.

10. Mauderly, J.L. (1997) Relevance of particle-induced rat lung tumors for assessing lung carcinogenic hazard and human lung cancer risk. *Environ. Health Perspect.*, **105** (suppl. 5), 1337–1346.
11. Roller, M. *et al.* (2006) Lung tumor risk estimates from rat studies with not specifically toxic granular dusts. *Ann. N. Y. Acad. Sci.*, **1076**, 266–280.
12. Imaida, K. *et al.* (1996) Initiation-promotion model for assessment of carcinogenicity: medium-term liver bioassay in rats for rapid detection of carcinogenic agents. *J. Toxicol. Sci.*, **21**, 483–487.
13. IARC (1999) The use of short- and medium-term tests for carcinogens and data on genetic effects in carcinogenic hazard evaluation. Consensus report. *IARC Sci. Publ.*, **146**, 1–18.
14. Asamoto, M. *et al.* (2000) Transgenic rats carrying human c-Ha-ras proto-oncogenes are highly susceptible to N-methyl-N-nitrosourea mammary carcinogenesis. *Carcinogenesis*, **21**, 243–249.
15. Han, B.S. *et al.* (2002) Inhibitory effects of 17 β -estradiol and 4-n-octylphenol on 7,12-dimethylbenz[*a*]anthracene-induced mammary tumor development in human c-Ha-ras proto-oncogene transgenic rats. *Carcinogenesis*, **23**, 1209–1215.
16. Ohnishi, T. *et al.* (2007) Possible application of human c-Ha-ras proto-oncogene transgenic rats in a medium-term bioassay model for carcinogens. *Toxicol. Pathol.*, **35**, 436–443.
17. Terpos, E. *et al.* (2005) Significance of macrophage inflammatory protein-1 α (MIP-1 α) in multiple myeloma. *Leuk. Lymphoma*, **46**, 1699–1707.
18. Driscoll, K.E. *et al.* (1993) Macrophage inflammatory proteins 1 and 2: expression by rat alveolar macrophages, fibroblasts, and epithelial cells and in rat lung after mineral dust exposure. *Am. J. Respir. Cell Mol. Biol.*, **8**, 311–318.
19. Hamaguchi, T. *et al.* (2006) Establishment of an apoptosis-sensitive rat mammary carcinoma cell line with a mutation in the DNA-binding region of p53. *Cancer Lett.*, **232**, 279–288.
20. IARC (1989) Titanium dioxide. *IARC monograph Evaluation of carcinogenic risks to humans*. IARC Scientific Publications, Lyon, vol. 47, pp. 307–326.
21. Stoner, G.D. *et al.* (1993) Lung tumors in strain A mice: application for studies in cancer chemoprevention. *J. Cell. Biochem. Suppl.*, **17F**, 95–103.
22. Pitot, H.C. *et al.* (1978) Biochemical characterisation of stages of hepatocarcinogenesis after a single dose of diethylnitrosamine. *Nature*, **271**, 456–458.
23. Peraino, C. *et al.* (1971) Reduction and enhancement by phenobarbital of hepatocarcinogenesis induced in the rat by 2-acetylaminofluorene. *Cancer Res.*, **31**, 1506–1512.
24. Ito, N. *et al.* (2003) A medium-term rat liver bioassay for rapid *in vivo* detection of carcinogenic potential of chemicals. *Cancer Sci.*, **94**, 3–8.
25. Ito, N. *et al.* (1988) Wide-spectrum initiation models: possible applications to medium-term multiple organ bioassays for carcinogenesis modifiers. *Jpn. J. Cancer Res.*, **79**, 413–417.
26. IARC (1980) Long-term and short-term screening assays for carcinogens: a critical appraisal. *IARC Scientific Publications, Lyon, vol. 83* (suppl. 2), pp. 1–146.
27. Konishi, Y. *et al.* (1987) Lung carcinogenesis by N-nitrosobis(2-hydroxypropyl)amine-related compounds and their formation in rats. *IARC Sci. Publ.*, **82**, 250–252.
28. Nishikawa, A. *et al.* (1994) Effects of cigarette smoke on N-nitrosobis(2-oxopropyl)amine-induced pancreatic and respiratory tumorigenesis in hamsters. *Jpn. J. Cancer Res.*, **85**, 1000–1004.
29. Yamanaka, K. *et al.* (1996) Exposure to dimethylarsinic acid, a main metabolite of inorganic arsenics, strongly promotes tumorigenesis initiated by 4-nitroquinoline 1-oxide in the lungs of mice. *Carcinogenesis*, **17**, 767–770.
30. Rom, W.N. *et al.* (1991) Cellular and molecular basis of the asbestos-related diseases. *Am. Rev. Respir. Dis.*, **143**, 408–422.
31. Heppleston, A.G. (1984) Pulmonary toxicology of silica, coal and asbestos. *Environ. Health Perspect.*, **55**, 111–127.
32. Renwick, L.C. *et al.* (2001) Impairment of alveolar macrophage phagocytosis by ultrafine particles. *Toxicol. Appl. Pharmacol.*, **172**, 119–127.
33. Rimal, B. *et al.* (2005) Basic pathogenetic mechanisms in silicosis: current understanding. *Curr. Opin. Pulm. Med.*, **11**, 169–173.
34. Wang, Y. *et al.* (2007) The role of the NADPH oxidase complex, p38 MAPK, and Akt in regulating human monocyte/macrophage survival. *Am. J. Respir. Cell Mol. Biol.*, **36**, 68–77.
35. Bhatt, N.Y. *et al.* (2002) Macrophage-colony-stimulating factor-induced activation of extracellular-regulated kinase involves phosphatidylinositol 3-kinase and reactive oxygen species in human monocytes. *J. Immunol.*, **169**, 6427–6434.
36. Dorger, M. *et al.* (2000) Comparison of the phagocytic response of rat and hamster alveolar macrophages to man-made vitreous fibers *in vitro*. *Hum. Exp. Toxicol.*, **19**, 635–640.
37. Blake, T. *et al.* (1998) Effect of fiber length on glass microfiber cytotoxicity. *J. Toxicol. Environ. Health A*, **54**, 243–259.
38. Kabir, S. *et al.* (1995) Serum levels of interleukin-1, interleukin-6 and tumour necrosis factor- α in patients with gastric carcinoma. *Cancer Lett.*, **95**, 207–212.
39. Schneider, M.R. *et al.* (2000) Interleukin-6 stimulates clonogenic growth of primary and metastatic human colon carcinoma cells. *Cancer Lett.*, **151**, 31–38.
40. Asselin-Paturel, C. *et al.* (1998) Quantitative analysis of Th1, Th2 and TGF- β 1 cytokine expression in tumor, TIL and PBL of non-small cell lung cancer patients. *Int. J. Cancer*, **77**, 7–12.
41. Matanic, D. *et al.* (2003) Cytokines in patients with lung cancer. *Scand. J. Immunol.*, **57**, 173–178.
42. Brichory, F.M. *et al.* (2001) An immune response manifested by the common occurrence of annexins I and II autoantibodies and high circulating levels of IL-6 in lung cancer. *Proc. Natl Acad. Sci. USA*, **98**, 9824–9829.
43. Rollins, B.J. (1997) Chemokines. *Blood*, **90**, 909–928.
44. Zhou, Y. *et al.* (2005) The chemokine GRO- α (CXCL1) confers increased tumorigenicity to glioma cells. *Carcinogenesis*, **26**, 2058–2068.
45. Yang, G. *et al.* (2006) The chemokine growth-regulated oncogene 1 (Gro-1) links RAS signaling to the senescence of stromal fibroblasts and ovarian tumorigenesis. *Proc. Natl Acad. Sci. USA*, **103**, 16472–16477.
46. Li, A. *et al.* (2004) Constitutive expression of growth regulated oncogene (gro) in human colon carcinoma cells with different metastatic potential and its role in regulating their metastatic phenotype. *Clin. Exp. Metastasis*, **21**, 571–579.
47. Rollins, B.J. (2006) Inflammatory chemokines in cancer growth and progression. *Eur. J. Cancer*, **42**, 760–767.
48. Lentzsch, S. *et al.* (2003) Macrophage inflammatory protein 1- α (MIP-1 α) triggers migration and signaling cascades mediating survival and proliferation in multiple myeloma (MM) cells. *Blood*, **101**, 3568–3573.
49. Baggs, R.B. *et al.* (1997) Regression of pulmonary lesions produced by inhaled titanium dioxide in rats. *Vet. Pathol.*, **34**, 592–597.
50. Tsuda, H. *et al.* (2001) High susceptibility of transgenic rats carrying the human c-Ha-ras proto-oncogene to chemically-induced mammary carcinogenesis. *Mutat. Res.*, **477**, 173–182.

Received September 27, 2009; revised January 14, 2010;
accepted January 24, 2010

MINI-REVIEW

Toxicology of Engineered Nanomaterials - A review of Carcinogenic Potential

Hiroyuki Tsuda^{1,2*}, Jiegou Xu², Yuta Sakai³, Mitsuru Futakuchi², Katsumi Fukamachi²

Abstract

Nanotechnology has considerable socioeconomic potential. Benefits afforded by engineered nanoparticles (NP: defined as being less than 100 nm in diameter) are expected to be significant in fields such as plastics, energy, electronics, aerospace and medicine. However, NPs are being introduced into the market without adequate assessment of their potential toxicities. It is urgently important to conduct risk assessment of commercial NPs and establish a framework enabling risk management which is not subordinate to their commercial production. An overview of currently available carcinogenicity risk evaluation results of NP materials raises serious questions as to their safety. NP sized titanium dioxide (nTiO₂) and carbon black (nCB) are carcinogenic to the lung of female rats, and the tumors preferentially include squamous cell morphology. Carbon nanotubes (CNT) induce mesotheliomas when applied intraperitoneally in rats and mice. Data for Fullerenes are insufficient to evaluate carcinogenic risk. Sub-chronic toxicity data indicate that, in general, NPs form aggregates and agglomerates and cause foreign body reactions at their applied sites with inflammatory cell, including macrophage, infiltration. These findings are similar to the biological effects of asbestos, a potent carcinogen, and indicate that careful assessment of NPs is indispensable.

Key words: Nanoparticles - toxicology - carcinogenicity - titanium dioxide - carbon black

Asian Pacific J Cancer Prev, 10, 975-980

Principles of Safety

The safety of our living environment can be secured by the balanced function of three elements: risk assessment, risk management and risk communication (Figure 1). The first of these elements, risk assessment, must be addressed first, since without reliable risk assessment, risk communication and risk management can not function. Importantly, for reliable risk assessment long-term animal studies are indispensable.

These principles, of course, hold true for engineered nanoparticles. Unfortunately, the risk assessment data for engineered nanoparticles are rather fragmentary. However, the available findings do present a disturbing picture of potential carcinogens entering the market place. Engineered nanoparticles included in this review include nano-size titanium dioxide (nTiO₂), carbon black (nCB), single-walled carbon nanotubes (SWCNT), multiple-walled carbon nanotubes (MWCNT) and fullerenes (C₆₀).

Metals and Metal-derived Nanoparticles: Titanium dioxide (nTiO₂)

In an inhalation study, female rats were exposed to air containing nTiO₂ (28nm in diameter) at a concentration of

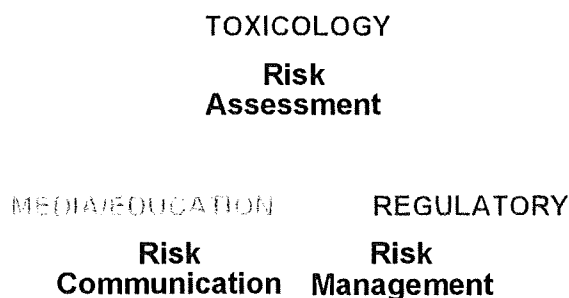

Figure 1. Principles of Safety of the Living Environment. Safety of the living environment can be secured by the balanced function of three elements: risk assessment, risk management and risk communication

7.5 mg/m³ for 4 months, then at a concentration of 15 mg/m³ for 4 months, and finally at a concentration of 10 mg/m³ for 16 months, then killed at month 30. The incidence of lung tumors (19%), benign and malignant squamous and alveolar cell tumors combined, were significantly increased compared to the clean air control group (0.5%) (Heinrich et al., 1995).

¹Nanotoxicology Project, ²Department of Molecular Toxicology, Nagoya City University Graduate School of Medical Sciences, ³Department of Drug Metabolism and Disposition, Nagoya City University Graduate School of Pharmacological Sciences, Nagoya, Japan *For correspondence: a

In another study, female rats were administered nTiO₂ by intratracheal instillation. In this study, several dosing strategies were used. Hydrophilic nano-sized nTiO₂ (21-25 nm in diameter) was applied in 5 doses of 3 mg each, 5 doses of 6 mg each, or 10 doses of 6 mg each. Hydrophobic nano-sized nTiO₂ (21 nm in diameter) was applied in 15 doses of 0.5 mg each or 30 doses of 0.5 mg each. Hydrophilic anatase nTiO₂ (200 nm in diameter) was applied in 10 doses of 6 mg each or 20 doses of 6 mg each. The nTiO₂, hydrophilic and hydrophobic nTiO₂ and hydrophilic anatase nTiO₂, was suspended in PBS with 0.5% Tween 80. The instillation was done once weekly. The animals were observed for up to 30 weeks. The incidences of lung tumors (52-69.6%), adenomas/carcinomas and squamous cell epitheliomas/carcinomas combined, in rats receiving hydrophilic nTiO₂ were significantly increased over untreated controls (0%). Anatase nTiO₂ also induced significant incidences of lung tumors (29.5-63.6%), and these tumors were similar to those induced by hydrophilic nTiO₂. The incidences of benign and malignant lung tumors in the hydrophobic nTiO₂ groups (6.7%) was not significant (Pott and Roller, 2005).

In another inhalation study, female rats were treated with TiO₂ (size, not indicated) at a concentration of 11.3mg/m³ for 24 months followed by observation for 6 months. Incidences of cystic keratinizing epitheliomas (11.7%) and squamous cell carcinomas (4.8%) were significantly greater than the control group (0.5%) (Rittinghausen et al., 1997). nTiO₂ is not carcinogenic to the skin because it does not penetrate the dermal tissue (Newman et al., 2009). Based on the studies outlined here, nTiO₂ is evaluated by WHO/IARC as a Group 2B compound (possibly carcinogenic to humans) (Baan, 2007).

Carbon-derived Nanoparticles

1. Carbon black (nCB)

Because of its long history of production and consumption, the highest number of reports concerning the carcinogenicity of carbon-derived nanomaterials are about nCB.

a) Rat studies. In an inhalation study, female rats were exposed to nCB (Printex90, 14 nm in diameter) at a concentration of 7.5 mg/m³ for 4 months and then at a concentration of 12 mg/m³ for 20 months followed by clean air for 6 months. The incidence of lung tumors (39%), benign and malignant squamous cell tumors and bronchio-alveolar cell tumors combined, was significantly increased as compared to the clean air group (0.5%) (Heinrich et al., 1995).

In another study, nCB (Printex90, 14 nm in diameter and Lamp Black 101, 98nm in diameter) was administered to female Wistar rats by intratracheal instillation. Printex90 was washed in boiling toluene and suspended in saline containing 0.25% Tween 80. The Printex90 was administered once per week for 3 weeks at a dose of 0.66 mg per rat for 3 weeks then once per week for 13 weeks at a dose of 1.0 mg per rat. Animals were observed for up to 800 days from the beginning of the study. The incidence

of cystic keratinizing epitheliomas and bronchio-alveolar cell tumors combined in Printex90 treated rats (21%) was similar to that observed in rats treated with benzo[a]pyrene and diesel emission particles and significantly elevated compared to the vehicle control group (0%). Lamp Black 101 treated rats also showed a significant increase in lung tumors compared to the control group (Dasenbrock et al., 1996).

In a second inhalation study, female Wistar rats were exposed to nCB (Printex90, 14 nm in diameter) at a concentration of 11.3 mg/m³ for four months and then at a concentration of 12.2 mg/m³ for the following 20 months. The incidence of cystic keratinizing tumors (20%), epitheliomas and carcinomas combined, was significantly increased compared to the clean air control group (0%) (Rittinghausen et al., 1997).

In the same series of experiments as the one outlined above, Printex90 was administered to female Wistar rats by intratracheal instillation. Printex90 was suspended in saline with 0.25% Tween 80 and administered 16-17 times (total dose 15 mg per animal). Animals were observed for up to 24 months. In rats receiving Printex90, the incidence of cystic keratinizing epitheliomas (19%) was significantly increased compared to saline treated animals (0%). Rats were also treated with purified Lamp Black: the treatment regimen was the same as for Printex90. Tumor incidence in these rats (6.3%) was not significantly elevated (Rittinghausen et al., 1997).

In a fifth study, nCB (Printex90, 14 nm in diameter and Lamp Black 101, 98nm in diameter; Degussa) was administered to female Wistar rats by intratracheal instillation. Printex90 was washed in boiling toluene and suspended in saline containing 0.25% Tween 80. The Printex90 was applied once per week for 3 weeks at a dose of 0.66 mg per rat for 3 weeks then once per week for 13 weeks at a dose of 1.0 mg per rat. Animals were observed for up to 800 days from the beginning of the study. The incidence of cystic keratinizing epitheliomas and bronchio-alveolar cell tumors combined in Printex90 treated rats (21%) was similar to that observed in rats treated with benzo[a]pyrene and diesel emission particles and significantly elevated compared to the vehicle control group (0%). Lamp Black 101 treated rats also showed a significant increase in lung tumors compared to the control group (Dasenbrock et al., 1996).

In a sixth study, nCB (Printex90 or purified Lamp Black 101) was administered to female SPF Wistar rats intratracheal instillation. Animals were observed for up to 30 months. Several dosing strategies were used: animals were treated from 5 to 20 times with 1.5 to 6 mg nCB. Total lung tumor incidence for each treatment regimen (Printex90, 56% to over 80%; Lamp Black, 44% to 70%) was significantly elevated compared to the control group (2%) (Pott and Roller, 2005).

Based on the studies outlined here, nCB is evaluated by WHO/IARC as a Group 2B compound (possibly carcinogenic to humans) (Baan, 2007).

b) Mouse and Hamster Studies. No data are available as to carcinogenicity and related studies in mice and hamsters.

c) **Summary.** nCB is carcinogenic to the female rat inducing cystic keratinizing epitheliomas and bronchio-alveolar cell lung tumors. Mechanisms to explain why cystic squamous cell tumors were induced exclusively in female rats have not yet been elucidated. No data for carcinogenicity of nCB in mice and hamsters are available.

2. Carbon nanotubes

There are two types of carbon nanotubes: single-walled carbon nanotubes (SWCNT) are tube structures with a diameter of close to 1 nanometer and composed of a one-atom-thick layer of graphite (Figure 2, left), and multi-walled carbon nanotubes (MWCNT) are tube structures with a diameter of close to 1 nanometer and composed of two or more layers of graphite atoms (Figure 2, right).

A) SWCNT: a) Rat studies. In a short to medium-term (6 months or less) study, SWCNT (diameter 1.4 nm, length more than 1 mm agglomerate at use) was administered to male CrI:CD(SD)IGS BR rats intratracheal instillation. The SWCNT particles were suspended in PBS with 1% Tween 80 and administered one time at 1 or 5 mg/kg. Animals were observed up to 12 weeks. Multifocal small granulation tissue with deposition of aggregates of SWCNT were observed in the lung. Inflammatory cell counts of bronchoalveolar lavage (BAL) did not clearly correlate with the degree of the inflammatory reaction. Similar inflammatory changes were also observed in rats which received quartz particles (crystalline, diameter 1-3 nm). No tumors were found in any of the groups (Warheit et al., 2004).

b) Mouse studies. In a short to medium-term (6 months or less) study, SWCNT (diameter 0.8-2.2 nm, length not indicated) and cup-stacked CNT (mean diameter 80 nm, length not more than 100 nm) were administered to female BALB/c mice by subcutaneous injection. The SWCNT and CNT particles were suspended in saline and animals were injected at 2 mg per animal then observed for up to 12 weeks. The iron content of these materials was 3.5-5.0% (weight). Although inflammatory lesions in the injected site were observed, no tumors were found (Koyama et al., 2006).

In another short to medium-term (6 months or less) study, SWCNT (iron content, 26.9% weight) was administered to male B6C3F1 mice by intratracheal instillation. Unpurified SWCNT and purified (polycyclic aromatic hydrocarbon-free) SWCNT suspended in heat-inactivated mouse serum at a concentration of 2 mg/ml was administered one time at 0.1 or 0.5 ml/mouse. The animals were then observed for 7 or 90 days. Granulation tissue formation with epithelioid cell reaction was observed

in the bronchioles, respiratory ducts and alveoli. The inflammatory reaction in animals given SWCNT was more prominent than animals treated with carbon black. Neoplastic lesion development was not observed (Lam et al., 2004).

B) MWCNT: a) Rat studies. In a short to medium-term (6 months or less) study, MWCNT (average 15 carbon layers, approximate inner diameter 5 nm, outer diameter 9-10 nm) was administered to female SD rats by intratracheal instillation. The MWCNT particles were suspended in saline with 1% Tween 80 and administered one time at doses of 0.5, 2.0 and 5 mg/rat in 0.5 ml saline. The rats were killed on day 60. Small granulation tissue with deposition of MWCNT was observed in the bronchi, bronchio-alveolar space and some alveoli. No tumors were found (Muller et al., 2005).

In another study, MWCNT (MUTSUI MWCNT-7, 3500 ppm iron content; diameter 70-100 nm; approximate length 1-4 micrometers) was administered to male F344/DuCrJ rats by a single intrascrotal injection. The MWCNT particles were suspended in 0.5% methyl cellulose with 1.0% Tween 80 and administered at a dose of 20 mg/mouse. The animals were then observed until week 104. Another group of mice were treated with crocidolite (UICC grade asbestos). The incidence of disseminated mesothelioma in the peritoneal cavity was 86% in MWCNT and 0% in crocidolite groups (Sakamoto et al., 2009).

In a third study, MWCNT (11.3 nm in mean diameter, approximate length 0.7 micrometers) was administered to three groups of male Wistar rats by a single intraperitoneal injection. MWCNT with structural defects was suspended in PBS and administered at a dose of 2 or 20 mg/rat and MWCNT without structural defects was suspended in PBS and administered at a dose of 20 mg/rat. The animals were then observed for up to 104 weeks. Another group of rats was treated with 2 mg crocidolite (UICC grade asbestos) per rat. The incidence of mesothelioma in the group administered crocidolite was 34.6%, but the incidence of mesothelioma in the MWCNT groups (up to 6%) was not statistically higher than the incidence (3.8%) in the vehicle control group (Muller et al., 2009).

b) Mouse studies. In a short to medium-term (6 months or less) study, MWNT (diameter 20-150 nm, length 10-20 nm) was administered to female BALB/c mice by a single subcutaneous injection. The nano-particles were suspended in saline administered at 2 mg per mouse. The animals were then observed for up to 12 weeks. The iron content of these materials was 3.5-5.0% (weight). Although




Figure 2. Structure of a Single-walled Carbon Nanotube (SWCNT) and a Multiple-walled Carbon Nanotube (MWCNT). (Courtesy of Dr. M. Ata; National Institute of Advanced Industrial Science and Technology, Japan)

inflammatory lesions at the injected site were observed, no tumors were found (Koyama et al., 2006).

In another short to medium-term (6 months or less) study, two types of MWCNT, pure MWCNT and N-doped (nitrogen attached on the surface) MWCNT (approximately 30-50 nm in diameter and 100-300 nm in length) were administered intranasally, intratracheally, orally or intraperitoneally to male CD1 mice. The MWCNT particles were suspended in phosphate buffered saline (PBS) and administered one time at doses of 1, 2.5 or 5 mg/mouse. The animals were killed after 30 days. Intratracheal administration of MWCNT resulted in inflammatory lesions surrounding aggregates of MWCNT and hyperplastic change of the bronchial epithelium in a dose dependent manner. These changes were less intense in N-doped MWCNT. No obvious clinical symptoms were noted in mice treated through other routes (Carrero-Sanchez et al., 2006).

In a third study, MWCNT (MUTSUI MWCNT-7, 3500 ppm iron content; diameter 100 nm; approximate length 1-5 micrometers) was administered to male p53 (+/-) mouse with a C57BL/6 background by intraperitoneal injection. The MWCNT was suspended in 0.5% methyl cellulose with 1.0% Tween 80 and administered one time

at a dose of 3 mg/mouse. The animals were then observed for 25 weeks. Other groups of mice were treated with C60 and crocidolite (UICC grade asbestos) at a dose of 3 mg/mouse. The incidence of mesothelioma in the peritoneal cavity was 14/16 (87.5%) in the MWCNT group and 0% in the C60 group and 14/18 (77.8%) in the crocidolite group (Takagi et al., 2008).

c) Summary. Apparently contradictory results are reported in the rat studies. In one study, intrascrotal injection of MWCNT (approximate length 1-4 micrometers) resulted in mesothelioma in the peritoneal cavity, but intrascrotal injection of crocidolite did not induce tumor formation; in another study, mesothelioma was induced by intraperitoneal injection of crocidolite but intraperitoneal injection of MWCNT (approximate length 0.7 micrometers) did not induce tumor formation. Obviously, further studies to confirm carcinogenic potential of MWCNT, especially MWCNT of different lengths, in rats is required. SWCNT and MWCNT induced a small amount of granulation tissue formation in the bronchioles and bronchio-alveolar area in mice. In a critically important study, MWCNT was found to induce mesothelioma in p53-/- mice. Data pertaining to the carcinogenicity of SWCNT was negative in both rats and mice.

3) Fullerenes (C60/70)

Fullerene was named after Richard Buckminster Fuller, an architect who popularized the geodesic dome which resembles a spherical fullerene in appearance. C60 is composed of 60 carbons arranged at the corners of each hexagon and a bond along each edge resembling a soccer ball (Fig. 3). C70 is composed of 70 carbons (Fig. 3) and is similar in structure to C60. C60 has photocatalytic activity releasing reactive oxygen species in the presence of light.

a) Rat studies. No data is available as to carcinogenicity and related studies in rats.

b) Mouse studies. Fullerene was tested for skin tumor promotion. Female CD-1 mice were initially painted with 7,12-dimethylbenz[a]anthracene (DMBA): 20 nmol DMBA dissolved in 200 mL acetone was applied one time to shaved dorsal skin. 1 week later, a C60/C70 mixture (6:1) dissolved in benzene was applied twice a week for 25 weeks. No tumors were found in the skin. Another group of mice was treated with 12-O-tetradecanoylphorbol-13-acetate (TPA) (5mg in 200 mL acetone), a known skin tumor promoter. The incidence of tumor development in the TPA treated mice (100%) was significantly greater than in the acetone treated controls (0%). In a co-occurrent experiment ornithine decarboxylase (ODC) activity and DNA synthesis, measured by 3H-thymidine incorporation, were also increased by TPA treatment but not by C60/C70 (Nelson et al., 1993).

c) In vitro studies related to carcinogenesis. Fullerene C60 was treated with polyvinylpyrrolidone (PVP) and then dissolved in water. In the presence of rat liver microsomes,

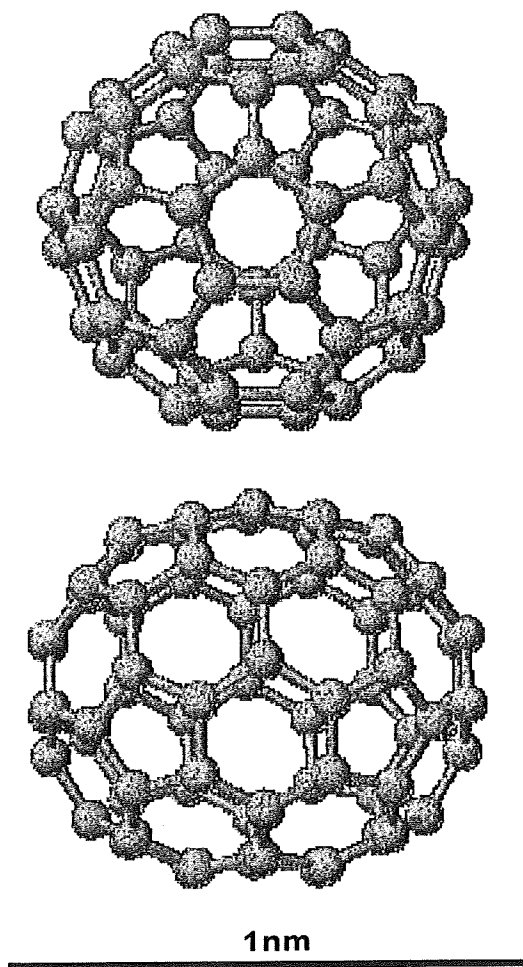


Figure 3. Structure of Fullerene 60 (C60) and Fullerene 70 (C70). (Courtesy of Dr. M. Ata; National Institute of Advanced Industrial Science and Technology, Japan)

treated C60 was mutagenic for Salmonella strains TA102, TA104 and YG3003, but only when exposed to visible light and not in the absence of light. Mutagenicity was reduced in the presence of antioxidants. The results suggest that singlet molecular oxygen radicals were generated by irradiating C60 with visible light. Further experiments indicated that the mutagenicity was due to oxidized phospholipids in the rat liver microsomes, in particular those present in the HPLC isolated linoleate fraction (Sera et al., 1996). Similarly, C60 induced peroxidation of lipids which caused oxidative liver cell injury in the presence of microsomes from hepatocytes (Kamat et al., 1998).

d) *Summary.* *In vitro*, C60 caused DNA damage when irradiated with visible light. In one *in vivo* study using mice, C60/70 did not show skin tumor promotion activity in a 26-week initiation-promotion protocol. No long-term carcinogenicity studies were reported.

Overall Evaluation and Proposal for the Future

During the development and marketing of nanomaterials, risk assessment of these new products has been perfunctory at best. While nanomaterials have undeniable benefits, their use also has undeniable potential risk. This risk must be addressed in an unbiased and thorough manner. Only after the toxicity of the various nanomaterials is understood can their true benefits be realized.

In rodent studies, nTiO₂ whether administered by inhalation or intratracheal instillation was shown to induce lung tumors with characteristic squamous cell morphology in female rats. These nanomaterials did not induce lung tumors in male rats. Our own studies have also shown that instillation of nTiO₂ into the lungs of female rats showed tumor promoting activity and resulted in elevated ROS-mediated damage and production of inflammatory cytokines. It is reasonable to assume that other metal-derived nanoparticles, such as aluminium and copper nanoparticles, and metal containing nanoparticles, for example nCB-metal mixtures and SWCNT and MWCNT preparations, are also capable of producing these effects.

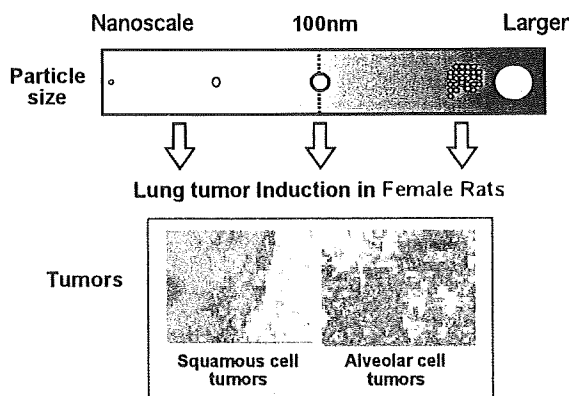


Figure 4. Schematic Presentation of Carcinogenic Effects of TiO₂, Carbon Black. Carcinogenic effects were elicited by both nano-scale and larger sized particles

Nanoparticles such as nTiO₂, nCB, SWCNT and MWCNT when intratracheally administered, were detected by light microscope as aggregates or agglomerates and these forms are reported to induce foreign body granulation tissue with various degree of inflammatory reaction. Although the relevance of foreign body-induced chronic inflammation to carcinogenesis is not clearly established, it is possible that reactive oxygen species (ROS) produced by macrophages attempting to destroy the foreign material in the inflammation site may cause DNA damage associated with carcinogenesis. Another possible contributing factor is metal, for example from metal-derived nanoparticles such as TiO₂ or from metal contaminants: these metals could also be involved in ROS production. Thus, it is possible that the observed carcinogenic effect is not specific to nanoparticles but rather associated with their ability to induce persistent foreign body-induced chronic inflammation and/or introduce metals into susceptible sites. For example, TiO₂ and carbon blacks larger than 100nm in diameter are known to induce lung tumors including similar squamous cell morphology (Nikula, 2000); (Pott and Roller, 2005) and both of these materials (larger than nano size) are classified as into group 2B (possibly carcinogenic to humans) by WHO/IARC.

Mechanisms for mesothelioma induction by MWCNT in mice and rats have not been elucidated yet. A possible contributing factor is metal: Transition metals, such as iron, are commonly used as a catalytic center in the formation of CNTs, and contaminating metal in SWCNT and MWCNT particles could catalyze the formation of ROS by the Fenton reaction (Liu and Okada, 1994). One example of this type of toxicity is that human keratinocytes exposed to SWCNT were killed by ROS in the media (Shvedova et al., 2003). Another possible contributing factor is the length of the MWCNT (Pott and Roller, 2005; Muller et al., 2009; Sakamoto et al., 2009).

As noted at the beginning of this review, for reliable risk assessment long-term animal studies are indispensable. This is particularly true for risk assessment of potential carcinogens. The standard for the evaluation of the carcinogenic potential of a test chemical is testing in two rodent species, generally rats and mice, of each sex, at 3 doses (0, low and high) of the test chemical for up to two years. In the studies conducted to date concerning the carcinogenic risk presented by nanoparticles, there is a noticeable lack of long term testing: No long-term tests of any type have been reported for either SWCNT or fullerenes. Importantly, the primary goal of risk assessment is not to simply ban a product from the market place, but rather to determine product safety and establish guidelines for its production and use and promote consumer confidence. Given the known ability of many nanomaterials to induce mechanisms which are active in humans that are risk factors for carcinogenesis, for example ROS and inflammatory cytokine production, the continued introduction of these materials into the market is alarming. Establishing the safety of these materials is urgently needed.

In this short review, available *in vivo* data concerning the carcinogenic effects of nTiO₂, nCB, SWCNT and

MWCNT, and Fullerenes is outlined. Of these, nTiO₂ and nCB are classified as possibly carcinogenic to humans. Testing of the carcinogenic activity of MWCNT produced mixed results. SWCNT and fullerenes have no carcinogenic activity in the studies conducted to date, however, toxicity testing of these materials has been quite limited and both of these materials have the potential to produce ROS. The observations noted here may apply to possible carcinogenic risk of other nanoparticles because of shared mechanisms of induction of inflammatory lesions and ROS generation. Our conclusions are that nanoparticles are clearly potentially toxic/carcinogenic to humans and their toxicity must be assessed, and their production and use managed appropriately.

Acknowledgements

The authors express gratitude to Dr David B Alexander for assistance in preparation of the manuscript. The collection of the references was supported by Health and Labour Sciences Research Grant (Research on Risk of Chemical Substance 21340601, H18-kagaku-ippan-007) from the Ministry of Health, Labour and Welfare, Japan.

References

- Baan RA (2007). Carcinogenic hazards from inhaled carbon black, titanium dioxide, and talc not containing asbestos or asbestiform fibers: recent evaluations by an IARC Monographs Working Group. *Inhal Toxicol*, **19 Suppl 1**, 213-28.
- Carrero-Sanchez JC, Elias AL, Mancilla R, et al (2006). Biocompatibility and toxicological studies of carbon nanotubes doped with nitrogen. *Nano Lett*, **6**, 1609-16.
- Dasenbrock C, Peters L, Creutzenberg O, Heinrich U (1996). The carcinogenic potency of carbon particles with and without PAH after repeated intratracheal administration in the rat. *Toxicol Lett*, **88**, 15-21.
- Emerich DF, Thanos CG (2003). Nanotechnology and medicine. *Expert Opin Biol Ther*, **3**, 655-63.
- Heinrich U, Fuhs R, Rittinghausen S, et al (1995). Chronic inhalation exposure of Wistar rats and two different strains of mice to diesel engine exhaust, carbon black, and titanium dioxide. *Inhal Toxicol*, **7**, 533-56.
- Kamat JP, Devasagayam TP, Priyadarsini KI, Mohan H, Mittal JP (1998). Oxidative damage induced by the fullerene C60 on photosensitization in rat liver microsomes. *Chem Biol Interact*, **114**, 145-59.
- Koyama S, Endo M, Kim YA, et al (2006). Role of systemic T-cells and histopathological aspects after subcutaneous implantation of various carbon nanotubes in mice. *Carbon*, **44**, 1079-92.
- Lam CW, James JT, McCluskey R, Hunter RL (2004). Pulmonary toxicity of single-wall carbon nanotubes in mice 7 and 90 days after intratracheal instillation. *Toxicol Sci*, **77**, 126-34.
- Liu M, Okada S (1994). Induction of free radicals and tumors in the kidneys of Wistar rats by ferric ethylenediamine-N,N'-diacetate. *Carcinogenesis*, **15**, 2817-21.
- Muller J, Delos M, Panin N, et al (2009). Absence of carcinogenic response to multiwall carbon nanotubes in a 2-year bioassay in the peritoneal cavity of the rat. *Toxicol Sci*, **110**, 442-8.
- Muller J, Huaux F, Moreau N, et al (2005). Respiratory toxicity of multi-wall carbon nanotubes. *Toxicol Appl Pharmacol*, **207**, 221-31.
- Nelson MA, Domann FE, Bowden GT, et al (1993). Effects of acute and subchronic exposure of topically applied fullerene extracts on the mouse skin. *Toxicol Ind Health*, **9**, 623-30.
- Newman MD, Stotland M and Ellis JI (2009). The safety of nanosized particles in titanium dioxide- and zinc oxide-based sunscreens. *J Am Acad Dermatol*, **61**, 685-92.
- Nikula KJ (2000). Rat lung tumors induced by exposure to selected poorly soluble nonfibrous particles. *Inhal Toxicol*, **12**, 97-119.
- Pott F, Roller M (2005). Carcinogenicity study with nineteen granular dusts in rats. *Eur J Oncol*, **10**, 249.
- Rittinghausen S, Mohr U, Dungworth DL (1997). Pulmonary cystic keratinizing squamous cell lesions of rats after inhalation/instillation of different particles. *Exp Toxicol Pathol*, **49**, 433-46.
- Roco MC (2003). Nanotechnology: convergence with modern biology and medicine. *Curr Opin Biotechnol*, **14**, 337-46.
- Sakamoto Y, Nakae D, Fukumori N, et al (2009). Induction of mesothelioma by a single intrascrotal administration of multi-wall carbon nanotube in intact male Fischer 344 rats. *J Toxicol Sci*, **34**, 65-76.
- Sera N, Tokiwa H, Miyata N (1996). Mutagenicity of the fullerene C60-generated singlet oxygen dependent formation of lipid peroxides. *Carcinogenesis*, **17**, 2163-9.
- Shvedova AA, Castranova V, Kisin ER, et al (2003). Exposure to carbon nanotube material: assessment of nanotube cytotoxicity using human keratinocyte cells. *J Toxicol Environ Health A*, **66**, 1909-26.
- Takagi A, Hirose A, Nishimura T, et al (2008). Induction of mesothelioma in p53^{+/−} mouse by intraperitoneal application of multi-wall carbon nanotube. *J Toxicol Sci*, **33**, 105-16.
- Warheit DB, Laurence BR, Reed KL, et al (2004). Comparative pulmonary toxicity assessment of single-wall carbon nanotubes in rats. *Toxicol Sci*, **77**, 117-25.

SYMPOSIUM PRESENTATION

Risk Assessment Studies of Nanomaterials in Japan and Other Countries

Hiroyuki Tsuda

Abstract

Recent developments in nanoparticle (NP) technology and their commercial production have raised concern regarding NP risk to health and the environment. The toxicological characteristics of NP may not be similar to that observed in pre-NP materials because of the enormous differences in size and surface area. Thus, careful risk evaluation studies are required. Since some NP have already been produced and introduced into the market, before a suitable framework enabling risk management has been firmly established, toxicological studies based on the specificity of NP which are not subordinate to their commercial production are indispensable. The summary of nanotoxicology studies shown below clearly indicates that compared with the UK, EU, USA, and other countries, Japanese studies regarding metals and SWCNT are far from sufficient to evaluate risk.

Key Words: Nanoparticles - toxicology - carcinogenicity - titanium dioxide - carbon black




Asian Pacific J Cancer Prev, 10, DIMS Supplement 11-12

Introduction

The safety of our living environment can be secured by the balanced function of three elements: risk assessment, risk management and risk communication. The first of these elements, risk assessment, must be addressed first, since without reliable risk assessment, risk communication and risk management can not function. Importantly, for reliable risk assessment long-term animal studies are indispensable.

These principles, of course, hold true for engineered nanoparticles. Unfortunately, the risk assessment data for engineered nanoparticles are rather fragmentary. However, the available findings do present a disturbing picture of potential carcinogens entering the market place. Engineered nanoparticles included in this review include nano-size titanium dioxide (nTiO₂), carbon black (nCB), single-walled carbon nanotubes (SWCNT), multiple-walled carbon nanotubes (MWCNT) and fullerenes

Table 1. Number of Subacute/Chronic Toxicity Tests (PubMed, ~2007)

				Total
TiO ₂	1	2	2*	5
SMW-CNT	2			2
Fullerenes		1		1
LT Carbon black			4*	4
Total	0	3	6	9

*Carcinogenic

*Nanotoxicology Project, Department of Molecular Toxicology, Nagoya City University Graduate School of Medical Sciences
1 Kawasumi, Mizuho-cho, Mizuho-ku, Nagoya 467 8601, Japan*

(C60) A summary of the testing so far performed shows that data are limited and Japan is not putting the priority this subject deserves (see Table 1) and Tsuda et al (2009), for a review.

Overall Evaluation and Proposal for the Future

During the development and marketing of nanomaterials, risk assessment of these new products has been perfunctory at best. While nanomaterials have undeniable benefits, their use also has undeniable potential risk. This risk must be addressed in an unbiased and thorough manner. Only after the toxicity of the various nanomaterials is understood can their true benefits be realized.

In rodent studies, nTiO₂, whether administered by inhalation or intratracheal instillation was shown to induce lung tumors with characteristic squamous cell morphology in female rats. These nanomaterials did not induce lung tumors in male rats. Our own studies have also shown that instillation of nTiO₂ into the lungs of female rats showed tumor promoting activity and resulted in elevated ROS-mediated damage and production of inflammatory cytokines. It is reasonable to assume that other metal-derived nanoparticles, such as aluminium and copper nanoparticles, and metal containing nanoparticles, for example nCB-metal mixtures and SWCNT and MWCNT preparations, are also capable of producing these effects.

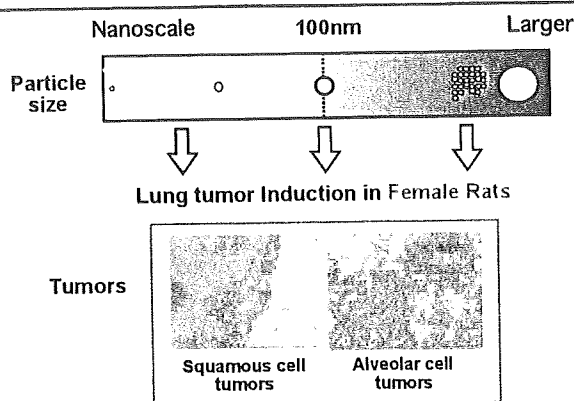


Figure 1. Schematic Presentation of Carcinogenic Effects of TiO_2 , Carbon Black. Carcinogenic effects were elicited by both nano-scale and larger sized particles

Nanoparticles such as nTiO_2 , nCB , SWCNT and MWCNT when intratracheally administered, were detected by light microscope as aggregates or agglomerates and these forms are reported to induce foreign body granulation tissue with various degree of inflammatory reaction. Although the relevance of foreign body-induced chronic inflammation to carcinogenesis is not clearly established, it is possible that reactive oxygen species (ROS) produced by macrophages attempting to destroy the foreign material in the inflammation site may cause DNA damage associated with carcinogenesis. Another possible contributing factor is metal, for example from metal-derived nanoparticles such as TiO_2 or from metal contaminants: these metals could also be involved in ROS production. Thus, it is possible that the observed carcinogenic effect is not specific to nanoparticles but rather associated with their ability to induce persistent foreign body-induced chronic inflammation and/or introduce metals into susceptible sites. For example, TiO_2 and carbon blacks larger than 100nm in diameter are known to induce lung tumors including similar squamous cell morphology (Nikula, 2000); (Pott and Roller, 2005) and both of these materials (larger than nano size) are classified as into group 2B (possibly carcinogenic to humans) by WHO/IARC (see Figure 1).

Mechanisms for mesothelioma induction by MWCNT in mice and rats have not been elucidated yet. A possible contributing factor is metal: Transition metals, such as iron, are commonly used as a catalytic center in the formation of CNTs, and contaminating metal in SWCNT and MWCNT particles could catalyze the formation of ROS by the Fenton reaction (Liu and Okada, 1994). One example of this type of toxicity is that human keratinocytes exposed to SWCNT were killed by ROS in the media (Shvedova et al., 2003). Another possible contributing factor is the length of the MWCNT (Pott and Roller, 2005; Muller et al., 2009; Sakamoto et al., 2009).

As noted at the beginning of this review, for reliable risk assessment long-term animal studies are indispensable. This is particularly true for risk assessment of potential carcinogens. The standard for the evaluation of the carcinogenic potential of a test chemical is testing

in two rodent species, generally rats and mice, of each sex, at 3 doses (0, low and high) of the test chemical for up to two years. In the studies conducted to date concerning the carcinogenic risk presented by nanoparticles, there is a noticeable lack of long term testing: No long-term tests of any type have been reported for either SWCNT or fullerenes. Importantly, the primary goal of risk assessment is not to simply ban a product from the market place, but rather to determine product safety and establish guidelines lines for its production and use and promote consumer confidence. Given the known ability of many nanomaterials to induce mechanisms which are active in humans that are risk factors for carcinogenesis, for example ROS and inflammatory cytokine production, the continued introduction of these materials into the market is alarming. Establishing the safety of these materials is urgently needed.

In this short review, available *in vivo* data concerning the carcinogenic effects of nTiO_2 , nCB , SWCNT and MWCNT, and Fullerenes is outlined. Of these, nTiO_2 and nCB are classified as possibly carcinogenic to humans. Testing of the carcinogenic activity of MWCNT produced mixed results. SWCNT and fullerenes have no carcinogenic activity in the studies conducted to date, however, toxicity testing of these materials has been quite limited and both of these materials have the potential to produce ROS. The observations noted here may apply to possible carcinogenic risk of other nanoparticles because of shared mechanisms of induction of inflammatory lesions and ROS generation. Our conclusions are that nanoparticles are clearly potentially toxic/carcinogenic to humans and their toxicity must be assessed, and their production and use managed appropriately.

References

- Liu M, Okada S (1994). Induction of free radicals and tumors in the kidneys of Wistar rats by ferric ethylenediamine- N,N' -diacetate. *Carcinogenesis*, **15**, 2817-21.
- Muller J, Delos M, Panin N, et al (2009). Absence of carcinogenic response to multiwall carbon nanotubes in a 2-year bioassay in the peritoneal cavity of the rat. *Toxicol Sci*, **110**, 442-8.
- Muller J, Huaux F, Moreau N, et al (2005). Respiratory toxicity of multi-wall carbon nanotubes. *Toxicol Appl Pharmacol*, **207**, 221-31.
- Nikula KJ (2000). Rat lung tumors induced by exposure to selected poorly soluble nonfibrous particles. *Inhal Toxicol*, **12**, 97-119.
- Pott F, Roller M (2005). Carcinogenicity study with nineteen granular dusts in rats. *Eur J Oncol*, **10**, 249.
- Sakamoto Y, Nakae D, Fukumori N, et al (2009). Induction of mesothelioma by a single intrascrotal administration of multi-wall carbon nanotube in intact male Fischer 344 rats. *J Toxicol Sci*, **34**, 65-76.
- Shvedova AA, Castranova V, Kisin ER, et al (2003). Exposure to carbon nanotube material: assessment of nanotube cytotoxicity using human keratinocyte cells. *J Toxicol Environ Health A*, **66**, 1909-26.
- Tsuda H, Xu J, Sakai Y, Futakuchi M, Fukamachi K (2009). Toxicology of engineered nanomaterials - A review of carcinogenic potential. *Asian Pacific J Cancer Prev*, **10**, 975-80.

Mature acinar cells are refractory to carcinoma development by targeted activation of Ras oncogene in adult rats

Hajime Tanaka,¹ Katsumi Fukamachi,² Mitsuru Futakuchi,² David B. Alexander,² Ne Long,² Shojiro Tamamushi,⁴ Kohtaro Minami,⁵ Susumu Seino,⁵ Hiroataka Ohara,¹ Takashi Joh¹ and Hiroyuki Tsuda^{2,3,6}

¹Departments of Gastroenterology and Metabolism, ²Molecular Toxicology and ³Nanotoxicology Project, Nagoya City University Graduate School of Medical Sciences, Nagoya; ⁴CLEA Japan Inc., Shizuoka; ⁵Division of Cellular and Molecular Medicine Kobe University Graduate School of Medicine, Kobe, Japan

(Received July 20, 2009/Revised October 8, 2009/Accepted October 13, 2009/Online publication November 16, 2009)

Pancreatic ductal adenocarcinoma (PDA) is one of the most debilitating malignancies in humans. A thorough understanding of the cytogenesis of this disease will aid in establishing successful treatments. We have developed an animal model which uses adult Hras^{G12V} and Kras^{G12V} transgenic rats in which oncogene expression is regulated by the Cre/loxP system and neoplastic lesions are induced by injection of adenovirus-expressing Cre recombinase. When adenovirus with Cre recombinase under the control of the CMV enhancer/chicken β -actin (CAG) promoter (Ad-CAG-Cre) is injected into the pancreatic duct of these animals, pancreatic neoplasias develop. Pathologically, the origin of these lesions is duct, intercalated duct, and centroacinar cells, but not acinar cells. The present study was undertaken to test the effect of acinar cell-specific oncogenic *ras* expression. Adult transgenic rats were injected with adenovirus with Cre recombinase under the control of the acinar cell-specific promoters amylase (Ad-Amy-Cre) and elastase-1 (Ad-Ela-Cre) or under the control of the non-specific CAG promoter. Injection of either Ad-Amy-Cre or Ad-Ela-Cre into the pancreatic ducts of transgenic animals in which oncogenic *Kras* is tagged with hemagglutinin (HA), HA-Kras^{G12V} rats resulted in expression of oncogenic *ras* in acinar cells but not in duct, intercalated duct, or centroacinar cells. Notably, injected animals did not develop any observable proliferative or neoplastic lesions. In marked contrast, injection of Ad-CAG-Cre resulted in pancreatic cancer development within 4 weeks. These results indicate that adult acinar cells are refractory to Ras oncogene activation and do not develop neoplasia in this model. (*Cancer Sci* 2010; 101: 341–346)

Pancreatic ductal adenocarcinoma (PDA) is a highly lethal disease, which is usually diagnosed in an advanced state. Most patients die within 1 year of diagnosis,⁽¹⁾ and the 5-year survival rate is <5%.⁽²⁾ Understanding of the cytogenesis of PDA offers new directions for targeted therapeutic approaches to combat this disease.

Previously, we reported on an animal model in which pancreatic neoplasia was induced in adult Hras^{G12V} transgenic rats by injection of adenovirus with Cre recombinase under the control of the CMV enhancer/chicken β -actin (CAG) promoter into the pancreatic duct.⁽³⁾ In these animals, it was shown that duct, intercalated duct, centroacinar, and acinar cells were all infected with the adenovirus, but induced pre-neoplastic and neoplastic lesions were shown to express only duct cell-specific characteristics and not acinar cell-specific characteristics. Moreover, proliferative lesions were not observed in acinar cells. Therefore, we hypothesized that PDA does not develop from adult pancreatic acinar cells in this model.

The present study was undertaken to directly test the capability of mature acinar cells to develop into a neoplastic lesion.

Transgenic rats with an Hras or hemagglutinin (HA)-tagged *Kras* oncogene were injected with Cre recombinase expressing adenoviruses in which Cre expression was under the control of promoters specifically active in acinar cells. Mature acinar cells in injected rats did express active Ras proteins, but did not develop any proliferative or neoplastic lesions.

Materials and Methods

Generation of transgenic rats. For the generation of transgenic rats conditionally expressing human *Kras*^{G12V}, we first made a cDNA fragment encoding the human *Kras*4B^{G12V} with a 3 \times HA tag sequence at its 5' end (HA-Kras^{G12V}). The HA-Kras^{G12V} cDNA was subcloned into the *Sac*I/*Kpn*I site of pCALNL5 (DNA Bank, RIKEN Bio Resource Center, Ibaraki, Japan)^(4,5) to produce pCALNLHAKras. pCALNLHAKras was digested with *Sal*I/*Hind*III. The purified cassette (Fig. 1A) was injected into the pronuclei of Sprague–Dawley rats (CLEA Japan, Tokyo, Japan). Techniques used for the generation of transgenic rats were the same as those reported previously.^(3,6) A total of 265 injected eggs were transplanted into pseudo-pregnant Sprague–Dawley rats. Of 37 potential transgenic rats screened, four male and one female rat were shown by PCR to carry the transgene. Transgenic founder rats were mated with Sprague–Dawley rats, and offspring were screened for the presence of the transgene by PCR analysis of genomic DNA isolated from tail biopsies at the age of 3 weeks. The following primers were used: 5'-TCTGGATCAAATCCGAACGC-3', 5'-TGACCTGCTGTGTCGAGAAT-3'. Two founder rats carrying a CALNLHAKras^{G12V} transgene transmittable to descendent generations (Kras301 and Kras327) and two founder rats (Kras409 and Kras417) carrying a non-tagged *Kras*^{G12V} transgene were established using the same cassette (data not shown). In this study, we used Kras301 and Kras327. Hras250 rats conditionally expressing human Hras^{G12V} were generated as previously described.⁽³⁾ They were maintained in plastic cages in an air-conditioned room with a 12-h light/12-h dark cycle. All experiments were conducted according to the Guidelines for Animal Experiments of the Nagoya City University Graduate School of Medical Sciences.

Preparation of adenovirus vectors. Adenoviruses in which either the mouse amylase-2 or the rat elastase-1 promoter drove the expression of Cre recombinase (Ad-Amy-Cre or Ad-Ela-Cre) (Fig. 1B) were prepared as described previously.⁽⁷⁾ Recombinant adenovirus vectors carrying the *Cre* gene (Ad-CAG-Cre) (Fig. 1B) and empty adenovirus vector were prepared as described previously.⁽³⁾ Recombinant adenovirus vectors were amplified in HEK-293 cells and then purified using Vivapur

⁶To whom correspondence should be addressed.
E-mail: htsuda@med.nagoya-cu.ac.jp

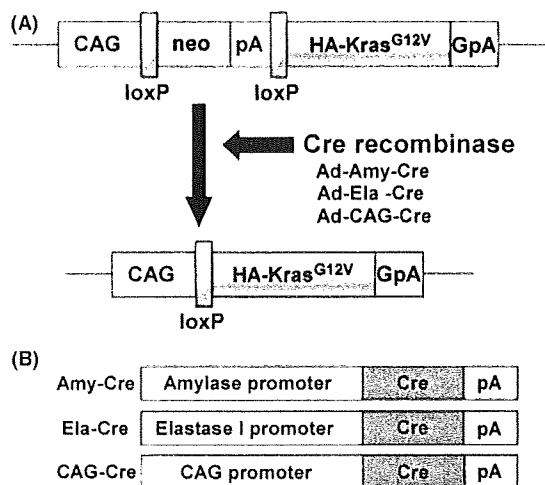


Fig. 1. Conditional expression of *Kras*^{G12V} transgene. (A) The CALNL-HAKras^{G12V} transgene is comprised of a hybrid CMV enhancer/chicken β -actin (CAG) promoter, a cassette for the neomycin resistance gene flanked by loxP sites, and a sequence containing a human *Kras*^{G12V} with a hemagglutinin (HA)-tag. Infection with the Cre recombinase-expressing adenovirus results in Cre-mediated recombination of the transgene and removal of the neo-coding region and its associated mRNA polyadenylation signal, generating a functional HA-Kras^{G12V} gene expression unit. GpA, rabbit- β -globin poly(A) site; pA, SV40 early poly(A) site. (B) Cre recombinase with nuclear localization signal expressing adenovirus in which Cre expression is under the control of three different promoters: the amylase promoter and the elastase-1 promoter which are active in acinar cells, and the CAG promoter which is a nonspecific promoter.

Adenopack (Vivascience, Hannover, Germany). The titer of the adenovirus was determined by using the Rapid titer kit (Clontech, Mountain View, CA, USA). The virus stock was concentrated to 1.0×10^{10} pfu/mL.

Induction of active Ras in the pancreas. Adenovirus vectors were injected into the pancreatic ducts of 12-week-old adult male rats through the common duct as previously reported. To induce active Ras specifically in acinar cells, adenoviruses (6×10^8 pfu/rat) in which the expression of Cre recombinase was under the control of acinar cell specific promoters, either the amylase-2 (Ad-Amy-Cre) or elastase-1 (Ad-Ela-Cre) promoter, were used. To induce active Ras non-specifically, adenoviruses (6×10^8 pfu/rat) in which the expression of Cre recombinase was under the control of the non-specific CAG promoter were used.

Western blotting. Western blot analysis and detection of activated Ras protein was performed using a Ras Activation Assay kit (Upstate, Lake Placid, NY, USA) as described previously.^(3,8) Concentrations of the proteins were determined by Bio-Rad Protein assay. Proteins were separated by SDS-PAGE. After transfer to a polyvinylidene difluoride membrane, the membrane was blocked with 5% nonfat milk and then incubated for 1 h at room temperature with primary antibodies. The following antibodies were used: anti-Ras, clone Ras10 (Upstate) diluted 1:4000; HA-probe (Y-11; Santa Cruz Biotechnology, Santa Cruz, CA, USA) diluted 1:1,000; and monoclonal anti- β -actin (A5441; Sigma, St Louis, MO) diluted 1:10 000. The primary antibodies were detected using HRP-conjugated secondary antibodies (Southern Biotechnology Associates, Birmingham, AL, USA) and ECL plus (GE Healthcare UK, Buckinghamshire, UK).

Immunostaining. Tissues were fixed in 10% formalin or 4% paraformaldehyde fixative and embedded in paraffin. For Ki67, proliferating cell nuclear antigen (PCNA), and HA-tag staining, sections were boiled for 10 min in a 10-mM citrate buffer (pH

6.0) and then allowed to cool in PBS for 30 min before incubation with antibodies. For anti- α -amylase staining, section slides were incubated for 10 min in a 0.1% trypsin solution at 37°C and then washed in PBS for 5 min before incubation with antibodies.

Before staining, each section was blocked with 10% goat serum (Nichirei Bio Science, Tokyo, Japan) for 5 min at room temperature. The slides were incubated overnight at 4°C with primary antibodies against Ki67 antigen (NCL-Ki67-p; Novocastra Laboratories, Newcastle, UK), diluted 1:3000; PCNA (clone PC10; DakoCytomation, Glostrup, Denmark), diluted 1:50; HA-Tag (6E2; Cell Signaling, Danvers, MA, USA), diluted 1:100; or anti- α -amylase (A8273; Sigma, St Louis, MO, USA), diluted 1:200. Slides were incubated with secondary antibodies conjugated with Alexa Fluor488, 546, and 647 (Invitrogen, Carlsbad, CA, USA), and images were obtained with a FLUOVIEW FV300 confocal microscope (Olympus, Tokyo, Japan) or a BZ-9000 fluorescence microscope (Keyence, Osaka, Japan).

Results

Targeted activation of HA-Kras^{G12V} transgenes in mature acinar cells. Injection of transgenic rats with Cre recombinase expressing adenovirus resulted in excision of the stuffer DNA between the CAG promoter and the transgene and consequent expression of the transgene in infected cells (Fig. 1A). Kras301/327 rats were injected with Ad-Amy-Cre or Ad-Ela-Cre. Expression of HA-Kras^{G12V} was observed only in amylase-positive acinar cells and not in duct, centroacinar, intercalated duct, or islet cells (Table 2) (Fig. 2A; data for Ad-Ela-Cre is identical to that of Ad-Amy-Cre). Some acinar cells with nuclei with an "owl-eye" or "ground glass" appearance, which are generally used for identification of virus-infected cells,⁽⁹⁾ in rats treated with Ad-Amy-Cre or Ela-Cre were also positive for both amylase and HA (Fig. 2A-d,e). All acinar cells positive for HA were entirely negative for Ki67 (Fig. 2A).

Lack of PDA development by targeted activation of Ras^{G12V} in mature acinar cells. None of the Kras301/327 rats injected with Ad-Amy-Cre or Ela-Cre developed pancreatic lesions (Ad-Amy-Cre, 0 out of 5; Ad-Ela-Cre, 0 out of 7) after 8 weeks (Fig. 2B, Table 1). Similarly, none of the Hras250 rats injected with Ad-Amy-Cre or Ad-Ela-Cre (6×10^8 pfu/rat) developed pancreatic lesions (Ad-Amy-Cre, 0 out of 7; Ad-Ela-Cre, 0 out of 8) after 8 weeks (Table 1). In addition, Kras301/327 rats injected with higher titers of Ad-Amy-Cre (6×10^9 pfu/rat) did not develop pancreatic lesions (data not shown). Finally, tumor induction was not observed in injected Kras301/327 rats even after 6 months (data not shown).

Neoplasia development by activation of Ras^{G12V} transgenes in ductal cells. Both Kras301/327 and Hras250 rats injected with Ad-CAG-Cre (6×10^8 pfu/rat) developed pancreatic neoplasias: 22 of 22 Kras301/327 rats and 30 of 35 and Hras250 rats after 2 to 4 weeks (Table 1), as observed in our previous report.⁽³⁾ Pancreatic neoplasias were also observed in Kras301/327 rats injected with lower titers of Ad-CAG-Cre (6×10^7 pfu/rat) (data not shown). Activation of the transgene in the pancreatic ductal lesions of Kras301/327 rats was shown by Western blotting using anti-HA antibody (Fig. 3). The expression of HA-Kras^{G12V} was detected in pancreatic intraepithelial neoplasia (PanIN) and neoplastic lesions, but not in normal-looking pancreatic duct cells or stromal cells (Fig. 4A). Ki67 or PCNA and HA were positive in PanIN lesions (Fig. 4B) and in many neoplastic cells (Fig. 4C).

Discussion

The morphological and molecular signatures associated with human pancreas tumors suggests that duct epithelium is

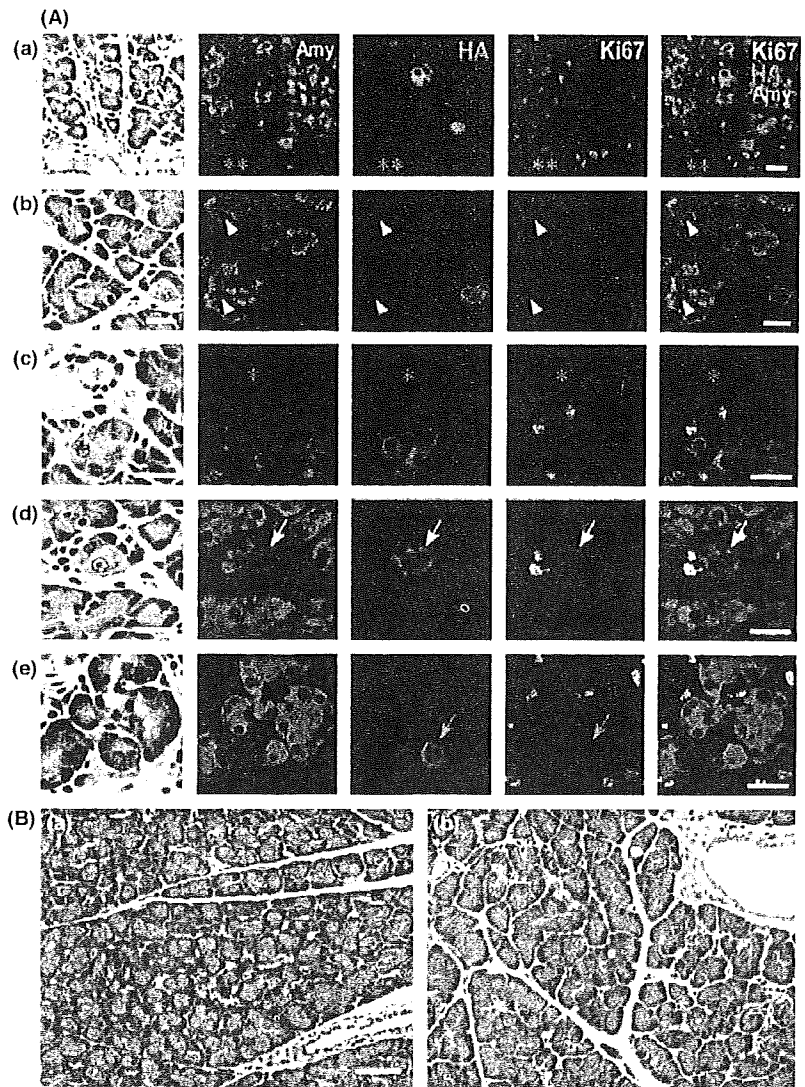


Fig. 2. Acinar cell-specific expression of hemagglutinin (HA)-Kras^{G12V}. (A) Localization of amylase (blue) protein, HA-Kras^{G12V} (red) and Ki67 (green) at 2 days after injection of virus with Ad-Amy-Cre (a, b, c, d) and Ela-Cre (e). All the HA-Kras^{G12V} positive cells (red) were acinar cells; expression was not observed in duct cells (**), centroacinar cells (yellow arrowhead), or small duct cells (*). Most virally infected acinar cells positive for HA-Kras^{G12V} were indistinguishable from non-infected acinar cells by hematoxylin-eosin staining. Some infected acinar cells have nuclei with a so-called "owl-eye" (yellow arrows) or "ground glass" (red arrows) appearance. Ki67 (green) is not present in the nuclei of the cells expressing HA-Kras^{G12V} (red). Bar, 20 μ m. (B) None of the Ad-Amy-Cre (a) or the Ad-Ela-Cre (b) groups displayed any pancreatic lesions, even after 8 weeks. Bar, 50 μ m.

responsible for the development of PDA, but it remains unclear whether other pancreatic cells might also contribute to the cytogenesis of these lesions. In our previous study using the Hras250 rat, 4 weeks after injection of adenovirus with Cre recombinase under the control of the constitutive CAG promoter, proliferative lesions in the duct epithelium, intercalated ducts, and centroacinar cells were widespread, but we could not detect any proliferative lesions in acinar cells; moreover, subsequent neoplastic lesions expressed only duct cell-specific characteristics and not acinar cell-specific ones.⁽³⁾ We have obtained essentially

identical results with Kras transgenic rats as we did with Hras250 rats (data not shown). These results suggest that PDAs may arise from centroacinar cells, intercalated duct, or pancreatic duct epithelium, but not from acinar cells.

The current study was undertaken to clarify whether mature acinar cells in adult rats could be induced to develop to PDA by targeted activation of oncogenic *ras*. Activation of oncogenic *ras* in acinar cells did not lead to the development of any observable pancreatic lesions, while nonspecific activation of oncogenic *ras* in the pancreas resulted in rapid development of

Table 1. Pancreas tumor induction by activation of Hras^{G12V} or hemagglutinin (HA)-Kras^{G12V} oncogene after Cre-adenovirus injection

Oncogene	Virus vector	Number of rats with tumor (%)
Hras ^{G12V}	Amylase-Cre	0/7 (0)
	Elastase-Cre	0/8 (0)
	CAG-Cre	30/35 (87.5)
HA-Kras ^{G12V}	Amylase-Cre	0/5 (0)
	Elastase-Cre	0/7 (0)
	CAG-Cre	22/22 (100)

Table 2. Target cell and tumor type in Hras^{G12V} and hemagglutinin (HA)-Kras^{G12V} transgenic rats

Virus vector	Target cells			Tumor yield	
	Acinar cells	Centroacinar cells	Duct cells	Acinar cells	Duct cells
Amy-Cre	+	-	-	-	-
Ela-Cre	+	-	-	-	-
CAG-Cre ⁽³⁾	+	+	+	-	+

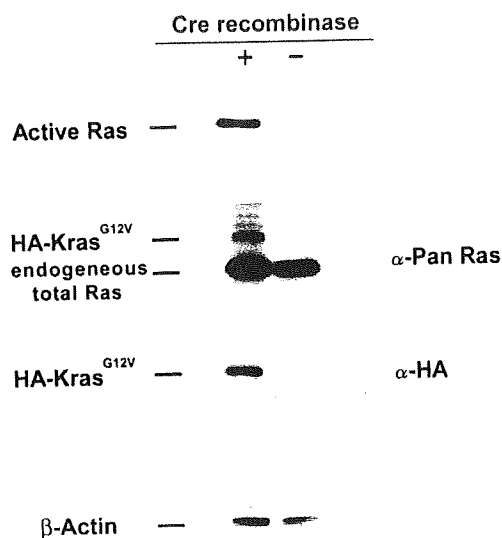


Fig. 3. Transgene activation in *Kras301* and *327* by Western blotting. A high level of active Ras and hemagglutinin (HA)-*Kras*^{G12V} were detected in the pancreas of the Ad-CAG-Cre-treated rats. The amount of active Ras was analyzed by RBD (Ras-binding domain of Raf-1) pull-down assay followed by Western blotting with anti-pan Ras antibody. HA-*Kras*^{G12V} and endogenous total Ras was detected using anti-Pan Ras antibody. HA-*Kras*^{G12V} was detected using anti-HA antibody. β -Actin was used as a loading control.

pancreatic neoplasias. Our results clearly show that conditional expression of oncogenic *ras* in acinar cells in fully developed pancreas tissue does not result in induction of neoplasia in this model (Table 1).

Previous reports in which *Kras* was activated in immature acinar cells during embryonic development^(10,11) suggested that acinar-ductal metaplasia played a role in the development of PDA. In these models, premalignant acinar-ductal metaplasia and acinar tumor mixed with duct-like lesions developed in transgenic mice. This acinar-ductal metaplasia, however, may have occurred before the pancreas fully developed. Our model, on the other hand, targets mature acinar cells which express digestive enzymes, amylase and/or elastase, and these cells do not undergo acinar-ductal metaplasia in response to *ras* activation.

Our results are in agreement with a recent study in which the distribution of *K-RAS2* gene mutations was extensively examined in surgically resected pancreata from human patients and which concluded that ductal neoplasms of the human pancreas did not appear to arise from acinar cells.⁽¹²⁾

Kras mutations were not observed in pancreatic acinar cell carcinoma (ACC) induced in mature rats by administration of azaserine.⁽¹³⁾ Furthermore, alterations in the APC/ β -catenin pathway were detected in 23.5% of human ACC,⁽¹⁴⁾ but mutation of *Kras* was not observed.^(15,16) Thus, it is possible that APC/ β -catenin or another pathway, but not necessarily *Kras* activation, is involved in ACC development.

While pancreas cancer in the hamster model is also believed to arise from ductal epithelial hyperplasia,^(17,18) several studies using transgenic mice^(11,19-24) suggest that PDA may develop from acinar cells. In most of these studies, however, oncogenic stimuli are present during embryonic development, prior to the development of a mature pancreas. Therefore, the acinar cells which were activated and developed into neoplasias in these models could very well be at a different developmental stage to the acinar cells which are present in a mature pancreas. This is important because the majority of PDA patients are 60 years of age or older. It is highly unlikely that an oncogenic insult occur-

ring in the uterus is the root cause of most of these PDAs. Moreover, epidemiological studies indicate the incidence of PDA is closely related to lifestyle.⁽²⁵⁾ Therefore, PDA most likely develops from cells in the mature pancreas. Consequently, pancreas tumor models in which the oncogenic insult occurs during embryonic development are unlikely to be appropriate for determining the cytogenesis of human PDA.

Two models⁽²²⁻²⁴⁾ use conditional activation of Cre recombinase to activate oncogenic *ras* in adult animals: one model⁽²²⁾ uses the tet-off system to control expression of Cre recombinase and the other model^(23,24) uses the tamoxifen-estrogen receptor system to control nuclear localization of Cre recombinase. These studies had slightly conflicting results. In one study, expression of oncogenic *ras* in adult acinar cells did not by itself induce pancreatic lesions; additional treatment causing chronic pancreatitis was also needed.⁽²²⁾ In the other study, expression of oncogenic *ras* was sufficient to induce PanIN-like lesions.^(23,24) In our model, we clearly showed that while expression of oncogenic *ras* is sufficient to induce duct, intercalated duct, and/or centroacinar cells to develop into pancreatic cancers, it is not sufficient to induce acinar cells to develop into pancreatic cancers. Whether these discrepancies are due to experimental procedures, the nature of the Cre recombinase constructs used, or differences between mice and rats remains to be resolved. There are however, a few readily apparent differences. In our rat system, there is no expression of Cre recombinase in the animal until injection of adenovirus-expressing Cre recombinase, and the expression of Cre recombinase is transient. In the model which uses tamoxifen, on the other hand, Cre recombinase is expressed during embryonic development, but nuclear localization is regulated by tamoxifen.^(23,24) In this model, however, there was a low level of tamoxifen-independent recombination events resulting in expression of oncogenic *ras* in embryonic acinar cells.⁽²⁴⁾ It is possible that embryonic acinar cells expressing oncogenic *ras* did not fully differentiate in the adult pancreas; for example, in the mouse colon expression of *Kras*^{G12V} inhibits differentiation.⁽²⁶⁾ Therefore, it is possible that in the tamoxifen-estrogen regulated model,^(23,24) the acinar cells which were activated to undergo metaplasia to duct-like cells in the adult were not actually mature acinar cells. The other obvious difference is that in the model regulated by the tet-off system, two events were required to induce pancreas cancer: activation of oncogenic *Kras* and chronic pancreatitis.⁽²²⁾ Chronic pancreatitis would very likely result in the death of mature acinar cells and their replacement from a proliferative compartment. It is possible that these replacement cells are not fully mature acinar cells, again suggesting the possibility that the acinar cells which underwent metaplasia to duct-like cells were not actually mature acinar cells.

The primary aim of this study was to determine whether activation of oncogenic *Kras* in mature, digestive enzyme-secreting acinar cells would lead to pancreatic lesions. Our findings support our earlier hypothesis that PDA does not develop from *Kras* activation in mature acinar cells. It is possible, however, that PDA could develop from *Kras* activation in immature acinar cells, and in this regard we would like to emphasize the results of Guerra *et al.*⁽²²⁾ in which activation of *Kras* in the mature pancreas accompanied by chronic pancreatitis resulted in induction of PDA in transgenic mice. Importantly, chronic pancreatitis has been shown to be one of the main risk factors for PDA development in humans.^(27,28)

Other factors which may influence PDA development in our model are inflammation and fibrosis. Shortly after infection of pancreatic tissue with Cre recombinase carrying adenovirus to activate the *Kras* transgene, infiltration of macrophages and lymphocytes could be observed. This infiltration is presumably in response to viral infection. A moderate degree of inflammation, however, was still observed in the stromal tissue surrounding the tumors when PDA developed. These findings suggest that

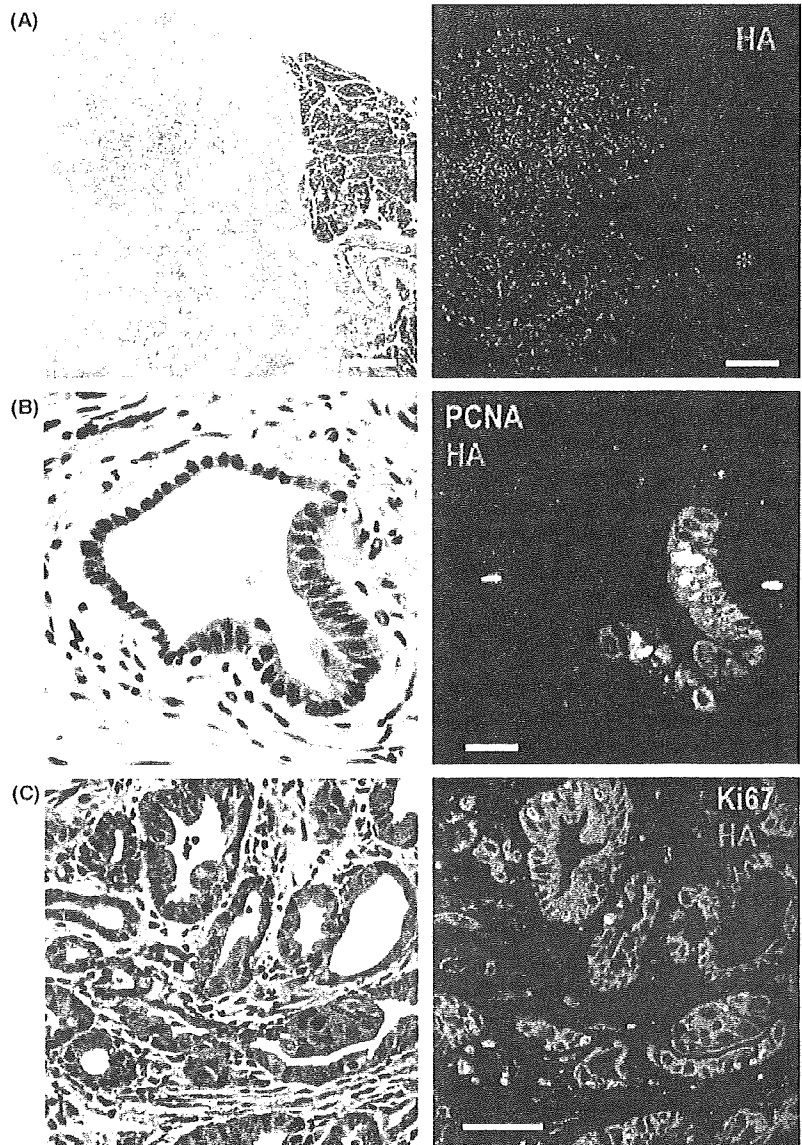


Fig. 4. Pancreatic ductal adenocarcinoma (PDA) induced by injection of Ad-CAG-Cre in *Kras*^{301/327} rats. (A) The expression of hemagglutinin (HA)-*Kras*^{G12V} (red) was seen only in PDA lesions (on the left of photo), and not in stromal cells, acinar cells (on the right of photo), or normal pancreatic duct cells (*). Bar, 500 μ m. (B) A pancreatic intraepithelial neoplasia (PanIN) lesion was surrounded by fibrous tissue with some infiltration of inflammatory cells. Expression of proliferating cell nuclear antigen (PCNA) (green) and HA protein (red) in a PanIN lesion in rats of the CAG-Cre group. PCNA is preferentially expressed in PanIN cells. Bar, 20 μ m. (C) Expression of Ki67 (green) and HA protein (red) in PDA cells. Many PDA cells (red) are simultaneously positive for Ki67. Bar, 50 μ m.

inflammation may play a role in PDA development in this model. However, interaction between the immune system and tumors is complex and whether inflammation actually promotes PDA development in this model remains to be examined.

A current study has demonstrated that the fibrous element accompanying inflammation can also play an important role in cancer development.⁽²⁹⁾ This aspect of PDA development in our model also remains to be examined.

In summary, while there are discrepancies between different animal models of pancreatic cancer, our results indicate that expression of oncogenic *ras* in fully mature acinar cells does not induce cell proliferation or result in development of any pancreatic lesions. Thus, we conclude that mature acinar cells are not the origin of PanIN or pancreatic neoplasia in this model.

References

- 1 Beger HG, Rau B, Gansauge F, Poch B, Link KH. Treatment of pancreatic cancer: challenge of the facts. *World J Surg* 2003; 27: 1075–84.
- 2 Jemal A, Siegel R, Ward E, Murray T, Xu J, Thun MJ. Cancer statistics, 2007. *CA Cancer J Clin* 2007; 57: 43–66.

Acknowledgments

We thank Dr T. Shirai (Nagoya City University) for his kind advice for histological examination and assistance in histological specimen preparation. This work was supported in part by a Grant-in-Aid for Scientific Research (C) from Japan Society for the Promotion of Science; a Grant-in-Aid for Cancer Research (15-2, 16-13, 17S-6, 20S-8) from the Ministry of Health, Labour and Welfare, Japan; a Grant-in-Aid for Research on Nanotechnical Medical (H19-Nano-Ippan-014) from the Ministry of Health, Labour, and Welfare of Japan; a Grant-in-Aid for Research on Risk of Chemical Substances (H19-Kagaku-Ippan-006) from the Ministry of Health, Labour, and Welfare of Japan; and a Grant-in-Aid for Nagoya Ohjinkai Young Investigators Medical Research Award from Nagoya City University, Japan.

- 3 Ueda S, Fukamachi K, Matsuoka Y *et al*. Ductal origin of pancreatic adenocarcinomas induced by conditional activation of a human Ha-ras oncogene in rat pancreas. *Carcinogenesis* 2006; 27: 2497–510.
- 4 Kanegae Y, Lee G, Sato Y *et al*. Efficient gene activation in mammalian cells by using recombinant adenovirus expressing site-specific Cre recombinase. *Nucleic Acids Res* 1995; 23: 3816–21.

- 5 Niwa H, Yamamura K, Miyazaki J. Efficient selection for high-expression transfectants with a novel eukaryotic vector. *Gene* 1991; **108**: 193–9.
- 6 Asamoto M, Ochiya T, Toriyama-Baba H *et al*. Transgenic rats carrying human c-Ha-ras proto-oncogenes are highly susceptible to N-methyl-N-nitrosourea mammary carcinogenesis. *Carcinogenesis* 2000; **21**: 243–9.
- 7 Minami K, Okuno M, Miyawaki K *et al*. Lineage tracing and characterization of insulin-secreting cells generated from adult pancreatic acinar cells. *Proc Natl Acad Sci U S A* 2005; **102**: 15116–21.
- 8 Fukamachi K, Imada T, Ohshima Y, Xu J, Tsuda H. Purple corn color suppresses Ras protein level and inhibits 7,12-dimethylbenz[*a*]anthracene-induced mammary carcinogenesis in the rat. *Cancer Sci* 2008; **99**: 1841–6.
- 9 Kobayashi TK, Sato S, Tsubota K, Takamura E. Cytological evaluation of adenoviral follicular conjunctivitis by cytobrush. *Ophthalmologica* 1991; **202**: 156–60.
- 10 Schmid RM. Acinar-to-ductal metaplasia in pancreatic cancer development. *J Clin Invest* 2002; **109**: 1403–4.
- 11 Grippo PJ, Nowlin PS, Demeure MJ, Longnecker DS, Sandgren EP. Preinvasive pancreatic neoplasia of ductal phenotype induced by acinar cell targeting of mutant Kras in transgenic mice. *Cancer Res* 2003; **63**: 2016–9.
- 12 Shi C, Hong SM, Lim P *et al*. KRAS2 mutations in human pancreatic acinar-ductal metaplastic lesions are limited to those with PanIN: implications for the human pancreatic cancer cell of origin. *Mol Cancer Res* 2009; **7**: 230–6.
- 13 Longnecker DS, Culphey TJ. Adenocarcinoma of the pancreas in azaserine-treated rats. *Cancer Res* 1975; **35**: 2249–58.
- 14 Abraham SC, Wu TT, Hruban RH *et al*. Genetic and immunohistochemical analysis of pancreatic acinar cell carcinoma: frequent allelic loss on chromosome 11p and alterations in the APC/beta-catenin pathway. *Am J Pathol* 2002; **160**: 953–62.
- 15 Terhune PG, Memoli VA, Longnecker DS. Evaluation of p53 mutation in pancreatic acinar cell carcinomas of humans and transgenic mice. *Pancreas* 1998; **16**: 6–12.
- 16 Van Kranen HJ, Vermeulen E, Schoren L *et al*. Activation of c-K-ras is frequent in pancreatic carcinomas of Syrian hamsters, but is absent in pancreatic tumors of rats. *Carcinogenesis* 1991; **12**: 1477–82.
- 17 Tsutsumi M, Kondoh S, Noguchi O *et al*. K-ras gene mutation in early ductal lesions induced in a rapid production model for pancreatic carcinomas in Syrian hamsters. *Jpn J Cancer Res* 1993; **84**: 1101–5.
- 18 Tsutsumi M, Konishi Y. Precancerous conditions for pancreatic cancer. *J Hepatobiliary Pancreat Surg* 2000; **7**: 575–9.
- 19 Tuveson DA, Zhu L, Gopinathan A *et al*. Mist1-KrasG12D knock-in mice develop mixed differentiation metastatic exocrine pancreatic carcinoma and hepatocellular carcinoma. *Cancer Res* 2006; **66**: 242–7.
- 20 Hingorani SR, Petricoin EF, Maitra A *et al*. Preinvasive and invasive ductal pancreatic cancer and its early detection in the mouse. *Cancer Cell* 2003; **4**: 437–50.
- 21 Wagner M, Luhrs H, Kloppel G, Adler G, Schmid RM. Malignant transformation of duct-like cells originating from acini in transforming growth factor transgenic mice. *Gastroenterology* 1998; **115**: 1254–62.
- 22 Guerra C, Schuhmacher AJ, Canamero M *et al*. Chronic pancreatitis is essential for induction of pancreatic ductal adenocarcinoma by K-Ras oncogenes in adult mice. *Cancer Cell* 2007; **11**: 291–302.
- 23 Habbe N, Shi G, Meguid RA *et al*. Spontaneous induction of murine pancreatic intraepithelial neoplasia (mPanIN) by acinar cell targeting of oncogenic Kras in adult mice. *Proc Natl Acad Sci U S A* 2008; **105**: 18913–8.
- 24 De La OJ, Emerson LL, Goodman JL *et al*. Notch and Kras reprogram pancreatic acinar cells to ductal intraepithelial neoplasia. *Proc Natl Acad Sci U S A* 2008; **105**: 18907–12.
- 25 Jiao L, Mitrou PN, Reedy J *et al*. A combined healthy lifestyle score and risk of pancreatic cancer in a large cohort study. *Arch Intern Med* 2009; **169**: 764–70.
- 26 Haigis KM, Kendall KR, Wang Y *et al*. Differential effects of oncogenic K-Ras and N-Ras on proliferation, differentiation and tumor progression in the colon. *Nat Genet* 2008; **40**: 600–8.
- 27 Lowenfels AB, Maisonneuve P, Cavallini G *et al*. Pancreatitis and the risk of pancreatic cancer. International Pancreatitis Study Group. *N Engl J Med* 1993; **328**: 1433–7.
- 28 Malka D, Hammel P, Maire F *et al*. Risk of pancreatic adenocarcinoma in chronic pancreatitis. *Gut* 2002; **51**: 849–52.
- 29 Sangai T, Ishii G, Kodama K *et al*. Effect of differences in cancer cells and tumor growth sites on recruiting bone marrow-derived endothelial cells and myofibroblasts in cancer-induced stroma. *Int J Cancer* 2005; **115**: 885–92.

Research paper

Anticarcinogenesis pathways activated by bovine lactoferrin in the murine small intestine

Masaaki Iigo^{a,b}, David B. Alexander^b, Ne Long^b, Jiegou Xu^b, Katsumi Fukamachi^b, Mitsuru Futakuchi^b, Mitsunori Takase^c, Hiroyuki Tsuda^{b,*}

^a *Cancer Prevention Basic Research Project, National Cancer Center Research Institute, Tsukiji, Chuo-ku, Tokyo*

^b *Department of Molecular Toxicology, Nagoya City University, Graduate School of Medical Sciences, Nagoya-shi, Aichi-ken, Japan*

^c *Food Science & Technology and Nutritional Science Institutes, Morinaga Milk Industry Co., Ltd, Zama, Japan*

Received 30 January 2008; accepted 20 June 2008

Available online 27 June 2008

Abstract

Oral administration of bovine lactoferrin (bLF) inhibits carcinogenesis in the colon and other organs in rats, and lung metastasis in mice. A likely mechanism by which bLF mediates its anticarcinogenesis effects is by enhanced expression of cytokines and subsequent activation of immune cells. Oral administration of bLF enhances expression of interleukin-18 (IL-18) mRNA in the mucosa of the small intestine of mice. Importantly, the pepsin hydrolysate of bLF (bLFH) also induced expression of IL-18 mRNA in the mouse small intestine and a peptide produced by pepsin digestion of bLF, bovine lactoferricin (bLFcin), induced expression of mature IL-18 in organ culture. In addition to IL-18, bLF and bLFcin both induced significant increases in caspase-1 activity in peritoneal macrophages and in organ cultures. The increase of mature IL-18 by macrophages was inhibited by caspase-1 inhibitor: caspase-1 is known to cleave the proform of IL-18 to produce active mature IL-18. Finally, bLF also induced expression of IFN γ by peritoneal macrophages. Importantly, in IFN γ knockout (GKO) mice, bLF administration resulted in increased expression of caspase-1 protein, but induction of IL-18 mRNA, caspase-1 activity, and mature IL-18 was not observed. These results indicate that orally administered bLF can induce expression of IFN γ and caspase-1 in the small intestine. IFN γ in turn increases expression of target genes, including IL-18. Active caspase-1 then cleaves pro-IL-18 to generate mature IL-18. Thus, bLF activates an effector pathway mediated by IFN γ , caspase-1, and IL-18. We also show that ingested bLF is able to activate more than a single effector pathway. For example, in GKO mice while bLF administration could not activate the IFN γ /caspase-1/IL-18 effector pathway, it was able to inhibit tumor growth and metastasis by activation of an IFN α /IL-7 effector pathway.

© 2008 Elsevier Masson SAS. All rights reserved.

Keywords: Lactoferrin; Innate immune system; Cytokine; Chemoprevention; Carcinogenesis

1. Introduction

Lactoferrin (LF), an approximately 80 kDa iron binding glycoprotein initially purified from milk, is an important component of the innate immune system. A potent antimicrobial and antiviral agent [1–5], LF is a major component

of antimicrobial host defense and is found in a variety of exocrine secretions, e.g., tears, nasal exudate, saliva, bronchial mucus, gastrointestinal fluids, cervicovaginal mucus, and seminal fluid. In addition to its presence in mucosal secretions, LF is released by activated neutrophils at septic sites.

The concentration of LF in human colostrum is particularly high (7–10 mg/ml) [6] resulting in ingestion of 1–2 g/day for several months by a suckling infant [7]. It is thought that orally ingested LF may be able to interact with epithelial cells and immune cells in the mucosa of the intestine: ingested LF is reported to stimulate cytokine

* Corresponding author at: Department of Molecular Toxicology, Nagoya City University, Graduate School of Medical Sciences, 1 Kawasumi, Mizuho-ch., Mizuho-ku, Nagoya-shi, Aichi-ken 467-8601, Japan. Tel.: +81 52 853 8991; fax: +81 52 853 8996.

E-mail address: htsuda@med.nagoya-cu.ac.jp (H. Tsuda).