(Fig. 1B), and he experienced drop attacks once more. 3D-FLAIR MRI revealed endolymphatic hydrops to a similar degree as that observed in the first MRI (Fig. 2B). He was treated with medication including a diuretic, and his hearing level improved and stabilized at 40–50 dB, especially at lower frequencies, and he experienced no further drop attacks (Fig. 1C). A third 3D-FLAIR MRI examination was performed 15 months after the second examination and it revealed reduced endolymphatic hydrops in the cochlea (mild hydrops) compared with that observed in the two previous examinations (significant hydrops) [3]. The gadolinium was more strongly visible in the vestibule and the semicircular canals (Fig. 2C). The hearing level on the right side was within the normal range throughout this period. Vestibular findings, such as nystagmus, were not observed in the patient during the follow-up periods using MRI, except for the patient's experience of drop attacks. The VEMP test and EcochG were not performed during the second and third MRI examinations.

3. Discussion

MRI with intratympanic administration of gadolinium can be used for imaging analysis of the inner ear in patients with Meniere's disease [1]. The clinical imaging of endolymphatic hydrops using 3-T 3D-FLAIR MRI was also reported [2]. Intratympanically administered gadolinium moves into the scala tympani of the basal turn of the cochlea and the perilymphatic space of the vestibule, and the border between the perilymph and endolymph is clearly visible in 3D-FLAIR MRI taken 24 h after the injection [2]. 3D-FLAIR MRI is sensitive enough to detect inner ear disturbances [4,5].

Our patient's hearing level, especially at lower frequencies, had fluctuated along with equilibrium disturbance, which are typical symptoms of Meniere's disease. 3D-FLAIR MRI showed the changing severity of the endolymphatic hydrops and that this correlated with changes in the patient's hearing level. That is, the observed enlarged or reduced endolymphatic hydrops, especially in the upper turns, correlated with deterioration or improvement of his hearing thresholds at lower frequencies. Importantly, the gadolinium was more clearly visible in the vestibule on the third MRI, suggesting that the reduced endolymphatic hydrops in the vestibule enabled the movement of the gadolinium from the scala tympani of the cochlea to the vestibule. Pathophysiologically, a drop attack might occur when the endolymphatic hydrops involves the vestibule.

Pathological changes of Meniere's disease include endolymphatic hydrops and abnormalities in the cochlear lateral wall, hair cells, and spiral ganglion. Endolymphatic hydrops may be considered a histological marker for Meniere's disease rather than being directly responsible for its symptoms [6]. Endolymphatic hydrops observed with MRI could provide useful information for the treatment of patients diagnosed with Meniere's disease. No adverse effects of the intratympanic injection of gadolinium have been observed so far, and this procedure is considered a safe method with no ototoxicity [7].

We are planning further investigations to evaluate more precisely the relationship between images of the endolymphatic space and clinical findings on a large number of patients with Meniere's disease. We will collect data on the changes of hearing level, direction of nystagmus, VEMP, and EcochG.

Acknowledgements

This study was supported by research grants from the Ministry of Health, Labor, and Welfare and from the Ministry of Education, Culture, Sports, Science, and Technology of Japan.

References

[1] Zou J, Pyykkö I, Bjelke B, Dastidar P, Toppila E. Communication between the perilymphatic scalae and spiral ligament visualized by in vivo MRI. Audiol Neurootol 2005;10:145–52.

[2] Nakashima T, Naganawa S, Sugiura M, Teranishi M, Sone M, Hayashi H, et al. Visualization of endolymphatic hydrops in patients with Meniere's disease. Laryngoscope 2007;17:415–20.

[3] Nakashima T, Naganawa S, Pyykkö I, Gibson WP, Sone M, Nakata S, et al. Grading of endolymphatic hydrops using magnetic resonance imaging. Acta Otolaryngol 2009;129:5–8.

[4] Sone M, Mizuno T, Sugiura M, Naganawa S, Nakashima T. Three-dimensional fluid-attenuated inversion recovery magnetic resonance imaging investigation of inner ear disturbances in cases of middle ear cholesteatoma with labyrinthine fistula. Otol Neurotol 2007;28:1029–33.

[5] Sone M, Mizuno T, Naganawa S, Nakashima T. Imaging analysis in cases with inflammation-induced sensorineural hearing loss. Acta Otolaryngologica 2009;129:239–43.

[6] Merchant SN, Adams JC, Nador Jr JB. Pathophysiology of Meniere's syndrome: are symptoms caused by endolymphatic hydrops? Otol Neurotol 2005;26:74–81.

[7] Nakashima T, Naganawa S, Sone M. In reference to visualization of endolymphatic hydrops in patients with Meniere's disease. Laryngoscope 2008;118:946–7.

Eur Arch Otorhinolaryngol (2009) 266:1871–1877
DOI 10.1007/s00405-009-0989-5

OTOLOGY

Image evaluation of endolymphatic space in fluctuating hearing loss without vertigo

**Masaaki Teranishi · Shinji Naganawa ·
Naomi Katayama · Makoto Sugiura · Seiichi Nakata ·
Michihiko Sone · Tsutomu Nakashima**

Received: 22 October 2008 / Accepted: 28 April 2009 / Published online: 20 May 2009

Abstract The objective of the present study was to investigate endolymphatic space images in patients with fluctuating hearing loss without vertigo, and to elucidate its underlying pathophysiology. Eight patients with fluctuating hearing loss without vertigo were included in this study. 3T MRI was taken, 24 h after intratympanic injection of gadolinium-diethylenetriamine pentaacetic acid (Gd-DTPA). Electrocochleography and VEMP tests were performed to evaluate cochlear and vestibular functions. Endolymphatic hydrops were observed both in the cochlea and in the vestibule of all eight patients. Three patients out of six whose summating potential/action potential (SP/AP) ratio was recordable showed an elevation of SP/AP ratio. In the two patients with remarkable endolymphatic hydrops in the vestibule, VEMP was absent from the affected ear. In conclusion, 3T MRI after intratympanic injection of Gd-DTPA revealed endolymphatic hydrops both in the cochlea and in the vestibule in the patients with fluctuating hearing loss without vertigo.

Keywords Fluctuating hearing loss without vertigo · MRI · Endolymphatic space · Electrocochleography · VEMP · Meniere

Introduction

Fluctuating hearing loss without vertigo is frequently termed as cochlear Meniere's disease. Meniere's disease is a syndrome characterized by repeated vertiginous spells accompanied by fluctuating hearing loss and aural fullness. Hallpike and Yamakawa almost simultaneously, but independently, reported an enlarged endolymphatic space in the temporal bones of patients with Meniere's disease, demonstrating that endolymphatic hydrops are its principal underlying pathology [1, 2]. As well as classic or typical Meniere's disease, which shows repeated vertigo, hearing loss and aural fullness, atypical Meniere's disease exists, which shows fluctuating hearing loss without vertigo or repeated vertigo without hearing loss. Atypical Meniere's disease involving fluctuating hearing loss without vertigo was defined as cochlear Meniere's disease by the subcommittee on equilibrium and its measurement of the American Academy of Ophthalmology and Otolaryngology (AAOO) in 1972 [3]. Williams reported patients that show solely cochlear symptoms as endolymphatic hydrops without vertigo [4]. Some previous case reports that investigated the temporal bones of patients showed endolymphatic hydrops, suggesting that it is involved in the pathology of both cochlear Meniere's disease and classic Meniere's disease [5–7]. However, in 1985, the Committee on Hearing and Equilibrium of the American Academy of Otolaryngology-Head and Neck Surgery (AAO-HNS) decided to limit the diagnostic term "Meniere's disease" to those patients with the full complement of classic symptoms and exclude the variants of Meniere's disease that are referred to as cochlear and vestibular Meniere's disease. This exclusion was based on an absence of documentation that these variants are based on the same pathological disorder as Meniere's disease [8]. Thus, the exact definition of variants of

---

M. Teranishi (✉) · N. Katayama · M. Sugiura · S. Nakata · M. Sone · T. Nakashima
Department of Otorhinolaryngology,
Graduate School of Medicine, Nagoya University,
65, Tsurumai-cho, Showa-ku, Nagoya 466-8550, Japan
e-mail: masaaki@med.nagoya-u.ac.jp

S. Naganawa
Department of Radiology, Graduate School of Medicine,
Nagoya University, Nagoya, Japan

Meniere's disease continues to be controversial. According to the most recent definition by AAO-HNS in 1995, cochlear variants with disequilibrium are classified as possible Meniere's disease. In the AAO-HNS criteria in 1995, certain Meniere's disease requires histological pathological confirmation after autopsy [9]; objective diagnosis with histological confirmation is now virtually impossible for live patients. Recently, we established an endolymphatic space imaging using 3T MRI after intratympanic injection of gadolinium-diethylenetriamine pentaacetic acid (Gd-DTPA). Gd-DTPA distributes widely in the perilymphatic space of both cochlea and vestibule 24 h after intratympanic injection. The enlarged endolymphatic space without Gd-DTPA distribution has been recognized as an area of low-signal intensity surrounded by high-signal perilymphatic fluid with Gd-DTPA distribution in patients with Meniere's disease [10–13]. Therefore, MRI after intratympanic injection of Gd-DTPA is a promising alternative for the histological confirmation of endolymphatic hydrops. We have undertaken the present study to investigate endolymphatic space images in patients with fluctuating hearing loss without vertigo, and to elucidate its underlying pathophysiology.

Materials and methods

Patients

Eight patients, who showed fluctuation of unilateral hearing loss without vertiginous spells and met the 1972 AAOO criteria for cochlear Meniere's disease [3], were enrolled in this study. Age, sex, affected side, and average hearing level at 500 Hz, 1, and 2 kHz are presented in Table 1. Each patient underwent intratympanic administration of gadolinium-diethylenetriamine pentaacetic acid bis(methylamide) (Gd-DPTA-BMA; Omniscan, Daiichi Pharmaceutical Co., Tokyo, Japan) in the affected ear. The protocol of the study was approved by the Ethics Review Committee of Nagoya University School of Medicine. All patients gave their informed consent to participate in this study. Each patient's written informed consent was attached to his or her electronic medical record after permission was given.

Intratympanic gadolinium injection

The detailed methods for intratympanic gadolinium injection have been reported previously [10]. Gd-DPTA BMA was diluted eightfold with saline (v/v 1:7). The diluted Gd-DPTA BMA was injected through the tympanic membrane using a 23-G needle and a 1-ml syringe after the patient was placed in the supine position with the head turned approximately 30° away from the sagittal line toward the other ear. The injection was performed under a microscope. The amount of diluted gadolinium injected was 0.4–0.5 ml. After the injection, the patient remained in the supine position for 60 min with the head turned approximately 60° away from the sagittal line toward the other ear.

MR imaging

According to the results from the previous study, scan delay after intratympanic gadolinium injection was determined as 24 h to allow the distribution of gadolinium widely in the perilymphatic space of the labyrinth [10]. MRI scans were performed with a 3T MR unit (Trio, Siemens, Erlangen, Germany) using a receive-only 12-channel phased-array coil. As described previously [11–13], T1-weighted 3D-FLASH (fast low-angle shot) and conventional 3D-FLAIR (fluid-attenuated inversion recovery) imaging was performed. T2-weighted 3D-CISS (construc-

Table 1 Summary of clinical and MRI findings

Case number	Age, gender	Affected side	Hearing levels (dB)	Vestibular symptoms	SP/AP (%)	VEMP	Size of endolymphatic space in cochlea	Size of endolymphatic space in vestibule
1	31, M	Right	25, 37	None	Not performed	Normal	2	1
2	60, F	Right	20, 37	None	43	Not performed	1	1
3	45, M	Right	52, 63	Dizziness	21	Noise level	2	1
4	65, M	Left	50, 55	None	Not recordable	Noise level	2	2
5	54, M	Left	23, 23	None	30	Normal	2	1
6	44, F	Right	38, 42	Dizziness	41	Noise level	2	1
7	69, F	Left	22, 23	None	55	Noise level	2	2
8	44, F	Left	13, 28	None	23	Normal	1	1

Hearing levels indicates average of hearing level of 500 Hz, 1, 2 kHz and average of hearing level of 250, 500 Hz, 1 kHz

Size of endolymphatic space in cochlea and in vestibule: *0* no endolymphatic hydrops, *1* mild endolymphayic hydrops, *2* significant endolymphatic hydrops

SP/AP summating potential/action potential on electrocochleography, *VEMP* vestibular evoked myogenic potential tive interference in the steady state) imaging was performed to obtain reference images of labyrinthine fluid-space anatomy. The parameters for 3D-FLAIR and 3D-IR TSE were as follows: TR of 9,000 ms, TE of 134 ms, flip angle of 180° (constant) for the turbo-spin-echo refocusing echo train, echo train length of 23, matrix size of 384 × 384, and 12 axial 2-mm-thick slices covering the labyrinth with a 16-cm^2 field of view, acquired using the GRAPPA parallel imaging technique with an acceleration factor of 2 [14]. The number of excitations was one, and the scan time was 14 min. As previously described [12], TI of 1,000 ms was selected for 3D inversion-recovery imaging of the endolymphatic space, nulling the signal of Gd-containing perilymph. As the suppression of fluid without Gd could be achieved with a TI of 2,500 ms on 3D-FLAIR images, a TI of 1,700 ms (near the midpoint between 1,000 and 2,500 ms) was selected to assign positive longitudinal magnetization to perilymphatic fluid, negative longitudinal magnetization to endolymphatic fluid and zero magnetization to compact bone and air.

Image evaluation of endolymphatic space in MRI

The size of the endolymphatic space was scored according to the reports on the MRI by radiologists who did not know the corresponding clinical information. Scoring was performed using the following criteria. In the vestibule, a score of 2 indicates a remarkable enlargement of endolymphatic space that occupied more than half of the vestibule. A score of 1 indicates a moderate enlargement of endolymphatic space that occupied between 33.3 and 50% area of the vestibule. A score of 0 indicates no or very mild if any enlargement of endolymphatic space that occupied $< 33.3\%$ of the vestibule. In the cochlea, a score of 2 indicates a remarkable enlargement of endolymphatic space whose size is as large as or larger than the scala vestibuli. A score of 1 indicates a moderate enlargement of endolymphatic space. Reissner's membrane was bulging toward the scala vestibuli, although the endolymphatic space is smaller than the perilymphatic space of the scala vestibuli. A score of 0 indicates no or very mild if any enlargement of endolymphatic space. No bulging of Reissner's membrane was shown or no endolymphatic space was observed. These tentative criteria were established according to previous histological research in humans and animals [12, 13, 15–17].

EcochG (extratympanic electrocochleography)

A silver ball electrode was placed on the posteroinferior quadrant of the external ear canal, close to the tympanic membrane. Before the electrode was placed, the skin of the electrode area was cleaned with skin preparation gel for bioelectrical measurements (Skin Pure, Nihonkoden, Tokyo, Japan), and then electrode paste (Biotech, GE Yokogawa Medical, Tokyo, Japan) was spread over the skin area. EcochG was performed while the patient was lying down in a sound-attenuated room. The reference electrode was close to the earlobe, and the ground electrode was on the forehead. The click stimuli were presented four times a second with rarefaction and condensation polarity (Synax 2100, NEC Medical Systems, Tokyo, Japan). The signal was added 500 times through the bandpass filter (100–3,000 Hz). The summating potential (SP) to action potential (AP) ratio was calculated when SP and AP were clear.

VEMP

Surface myogenic potentials in the sternocleidomastoid muscle were added 150 times with a reference electrode over the sternum while clicks (105 dB) were presented to the ipsilateral ear and white noise (75 dB) was presented to the contralateral ear (Synax 2100, NEC Medical Systems, Tokyo, Japan). The ground electrode was on the forehead. The stimulation rate of the clicks was 5 Hz, and the electromyogenic signal was amplified through a bandpass filter (20–2,000 Hz). The patient was instructed to turn his or her head toward the contralateral side in the sitting position to activate the sternomastoid muscle.

Results

Table 1 summarizes patients' clinical and imaging results. Eight patients (four male, four female) were included in this study. Their average age was 51.5 years, with a range of 31–69 years. All the patients experienced fluctuating hearing loss. Figure 1 shows audiograms of each case to demonstrate the best and the worst hearing levels on the affected ear during our observation, so that how far hearing threshold fluctuated in our patients can be recognized. Six patients experienced no vestibular symptoms (no vertigo or dizziness). Two patients experienced subtle dizziness, but no Meniere-type vertigo spells. Endolymphatic hydrops were observed both in the cochlea and in the vestibule of all the eight patients with cochlear Meniere's disease. The evaluation for cochlear alteration/enlargement of endolymphatic space was determined in basal, middle, and apical turns of the cochlea, if the gadolinium was distributed in the perilymph of all cochlear turns and endolymphatic space was recognized. In all the cases except case 2, the extent of endolymphatic hydrops does not differ among each cochlear turn. In case 2, gadolinium was distributed only in the basal turn and endolymphatic space was determined only in the basal turn. Three patients (cases 2, 6, and 7) out of six whose SP/AP ratio was recordable showed an

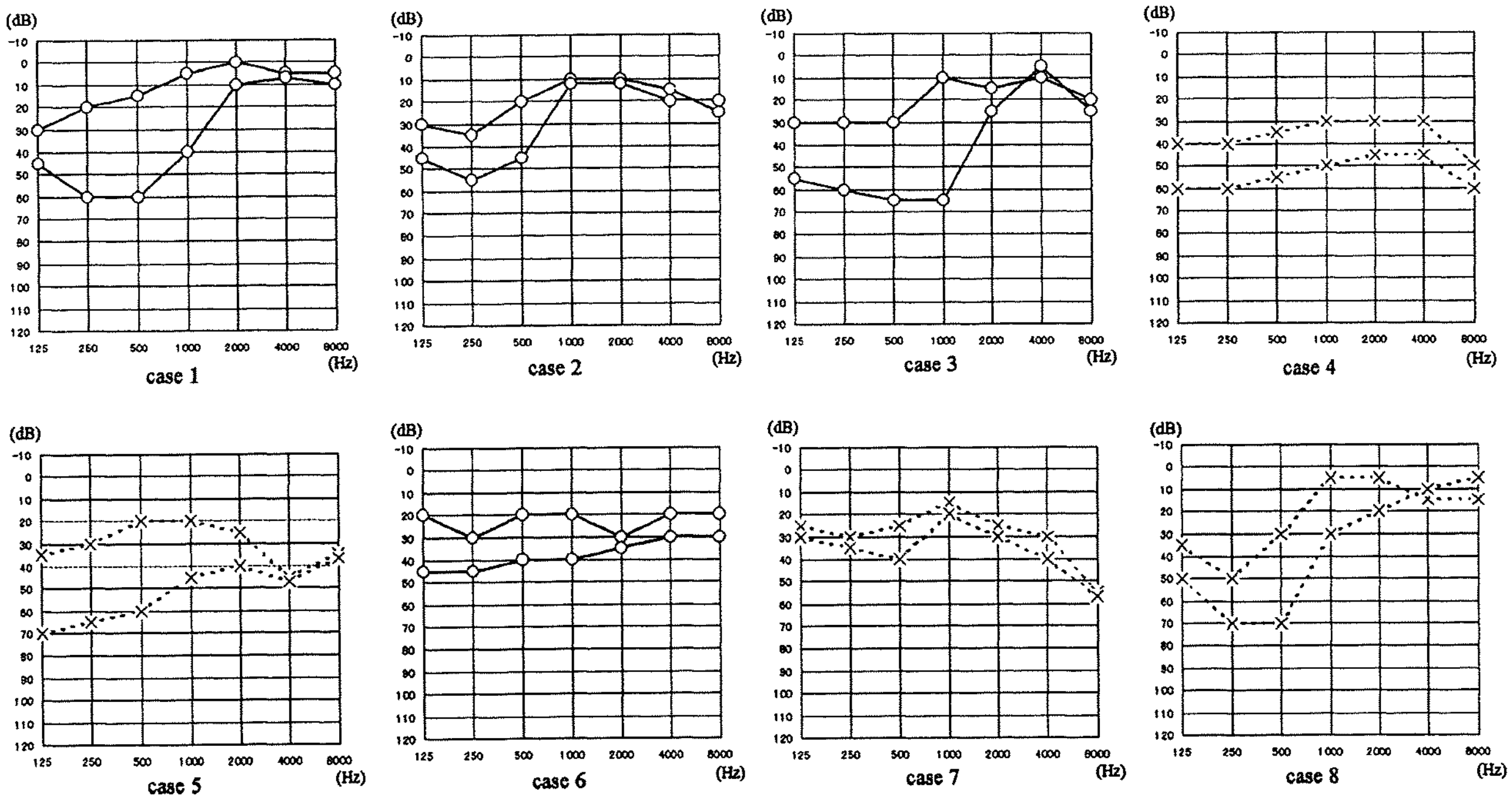

Fig. 1 Audiograms on the affected ear of the eight cases. The best hearing level and the worst one during our observation were shown. The vertical axis indicates hearing level (dB) on air conduction and the horizontal axis indicates each frequency (Hz). *o* right side of the ear, *x* left side of the ear

elevation of SP/AP ratio. In the two patients (cases 4 and 7) with remarkable endolymphatic hydrops in the vestibule, VEMP was absent from the affected ear. Among the five patients with moderate endolymphatic hydrops who underwent the VEMP test, the response was absent in two patients (cases 3 and 6) and the response was present in three patients (cases 1, 5, and 8) in the affected ears. No side effects related to the intratympanic injection of Gd-DTPA such as worsening of hearing level or tinnitus was observed.

Figure 2 shows MR images of a 45-year-old man (case 3). He experienced repeated aural fullness and fluctuation of hearing loss at low frequencies. He also felt slight dizziness from time to time. SP/AP ratio from electrocochleography was 21% and VEMP response was absent from the affected side. 3D-FLAIR shows an enlarged endolymphatic space in the cochlea as low signal areas. However, the boundary between the endolymphatic space and surrounding bone is unclear. Moderate enlargement of the endolymphatic space in the vestibule was observed. A 3D-real IR sequence visualizes remarkably enlarged endolymphatic space in the cochlea and moderately enlarged endolymphatic space in the vestibule as negative signal intensity values, while the surrounding bone area has near-zero signal intensity. This image allows the separation of the perilymphatic space (high signal intensity), endolymphatic space, and surrounding bone on a single plain, so that endolymphatic hydrops in all cochlear turns were identified.

Figure 3 shows MR images of a 54-year-old man (case 5). He experienced repeated aural fullness and fluctuation of hearing loss at low frequencies. He did not experience vestibular symptoms. The SP/AP ratio from electrocochleography was 30% and VEMP showed a normal response on the affected side. Remarkable endolymphatic hydrops are observed in the cochlea and moderate endolymphatic hydrops are observed in the vestibule.

Discussion

This study is the first report of image evaluation of endolymphatic space in fluctuating hearing loss without vertigo. We have shown in the present study that 3T MRI taken 24 h after intratympanic injection of Gd-DTPA revealed endolymphatic hydrops both in the cochlea and in the vestibule in all eight patients with cochlear Meniere's disease. Merchant et al. reported that seven out of eight patients with fluctuating or progressive sensorineural hearing loss in the absence of vertigo spells showed idiopathic endolymphatic hydrops both in the cochlea and in the vestibule of their temporal bones after autopsy, with one exception that showed endolymphatic hydrops only in the cochlea. They also demonstrated in the same study that all 26 patients with classic Meniere's symptom complex showed dilatation of the cochlear duct and the saccule, and the majority (65%) also had hydrops involving the utricle or the ampullae

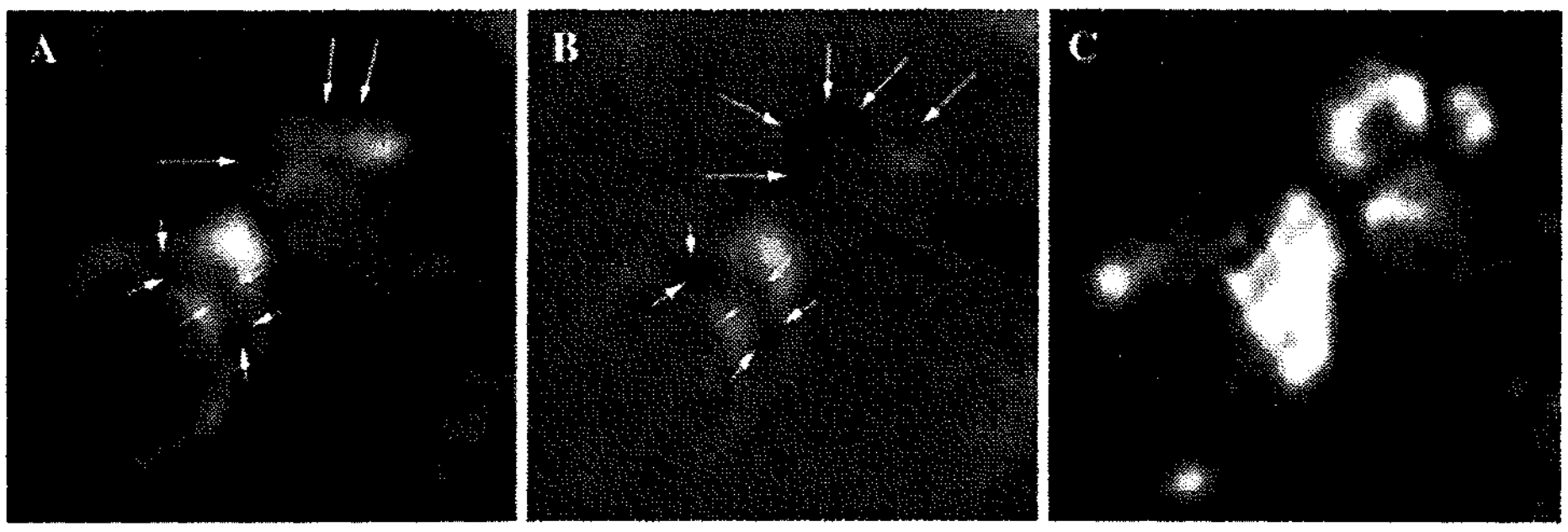

Fig. 2 MRI of case 3. **a** 3D FLAIR shows an enlarged endolymphatic space in the cochlea (*arrows*) as a low signal area. However, the boundary between the endolymphatic space and surrounding bone is unclear. Moderate enlargement of the endolymphatic space in the vestibule (*short arrows*) was observed. **b** A 3D-real IR sequence visualizes remarkably enlarged endolymphatic space in the cochlea (*arrows*) and moderately enlarged endolymphatic space in the vestibule (*short arrows*) as negative signal intensity values, while the surrounding bone area has near-zero signal intensity. Endolymphatic hydrops in all cochlear turns were identified. **c** 3D-CISS image shows the combination of endolymphatic and perilymphatic space

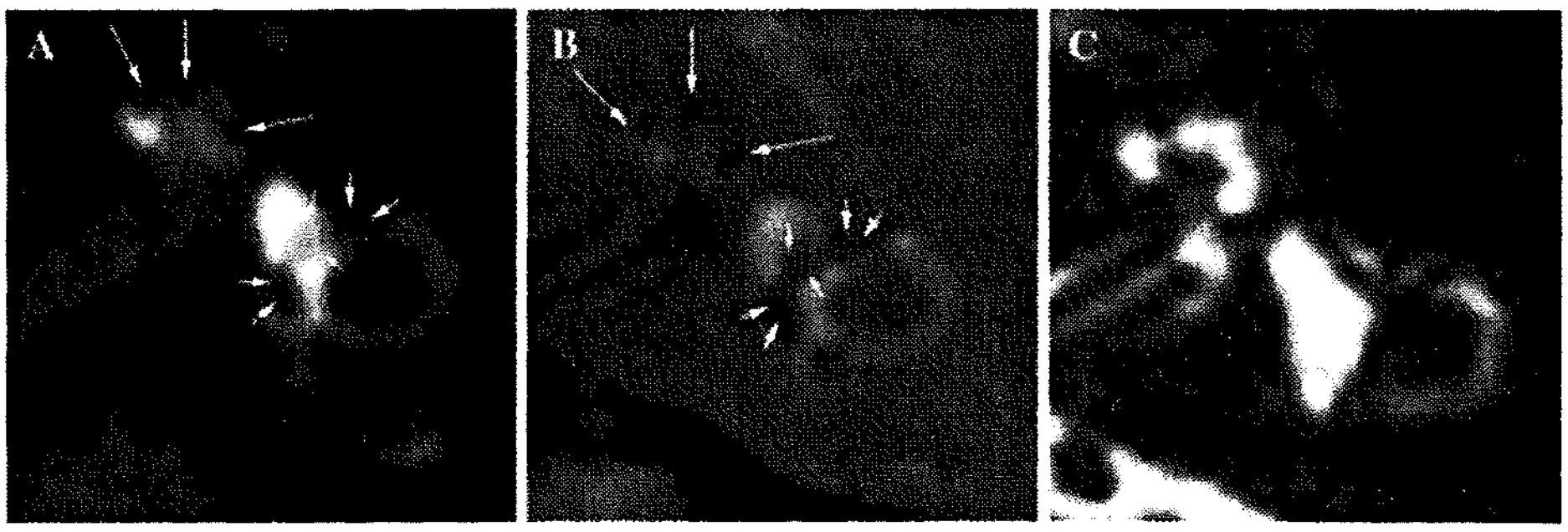

Fig. 3 MRI of case 5. **a** 3D FLAIR shows enlarged endolymphatic space in the cochlea (*arrows*) as low signal areas. However, the boundary between the endolymphatic space and surrounding bone is unclear. Moderate enlargement of the endolymphatic space in the vestibule (*short arrows*) was observed. **b** A 3D-real IR sequence visualizes remarkably enlarged endolymphatic space in the cochlea (*arrows*) and moderately enlarged endolymphatic space in the vestibule (*short arrows*) as negative signal intensity values, while the surrounding bone area has near-zero signal intensity. **c** 3D-CISS image shows the combination of endolymphatic and perilymphatic space

[18]. We recently reported that 3T MRI 24 h after intratympanic injection of Gd-DTPA revealed endolymphatic hydrops both in the cochlea and in the vestibule in all six patients with classic Meniere's disease [13]. The pathophysiological essence of Meniere's disease is endolymphatic hydrops. The existence of cochlear Meniere's disease has been questioned because of lack of evidence on its association with endolymphatic hydrops [8, 19]. Judging from our present study and a recent temporal bone study by others, cochlear Meniere's disease is truly a subtype of Meniere's disease and a similar pathophysiological mechanism is involved in both classic and cochlear Meniere's disease. The only difference is the manifestation of symptoms. Clinical and pathological evidence supports the existence of symptomatic and asymptomatic forms of endolymphatic hydrops. About one-third of the contralateral ears showed asymptomatic endolymphatic hydrops in patients with unilateral Meniere's disease by a temporal bone study after autopsy [20]. Schuknecht et al. reported that the endolymphatic hydrops must be progressive, thereby causing ruptures and distortion of the labyrinth, if they are symptomatic [21]. So far, we have no way of establishing whether the hydrops in asymptomatic cases are progressive or not. A 3T MRI after intratympanic injection of Gd-DTPA has the potential of in vivo imaging to permit a systematic assessment of the dynamic events over time in patients with endolymphatic hydrops. The utriculo-endolymphatic valve is located in the anteroinferior wall of the utricle at the orifice of the utricular duct and its probable role is to maintain the anatomical and humoral independence of the pars superior (utricle and canals) from the pars inferior (cochlear duct and saccule). The utriculo-endolymphatic valve might protect the vestibular apparatus from the hydropic condition [19, 22]. A substantial number of patients (80%) with cochlear Meniere's disease eventually proceed to classic Meniere's disease [23]. People under mental stress show an elevation of plasma level of stress-related hormone, vasopressin [24, 25]. Patients with endolymphatic hydrops-related diseases such as Meniere's disease also show an elevation of plasma level of vasopressin [26]. Guinea pig or rats treated systemically with vasopressin showed remarkable endolymphatic hydrops in the inner

ear compared with controls [27, 28]. Patients with cochlear Meniere's disease could have vertigo spells eventually, via progression of endolymphatic hydrops if they continue to be under stress.

We have performed functional tests, including EcochG, to assess cochlear function and a VEMP test to assess vestibular function [29, 30]. Elevation of the SP/AP ratio by more than 36% is considered positive for cochlear endolymphatic hydrops [13, 31]. In the present study, three patients (50%) out of six whose SP/AP ratio was recordable showed an elevation of SP/AP ratio. Dornhoffer previously reported that six of nine ears (67%) with cochlear Meniere's disease showed abnormal EcochG results suggestive of endolymphatic hydrops, which is similar to our present study [19]. Using click SP/AP ratio, the false negative results reach 54%, if the hearing level is less than 40 dB. Further utilization of tone burst data will make EcochG more sensitive. By using the norms established for 1,000 Hz, false negative results are reduced to 23% [32]. Introduction with other frequencies using tone burst will further increase the sensitivity of EcochG [19, 33]. A positive VEMP response is considered a normal sign of vestibular function, especially for the saccule. Lin reported the usefulness of the VEMP test to detect asymptomatic saccular hydrops [30]. However, we did not perform caloric tests to evaluate vestibular function transmitted by the pars superior of the vestibular nerve. This is the limitation of our study. Among the five patients with moderate endolymphatic hydrops who underwent a VEMP test, a VEMP response was absent in two patients (40%) in the affected ear. On the other hand, in the two patients with remarkable endolymphatic hydrops in the vestibule, a VEMP response was absent from the affected ears of both patients (100%). This may imply that the presence or absence of VEMP reflects the severity of vestibular endolymphatic hydrops. The existence of VEMP depends also on the degree of hearing loss, especially in lower frequencies as previously reported [34]. The two patients whose VEMP response was present among five patients with mild vestibular endolymphatic hydrops had better average hearing level of 250 Hz, 500 Hz, 1 kHz than the three patients whose VEMP was absent. Hearing level in lower frequencies might have influenced the presence or absence of VEMP in patients with mild vestibular endolymphatic hydrops.

In conclusion, 3T MRI after intratympanic injection of Gd-DTPA revealed endolymphatic hydrops both in the cochlea and in the vestibule in patients with cochlear Meniere's disease, a true variant of classic Meniere's disease.

Acknowledgments This study was supported by research grants from the Ministry of Health, Labor, and Welfare and from the Ministry of Education, Culture, Sports, Science, and Technology of Japan.

References

1. Yamakawa K (1938) Uber die pathologisch Veranderung bei einem Meniere-Kranken. J Otorhinolaryngol Soc Jpn 4:2310–2312
2. Hallpike SC, Cairns H (1938) Observations on the pathology of Meniere's syndrome. J Laryngol Otol 53:625–655. doi:10.1017/S0022215100003947
3. Alford BR (1972) Report of subcommittee on equilibrium and its measurement. Meniere's disease: criteria for diagnosis and evaluation of therapy for reporting. Trans Am Acad Ophthalmol Otolaryngol 76:1462–1464
4. Williams HL (1950) Endolymphatic hydrops without vertigo. Arch Otolaryngol 51:557–581
5. Lindsay JR, von Schulthess G (1958) An usual case of labyrinthine hydrops. Acta Otolaryngol 49:315–324. doi:10.3109/00016485809134760
6. Kohut RI, Lindsay JR (1972) Pathologic changes in idiopathic labyrinthine hydrops. Acta Otolaryngol 73:402–412. doi:10.3109/00016487209138959
7. Altmann F, Kornfield M (1965) Histological studies of Meniere's disease. Ann Otol Rhinol Laryngol 74:915–943
8. Pearson BW, Brackmann DE (1985) Committee on hearing and equilibrium guidelines for reporting treatment results in Meniere's disease. Otolaryngol Head Neck Surg 93:579–582
9. American Academy of Otolaryngology-Head and Neck Surgery Foundation, Inc (1995) Committee on hearing and equilibrium guidelines for the diagnosis and evaluation of therapy in Meniere's disease. Otolaryngol Head Neck Surg 113:181–185
10. Nakashima T, Naganawa S, Sugiura M et al (2007) Visualization of endolymphatic hydrops in patients with Meniere's disease. Laryngoscope 117:415–420. doi:10.1097/MLG.0b013e31802c300c
11. Naganawa S, Satake H, Iwano S et al (2008) Imaging endolymphatic hydrops at 3 tesla using 3D-FLAIR with intratympanic Gd-DTPA administration. Magn Reson Med Sci 7:85–91. doi:10.2463/mrms.7.85
12. Naganawa S, Satake H, Kawamura M et al (2008) Separate visualization of endolymphatic space, perilymphatic space and bone by a single pulse sequence; 3D-inversion recovery imaging utilizing real reconstruction after intratympanic Gd-DTPA administration at 3 Tesla. Eur Radiol 18:920–924. doi:10.1007/s00330-008-0854-8
13. Naganawa S, Sugiura M, Kawamura M et al (2008) Imaging of endolymphatic and perilymphatic fluid at 3T after intratympanic administration of gadolinium-diethylene-triamine pentaacetic acid. AJNR Am J Neuroradiol 29:724–726. doi:10.3174/ajnr.A0894
14. Griswold MA, Jakob PM, Heidemann RM et al (2002) Generalized autocalibrating partially parallel acquisitions (GRAPPA). Magn Reson Med 47:1202–1210. doi:10.1002/mrm.10171
15. Salt AN, Henson MM, Gewalt SL et al (1995) Detection and quantification of endolymphatic hydrops in the guinea pig cochlea by magnetic resonance microscopy. Hear Res 88:79–86. doi:10.1016/0378-5955(95)00103-B
16. Shinomori Y, Spack DS, Jones DD, Kimura RS (2001) Volumetic and dimensional analysis of the guinea pig inner ear. Ann Otol Rhinol Laryngol 110:91–98
17. Buckingham RA, Valvassori GE (2001) Inner ear fluid volumes and the resolving power of magnetic resonance imaging: can it differentiate endolymphatic structures? Ann Otol Rhinol Laryngol 110:113–117
18. Merchant SN, Adams JC, Nadol JB Jr (2005) Pathophysiology of Meniere's syndrome: are symptoms caused by endolymphatic hydrops? Otol Neurotol 26:74–81. doi:10.1097/00129492-200501000-00013

19. Dornhoffer JL (1998) Diagnosis of cochlear Meniere's disease with electrocochleography. ORL J Otorhinolaryngol Relat Spec 60:301–305. doi:10.1159/000027614
20. Kariya S, Cureoglu S, Fukushima H et al (2007) Histopathologic changes of contralateral human temporal bone in unilateral Meniere's disease. Otol Neurotol 28:1063–1068
21. Schuknecht HF, Gulya AJ (1983) Endolymphatic hydrops. An overview and classification. Ann Otol Rhinol Laryngol Suppl 106:1–20
22. Schuknecht HF, Belal AA (1975) The utriculo-endolymphatic valve: its functional significance. J Laryngol Otol 89:985–996. doi:10.1017/S0022215100081305
23. Kitahara M, Takeda T, Yazawa Y et al (1984) Pathophysiology of Meniere's disease and its subvarieties. Acta Otolaryngol Suppl 406:52–55
24. Dugue B, Leppanen EA, Teppo AM et al (1993) Effects of psychological stress on plasma interleukins-1 beta and 6, C-reactive protein, tumour necrosis factor alpha, anti-diuretic hormone and serum cortisol. Scand J Clin Lab Invest 53:555–561. doi:10.3109/00365519309092553
25. Charmandari E, Tsigos C, Chrousos G (2005) Endocrinology of the stress response. Annu Rev Physiol 67:259–284. doi:10.1146/annurev.physiol.67.040403.120816
26. Takeda T, Kakigi A, Saito H (1995) Antidiuretic hormone (ADH) and endolymphatic hydrops. Acta Otolaryngol Suppl 519:219–222. doi:10.3109/00016489509121909
27. Takeda T, Takeda S, Kitano H et al (2000) Endolymphatic hydrops induced by chronic administration of vasopressin. Hear Res 140:1–6. doi:10.1016/S0378-5955(99)00180-X
28. Sawada S, Takeda T, Kitano H et al (2002) Aquaporin-2 regulation by vasopressin in the rat inner ear. Neuroreport 13:1127–1129. doi:10.1097/00001756-200207020-00011
29. Ferraro JA, Durrant JD (2006) Electrocochleography in the evaluation of patients with Meniere's disease/endolymphatic hydrops. J Am Acad Audiol 17:45–68. doi:10.3766/jaaa.17.1.6
30. Lin MY, Timmer FC, Oriel BS et al (2006) Vestibular evoked myogenic potentials (VEMP) can detect asymptomatic saccular hydrops. Laryngoscope 116:987–992. doi:10.1097/01.mlg.0000216815.75512.03
31. Ikino CM, de Almeida ER (2006) Summating potential-action potential waveform amplitude and width in the diagnosis of Meniere's disease. Laryngoscope 116:1766–1769. doi:10.1097/01.mlg.0000227976.43352.61
32. Gibson WPR (1990) Electrocochleography: a comparison of clicks versus tone bursts in the diagnosis of endolymphatic hydrops. Proceedings of 3rd international symposium on Meniere's disease, Snowmass-Aspen, pp 281–285
33. Arenberg IK, Bohlen HK (1992) Diagnosis of endolymphatic hydrops using transtympanic electrocochleography. First international conference on ECoG/otoacoustic emissions and electrophysiologic monitoring, Wurzburg
34. de Waele C, Huy PT, Diard JP et al (1999) Saccular dysfunction in Meniere's disease. Am J Otol 20:223–232. doi:10.1016/S0196-0709(99)90004-2

Acta Oto-Laryngologica, 2009; 129: 43–47

informa
healthcare

ORIGINAL ARTICLE

3D computerized model of endolymphatic hydrops from specimens of temporal bone

MASAAKI TERANISHI[1], TADAO YOSHIDA[1], NAOMI KATAYAMA[1], HIDEO HAYASHI[1], HIRONAO OTAKE[1], SEIICHI NAKATA[1], MICHIHIKO SONE[1], PATRICIA A. SCHACHERN[2], MICHAEL M. PAPARELLA[2] & TSUTOMU NAKASHIMA[1]

[1]*Department of Otorhinolaryngology, Nagoya University, Graduate School of Medicine, Nagoya, Japan and*
[2]*Department of Otolaryngology, University of Minnesota, USA*

Abstract

Conclusion: The 3D models of endolymphatic and perilymphatic spaces enabled us to obtain normal and pathological volumes of each space and helped us to understand the 3D structure of various parts of the inner ear and of endolymphatic hydrops. *Objective:* To make a 3D model of the inner ear using sections of temporal bone with and without hydrops. *Materials and methods:* Every 10th 20 μm thick section of temporal bone was collected from two ears with endolymphatic hydrops and five ears without hydrops. Using ZedView, 3D Doctor, FreeForm as analytical software, a 3D model of the inner ear was obtained by reconstruction of these sections. The volumes of the endolymphatic (EV) and perilymphatic spaces (PV) were calculated in each part of the cochlea and vestibular apparatus including the semicircular canals, but the endolymphatic duct and sac were not included. *Results:* In normal ears (controls), the average cochlear EV was 5.1 μl and the PV was 41.9 μl, and the average vestibular EV was 24.0 μl and the PV 75.7 μl. In one hydropic ear, the cochlear EV was 17.5 μl, cochlear PV 30.7 μl, vestibular EV 42.5 μl, and vestibular PV 33.4 μl. In the other hydropic ear, cochlear EV was 31.2 μl, cochlear PV 30.1 μl, vestibular EV 25.6 μl, and vestibular PV 71.8 μl.

Keywords: *Three-dimensional model, endolymphatic space, perilymphatic space, endolymphatic hydrops, temporal bone specimen*

Introduction

A 3D model of the human inner ear is an important tool to aid our understanding of normal physiologic processes as well as their modification during disease [1]. Therapy using intratympanic gentamicin is now widely used for the treatment of intractable Meniere's disease, and intratympanic therapy using steroids has been used to treat Meniere's disease or sudden deafness. A 3D model of hydrops in the inner ear will be helpful in understanding the underlying pathology of Meniere's disease and the pattern of distribution of locally applied drugs such as gentamicin and steroids. In this study we compared the volume of endolymph and perilymph in temporal bones with and without endolymphatic hydrops.

Materials and methods

We used two ears with endolymphatic hydrops and five ears without hydrops from the collection of temporal bones at the University of Minnesota. Clinical information about these patients is shown in Table I. Every 10th 20 μm thick section of temporal bone was studied (Figure 1), using ZedView, 3D Doctor, FreeForm as the analytical software. The 3D reconstruction of the inner ear was performed through segmentation of the endolymphatic and perilymphatic spaces (Figure 2). Endolymphatic volume (EV) and perilymphatic volume (PV) were calculated in each part of the cochlea and in the vestibular apparatus, including the semicircular canals. However, the endolymphatic duct and sac were not investigated because of

---

Correspondence to: Masaaki Teranishi, Department of Otorhinolaryngology, Nagoya University, Graduate School of Medicine, 65, Tsurumai-cho, Showa-ku, Nagoya, 466-8550, Japan. E-mail: masaaki@med.nagoya-u.ac.jp

(Received 24 December 2008; accepted 7 January 2009)

ISSN 0001-6489 print/ISSN 1651-2251 online
DOI: 10.1080/00016480902729868

Table I. Clinical information for the cases studied.

Case no.	Age, gender	Cause of death	Ear
1	77, female	Lung cancer, hepatoma	Endolymphatic hydrops, otosclerosis
2	78, female	Traffic accident	Endolymphatic hydrops, otosclerosis
3	72, male	Cancer, origin unknown	Control
4	74, male	Myocardial infarction	Control
5	67, female	Unknown	Control
6	59, female	Myocardial infarction	Control
7	59, female	Cancer of uterus	Control

difficulty of reconstruction from every 10th section in this area.

Results

In the five ears used as controls, average cochlear EV was 5.1 µl, and average cochlear PV was 41.9 µl. Average vestibular EV in controls was 24.0 µl and average vestibular PV was 75.7 µl. The EV and PV in the inner ears of two hydropic and five control ears are shown in Table II and Figure 3. In one hydropic ear (case 1), the cochlear and vestibular EV was large compared with that in controls. In the other hydropic ear (case 2), the cochlear EV was large but vestibular EV was not large compared with that in controls.

3D models of endolymphatic hydrops (cases 1 and 2) and controls (cases 3 and 7) are presented in Figures 4–7. Figure 4 shows a 3D model of the inner ear of case 1 (with hydrops). This case demonstrates endolymphatic hydrops both in the cochlea and vestibule. Figure 5 shows a 3D model of the inner ear of case 2 (with hydrops). This case demonstrates endolymphatic hydrops only in the cochlea. Figures 6 and 7 show 3D models of the inner ears of cases 3 and 7 (controls). In these cases the endolymphatic space is not enlarged in either the cochlea or the vestibule.

Figure 1. Section of an ear with endolymphatic hydrops.

Figure 2. Segmentation of endolymphatic and perilymphatic spaces. Dark blue areas indicate endolymphatic spaces and light blue areas indicate perilymphatic spaces (case 1).

Table II. Endolymphatic and perilymphatic volumes in the inner ear.

Case no.	Cochlear EV (µl)	Cochlear PV (µl)	Vestibular EV (µl)	Vestibular PV (µl)
1 (hydrops)	17.5	30.7	42.5	33.4
2 (hydrops)	31.2	30.1	25.6	71.8
3 (control)	5.5	36.9	26.5	77.7
4 (control)	4.7	45.7	18.2	56.9
5 (control)	4.7	35.9	22.2	66.4
6 (control)	4.4	38.8	24.6	77.6
7 (control)	6.0	52.4	28.7	100.0

EV, endolymphatic volume; PV, perilymphatic volume.

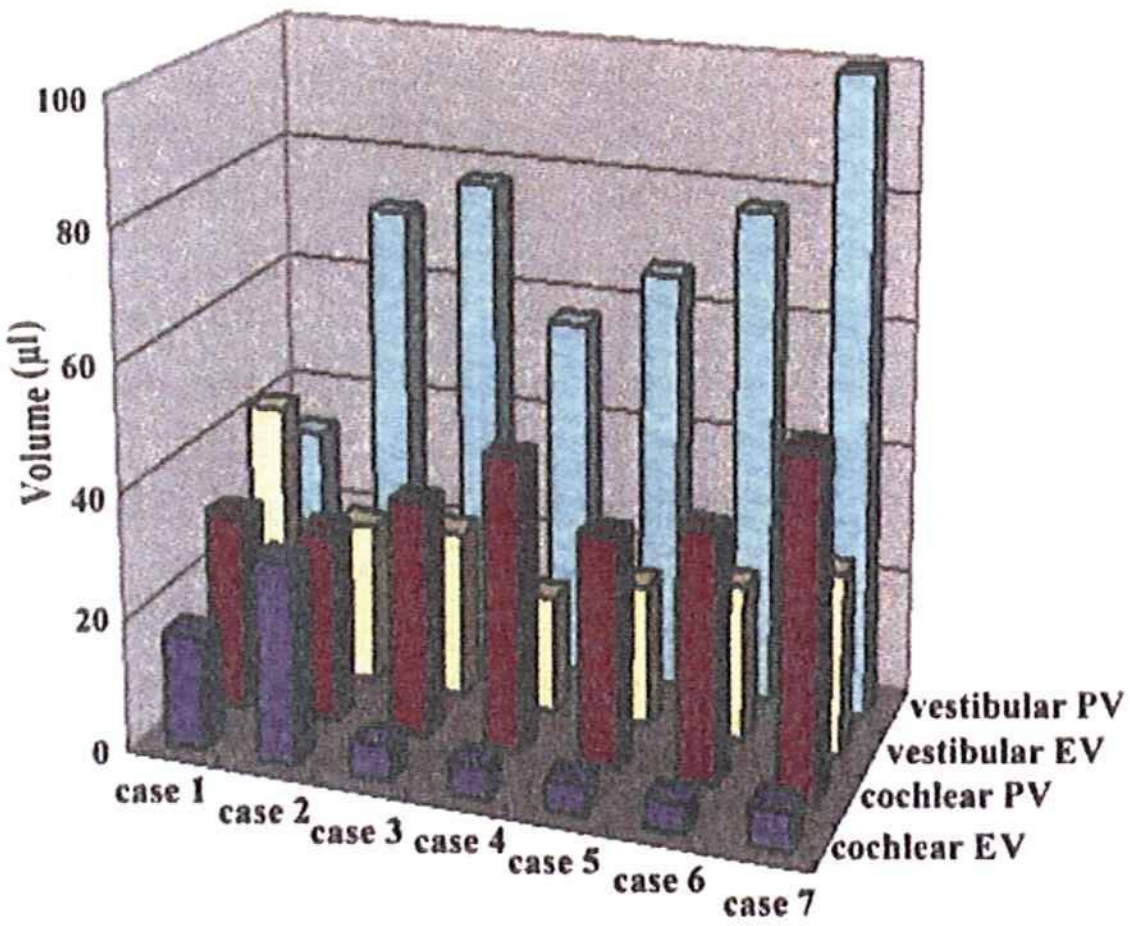

Figure 3. Graph demonstrating endolymphatic volume (EV) and perilymphatic volume (PV) in the inner ear. Case 1 indicates a higher EV than that in controls, both in the cochlea and in the vestibule. Case 2 indicates a higher EV than in controls in the cochlea, but not in the vestibule. Controls: cases 3, 4, 5, 6, and 7.

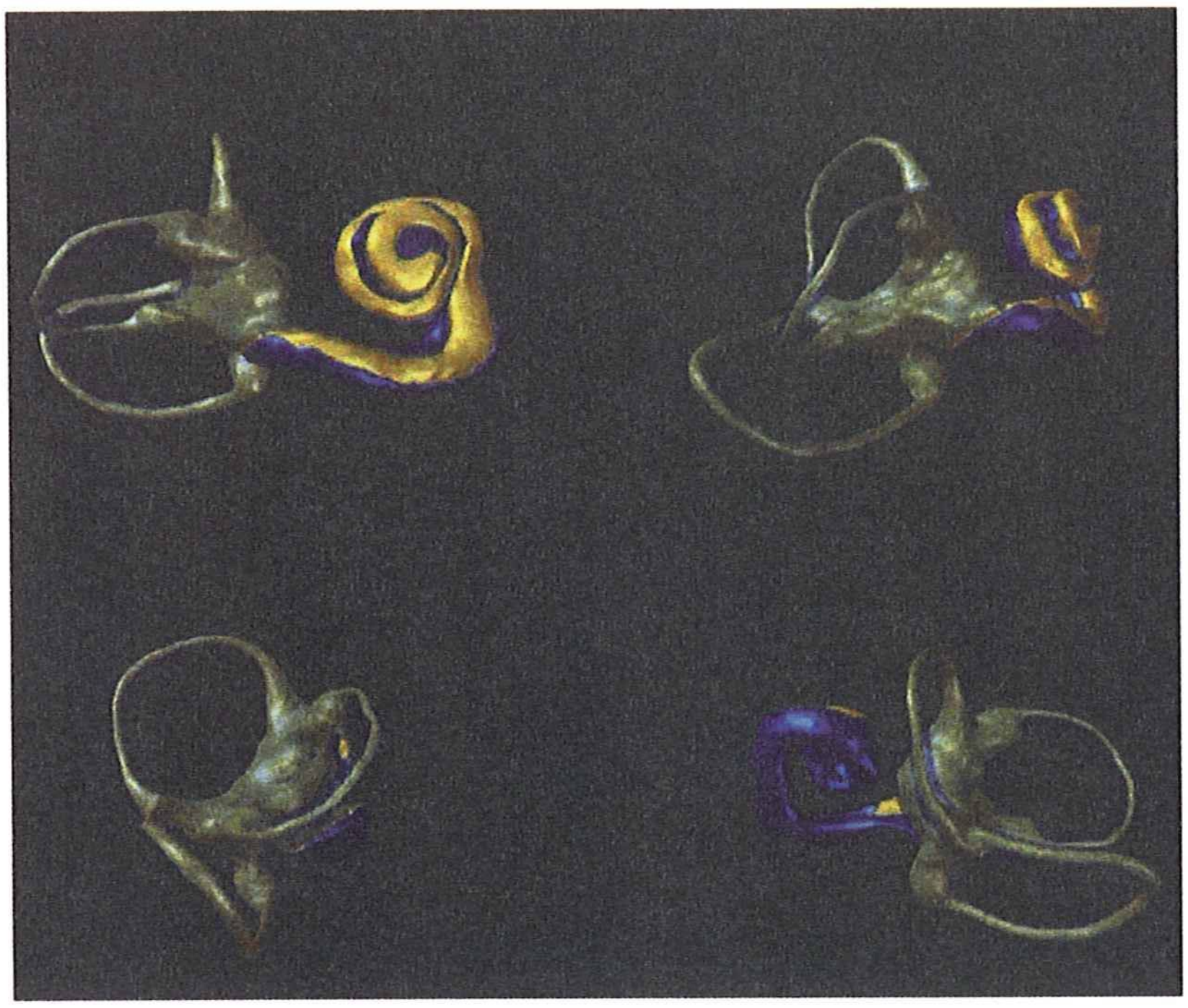

Figure 4. A 3D model of the inner ear of case 1 (with hydrops). Blue area indicates perilymphatic space and yellow area indicates endolymphatic space. This case demonstrates endolymphatic hydrops in both the cochlea and vestibule.

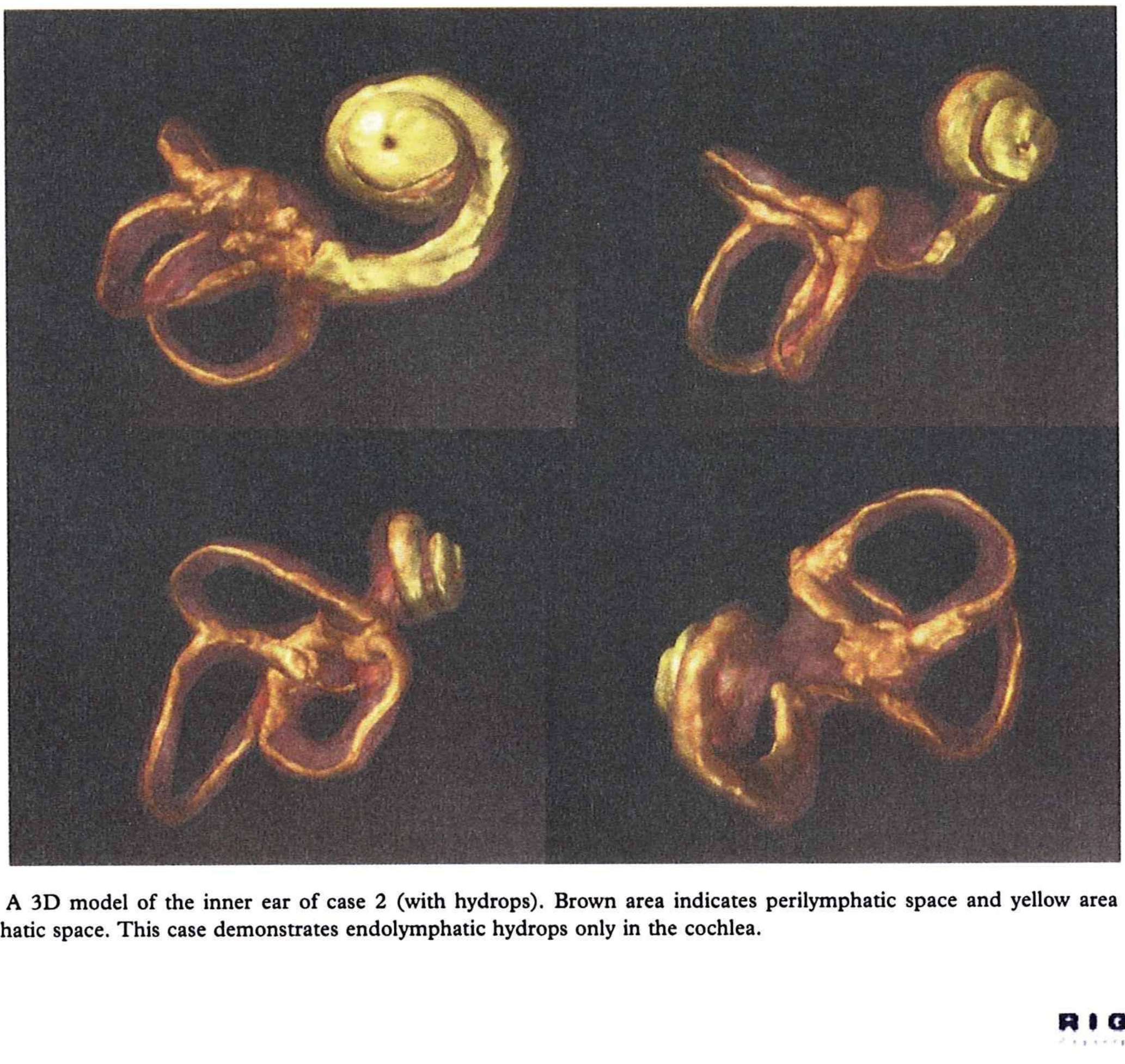

Figure 5. A 3D model of the inner ear of case 2 (with hydrops). Brown area indicates perilymphatic space and yellow area indicates endolymphatic space. This case demonstrates endolymphatic hydrops only in the cochlea.

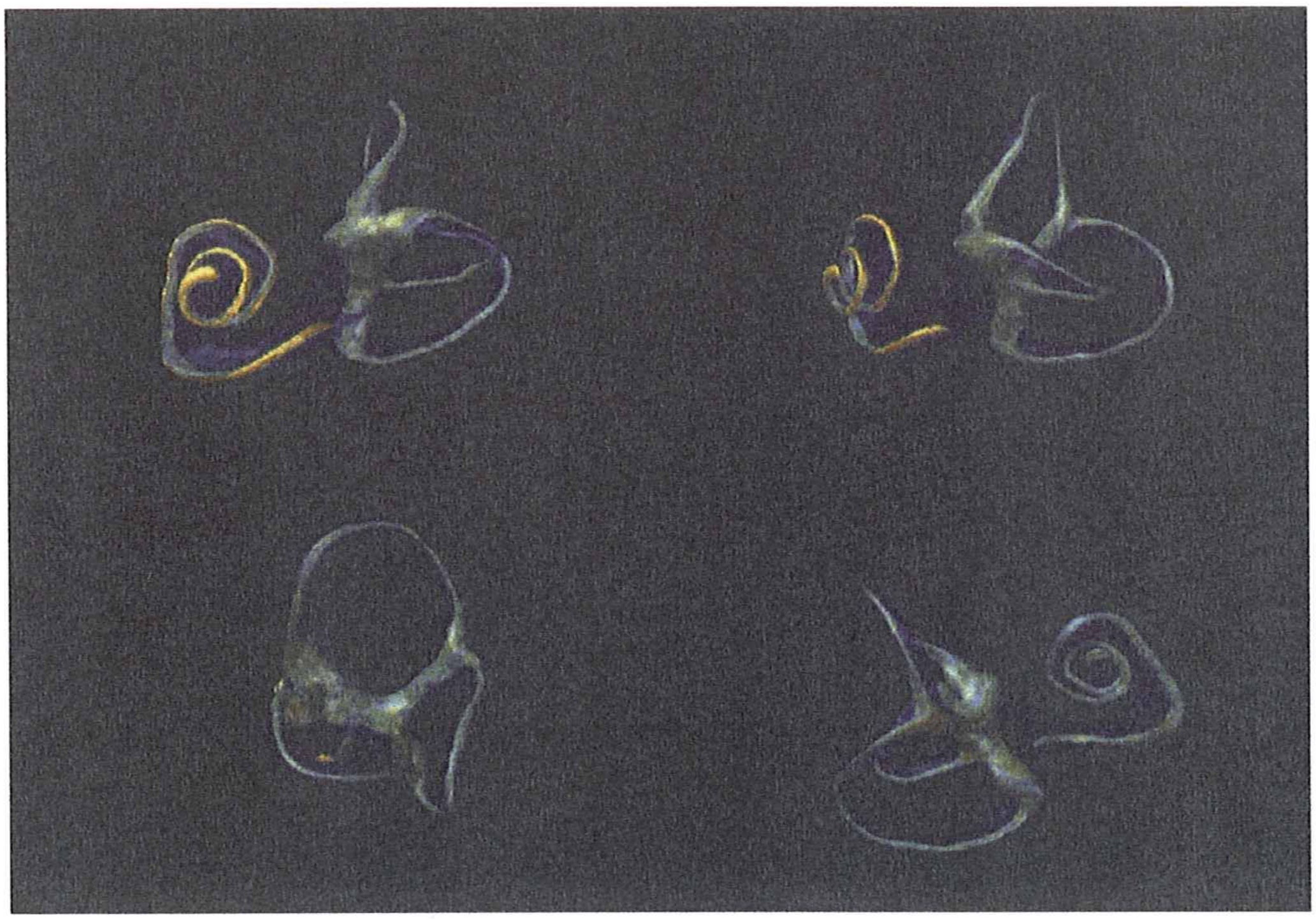

Figure 6. A 3D model of the inner ear of case 3 (a control). Blue area indicates perilymphatic space and yellow area indicates endolymphatic space. The endolymphatic space is not enlarged in either the cochlea or the vestibule.

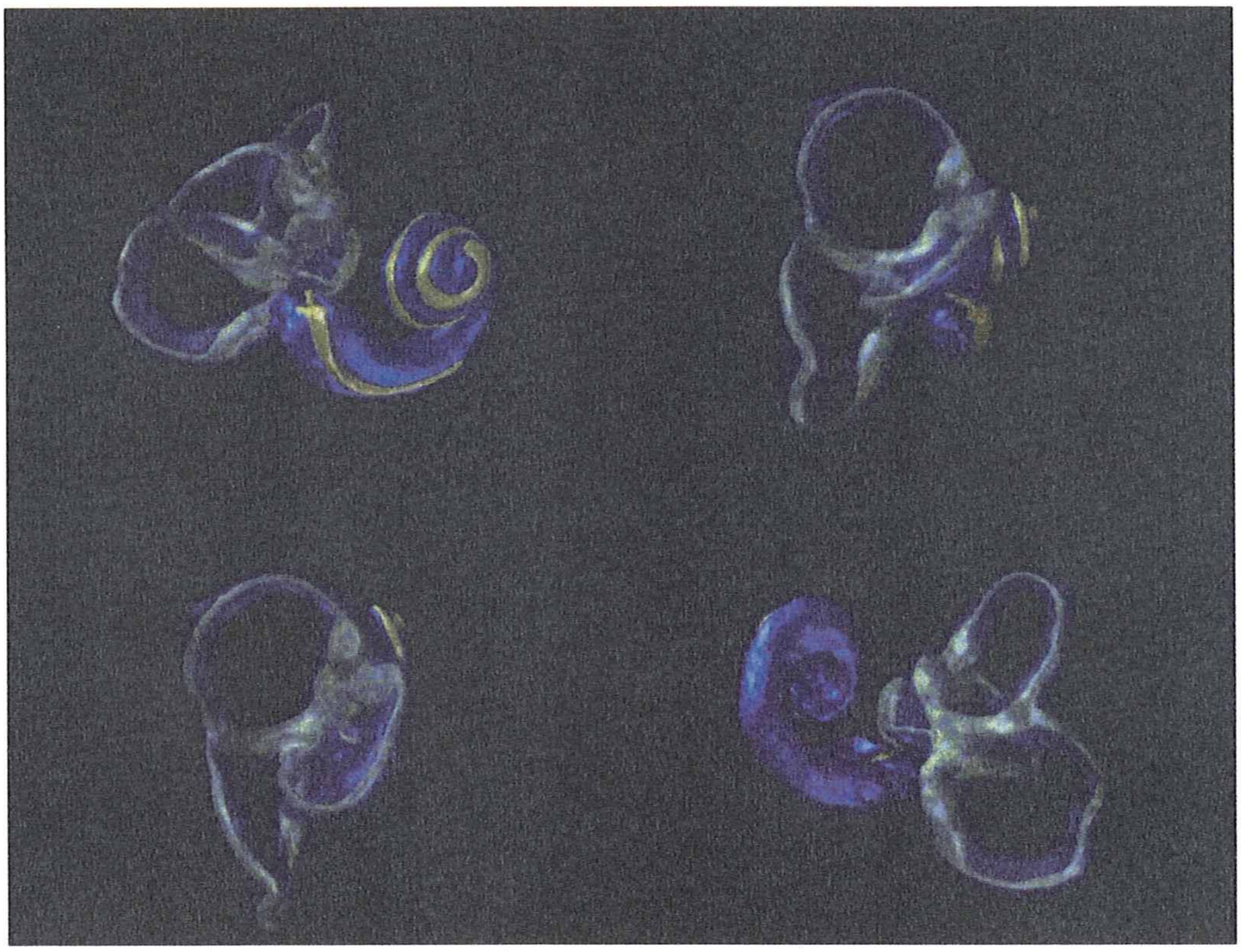

Figure 7. A 3D model of the inner ear of case 7 (a control). Blue area indicates perilymphatic space and yellow area indicates endolymphatic space.

Discussion

Using image-analytical software we have succeeded, for the first time to our knowledge, in making a 3D model of the inner ear and measuring the volumes of perilymphatic and endolymphatic spaces from sections obtained at autopsy in patients who had endolymphatic hydrops. A 3D model of endolymphatic and perilymphatic spaces enabled us to obtain the volumes of each space and gave us useful information about the composition of the inner ear with endolymphatic hydrops. It helps us understand endolymphatic and perilymphatic structures three-dimensionally in various parts of the inner ear because we can observe these from every point of view [1–3].

We conclude that a 3D model of endolymphatic and perilymphatic spaces will enable us to acquire the volumes of each space for further analysis and understanding of the fundamental physiology of these spaces in the hearing apparatus, and may provide possible clinical guidance in diagnostic or therapeutic tasks. It will give us useful information regarding the 3D structures of various parts of the inner ear and the composition of the inner ear with endolymphatic hydrops.

Acknowledgements

This study was supported by research grants from the Ministry of Health, Labour, and Welfare of Japan.

Declaration of interest: The authors report no conflicts of interest. The authors alone are responsible for the content and writing of the paper.

References

[1] Li SF, Zhang TY. Wang ZM. An approach for precise three-dimensional modeling of the human inner ear. ORL J Otorhinolaryngol Relat Spec 2006;68:302–10.
[2] Wang H, Merchant SN, Sorensen MS. A downloadable three-dimensional virtual model of the visible ear. ORL J Otorhinolaryngol Relat Spec 2007;69:63–7.
[3] Wang H, Nothrop C, Burgess B, Liberman MC, Merchant SN. Three-dimensional virtual model of the human temporal bone: a stand-alone, downloadable teaching tool. Otol Neurotol 2006;27:452–7.

Acta Oto-Laryngologica, 2009; 129: 5–8

informa
healthcare

ORIGINAL ARTICLE

Grading of endolymphatic hydrops using magnetic resonance imaging

TSUTOMU NAKASHIMA[1], SHINJI NAGANAWA[2], ILMARI PYYKKÖ[3],
WILLIAM P.R. GIBSON[4], MICHIHIKO SONE[1], SEIICHI NAKATA[1] &
MASAAKI TERANISHI[1]

[1]*Department of Otorhinolaryngology and* [2]*Department of Radiology, Nagoya University School of Medicine, Nagoya, Japan,* [3]*Department of Otolaryngology, University of Tampere, Tampere, Finland and* [4]*Department of Surgery/Otolaryngology, University of Sydney, New South Wales, Australia*

Abstract

Conclusion: Grading of endolymphatic hydrops in the vestibule and the cochlea using magnetic resonance imaging (MRI) is proposed (2008 Nagoya scale). *Objective:* To standardize the evaluation of endolymphatic hydrops in both the vestibule and the cochlea using MRI. *Patients and methods:* The endolymphatic space was evaluated after intratympanic gadolinium injection using three-dimensional fluid attenuated (3D-FLAIR) MRI and three-dimensional real inversion recovery (3D-real IR) MRI. *Results:* A simple three-stage grading system was acceptable for hydrops in both the vestibule and the cochlea: none, mild, and significant. In the vestibule, the grading was determined by the ratio of the area of endolymphatic space to the vestibular fluid space (sum of the endolymphatic and perilymphatic spaces). Patients with no hydrops have a ratio of one-third or less, those with mild hydrops have between one-third and a half, and those with significant hydrops have a ratio of more than 50%. In the cochlea, patients classified as having no hydrops show no displacement of Reissner's membrane; those with mild hydrops show displacement of Reissner's membrane but the area of the endolymphatic space does not exceed the area of the scala vestibuli; and in those with significant hydrops the area of the endolymphatic space exceeds the area of the scala vestibuli.

Keywords: *Membranous labyrinth, endolymphatic space, cochlea, vestibule, gadolinium*

Introduction

Successful visualization of endolymphatic hydrops has been reported in patients with inner ear diseases using advanced magnetic resonance imaging (MRI) with intratympanic gadolinium (Gd) injection [1–3]. Endolymphatic imaging after intravenous Gd injection has also been reported [4,5]. Because endolymphatic space imaging has started to be used or is being planned in many hospitals, standardization of the evaluation of endolymphatic hydrops is necessary.

Patients and methods

In Nagoya University Hospital, endolymphatic imaging was performed after intratympanic Gd injection in more than 70 patients with inner ear diseases. The details of the method are as described previously [1–3]. Briefly, Gd diluted eightfold with saline was injected intratympanically. One day after the injection, inner ear scans were taken using a 3 Tesla MR unit with three-dimensional fluid attenuated (3D-FLAIR) MRI and three-dimensional real inversion recovery (3D-real IR) MRI.

With assistance from the Ministry of Health, Labor and Welfare in Japan, two of the authors (I.P. and W.P.G.) visited Nagoya University for 1 week and investigated endolymphatic imaging performed on three patients. In these patients, meglumin gadopentate (Magnevist®; Bayer HealthCare Pharmaceuticals, Leverkusen, Germany) diluted eightfold with saline (0.5 ml) was injected intratympanically. All authors observed the endolymphatic space in the vestibule and the cochlea of the MRI from the electronic medical records and discussed the images and clinical symptoms.

Correspondence: Tsutomu Nakashima, Department of Otorhinolaryngology, Nagoya University School of Medicine, 65, Tsurumai-cho, Showa-ku, Nagoya, 466-8550, Japan. Tel: +81 52 744 2320. Fax: +81 52 744 2325. E-mail: tsutomun@med.nagoya-u.ac.jp

(Received 5 December 2008; accepted 7 January 2009)

ISSN 0001-6489 print/ISSN 1651-2251 online © 2009 Informa UK Ltd. (Informa Healthcare, Taylor & Francis As)
DOI: 10.1080/00016480902729827

To determine the grading of endolymphatic hydrops, the endolymphatic and perilymphatic spaces were outlined. The ratio of the area of the endolymphatic space to that of the fluid space in the vestibule was calculated using computer software (Adobe Photoshop CS3 Extended; Adobe Systems Inc., San Jose, CA, USA). For reference, the ratio of the endolymphatic space area to that of the fluid space in the vestibule was also calculated for four temporal bone specimens from patients without inner ear diseases.

Results

A scheme for grading endolymphatic hydrops is proposed for the vestibule and the cochlea, respectively. This is shown in Table I. An example of significant hydrops is shown in Figures 1 and 2. Examples of each grade are shown in the next paper in this Supplement.

In the vestibule, when the area ratio of endolymphatic space to the vestibular fluid space exceeds one-third, it is judged as endolymphatic hydrops. When the endolymphatic space exceeds 50% of fluid area in the vestibule, it is classified as significant hydrops. In temporal bone specimens from patients without inner ear diseases, the area ratio of endolymphatic space to the vestibular fluid ranged from 26.5% to 39.4% (mean 33.2%).

For the cochlea, the grading of endolymphatic hydrops has been determined as described in Table I. When the grade of endolymphatic hydrops differs between the basal and upper turns, we recommend reporting a higher grade of endolymphatic hydrops in the cochlea.

Table I. Grading of endolymphatic hydrops using MRI.

Grade of hydrops	Vestibule (area ratio*)	Cochlea
None	≤33.3%	No displacement of Reissner's membrane
Mild	>33.3%, ≤50%	Displacement of Reissner's membrane Area of cochlear duct ≤ area of the scala vestibuli
Significant	>50%	Area of the cochlear duct exceeds the area of the scala vestibuli

*Ratio of the area of the endolymphatic space to that of the fluid space (sum of the endolymphatic and perilymphatic spaces) in the vestibule measured on tracings of images.

Discussion

In the vestibule, an endolymphatic area one-third that of the vestibular fluid space was determined as the border between normal and mild hydrops. This value might be slightly lower compared to the value of the area ratio obtained from the temporal bone specimens. However, the area ratio did not exceed 40% in any temporal bone specimen. We adopted this one-third ratio as a simple index in this study. In future, volume percentage of endolymphatic space should be calculated using more advanced MRI.

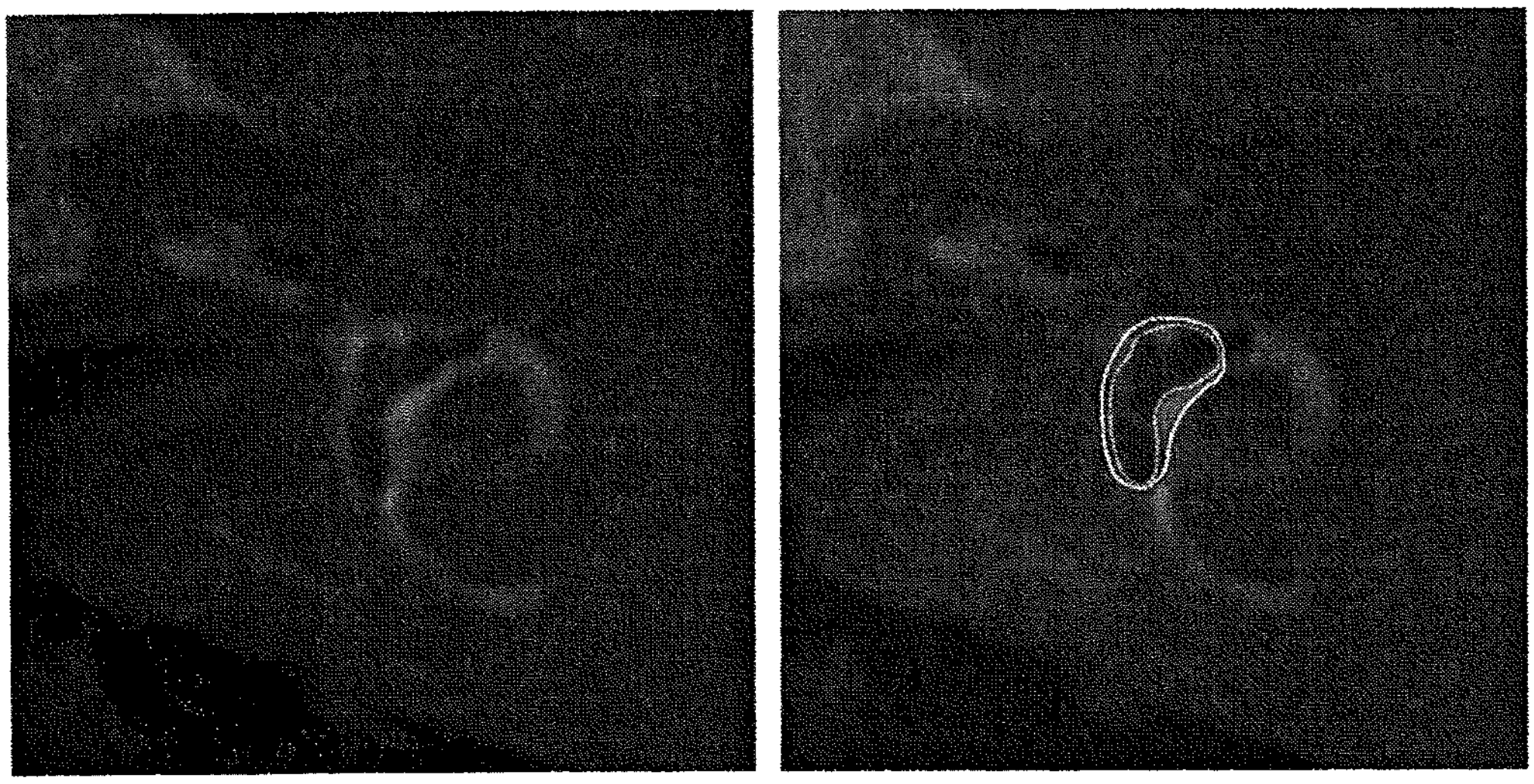

Figure 1. 3D-real IR MRI in a 57-year-old male patient with left Ménière's disease. Original MRI (left side) and line drawings on the MRI (right side). In this MRI, the lateral and posterior semicircular canals are also seen. Dotted line indicates endolymphatic space and solid line indicates the fluid space in the vestibule. Area ratio of the endolymphatic space to the vestibular fluid space is 67.5% (i.e. significant hydrops in the vestibule).

Figure 2. 3D-real IR MRI of the next section of Figure 1. Original MRI (left side) and line drawings of the cochlea on the MRI (right side). Dotted lines indicate endolymphatic spaces of cochlear turns. Solid line indicates fluid area of the cochlea. It it clear that the endolymphatic space (cochlear duct) is larger than the area of the scala vestibuli in the upper turns (i.e. significant hydrops in the cochlea).

In MRI, the cochlear endolymphatic space is divided into cochlear turns, and each space is small. However, the section that includes the modiolus (mid-modiolar section) is the most suitable region for evaluating the endolymphatic space. Not only the mid-modiolar section, but also other sections that include the cochlea help in the evaluation of the endolymphatic space in the cochlea. However, it is occasionally difficult to evaluate the endolymphatic space in all cochlear turns.

When there is collapse of the endolymphatic space, it is not recognized in MRI scans. Moreover, if there is rupture of Reissner's membrane, Gd may enter the endolymphatic space. In this study, collapse of an endolymphatic hydrops in the cochlea was suspected in one patient and collapse of an endolymphatic hydrops in the vestibule was suspected in another patient. In one patient with a large vestibular aqueduct syndrome, rupture of Reissner's membrane was suspected after deterioration in their hearing level. In this patient, Gd was seen in the endolymph of the endolymphatic sac and duct. Accordingly, classification as 'no hydrops' does not always mean 'normal'.

Conclusion

Seventy years have passed since Hallpike and Yamakawa demonstrated endolymphatic hydrops in temporal bone specimens in patients with Ménière's disease. Today, we can image endolymphatic hydrops using advanced MRI technology in living patients. For the standard evaluation of endolymphatic hydrops, we propose a simple three-stage grading of endolymphatic hydrops in the vestibule and the cochlea. The new technology has also enabled us to see pathological conditions in patients with inner ear diseases such as idiopathic sudden sensorineural hearing loss and viral labyrinthitis. Further advancement of MRI is expected to allow more detailed imaging of pathology in patients with inner ear diseases.

Acknowledgements

This study was supported by research grants from the Ministry of Health, Labor and Welfare in Japan. This study was also supported by the Program for the Invitation of Foreign Scientists to Japanese Institutes provided by the Japan Foundation for Aging and Health.

Declaration of interest: The authors report no conflicts of interest. The authors alone are responsible for the content and writing of the paper.

References

[1] Nakashima T, Naganawa S, Sugiura M, Teranishi M, Sone M, Hayashi H, et al. Visualization of endolymphatic hydrops in patients with Meniere's disease. Laryngoscope 2007;117:415–20.

[2] Naganawa S, Sugiura M, Kawamura M, Fukatsu H, Sone M, Nakashima T. Imaging of endolymphatic and perilymphatic fluid at 3T after intratympanic administration of gadolinium-diethylene-triamine pentaacetic acid. AJNR Am J Neuroradiol 2008;29:724–6.

[3] Naganawa S, Satake H, Kawamura M, Fukatsu H, Sone M, Nakashima T. Separate visualization of endolymphatic space, perilymphatic space and bone by a single pulse sequence; 3D-

inversion recovery imaging utilizing real reconstruction after intratympanic Gd-DTPA administration at 3 Tesla. Eur Radiol 2008;18:920–4.

[4] Naganawa S, Komada T, Fukatsu H, Ishigaki T, Takizawa O. Observation of contrast enhancement in the cochlear fluid space of healthy subjects using a 3D-FLAIR sequence at 3 Tesla. Eur Radiol 2006;16:733–7.

[5] Carfrae MJ, Holtzman A, Eames F, Parnes SM, Lupinetti A. 3 Tesla delayed contrast magnetic resonance imaging evaluation of Meniere's disease. Laryngoscope 2008;118:501–5.

Acta Oto-Laryngologica, 2009; 129: 9–14

informa
healthcare

ORIGINAL ARTICLE

Clinical significance of endolymphatic imaging after intratympanic gadolinium injection

TSUTOMU NAKASHIMA[1], SHINJI NAGANAWA[2], NAOMI KATAYAMA[1], MASAAKI TERANISHI[1], SEIICHI NAKATA[1], MAKOTO SUGIURA[1], MICHIHIKO SONE[1], SACHIO KASAI[1], MAYUMI YOSHIOKA[1] & MASAKO YAMAMOTO[1]

[1]*Department of Otorhinolaryngology and* [2]*Department of Radiology, Nagoya University, Nagoya, Japan*

Abstract

Conclusion: Using three-dimensional real inversion recovery (3D-real IR) and three-dimensional fluid-attenuated inversion recovery (3D-FLAIR) magnetic resonance imaging (MRI), various degrees of endolymphatic hydrops were observed in the basal and upper turns of the cochlea and in the vestibular apparatus after intratympanic gadolinium (Gd) injection. MRI may contribute to our understanding of inner ear diseases and may be a useful addition to intratympanic drug therapy in the management of inner ear diseases. *Objective:* To evaluate 3D-real IR MRI and 3D-FLAIR MRI with clinical symptoms and signs in patients with inner ear disease. *Patients and methods:* Gd was diluted in saline and injected intratympanically in 73 patients with inner ear disease. The endolymphatic space was evaluated with 3-Tesla MRI at 1 day after the intratympanic Gd injection. *Results:* 3D-real IR MRI was generally better than 3D-FLAIR MRI in discriminating between the perilymphatic space and endolymphatic space in the cochlear turns and in the vestibular apparatus. However, when Gd concentration was insufficient in the perilymph, it was more difficult to visualize the Gd with 3D-real IR MRI than with 3D-FLAIR MRI. Endolymphatic hydrops was observed using MRI in patients with 'probable' Ménière's disease based on the criteria.

Keywords: *Membranous labyrinth, magnetic resonance imaging, MRI, endolymphatic space, perilymphatic space*

Introduction

Endolymphatic hydrops can be visualized using three-dimensional fluid-attenuated inversion recovery (3D-FLAIR) magnetic resonance imaging (MRI) after gadolinium (Gd), diluted eightfold with saline, is injected in patients with inner ear disease [1,2]. Gd enters the perilymphatic space through the round window membrane and can then delineate the perilymphatic and endolymphatic spaces.

This clinical endolymphatic imaging has two purposes. One is to investigate the relationship between clinical symptoms and endolymphatic hydrops. According to the criteria of the 1995 American Academy of Otolaryngology–Head and Neck Surgery (AAOHNS) guidelines [3], histopathological confirmation is necessary to diagnose 'certain' Ménière's disease in addition to 'definite' Ménière's disease. In addition, the diagnosis can be made when endolymphatic hydrops is observed with MRI in patients with 'probable' or 'possible' Ménière's disease. Thus, visualization of endolymphatic hydrops may be vital for making a new diagnosis of Ménière's disease. Investigation of the relationship between the endolymphatic image and functional tests such as electrocochleography and vestibular-evoked myogenic potential may deepen our understanding of inner ear diseases [1].

Another purpose of this clinical imaging is to investigate the permeability of the round window membrane and to observe drug distribution inside the inner ear. Intratympanic gentamicin administration is now used widely in the treatment of intractable Ménière's disease [4–6], and intratympanic steroid

---

Correspondence: Tsutomu Nakashima, Department of Otorhinolaryngology, Nagoya University School of Medicine, 65, Tsurumai-cho, Showa-ku, Nagoya 466-8550, Japan. Tel: +81 52 744 2320. Fax: +81 52 744 2325. E-mail: tsutomun@med.nagoya-u.ac.jp

(Received 5 December 2008; accepted 7 January 2009)

ISSN 0001-6489 print/ISSN 1651-2251 online
DOI: 10.1080/00016480902729801

administration is used to treat sudden sensory hearing loss [7–10]. The number of papers on intratympanic drug therapy for the treatment of inner ear diseases is increasing. Intratympanic drug administration therapy depends on the permeability of the round window membrane. However, the permeability of the round window membrane is diminished in some patients [11,12]. Confirming that an intratympanically applied drug actually reaches the inner ear and investigating its distribution inside the inner ear are important when using intratympanic drug therapy to treat inner ear diseases.

MRI of the endolymphatic and perilymphatic spaces following intratympanic Gd injection may play an essential role in the management of inner ear diseases. However, the toxicity of Gd to the inner ear must be considered. Kakigi et al. [13] reported no remarkable effects on the stria vascularis after Gd diluted eightfold with saline was injected into the tympanic cavity of guinea pigs, although a higher concentration had adverse effects. In the present study, we used Gd diluted 16-fold with saline and compared the MRI with that obtained with Gd diluted 8-fold.

We recently developed three-dimensional real inversion recovery (3D-real IR) MRI to discriminate between the perilymphatic space and endolymphatic space, and between the endolymphatic space and the surrounding bone [14]. Improvements in software and hardware used in MRI may help to reduce the amount of injected Gd and improve the quality of the images. In the present study, we compared the results of 3D-FLAIR MRI and 3D-real IR MRI applied using the 8-fold and 16-fold Gd dilutions.

Patients and methods

The subjects for this investigation included 73 patients with inner ear disease. They had idiopathic sudden sensorineural hearing loss, Ménière's disease, delayed endolymphatic hydrops, fluctuating hearing loss without vertigo, or acute hearing deterioration with large vestibular aqueduct syndrome. Most of the patients were candidates for intratympanic steroid therapy or intratympanic gentamicin therapy. Using a 3-Tesla MRI unit, 3D-FLAIR, T1, and CISS (heavily T2) MRI was applied in all patients. 3D-real IR MRI was also used in 60 patients. The method of MRI was described previously [1,2,14].

Gadodiamide hydrate (Gd-DTPA-BMA: Omniscan®) or gadopentetate dimeglumine (Gd-DTPA: Magnevist®) diluted with saline was injected intratympanically. Fifty-four patients received gadodiamide hydrate and 19 patients received gadopentetate dimeglumine. In each drug group, the Gd was diluted 16-fold with saline in three patients. In the other patients, the drug was diluted eightfold with saline.

The method of intratympanic injection was the same as described previously [1]. To make the solution for the intratympanic injection, we opened a 5 ml or 10 ml commercially available Gd syringe used for intravenous injection. Because the chelator surrounding the free Gd is apt to separate after the syringe is opened, we opened the syringe immediately before it was used for the intratympanic injection.

The protocol of the study was approved by the Ethics Review Committee of Nagoya University School of Medicine (approval numbers 369, 369-2, 369-3, and 369-4). All patients gave their informed consent to participation in this study. Their written informed consent was attached to the electronic medical record after permission was given by each patient.

Results

Enhancement was fainter with the 16-fold dilution than with the 8-fold dilution, although the degree of endolymphatic hydrops could be evaluated with the 16-fold dilution. This tendency was observed with both gadodiamide hydrate and gadopentetate dimeglumine. We used the eightfold dilution in the other patients.

3D-real IR MRI was generally better than 3D-FLAIR MRI for visualizing the endolymphatic space because the 3D-real IR MRI could discriminate the perilymphatic space from the surrounding bone. However, when the Gd concentration was not sufficient in the perilymph, it was more difficult to visualize the Gd using 3D-real IR MRI than using 3D-FLAIR MRI. Example results of 3D-FLAIR MRI and 3D-real IR MRI are shown in Figure 1a and b. The degree of endolymphatic hydrops could be evaluated more accurately using both 3D-real IR and 3D-FLAIR MRI. Figures 2 and 3 reveal different degrees of endolymphatic hydrops in various parts of the inner ear.

In patients with severe endolymphatic hydrops and almost no perilymphatic space recognized in the vestibule, the Gd movement toward the semicircular canals was disturbed (Figure 4). This disturbance occurred because Gd passage was restricted through the perilymphatic space. The

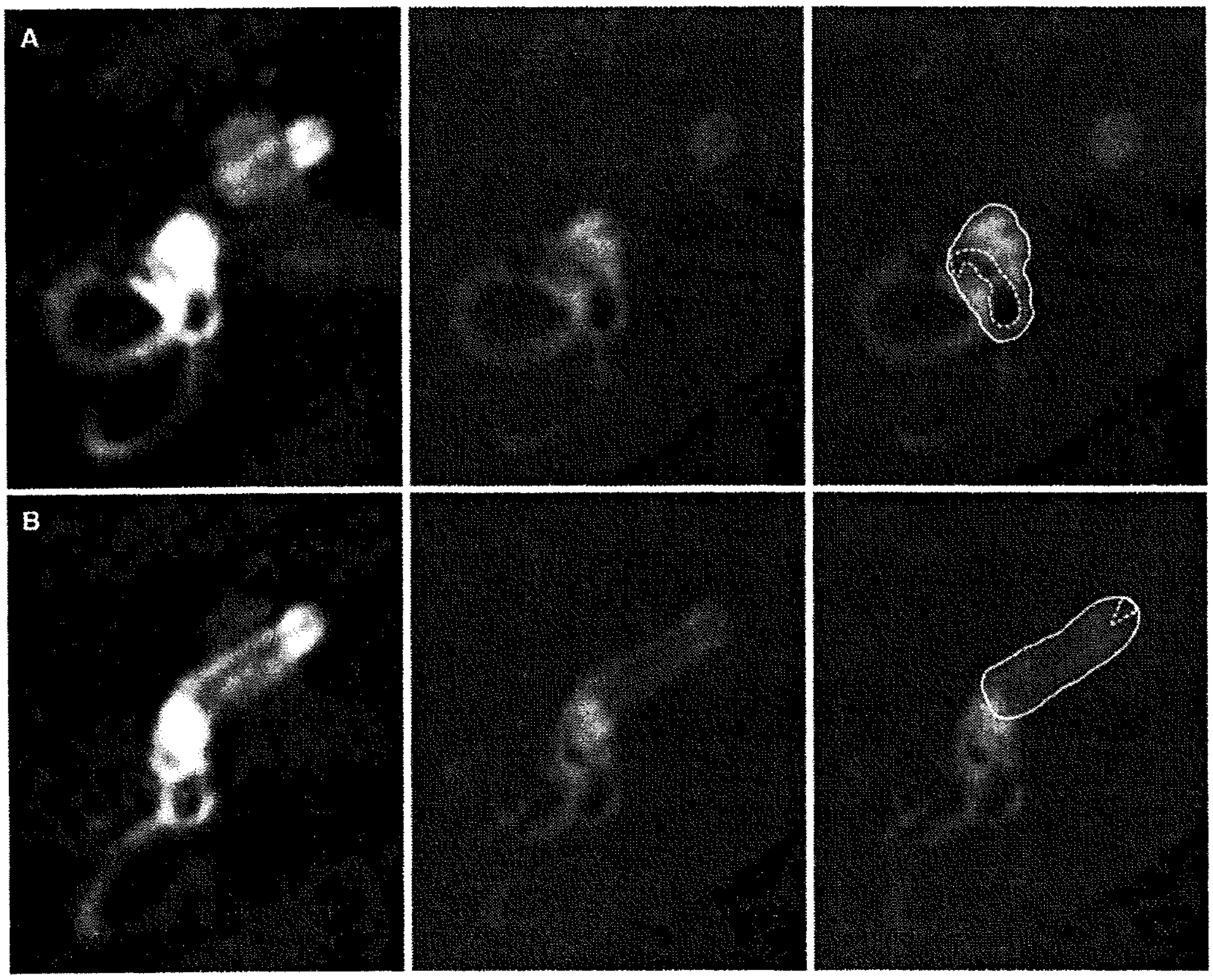

Figure 1. Images in (A) and (B) are consecutive sections of MRI in a 57-year-old woman who had right sudden deafness. 3D-FLAIR MRI (left side), 3D-real IR MRI (center), and the line drawings (right side) are shown. The 3D-real IR MRI is fainter than the 3D-FLAIR MRI. In 3D-real IR MRI, Gd is observed only in the basal turn in the cochlea. In the line drawings in (A), the area ratio of endolymphatic space (dotted circle) to total fluid space (solid line) in the vestibule is 25.2% (no vestibular hydrops). In (B), endolymphatic space is barely visible in the basal turn of the cochlea (dotted line).

effect of intratympanic gentamicin therapy was poor in two patients who showed this restricted passage toward the semicircular canal and who had received intratympanic gentamicin therapy.

Significant endolymphatic hydrops was observed in two patients with 'probable' Ménière's disease according to the 1995 AAOHNS criteria. An example is shown in Figure 5. This patient had frequent

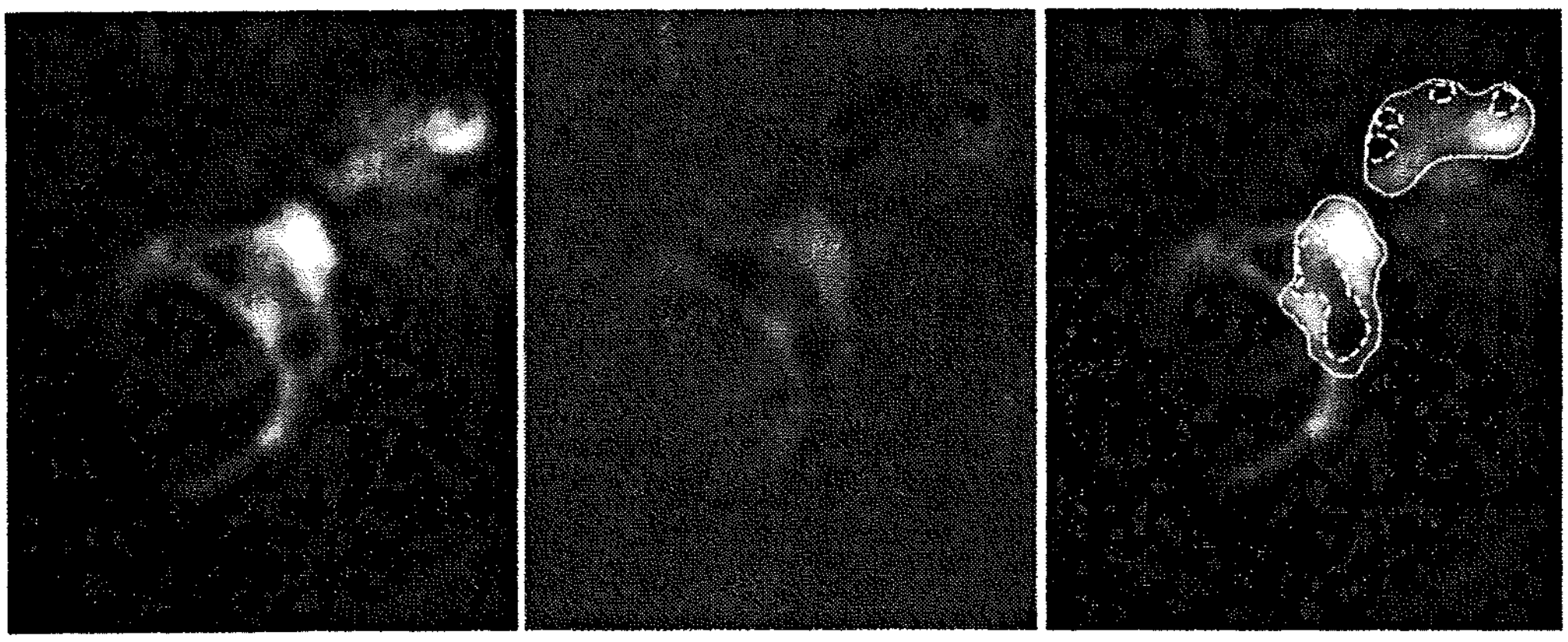

Figure 2. MRI in a 45-year-old man with right Ménière's disease. 3D-FLAIR MRI (left side), 3D-real IR MRI (center), and line drawing of the endolymphatic hydrops (right side). In the vestibule, the area ratio of endolymphatic space (dotted circle) to total fluid space (solid line) is 35.4% (mild vestibular hydrops). In the cochlea, endolymphatic hydrops is observed but the size is smaller than the size of the scala vestibuli (mild cochlear hydrops).