

Impact of Energy Loss Coefficient on Left Ventricular Mass Regression in Patients Undergoing Aortic Valve Replacement: Preliminary Observation

Teruyoshi Kume, MD, Hiroyuki Okura, MD, Takahiro Kawamoto, MD, Nozomi Watanabe, MD, Yoji Neishi, MD, Akihiro Hayashida, MD, Kazuo Tanemoto, MD, and Kiyoshi Yoshida, MD, *Kurashiki, Japan*

Background: The purpose of this study was to evaluate the impact of Doppler-derived energy loss coefficient (ELCo) on the regression of left ventricular (LV) hypertrophy after aortic valve replacement (AVR) in patients with severe aortic stenosis.

Methods: Twenty-four patients with severe aortic stenosis who underwent AVR with Carpentier-Edwards pericardial bioprosthetic valves (valve size 19 mm, n = 16; valve size 21 mm, n = 8) were examined. Within 12 months after AVR, follow-up echocardiography and Doppler measurements were performed. The effect of AVR was quantified on the basis of absolute and relative LV mass regression.

Results: There were significant correlations between indexed ELCo and absolute ($r = 0.50$, $P = .013$) and relative ($r = 0.48$, $P = .018$) LV mass regression. The mean value of relative LV mass regression was 25%, and a cutoff value of $0.9 \text{ cm}^2/\text{m}^2$ for indexed ELCo could detect patients with relative LV mass regression > 25% after AVR with sensitivity of 71% and specificity of 100%.

Conclusions: ELCo, which can be calculated noninvasively from echocardiography, might be an important value to relate to LV mass regression in patients after AVR. (*J Am Soc Echocardiogr* 2009;22:454-457.)

Keywords: Echocardiography, Valvular diseases, Myocardium

Aortic valve replacement (AVR) improves prognosis, accompanied by a regression in left ventricular (LV) hypertrophy, in most patients with aortic stenosis (AS).¹ However, some patients with AS experience a hindrance to or delay of the regression of LV hypertrophy after AVR.^{2,3} Prosthesis-patient mismatch (PPM) is a more frequent problem than originally believed, and it occurs when the effective orifice area (EOA) of the prosthesis being implanted is less than that of the normal human valve.^{4,5} It has been reported that indexed EOA (ie, the EOA of the prosthesis divided by the patient's body surface area) < $0.85 \text{ cm}^2/\text{m}^2$ is generally regarded as the threshold for PPM, and PPM is thought to be a strong and independent predictor not only of LV mass regression but also of cardiac events and short-term and midterm mortality among patients undergoing AVR.⁶⁻¹²

Recently, it was reported that discrepancies between EOA obtained using the Gorlin formula during cardiac catheterization (EOA_{cath}) and EOA obtained using the continuity equation during Doppler echocardiography (EOA_{Dop}) of up to 20% might be observed depending on the pressure recovery phenomenon in the

ascending aorta in patients with AS.^{13,14} The concept of the pressure recovery phenomenon is based on fluid mechanics theory: the increase of static pressure downstream of the stenosis due to the reconversion of kinetic energy into potential energy.¹⁵ Doppler-derived energy loss coefficient (ELCo), which can take into account pressure recovery phenomenon and reconcile discrepancies between EOA_{cath} and EOA_{Dop} , is proposed as an equivalent index representing EOA_{cath} .^{13,14,16}

However, no clinical study has yet to clarify the impact of ELCo on the regression of LV hypertrophy after AVR in patients with AS. Therefore, the purpose of our study was to evaluate the impact of ELCo on the regression of LV hypertrophy after AVR in patients with severe AS.

METHODS

Patients

Twenty-four patients with severe AS (mean age, 73 ± 9 years; 19 women, 5 men) who underwent AVR with Carpentier-Edwards pericardial bioprosthetic valves (valve size 19 mm, n = 16; valve size 21 mm, n = 8; Edwards Lifesciences, Inc., Orange, CA) were retrospectively examined. All patients were in sinus rhythm. Written informed consent was obtained from each patient and family. The existence of hypertension, hyperlipidemia, and diabetes mellitus was determined using the following criteria. Hypertension was defined as blood pressure > 140/90 mmHg or current medication use. Hyperlipidemia was defined as total cholesterol level > 220 mg/dL or triglyceride level > 150 mg/dL or current medication use. Diabetes mellitus was defined

From the Department of Cardiology (T. Kume, H.O., T. Kawamoto, N.W., Y.N., A.H., K.Y.) and the Division of Thoracic and Cardiovascular Surgery, Department of Surgery (K.T.), Kawasaki Medical School, Kurashiki, Japan.

Reprint requests: Hiroyuki Okura, MD, Kawasaki Medical School, Department of Cardiology, 577 Matsushima, Kurashiki, Okayama, 701-0192, Japan (E-mail: hokura@fides.dti.ne.jp).

0894-7317/\$36.00

Copyright 2009 by the American Society of Echocardiography.

doi:10.1016/j.echo.2009.02.018

Table 1 Patient characteristics

Variable	Value
Age (y)	73 ± 9
Women	19 (79%)
Body surface area (m ²)	1.49 ± 0.18
Hypertension	11 (46%)
Diabetes mellitus	6 (25%)
Hyperlipidemia	7 (29%)
Smoking	3 (13%)
Dialysis	3 (13%)
Symptoms (dyspnea, angina pectoris, syncope)	
Preoperative	22 (92%)
Postoperative	4 (17%)

Data are expressed as mean ± SD or as number (percentage).

as fasting plasma glucose level > 120 mg/dL, plasma glucose level (at any time) > 200 mg/dL, or current medication use. Previously, we reported the preoperative clinical impact of ELCo in 33 patients with severe AS.¹⁶ Thirteen of the 33 patients (39%) in that study were included in the current study. We excluded patients with atrial fibrillation, moderate to severe other valvular heart disease, and systolic LV dysfunction before or after AVR (LV ejection fraction < 40%).

Echocardiography

Echocardiographic examinations were performed before and after AVR. All echocardiographic procedures were conducted using a standard approach. We evaluated echocardiographic parameters such as LV dimension, LV wall thickness, LV ejection fraction, and LV mass. LV dimension and LV wall thickness were measured using the 2-dimensional method, and LV ejection fraction was evaluated using the apical biplane method of discs (modified Simpson's rule).¹⁷ LV mass was calculated using the method of Devereux et al.¹⁸ The effect of AVR was quantified on the basis of the absolute and relative LV mass regression as follows: absolute LV mass regression (grams) = postoperative LV mass – preoperative LV mass, and relative LV mass regression (percentage) = (postoperative LV mass – preoperative LV mass)/preoperative LV mass.¹⁹ The transvalvular gradients were measured using a continuous-wave Doppler technique. In addition, the aortic diameters were measured at the level of the sinotubular junction.¹¹ To correct the EOA for pressure recovery phenomenon, the ELCo equation was used, as previously reported^{13,14,20}: $ELCo = (EOA_{Dop} \times \text{aortic cross-sectional area}) / (\text{aortic cross-sectional area} - EOA_{Dop})$.

EOA_{Dop} for the Carpentier-Edwards pericardial valve was derived from previously published, normal, in vivo EOA values (valve size 19 mm, $EOA_{Dop} = 1.10 \text{ cm}^2$; valve size 21 mm, $EOA_{Dop} = 1.30 \text{ cm}^2$).^{7,10,19,20}

Statistical Methods

To compare the preoperative and postoperative echocardiographic findings, paired *t* tests were used for continuous variables. Comparison of medications between patients with relative LV mass regression > 25% and those with regression ≤ 25% after AVR was performed using Fisher's exact test. Data are expressed as mean ± SD. A *P* value < .05 was considered significant. Using receiver-operating characteristic curves (ie, plots of sensitivity vs 1 minus specificity), we defined the best cutoff value of indexed ELCo for detecting patients with better relative LV mass regression after AVR.

Table 2 Preoperative and postoperative LV mass and function

Variable	Preoperative	Postoperative	<i>P</i> value
Peak aortic gradient (mm Hg)	80 ± 25	27 ± 11	<.001
LV diastolic dimension (mm)	45 ± 7	41 ± 7	.065
LV systolic dimension (mm)	29 ± 10	27 ± 8	.550
LV ejection fraction (%)	60 ± 16	65 ± 10	.148
LV mass (g)	299 ± 98	221 ± 94	.008
LV mass index (g/m ²)	205 ± 79	150 ± 66	.011
Absolute LV mass regression (g)		–55 ± 50	
Relative LV mass regression (%)		–25 ± 21	

Data are expressed as mean ± SD.

RESULTS

The mean age of the patients was 73 years, and 19 of 24 patients (79%) were women (Table 1). The mean interval from AVR to the echocardiographic study was 5.4 ± 3.9 months. No significant differences were observed between preoperative and postoperative diameters or LV systolic functional parameters, but LV mass and mass index decreased significantly during the follow-up period (Table 2). There were no significant correlations between peak aortic gradient after AVR and absolute ($R = 0.025$, $P = .908$) or relative ($R = 0.169$, $P = .429$) LV mass regression. Furthermore, there were no significant correlations between indexed EOA and absolute or relative LV mass regression (Figure 1). On the other hand, there were significant correlations between indexed ELCo and absolute and relative LV mass regression (Figure 2). The mean value of relative LV mass regression was 25%, and a cutoff value of 0.9 cm²/m² for indexed ELCo could detect patients who had relative LV mass regression > 25% after AVR with sensitivity of 71% and specificity of 100%. Table 3 shows the patients' medications. There were no significant differences in the medications between patients with relative LV mass regression > 25% and those with regression ≤ 25% after AVR (angiotensin-converting enzyme inhibitors, $P = .330$; angiotensin I receptor antagonists, $P = .506$; calcium channel blockers, $P = .332$; α-blockers, $P = .417$; β-blockers, $P = .583$; statins, $P = .357$).

DISCUSSION

In our study, there was a significant correlation between indexed ELCo, which can take into account the pressure recovery phenomenon, and LV mass regression after AVR. To the best of our knowledge, this is the first report to elucidate the significant relationship between ELCo and LV mass regression after AVR.

Doppler echocardiographic examinations are now frequently used as part of follow-up procedures for patients with prosthetic heart valves.²¹ It has been reported that a high residual pressure gradient across the prosthetic valve might cause a delay of the regression of LV hypertrophy after AVR.^{2,3} However, the prosthetic valve gradient does not take the pressure recovery phenomenon into account. Therefore, the peak aortic gradient might not have been related to the degree of LV mass regression after AVR in our study.

Del Rizzo et al²² reported a strong relation between indexed EOA after AVR and the extent of LV mass regression. However, there was no statistically significant relationship between indexed EOA after AVR and the extent of LV mass regression in our study. Such a discrepancy might be based on the pressure recovery phenomenon. The concept of the pressure recovery phenomenon is based on fluid mechanics theory, and EOA_{Dop} does not take the pressure recovery phenomenon

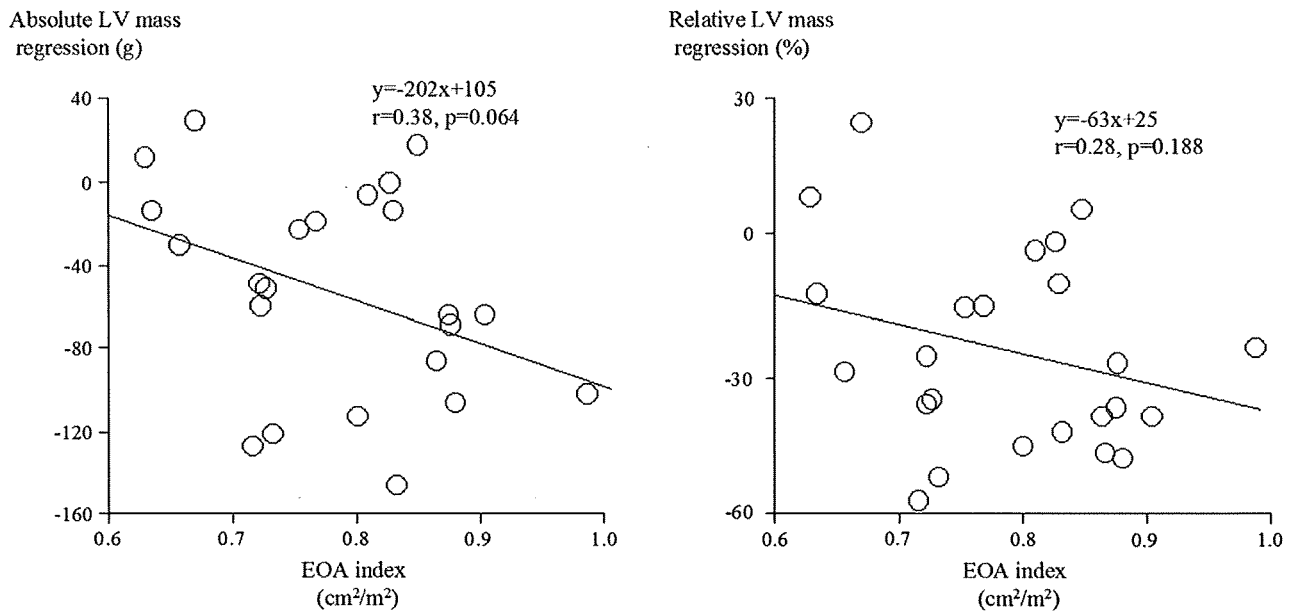


Figure 1 Comparison between indexed EOA and absolute and relative LV mass regression. There were no significant correlations between indexed EOA and absolute and relative LV mass regression.

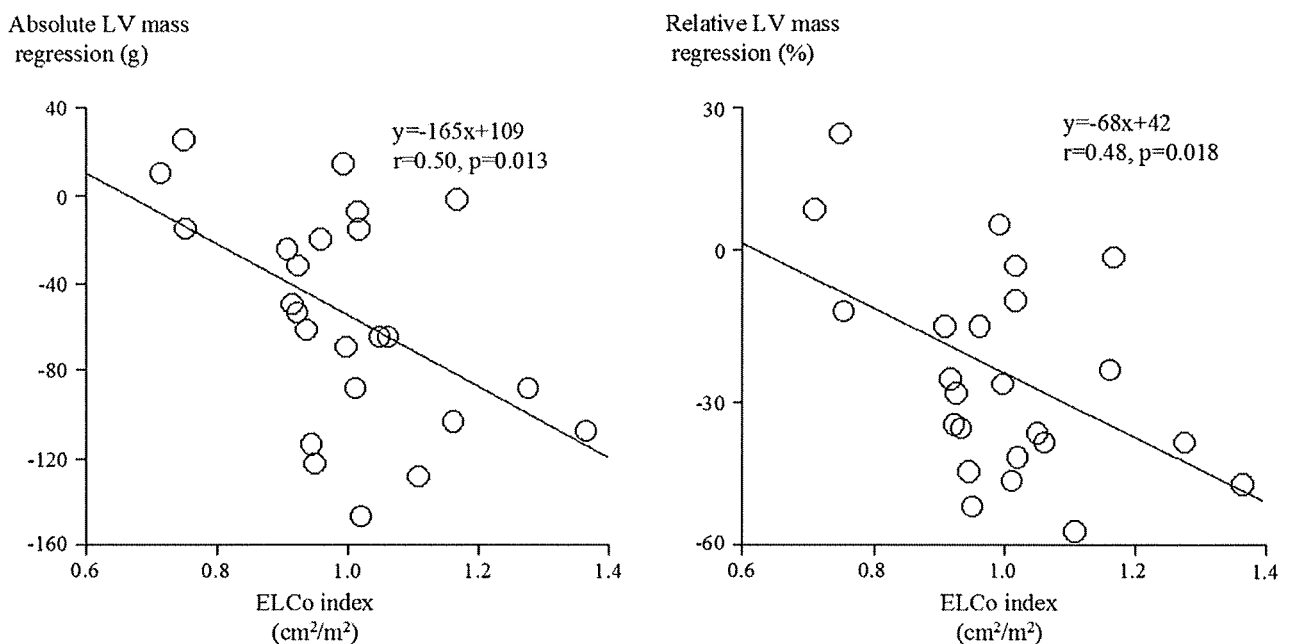


Figure 2 Comparison between indexed ELCo and absolute and relative LV mass regression. There were significant correlations between indexed ELCo and absolute and relative LV mass regression.

into account. Therefore, measurements made from EOA_{Dop} resulted in overestimations of the severity of AS compared with ELCo.¹⁶ In addition, the pressure recovery in the ascending aorta was different between prosthetic valve types,²³ and we evaluated ELCo only in patients who received AVR with Carpentier-Edwards pericardial bioprosthetic valves. Therefore, a more significant relationship might be demonstrated between indexed ELCo and LV mass regression after AVR compared with indexed EOA and LV mass regression after AVR. In combination with our data, we speculate that ELCo might be a better reflection of the pressure load on the left ventricle than EOA and a useful measure for predicting LV mass regression after AVR.

PPM is a more frequent problem than originally believed, and PPM is thought to be a strong and independent predictor of cardiac events and short-term and midterm mortality among patients undergoing AVR.⁶⁻¹² On the other hand, similar functional recovery was demonstrated in patients along the full spectrum of valve sizes indexed to body size, even for values considered to represent severe PPM and factors other than prosthesis and patient sizes might influence the functional quality of life after AVR.²⁴ Such a discrepancy among investigations with regard to PPM and outcomes after AVR may be related to the variable definition of PPM without taking into account the pressure recovery phenomenon. Considering these

Table 3 Patient medications after AVR

Medication	n (%)
Angiotensin-converting enzyme inhibitors	2 (8%)
Angiotensin I receptor antagonists	6 (25%)
Calcium channel blockers	5 (21%)
α -blockers	1 (4%)
β -blockers	1 (4%)
Statin	7 (29%)

results and our data, indexed ELCo might be an important value to relate to not only LV mass regression but also the prognoses of patients after AVR.

Limitations

Kadem et al²⁵ determined the effect of systemic arterial hypertension, induced by banding of the distal thoracic aorta in 14 pigs, on indices of AS severity, including ELCo. They reported that the changes in systemic arterial hemodynamic properties that are associated with systemic hypertension could cause an increase in ELCo. Therefore, hypotension associated with LV dysfunction before or after AVR could affect the ELCo value.

ELCo does not take into account the possible impact of valvular or paravalvular regurgitation. Therefore, the exact evaluation of ELCo after AVR with significant aortic regurgitation could not be performed.

Our study was a retrospective investigation. Therefore, the variation in the interval between AVR and the estimation of ELCo among the patients studied could have influenced the results. Furthermore, 19 of 24 patients were women with low body surface area values. Sixteen patients received valves 19 mm in size, and the remainder received valves 21 mm in size, which is a limited valve size, not common in a "normal" valve patient population. If more patients with larger valve sizes and higher body surface areas were added, a more significant association between ELCo index and LV mass regression might be obtained.

CONCLUSIONS

ELCo might be an important value to relate to LV mass regression in patients after AVR. ELCo can be calculated noninvasively from echocardiography and predicted before AVR. Large prospective studies are needed to clarify the clinical impact of ELCo in patients after AVR.

REFERENCES

1. Monrad ES, Hess OM, Murakami T, Nonogi H, Corin WJ, Krayenbuehl HP. Time course of regression of left ventricular hypertrophy after aortic valve replacement. *Circulation* 1988;77:1345-55.
2. Krayenbuehl HP, Hess OM, Monrad ES, Schneider J, Mall G, Turina M. Left ventricular myocardial structure in aortic valve disease before, intermediate, and late after aortic valve replacement. *Circulation* 1989;79:744-55.
3. Jin XY, Zhang ZM, Gibson DG, Yacoub MH, Pepper JR. Effects of valve substitute on changes in left ventricular function and hypertrophy after aortic valve replacement. *Ann Thorac Surg* 1996;62:683-90.
4. Rahimtoola SH. The problem of valve prosthesis-patient mismatch. *Circulation* 1978;58:20-4.
5. Rahimtoola SH, Murphy E. Valve prosthesis-patient mismatch. A long-term sequela. *Br Heart J* 1981;45:331-5.
6. Tasca G, Mhagna Z, Perotti S, Centurini PB, Sabatini T, Amaducci A, et al. Impact of prosthesis-patient mismatch on cardiac events and midterm

- mortality after aortic valve replacement in patients with pure aortic stenosis. *Circulation* 2006;113:570-6.
7. Blais C, Dumesnil JG, Baillet R, Simard S, Doyle D, Pibarot P. Impact of valve prosthesis-patient mismatch on short-term mortality after aortic valve replacement. *Circulation* 2003;108:983-8.
8. Dumesnil JG, Honos GN, Lemieux M, Beauchemin J. Validation and applications of indexed aortic prosthetic valve areas calculated by Doppler echocardiography. *J Am Coll Cardiol* 1990;16:637-43.
9. Dumesnil JG, Yoganathan AP. Valve prosthesis hemodynamics and the problem of high transprosthetic pressure gradients. *Eur J Cardiothorac Surg* 1992;(suppl):S34-78.
10. Pibarot P, Dumesnil JG. Hemodynamic and clinical impact of prosthesis-patient mismatch in the aortic valve position and its prevention. *J Am Coll Cardiol* 2000;36:1131-41.
11. Pibarot P, Honos GN, Durand LG, Dumesnil JG. The effect of prosthesis-patient mismatch on aortic bioprosthetic valve hemodynamic performance and patient clinical status. *Can J Cardiol* 1996;12:379-87.
12. Pibarot P, Dumesnil JG, Lemieux M, Cartier P, Metras J, Durand LG. Impact of prosthesis-patient mismatch on hemodynamic and symptomatic status, morbidity and mortality after aortic valve replacement with a bioprosthetic heart valve. *J Heart Valve Dis* 1998;7:211-8.
13. Razzolini R, Manica A, Tarantini G, Ramondo A, Napodano M, Illiceto S. Discrepancies between catheter and Doppler estimates of aortic stenosis: the role of pressure recovery evaluated "in vivo". *J Heart Valve Dis* 2007;16:225-9.
14. Garcia D, Dumesnil JG, Durand LG, Kadem L, Pibarot P. Discrepancies between catheter and Doppler estimates of valve effective orifice area can be predicted from the pressure recovery phenomenon: practical implications with regard to quantification of aortic stenosis severity. *J Am Coll Cardiol* 2003;41:435-42.
15. Clark C. The fluid mechanics of aortic stenosis—I. Theory and steady flow experiments. *J Biomech* 1976;9:521-8.
16. Kume T, Okura H, Kawamoto T, Watanabe N, Hayashida A, Neishi Y, et al. Clinical implication of energy loss coefficient in patients with severe aortic stenosis diagnosed by Doppler echocardiography. *Circ J* 2008;72:1265-9.
17. Lang RM, Bierig M, Devereux RB, Flachskampf FA, Foster E, Pellikka PA, et al; Chamber Quantification Writing Group; American Society of Echocardiography's Guidelines and Standards Committee; European Association of Echocardiography. Recommendations for chamber quantification: a report from the American Society of Echocardiography's Guidelines and Standards Committee and the Chamber Quantification Writing Group, developed in conjunction with the European Association of Echocardiography, a branch of the European Society of Cardiology. *J Am Soc Echocardiogr* 2005;18:1440-63.
18. Devereux RB, Alonso DR, Lutas EM, Gottlieb GJ, Campo E, Sachs J, et al. Echocardiographic assessment of left ventricular hypertrophy: comparison to necropsy findings. *Am J Cardiol* 1986;57:450-8.
19. Kato Y, Suehiro S, Shibata T, Sasaki Y, Hirai H. Impact of valve prosthesis-patient mismatch on long-term survival and left ventricular mass regression after aortic valve replacement for aortic stenosis. *J Card Surg* 2007;22:314-9.
20. Garcia D, Pibarot P, Dumesnil JG, Sakr F, Durand LG. Assessment of aortic valve stenosis severity: a new index based on the energy loss concept. *Circulation* 2000;101:765-71.
21. Salomon NW, Okies JE, Krause AH, Page US, Bigelow JC, Colburn LQ. Serial follow-up of an experimental bovine pericardial aortic bioprosthesis: usefulness of pulsed Doppler echocardiography. *Circulation* 1991;84(suppl). II-17-23.
22. Del Rizzo DF, Abdoh A, Cartier PC, David TE, Doty DB, Westaby S. Factors affecting LV mass regression following AVR with stentless valves. *Semin Thorac Cardiovasc Surg* 1999;11(suppl). I-114-20.
23. Bech-Hanssen O, Caidahl K, Wallentin I, Ask P, Wranné B. Assessment of effective orifice area of prosthetic aortic valves with Doppler echocardiography: an in vivo and in vitro study. *J Thorac Cardiovasc Surg* 2001;122:287-95.
24. Koch CG, Khandwala F, Estafanous FG, Loop FD, Blackstone EH. Impact of prosthesis-patient size on functional recovery after aortic valve replacement. *Circulation* 2005;111:3221-9.
25. Kadem L, Dumesnil JG, Rieu R, Durand LG, Garcia D, Pibarot P. Impact of systemic hypertension on the assessment of aortic stenosis. *Heart* 2005;91:354-61.

GUIDELINES AND STANDARDS

Recommendations for Evaluation of Prosthetic Valves With Echocardiography and Doppler Ultrasound

A Report From the American Society of Echocardiography's Guidelines and Standards Committee and the Task Force on Prosthetic Valves, Developed in Conjunction With the American College of Cardiology Cardiovascular Imaging Committee, Cardiac Imaging Committee of the American Heart Association, the European Association of Echocardiography, a registered branch of the European Society of Cardiology, the Japanese Society of Echocardiography and the Canadian Society of Echocardiography, Endorsed by the American College of Cardiology Foundation, American Heart Association, European Association of Echocardiography, a registered branch of the European Society of Cardiology, the Japanese Society of Echocardiography, and Canadian Society of Echocardiography

William A. Zoghbi, MD, FASE, Chair, John B. Chambers, MD,* Jean G. Dumesnil, MD,† Elyse Foster, MD,‡ John S. Gottdiener, MD, FASE, Paul A. Grayburn, MD, Bijoy K. Khandheria, MBBS, FASE, Robert A. Levine, MD, Gerald Ross Marx, MD, FASE, Fletcher A. Miller, Jr., MD, FASE, Satoshi Nakatani, MD, PhD,§ Miguel A. Quiñones, MD, Harry Rakowski, MD, FASE, L. Leonardo Rodriguez, MD, Madhav Swaminathan, MD, FASE, Alan D. Waggoner, MHS, RDCS, Neil J. Weissman, MD, FASE,|| and Miguel Zabalgoitia, MD, *Houston and Dallas, Texas; London, United Kingdom; Quebec City, Quebec, Canada; San Francisco, California; Baltimore, Maryland; Scottsdale, Arizona; Boston, Massachusetts; Rochester, Minnesota; Suita, Japan; Toronto, Ontario, Canada; Cleveland, Ohio; Durham, North Carolina; St Louis, Missouri; Washington, DC; Springfield, Illinois*

From the Methodist DeBakey Heart and Vascular Center, Houston, Texas (W.A.Z., M.A.Q.); St Thomas Hospital, London, United Kingdom (J.B.C.); Hospital Laval, Quebec City, Quebec, Canada (J.G.D.); the University of California, San Francisco, San Francisco, California (E.F.); the University of Maryland Hospital, Baltimore, Maryland (J.S.G.); Baylor University Medical Center, Dallas, Texas (P.A.G.); Mayo Clinic, Scottsdale, Arizona (B.K.K.); Massachusetts General Hospital, Boston, Massachusetts (R.A.L.); Harvard School of Medicine/Boston Children's Hospital, Boston, Massachusetts (G.R.M.); the Mayo Clinic, Rochester, Minnesota (F.A.M.); Osaka University Graduate School of Medicine, Suita, Japan (S.N.); Toronto General Hospital, Toronto, Ontario, Canada (H.R.); the Cleveland Clinic, Cleveland, Ohio (L.L.R.); Duke University Medical Center, Durham, North Carolina (M.S.); Washington University School of Medicine, St Louis, Missouri (A.D.W.); Washington Hospital Center, Washington, DC (N.J.W.); and Prairie Cardiovascular Consultants, Springfield, Illinois (M.Z.).

Reprint requests: American Society of Echocardiography, 2100 Gateway Centre Boulevard, Suite 310, Morrisville, NC 27560 (E-mail: ase@asecho.org).

* Representing the European Association of Echocardiography. † Representing the Canadian Society of Echocardiography. ‡ Representing the Cardiac Imaging Committee of the American Heart Association. § Representing the Japanese Society of Echocardiography. || Representing the American College of Cardiology Cardiovascular Imaging Committee.

0894-7317/\$36.00

Copyright 2009 by the American Society of Echocardiography.

doi:10.1016/j.echo.2009.07.013

Accreditation Statement:

The American Society of Echocardiography is accredited by the Accreditation Council for Continuing Medical Education to provide continuing medical education for physicians.

The ASE designates this educational activity for a maximum of 1 AMA PRA Category 1 Credit™. Physicians should only claim credit commensurate with the extent of their participation in the activity.

The American Registry of Diagnostic Medical Sonographers and Cardiovascular Credentialing International recognize the ASE's certificates and have agreed to honor the credit hours toward their registry requirements for sonographers.

The ASE is committed to ensuring that its educational mission and all sponsored educational programs are not influenced by the special interests of any corporation or individual, and its mandate is to retain only those authors whose financial interests can be effectively resolved to maintain the goals and educational integrity of the activity. Although a monetary or professional affiliation with a corporation does not necessarily influence an author's presentation, the essential areas and policies of the ACCME require that any relationships that could possibly conflict with the educational value of an activity be resolved prior to publication and disclosed to the audience. Disclosures of faculty and commercial support relationships, if any, have been indicated.

Target Audience:

This activity is designed for all cardiovascular physicians and cardiac sonographers with a primary interest and knowledge base in the field of echocardiography. In addition, residents, researchers, clinicians, intensivists, and other medical professionals with specific interest in cardiac ultrasound will find this activity beneficial.

Objectives:

Upon completing this article, participants will be better able to:

1. Name the components of a complete imaging and Doppler evaluation for prosthetic valve function.
2. Identify the components of an integrative approach to assessing prosthetic aortic and mitral valve stenosis and regurgitation.
3. Identify the components of an integrative approach to assessing prosthetic pulmonary and tricuspid valve stenosis and regurgitation.
4. Describe the pitfalls and limitations of the evaluation of prosthetic valve function.
5. Recognize the special aspects of the pediatric population that add complexity to the evaluation of prosthetic valve function.

Author Disclosures:

Elyse Foster receives research and grant support from Evalve (Menlo Park, CA), Boston Scientific Corporation (Natick, MA), and Evidence Based Research, Inc (Vienna, VA). Paul A. Grayburn is the Associate Editor of the *American Journal of Cardiology* and receives research support from the National Institutes of Health (Bethesda, MD), Evalve (Menlo Park, CA), GE (Milwaukee, WI), and Amersham (Amersham, UK). Harry Rakowski chairs the Data Safety Monitoring Board for Medtronic, Inc (Minneapolis, MN). Neil J. Weissman receives research/grant support from ATS Medical, Inc (Minneapolis, MN), Sorin/Carbomedics (Milan, Italy), Edwards Lifesciences (Irvine, CA), St Jude Medical (St Paul, MN), MitralSolutions, Inc (Fort Lauderdale, FL), Arbor Surgical Technologies (Sunnyvale, CA), Evalve (Menlo Park, CA), Mitralign, Inc (Tewksbury, MA), Medispec (Germantown, MD), and Direct Flow Medical, Inc (Santa Rosa, CA).

William A. Zoghbi, John B. Chambers, Jean G. Dumesnil, John S. Gottdiener, Bijoy K. Khandheria, Robert A. Levine, Gerald Ross Marx, Fletcher A. Miller, Jr, Satoshi Nakatani, Miguel A. Quiñones, L. Leonardo Rodriguez, Madhav Swaminathan, Alan D. Waggoner, and Miguel Zabalgotia all reported that they have no actual or potential conflicts of interest in relation to this program.

Conflict of Interest:

This activity has been peer reviewed by a nonbiased member of the ASE ACCME/CME committee. No indication of an actual or potential bias in relation to the author disclosures was determined.

Estimated Time to Complete This Activity: 1 hour

TABLE OF CONTENTS

- I. Introduction 976
- II. General Considerations With Prosthetic Valves 977
 - A. Types of Prosthetic Valves 977
 - B. Evaluation of Prosthetic Valves With Echocardiography and Doppler: General Recommendations 977
 - 1. Clinical Data 978
 - 2. Echocardiographic Imaging 978
 - 3. Doppler Echocardiography 979
 - a. Determination of Gradients Across Prosthetic Valves 979
 - b. EOA 980
 - c. Pressure Recovery: Hemodynamic Conditions and Clinical Implications 980
 - d. PPM 981
 - e. Doppler Recordings and Measurements Based on Prosthetic Valve Position 981
 - f. Physiologic Regurgitation 982
 - g. Pathologic Prosthetic Regurgitation 982
 - C. Considerations for Intraoperative Patients 982
 - D. Complications of Prosthetic Valves 983
 - 1. General Considerations: Early Versus Late Complications 983
 - a. Early Complications 983
 - b. Late Complications 983
 - 2. Endocarditis 983
 - 3. Prosthetic Valve Thrombosis Versus Pannus 984
 - E. Stress Echocardiography in Evaluating Prosthetic Valve Function 984
 - 1. Prosthetic Aortic Valves 984
 - 2. Prosthetic Mitral Valves 985
 - F. Other Techniques for Assessing Replacement Heart Valves 986
 - 1. Cinefluoroscopy 986
 - 2. CT 986
 - 3. Cardiac Catheterization 986
 - G. Postoperative Evaluation and Follow-Up Studies 986
- III. Evaluation of Prosthetic Aortic Valves 986
 - A. Prosthetic Aortic Valve Function and Stenosis 986
 - 1. Imaging Considerations 986
 - 2. Doppler Parameters of Prosthetic Aortic Valve Function 986
 - a. Velocity and Gradients 986
 - b. EOA 987
 - c. DVI 987
 - 3. Diagnosis of Prosthetic Aortic Valve Stenosis 987
 - B. Prosthetic Aortic Valve Regurgitation 989
 - 1. Imaging Considerations 989
 - 2. Doppler Evaluation of Severity of Prosthetic AR 989
 - a. Color Doppler 989
 - b. Spectral Doppler 990
 - 3. Role of TEE in Prosthetic AR 991
- IV. Evaluation of Prosthetic Mitral Valves 991
 - A. Prosthetic Mitral Valve Function and Stenosis 991
 - 1. Imaging Considerations 991
 - a. Parasternal Views 991
 - b. Apical Views 992
 - 2. Doppler Parameters of Prosthetic Mitral Valve Function 992
 - a. Peak Early Mitral Velocity 992
 - b. Mean Gradient 993
 - c. Pressure Half-Time 993
 - d. EOA 994
 - e. DVI 995
 - 3. Diagnosis of Prosthetic Mitral Valve Stenosis 995
 - B. Prosthetic Mitral Valve Regurgitation 996
 - 1. Imaging Considerations 996
 - 2. Role of TEE 996
 - 3. Assessment of Severity of Prosthetic MR 996
- V. Evaluation of Prosthetic Pulmonary Valves 996
 - A. Prosthetic Pulmonary Valve Function 996
 - 1. Imaging Considerations 996
 - 2. Evaluation of Pulmonary Valve Function 998
 - B. Prosthetic Pulmonary Valve Regurgitation 998
- VI. Evaluation of Prosthetic Tricuspid Valves 998
 - A. Prosthetic Tricuspid Valve Function 998
 - 1. Imaging Considerations 998
 - 2. Doppler Parameters of Tricuspid Prosthetic Valve Function 999
 - 3. Diagnosis of Prosthetic Tricuspid Valve Stenosis 999
 - B. Prosthetic TR 1000
 - 1. Imaging Considerations 1000
 - 2. Doppler Parameters of Tricuspid Prosthetic Valve Regurgitation 1000
 - 3. TEE for Prosthetic Tricuspid Valves 1001
- VII. Echocardiographic Evaluation of Prosthetic Valves in the Pediatric Population 1002
 - A. Prosthetic Valves Are Uncommon in Pediatrics 1002
 - B. Aspects of Pediatric Congenital Heart Disease Alter the Standard Approach to Echocardiographic Prosthetic Valve Evaluation 1002
 - C. Importance of PPM in Pediatrics 1003
 - D. Potential Pitfalls in the Measurement of Prosthetic Valve EOA in Pediatrics 1004
 - E. Evaluation of Corresponding Atrial and Ventricular Size and Function 1004
 - F. The Need for More Research in the Pediatric Population 1004
- VIII. Conclusions and Future Directions 1004
- Appendix A: Normal Doppler Echocardiographic Values for Prosthetic Aortic Valves 1010
- Appendix B: Normal Doppler Echocardiographic Values for Prosthetic Mitral Valves 1013

I. INTRODUCTION

In patients with significant valvular stenosis or regurgitation, an intervention on the valve with repair, valvuloplasty, or valve replacement is ultimately inevitable. Although valve repair is now frequently performed, especially for mitral regurgitation (MR) and tricuspid regurgitation (TR), valve replacement remains common, particularly in adults. This enlarging cohort may be difficult to assess. Symptoms may be nonspecific, making it difficult to differentiate the effects of prosthetic valve dysfunction from ventricular dysfunction, pulmonary hypertension, the pathology of the remaining native valves, or noncardiac conditions. Although physical examination can alert clinicians to the presence of significant prosthetic valve dysfunction, diagnostic methods are often needed to assess the function of the prosthesis. Echocardiography with Doppler is the method of choice for the

noninvasive evaluation of prosthetic valve function. This document offers a review of echocardiographic and Doppler techniques used in the assessment of prosthetic valves and provides recommendations and general guidelines for the evaluation of prosthetic valve function on the basis of the scientific literature and the consensus of an international panel of experts. Issues of medical management and considerations for reoperation on valvular complications are beyond the scope of the current recommendations and have been recently addressed.¹

Echocardiography of prosthetic heart valves is more demanding, both to perform and to interpret, compared with the assessment of native valves. By their design, almost all replacement valves are obstructive compared with normal native valves. The degree of obstruction varies with the type and size of the valve. Thus, it may be difficult to differentiate obstructive hemodynamics due to valve design from those of mild obstruction observed with pathologic changes and from prosthesis-patient mismatch (PPM). Most mechanical valves and many biologic valves are associated with trivial or mild transprosthetic regurgitation. The pattern of this "physiologic" regurgitation varies with the design of the replacement valve. Last, because of shielding and artifacts, insonation of the valve and particularly of regurgitant jets associated with the valve may be difficult. A full transthoracic echocardiographic study requires multiple angulations of the probe and the use of off-axis views. On rare occasions, intermittent obstruction may be suspected, and prolonged Doppler examination may then be required for diagnosis. Transesophageal echocardiography (TEE) is more likely to be needed than for native valves for the evaluation of prosthetic valvular structure and associated complications, including regurgitation, especially in the mitral position.

II. GENERAL CONSIDERATIONS WITH PROSTHETIC VALVES

A. Types of Prosthetic Valves

Over the past 40 years, a large variety of prosthetic valves have been developed with the aim of improving hemodynamic function, increasing durability, and reducing complications. Nevertheless, there is no ideal valve, and all prosthetic valves are prone to dysfunction. The valve types now implanted include bileaflet and tilting disc mechanical valves, stented porcine and pericardial xenografts, stentless porcine xenografts, cadaveric homografts, and autografts (Ross procedure). Various types of currently used prosthetic valves in the aortic and mitral positions are listed in Appendices A and B. Figures 1 and 2 depict examples of mechanical and bioprosthetic valves and their echocardiographic images, respectively. In patients with aortic root disease, composite grafts may be required to replace the aortic valve and root, usually necessitating coronary reimplantation. Recently, successful percutaneous aortic and pulmonary valve replacements have been accomplished.

Prosthetic valves are broadly grouped as biologic or mechanical (Table 1).² The most frequently implanted biologic valve is a stented xenograft. These are composed of fabric-covered polymer or wire stents. The valve may be an entire porcine valve or a composite from 2 or 3 individual pigs. The cusps of stented pericardial xenografts are made from pericardium using a template and sewn inside or outside of the stent posts. Usually, the pericardium is bovine, but pericardium of other species has also been used. Xenografts also differ in the method of preservation of the valve cusps, the use of anticalcification regimens, and the composition and design of the stents and sewing rings.

Stentless xenograft valves usually consist of a preparation of porcine aorta. The aorta may be relatively long (Medtronic Freestyle; Medtronic, Inc, Minneapolis, MN) or may be sculpted to fit under the coronary arteries (St Jude Medical Toronto; St Jude Medical, St Paul Minnesota). Some are tricomposite (CryoLife O'Brien, CryoLife, Inc, Kennesaw, GA; BioCor, LLC, Yardley, PA) or made from bovine pericardium (Sorin Freedom; Sorin Group, Milan, Italy). Homograft valves consist of cryopreserved human aortic or, less commonly, pulmonary valves. Most are prepared in tissue banks, although a small number are produced by commercial companies (eg, CryoLife). Stentless valves were introduced to increase the effective orifice area (EOA). It was also hoped that stresses on the cusps might be lessened, leading to better durability and less thrombosis.

Currently, the most frequently implanted mechanical valves are the bileaflet valves. The various designs differ in the composition and purity of the pyrolytic carbon, the shape and opening angle of the leaflets, the design of the pivots, the size and shape of the housing, and the design of the sewing ring. Single tilting disc valves are also frequently used, whereas the Starr-Edwards caged-ball valve is rarely used nowadays but, because of its durability, will continue to be encountered.

Usually, the reported size of a prosthesis refers to the outer diameter of the valve ring, in millimeters. Comparison of the different valve types is difficult, however, because of major variations in sizing convention.^{3,4} This means that for a given patient's tissue annulus, there may be major differences in the labeled size. In a study comparing valve size as stated by the manufacturer against a modeled patient tissue annulus provided by machined polypropylene blocks, the patient "tissue annulus" diameter ranged from 3.5 mm smaller to 3.0 mm larger than the labeled size.⁴

The various valve types can differ also by their implantation position relative to the valve annulus. This is mainly in the aortic site. Valve implantation can be intra-annular, partially supra-annular, or wholly supra-annular. The supra-annular position is designed to lift as much of the replacement valve above the annulus to maximize the orifice area available for flow. The maximum label size implantable may then be limited by the diameter of the aortic root or the position of the coronary ostia.

Percutaneous valve implantation is an emerging technique whose feasibility has already been demonstrated.⁵⁻⁷ Clinical trials evaluating safety and durability are currently in progress. Percutaneous valves have been implanted in the pulmonary and aortic positions.⁵⁻⁷ The basic concept is of a tissue valve mounted on a balloon or self-expandable stent. Preliminary experience suggests that echocardiography will be a valuable tool for guiding the procedure and for the evaluation of gradients and residual aortic regurgitation (AR).⁸ Normal values for velocities and gradients are available in a small number of patients, but low gradients should be expected.^{7,8}

In select older high-risk patients, particularly those with prior coronary artery bypass grafting and severely calcific aortas in whom aortic cross-clamping would pose undue technical difficulty and risk, an aortic valve bypass (apicoaortic conduit) may be performed. This operation interposes a fabric conduit containing either a bioprosthetic or mechanical valve between the left ventricular (LV) apex and descending thoracic aorta.⁹ Postoperative evaluation focuses on evaluation of the apical cannula for absence of thrombus and adequate flow.

B. Evaluation of Prosthetic Valves With Echocardiography and Doppler: General Recommendations

A comprehensive evaluation is needed for the optimal assessment of prosthetic valve function. This includes obtaining pertinent clinical information in addition to echocardiography and Doppler evaluation. A

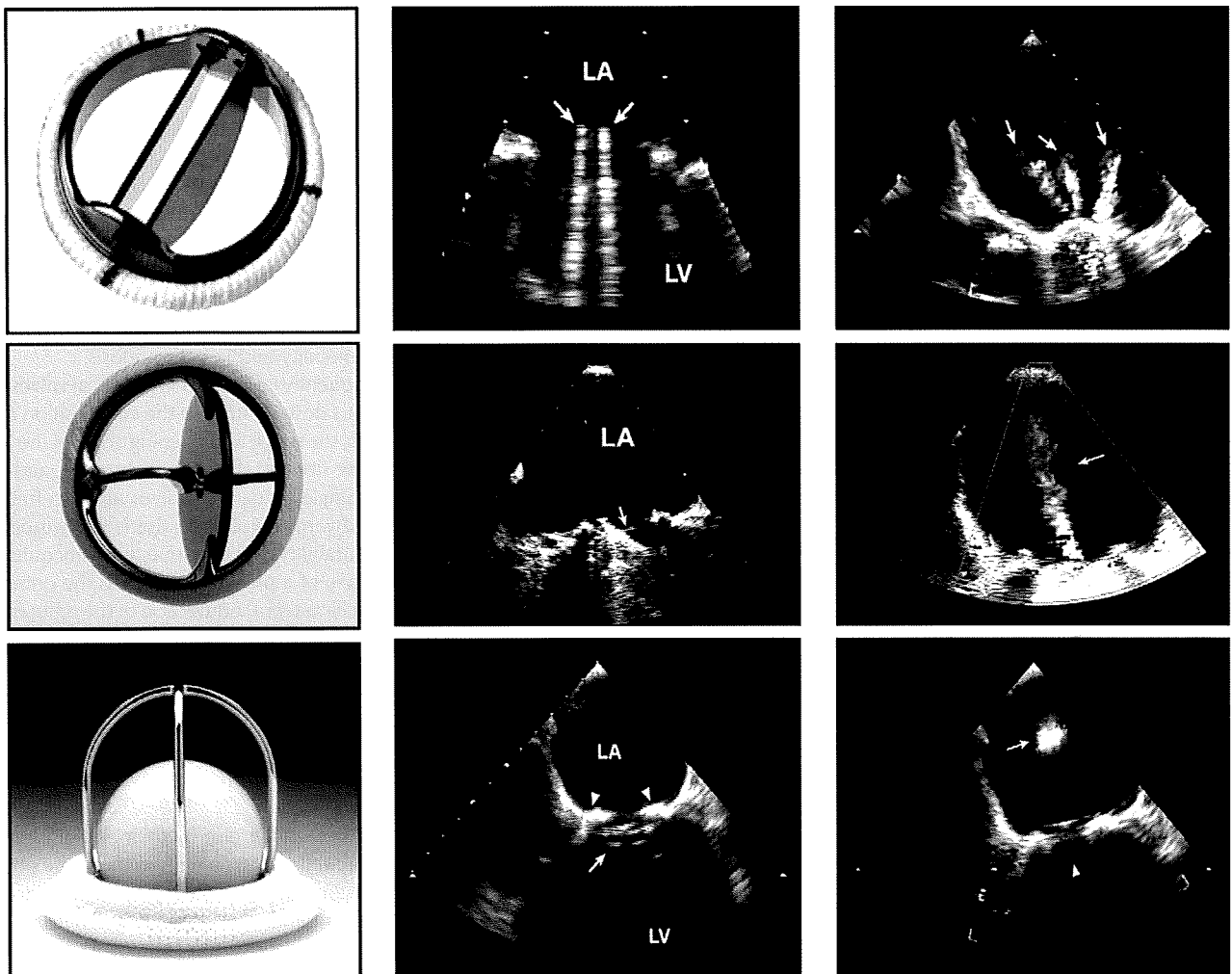


Figure 1 Examples of bileaflet, single-leaflet, and caged-ball mechanical valves and their transesophageal echocardiographic characteristics taken in the mitral position in diastole (*middle*) and in systole (*right*). The *arrows* in diastole point to the occluder mechanism of the valve and in systole to the characteristic physiologic regurgitation observed with each valve. Videos 1 to 6 show the motion and color flow patterns seen with these valves. [View video clips online.](#)

comparison with a baseline study or serial postoperative Doppler echocardiographic studies is often helpful, particularly when the function of the valve is in question (Table 2).

1. Clinical Data. The reason for the echocardiographic study and the patient's symptoms should be clearly documented. Furthermore, because Doppler findings and interpretation depend on the type and size of the replacement valve, this information and the date of surgery should be incorporated in the report when available, as this can be used in subsequent studies. Blood pressure and heart rate should be measured. The heart rate of the cardiac cycles used for Doppler measurements is particularly important in mitral and tricuspid prosthetic valves, because the mean gradient is dependent on the diastolic filling period. Finally, the patient's height, weight, and body surface area should be recorded to assess whether PPM is present and to interpret cardiac chamber size.

2. Echocardiographic Imaging. The echocardiographic assessment of patients with prosthetic valves includes standardized measurement and evaluation of the size of cardiac chambers, LV wall thickness and mass, and indices of LV systolic and diastolic function

per guidelines of the ASE.¹⁰ In patients with aortic prostheses, measurements of the aortic root and ascending aorta are recommended. Valves should be imaged from multiple views, with particular attention to the following:

- the opening and closing motion of the moving parts of the prosthesis (leaflets for bioprosthesis and occluders for mechanical prostheses);
- the presence of leaflet calcifications or abnormal echo density attached to the sewing ring, occluder, leaflets, stents, or cage; and
- the appearance of the sewing ring, including careful inspection for regions of separation from the native annulus and for abnormal rocking motion during the cardiac cycle.

In general, magnification of real-time images is necessary for better visualization of the leaflets or occluder mechanism. Mild thickening is often the first sign of primary failure of a biologic valve and is a signal to follow the patient more carefully.¹¹ Occluder motion of a mechanical valve may not be well visualized by transthoracic echocardiography (TTE) because of artifact and reverberations. Nevertheless, optimal 2-dimensional (2D) echocardiographic visualization of occluder motion in tilting disc valves in the mitral or tricuspid position frequently necessitates incremental rotation of the imaging plane

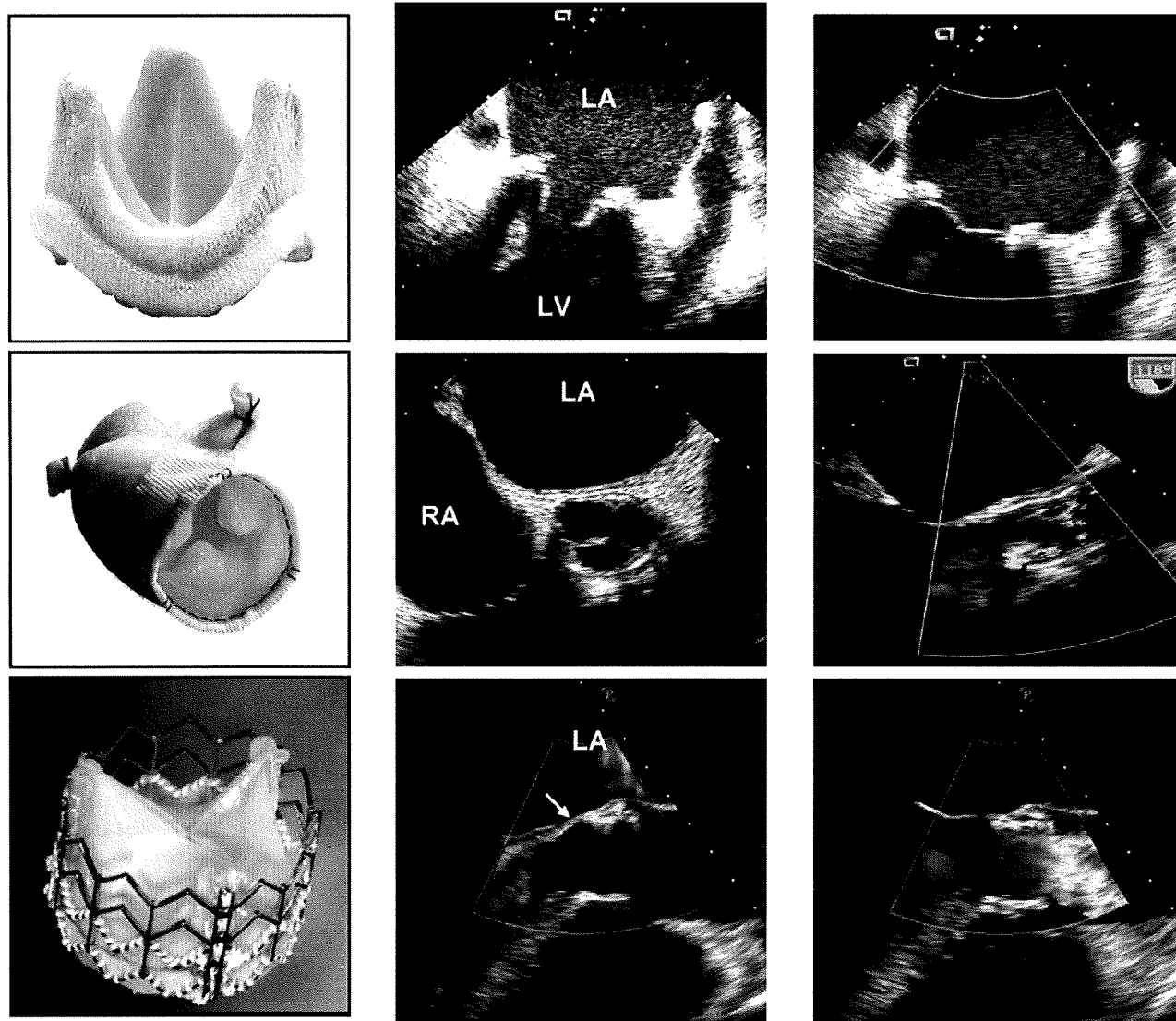


Figure 2 Examples of stented, stentless, and percutaneous biologic valves and their echocardiographic features in diastole (*middle*) and in systole (*right*) as seen by TEE. The stentless valve is inserted by the root inclusion technique. Mild perivalvular AR in the percutaneous valve is shown by *arrow*. The percutaneous biologic valve is currently for investigational use only. Videos 7 to 10 show the valve motion and color Doppler flow pattern of these valves. View video clips online.

from apical views until the occluder motion is seen. Rocking motion of a replacement valve is almost invariably a sign of a large dehiscence in the aortic position.¹² For valves in the mitral position, however, retention of the posterior or both the anterior and posterior native leaflets can allow increased mobility of a normal prosthesis. This situation can usually be differentiated from a dehiscence by the absence of a regurgitant jet. A few microcavitations, detected as microbubbles, are often seen within the LV cavity in the presence of mechanical valves; these are of doubtful clinical significance. The aortic root may be thickened as a result of hematoma and edema after the insertion of a stentless valve as an inclusion inside the aortic root.^{13,14} This appearance, which can be initially mistaken for an aortic root abscess, usually resolves over 3 to 6 months. This entity can be corroborated on review of the intraoperative or early postoperative study, if available. Last, in patients with or without histories of infective endocarditis, a search for the presence of abscess formation in the region of the prosthetic valve annulus or sewing ring should be undertaken. Most

of the above structural abnormalities however are usually better delineated with TEE.

3. Doppler Echocardiography. The principles of interrogation and recording of flow velocity through prosthetic valves are similar to those used in evaluating native valve stenosis or regurgitation.^{15,16} This includes pulsed-wave (PW) and continuous-wave (CW) Doppler as well as color Doppler, using several windows for optimal recording and minimizing angulation between the Doppler beam and flow direction.

a. **Determination of Gradients Across Prosthetic Valves.** Blood velocity across a prosthetic valve is dependent on several factors, including flow and valve size and type. The simplified Bernoulli equation has been the key to the noninvasive calculation of pressure gradients across all cardiac valves, including prosthetic valves,¹⁷ whereby pressure gradient is derived as $4 \times V^2$, where V is the

Table 1 Types of prosthetic heart valves

Biologic
Stented
Porcine xenograft
Pericardial xenograft
Stentless
Porcine xenograft
Pericardial xenograft
Homograft (allograft)
Autograft
Percutaneous
Mechanical
Bileaflet
Single tilting disc
Caged-ball

velocity of the jet in meters per second. In patients with aortic prostheses and high cardiac output or narrow LV outflow (LVO), the velocity proximal to the prosthesis may be elevated and therefore not negligible (proximal velocity > 1.5 m/s). In these situations, estimation of the pressure gradient is more accurately determined by considering the velocity proximal to the prosthesis as $P = 4(V_2^2 - V_1^2)$. Pressure gradients derived with the simplified Bernoulli equation have correlated well with hemodynamically measured gradients. In bileaflet prostheses and caged-ball valves, however, overestimation of the gradient may occur, particularly with smaller valves and high cardiac output (see below).¹⁸⁻²¹

b. EOA. The EOA of a prosthesis by the continuity equation is a better index of valve function than gradient alone. This is calculated as

$$EOA = \text{stroke volume} / \text{VTI}_{\text{PrV}}$$

where VTI_{PrV} is the velocity-time integral through the prosthesis determined by CW Doppler. Stroke volume is usually derived as cross-sectional area just proximal to the prosthesis (in aortic or pulmonary valves) multiplied by the VTI of flow by PW Doppler at that site. Using the label size of the prosthetic valve to calculate the cross-sectional area of the annulus is not valid because of significant discrepancy between these measurements. In prosthetic mitral valves, stroke volume calculated at the aortic annulus or pulmonary annulus may be used, provided no significant regurgitation exists. In prosthetic aortic valves, a simplification of the continuity equation is the Doppler velocity index (DVI), the ratio of velocity proximal to the valve, to the velocity through the valve.²² This index does not rely on measurement of the LVO tract. Conceivably, it may also be applied to prosthetic pulmonary valves, but validation is needed.

c. Pressure Recovery: Hemodynamic Conditions and Clinical Implications. In prosthetic valves, the phenomenon of pressure recovery can occur in two regions: (1) downstream of a valve and (2) within some prosthetic valves, typically bileaflet or caged-ball valves.^{18-21,23-31}

In the first scenario (Figure 3, left), as flow expands into the wider lumen beyond a valve, velocity and kinetic energy will decrease and pressure will be recovered. The pressure gradient measured directly by catheter therefore decreases as the catheter port is moved downstream from the prosthetic orifice and will generally be smaller than the gradient estimated from maximal CW Doppler velocity at the vena contracta: the smallest area occupied by flow. The magnitude of this phenomenon is generally small, except in cases in which the aorta is <3 cm in diameter, an infrequent finding in adults.

Table 2 Essential parameters in the comprehensive evaluation of prosthetic valve function

	Parameter
Clinical information	Date of valve replacement Type and size of the prosthetic valve Height, weight, body surface area Symptoms and related clinical findings Blood pressure and heart rate
Imaging of the valve	Motion of leaflets or occluder Presence of calcification on the leaflets or abnormal echo densities on the various components of the prosthesis Valve sewing ring integrity and motion
Doppler echocardiography of the valve	Contour of the jet velocity signal Peak velocity and gradient Mean pressure gradient VTI of the jet DVI Pressure half-time in MV and TV. EOA* Presence, location, and severity of regurgitation†
Other echocardiographic data	LV and RV size, function, and hypertrophy LA and right atrial size Concomitant valvular disease Estimation of pulmonary artery pressure
Previous postoperative studies, when available	Comparison of above parameters is particularly helpful in suspected prosthetic valvular dysfunction

MV, Mitral valve; TV, tricuspid valve.

*EOA using the continuity equation; needs to be compared with normal Doppler values of the valve type and size.

†Transthoracic Doppler is less sensitive to detection of valvular regurgitation in mitral and tricuspid prosthesis; TEE is frequently needed for a more definitive assessment.

In the case of mechanical bileaflet prostheses (Figure 3, right), the particular design of the valve may cause a separate phenomenon of pressure recovery at the level of the valve. This is not seen in mono-leaflet prostheses or bioprostheses but may be observed in caged-ball prostheses.¹⁹ The smaller central orifice in bileaflet valves may give rise to a high-velocity jet that corresponds to a localized pressure drop that is largely recovered once the central flow reunites with flows originating from the two lateral orifices (Figure 3, right).^{18,19} CW Doppler recording often includes this high-velocity jet, which leads to overestimation of gradients and thus underestimation of EOA compared with the invasive hemodynamic standard, particularly in small prostheses and in high flow states. Differentiation of central from lateral orifice jets by Doppler is usually not feasible with TTE but is possible with TEE in prosthetic mitral valves. These effects of pressure recovery usually do not confer a significant problem in assessing valvular dysfunction, because the reported normal Doppler values for bileaflet and caged-ball valves (Appendices A and B) already incorporate this phenomenon, with which individual patient values are compared.³² However, in situations in which bileaflet valves are very small (19 mm) and accompanied by high flow, differentiation

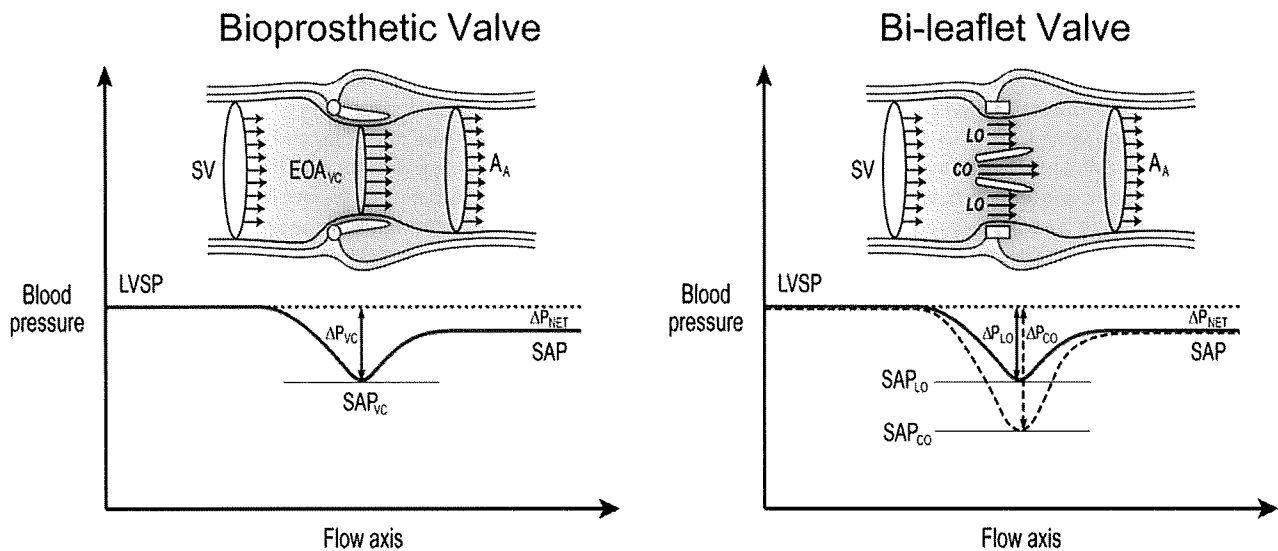


Figure 3 Schematic representation of velocity and pressure changes from the LVO tract to the ascending aorta (A_A) in the presence of a stented bioprosthesis and a bileaflet mechanical valve illustrating the phenomenon of pressure recovery. Because of pressure recovery, velocities are lower and systolic arterial pressure (SAP) is higher at the distal aorta than at the level of the vena contracta (VC). This is further exaggerated in the case of a bileaflet valve, in which the velocity is higher in the central orifice (CO) and thus pressure drop is higher at that level. Doppler gradients are estimated from maximal velocity at the level of the vena contracta and represent the maximal pressure drop, whereas invasive estimation of gradients usually reflect net pressure difference (ΔP) between LV systolic pressure (LVSP) and ascending aorta. LO, Lateral orifice; SV, stroke volume in LVO.

from normal may be difficult and requires evaluation of valve motion and structure using TEE, fluoroscopy, and/or computed tomography (CT).

d. PPM. The physiologic relationship between flow, valve area, and gradient is illustrated by the equation $\text{gradient} = Q^2 / (K \times \text{EOA}^2)$, where Q is flow and K is a constant. For gradients to remain low, the EOA must be proportionate to the flow requirements of the individual, which at rest are largely determined by body size. PPM occurs when the EOA of the prosthesis is too small in relation to the patient's body size, resulting in abnormally high postoperative gradients.³³⁻³⁶

The parameter used to characterize PPM is EOA indexed to the patient's body surface area. Although the principles underlying PPM theoretically apply to all valve positions, most studies have focused on the aortic valve. Gradients increase exponentially when the indexed EOA is ≤ 0.8 to $0.9 \text{ cm}^2/\text{m}^2$.^{33,35-37} On the basis of this relationship, PPM is considered to be hemodynamically insignificant if the indexed EOA is $>0.85 \text{ cm}^2/\text{m}^2$, moderate if between 0.65 and $0.85 \text{ cm}^2/\text{m}^2$, and severe if $<0.65 \text{ cm}^2/\text{m}^2$.³⁶ Such categorization is important because the impact of PPM on clinical outcomes increases with severity.^{38,39} The reported prevalence of moderate PPM varies between 20% and 70%, whereas that of severe PPM is between 2% and 11%.^{36,38,40} It should be emphasized that the indexed EOA, not the size or geometric specifications of the prosthesis, is the only parameter to be consistently related to postoperative gradients and/or adverse clinical outcomes.⁴¹⁻⁴⁴

The main adverse clinical outcome ascribed to PPM is reduced short-term and long-term survival, particularly if associated with LV dysfunction.^{38,45,46} There are some reports of lesser regression of LV hypertrophy,⁴⁰ increased incidence of late cardiac events,^{39,46} and less improvement in functional class,⁴⁷ although other studies have found little effect. PPM can largely be avoided^{36,43,44,48,49} by the calculation of the projected indexed EOA of the prosthesis to

be implanted. If PPM is anticipated, choosing an alternative prosthesis or considering aortic root enlargement surgery is advised.

PPM has also been described in the mitral position.⁵⁰ It has been suggested that the indexed EOA of mitral prostheses should ideally be no less than 1.2 to $1.3 \text{ cm}^2/\text{m}^2$ to avoid abnormally high postoperative gradients.^{34,35} Depending on the study,⁵¹⁻⁵³ the reported prevalence for mitral PPM varies between 39% and 71% and was shown to be associated with persisting pulmonary hypertension⁵² and decreased long-term survival.^{51,53}

Recent data suggest that PPM may not have similar detrimental effects in obese patients (body mass index $> 30 \text{ kg}/\text{m}^2$) compared with nonobese patients.⁵⁴ For similar body surface areas, obese patients tend to have lower cardiac output requirements. Future studies are needed to determine if it would be more appropriate to index the EOA for fat-free mass rather than body surface area in obese patients.

e. Doppler Recordings and Measurements Based on Prosthetic Valve Position. For the aortic position, the measurements needed are peak velocity, mean gradient, VTI, DVI, and EOA by the continuity equation. For serial studies, it is reasonable to use the DVI (see below under "Prosthetic Aortic Valves") because this avoids measuring the LVO tract diameter. For the pulmonary position, the measurements needed are those of peak velocity and derived mean pressure difference. Although EOA and DVI could be calculated for a prosthetic pulmonary valve, little experience exists with these parameters.

In the mitral and tricuspid positions, the measurements needed are peak velocity, mean pressure gradient, VTI, and pressure half-time. Heart rate reporting is essential. It is not appropriate to use the pressure half-time formula ($220/\text{pressure half-time}$) to estimate orifice area in prosthetic valves. This is valid only for moderate or severe stenoses with orifice areas $< 1.5 \text{ cm}^2$. For larger valve areas, the pressure half-time reflects atrial and LV compliance characteristics and loading conditions and has no relation to valve area.^{34,55}

Doppler recordings should be performed at a sweep speed of 100 mm/s. Measurements should be taken over 1 to 3 cycles in sinus rhythm. In atrial fibrillation, Doppler measurements should be performed when possible during periods of physiologic heart rate (65-85 beats/min). Averaging from 5 to 15 beats in atrial fibrillation has been suggested but is cumbersome and may still give an unrepresentative result, because cycle lengths may vary substantially. In cases in which the derivation of a parameter requires measurements from different cardiac cycles (eg, EOA by the continuity equation, DVI), matching of the respective cycle lengths to within 10% is advised. For prosthetic aortic EOA calculation, the preceding intervals of LVO velocity and prosthetic valve flow should be matched, whereas for mitral valves, the cycle length of mitral inflow should be matched with the preceding interval of LVO velocity, if this is an acceptable site for stroke volume measurement.

f. Physiologic Regurgitation. Minor regurgitation is normal in virtually all mechanical valves (Figures 1 and 2). Two types of "physiologic" regurgitation may be seen: a closing volume (a displacement of blood caused by the motion of the occluder) and true trivial or mild regurgitation at the hinges of the occluder. For the Starr-Edwards valve, there is a typical small closing volume and usually little or no true transvalvular regurgitation (Figure 1). The single tilting disc valves have both types of regurgitation, but the pattern may vary: the Bjork-Shiley valve has small jets located just inside the sewing ring, where the closed disc meets the housing, while the Medtronic Hall valve has these same jets plus a single large jet through a central hole in the disc (Figure 1). The bileaflet valves typically have multiple jets located just inside the sewing ring, where the closed leaflets meet the housing, and centrally, where the closed bileaflets meet each other (Figure 1). These "washing jets" are thought to prevent the formation of thrombi at sites of stasis within the housing. The associated regurgitant fraction is directly related to the size of the valve and is also larger at low cardiac outputs. Although the regurgitant fraction is usually no larger than 10% to 15%, the associated color jet can look large, up to 5 cm long (especially in Medtronic Hall valves), but narrow at its origin (Figure 1). In the case of bileaflet valves, they are usually found in formation, two from each pivotal point; sometimes these single pivotal washing jets divide into 2 or 3 separate "plumes" (Figure 1). The jets are invariably low in momentum, so that they are homogeneous in color, with aliasing mostly confined to the base of the jet.

Regurgitation is increasingly reported in normal biologic valves, mainly because of increased sensitivity of current ultrasound machines. Stentless valves, including homografts and autografts, are more likely than stented valves to have minor regurgitant jets. Percutaneous aortic valves may have small central and/or paravalvular regurgitation (Figure 2).

g. Pathologic Prosthetic Regurgitation. Pathologic regurgitation is either central or paravalvular. Most pathologic central valvular regurgitation is seen with biologic valves, whereas paravalvular regurgitation is seen with either valve type and is frequently the site of regurgitation in mechanical valves. Localization of paravalvular regurgitation may be difficult and is possible with confidence only if a trail of flow can be visualized around the outside of the sewing ring. This may require the use of multiple transducer positions, including off-axis views. Multiplanar TEE may be necessary, particularly in mitral and tricuspid valves. Although paraprosthetic regurgitation is abnormal, small jets are not uncommon, especially during perioperative examination early after surgery. Immediately following implantation, the prevalence of paravalvular regurgitation ranges between 5% and 20%^{56,57}; the majority of these leaks, however, are clinically

and hemodynamically insignificant and, in the absence of endocarditis, have a benign course. There is no evidence that they increase the risk for endocarditis, but on occasion, they may cause hemolytic anemia due to red cell destruction.

Broadly, the same principles and methods used for quantitation of native valvular regurgitation, detailed in a previous document,¹⁶ can be used for prosthetic valves, but are more challenging. Because of shielding and reverberations of the prosthesis, detection of regurgitation with TTE is more difficult for valves in the mitral and tricuspid positions, particularly in mechanical valves (Figure 4). Indirect clues from various Doppler parameters can suggest the presence of significant regurgitation. However, TEE is frequently needed for the diagnosis of prosthetic MR. The frequent eccentricity of regurgitant jets, particularly in mechanical valves, renders the quantitation and assessment of regurgitation in general more difficult or limited. Multiple small normal transprosthetic jets cannot be quantified accurately, but this is not necessary in clinical practice. For paravalvular jets, the proportion of the circumference of the sewing ring occupied by the jet gives an approximate guide to severity. Comparative flow measurements for the determination of regurgitant volume or fraction, which frequently rely on the determination of stroke volume at annular sites, can be used for prosthetic AR and pulmonary regurgitation (PR) (annular measurement not hindered by the prosthesis) but not for prosthetic MR. The availability of real-time 3-dimensional (3D) TEE with Doppler may facilitate the quantitation of prosthetic regurgitation.

C. Considerations for Intraoperative Patients

Since its introduction in the early 1970s, intraoperative echocardiography has steadily become an invaluable diagnostic tool for patients undergoing valve surgery. Because of the potential for suboptimal surgical results, the intraoperative detection of prosthetic valve dysfunction is highly desirable. Among the available routes and modalities for imaging, such as TEE and epicardial and epiaortic ultrasound, TEE remains the most widely used. The American Society of Anesthesiologists has recommended intraoperative TEE as a category II indication in patients undergoing valve surgery.⁵⁸ Current American College of Cardiology and American Heart Association practice guidelines recommend TEE as a class I indication for patients undergoing valve replacement with stentless xenograft, homograft, or autograft valves.¹

The comprehensive assessment of prosthetic valves requires advanced echocardiographic training, which must be factored in when the intraoperative use of TEE is considered. Although the criteria for assessment remain similar, intraoperative patients deserve special consideration. The intraoperative environment presents unique challenges. The period prior to cardiopulmonary bypass is usually associated with reduced preload and myocardial depression that accompanies the anesthetized state.⁵⁹ Moreover, an open chest, open pericardial cavity, and positive pressure ventilation also influence loading conditions.⁶⁰ The postbypass phase, on the other hand, is a labile period during which there are frequent changes in preload and afterload, inotropic and chronotropic drugs may be in effect, and the heart is frequently electrically paced.⁶¹ All of the above factors must be considered during the echocardiographic assessment of prosthetic valve function.

Prosthetic valves may need to be assessed intraoperatively in 3 situations: (1) after the replacement of a diseased native valve, (2) in unrelated cardiac surgery as a part of comprehensive TEE, and (3) prior to redo valve surgery in dysfunctional prosthetic valves. A patient who presents for valve replacement surgery has usually undergone extensive imaging preoperatively, and the decision to replace the valve has already been made. However, in the operating room, the intraoperative echocardiographer can provide valuable feedback

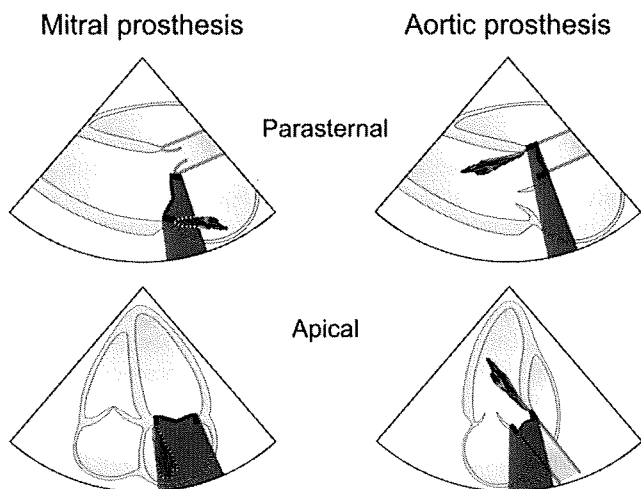


Figure 4 Effect of mechanical prosthetic valve position and echocardiographic imaging view on shadowing and masking of a regurgitation jet by Doppler. A higher effect from transthoracic imaging is seen on prostheses in the mitral position compared to the aortic position.

to the surgeon regarding the size of the valve annulus to assist with prosthetic valve selection. After cardiopulmonary bypass, the assessment of the newly seated valve is essential. Multiple echocardiographic views are obtained to determine the appropriate movement of valve leaflets, and color flow Doppler should exclude the presence of paravalvular leaks. Intraoperative echocardiography is also important in patients at risk for "geometric mismatch" of the valve and surrounding tissue or annulus, with resultant regurgitation because of the relatively small size of the valve (patients with stentless valves or the Ross procedure). Postoperatively, any regurgitation that is graded moderate or severe would need to be surgically corrected immediately prior to leaving the operating room. Other complications, such as "stuck" mechanical valve leaflets, valve dehiscence, and dysfunction of adjacent valves, may also be detected and require immediate surgical attention. The pressure gradient across a newly seated valve may initially be abnormally high, especially in the aortic position.⁶² Several factors could contribute to the finding of an elevated gradient, including high postbypass cardiac output, hemodilution, high subvalvular velocities, and PPM. Regardless of the possible reasons, a high gradient should always prompt the search for mechanical causes of valve obstruction, such as stuck valve leaflets or occlusive thrombus. If echocardiographic assessment demonstrates no apparent mechanical cause, the surgery may proceed as planned and the valve may be interrogated postoperatively. Inappropriately high gradients may also be assessed by alternate imaging modalities, such as epicardial or epiaortic ultrasound. During the placement of a prosthetic valve in the mitral position, the surgeon may choose a transeptal approach to the left atrium. Postoperatively, the interatrial septum should be evaluated for any residual communication.

In situations in which the insertion of a transesophageal echocardiographic probe is not preferred (eg, esophageal stricture), prosthetic valves may need to be assessed by epicardial or epiaortic ultrasound. These modalities may also be indicated to interrogate a prosthetic valve to obtain Doppler-derived gradients. Surface echocardiography affords greater flexibility for aligning the Doppler beam with the direction of blood flow. However, appropriate expertise must be available for image acquisition and interpretation.⁶³

D. Complications of Prosthetic Valves

1. General Considerations: Early Versus Late Complications.

a. Early Complications. Valvular dysfunction after surgery is usually related to technical challenges during surgery or early infection. Paravalvular leak is more frequent after debridement of calcium, repeat valvular surgery, and reconstruction of the aortic or mitral annulus and in older patients. Early leaks are usually mild and may not be detected clinically or by TTE (particularly in the mitral position). PPM and geometric mismatch are increasingly recognized complication of valve replacement (Table 3). Early prosthetic thromboembolism is rare in the absence of a coagulopathy or inadequate anticoagulation. Rarely, the technique of chordal preservation for mitral prostheses may lead to chordal entrapment and obstruction of a mechanical prosthesis. Last, acute endocarditis occurs in <1% of patients and is likely reduced by the common use of perioperative antibiotics.

b. Late Complications. The incidence and nature of late dysfunction varies more with the type of prosthesis used, its durability and thrombogenicity, as well as patient factors such as the risk for endocarditis (Table 3). Thromboembolism is determined by the type of heart valve as well as by patient-related factors (LV function, left atrial [LA] size, presence of atrial fibrillation). Mechanical valves are associated with a significant incidence of thromboembolic complications, though critical valve thrombosis is uncommon. The cause is usually inadequate anticoagulation. Both mechanical and tissue valves are also at risk for interaction between the prosthesis and host to create fibrous ingrowth or pannus, which can lead to progressive obstruction. Rizzoli et al⁶⁴ followed 2680 patients who received ≥ 1 mechanical prosthesis for the development of complications requiring reoperation. Risk increased from the aortic to mitral to double-valve implants. Reoperation for prosthetic valve malfunction was required in 251 patients and was due to dehiscence in 133, pannus in 48 (a linearized rate of 0.24%/patient-year), and thrombosis in 29 (a linearized rate of 0.15%/patient-year).⁶⁴ Obstruction of stentless or autograft valves due to thrombosis is rare, and pannus is much less frequent.

Valve degeneration leading to stenosis and/or regurgitation remains the most frequent complication of biologic valves, despite advances in valve design that have led to significant improvement in durability. For example, the Carpentier-Edwards pericardial valve (Edwards Lifesciences, Inc, Irvine, CA), introduced in 1981, has had greater success, with a freedom from structural valve failure in the mitral position that ranges from 69% to 85% at 10 years in a patient population with a mean age of 60 to 70 years.⁶⁵ Better results are obtained in the aortic position and worse results in younger patients or in those with renal failure who are more prone to leaflet calcification. Aortic homografts appear to have increased longevity, especially in younger patients, compared with stented valves.⁶⁶

Patients with composite aortic valve and root replacement have the same type of complications as the type of valve used within the conduit and in addition may suffer from pseudoaneurysm or dehiscence at the coronary artery buttons and/or at the annular anastomosis.⁶⁷ Although this complication can be suspected from the transthoracic examination, it usually requires transesophageal echocardiographic evaluation. The various complications after valve replacement and their echocardiographic features are beyond the scope of this document and have been recently reviewed.⁶⁷

2. Endocarditis. Echocardiography plays a central role in the diagnosis and management of patients with infective endocarditis and should be performed in all cases in which there is a medium or

Table 3 Early and late complications of prosthetic valves

PPM
Geometric mismatch
Dehiscence
Primary failure
Thrombosis and thromboembolism
Pannus formation
Pseudoaneurysm formation
Endocarditis
Hemolysis

high clinical suspicion or when the patient is severely ill. However, echocardiography is not usually indicated in a stable patient as part of a fever screen until other more common causes of fever are excluded. Vegetations are usually irregularly shaped and can be recognized on echocardiography as independently mobile structures of relatively low echogenicity. Vegetations in the setting of prosthetic valves tend to form in the valve ring area and may spread to the leaflet of the prosthetic valve, stent, or occluder and impair the opening and closing of the valve. Differentiation of vegetations from other masses, such as thrombus, sutures, or pledgets, may be difficult without considering the echocardiographic findings in the context of the clinical presentation. Comparison of findings with those from previous studies is also quite helpful.

Abnormal cavities, produced by either an echo-lucent or an echodense mass, may be seen in the valve ring area. Abscesses are sometimes observed even in cases in which vegetations are absent and may occasionally infiltrate the septum and impair the conduction system. Early after surgery, particularly in stentless valves, edema and hematoma may occur and simulate a walled-off abscess. Progression of an abscess may result in a fistula between the heart chambers. Color Doppler is very useful in these situations for shunt detection. Endocarditis may also lead to suture dehiscence and paravalvular regurgitation in all prosthetic valves and to valve destruction in bioprosthetic valves.

TTE is often limited in assessing prosthetic valve endocarditis and its complications. TEE, on the other hand, demonstrates high sensitivity (86%-94%) and specificity (88%-100%) for the detection of vegetations.⁶⁸⁻⁷⁰ TEE is also superior to TTE in detecting associated paravalvular abscesses in the posterior but not in the anterior aortic root.⁷¹⁻⁷³ The reported sensitivity and specificity for the diagnosis of paravalvular abscesses with TTE are 28% and 98%, respectively, and with TEE, 87% and 95%, respectively.⁷² TEE is therefore necessary in cases in which infective endocarditis is strongly suspected, even when no significant findings are seen on TTE.^{74,75} TEE is also indicated if signs of infection persist or progress despite appropriate antimicrobial treatment, evoking suspected complications such as valve ring abscess or shunt. For the best diagnostic accuracy, a combination of TTE and TEE is needed, because anterior structural abnormalities can be missed by TEE because of shadowing, depending on valve location.^{71,74} The negative predictive value of combined TTE and TEE is 95%.^{76,77} Thus, although the combined approach is highly accurate in diagnosing endocarditis and its complications, a small percentage of cases can be missed, particularly if clinical suspicion is strong.^{77,78} In such cases, a repeat study is recommended after 7 to 10 days.

3. Prosthetic Valve Thrombosis Versus Pannus. Prosthetic valve thrombosis is much more common in mechanical than tissue valves. Although thrombus formation is frequently associated with valve obstruction, regurgitation, or embolism, it may be an incidental finding during imaging.⁷⁹ Recent history of a systemic embolic event

is associated with the presence of a thrombus⁷⁹ or fibrinous-like mobile "strands" that can be detected with TEE.^{80,81}

The distinction between thrombus and pannus as the underlying etiology of obstruction is essential if thrombolytic therapy is contemplated. TEE along with clinical parameters can help differentiate the two entities.⁸² Thrombi are in general larger and have a soft ultrasound density, similar to that of the myocardium. Specific features for pannus formation include a small dense mass that in 30% of cases may not be distinctly visualized. Detection of abnormal prosthetic valve motion by TEE is more common in valves with thrombus. Pannus formation is more common in the aortic position (Figure 5). Characteristically, thrombi associated with mitral prostheses extend beyond the surgical ring into the left atrium and atrial appendage. Compared with pannus formation, obstruction due to thrombus is associated with a short duration of symptoms and with a history of inadequate anticoagulation (international normalized ratio < 2). The combination of findings of a soft density on the prosthesis and an inadequate international normalized ratio has reported positive and negative predictive values of 87% and 89%, respectively, for thrombus formation.⁸²

Thrombus formation may interfere with the mechanism of valve motion and cause significant obstruction that may be catastrophic (Figure 6). Traditionally, these patients underwent redo valve replacement. Recently, fibrinolytic therapy has emerged as an alternative to surgical treatment for obstructed left-sided prosthetic valves and is considered the treatment of choice for tricuspid valve thrombosis.⁸³⁻⁸⁶ If thrombolysis is contemplated, TEE should be performed for diagnosis and risk stratification. A thrombus area on TEE of <0.85 cm² confers a lower risk for embolic phenomena or death associated with thrombolysis.⁸⁶ Doppler echocardiography is the preferred modality to assess serially the hemodynamic success of thrombolysis.^{86,87} It is important to remember that pannus and thrombus may both be present. After thrombolysis that is judged successful on the basis of improved hemodynamics and/or valve motion, it is very important to follow patients with serial clinical and echocardiographic examinations, because residual pannus can lead to rethrombosis of the prosthesis.

E. Stress Echocardiography in Evaluating Prosthetic Valve Function

1. Prosthetic Aortic Valves. Some patients with symptoms as a result of pathologic obstructions or PPM have equivocal Doppler parameters of prosthetic valve function at rest. Stress echocardiography should be considered in patients with exertional symptoms for which the diagnosis is not clear. The aim is to test for valve dysfunction, coexistent coronary disease, and, on occasion, new or worsening MR. Dobutamine and supine bicycle exercise are most commonly used. Treadmill exercise provides additional information about exercise capacity but is less frequently used because the recording of the valve hemodynamics is after completion of exercise, when the hemodynamics may rapidly return to baseline.

Normally functioning stentless valves open well in systole with a resultant minimal increase in mean pressure gradient from about 6 mm Hg at rest to 9 mm Hg during stress.⁸⁸⁻⁹² Stented bovine pericardial valves are similar,⁹³ while porcine valves are relatively more obstructive. In one study, mean pressure difference for the Medtronic intact porcine valve rose from 19 to 28 mm Hg during stress.⁹¹ Comprehensive normal ranges and precise cut points, however, are not available. It is likely that a guide to significant obstruction would be similar to that for native valves, such as a rise in mean gradient >15 mm Hg with stress.⁹² In clinical practice, a combination of exact reproduction of symptoms with no

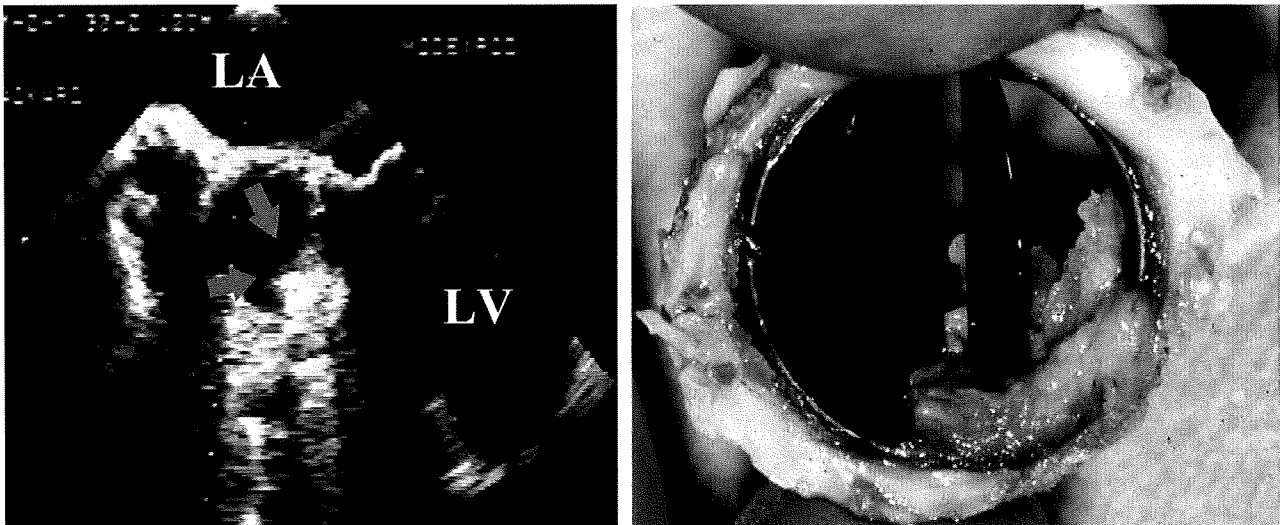


Figure 5 Pannus formation on a St Jude Medical valve prosthesis in the aortic position as depicted by TEE. The mass is highly echogenic and corresponds to the pathology of the pannus at surgery. The pannus is depicted by the *arrows*. LA, Left atrium; LV, left ventricle.

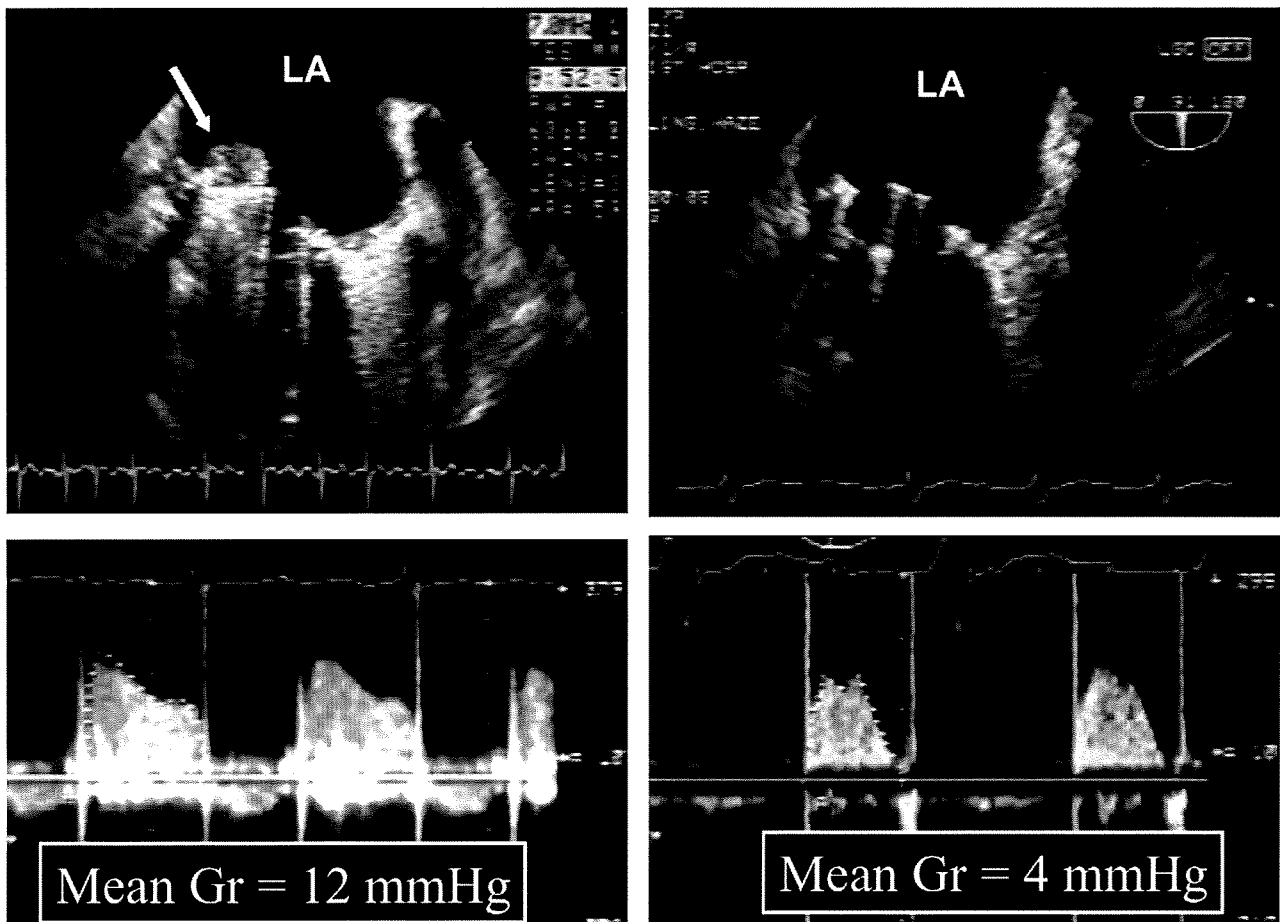


Figure 6 Prosthetic St Jude Medical valve thrombosis in the mitral position (*arrow*) obstructing and immobilizing one of the leaflets of the valve. After thrombolysis, leaflet mobility is restored, and the mean gradient (Gr) is significantly decreased. LA, Left atrium.

wall motion abnormality and a large rise in pressure difference is highly suggestive of abnormal valve dynamics.

2. Prosthetic Mitral Valves. Exertional dyspnea after mitral valve replacement may be caused by primary valve failure, LV and/or right

ventricular (RV) dysfunction, pulmonary hypertension, or other non-cardiac causes. Stress echocardiography should be considered in patients with exertional symptoms for which the diagnosis is not clear. The aims are to record changes in transmitral velocities and the tricuspid regurgitant signal. Stress testing modalities similar to those for

aortic valves can be used. In the elderly, light exercise around the echocardiography laboratory or using a step stool may be sufficient to elicit the abnormal hemodynamics. No normal ranges or cut points exist, but data from native valves provide a guide. Obstruction or PPM is likely if the mean gradient rises above 18 mm Hg after exercise, even when the resting mean gradient is normal.⁹⁴

F. Other Techniques for Assessing Replacement Heart Valves

1. Cinefluoroscopy. Cinefluoroscopy was the first noninvasive imaging technique to evaluate prosthetic valves. In mechanical prosthetic valves, cinefluoroscopy is easily applied because of the radiopaque base ring and the ball or disc occluder. In tissue valves, however, cinefluoroscopy has limited value.⁹⁵⁻⁹⁷ Abnormal tilting or rocking of the base ring is indicative of extensive valve dehiscence. Small or moderate dehiscence, however, cannot be diagnosed without cardiac catheterization and dye injection. Impaired excursion or incomplete seating of the moving parts of the prosthesis suggests the presence of tissue in-growth or thrombus. Detection of calcium on the leaflets of a tissue valve is diagnostic of degeneration but does not allow assessment of its hemodynamic impact.^{98,99} A serious complication of older models of valve prostheses with dramatic clinical presentation and high mortality was strut fracture with disc embolization. In these cases, cinefluoroscopy or plain-film radiography was the study of choice.¹⁰⁰⁻¹⁰³ Modifications in design and construction in the new generation of valves have abolished this problem.

With the advent of TEE, motion as well as structure of prosthetic valves can be assessed, thus providing an advantage over cinefluoroscopy. TEE allows an excellent evaluation of valve motion in mitral and tricuspid prosthetic valves, because of their en face position in relation to the imaging plane. Cinefluoroscopy currently still plays a complementary diagnostic role in evaluating disc mobility of mechanical aortic valves.

2. CT. In prosthetic valves, the simple visualization of mobile cusps or occluder, without quantification, can be enough to differentiate PPM from pathology as a cause of unexpectedly high gradients. Case studies have reported successful imaging of cusps and occluders with CT in normally functioning aortic and mitral replacement valves and the detection of a stuck mechanical leaflet.¹⁰⁴⁻¹⁰⁶ CT of moving structures (cine CT), however, requires reconstruction of multiple phases of the cardiac cycle and at this time has limited temporal resolution.

CT can also image pannus^{107,108} which may be difficult on TTE or TEE, particularly in the aortic position. Case reports suggest that vegetations can also be imaged.¹⁰⁹ Calcification on CT correlates approximately with the grade of stenosis on echocardiography in native valves¹¹⁰ and could aid in the detection of early primary failure of biologic replacement valves.¹¹¹

To date, there are no systematic studies comparing CT with echocardiography. At this time, there are no definitive indications for CT in assessing prosthetic heart valve dysfunction. However, early clinical experience shows that CT could be used as an alternative to fluoroscopy for mechanical valves and could be considered for imaging the cusps of biologic valves if the results of TEE are inconclusive.

3. Cardiac Catheterization. Measurements of flow and pressure gradients are used for the calculation of EOA using the Gorlin formula. Normal values of valve gradients and effective areas have been reported for several heart valves.¹¹² Contrast injection allows the assessment of prosthetic valve regurgitation. Ideally, a dual-catheter approach is needed to measure pressure upstream and downstream

from the valve. In clinical practice, however, this is not commonly performed. Crossing a prosthetic valve with a catheter should not be attempted in mechanical valves because of limitations and possible complications.¹¹³⁻¹¹⁵ In prosthetic mitral valves, the use of pulmonary capillary wedge pressure for measurement of transmitral gradient frequently results in an overestimation of gradient and hence underestimation of valve area compared with direct measurement of LA pressure.^{17,116-118} Thus, in the rare cases in which invasive mitral prosthetic gradients need to be assessed, a direct measurement of LA pressure with a transeptal technique is currently recommended. Tissue valves can be crossed with a catheter easily, but a degenerative, calcified bioprosthesis is friable, and leaflet rupture with acute severe regurgitation is possible. A dual-catheter technique for the measurement of gradients is still needed in rare cases of prosthetic aortic valves in which gradients cannot be adequately obtained by transthoracic Doppler echocardiography or TEE. Contrast angiography is occasionally used, along with TEE, in delineating associated complications of prosthetic valves, such as fistulas and pseudoaneurysms.

G. Postoperative Evaluation and Follow-Up Studies

Ideally, a baseline postoperative transthoracic echocardiographic study should be performed at the first visit, 2 to 4 weeks after hospital discharge, when the chest wound has healed, ventricular function has improved, and anemia with its attendant hyperdynamic state has abated.¹ However if the patient is being transferred and may not return, it may be best to perform the study before hospital discharge.

Routine follow-up clinical visits should be conducted annually after valve replacement, with earlier reevaluations and echocardiography if there is a change in clinical status. Routine echocardiography after a first postoperative study is not indicated for normally functioning prostheses in the absence of associated pathology, other indications for echocardiography (eg, follow-up of LV dysfunction), or clinical symptoms suggestive of valvular dysfunction or other cardiac pathology.¹ Patients with bioprosthetic valves may be considered for annual echocardiography after the first 5 years in the absence of a change in clinical status. In patients with mechanical heart valves, routine annual echocardiography is not indicated in the absence of a change in physical examination or clinical status.¹

III. EVALUATION OF PROSTHETIC AORTIC VALVES

A. Prosthetic Aortic Valve Function and Stenosis

1. Imaging Considerations. Echocardiographic imaging should identify the sewing ring, the valve or occluder mechanism, and the surrounding area. The ball or disc is often indistinctly imaged because of echo reverberations, whereas the leaflets of normal tissue valves should be thin with an unrestricted motion. Stentless or homograft valves may be indistinguishable from native valves. Imaging from the parasternal views should also be aimed at delineating well the LVO tract for measurement of LVO diameter to determine stroke volume and EOA. One can use modified views (lower parasternal location) to keep the artifact from the valve away from the LVO.

2. Doppler Parameters of Prosthetic Aortic Valve Function. A complete examination includes an estimation of pressure gradients, DVI, EOA, an assessment of regurgitation if present, and LV size and function (Table 4).

a. Velocity and Gradients. Doppler velocity recordings across normal prosthetic valves usually resemble those of mild native aortic

stenosis, with a maximal velocity usually >2 m/s, along with a triangular shape of the velocity contour, with occurrence of the maximal velocity in early systole. With increasing stenosis of the valve, a higher velocity and gradient are observed, with longer duration of ejection and more delayed peaking of the velocity during systole (Figure 7). High gradients may be seen with normally functioning valves with a small size, increased stroke volume, PPM, or valve obstruction. Conversely, a mildly elevated gradient in the setting of severe LV dysfunction may indicate significant stenosis. Thus, the ability to distinguish malfunctioning from normal prosthetic valves in high flow states on the basis of gradients alone may be difficult. If the velocity in the LVO is >2 m/s, a suspicion of a dynamic or fixed obstruction exists upstream to the valve. In this situation, the estimated gradient through the prosthesis should reflect that it is a combined gradient. To minimize angle error, CW Doppler evaluation of aortic prostheses must be performed, similar to native aortic stenosis, from multiple transducer positions, including apical, right parasternal (with the patient in the right lateral decubitus position), right supraclavicular, and supra-sternal notch (with the patient in a supine or semirecumbent position for these last two). Measurements of prosthesis velocity and gradients are made from the transducer position yielding the highest velocities. Occasionally, such as in patients with chronic lung disease, subcostal transducer positions yield the highest velocities.

For the adequate assessment of prosthetic valve function, other qualitative and quantitative indices that are less dependent on flow should be evaluated (Table 4). The contour of the velocity through the prosthesis is a qualitative but valuable index of prosthetic valve function that is used in conjunction with the other quantitative indices. In a normal valve, even during high flow, there is a triangular shape to the velocity, with early peaking of the velocity and a short acceleration time (AT; the time from the onset of flow to maximal velocity), similar to mild native aortic stenosis. With prosthetic valve obstruction, a more rounded velocity contour is seen, with the velocity peaking almost in mid-ejection, prolonged AT, ejection time (ET) as well as the AT/ET ratio (Figure 7).^{119,120} These parameters are valuable in the overall assessment of valve function, particularly in high gradients. Recent data have shown that a cutoff of AT of 100 ms differentiates well between normal and stenotic prosthetic valves.^{119,121} An AT/ET > 0.4 is also consistent with prosthetic valve obstruction.^{119,121} These indices are independent of Doppler angulation with the jet direction. Other quantitative indices of valve function that are less dependent on flow are EOA and DVI.

b. EOA. Aortic EOA^{24,122,123} is most often derived with stroke volume at the LVO as

$$EOA_{PrAV} = (CSA_{LVO} \times VTI_{LVO}) / VTI_{PrAV}$$

where CSA_{LVO} is the cross-sectional area of the outflow tract, derived from a diameter measurement just underneath the prosthesis from the parasternal long-axis view assuming a circular geometry, and VTI_{LVO} is the VTI proximal to the leaflets or occluder as recorded from an apical 5-chamber or long-axis view using PW Doppler (Figure 8). Care should be exercised in locating the sample volume adjacent to the prosthesis while avoiding the region of subvalvular acceleration (this usually requires a position 0.5 to 1 cm below the sewing ring (toward the apex). The Doppler waveform should be smooth, with minimal spectral broadening and a well-defined peak. VTI_{PrAV} is the VTI across the prosthesis using CW Doppler and is obtained from the same signals that are used for measurement of prosthesis peak velocity and mean gradient.

Table 4 Doppler echocardiographic evaluation of prosthetic aortic valves

	Parameter
Doppler echocardiography of the valve	Peak velocity/gradient Mean gradient Contour of the jet velocity; AT DVI EOA Presence, location, and severity of regurgitation
Pertinent cardiac chambers	LV size, function, and hypertrophy

EOA, as expected, is dependent on the size of the inserted valve (Appendix A). EOA should therefore be referenced to the valve size of a particular valve type. For valves of any size, significant stenosis is suspected when valve area is <0.8 cm². However, for the smallest size valve, this may still be normal, particularly for bileaflet valves because of pressure recovery (Appendix A). These are situations in which the size of the valve is crucial to know, and a comparison with a baseline postoperative study is helpful. The largest source of variability is measurement of the LVO tract. When this diameter is difficult to obtain, another site for flow measurement may be used. If TEE is performed, it offers an excellent opportunity for an LVO measurement.¹²⁴

c. DVI. DVI is a dimensionless ratio of the proximal velocity in the LVO tract to that of flow velocity through the prosthesis:

$$DVI = V_{LVO} / V_{PrAV}$$

DVI is calculated as the ratio of respective VTIs and can be approximated as the ratio of the respective peak velocities (Figure 9).²² DVI incorporates the effect of flow on velocity through the valve and is much less dependent on valve size.²² DVI can therefore be helpful to screen for valve dysfunction, particularly when the cross-sectional area of the LVO tract cannot be obtained or valve size is not known. Part of the reason why DVI is less dependent on valve size is inherent in the relation of aortic valve size to the LVO cross-sectional area: the larger the LVO area, the larger the size of the valve that can be fitted at surgery.²² DVI is always less than unity, because velocity will always accelerate through the prosthesis. A DVI < 0.25 is highly suggestive of significant valve obstruction. In a group of patients with severe stenosis of St Jude Medical aortic valves requiring reoperation, the mean DVI was 0.19 ± 0.05 (range, 0.12-0.27) and significantly lower compared with matched controls with normal prosthetic valve function (mean DVI, 0.39; range, 0.28-0.55).^{22,125} Similar to EOA, DVI is not affected by high flow conditions through the valve, including AR, whereas blood velocity and gradient across the valve are.¹²⁵

3. Diagnosis of Prosthetic Aortic Valve Stenosis. The appearance of a new murmur with new congestive heart failure symptoms in a patient with prosthetic aortic valve should prompt an urgent transthoracic study and, if indicated, TEE. However, the initial suspicion of prosthetic valve stenosis may be the incidental finding of abnormally high flow velocities detected during a routine examination. One must bear in mind that high velocity alone is not proof of intrinsic prosthetic obstruction and may be secondary to high flow or PPM. To the opposite, high gradients may not be manifest in patients with prosthesis dysfunction and low cardiac output state. Finally, Doppler recorded gradients may be spuriously elevated in bileaflet mechanical prosthesis because of pressure recovery at the valvular level.

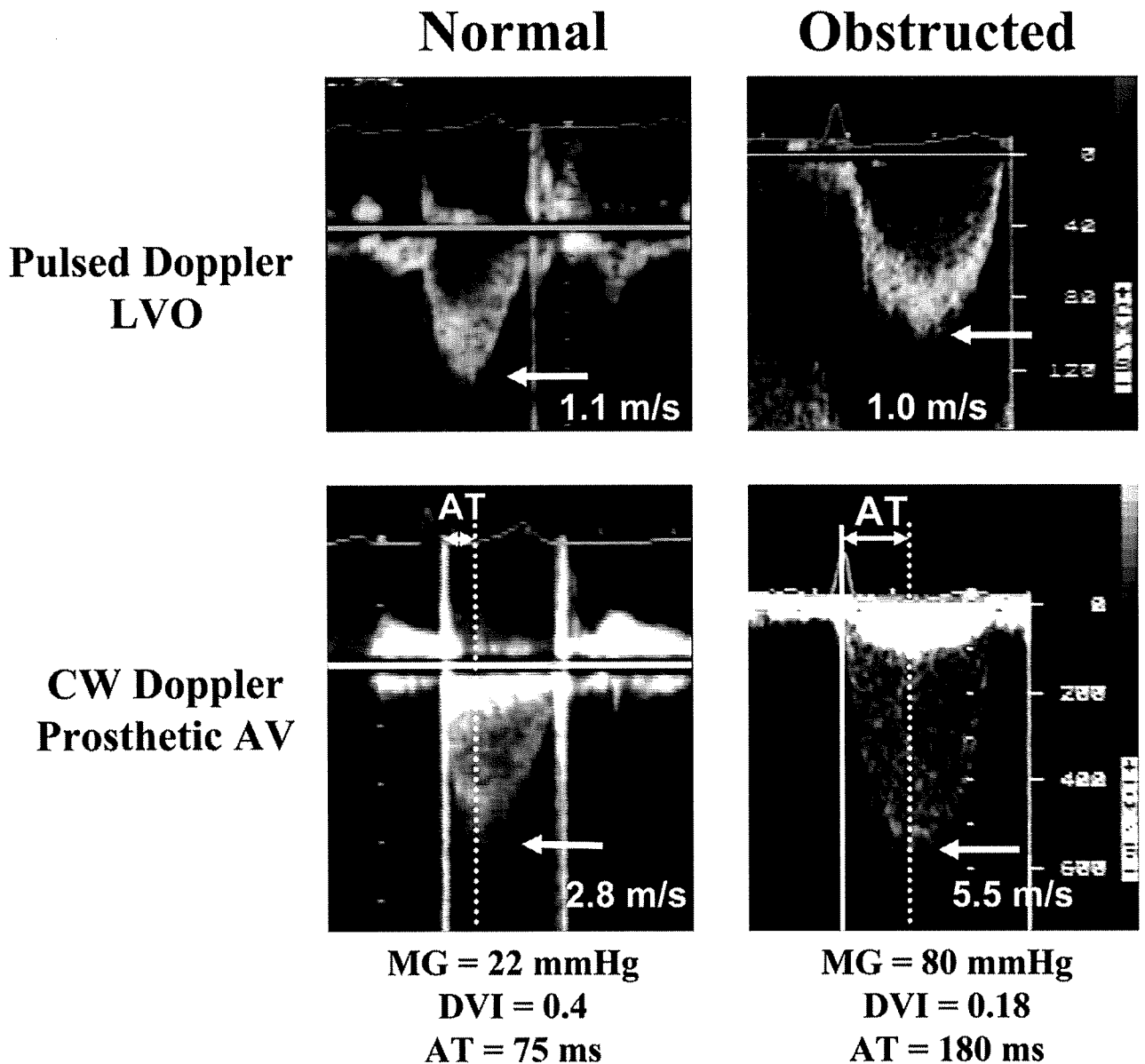


Figure 7 Doppler recordings of a normal and obstructed prosthetic valve in the aortic position. With obstruction, the velocity of the jet is increased along with changes in the contour of the jet velocity to that of a parabolic, late peaking profile. The ET as well as the AT is increased. AT (in milliseconds) is measured as the duration from the onset of aortic ejection (solid line) to the maximal jet velocity (dotted line). Mean gradient (MG) is increased and the DVI is decreased with prosthetic obstruction.

There is significant variability in quantitative parameters of valve function because of different valve types and sizes. Individual valve parameters of velocity, gradients, and EOAs for various valve types and sizes in the aortic position are listed in Appendix A.¹²⁶ While recognizing these differences, the writing group has provided general guidelines regarding parameters that should be measured and evaluated to assess aortic valve function. Table 5 offers a general guide to collective normal values, intermediate values for which stenosis may be possible, and values that usually suggest obstruction in prosthetic aortic valves under normal or nearly normal cardiac output conditions. These in general apply to most prosthetic valves and exclude homografts, stentless valves, and percutaneous prostheses, because the latter have flow dynamics that are close to native valves.

In the presence of any abnormality of these parameters, a systematic assessment of the findings should be performed. The algorithm in

Figure 10 proposes an approach to the evaluation of valves with an elevated peak velocity >3.0 m/s. A DVI is calculated and its value integrated with information from the contour of the jet velocity. If the DVI is >0.25 and the jet shows early peaking of the velocity (AT < 100 ms),^{119,121} most likely, the valve is normal, particularly if the other quantitative parameters fall in the normal or intermediate range (Table 5). In this case, the high velocity is most likely because of high flow, PPM, or pressure recovery from a bileaflet or caged-ball valve. Obstruction of the valve starts to be suspected when the DVI is <0.30 and is highly suggested if the DVI is <0.25 and the jet has a rounded contour, with late peaking of the velocity (AT > 100 ms). The more abnormal the quantitative parameters, the more certainty there is regarding prosthetic obstruction.

In cases of discordance between information from the DVI and contour of the jet, considerations should be given to either valvular

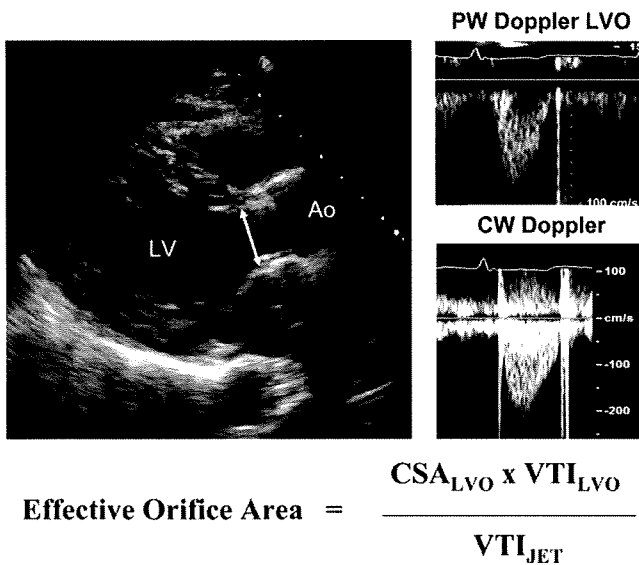


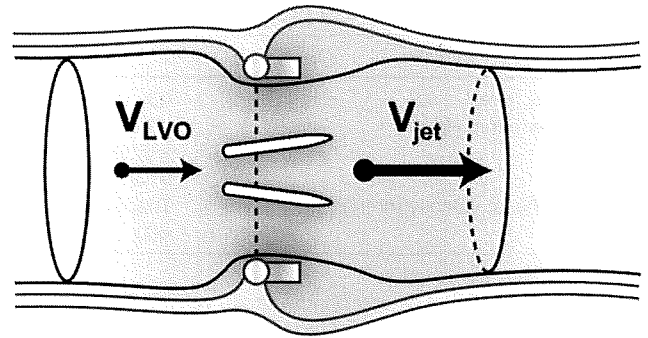
Figure 8 Derivation of EOA of a prosthetic valve in the aortic position by Doppler echocardiography. The diameter of the LVO tract, just below the insertion of the prosthetic aortic valve, is shown. Note that the tip of the anterior arrow is at the junction of sewing ring and ventricular septum, and the tip of the posterior arrow is at the junction (pivot point) between the sewing ring and the base of the anterior mitral leaflet. Once the diameter has been measured, pulsed Doppler in the LVO tract from the apical window combined with CW Doppler recording is used to complete the data acquisition for EOA calculation. CSA, Cross-sectional area derived from diameter measurement assuming a circular geometry.

dysfunction or technical issues. In a normal DVI of >0.30 but a rounded contour and an AT > 100 ms, prosthetic stenosis should be considered, the reason for the elevated LVO velocity being either improper position of PW Doppler sample volume (too close to the valve, causing high velocity recording in the LVO) or subvalvular narrowing. Alternatively, the gradient through the prosthesis may be underestimated by improper CW Doppler recording because of problems of angulation of ultrasound with the stenotic jet. In the converse situation of a low DVI (<0.25) and a normal contour of the jet and an AT < 100 ms, an improper LVO velocity recording is most likely the situation (sample volume position too far apical from the prosthesis).

If the diagnosis of valve obstruction is in question, confirmation of the abnormality in valve motion is undertaken with TEE and/or fluoroscopy or CT. Although TEE can help evaluate complications of a valve, such as dehiscence, endocarditis, or thrombus formation, leaflet mobility in the aortic position is not optimally assessed with TEE in mechanical valves. In the latter situation, fluoroscopy and CT are very helpful to visualize mobility of the occluder.

B. Prosthetic Aortic Valve Regurgitation

1. Imaging Considerations. TTE is useful to identify the presence of both paravalvular and intravalvular prosthetic AR. Acoustic shadowing, so problematic with mitral prostheses, is less of an issue for prosthetic AR (Figure 4). The optimal views for the detection of regurgitant jets include the parasternal long-axis and short-axis views, the apical long-axis view, and the 5-chamber view. Off-axis views may be helpful in localizing regurgitant jets and determining their origin.



$$\text{Doppler Velocity Index} = \frac{\text{Velocity}_{\text{LVO}}}{\text{Velocity}_{\text{jet}}}$$

Figure 9 Schematic representation of the concept of the DVI. Velocity across the prosthesis is accelerated through the jet from the LVO tract. DVI is the ratio velocity in the LVO (V_{LVO}) to that of the jet (V_{jet}).

In the parasternal short-axis view, color flow Doppler interrogation of the sewing ring may be able to localize and define the extent of a perivalvular leak. However, in this view, acoustic shadowing may obscure jets in the region of the noncoronary sinus.

2. Doppler Evaluation of Severity of Prosthetic AR. Few studies have attempted to quantitate the severity of prosthetic AR.¹²⁷ Rallidis et al¹²⁷ classified mild AR as a narrow turbulent jet, with a ratio of jet diameter/LVO diameter of $<25\%$. Broader jets were classified as moderate or severe, depending on other criteria, such as the pressure half-time or the presence of holodiastolic flow reversal in the descending aorta.¹²⁷ The integrative approach recommended for native aortic valve regurgitation should be applied to prosthetic AR, with several caveats and modifications¹⁶ (Table 6), as noted below.

a. **Color Doppler.** With color Doppler, an evaluation of the components of the color AR jet (flow convergence, vena contracta, and extent in the LVO and left ventricle), its origin, and its direction is necessary for an accurate evaluation. Normal “physiologic” jets will usually be low in momentum, as shown by homogeneous color jets that are small in extent. The ratios of jet diameter/LVO diameter from parasternal long-axis imaging and jet area/LVO area from parasternal short-axis imaging of the LVO just below the prosthesis, as parameters of AR severity, are best applied in central jets. In certain instances, acoustic shadowing directly below the valve may obscure accurate measurement of jet width in the LVO. As AR jets may often be eccentric, measurement of the jet width perpendicular to the LVO tract will cut the jet obliquely and risk overestimation (Figure 11). Last, and similar to native AR, entrainment of the jet in the LVO tract may lead to rapid broadening of the jet just after the vena contracta and thus to overestimation of regurgitant severity. Conversely, jets of significant AR may be so eccentric as to impinge on the wall of the LVO or anterior mitral valve and be less impressive on color Doppler. In these instances, integration of the evaluation by other Doppler parameters is necessary.

In contrast to native valves, the width of the vena contracta, as a parameter of AR severity, may be difficult to accurately measure in the long axis in the presence of a prosthesis. Careful imaging of the neck of the jet in a short-axis view, at the level of the prosthesis sewing ring, allows determination of the circumferential extent of the

Table 5 Doppler parameters of prosthetic aortic valve function in mechanical and stented biologic valves*

Parameter	Normal	Possible stenosis	Suggests significant stenosis
Peak velocity (m/s) [†]	<3	3-4	>4
Mean gradient (mm Hg) [†]	<20	20-35	>35
DVI	≥0.30	0.29-0.25	<0.25
EOA (cm ²)	>1.2	1.2-0.8	<0.8
Contour of the jet velocity through the PrAV	Triangular, early peaking	Triangular to intermediate	Rounded, symmetrical contour
AT (ms)	<80	80-100	>100

PrAV, Prosthetic aortic valve.

*In conditions of normal or near normal stroke volume (50-70 mL) through the aortic valve.

†These parameters are more affected by flow, including concomitant AR.

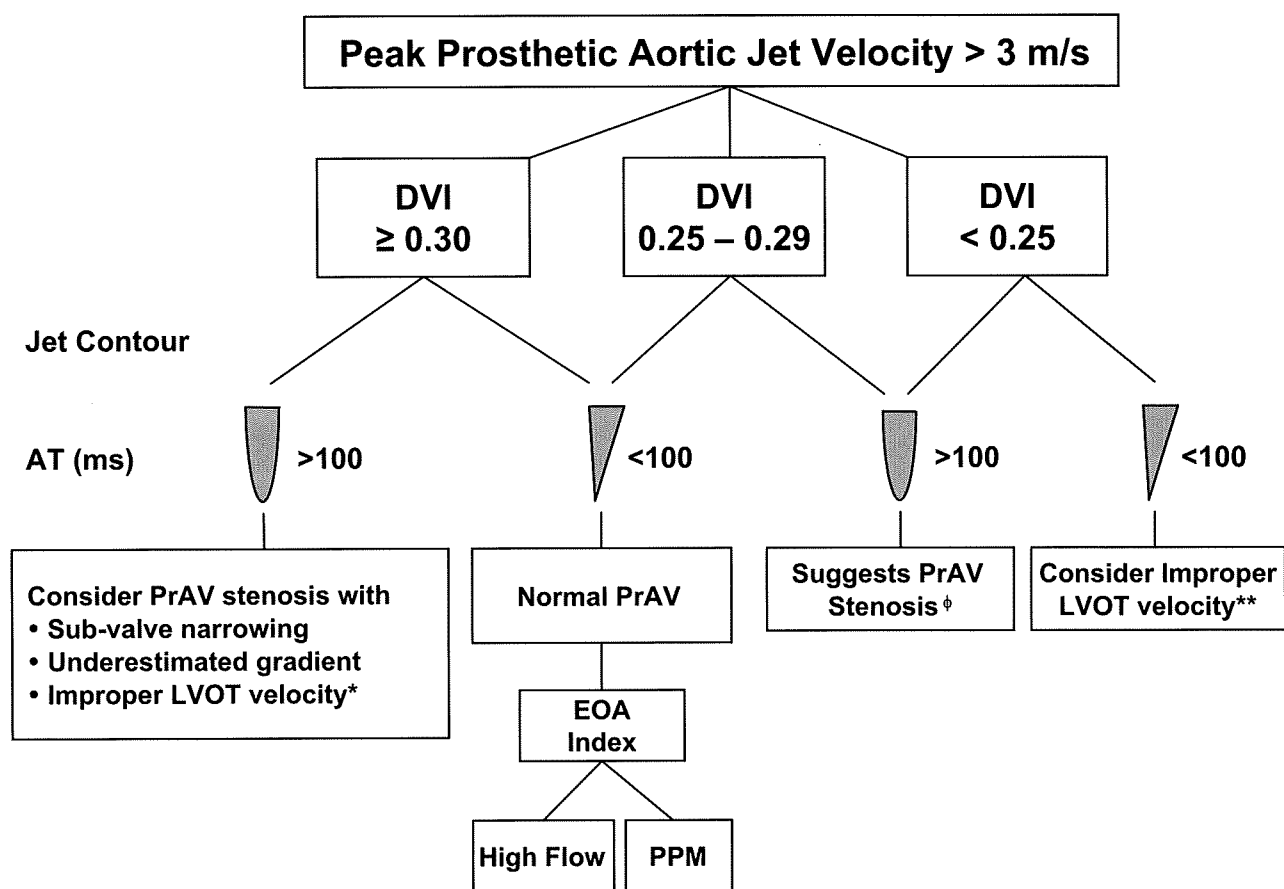


Figure 10 Algorithm for evaluation of elevated peak prosthetic aortic jet velocity incorporating DVI, jet contour, and AT. *PW Doppler sample too close to the valve (particularly when jet velocity by CW Doppler is ≥ 4 m/s). **PW Doppler sample too far (apical) from the valve (particularly when jet velocity is 3-3.9 m/s). ϕ Stenosis further substantiated by EOA derivation compared with reference values if valve type and size are known. Fluoroscopy and TEE are helpful for further assessment, particularly in bileaflet valves. AVR, Aortic valve replacement.

regurgitation in the case of paravalvular regurgitation as a semiquantitative measure of severity. As an approximate guide, <10% of the sewing ring suggests mild, 10% to 20% suggests moderate, and >20% suggests severe. Rocking of the prosthesis is usually associated with >40% dehiscence.¹²

b. Spectral Doppler. Semiquantitative and quantitative methods that are not influenced by the presence of the prosthesis should also be used in assessing AR severity. The pressure half-time is useful when the value is <200 ms, suggesting severe regurgitation, or >500 ms, consistent with mild regurgitation. However, intermediate ranges

of pressure half-time (200-500 ms) may reflect other hemodynamic variables such as LV compliance and are less specific.¹⁶ The presence of holodiastolic flow reversal in the descending thoracic aorta is indicative of at least moderate AR; severe AR is suspected when the VTI of the reverse flow approximates that of the forward flow (Figure 11). Holodiastolic flow reversal in the abdominal aorta is usually indicative of severe AR. Regurgitant volume can be calculated as the difference between stroke volume at the LVO (or 2D-derived total LV stroke volume) and the transmitral or pulmonary flow. Cut points for severity are similar to those for AR of native valves.¹⁶ Care should be exercised in measuring the flow integral in the LVO tract. When the sample volume