

the lateral SNs, LPLD was performed prophylactically. Of the three patients who had a tumor-negative SN, all of the dissected lateral non-SNs were negative in the three patients. Therefore, in patients with tumor-negative lateral SNs, the negative predictive value was 100% (three of three), and concordance was observed between the lateral SNs and the dissected lateral LN status in six (100%) of the six patients. The false-negative rate was 0% (zero of three).

In 2 of 25 patients, LPLD was performed prophylactically because we could not detect the lateral SNs. However, no tumor-positive LNs were detected in the dissected lateral LNs. In total, LPLD was performed in eight patients. However, 17 patients underwent a rectal resection without LPLD.

DISCUSSION

One of the most common sites of recurrence after a curative resection of rectal cancer is the pelvis, and local control is a major goal of surgical treatment. Several trials comparing LPLD with preoperative chemoradiotherapy found no differences in either locoregional recurrence or survival, but genitourinary dysfunction was observed to increase in the LPLD group.^{5,21-24} Kusters et al. reported that both extended surgery and preoperative radiotherapy plus total mesorectal excision (TME) resulted in good local control, as compared with TME alone.²⁵ Kim et al. reported that postoperative chemoradiotherapy and LPLD after TME resulted in comparable survival rates, but the locoregional recurrence rate was higher in the LPLD group.²⁶ Recently, Kim et al. reported lateral lymph node metastasis to be a major cause of locoregional recurrence in rectal cancer treated with preoperative chemoradiotherapy and a curative resection.²⁷ In the context of clinically suspected lateral lymph nodes disease, the dissection should be attempted to remove these nodes, if it is technically feasible.²⁸ For that reason, the significance of LPLD is controversial. If the lateral SNs to which the fluid first spread from the primary lower rectal cancer are detected accurately, then this may indicate the need for LPLD.

Although ICG was initially developed as a test drug for the liver and circulatory function, it has also been used for lymphography, angiography, and SN detection because ICG is a popular diagnostic and readily available reagent.^{12,29-33} Moreover, the ICG method is convenient and safe compared with the radioisotope method.¹⁷ The avoidance of radioisotope is also beneficial, especially at institutes where the use of radioisotopes is limited.

The clinical applicability of SN navigation surgery (SNNS) has been extensively investigated in gastrointestinal tract cancer.¹²⁻¹⁵ The usefulness of dye-guided SN detection in colon cancer has already been reported.³⁴

These studies have shown the high efficacy (70% to 99%) of analysis of the SN. However, there are few reports about the lateral SN in rectal cancer. Recently, Kawahara et al. reported the initial lateral pelvic LN assessment for lower rectal cancer by infrared ray electronic endoscopy (IREE) with ICG.³⁵ However, their detection rate of SN was not as high (43%, 6 of 14). Detection by absorption spectroscopy is more sensitive than color perception, and some surgeons have also reported that IREE with ICG injection is useful for SNs detection.^{36,37} However, Ishikawa et al., using the IREE system, reported an obese patient with a falsely negative SN by laparoscopic SN navigation, even though infrared rays can penetrate fatty tissues up to a depth of 3 mm.³⁷ Kitai et al. noted, in their preliminary report of ICG fluorescence imaging in breast cancer surgery, that the sensitivity of fluorescence spectroscopy is much greater than that of absorption spectroscopy.³⁸ They also reported that fluorescence was observed from an ICG solution embedded 1 cm deep in the material with optical properties compatible to human tissue in a preliminary study that used a phantom.³⁸ Similarly, Miyashiro et al. recently reported that the sensitivity of ICG fluorescence imaging seems to be much greater than that of infrared ray imaging.¹⁷ In fact, our detection rate of lateral SN by PDE was 2.1 times greater (92% vs. 43%) compared with Kawahara's result.³⁵

In our previous study, the lateral SNs for lower rectal cancer were investigated by means of ICG with examination by the naked eye. However, the lateral SNs were identified in only 7 (28%) of 25 patients.³⁹ Because the previous detection rate was so low, it was hard to use this method in clinical practice. In this study, a PDE was able to detect the lateral SNs for lower rectal cancer, thereby improving the detection rate of SNs. The success rate of detecting the lateral SNs by means of ICG with PDE was 92%. The detection rate of SNs with PDE was 3.3 times greater in comparison to naked eye examination. The detection rate of lateral SNs in the current study was 100% in all T1 and T2 (N = 6) disease. Even in T3 (N = 19) disease, the detection rate was 89.5%. Because of the high sensitivity of PDE, not only tumor-negative SNs but also tumor-positive SNs could be clearly detected with PDE. The patients who did not have LPLD might have had lateral lymph node metastasis, although extensive preoperative and intraoperative palpation and inspection for such spread is undertaken at this hospital, and therefore, the incidence is thought to be low.

In this study, the incidence of tumor-positive SNs was 13% (3 of 23). This incidence is approximately the same as the incidence of lateral LN metastasis in patients with advanced lower rectal cancer.^{6,7,9} The lateral SNs could not be detected in two cases (11%) of the T3 disease. However, these two cases occurred in the early period after the introduction of this treatment method. After the fifth case,

the detection rate of the lateral SNs was 100% even in T3 disease.

Although further studies of larger population samples are necessary, the dye-guided method using an ICG fluorescent imaging system is nevertheless considered to be a potentially safer, more convenient, and more cost-effective replacement of the radio-guided system. In the current study, the negative predictive value was 100%, and concordance was observed between the lateral SNs and dissected lateral LN status in 100%. The false-negative rate was 0%. The system is therefore considered to be a feasible technique that makes dye-guided lateral SNB in lower rectal cancer surgery easier, and also possibly shortens the learning curve.

ACKNOWLEDGMENT This study was supported in part by the Public Trust Surgery Research Fund.

REFERENCES

- Gerota D. Die Lymphgefäße des Rectums und des Anus. *Arch Anat Physiol Anat Abt.* 1895;240–56.
- Blair JB, Holyoke EA, Best RR. A note on the lymphatics of the middle and lower rectum and anus. *Anat Rec.* 1950;108:635–44.
- Stearns MW Jr, Deddish MR. Five-year results of abdominopelvic lymph node dissection for carcinoma of the rectum. *Dis Colon Rectum.* 1959;2:169–72.
- Suzuki K, Muto T, Sawada T. Prevention of local recurrence by extended lymphadenectomy for rectal cancer. *Surg Today.* 1995;25:795–801.
- Moriya Y, Sugihara K, Akasu T, Fujita S. Patterns of recurrence after nerve-sparing surgery for rectal adenocarcinoma with special reference to loco-regional recurrence. *Dis Colon Rectum.* 1995;38:1162–8.
- Mori T, Takahashi K, Yasuno M. Radical resection with autonomic nerve preservation and lymph node dissection techniques in lower rectal cancer surgery and its results: the impact of lateral lymph node dissection. *Langenbecks Arch Surg.* 1998;383:409–15.
- Moriya Y, Hojo K, Sawada T, Koyama Y. Significance of lateral node dissection for advanced rectal carcinoma at or below the peritoneal reflection. *Dis Colon Rectum.* 1989;32:307–15.
- Fujita S, Yamamoto S, Akasu T, Moriya Y. Lateral pelvic lymph node dissection for advanced lower rectal cancer. *Br J Surg.* 2003;90:1580–5.
- Ueno H, Mochizuki H, Hashiguchi Y, et al. Potential prognostic benefit of lateral pelvic node dissection for rectal cancer located below the peritoneal reflection. *Ann Surg.* 2007;245:80–7.
- Giuliano AE, Kirgan DM, Guenther JM, Morton DL. Lymphatic mapping and sentinel lymphadenectomy for breast cancer. *Ann Surg.* 1994;220:391–8.
- Veronesi U, Paganelli G, Galimberti V, et al. Sentinel-node biopsy to avoid axillary dissection in breast cancer with clinically negative lymph-nodes. *Lancet.* 1997;349(9069):1864–7.
- Hiratsuka M, Miyashiro I, Ishikawa O, et al. Application of sentinel node biopsy to gastric cancer surgery. *Surgery.* 2001;129:335–40.
- Saha S, Wiese D, Badin J, et al. Technical details of sentinel lymph node mapping in colorectal cancer and its impact on staging. *Ann Surg Oncol.* 2000;7:120–4.
- Joosten JJ, Strobbe LJ, Wauters CA, et al. Intraoperative lymphatic mapping and the sentinel node concept in colorectal carcinoma. *Br J Surg.* 1999;86:482–6.
- Kitagawa Y, Fujii H, Kumai K, et al. Recent advances in sentinel node navigation for gastric cancer: a paradigm shift of surgical management. *J Surg Oncol.* 2005;90:147–51.
- Saha S, Dan AG, Bilchik AJ, et al. Historical review of lymphatic mapping in gastrointestinal malignancies. *Ann Surg Oncol.* 2004;11(3 Suppl):245S–9S.
- Miyashiro I, Miyoshi N, Hiratsuka M, et al. Detection of sentinel node in gastric cancer surgery by indocyanine green fluorescence imaging: comparison with infrared imaging. *Ann Surg Oncol.* 2008;15:1640–3.
- Tajima Y, Yamazaki K, Masuda Y, et al. Sentinel node mapping guided by indocyanine green fluorescence imaging in gastric cancer. *Ann Surg.* 2009;249:58–62.
- Sobin LH, Wittekind C. TNM classification of malignant tumors. 6th edn. New York: Wiley-Liss; 2002.
- Japanese Society for Cancer of the Colon and Rectum. Japanese classification of colorectal carcinoma. First English edn. Tokyo: Kanehara; 1997.
- Pilipshen SJ, Heilweil M, Quan SH, et al. Patterns of pelvic recurrence following definitive resections of rectal cancer. *Cancer.* 1984;53:1354–62.
- Kobayashi H, Mochizuki H, Sugihara K, et al. Characteristics of recurrence and surveillance tools after curative resection for colorectal cancer: a multicenter study. *Surgery.* 2007;141:67–75.
- Nagawa H, Muto T, Sunouchi K, et al. Randomized, controlled trial of lateral node dissection vs. nerve-preserving resection in patients with rectal cancer after preoperative radiotherapy. *Dis Colon Rectum.* 2001;44:1274–80.
- Watanabe T, Tsurita G, Muto T, et al. Extended lymphadenectomy and preoperative radiotherapy for lower rectal cancers. *Surgery.* 2002;132:27–33.
- Kusters M, Beets GL, van de Velde CJ, et al. A comparison between the treatment of low rectal cancer in Japan and the Netherlands, focusing on the patterns of local recurrence. *Ann Surg.* 2009;249:229–35.
- Kim JC, Takahashi K, Yu CS, et al. Comparative outcome between chemoradiotherapy and lateral pelvic lymph node dissection following total mesorectal excision in rectal cancer. *Ann Surg.* 2007;246:754–62.
- Kim TH, Jeong SY, Choi DH, et al. Lateral lymph node metastasis is a major cause of locoregional recurrence in rectal cancer treated with preoperative chemoradiotherapy and curative resection. *Ann Surg Oncol.* 2008;15:729–37.
- Nelson H, Petrelli N, Carlin A, et al. Guidelines 2000 for colon and rectal cancer surgery. *J Natl Cancer Inst.* 2001;93:583–96.
- Caesar J, Shaldon S, Chiandussi L, et al. The use of indocyanine green in the measurement of hepatic blood flow and as a test of hepatic function. *Clin Sci.* 1961;21:43–57.
- Cherrick GR, Stein SW, Leevy CM, Davidson CS. Indocyanine green: observations on its physical properties, plasma decay, and hepatic extraction. *J Clin Invest.* 1960;39:592–600.
- Unno N, Inuzuka K, Suzuki M, et al. Preliminary experience with a novel fluorescence lymphography using indocyanine green in patients with secondary lymphedema. *J Vasc Surg.* 2007;45:1016–21.
- Unno N, Suzuki M, Yamamoto N, et al. Indocyanine green fluorescence angiography for intraoperative assessment of blood flow: a feasibility study. *Eur J Vasc Endovasc Surg.* 2008;35:205–7.
- Motomura K, Inaji H, Komoike Y, et al. Sentinel node biopsy guided by indocyanine green dye in breast cancer patients. *Jpn J Clin Oncol.* 1999;29:604–7.

34. Saha S, Nora D, Wong JH, Weise D. Sentinel lymph node mapping in colorectal cancer—a review. *Surg Clin North Am.* 2000;80:1811–9.
35. Kawahara H, Nimura H, Watanabe K, et al. Where does the first lateral pelvic lymph node receive drainage from? *Dig Surg.* 2007;24:413–7.
36. Nimura H, Narimiya N, Mitsumori N, et al. Infrared ray electronic endoscopy combined with indocyanine green injection for detection of sentinel nodes of patients with gastric cancer. *Br J Surg.* 2004;91:575–9.
37. Ishikawa K, Yasuda K, Shiromizu A, et al. Laparoscopic sentinel node navigation achieved by infrared ray electronic endoscopy system in patients with gastric cancer. *Surg Endosc.* 2007;21:1131–4.
38. Kitai T, Inomoto T, Miwa M, Shikayama T. Fluorescence navigation with indocyanine green for detecting sentinel lymph nodes in breast cancer. *Breast Cancer.* 2005;12:211–5.
39. Noura S, Ohue M, Seki Y, et al. Evaluation of the lateral sentinel node by indocyanine green for rectal cancer based on micrometastasis determined by reverse transcriptase–polymerase chain reaction. *Oncol Rep.* 2008;20:745–50.

Histopathologic Tumor Spread in Very Low Rectal Cancer Treated with Abdominoperineal Resection

Kazuo Shirouzu, M.D., Ph.D. • Yutaka Ogata, M.D., Ph.D.

Department of Surgery, Kurume University Faculty of Medicine, Kurume, Fukuoka, Japan

PURPOSE: We have pathologically evaluated the tumor spread in low rectal cancer treated with abdominoperineal resection to clarify the potential indication of intersphincteric resection and other anus-preserving operations with external sphincter muscle resection.

METHODS: A total of 197 patients received abdominoperineal resection between 1982 and 2001. We determined histopathologically any invasion or metastasis into the anal canal structures.

RESULTS: When the lowest edge of a tumor was located above the dentate line, the invasion was rarely beyond the internal sphincter muscle, in particular, where the distance between the tumor and the dentate line was longer than 2 cm. When the lowest edge was located at or below the dentate line (Pb-cancer), invasion tended to extend into the external sphincter muscle and into the intermuscular groove. A logistic regression analysis showed that the Pb-cancer, any distant metastasis, and the tumor histology of mucinous carcinoma were each an independent significant risk factor to invasion beyond the internal sphincter muscle, whereas the Pb-cancer, the poorly differentiated adenocarcinoma, and the mucinous carcinoma were each an independent significant risk factor to invasion into the intermuscular groove.

CONCLUSION: The anus-preserving operation with sphincter muscle resection was theoretically possible for low rectal cancer in patients who underwent abdominoperineal resection. However, the procedure cannot be indicated for a tumor where the lowest edge is

below the dentate line and where a preoperative biopsy shows a poorly differentiated adenocarcinoma or mucinous carcinoma, even if the intermuscular groove is macroscopically unaffected by the tumor.

KEY WORDS: Rectal cancer; Anus-preserving operation; Intersphincteric resection; Histopathologic tumor spread.

An abdominoperineal resection (APR) removes all the anal canal structures and creates a permanent colostoma. With the increasing use of autosuture devices, the standard anus-preserving operation, such as low (or ultralow) anterior resection and conventional coloanal anastomosis, has now become common for treating a low rectal cancer.¹⁻³ However, for a low rectal cancer extremely close to the anus and for anal canal cancer, an APR is generally performed. It has been technically difficult to salvage the anus by preserving the sphincter muscles in such cases. Recently, a new anus-preserving operation, which resects the internal sphincter muscle for a low rectal cancer extremely close to the anus, is becoming increasingly popular in Europe and Japan.⁴⁻¹² The authors have previously reported two new anus-preserving surgical methods.¹⁰ One surgical method is an intersphincteric resection (ISR), which salvages the anus by preserving all of the external sphincter muscles; this is similar to the methods reported by some European surgeons.⁴⁻⁹ Another surgical method is an external sphincter resection (ESR), which salvages the anus by means of preserving only the subcutaneous external sphincter muscle. ESR is our original method. Because of the introduction of these methods, the performance of APR has dramatically decreased to only a few patients a year in our department. However, the theoretical evidence justifying the use of this operation has not yet been reported. We have therefore examined pathologically the invasion and/or metastasis into the anal canal structures in the surgical specimens after APR. We have clarified the potential of the new anus-preserving operations, and here report the indications for ISR and ESR, respectively, for very low rectal cancer.

Supported in part by a Grant-in Aid for Cancer Research from the Ministry of Health, Labor and Welfare (Saito Research Group).

Address of correspondence: Kazuo Shirouzu, M.D., Ph.D., 67 Asahimachi, Kurume, Fukuoka 830-0011, Japan. E-mail: drkshirouzu@ktarn.or.jp

Dis Colon Rectum 2009; 52: 1887-1894
DOI: 10.1007/DCR.0b013e3181b1585a
©The ASCRS 2009

DISEASES OF THE COLON & RECTUM VOLUME 52: 11 (2009)

1887




FIGURE 1. Preparing specimens and making a pathologic diagnosis. A. Whole tumor mass was sliced into 5-mm-step sections. B. Each section consisted of a full thickness of the intestinal wall containing extramural fatty tissue. C. Many pathologic findings in each case have been sketched on ISO B4 paper in detail.

PATIENTS AND METHODS

Patient

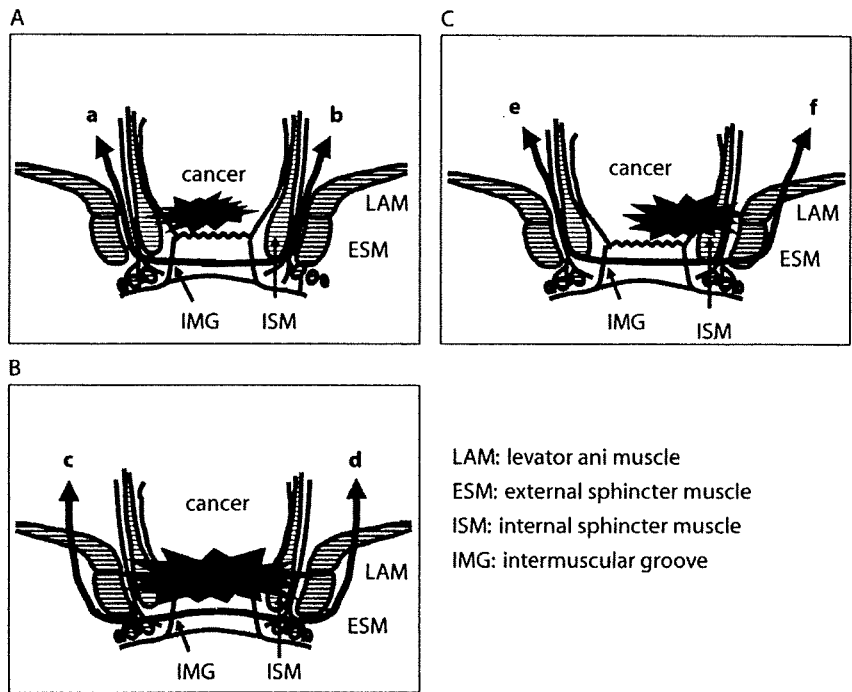
A total of 214 patients with low rectal cancer (adenocarcinoma) underwent APR between 1982 and 2001 at the Kurume University Hospital. Preoperative chemoradiotherapy was performed in 17 patients with cT3 or cT4 tumor for tumor downstaging and prevention of local recurrence between 1986 and 1996. Another 197 patients without preoperative therapies such as radiotherapy and chemotherapy were enrolled in this retrospective study. Patients who underwent total pelvic exenteration or posterior pelvic exenteration were not eligible for this study. Their average age was 62 ± 10 (range, 29–76) years. Of the patients enrolled, 123 were male and 74 were female. The patients consisted of 34 patients at Stage I, 58 patients at Stage II, 66 patients at Stage III, and 39 patients at Stage IV. The accurate distance from the anal verge to the lowest edge of the tumor was measured by use of rigid proctoscopy before the operation. The mean distance from the anal verge to the tumor was 3.2 ± 1.8 (range, 0–10 cm) cm.

All patients received surgical treatment based on the principles of total mesorectal excision with or without sacrificing the hypogastric nerve. The inferior mesenteric artery was doubly ligated and divided as it arises from the aorta. The mesenteric vein was also ligated and divided. The rectum was mobilized by sharp dissection and the visceral pelvic fascia, which enveloped the mesorectum, was separated from the parietal fascia overlying the pelvic cavity under direct vision. Perineal dissection was accom-

plished upward to the levator ani muscle. After dissection of the attachments of the rectum, the specimen was pulled down and delivered. In addition, in the cT3–4 tumor or the cN(+) tumor, lateral pelvic lymphadenectomy belonging to the internal iliac vessels was applied for control of intrapelvic recurrence. The tumor histologically invaded into the adjacent organs such as the vagina, bladder, seminal vesicle, prostate, sacrum, coccyx, and/or the anal canal structure in 49 patients (pT4). The patients with cT4 tumor underwent partial resection of the organs involved, whereas positive radial (circumferential) resection margin or incomplete resection was noted in 10 of 49 patients with pT4 tumor. Another six patients with pT3 tumor also had a positive radial resection margin. However, no positive radial resection margin at the level of the anal canal and the perineum was found.

Preparing Specimens

As we previously reported,^{13–17} each surgical specimen was pinned under tension onto a wooden board so that it conformed to the same dimensions as observed in life, and then was fixed initially in 20% formalin. After one week of fixation in formalin, the whole tumor mass was sliced into longitudinal serial step sections measuring 5 mm in thickness (Fig. 1A). Each section consisted of a full thickness of the intestinal wall containing extramural fatty tissue (Fig. 1B). These sections were dehydrated by alcohol for one week and then embedded in paraffin. Next, thin sections



LAM: levator ani muscle
 ESM: external sphincter muscle
 ISM: internal sphincter muscle
 IMG: intermuscular groove

FIGURE 2. A schematic drawing of the resection line. A. The resection line a-b represents ISR, which removes the internal sphincter muscles, and preserves all the external sphincter muscles. B. The resection line c-d represents extended ESR, which removes the internal sphincter muscles and the external sphincter muscles, and preserves only the subcutaneous external sphincter muscles. C. The resection line e-f represents unilateral ESR, which removes the internal sphincter muscles and external sphincter muscles for the same side of the tumor, and preserves the external sphincter muscles for the opposite side of the tumor. ISR = intersphincteric resection; ESR = external sphincter resection; LAM = levator ani muscle; ESM = external sphincter muscle; ISM = internal sphincter muscle; IMG = intermuscular groove.

measuring about 5- μ m thickness were sliced from the paraffin-embedded blocks by use of a microtome. These were mounted on glass slides, and stained with hematoxylin-eosin and elastica van Gieson.

Pathologic Diagnosis

Since 1982, one of the authors (KS) has sketched the pathologic findings on ISO B4 paper in detail (Fig. 1C). Tumor histology was classified into five categories: well differentiated adenocarcinoma, moderately differentiated adenocarcinoma, poorly differentiated adenocarcinoma, mucinous carcinoma, and signet-ring cell carcinoma. The category was defined by a dominant histologic type. The tumor location was divided into three categories. When the distance between the lowest edge of the tumor and the dentate line was longer than 2 cm, the category was considered to belong to the R-cancer group. When the lowest edge of the tumor was located in the anal canal and above the dentate line, the category was considered to belong to the Pa-cancer group, and when it was located at or below the dentate line, the category belonged to the Pb-cancer group. The extent of any invasion or metastasis into the anal canal structures, consisting of the levator ani muscle, internal or external sphincter muscles, intermuscular

groove, and ischioanal fossa's fatty tissue, was determined.

Registry of the Data and Clinical Stage

Our computer registration system was set up in 1982 by use of a database (dBASE™ III software, Ashton-Tate, Torrance, CA). Both the clinical information and the pathologic findings of resected specimens have been prospectively registered in detail in the database, as we reported previously.¹³⁻¹⁷ Since 1995, we have used the Visual dBASE™ software program for Windows (Visual dBASE™ version 5.6J, Borland, Austin, TX). After the final pathologic diagnosis was made, the postoperative clinical stage was determined based on the TNM classification.¹⁸

Logistic Regression Analysis

Logistic regression multivariate analysis was performed to evaluate various clinicopathologic factors for their independent contribution to any invasion into the levator ani muscle, and/or deep-superficial external sphincter muscles, relating to the indication for ISR, and to any invasion into the subcutaneous external sphincter muscles, the intermuscular groove, and/or the ischioanal fossa's fatty

TABLE 3. Logistic analyses for invasion into the subcutaneous external sphincter muscles, the intermuscular groove, and the ischio-rectal fossa's fatty tissue

Variable	P value	Odds ratio	95% Confidence interval
Pa-cancer or Pb-cancer			
Pb-cancer	0.021	13.85	1.48–130.02
Poor	0.021	10.01	1.41–71.14
Muc	0.044	4.33	1.04–17.86

Pa-cancer = the lowest edge of the tumor is located in the anal canal and is above the dentate line; Pb-cancer = the lowest edge of the tumor is located in the anal canal and is at or below the dentate line; Poor = poorly differentiated adenocarcinoma or signet-ring cell carcinoma; Muc = mucinous carcinoma including signet-ring cell carcinoma.

Logistic Regression Analysis for Invasion Into the Subcutaneous External Sphincter Muscles, the Intermuscular Groove, and the Ischio-rectal Fossa's Fatty Tissue

The tumor location (Pa vs. Pb), tumor histology (poorly differentiated adenocarcinoma or signet ring cell carcinoma vs. others; mucinous carcinoma including signet cell carcinoma vs. others), distant metastasis, and the anal spread of tumor were evaluated for their independent contribution to any invasion into the subcutaneous external sphincter muscles, the intermuscular groove, and/or the ischio-rectal fossa's fatty tissue by use of logistic regression analysis. The analysis among the P-cancers revealed that the Pb-cancer, the poorly differentiated adenocarcinoma, and the mucinous carcinoma were each an independent significant factor. The Pb-cancer had the highest odds ratio for the invasion into the subcutaneous external sphincter muscles, the intermuscular groove, and/or the ischio-rectal fossa's fatty tissue (Table 3).

Possible Tumor Clearance by ISR and/or ESR

The complete series of 197 patients was examined pathologically to clarify the possibility of anus preservation. Based on the findings of our pathologic study, in most patients who underwent APR, the tumor could be removed by ISR or ESR and be free from cancer cells at the surgical margin of the anal canal (resection margin > 0 mm). Among 75 patients with R-cancer, 73 patients (97.3%) had no invasion into the levator ani muscle, the deep-superficial external sphincter muscles, the intermuscular groove, or the subcutaneous external sphincter muscle; therefore, ISR could be indicated. For the other two patients with invasion into the levator ani muscle or the deep-superficial external sphincter muscles, unilateral ESR could be indicated.

Among 58 patients with Pa-cancer, for 52 patients (89.7%) without invasion beyond the internal sphincter muscle, ISR could be indicated. For another five patients (8.6%) with invasion into the levator ani muscle and/or the deep-superficial external sphincter muscles, unilateral ESR

could be indicated. For only one patient (1.7%) with invasion into the subcutaneous external sphincter muscle, in addition to the levator ani muscle and the deep-superficial external sphincter muscles, neither ISR nor ESR could be indicated.

Among 64 patients with Pb-cancer, for 33 patients (51.6%) without invasion beyond the internal sphincter muscle, ISR could be indicated. For 20 patients (31.3%) with invasion into the levator ani muscle and/or the deep-superficial sphincter muscles, unilateral ESR or extended ESR could be indicated. In the other 11 patients (17.2%) with invasion into the intermuscular groove, the subcutaneous external sphincter muscle, and/or ischio-rectal fossa's fatty tissue, no anus-preserving operation could make the resection margin free from cancer cells (Table 4).

DISCUSSION

It is extremely important to clarify the theoretical possibility of using ISR and ESR, and to pathologically demonstrate the surgical safety of the resection margins in each technique. According to our investigation of PubMed between 1990 and 2007, no large series of detailed pathologic studies based on the method of step sections of a whole tumor and the method of careful sketch diagnosis has ever been reported. The possibility of tumor clearance was examined in the present study for ESR; however, the validity of ESR should be verified from both oncologic and functional safety because there currently are no published data.

Based on our preparation methods, we examined the pathologic findings of a series of 197 patients that had received APR with no preoperative treatment. A sketch diagnosis and studying the whole tumor, including mesorectal fatty tissue, by step section methods gave us extremely detailed pathologic information regarding such factors as venous invasion, lymphatic permeation, lymph node metastasis, distal spread, and the status of the surgical resection margin. Miles¹⁹ previously pointed out that lymph node metastasis along the levator ani muscle or in the ischio-rectal fossa's fatty tissue was present. However, no such lymph node metastasis was detected in our study (data not shown). Therefore, the possibility of this new operation

TABLE 4. Possible tumor clearance by ISR or ESR

Procedure	R-cancer (n = 75)	Pa-cancer (n = 58)	Pb-cancer (n = 64)
ISR	73 (97.3)	52 (89.7)	33 (51.6)
ESR	2 (2.7)	5 (8.6)	20 (31.3)
No procedure except APR	0	1 (1.7)	11 (17.2)

R-cancer = distance between the lowest edge of tumor and the dentate line is more than 2 cm; Pa-cancer = lowest edge of the tumor is above the dentate line; Pb-cancer = lowest edge of the tumor is at or below the dentate line; ISR = Intersphincteric resection; ESR = external sphincter resection; APR, abdominoperineal resection. The values in parentheses are percentages.

can thus be theoretically considered from the viewpoint of a surgical resection margin.

For adequate application of ISR or ESR methods it is most important to determine any invasion into the anal canal structures preoperatively. Recently, some authors²⁰⁻²² have reported that magnetic resonance imaging was extremely valuable for predicting the extent of invasion into the anal canal structures, such as the external sphincter muscles. Moreover, careful digital examinations under anesthesia in the operating room seem to be more useful than any other diagnostic tools, as pointed out by Rullier *et al.*⁷ However, magnetic resonance imaging and digital examination seem to have less significance for diagnosis of microscopic tumor spread into the anal canal structures.

Goligher *et al.*²³ previously proposed a 5-cm rule for the distal resection margin, but recently, the length of the distal resection margin has become shorter. Some authors^{24,25} have reported that 1 to 2 cm may be sufficient. We have previously reported that the length of distal spread was less than 10 mm in most rectal cancers.¹⁶ Therefore, it might not be necessary to secure the distal resection margin at such a long length. After securing the distal resection margin of at least 1 cm, the anus-preserving operation with sphincter muscle resection is possible even in patients with a rectal cancer invading the anal canal structure. Regarding the radial resection margin, invasion into the levator ani and/or the external sphincter muscles was very rarely observed in the case of R-cancer. Holzer *et al.*²⁶ also reported that when the distance from the dentate line to the tumor was longer than 2 cm, there was no infiltration into the external sphincter muscle. He described that ISR could thus be performed in such cases as shown in Figure 2A. However, in the case of Pa-cancer or Pb-cancer, there might be a risk of residual cancer cells even if the internal sphincter muscle is removed by the ISR method. To make the radial resection margin free from cancer cells in such cases, the ESR method is thus needed (Fig. 2, B or C). A radical operation thus seems to be possible only by the ESR method. When the tumor is fortunately confined to the unilateral side with suspicion of invasion into the external sphincter muscle (the situation was seen in most tumors with invasion into the external sphincter muscles; data not shown), then ESR should be performed for the same side of the tumor, and ISR can be carefully applied for the opposite side of the tumor (Fig. 2C). The recent literature on APR from Europe^{27,28} has indicated that the radial resection margin on APR specimens is often positive. It has also been suggested that this radial resection margin positivity problem for APRs is the result of dissections that take place too close to the bowel wall, or even within the sphincter muscle, at the level of the anal canal. This situation would be similar for this new anus-preserving surgery, in particular, for ISR.

In addition, in the case of Pb-cancer, the intermuscular groove is often affected by the tumor. Therefore, another important point is the presence or absence of the tumor invasion into the intermuscular groove, because this new operation cuts the intermuscular groove open. Fortunately, the intermuscular groove can be detected by finger palpation, in particular, under anesthesia. Thus, it is easy to find whether or not the tumor macroscopically invades into the cut line on the intermuscular groove. When the tumor widely extends into the intermuscular groove, APR is necessary.

Statistically, the logistic regression analyses showed that the tumor location of Pb-cancer, extent of distant metastasis, and the tumor histology of mucinous carcinoma were each a significant risk factor for invasion into the levator ani and/or the deep-superficial external sphincter muscles. Taken together with the pathologic data, ISR can be indicated when the distance between the lowest edge of the tumor and the dentate line is longer than 2 cm. Even if the tumor invades into the anal canal, ISR can be indicated for a nonmucinous tumor without distant metastasis where the lowest edge is above the dentate line, after careful preoperative assessment of the T factor at the level of the anal canal. The logistic regression analysis also indicated that the Pb-cancer and the tumor histology of poorly differentiated adenocarcinoma or mucinous carcinoma were each a significant risk factor, suggesting invasion of the intermuscular groove, the subcutaneous external sphincter muscle, and/or ischioanal fossa's fatty tissue. It is suggested that no anus-preserving operation can be indicated for a tumor where the lowest edge is below the dentate line and where preoperative histology findings show a poorly differentiated adenocarcinoma or mucinous carcinoma, even if the intermuscular groove is macroscopically unaffected by the tumor.

In the present study, the patients who underwent preoperative radiotherapy were excluded. In general, in Europe and the United States preoperative chemoradiotherapy is applied for rectal cancer, and the radiotherapy may increase the chance of anus preservation in patients with large tumors or low rectal tumors.²⁹ Rullier *et al.*³⁰ reported that preoperative chemoradiotherapy induced significant tumor downstaging, including distal and radial (circumferential) margins in patients with a T3 carcinoma in the lower third of the rectum who underwent ISR. The achievement of distal and radial negative margins by preoperative chemoradiotherapy may allow not only a low local recurrence rate when ISR or ESR is indicated, but also an increase of the indication for ISR and ESR methods. Therefore, a similar pathologic investigation using specimens resected by APR with preoperative radiotherapy may be warranted.

In conclusion, the anus-preserving operation with sphincter muscle resection was theoretically possible for very low rectal cancer based on our pathologic findings in

patients who underwent APR. In the case of R-cancer the anus-preserving operation is possible with use of the ISR method. In the cases of Pa-cancer, the anus-preserving operation is possible with use of the ISR method in most patients having a nonmucinous tumor without distant metastasis after careful preoperative and intraoperative diagnosis of the T factor at the level of the anal canal. In the case of Pb-cancer, the anus-preserving operation can be performed successfully by the ISR or ESR method after an accurate preoperative and intraoperative diagnosis for invasion of the levator ani muscle, the external sphincter muscle, and the intermuscular groove. When invasion of the levator ani muscle and/or the deep-superficial external sphincter muscle is not suspected preoperatively and intraoperatively, ISR can be indicated. When tumor invades into the levator ani muscle and/or the deep-superficial external sphincter muscle, the anus-preserving operation is possible with use of the ESR method. For a tumor invading the external sphincter muscle or the intermuscular groove APR should be indicated. Moreover, the new anus-preserving operation cannot be indicated for a tumor if the preoperative biopsy shows a poorly differentiated adenocarcinoma or mucinous carcinoma, including signet cell carcinoma, even if the intermuscular groove is macroscopically unaffected by the tumor. As a result, APR may henceforth be considered as necessary only rarely.

REFERENCES

1. McAnena OJ, Heald RJ, Lockhart-Mummery HE. Operative and functional results of total mesorectal excision with ultra-low anterior resection in the management of carcinoma of the lower one-third of the rectum. *Surg Gynecol Obstet* 1990;170:517-21.
2. SeowChoen F, Goh HS. Prospective randomized trial comparing J colonic pouch-anal anastomosis and straight coloanal reconstruction. *Br J Surg* 1995;82:608-10.
3. Park JG, Lee MR, Lim SB, *et al.* Colonic J-pouch anal anastomosis after ultralow anterior resection with upper sphincter excision for low-lying rectal cancer. *World J Gastroenterol* 2005;11:2570-3.
4. Braun J, Treutner KH, Winkeltau G, Heidenreich U, Lerch MM, Schumpelick V. Results of intersphincteric resection of the rectum with direct coloanal anastomosis for rectal carcinoma. *Am J Surg* 1992;163:407-12.
5. Schiessel R, Karner-Hanusch J, Herbst F, Teleky B, Wunderlich M. Intersphincteric resection for low rectal tumors. *Br J Surg* 1994;81:1376-8.
6. Renner K, Rosen HR, Novi G, Hölbling N, Schiessel R. Quality of life after surgery for rectal cancer. *Dis Colon Rectum* 1999;42:1160-7.
7. Rullier E, Zerbib F, Laurent C, *et al.* Intersphincteric resection with excision of internal anal sphincter for conservative treatment of very low rectal cancer. *Dis Colon Rectum* 1999;42:1168-75.
8. Köhler A, Athanasiadis S, Ommer A, Psarakis E. Long-term results of low anterior resection with intersphincteric anastomosis in carcinoma of the lower one-third of the rectum: analysis of 31 patients. *Dis Colon Rectum* 2000;43:843-50.
9. Bretagnol F, Rullier E, Laurent C, Zerbib F, Gontier R, Saric J. Comparison of functional results and quality of life between intersphincteric resection and conventional coloanal anastomosis for low rectal cancer. *Dis Colon Rectum* 2004;47:832-8.
10. Shirouzu K, Ogata Y, Araki Y, Kishimoto Y, Sato Y. A new ultimate anus-preserving operation for extremely low rectal cancer and for anal canal cancer. *Tech Coloproctol* 2003;7:203-6.
11. Saito N, Ono M, Sugito M, *et al.* Early results of intersphincteric resection for patients with very low rectal cancer: an active approach to avoid a permanent colostomy. *Dis Colon Rectum* 2004;47:459-66.
12. Yamada K, Ogata S, Saiki Y, Fukunaga M, Tsuji Y, Takano M. Functional results of intersphincteric resection for low rectal cancer. *Br J Surg* 2007;94:1272-7.
13. Shirouzu K, Isomoto H, Kakegawa T, Morimatsu M. A prospective clinicopathologic study of venous invasion in colorectal cancer. *Am J Surg* 1991;162:216-22.
14. Shirouzu K, Isomoto H, Morodomi T, Kakegawa T. Carcinomatous lymphatic permeation. Prognostic significance in patients with rectal carcinoma: a long term prospective study. *Cancer* 1995;75:4-10.
15. Shirouzu K, Isomoto H, Kakegawa T. Prognostic evaluation of perineural invasion in rectal cancer. *Am J Surg* 1993;165:233-7.
16. Shirouzu K, Isomoto H, Kakegawa T. Distal spread of rectal cancer and optimal distal margin of resection for sphincter-preserving surgery. *Cancer* 1995;76:388-92.
17. Shirouzu K, Ogata Y, Araki Y. Oncologic and functional results of total mesorectal excision and autonomic nerve-preserving operation for advanced lower rectal cancer. *Dis Colon Rectum* 2004;47:1442-7.
18. Sobin LH, Wittekind C. UICC TNM classification of malignant tumours. 6th ed. New York: Wiley-Liss, 2002.
19. Miles WE. *Cancer of the rectum*. London: Harrison & Son, 1926.
20. Urban M, Rosen HR, Hölbling N, *et al.* MR imaging for the preoperative planning of sphincter-saving surgery for tumors of the lower third of the rectum: use of intravenous and endorectal contrast materials. *Radiology* 2000;214:503-8.
21. Beets-Tan RG, Beets GL, Vliegen RF, *et al.* Accuracy of magnetic resonance imaging in prediction of tumour-free resection margin in rectal cancer surgery. *Lancet* 2001;357:497-504.
22. Schiessel R, Novi G, Holzer B, *et al.* Technique and long-term results of intersphincteric resection for low rectal cancer. *Dis Colon Rectum* 2005;48:1858-67.
23. Goligher JC, Dukes CE, Bussey HJ. Local recurrences after sphincter-saving excisions for carcinomas of the rectum and rectosigmoid. *Br J Surg* 1951;39:199-211.
24. Vernava AM III, Moran M, Rothenberger DA, Wong WD. A prospective evaluation of distal margins in carcinoma of the rectum. *Surg Gynecol Obstet* 1992;175:333-6.
25. Pollet WG, Nicholls RJ. The relationship between the extent of distal clearance and survival and local recurrence rates after curative anterior resection for carcinoma of the rectum. *Ann Surg* 1983;198:159-63.
26. Holzer B, Urban M, Hölbling N, *et al.* Magnetic resonance imaging predicts sphincter invasion of low rectal cancer and influences selection of operation. *Surgery* 2003;133:656-61.
27. Nagtegaal ID, van de Velde CJ, Marijnen CA, van Krieken JH,

- Quirke P; Dutch Colorectal Cancer Group; The Pathology Review Committee. Low rectal cancer: a call for a change of approach in abdominoperineal resection. *J Clin Oncol* 2005;23:9257-65.
28. den Dulk M, Marijnen CA, Putter H, *et al*. Risk factors for adverse outcome in patients with rectal cancer treated with an abdominoperineal resection in the total mesorectal excision trial. *Ann Surg* 2007;246:83-90.
29. Crane CH, Skibber JM, Feig BW, *et al*. Response to preoperative chemoradiation increases the use of sphincter-preserving surgery in patients with locally advanced low rectal carcinoma. *Cancer* 2003;97:517-24.
30. Rullier E, Goffre B, Bonnel C, Zerbib F, Caudry M, Saric J. Preoperative radiochemotherapy and sphincter-saving resection for T3 carcinomas of the lower third of the rectum. *Ann Surg* 2001;234:633-40.

