T-cell lymphomas after high dose chemotherapy and stem cell transplant. *Leuk Lymphoma* 2004; **45**: 2261–2267.

22 Nademanee AP, Zain JM, Palmer J, Tsai N, Kogut NM, Krishnan A *et al*. The impact of disease status on the outcome of high-dose therapy (HDT) and autologous stem cell transplantation (ASCT) for peripheral T-cell lymphoma (PTCL). *ASH Annu Meeting Abstr* 2006; **108**: 3060.

23 Yang D-H, Kim WS, Kim SJ, Bae SH, Kim SH, Kim IH *et al*. The clinical outcomes of autologous stem cell transplantation in peripheral T cell lymphoma: from Retrospective Multicenter Study in Korea. *ASH Annu Meet Abstr* 2007; **110**: 1892.

24 Rodriguez J, Caballero MD, Gutierrez A, Gandarillas M, Sierra J, Lopez-Guillermo A *et al*. High dose chemotherapy and autologous stem cell transplantation in patients with peripheral T-cell lymphoma not achieving complete response after induction chemotherapy.The GEL-TAMO experience. *Haematologica* 2003; **88**: 1372–1377.

25 Mercadal S, Briones J, Xicoy B, Pedro C, Escoda L, Estany C *et al*. Intensive chemotherapy (high-dose CHOP/ESHAP regimen) followed by autologous stem-cell transplantation in previously untreated patients with peripheral T-cell lymphoma. *Ann Oncol* 2008; **19**: 958–963.

Int J Hematol (2009) 89:231–237
DOI 10.1007/s12185-008-0249-2

ORIGINAL ARTICLE

# Oral valganciclovir as preemptive therapy is effective for cytomegalovirus infection in allogeneic hematopoietic stem cell transplant recipients

**Katsuto Takenaka · Tetsuya Eto · Koji Nagafuji · Kenjiro Kamezaki · Yayoi Matsuo · Goichi Yoshimoto · Naoki Harada · Maki Yoshida · Hideho Henzan · Ken Takase · Toshihiro Miyamoto · Koichi Akashi · Mine Harada · Takanori Teshima · for Fukuoka Blood and Marrow Transplant Group (FBMTG)**

Received: 22 September 2008 / Revised: 26 November 2008 / Accepted: 18 December 2008 / Published online: 17 January 2009
© The Japanese Society of Hematology 2009

**Abstract** Between March 2007 and January 2008, the safety and efficacy of oral valganciclovir (VGC) preemptive therapy for cytomegalovirus (CMV) infection was evaluated in ten consecutive patients who received allogeneic hematopoietic stem cell transplantation (HSCT). Patients were screened once or twice per week after engraftment using CMV pp65 antigenemia assay. When more than 2 CMV antigen-positive cells per 50,000 leukocytes were detected, preemptive therapy with oral VGC was initiated at a dose of 900 mg twice daily for 3 weeks. Nine patients (90%) completed the 3-week VGC treatment except for one patient who developed febrile neutropenia. There was no other significant toxicity. CMV antigen-positive cells were rapidly decreased in all nine patients and became undetectable by the end of the VGC treatment. None of the patients developed CMV disease. CMV infection relapsed in four of the ten patients (40%) after the VGC treatment. These observations suggest that preemptive therapy with VGC is effective for preventing CMV disease in allogeneic HSCT patients. Further studies with a large number of patients will be necessary to determine the optimal initial- and maintenance-dose of VGC.

**Keywords** Allogeneic hematopoietic stem cell transplantation · Cytomegalovirus infection · Preemptive therapy · Valganciclovir

K. Takenaka (✉) · K. Nagafuji · K. Kamezaki · G. Yoshimoto · N. Harada · K. Akashi · M. Harada
Department of Medicine and Biosystemic Science, Kyushu University Graduate School of Medical Sciences, 3-1-1 Maidashi, Higashi-ku, Fukuoka 812-8582, Japan
e-mail: takenaka@intmed1.med.kyushu-u.ac.jp

T. Eto · Y. Matsuo · M. Yoshida · H. Henzan · K. Takase
Department of Hematology, Hamanomachi General Hospital, Fukuoka, Japan

T. Miyamoto · T. Teshima
Center for Cellular and Molecular Medicine, Kyushu University Hospital, Fukuoka, Japan

M. Harada
Department of Internal Medicine, National Hospital Organization Omuta National Hospital, Omuta, Japan

## 1 Introduction

Despite improvement in the treatment of cytomegalovirus (CMV) infection and CMV disease with ganciclovir (GCV) and/or foscarnet, CMV disease is still a major cause of morbidity and mortality after hematopoietic stem cell transplantation (HSCT) [1–4]. Major risk factors for CMV disease include CMV seropositivity before transplantation, development of graft-versus-host disease (GVHD), unrelated donor transplantation, and T cell depleted transplantation [3, 5–7]. In addition, new transplantation modalities such as nonmyeloablative conditioning regimens consisting of intensive immunosuppression increase the risk of late-onset CMV infection and CMV disease [2, 8]. Therefore, extended prevention of CMV disease may be required, especially for high-risk recipients, not only those within 100 days after HSCT but also those in the later period after HSCT [8–10]. Currently, the prevention of CMV disease involves general prophylaxis and preemptive therapy. Preemptive therapy is based on the early detection of CMV infection by virus surveillance, by monitoring with either CMV antigenemia assay or PCR techniques and followed by immediate treatment with anti-CMV drugs

[4, 11–13]. Intravenous GCV (IV-GCV) and/or foscarnet are commonly used for preemptive therapy and are effective for decreasing the incidence of early CMV disease [11, 13, 14]. However, these antiviral treatments are given intravenously and often require hospitalization, as well as high costs and IV-related complications.

Valganciclovir hydrochloride (VGC) is an oral valine-ester GCV prodrug with a tenfold higher bioavailability than oral GCV, and it is rapidly hydrolyzed to GCV after oral administration. VGC and IV-GCV have similar efficacy in the treatment of CMV retinitis in HIV-infected patients and in preemptive CMV treatment in solid organ (heart, renal, and renal-pancreas) transplant patients [15–19]. Recently, several studies have shown the efficacy of VGC for preemptive therapy in allogeneic HSCT patients [20–23]. We evaluated the safety and efficacy of oral VGC as preemptive therapy for CMV reactivation in ten allogeneic HSCT patients.

## 2 Patients and methods

### 2.1 Patients

This was a prospective multicenter study with VGC. The study patients were adults who had received an allogeneic bone marrow or peripheral blood stem cell transplant. Patients were eligible when they screened for CMV infection using CMV pp65 antigenemia assay and more than two CMV antigen-positive cells were detected. Patients unable to take oral medication, and those who impaired renal function (serum creatinine level >2.0 mg/dL) were ineligible. Patients, who developed CMV disease, had received antiviral agents other than acyclovir and who developed more than stage 2 gastrointestinal GVHD were also ineligible. Ten consecutive patients who received allogeneic HSCT at Kyushu University Hospital and Hamanomachi General Hospital between March 2007 and January 2008 were included in the study (Table 1). This study was approved by Institutional Review Board of each institute and a written informed consent was obtained from each participating patient.

Eight patients had acute myeloid leukemia, one had myelodysplastic syndrome, and one had non-Hodgkin's lymphoma. The median age of the patients at the time of transplantation was 56 years (range 33–63). They received bone marrow grafts from an HLA-matched sibling donor ($n = 1$), a matched unrelated donor ($n = 8$), or an HLA-1 locus mismatched unrelated donor ($n = 1$). All of the patients were CMV seropositive before transplantation. Nine patients received myeloablative preparative regimens including total body irradiation/cyclophosphamide (Cy) in five patients and busulfan (BU)/Cy in four patients.

**Table 1** Patient characteristics

| | |
|---|---|
| Number of patients | 10 |
| Median age, years (range) | 56 (33–65) |
| Diagnosis | |
| Acute myeloid leukemia | 8 |
| Myelodysplastic syndrome | 1 |
| Non-Hodgkin's lymphoma | 1 |
| Stem cell source | |
| HLA-identical sibling bone marrow | 1 |
| HLA-matched unrelated bone marrow | 8 |
| HLA-mismatched unrelated bone marrow | 1 |
| CMV serologic status | |
| Donor + /Recipient + | 9 |
| Donor −/Recipient + | 1 |
| Preparative regimens | |
| TBI/Cy | 5 |
| Bu/Cy | 4 |
| Flu/Bu/TBI | 1 |
| GVHD prophylaxis | |
| Taclorimus + MTX | 9 |
| CSP + MTX | 1 |
| Acute GVHD prior to CMV reactivation | |
| Grade I | 1 |
| Grade II | 7 |
| Grade III | 2 |
| PSL treatment at the time of starting VCG | 8 |

*Bu* busulfan, *CMV* cytomegalovirus, *CSP* cyclosporine, *Cy* cyclophosphamide, *Flu* fludarabine, *GVHD* graft-versus-host disease, *TBI* total body irradiation, *MTX* methotrexate, *PSL* prednisolone, *VGC* valganciclovir

The remaining patient received a fludarabine-based reduced-intensity conditioning regimen. GVHD prophylaxis consisted of taclorimus/short-term methotrexate (MTX) ($n = 9$) or cyclosporine/short-term MTX ($n = 1$). Patients who developed grade II–IV acute GVHD were given methylprednisolone (mPSL) or prednisolone (PSL) at a dose of 1 or 2 mg/kg. Acyclovir was administered orally (1,000 mg/day) or intravenously (500 mg/day) from days −7 to 35 as a prophylaxis against herpes simplex infection.

### 2.2 CMV antigenemia assay

CMV antigenemia assay was determined as previously described [7, 24]. In brief, peripheral blood leukocytes isolated from 3 mL of EDTA-treated blood were applied to slides by centrifugation and fixed with cold acetone. The slides were stained using a direct immunoperoxidase technique that employed the peroxidase-conjugated monoclonal antibody HRP-C7 (Teijin, Tokyo, Japan) against the CMV pp65 antigen. CMV antigen-positive cells were counted under a light microscope and the results were

expressed as the number of CMV antigen-positive cells per 50,000 leukocytes.

### 2.3 Definition of CMV infection and CMV disease

A positive test for CMV antigenemia was defined as the presence of one or more CMV antigen-positive cells per 50,000 leukocytes. CMV infection was considered in patients with a positive test for CMV antigenemia. CMV disease was diagnosed according to published recommendations [25]. Patients with clinical manifestations of CMV disease, such as interstitial pneumonia and gastroenteritis in the presence of CMV infection, were examined histopathologically and immunochemically from biopsy specimens.

### 2.4 Preemptive therapy with VGC for CMV infection

Monitoring with CMV antigenemia assay was performed at least once per week after engraftment until day 100 after HSCT and once every other week thereafter. Preemptive therapy with VGC for CMV infection was initiated at the time of the first detection of more than two CMV antigen-positive cells per 50,000 leukocytes. VGC was administered orally at a dose of 900 mg twice daily for 3 weeks. The dose was adjusted for patients with impaired renal function according to the manufacturer's recommendation. Acyclovir for the prophylaxis against herpes simplex infection was discontinued when VGC treatment was started. Supplemental immunoglobulin was administered only when a total IgG level was less than 400 mg/dL.

### 2.5 Endpoints and definitions

The primary endpoint was the rate of complete response of the VGC preemptive therapy to the CMV infection. The efficacy of VGC was monitored weekly using a CMV antigenemia assay. A complete response was defined as the conversion from positive to negative CMV antigenemia test results at the completion of the treatment. Patients who persistently showed positive test results for CMV antigenemia after 3 weeks of preemptive therapy or developed CMV disease during the period of preemptive therapy were considered a treatment failure.

The secondary endpoints included the safety of preemptive therapy, the incidence of CMV disease during VGC treatment, and the incidence of a recurrent CMV reactivation after the completion of VGC treatment. The patients were monitored with the CMV antigenemia assay for 5 weeks after the completion of the VGC treatment. At least once per week, a safety analysis was conducted. The analysis included the monitoring of blood counts, liver and renal function tests, and documenting other unexpected side effects. The incidence of CMV disease was evaluated for the entire period of the study. The incidence of recurrent reactivation of CMV infection after the VGC preemptive therapy was based on the conversion from negative CMV antigenemia to positive CMV antigenemia test results with more than two CMV antigen-positive cells per 50,000 leukocytes during the 5-week follow-up period.

## 3 Results

### 3.1 CMV infection and VGC preemptive therapy

Forty-seven patients received allogeneic bone marrow/peripheral blood stem cell transplants at these two institutes during the study period. Thirty-one patients showed positive CMV antigenemia test results after transplantation. Ten patients were enrolled into this study, but the remaining 21 patients were not enrolled mostly by their inability to take oral medication. Ten enrolled patients were given preemptive therapy with VGC for CMV infection (Table 1). All patients were CMV seropositive before transplantation, and nine donors were also CMV seropositive. In these patients, more than 2 CMV antigen-positive cells per 50,000 leukocytes were detected after a median of 69 days (range 22–252) following transplantation. The median number of CMV antigen-positive cells at the initiation of VGC therapy was 5 per 50,000 leukocytes (range 3–59). All of the patients developed acute GVHD prior to CMV infection after a median of 23 days (range 11–135). The severity of acute GVHD was grade I in one patient, grade II in seven, and grade III in two. Eight patients received mPSL or PSL for the treatment of acute GVHD. Preemptive therapy with VGC was started within five days after the detection of CMV antigen-positive cells. Nine patients completed 21 days of VGC treatment, whereas one patient failed to complete the therapy because of the development of grade 4 neutropenia and subsequent febrile neutropenia. Patients were followed at least 5 weeks after the completion of VGC preemptive therapy. The median follow-up was day 122 (range 41–355).

### 3.2 Response to VGC preemptive therapy

All patients showed negative test results for CMV antigenemia within 3 weeks after the initiation of the VGC treatment. In nine patients, CMV antigen-positive cells became negative within 2 weeks (Fig. 1). The remaining patient, who had 60/50,000 CMV antigen-positive cells at the time of initiation of VGC treatment, took 3 weeks to clear CMV antigen-positive cells. None of the patients required other anti-CMV agents. None of the patients developed CMV disease during the preemptive therapy or

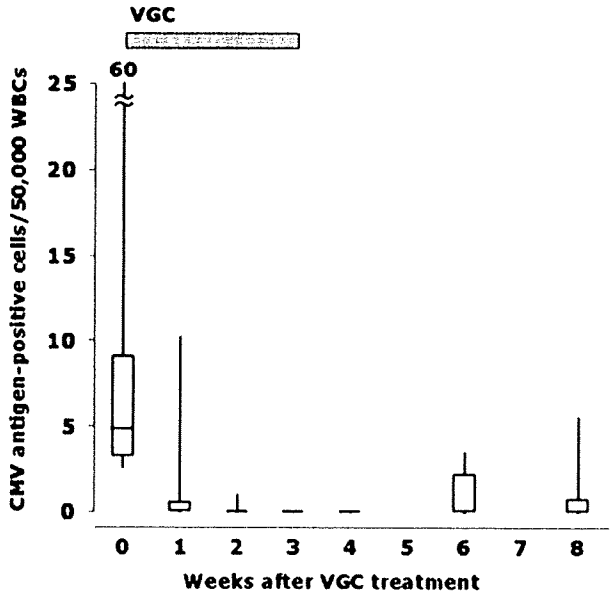


**Fig. 1** Time course of the number of cytomegalovirus (CMV) antigen-positive cells after valganciclovir treatment. CMV antigenemia was reduced during treatment with valganciclovir. The *box plots* display the median, the 25th and 75th percentiles (*box*), and the smallest and largest values (*longitudinal line*). One patient discontinued valganciclovir on day 18 due to grade 4 neutropenia

in the subsequent 5 weeks after the completion of the VGC treatment.

CMV infection relapsed in four of the ten patients within 3–5 weeks after the completion of the preemptive VGC therapy. These four patients were successfully treated with IV-GCV.

### 3.3 Toxicity

Nine patients completed a 21-day course of VGC treatment, but one patient discontinued VGC due to grade 4 neutropenia. Due to impaired renal function (serum creatinine level, 1.68 mg/dL), this patient received a reduced VGC dose of 450 mg once per day for the first week. Renal function improved with the reduced dose, and the VGC dosage was increased to 450 mg twice per day in the second week of treatment. However, this patient developed grade 4 neutropenia (absolute neutrophil counts $0.17 \times 10^9$/L) after 17 days of treatment and then developed febrile neutropenia. The VGC was discontinued, and the patient immediately received granulocyte-colony stimulating factor (G-CSF) and antibiotic therapy. Neutrophil counts recovered to more than $1.0 \times 10^9$/L, and neutropenia resolved after five days. Recurrent CMV reactivation was not observed in this patient during the follow-up period. None of the patients developed thrombocytopenia (platelet count $<30 \times 10^9$/L)(Fig. 2).

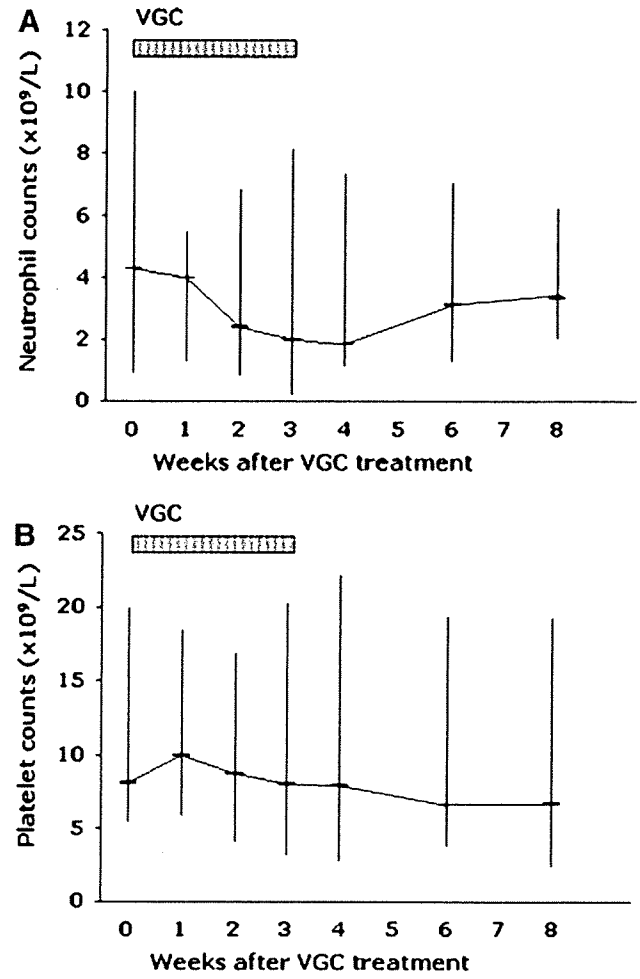


**Fig. 2** Time course of neutrophils and platelets during valganciclovir treatment. Time course of neutrophil (**a**) and platelet numbers (**b**) during treatment with valganciclovir. The bar graph displays the median (*horizontal line*), and the smallest and largest values (*longitudinal line*). One patient discontinued valganciclovir on day 18 due to grade 4 neutropenia

**Table 2** Adverse events other than hematological toxicities related to valganciclovir

| Adverse events | | No. of cases |
|---|---|---|
| Gastrointestinal | | |
| Diarrhea | Grade 1 | 1/10 |
| Hepatic | | |
| AST/ALT | Grade 1 | 3/10 |

None of the patients experienced renal toxicity during the VGC treatment. Three patients developed grade 1 liver dysfunction, and one patient had grade 1 diarrhea (Table 2). However, none of these complications required discontinuation of the VGC.

## 4 Discussion

Effective preemptive therapy with IV-GCV reduced the incidence of early CMV disease to 5–10%; however, the risk of late CMV disease beyond day 100 after transplantation has increased over the past few years. Therefore, extended CMV monitoring beyond day 100 is currently recommended, especially in high-risk patients [2, 8]. There is a need for an effective oral anti-CMV drug that can be used for outpatient care. Oral VGC could be a useful alternative to IV-GCV in patients who require preemptive therapy for CMV infection. This study demonstrated the efficacy and safety of preemptive VGC therapy for CMV infection after allogeneic HSCT. There are four published studies that have shown the safety and the efficacy of VGC as preemptive therapy after allogeneic HSCT [20–23]. Although dosage and duration of the drug varied between studies, VGC therapy resulted in a rapid decrease of the viral load in all of the patients. In this study, we administered a dose of 900 mg twice daily for 3 weeks, and corroborated the efficacy and the tolerability of preemptive VGC therapy.

We demonstrated that VGC at a dose of 900 mg twice per day was effective and resulted in a rapid clearance of CMV antigen-positive cells in all patients. No CMV disease developed during the preemptive therapy or the subsequent 5 weeks after the completion of treatment. VGC was well tolerated as 90% of the patients completed the entire treatment course. However, four of the ten patients developed a recurrent CMV reactivation after the discontinuation of VGC treatment, and they were all successfully treated with IV-GCV. Because a guideline for preemptive VGC therapy has not been established for patients that have received allogeneic HSCT, further studies will be necessary to determine the optimal initial- and maintenance-dose of VGC.

We, and four other groups, have obtained good results with VGC starting-doses of 900 mg twice per day [20–23]. This dose was based on observations from previous pharmacokinetics studies in HIV-infected patients and liver transplant recipients. A VGC dose of 900 mg results in an area under the concentration-time curve for GCV similar to that of 5 mg/kg IV-GCV [26, 27], which is the recommended standard dose for preemptive CMV therapy [28, 29]. One of the concerns of using VGC after allogeneic HSCT is the absorption of oral VGC in patients suffering from severe gastrointestinal GVHD. Recently, Einsele et al. [30] conducted a randomized crossover clinical trial of IV-GCV and VGC in patients with or without intestinal GVHD. The results showed that patients without intestinal GVHD who took VGC were exposed to more GCV when compared to those administered IV-GCV. This was also true in patients with grade I and II intestinal GVHD. Thus, VGC may be as effective even in patients developing a mild form of intestinal GVHD as in patients without intestinal GVHD. However, a higher exposure of VGC may increase the toxicity of the drug, and the absorption of VGC was not evaluated in patients with severe intestinal GVHD. Recently, Candoni et al. [22] examined the efficacy of a lower dose of VGC. Preemptive therapy with 900 mg/day VGC was as effective for clearing CMV antigen-positive cells and preventing CMV disease as the standard dose of 1800 mg/day. These findings suggest that the initial dose of VGC could be reduced to 900 mg/day as preemptive therapy in low-risk patients.

The effective duration for preemptive VGC therapy is currently unclear. In the previous studies, patients received VGC for 2 weeks and then it was either discontinued or continued at a maintenance dose of variable duration dependant upon a negative CMV test result. Different from previous studies, we continued an initial dose of VGC for 3 weeks. The dosage and duration of VGC therapy likely affects the incidence of hematological toxicity such as neutropenia. In a study by Busca et al. [21], in which VGC was administered at a dose of 1,800 mg/day for 2 weeks, followed by 900 mg/day for an additional 2 weeks, 4 of the 15 patients failed to complete the 3-week scheduled therapy due to neutropenia and/or thrombocytopenia. In our study, only one of the ten patients failed to complete treatment. Thus, hematologic toxicity may be a significant problem after a 3 week treatment with VGC.

In our study, four of the ten patients treated with VGC developed recurrent CMV reactivation 3–5 weeks after the discontinuation of VGC. This was somewhat similar to the 10–53% recurrence rates in previous studies [20–23]. Thus, careful monitoring after the completion of VGC therapy is recommended. We continued an initial dose of VGC for 3 weeks. However, when considering hematological toxicity and frequent recurrence of CMV antigenemia, the duration of treatment and/or maintenance should be decided by monitoring CMV.

As previously reported [20–23], we found neutropenia to be the main toxic effect of VGC. One patient, who had impaired renal function before the preemptive therapy that required a dose reduction, discontinued the drug on day 17 due to grade 4 neutropenia. In high-risk patients, especially outpatient should be closely monitored, although any other toxicity profile different from IV-GCV was not observed in this study.

Our study demonstrated that the oral VGC preemptive therapy at a dose of 900 mg daily seemed to be as effective as conventional IV-GCV at a dose of 10 mg/kg daily to clear CMV antigen-positive cells. However, as shown in Fig. 1, CMV antigen-positive cells seem to decrease in numbers much faster after VGC treatment than those observed after standard dose of IV-GCV treatment.

Furthermore, hematological toxicities were considerable. Although pharmacokinetic data was not available in this study, these observations coincide with the previous pharmacokinetic study in HSCT recipients that showed the exposure of GCV after administration of 1800 mg daily VGC was significantly higher compared with 10 mg/kg IV-GCV even in patients without gastrointestinal GVHD [30]. Careful monitoring of neutrophil counts will be useful to improve the safety of VGC in HSCT recipients, especially with reduced renal function. Kanda et al. [14] showed the efficacy of response-oriented preemptive therapy using a low initial dose of IV-GCV that resulted in a successful reduction of the total dose of IV-GCV and decreased hematological toxicities. A lower dose of VGC could be also used as preemptive therapy by close CMV monitoring. Similar studies with a large number of patients will be required to define the optimal treatment schedule for preemptive VGC therapy.

Despite a limited number of patients, our results suggest that oral VGC is an effective alternative to IV-GCV for preemptive therapy to prevent CMV disease in allogeneic HSCT patients. Studies with a larger number of patients will be necessary to assess the efficacy and long-term effect of this preemptive therapy.

## References


1. Boeckh M, Nichols WG. The impact of cytomegalovirus serostatus of donor and recipient before hematopoietic stem cell transplantation in the era of antiviral prophylaxis and preemptive therapy. Blood. 2004;103(6):2003–8. doi:10.1182/blood-2003-10-3616.
2. Boeckh M, Nichols WG, Papanicolaou G, Rubin R, Wingard JR, Zaia J. Cytomegalovirus in hematopoietic stem cell transplant recipients: current status, known challenges, and future strategies. Biol Blood Marrow Transplant. 2003;9(9):543–58. doi:10.1016/S1083-8791(03)00287-8.
3. Forman SJ, Zaia JA. Treatment and prevention of cytomegalovirus pneumonia after bone marrow transplantation: where do we stand? Blood. 1994;83(9):2392–8.
4. Ljungman P, Aschan J, Lewensohn-Fuchs I, et al. Results of different strategies for reducing cytomegalovirus-associated mortality in allogeneic stem cell transplant recipients. Transplantation. 1998;66(10):1330–4. doi:10.1097/00007890-199811270-00012.
5. Meyers JD, Flournoy N, Thomas ED. Risk factors for cytomegalovirus infection after human marrow transplantation. J Infect Dis. 1986;153(3):478–88.
6. Miller W, Flynn P, McCullough J, et al. Cytomegalovirus infection after bone marrow transplantation: an association with acute graft-v-host disease. Blood. 1986;67(4):1162–7.
7. Takenaka K, Gondo H, Tanimoto K, et al. Increased incidence of cytomegalovirus (CMV) infection and CMV-associated disease after allogeneic bone marrow transplantation from unrelated donors. The Fukuoka Bone Marrow Transplantation Group. Bone Marrow Transplant. 1997;19(3):241–8. doi:10.1038/sj.bmt.1700637.
8. Asano-Mori Y, Kanda Y, Oshima K, et al. Clinical features of late cytomegalovirus infection after hematopoietic stem cell transplantation. Int J Hematol. 2008;87(3):310–8. doi:10.1007/s12185-008-0051-1.
9. Boeckh M, Leisenring W, Riddell SR, et al. Late cytomegalovirus disease and mortality in recipients of allogeneic hematopoietic stem cell transplants: importance of viral load and T-cell immunity. Blood. 2003;101(2):407–14. doi:10.1182/blood-2002-03-0993.
10. Einsele H, Hebart H, Kauffmann-Schneider C, et al. Risk factors for treatment failures in patients receiving PCR-based preemptive therapy for CMV infection. Bone Marrow Transplant. 2000;25(7):757–63. doi:10.1038/sj.bmt.1702226.
11. Einsele H, Ehninger G, Hebart H, et al. Polymerase chain reaction monitoring reduces the incidence of cytomegalovirus disease and the duration and side effects of antiviral therapy after bone marrow transplantation. Blood. 1995;86(7):2815–20.
12. Goodrich JM, Mori M, Gleaves CA, et al. Early treatment with ganciclovir to prevent cytomegalovirus disease after allogeneic bone marrow transplantation. N Engl J Med. 1991;325(23):1601–7.
13. Reusser P, Einsele H, Lee J, et al. Randomized multicenter trial of foscarnet versus ganciclovir for preemptive therapy of cytomegalovirus infection after allogeneic stem cell transplantation. Blood. 2002;99(4):1159–64. doi:10.1182/blood.V99.4.1159.
14. Kanda Y, Mineishi S, Saito T, et al. Pre-emptive therapy against cytomegalovirus (CMV) disease guided by CMV antigenemia assay after allogeneic hematopoietic stem cell transplantation: a single-center experience in Japan. Bone Marrow Transplant. 2001;27(4):437–44. doi:10.1038/sj.bmt.1702805.
15. Devyatko E, Zuckermann A, Ruzicka M, et al. Pre-emptive treatment with oral valganciclovir in management of CMV infection after cardiac transplantation. J Heart Lung Transplant. 2004;23(11):1277–82. doi:10.1016/j.healun.2003.08.034.
16. Diaz-Pedroche C, Lumbreras C, Del Valle P, et al. Efficacy and safety of valgancyclovir as preemptive therapy for the prevention of cytomegalovirus disease in solid organ transplant recipients. Transplant Proc. 2005;37(9):3766–7. doi:10.1016/j.transproceed.2005.10.075.
17. Kalpoe JS, Schippers EF, Eling Y, Sijpkens YW, de Fijter JW, Kroes AC. Similar reduction of cytomegalovirus DNA load by oral valganciclovir and intravenous ganciclovir on pre-emptive therapy after renal and renal-pancreas transplantation. Antivir Ther. 2005;10(1):119–23.
18. Martin DF, Sierra-Madero J, Walmsley S, et al. A controlled trial of valganciclovir as induction therapy for cytomegalovirus retinitis. N Engl J Med. 2002;346(15):1119–26. doi:10.1056/NEJMoa011759.
19. Paya C, Humar A, Dominguez E, et al. Efficacy and safety of valganciclovir vs. oral ganciclovir for prevention of cytomegalovirus disease in solid organ transplant recipients. Am J Transplant. 2004;4(4):611–20. doi:10.1111/j.1600-6143.2004.00382.x.
20. Ayala E, Greene J, Sandin R, et al. Valganciclovir is safe and effective as pre-emptive therapy for CMV infection in allogeneic hematopoietic stem cell transplantation. Bone Marrow Transplant. 2006;37(9):851–6. doi:10.1038/sj.bmt.1705341.
21. Busca A, de Fabritiis P, Ghisetti V, et al. Oral valganciclovir as preemptive therapy for cytomegalovirus infection post allogeneic stem cell transplantation. Transpl Infect Dis. 2007;9(2):102–7. doi:10.1111/j.1399-3062.2006.00183.x.
22. Candoni A, Simeone E, Tiribelli M, Pipan C, Fanin R. What is the optimal dosage of valganciclovir as preemptive therapy for CMV infection in allogeneic hematopoietic SCT? Bone Marrow Transplant. 2008;42(3):207–8. doi:10.1038/bmt.2008.98.

23. van der Heiden PL, Kalpoe JS, Barge RM, Willemze R, Kroes AC, Schippers EF. Oral valganciclovir as pre-emptive therapy has similar efficacy on cytomegalovirus DNA load reduction as intravenous ganciclovir in allogeneic stem cell transplantation recipients. Bone Marrow Transplant. 2006;37(7):693–8. doi: 10.1038/sj.bmt.1705311.
24. Gondo H, Minematsu T, Harada M, et al. Cytomegalovirus (CMV) antigenaemia for rapid diagnosis and monitoring of CMV-associated disease after bone marrow transplantation. Br J Haematol. 1994;86(1):130–7. doi:10.1111/j.1365-2141.1994.tb03263.x.
25. Ljungman P, Griffiths P, Paya C. Definitions of cytomegalovirus infection and disease in transplant recipients. Clin Infect Dis. 2002;34(8):1094–7. doi:10.1086/339329.
26. Brown F, Banken L, Saywell K, Arum I. Pharmacokinetics of valganciclovir and ganciclovir following multiple oral dosages of valganciclovir in HIV- and CMV-seropositive volunteers. Clin Pharmacokinet. 1999;37(2):167–76. doi:10.2165/00003088-199937020-00005.
27. Pescovitz MD, Rabkin J, Merion RM, et al. Valganciclovir results in improved oral absorption of ganciclovir in liver transplant recipients. Antimicrob Agents Chemother. 2000;44(10):2811–5. doi:10.1128/AAC.44.10.2811-2815.2000.
28. Centers for Disease Control and Prevention IDSoA, American Society of Blood and Marrow Transplantation. Guidelines for preventing opportunistic infections among hematopoietic stem cell transplant recipients. Biol Blood Marrow Transplant. 2000; 6(6a):659–727.
29. Fraser GA, Walker II. Cytomegalovirus prophylaxis and treatment after hematopoietic stem cell transplantation in Canada: a description of current practices and comparison with Centers for Disease Control/Infectious Diseases Society of America/American Society for Blood and Marrow Transplantation guideline recommendations. Biol Blood Marrow Transplant. 2004;10(5): 287–97. doi:10.1016/j.bbmt.2003.10.007.
30. Einsele H, Reusser P, Bornhauser M, et al. Oral valganciclovir leads to higher exposure to ganciclovir than intravenous ganciclovir in patients following allogeneic stem cell transplantation. Blood. 2006;107(7):3002–8. doi:10.1182/blood-2005-09-3786.

Int J Hematol (2009) 90:253–260
DOI 10.1007/s12185-009-0370-x

ORIGINAL ARTICLE

# Rituximab for the treatment of corticosteroid-refractory chronic graft-versus-host disease

**Takanori Teshima · Koji Nagafuji · Hideho Henzan · Koichi Miyamura · Ken Takase · Michihiro Hidaka · Toshihiro Miyamoto · Katsuto Takenaka · Koichi Akashi · Mine Harada**

Received: 15 April 2009 / Revised: 23 May 2009 / Accepted: 3 June 2009 / Published online: 20 June 2009
© The Japanese Society of Hematology 2009

**Abstract** We prospectively evaluated the safety and efficacy of the anti-CD20 chimeric monoclonal antibody rituximab for the treatment of corticosteroid-refractory chronic graft-versus-host disease (GVHD) after allogeneic hematopoietic stem cell transplantation. Seven patients were treated with 375 mg/m$^2$ rituximab weekly for 4 consecutive weeks. Rituximab was well tolerated with no severe toxicity observed during treatment. At 1 year, 3 patients showed a partial response to rituximab therapy, 3 had stable disease, and 1 had progressive disease. Rituximab allowed a reduction in the dose of steroids in 4 patients. Responsive manifestations included mild to moderate skin and oral lesions, and immune hemolytic anemia, and thrombocytopenia. Severe manifestations involving the skin, fascia, and eye did not respond to treatment. These observations suggest that rituximab therapy may be effective for select patients with corticosteroid-refractory chronic GVHD that is not advanced.

**Keywords** Rituximab · Chronic GVHD · Corticosteroids · Allogeneic transplantation

T. Teshima (✉) · T. Miyamoto · K. Akashi
Center for Cellular and Molecular Medicine,
Kyushu University Graduate School of Medical Science,
3-1-1 Maidashi, Higashi-ku, Fukuoka 812-8582, Japan
e-mail: tteshima@cancer.med.kyushu-u.ac.jp

K. Nagafuji · T. Miyamoto · K. Takenaka ·
K. Akashi · M. Harada
Department of Medicine and Biosystemic Science,
Kyushu University Graduate School of Medical Science,
3-1-1 Maidashi, Higashi-ku, Fukuoka 812-8582, Japan

H. Henzan · K. Takase
Department of Hematology,
Hamanomachi General Hospital, Fukuoka, Japan

K. Miyamura
Department of Hematology,
Japanese Red Cross Nagoya Daiichi Hospital,
Nagoya, Japan

M. Hidaka
Department of Internal Medicine, National Hospital
Organization Kumamoto Medical Center, Kumamoto, Japan

## 1 Introduction

Chronic graft-versus-host disease (GVHD) remains to be the major cause of late morbidity and mortality, and has a significant effect on the functional status and quality of life in long-term survivors after allogeneic hematopoietic cell transplantation (HSCT). Chronic GVHD is a pleiomorphic syndrome with highly variable clinical manifestations, involving the skin, liver, eyes, mouth, esophagus, lung, serosal surfaces, lower gastrointestinal tract, female genitalia, and fascia [1, 2]. Corticosteroids in addition to the continuous administration of a calcineurin inhibitor are the standard treatment for chronic GVHD. The prognosis of patients with corticosteroid-refractory chronic GVHD is extremely poor, and there is no standard treatment for these patients [1, 3].

Although the biological mechanisms leading to chronic GVHD are not well understood compared with those leading to acute GVHD, multiple cellular and humoral mechanisms are likely to be involved in chronic GVHD [4, 5]. Much evidence suggest that B cells and humoral immunity are likely to play a role in the pathogenesis of chronic GVHD; the B cell compartment paradoxically shows simultaneous B lymphocytopenia and B cell hyperreactivity manifested by the production of autoantibodies.

CD86 expression is highly upregulated in B cells upon stimulation with toll-like receptor 9 in patients with chronic GVHD, as compared to that in controls [6]. Alloantibodies specific for recipient minor histocompatibility antigens have been detected in patients with chronic GVHD, usually 4–6 months after transplantation [7, 8]. Patients with antibodies to recipient minor histocompatibility antigens also have T cells specific for the same antigens [9]. A more direct role of B cells has been suggested by experiments showing that the depletion of donor B cells can protect mice from chronic GVHD [10].

Rituximab is a chimeric mouse/human anti-CD20 monoclonal antibody. It binds with high affinity to $CD20^+$ cells and specifically depletes B cells in vivo. Several phase II studies and case series studies have suggested that rituximab may be effective in the treatment of chronic GVHD [11–17]. Such beneficial effects of B cell depletion by rituximab further emphasize a potential pathogenic role of B cells in the development of chronic GVHD. However, the organ-specific responses observed between studies are substantially different, possible, in part, because previous retrospective studies involved patients who were heavily treated with different types of immunosuppressive therapy.

Ethnicity is associated with the incidence and severity of GVHD [18]. Japanese that have remained geographically isolated for significant periods of time are likely to have less genetic diversity than other ethnic populations experiencing recent and multiple immigrations. Japanese patients receiving allogeneic HSCT have a lower incidence of acute and chronic GVHD compared with patients in Western countries [19–22]. Furthermore, immunosuppressants other than calcineurin inhibitors and corticosteroids are rarely used to prevent and treat GVHD in Japan because they have not been approved for use. Thus, Japanese patients with chronic GVHD might represent a more homogeneous population in terms of genetic background and prior therapies. Here, we prospectively evaluated the safety and efficacy of rituximab in the treatment of corticosteroid-refractory chronic GVHD in Japanese patients undergoing allogeneic HSCT.

## 2 Patients and methods

### 2.1 Patients

An open-labeled and early phase II study of rituximab therapy for corticosteroid-refractory chronic GVHD was conducted. The primary objective was to determine the safety, toxicity, and efficacy of 4 courses of rituximab therapy. Eligible subjects had extensive chronic GVHD, which had shown resistance to prednisolone (PSL) at doses greater than 0.5 mg/kg for 30 days within the previous 12 months, who were receiving a stable dose of cyclosporine (CSP) or tacrolimus (TAC). The patients excluded from the study had a previous history of HSCT, an uncontrolled infection, were carriers of hepatitis B or C viruses, and younger than 18 years. This study was approved by the Institutional Review Board of each participating institute, according to the Declaration of Helsinki, and written informed consent was obtained from each participating patient.

### 2.2 Rituximab therapy

The patients were premedicated with acetaminophen and diphenhydramine, and then 375 $mg/m^2$ rituximab was intravenously administered weekly for 4 weeks. The initial rate of infusion was 25 mg/h, which was increased to 100 mg/h if there was no reaction to the infusion. During 4 courses of treatment, all patients were required to receive a stable dose of immunosuppressive agents. Following 4 courses of rituximab therapy, decisions regarding the tapering of the dose of immunosuppressive medications were prepared by the transplant physician. The recommended sequence was the withdrawal of corticosteroids and then the withdrawal of the calcineurin inhibitors based on the resolution of chronic GVHD.

### 2.3 Study evaluation

The diagnosis of chronic GVHD required the presence of at least one diagnostic clinical sign of chronic GVHD or diagnostic manifestation confirmed histologically or by other relevant tests in the absence of acute characteristics of GVHD [2]. The disease was classified as limited or extensive and as de novo, quiescent, or progressive GVHD [1, 23]. Chronic GVHD was staged and graded according to National Institute of Health consensus criteria [2]. The global assessment of the severity of chronic GVHD was derived by combining organ- and site-specific scores. Each organ or site was scored according to a 4-point scale (0–3), with 0 representing no involvement and 3 representing severe impairment. In addition, performance status (PS) was evaluated on this 4-point scale. For thrombocytopenia, a score of 0 was defined as platelets $\geq 140 \times 10^9/l$, 1 as platelets $\geq 100 \times 10^9/l$, 2 as platelets $\geq 50 \times 10^9/l$, and 3 as platelets $< 50 \times 10^9/l$. For autoimmune hemolytic anemia (AIHA), a score of 0 was defined as hemoglobin $\geq 12$ g/dl and a negative Coombs test result. Scores of 1, 2, and 3 were defined as hemoglobin $\geq 10$, $\geq 7$, and $< 7$ g/dl, respectively. A post-treatment evaluation was performed every week until 6 weeks and then 2, 3, 4, 6, and 12 months thereafter, which included an assessment of the severity of chronic GVHD in each organ or tissue and a safety analysis. The analysis included the monitoring of

blood counts and liver and renal function test results and documenting unexpected side effects. The severity of adverse events attributable to rituximab was evaluated on the basis of the Common Terminology Criteria for Adverse Events, version 3.0. The therapeutic response was assessed 1 year after the initiation of the study, and was defined as complete response (CR), partial response (PR), stable disease (SD), or progressive disease (PD). CR was defined as the resolution of all symptoms and signs of chronic GVHD. PR was defined as a partial improvement in scores of $\geq 2$ for at least one organ with no progression in any other organs and no requirement of additional systemic immunosuppressive therapy for chronic GVHD. SD was defined as no change in score and no requirement of additional systemic therapy. PD was defined as the objective worsening of the disease or the need for dose escalation of immunosuppressive agents or additional systemic treatment. Statistical analysis was performed using an unpaired 2-tailed $t$ test.

## 3 Results

### 3.1 Patient characteristics

Seven patients (5 men and 2 women; median age 48 years, age range 24–55 years) were enrolled in this study between April 2006 and March 2007. The patients' characteristics are summarized in Table 1. All patients had extensive and corticosteroid-refractory chronic GVHD after allogeneic HSCT. The diseases for which transplantation was performed were as follows: acute myelogenous leukemia (AML, $n = 3$), chronic myelogenous leukemia (CML, $n = 2$), acute lymphoblastic leukemia (ALL, $n = 1$), and myelodysplastic syndrome (MDS, $n = 1$). Four patients underwent bone marrow transplantation (BMT) from a human leukocyte antigen (HLA)-matched or HLA-DR-mismatched unrelated donor, and 3 underwent peripheral blood stem cell transplantation (PBSCT) from an HLA-matched sibling donor. Myeloablative conditioning regimens were used in 5 patients, whereas fludarabine-based reduced-intensity conditioning regimens were used in 2. GVHD prophylaxis consisted of CSP and short-term methotrexate (MTX) ($n = 4$), TAC and short-term MTX ($n = 2$), or TAC alone ($n = 1$). All patients developed acute GVHD (grade II in 6 patients and grade I in 1 patient), which was successfully treated with 1–2 mg/kg of methylprednisolone (mPSL) or PSL and subsequently developed into quiescent and extensive chronic GVHD. On the basis of the global staging system [2], 4 patients had "severe" chronic GVHD, and 3 had "moderate" disease. The median time from transplantation to study enrollment was 42 months (range 19–112 months). The median time

**Table 1** Patients' characteristics

| UPN | Age/sex | Diagnosis | Donors | HLA | Stem cell source | GVHD prophylaxis | Type of onset | Prior therapy | Interval from transplantation to rituximab (months) | Interval from onset of chronic GVHD to rituximab (months) |
|---|---|---|---|---|---|---|---|---|---|---|
| 1 | 24/F | CML | Sibling | Identical | PBSC | CSP+MTX | Quiescent | PSL, CSP | 19 | 8 |
| 2 | 39/M | MDS | Unrelated | Identical | BM | TAC+MTX | Quiescent | PSL, pulse mPSL, CSP, TAC | 42 | 39 |
| 3 | 48/M | AML | Unrelated | Identical | BM | TAC | Quiescent | PSL, TAC | 46 | 43 |
| 4 | 51/M | CML | Unrelated | DR mismatch | BM | TAC+MTX | Quiescent | PSL, CSP, TAC | 112 | 109 |
| 5 | 55/F | AML | Unrelated | Identical | BM | CSP+MTX | Quiescent | PSL, CSP | 34 | 30 |
| 6 | 55/M | AML | Sibling | Identical | PBSC | CSP+MTX | Quiescent | PSL, CSP | 47 | 37 |
| 7 | 29/M | ALL | Sibling | Identical | PBSC | CSP+MTX | Quiescent | PSL, mPSL, CSP | 27 | 25 |

from the onset of chronic GVHD to study enrollment was 37 months (range 8–109 months). In all patients, prior therapy for chronic GVHD was a combination of corticosteroid and CSP or TAC. None of the patients received other immunosuppressive medications. The intervals between dose escalations of corticosteroids and rituximab administration were at a minimum of 1 month. All subjects were followed for 1 year after the initiation of rituximab therapy.

### 3.2 Toxicity

All patients completed a 4-week course of rituximab treatment. Only one patient developed grade 2 allergic toxicity, i.e., an infusion reaction after the first dose of rituximab. None of the patients developed grade 3 or 4 adverse events attributable to rituximab during the 4-week treatment. Later adverse events, occurring within 1 year of the initiation of therapy, included the following: grade 3 bacterial infection that required intravenous administration of cephepim in 1 patient at 2 months, grade 2 herpes simplex virus infection that required treatment with valaciclovir in 1 patient at 4 months, grade 1 hepatic injury in 1, and grade 2 renal damage in 1. These adverse events were likely related to other drugs that were used or to pronounced immune suppression related to transplantation and chronic GVHD.

### 3.3 Efficacy

All patients were evaluable for their response to rituximab therapy at 1 year after the study initiation (Table 2). Unique patient number (UPN) 1 developed skin sclerosis, which was initially treated with 0.5 mg/kg of PSL. Six month later, her chronic GVHD progressed to "severe" skin sclerosis and contracture. Chronic GVHD initially responded to rituximab with an improvement of symptoms, leading to successful tapering of PSL by 67% over 6 weeks. However, sclerosis progressed thereafter, and the PSL dose was increased. The PSL dose was subsequently reduced again by 67% of the initial dose at 1 year, at which time the global staging and organ-specific scores were unchanged as compared to those before rituximab therapy. The overall response at 1 year was classified with PD because of the need for an escalation in the dose of PSL. UPN 2 developed chronic GVHD in the skin and mouth, which was initially responded to 250 mg of mPSL. Skin and oral lesions were exacerbated 10 months before enrollment to this study. CSP was replaced with TAC and PSL dose was increased to 0.5 mg/kg, but chronic GVHD progressed to "moderate" cutaneous and oral disease. Rituximab therapy was started, but was not effective. However, the disease was stable during the study period without the need for an escalation in dose of CSP and PSL.

UPN 3 developed extensive chronic GVHD, including cutaneous, oral, and hepatic lesions, and autoimmune hemolytic anemia (AIHA) and immune thrombocytopenia. This patient had steroid-induced diabetes mellitus and a history of tuberculosis. The patient was initially treated with 1 mg/kg of PSL. Three months before study enrollment, PSL was increased to 0.8 mg/kg, which was maintained until study entry according to the past history of exacerbation with less doses of PSL. Rituximab therapy improved "severe" GVHD to "moderate" GVHD, and allowed an 82% reduction in the dose of PSL within 1 year of the study.

UPN 4 had a 9-year history of chronic GVHD. The most severe manifestation was slowly progressive sclerodermatous lesions in the cervical and lower facial skin and fascia, which resulted in severe flexion and rotation contracture and difficulty in mouth opening and swallowing. Rituximab therapy failed to improve these manifestations, but the disease did not progress during the study period with stable doses of CSP and PSL. However, the patient required additional immunosuppressive therapy with high-dose cyclophosphamide 17 months after rituximab therapy and died of bacterial pneumonia, which developed during cyclophosphamide-induced neutropenia.

UPN 5 had "severe" sclerodermatous skin lesions in both the upper and lower extremities. The patient also had recurrent pleural effusion and ascites and a motility disorder of the intestine. The patient was initially treated with 0.5 mg/kg of PSL. Nine months before study enrollment, the disease was deteriorated and PSL dose was increased to 0.5 mg/kg, which was discontinued before rituximab therapy because of a lack of improvement and steroid intolerance. Rituximab therapy temporally improved serositis and diarrhea, but global staging and organ-specific scores were unchanged at 1 year. The patient died of bacterial pneumonia 19 months after the initiation of rituximab therapy.

UPN 6 developed corticosteroid-refractory chronic GVHD in the skin, mouth, eyes, and muscles. Rituximab improved these symptoms, and the patient was able to discontinue PSL by 1 year. Interestingly, the patient developed conductive hearing loss due to inflammation in the bilateral middle ear at the onset of chronic GVHD. The patient recovered dramatically from deafness after the fourth dose of rituximab therapy. UPN 7 developed cutaneous chronic GVHD and treated with PSL. The disease was progressed to sclerodermatous skin disease and the patient was started on 2 mg/kg of mPSL, which was reduced due to a lack of improvement and the patient entered to this study. Sclerodermatous skin lesion improved slowly after rituximab therapy and disappeared

**Table 2** Response to rituximab therapy

| UPN | Pretreatment | | | 2 months | | | 1 year | | | | |
|---|---|---|---|---|---|---|---|---|---|---|---|
| | Global staging | Organ/ manifestation | Score | Global staging | Score | % PSL reduction | Global staging | Score | % PSL reduction | Global response | Follow-up |
| 1 | Severe | PS | 1 | Severe | 1 | 67 | Severe | 1 | 67 | PD | Alive at 36 months |
| | | Skin | 2 | | 2 | | | 2 | | | |
| | | Mouth | 1 | | 1 | | | 1 | | | |
| | | Joints and fascia | 3 | | 3 | | | 3 | | | |
| 2 | Moderate | PS | 1 | Moderate | 1 | 0 | Moderate | 1 | 0 | SD | Alive at 35 months |
| | | Skin | 2 | | 2 | | | 2 | | | |
| | | Mouth | 2 | | 2 | | | 2 | | | |
| 3 | Severe | PS | 1 | Moderate | 1 | 40 | Moderate | 1 | 72 | PR | Alive at 34 months |
| | | Skin | 1 | | 1 | | | 1 | | | |
| | | Mouth | 1 | | 1 | | | 1 | | | |
| | | Liver | 3 | | 2 | | | 2 | | | |
| | | Thrombocytopenia | 2 | | 1 | | | 1 | | | |
| | | AIHA | 1 | | 0 | | | 0 | | | |
| 4 | Severe | PS | 1 | Severe | 1 | 0 | Severe | 1 | 0 | SD | Died of infection at 20 months |
| | | Skin | 3 | | 3 | | | 3 | | | |
| | | Eye | 1 | | 1 | | | 1 | | | |
| | | Joints and fascia | 3 | | 3 | | | 3 | | | |
| 5 | Severe | PS | 2 | Severe | 2 | – | Severe | 2 | – | SD | Died of infection at 19 months |
| | | Skin | 3 | | 3 | | | 3 | | | |
| | | Eye | 1 | | 1 | | | 1 | | | |
| | | Intestine | 1 | | 1 | | | 1 | | | |
| | | Joints and fascia | 1 | | 1 | | | 1 | | | |
| | | Serositis | 2 | | 2 | | | 2 | | | |
| | | Thrombocytopenia | 2 | | 2 | | | 1 | | | |
| 6 | Moderate | PS | 2 | Moderate | 1 | 0 | Moderate | 1 | 100 | PR | Alive at 30 months |
| | | Skin | 2 | | 1 | | | 1 | | | |
| | | Mouth | 2 | | 1 | | | 1 | | | |
| | | Eye | 2 | | 1 | | | 1 | | | |
| | | Muscle | 1 | | 0 | | | 0 | | | |
| 7 | Moderate | PS | 1 | Moderate | 1 | 0 | Moderate | 1 | 25 | PR | Alive at 23 months |
| | | Skin | 2 | | 2 | | | 0 | | | |
| | | Mouth | 1 | | 1 | | | 1 | | | |
| | | Eye | 2 | | 2 | | | 2 | | | |
| | | Joints and fascia | 1 | | 1 | | | 0 | | | |

at 1 year, although dry eye and oral mucositis did not improve.

Overall, none of the patients achieved a CR, whereas a PR was noted in 3 patients. SD was noted in 3 patients and PD in 1. One year after rituximab therapy began, PSL was discontinued or reduced in 4 of 6 patients; the median reduction rate was 67% (range 0–100%). None of the 7 patients required additional immunosuppressive therapy within 1 year after the initiation of the study. At a median follow-up of 30 months, 5 patients were alive with active and continuing chronic GVHD, and 2 had died of infection after the study period.

On the basis of global staging, only 1 patient with "severe" disease improved to "moderate" disease at 1 year, whereas 3 others with "severe" disease experienced no change. Patients with severe (score 3) skin sclerosis and joint contracture related to sclerodermatous skin GVHD and fascitis did not respond to rituximab therapy. One patient with severe (score 3) hepatic GVHD responded partially to rituximab therapy. Clinical responses were

observed primarily in patients with moderate (score 2) to mild (score 1) manifestations. It is noteworthy that 6 of 11 manifestations with a score 2 responded to rituximab therapy. Improvement in the skin, mouth, eye, liver, joints and fascia, intestine, and serous membrane was observed in 2 of 7, 1 of 5, 1 of 4, 1 of 1, 1 of 4, 0 of 1, and 0 of 1 cases, respectively. Notably, all cases of immune thrombocytopenia and anemia were responded well to rituximab. However, PS improved only in 1 patient who achieved a PR.

### 3.4 Immunological monitoring

B cell numbers were monitored after rituximab therapy using a flowcytometric analysis. $CD19^+$ B cells were quickly eliminated within 2 weeks after the first treatment and did not repopulate at least by 12 weeks (Fig. 1). Serum levels of IgG and IgA were unchanged by 6 weeks, but gradually declined thereafter. Serum IgM levels decreased much earlier and more profound compared with those of IgG and IgA.

## 4 Discussion

The prognosis of corticosteroid-refractory chronic GVHD is poor, and no standard therapy for corticosteroid-refractory chronic GVHD is available [1, 3]. In the present study, we evaluated the efficacy and safety of rituximab therapy in patients with quiescent-type chronic GVHD. This condition may have been related to the ethnicity of the transplant patients. The incidence of progressive-type chronic GVHD is high, reportedly 10–70% in Western countries [24, 25]. In contrast, progressive-type GVHD is rare and quiescent-type GVHD is common in Japanese patients [22]. Rituximab therapy was well tolerated, and no severe adverse events were attributed to rituximab therapy. A 4-week course of rituximab treatment produced an overall response rate of 43% at 1 year, which is slightly lower than

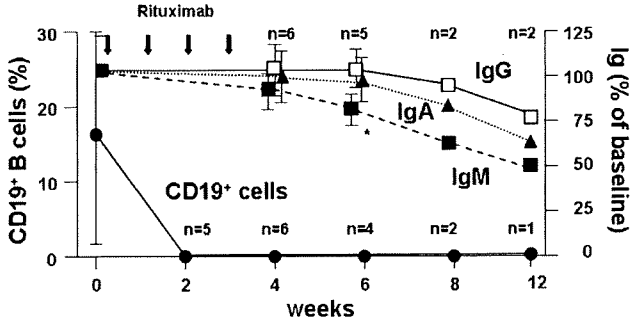


**Fig. 1** Laboratory parameters over time after rituximab therapy. IgG, IgA and IgM levels are shown as percentage of baseline levels.*$P < 0.01$ compared with IgG or IgA

the overall response rate of 50–83% reported in previous studies testing the efficacy of rituximab [11–13, 15–17]. CR rates ranged from 0 to 20% in previous studies [12, 13, 16, 17]. In the present study, none of the patients achieved CR. The steroid-sparing effect is an important indicator of efficacy assessments of GVHD [26]. Rituximab therapy resulted in a median reduction in the dose of corticosteroids of 67%, which was slightly lower than the 75–86% reduction in dose observed in 3 previous studies that addressed the steroid-sparing effect of rituximab in this setting [13, 15, 16]. These results were surprising because we initially hypothesized that rituximab would be more effective in Japanese patients who tend to develop less severe chronic GVHD than Caucasians [22].

Previous studies of the efficacy of rituximab therapy for steroid-resistant chronic GVHD highlight the potential activity of rituximab against skin involvement, including scleroderma, whereas the responses to rituximab appear to be less pronounced in other organs or tissues [11–17]. These studies also suggested that the steroid-sparing effect might be more pronounced in the skin and oral lesions than others in chronic GVHD [15, 16]. In addition, hematologic abnormalities associated with chronic GVHD also respond well to rituximab therapy [11, 15, 27]. In our study, rituximab was most effective against immune thrombocytopenia and AIHA, and less effective against skin sclerosis and joint contracture related to sclerodermatous skin lesions and fascitis. This discrepancy between the current study and previous studies might have resulted because more patients with advanced sclerodermatous chronic GVHD were enrolled in our study than in the previous studies. The interval between the time of the onset of chronic GVHD and the time of study enrollment was longer in the present study (median duration 37 months) than in most of the previous studies (median duration 14–37 months) [11–13, 15, 17]. Nonetheless, our patients had undergone less immunosuppressive therapy before study enrollment than did the patients in the previous studies, most of whom had received multiple courses of immunosuppressive therapy [11, 12, 15]. Thus, the long-term duration of disease without sufficient intervention might have resulted in the development of irreversible damage in our patients.

Many advanced manifestations in chronic GVHD are potentially irreversible, including skin and joint contracture, chronic dry eye, esophageal and vaginal stricture, and bronchiolitis obliterans in the lung. The enrollment of patients with advanced chronic GVHD may not be appropriate when the endpoint of the study is the response to treatment. Alternatively, irreversible lesions could be excluded from consideration in the assessment of response [28, 29]. Such considerations were not specified in our protocol. The results of our study suggest that rituximab

may be more effective against mild to moderate manifestations than against severe manifestations of chronic GVHD. Thus, earlier treatment with rituximab or with other investigational agents for corticosteroid-refractory chronic GVHD may increase the chances of a good response. Another possible explanation for the poorer response to rituximab in our study than in previous studies, although unlikely, is that dominant immunological mechanisms associated with chronic GVHD and treatment outcomes may differ by ethnicity, because the prognostic scoring system [25], which was developed on the basis of clinical findings in Western patients, is not prognostic in Japanese patients [22].

We confirmed complete depletion of B cells after rituximab therapy. B cells were still absent 2 months after the last infusion of rituximab. In the initial multi-institutional trial evaluating a single four dose course of rituximab in patients with follicular lymphoma, the median B cell count did decline to almost undetectable levels after the first dose in the majority of patients, with recovery beginning from 6 to 9 months post-treatment, and return to normal levels between 9 and 12 months [30]. Similarly, B cells were undetectable in patients with chronic GVHD until 1 year after rituximab therapy [13]. Such a profound and prolonged B cell depletion may explain why rituximab treatment is effective in several antibody-mediated autoimmune diseases with some responses ongoing for more than 1–2 years [31]. On the other hand, rituximab therapy could results in impaired humoral immune responsiveness [32]. We also found that serum immunoglobulin levels decrease after rituximab therapy. Of note, IgM fell much more than IgG and IgA. This phenomenon was observed in patients with rheumatoid arthritis and chronic GVHD [13, 33]. This may be due to higher sensitivity of $IgD^+$ memory B cell subset, which produces natural mutated IgM antibodies as a first-line of defense against blood-borne antigens [33, 34], to rituximab than plasma cells.

In conclusion, the current study suggests that rituximab therapy may be effective for selective patients with corticosteroid-refractory chronic GVHD that is not advanced. A recent study indicated that that low-dose rituximab therapy is also effective [17]. However, the optimal schedule and dosing regimens for rituximab need to be determined. Furthermore, a well-designed, large-scale, prospective study is needed to conclusively address the efficacy of rituximab in the treatment of corticosteroid-refractory chronic GVHD.

**Acknowledgments** This study was supported by the Health and Labor Science Research Grants (Tokyo, Japan) (to T.T.), and a grant from the Foundation for Promotion of Cancer Research (Tokyo, Japan) (to T.T.).

## References

1. Lee SJ, Vogelsang G, Flowers ME. Chronic graft-versus-host disease. Biol Blood Marrow Transplant. 2003;9:215–33.
2. Filipovich AH, Weisdorf D, Pavletic S, et al. National Institutes of Health consensus development project on criteria for clinical trials in chronic graft-versus-host disease: I. Diagnosis and staging working group report. Biol Blood Marrow Transplant. 2005;11:945–56.
3. Arora M, Burns LJ, Davies SM, et al. Chronic graft-versus-host disease: a prospective cohort study. Biol Blood Marrow Transplant. 2003;9:38–45.
4. Chu YW, Gress RE. Murine models of chronic graft-versus-host disease: insights and unresolved issues. Biol Blood Marrow Transplant. 2008;14:365–78.
5. Teshima T, Wynn T, Soiffer R, Matsuoka K-I, Martin P. Chronic graft-versus-host disease: how can we release Prometheus? Biol Blood Marrow Transplant. 2008;14:142–50.
6. She K, Gilman AL, Aslanian S, et al. Altered Toll-like receptor 9 responses in circulating B cells at the onset of extensive chronic graft-versus-host disease. Biol Blood Marrow Transplant. 2007; 13:386–97.
7. Miklos DB, Kim HT, Zorn E, et al. Antibody response to DBY minor histocompatibility antigen is induced after allogeneic stem cell transplantation and in healthy female donors. Blood. 2004;103:353–9.
8. Miklos DB, Kim HT, Miller KH, et al. Antibody responses to H–Y minor histocompatibility antigens correlate with chronic graft-versus-host disease and disease remission. Blood. 2005;105: 2973–8.
9. Zorn E, Miklos DB, Floyd BH, et al. Minor histocompatibility antigen DBY elicits a coordinated B and T cell response after allogeneic stem cell transplantation. J Exp Med. 2004;199:1133–42.
10. Zhang C, Todorov I, Zhang Z, et al. Donor CD4+T and B cells in transplants induce chronic graft-versus-host disease with autoimmune manifestations. Blood. 2006;107:2993–3001.
11. Ratanatharathorn V, Carson E, Reynolds C, et al. Anti-CD20 chimeric monoclonal antibody treatment of refractory immune-mediated thrombocytopenia in a patient with chronic graft-versus-host disease. Ann Intern Med. 2000;133:275–9.
12. Canninga-van Dijk MR, van der Straaten HM, Fijnheer R, Sanders CJ, van den Tweel JG, Verdonck LF. Anti-CD20 monoclonal antibody treatment in 6 patients with therapy-refractory chronic graft-versus-host disease. Blood. 2004;104:2603–6.
13. Cutler C, Miklos D, Kim HT, et al. Rituximab for steroid-refractory chronic graft-versus-host disease. Blood. 2006;108: 756–62.
14. Okamoto M, Okano A, Akamatsu S, et al. Rituximab is effective for steroid-refractory sclerodermatous chronic graft-versus-host disease. Leukemia. 2006;20:172–3.
15. Zaja F, Bacigalupo A, Patriarca F, et al. Treatment of refractory chronic GVHD with rituximab: a GITMO study. Bone Marrow Transplant. 2007;40:273–7.
16. Mohty M, Marchetti N, El-Cheikh J, Faucher C, Furst S, Blaise D. Rituximab as salvage therapy for refractory chronic GVHD. Bone Marrow Transplant. 2008;41:909–11.
17. von Bonin M, Oelschlagel U, Radke J, et al. Treatment of chronic steroid-refractory graft-versus-host disease with low-dose rituximab. Transplantation. 2008;86:875–9.
18. Oh H, Loberiza FR Jr, Zhang MJ, et al. Comparison of graft-versus-host-disease and survival after HLA-identical sibling bone marrow transplantation in ethnic populations. Blood. 2005;105: 1408–16.

19. Morishima Y, Morishita Y, Tanimoto M, et al. Low incidence of acute graft-versus-host disease by the administration of methotrexate and cyclosporine in Japanese leukemia patients after bone marrow transplantation from human leukocyte antigen compatible siblings; possible role of genetic homogeneity. The Nagoya Bone Marrow Transplantation Group. Blood. 1989;74:2252–6.
20. Morishima Y, Kodera Y, Hirabayashi N, et al. Low incidence of acute GVHD in patients transplanted with marrow from HLA-A, B, DR-compatible unrelated donors among Japanese. Bone Marrow Transplant. 1995;15:235–9.
21. Sasazuki T, Juji T, Morishima Y, et al. Effect of matching of class I HLA alleles on clinical outcome after transplantation of hematopoietic stem cells from an unrelated donor. Japan Marrow Donor Program. N Engl J Med. 1998;339:1177–85.
22. Atsuta Y, Suzuki R, Yamamoto K, et al. Risk and prognostic factors for Japanese patients with chronic graft-versus-host disease after bone marrow transplantation. Bone Marrow Transplant. 2006;37:289–96.
23. Shulman HM, Sullivan KM, Weiden PL, et al. Chronic graft-versus-host syndrome in man: a long-term clinicopathologic study of 20 Seattle patients. Am J Med. 1980;69:204–17.
24. Lee SJ, Klein JP, Barrett AJ, et al. Severity of chronic graft-versus-host disease: association with treatment-related mortality and relapse. Blood. 2002;100:406–14.
25. Akpek G, Lee SJ, Flowers ME, et al. Performance of a new clinical grading system for chronic graft-versus-host disease: a multicenter study. Blood. 2003;102:802–9.
26. Martin PJ, Storer BE, Rowley SD, et al. Evaluation of mycophenolate mofetil for initial treatment of chronic graft-versus-host disease. Blood. 2009;113:5074–82.
27. Ratanatharathorn V, Ayash L, Reynolds C, et al. Treatment of chronic graft-versus-host disease with anti-CD20 chimeric monoclonal antibody. Biol Blood Marrow Transplant. 2003;9:505–11.
28. Pavletic SZ, Martin P, Lee SJ, et al. Measuring therapeutic response in chronic graft-versus-host disease: National Institutes of Health Consensus Development Project on Criteria for Clinical Trials in Chronic Graft-versus-Host Disease: IV. Response Criteria Working Group report. Biol Blood Marrow Transplant. 2006;12:252–66.
29. Martin PJ, Weisdorf D, Przepiorka D, et al. National Institutes of Health Consensus Development Project on Criteria for Clinical Trials in Chronic Graft-versus-Host Disease: VI. Design of Clinical Trials Working Group Report. Biol Blood Marrow Transplant. 2006;12:491–505.
30. McLaughlin P, Grillo-Lopez AJ, Link BK, et al. Rituximab chimeric anti-CD20 monoclonal antibody therapy for relapsed indolent lymphoma: half of patients respond to a four-dose treatment program. J Clin Oncol. 1998;16:2825–33.
31. Parodi E, Nobili B, Perrotta S, et al. Rituximab (anti-CD20 monoclonal antibody) in children with chronic refractory symptomatic immune thrombocytopenic purpura: efficacy and safety of treatment. Int J Hematol. 2006;84:48–53.
32. van der Kolk LE, Baars JW, Prins MH, van Oers MH. Rituximab treatment results in impaired secondary humoral immune responsiveness. Blood. 2002;100:2257–9.
33. Roll P, Dorner T, Tony HP. Anti-CD20 therapy in patients with rheumatoid arthritis: predictors of response and B cell subset regeneration after repeated treatment. Arthritis Rheum. 2008;58:1566–75.
34. Weller S, Braun MC, Tan BK, et al. Human blood IgM "memory" B cells are circulating splenic marginal zone B cells harboring a prediversified immunoglobulin repertoire. Blood. 2004;104:3647–54.

Bone Marrow Transplantation (2010) 45, 602–604
© 2010 Macmillan Publishers Limited All rights reserved 0268-3369/10 $32.00
www.nature.com/bmt

# LETTER TO THE EDITOR

# Unexpectedly high AUC levels in a child who received intravenous busulfan before stem cell transplantation

*Bone Marrow Transplantation* (2010) **45**, 602–604; doi:10.1038/bmt.2009.195; published online 17 August 2009

A 6-year-old boy underwent a craniotomy with subtotal resection of the cerebellar vermian tumor. Microscopic examination showed medulloblastoma. Brain magnetic resonance imaging after resection did not show residual disease. He subsequently received four cycles of ICE (ifosfamide, cisplatin, and etoposide) chemotherapy followed by whole craniospinal (24 Gy) and local (30 Gy) radiation therapy. He eventually received tandem high-dose chemotherapy. Conditioning regimens for the first and the second were carboplatin (1200 mg/m$^2$) + thiotepa (750 mg/m$^2$) and busulfan 1.1 mg/kg/dose intravenous every 6 h for total 16 doses (17.6 mg/kg) + melphalan 70 mg/m$^2$ once daily intravenous for 2 days (140 mg/m$^2$), respectively. Autologous PBSC were infused after high-dose chemotherapy. The numbers of CD-34-positive cells were $5.2 \times 10^6$/kg in the first and $7.0 \times 10^6$/kg in the second, respectively. Engraftment after the second autologous PBSCT was achieved on day 11. Brain magnetic resonance imaging on day 25 of the second autologous PBSCT showed no evidence of recurrence.

On day 64 of the second autologous PBSCT, he developed sudden dyspnea with 90% oxygen saturation in room air. A chest X-ray film showed a ground-glass appearance in both lungs. Chest computed tomography scan also showed bilateral areas of ground-glass opacities, and no centrilobular micronodule. Aspergillus, candida, and cryptococcal antigen for the serum were negative. The β-D-glucan level was significantly elevated (234.4 pg/ml). Intravenous cotrimoxazole therapy was initiated, because pneumocystis pneumonia was thought to have caused pneumonia based on the clinical course. He was placed on mechanical ventilation and methylprednisolone pulse therapy (30 mg/kg × 3 days) was started on day 72. His respiratory condition improved quickly with these treatments and mechanical ventilation was discontinued on day 77. Although polymerase chain reaction for *Pneumocystis jirovecii* in bronchoalveolar lavage fluid was negative, we diagnosed the cause of his pulmonary disorder had been pneumocystis pneumonia. His respiratory condition deteriorated again on day 82. Despite the second course of methylprednisolone pulse and continued cotrimoxazole therapy, he was placed on mechanical ventilation again on day 85 (Figure 1a). No pathogenic bacterial, fungal, or viral agents, including cytomegalovirus were identified by microbiological cultures and serological studies. The β-D-glucan level was also decreased to 33.4 pg/ml. Although various antibiotics, ganciclovir, antifungal drugs, and cotrimoxazole therapy were continued, his pulmonary oxygenation became worse day-by-day. He died on day 133 of the second autologous PBSCT because of respiratory failure (Figure 1b).

An autopsy was performed with the consent of his parents. Microscopically, organizing diffuse alveolar damage was seen, and nuclear enlargement, hyperchromasia, and pleomorphism were seen along alveolar and bronchial epithelium. This cytologic atypia was seen not only in the lung, but also in the urothelium of the renal pelvis. There was no evidence of bacterial, fungal, or viral infection. These pathological findings were consistent with busulfan-induced lung disease. Organizing diffuse alveolar damage is the most common manifestation of busulfan lung toxicity and is associated with bronchiolar and alveolar epithelium atypia.[1] This cytologic atypia is often seen extrapulmonary sites, including urinary bladder, breast, and uterine cervix.[1] The incidence of pulmonary toxicity after high-dose oral busulfan therapy before stem cell transplantation has been reported to be 3.6%.[2] Corticosteroids are effective for treating this disease to various degrees. Although some patients improve, others progress and die.[1]

It has become evident posthumously that busulfan areas under the drug plasma concentration–time curve (AUC) levels at the 1st and 9th doses were significantly elevated (2353 μM × min, 2347 μM × min) (target AUC; 900–1500 μM × min). Busulfan concentrations for the 1st and 9th doses and the accumulation of intravenous busulfan in plasma were assayed using a high-performance liquid chromatography system (Figure 2).[3] Plasma concentrations were analyzed by the non-compartmental method using WinNonlin (version 5.2.1; Pharsight Corp., Mountain View, CA, USA). The AUC from time 0 to infinity ($AUC_{inf}$) for the 1st dose and at steady state ($AUC_{ss}$) for the 9th dose was calculated using linear trapezoidal rule. The relationship between high busulfan AUC levels and the occurrence of busulfan-induced lung disease has not been established,[4] although high busulfan AUC levels are commonly associated with hepatic veno-occlusive disease.[5]

The cause of high busulfan AUC levels in our patient is still unclear. He did not have the distinct liver or renal disorder at the time of busulfan administration. Busulfan is metabolized in the liver through conjugation with glutathione by glutathione *S*-transferase (GST) enzymes.[6] GSTA1 is the predominant isoform of GST, which catalyzes the conjugation of busulfan with glutathione. Polymorphisms in GSTA1 are thought to be associated with alterations in the pharmacokinetics of busulfan.[7]

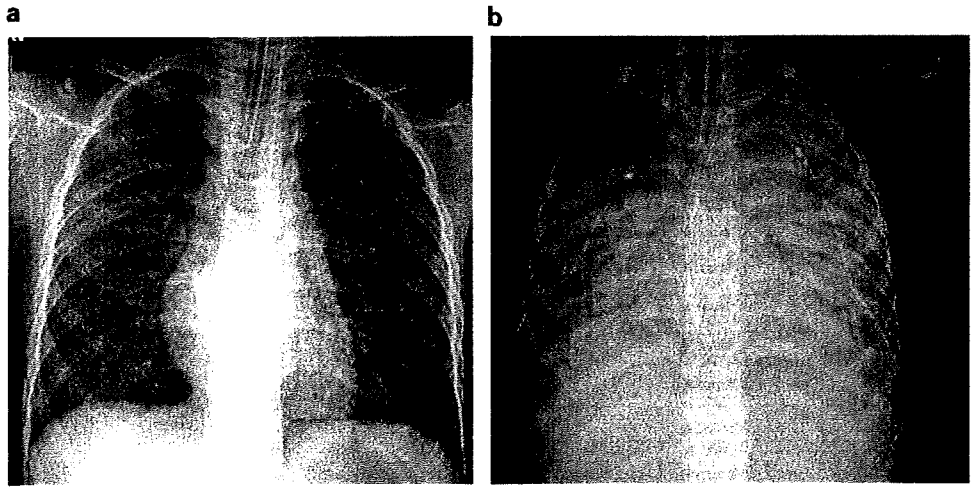


**Figure 1** Chest X-ray films. (**a**) (On day 85) bilateral lung fields showed a ground-glass appearance. (**b**) (On day 133) bilateral lung fields showed marked radiopacity and air bronchograms.

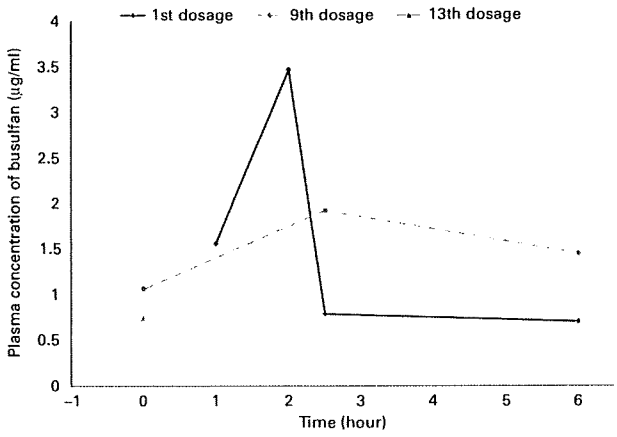


**Figure 2** Plasma concentration of busulfan. Peak level of plasma concentration of busulfan is very high (1st dose). Busulfan clearance is poor (before 13th dose).

Johnson *et al.*[7] reported that the GSTA1*B variant had a 2.6-fold higher busulfan AUC level than other variants after intravenous busulfan exposure in the pediatric population. Our patient's genotype of the promoter region of GST A1 by DNA sequencing was GSTA1*A diplotype (-567T, -69C, -52G) which is thought to be more active than the GSTA1 *A/*B. Nevertheless, busulfan AUC levels were significantly elevated. This may indicate that polymorphisms other than GSTA1 polymorphisms may affect busulfan metabolism.

Intravenous busulfan should have a much more predictable pharmacokinetic profile than oral busulfan. Treatment with a fixed dose of 0.80 mg/kg intravenous busulfan achieved the target AUC level (900–1500 μM × min) in 80% of adult patients.[8] The remaining 20% were very close to achieving the target level.[8] A recent European study showed that 91% of children achieved target AUC levels by weight-based dosing.[9] They concluded that this weight-based dosing in children is sufficient without therapeutic drug monitoring and dose adjustment. Our patient received intravenous busulfan according to his body weight, as in the European study. However, his busulfan AUC levels were higher than has been reported elsewhere in the literature.[9,10] To avoid unexpectedly high busulfan AUC levels, therapeutic drug monitoring and dose adjustment should be recommended for all patients who are treated with high-dose busulfan. When therapeutic drug monitoring is not applicable, test dosing of intravenous busulfan before high-dose therapy would be preferable.

## Conflict of interest

The authors declare no conflict of interest.

## Acknowledgements

This work was supported in part by funds for Clinical Cancer Research from the Health and Labour Sciences Research Grants.

T Nishikawa[1], Y Okamoto[1], T Tanabe[1], Y Shinkoda[1], Y Kodama[1], M Higashi[2], H Hirano[3], K Arita[3] and Y Kawano[1]

[1]*Department of Pediatrics, Kagoshima University Graduate School of Medical and Dental Sciences, Kagoshima, Japan;* [2]*Department of Human Pathology, Kagoshima University Graduate School of Medical and Dental Sciences, Kagoshima, Japan and* [3]*Department of Neurosurgery, Kagoshima University Graduate School of Medical and Dental Sciences, Kagoshima, Japan*

*E-mail: adu44150@ams.odn.ne.jp*

## References

1 Myers JL, El-Zammar O. Pathology of drug-induced lung disease. In: Katzenstein AL (ed). *Katzenstein and Askin's Surgical Pathology of Non-Neoplastic Lung Disease*, 4th edn. Elsevier Publishing Ltd: Philadelphia, PA, 2006, pp 85–89.

2 Kalaycio M, Pohlman B, Kuczkowski E, Rybicki L, Andresen S, Sobecks R *et al.* High-dose busulfan and the risk of pulmonary mortality after autologous stem cell transplant. *Clin Transplant* 2006; **20**: 783–787.
3 Henner WD, Furlong EA, Flaherty MD, Shea TC, Peters WP *et al.* Measurement of busulfan in plasma by high-performance liquid chromatography. *J Chromatogr* 1987; **416**: 426–432.
4 Li CK, Yuen PM, Wong R, Pang CP, Lai WK, Chik KW *et al.* Busulphan level and early mortality in thalassaemia patients after BMT. *Bone Marrow Transplant* 1999; **23**: 307–310.
5 Dix SP, Wingard JR, Mullins RE, Jerkunica I, Davidson TG, Gilmore CE *et al.* Association of busulfan area under the curve with veno-occlusive disease following BMT. *Bone Marrow Transplant* 1996; **17**: 225–230.
6 Czerwinksi M, Gibbs JP, Slattery JT. Busulfan conjugation by glutathione S-transferases alpha, mu and pi. *Drug Metab Dispos* 1996; **24**: 1015–1019.
7 Johnson L, Orchard PJ, Baker KS, Brundage R, Cao Q, Wang X *et al.* Glutathione S-transferase A1 genetic variants reduce busulfan clearance in children undergoing hematopoietic cell transplantation. *J Clin Pharmacol* 2008; **48**: 1052–1062.
8 Nguyen L, Leger F, Lennon S, Puozzo C. Intravenous busulfan in adults prior to haematopoietic stem cell transplantation: a population pharmacokinetic study. *Cancer Chemother Pharmacol* 2006; **57**: 191–198.
9 Vassal G, Michel G, Esperou H, Gentet JC, Valteau-Couanet D, Doz F *et al.* Prospective validation of a novel IV busulfan fixed dosing for paediatric patients to improve therapeutic AUC targeting without drug monitoring. *Cancer Chemother Pharmacol* 2008; **61**: 113–123.
10 Stein J, Davidovitz M, Yaniv I, Ben-Ari J, Gamzu Z, Hoffer E *et al.* Accidental busulfan overdose: enhanced drug clearance with hemodialysis in a child with Wiskott-Aldrich syndrome. *Bone Marrow Transplant* 2001; **27**: 551–553.