

REFERENCES

1. Gatter KC, Warnke RA: Intravascular large B-cell lymphoma, in Jaffe ES, Harris NL, Stein H, Vardiman JW (eds): World Health Organization: Pathology and Genetics of Tumors of Haematopoietic and Lymphoid Tissues. Lyon, France, IARC Press, 2001, pp 177-178
2. Ponzone M, Ferreri AJ, Campo E, et al: Definition, diagnosis, and management of intravascular large B-cell lymphoma: Proposals and perspectives from an international consensus meeting. *J Clin Oncol* 25:3168-3173, 2007
3. Murase T, Nakamura S, Kawauchi K, et al: An Asian variant of intravascular large B-cell lymphoma: Clinical, pathological and cytogenetic approaches to diffuse large B-cell lymphoma associated with haemophagocytic syndrome. *Br J Haematol* 111:826-834, 2000
4. Ferreri AJ, Campo E, Seymour JF, et al: Intravascular lymphoma: Clinical presentation, natural history, management and prognostic factors in a series of 38 cases, with special emphasis on the 'cutaneous variant'. *Br J Haematol* 127:173-183, 2004
5. Anghel G, Petrino G, Severino A, et al: Intravascular B-cell lymphoma: Report of two cases with different clinical presentation but rapid central nervous system involvement. *Leuk Lymphoma* 44:1353-1359, 2003
6. Monteiro M, Duarte I, Cabecadas J, et al: Intravascular large B-cell lymphoma of the breast. *Breast* 14:75-78, 2005
7. Domizio P, Hall PA, Cotter F, et al: Angiotropic large cell lymphoma (ALCL): Morphological, immunohistochemical and genotypic studies with analysis of previous reports. *Hematol Oncol* 7:195-206, 1989
8. Gill S, Melosky B, Haley L, et al: Use of random skin biopsy to diagnose intravascular lymphoma presenting as fever of unknown origin. *Am J Med* 114:56-58, 2003
9. Narimatsu H, Morishita Y, Saito S, et al: Usefulness of bone marrow aspiration for definite diagnosis of Asian variant of intravascular lymphoma: Four autopsied cases. *Leuk Lymphoma* 45:1611-1616, 2004
10. Estalilla OC, Koo CH, Brynes RK, et al: Intravascular large B-cell lymphoma: A report of five cases initially diagnosed by bone marrow biopsy. *Am J Clin Pathol* 112:248-255, 1999
11. DiGiuseppe JA, Nelson WG, Seifter EJ, et al: Intravascular lymphomatosis: A clinicopathologic study of 10 cases and assessment of response to chemotherapy. *J Clin Oncol* 12:2573-2579, 1994
12. Ferreri AJ, Campo E, Ambrosetti A, et al: Anthracycline-based chemotherapy as primary treatment for intravascular lymphoma. *Ann Oncol* 15:1215-1221, 2004
13. Sonneveld P, de Ridder M, van der Lelie H, et al: Comparison of doxorubicin and mitoxantrone in the treatment of elderly patients with advanced diffuse non-Hodgkin's lymphoma using CHOP versus CNOP chemotherapy. *J Clin Oncol* 13:2530-2539, 1995
14. Reff ME, Carner K, Chambers KS, et al: Depletion of B cells in vivo by a chimeric mouse human monoclonal antibody to CD20. *Blood* 83:435-445, 1994
15. Maloney DG, Liles TM, Czerwinski DK, et al: Phase I clinical trial using escalating single-dose infusion of chimeric anti-CD20 monoclonal antibody (IDEC-C2B8) in patients with recurrent B-cell lymphoma. *Blood* 84:2457-2466, 1994
16. Maloney DG, Grillo-Lopez AJ, Bodkin DJ, et al: IDEC-C2B8: Results of a phase I multiple-dose trial in patients with relapsed non-Hodgkin's lymphoma. *J Clin Oncol* 15:3266-3274, 1997
17. Coiffier B, Lepage E, Briere J, et al: CHOP chemotherapy plus rituximab compared with CHOP alone in elderly patients with diffuse large-B-cell lymphoma. *N Engl J Med* 346:235-242, 2002
18. Pfreundschuh M, Trumper L, Osterborg A, et al: CHOP-like chemotherapy plus rituximab versus CHOP-like chemotherapy alone in young patients with good-prognosis diffuse large-B-cell lymphoma: A randomised controlled trial by the MabThera International Trial (MInT) Group. *Lancet Oncol* 7:379-391, 2006
19. Shimizu I, Ichikawa N, Yotsumoto M, et al: Asian variant of intravascular lymphoma: Aspects of diagnosis and the role of rituximab. *Intern Med* 46:1381-1386, 2007
20. Bouzani M, Karmiris T, Rontogianni D, et al: Disseminated intravascular B-cell lymphoma: Clinicopathological features and outcome of three cases treated with anthracycline-based immunochemotherapy. *Oncologist* 11:923-928, 2006
21. Bazhenova L, Higginbottom P, Mason J: Intravascular lymphoma: A role for single-agent rituximab. *Leuk Lymphoma* 47:337-341, 2006
22. Byrd JC, Waselenko JK, Maneatis TJ, et al: Rituximab therapy in hematologic malignancy patients with circulating blood tumor cells: Association with increased infusion-related side effects and rapid blood tumor clearance. *J Clin Oncol* 17:791-795, 1999
23. Murase T, Yamaguchi M, Suzuki R, et al: Intravascular large B-cell lymphoma (IVLBCL): A clinicopathologic study of 96 cases with special reference to the immunophenotypic heterogeneity of CD5. *Blood* 109:478-485, 2007
24. Trotti A, Colevas AD, Setzer A, et al: CTCAE v3.0: Development of a comprehensive grading system for the adverse effects of cancer treatment. *Semin Radiat Oncol* 13:176-181, 2003
25. A predictive model for aggressive non-Hodgkin's lymphoma. The International Non-Hodgkin's Lymphoma Prognostic Factors Project. *N Engl J Med* 329:987-994, 1993
26. Nyman H, Adde M, Karjalainen-Lindsberg ML, et al: Prognostic impact of immunohistochemically defined germinal center phenotype in diffuse large B-cell lymphoma patients treated with immunochemotherapy. *Blood* 109:4930-4935, 2007
27. Wu SJ, Chou WC, Ko BS, et al: Severe pulmonary complications after initial treatment with rituximab for the Asian-variant of intravascular lymphoma. *Haematologica* 92:141-142, 2007
28. Martusewicz-Boros M, Wiatr E, Radzikowska E, et al: Pulmonary intravascular large B-cell lymphoma as a cause of severe hypoxemia. *J Clin Oncol* 25:2137-2139, 2007
29. Matsue K, Takeuchi M, Uryu H, et al: Rapid improvement of hypoxemia by the use of rituximab in patients with pulmonary intravascular lymphoma. *Leuk Lymphoma* 48:197-200, 2007
30. Sawamoto A, Narimatsu H, Suzuki T, et al: Long-term remission after autologous peripheral blood stem cell transplantation for relapsed intravascular lymphoma. *Bone Marrow Transplant* 37:233-234, 2006
31. Koizumi M, Nishimura M, Yokota A, et al: Successful treatment of intravascular malignant lymphomatosis with high-dose chemotherapy and autologous peripheral blood stem cell transplantation. *Bone Marrow Transplant* 27:1101-1103, 2001
32. Yamaguchi M, Kimura M, Watanabe Y, et al: Successful autologous peripheral blood stem cell transplantation for relapsed intravascular lymphomatosis. *Bone Marrow Transplant* 27:89-91, 2001

Acknowledgment

The Acknowledgment is included in the full-text version of this article, available online at www.jco.org. It is not included in the PDF version (via Adobe® Reader®).

Evaluation of organ involvement in intravascular large B-cell lymphoma by ^{18}F -fluorodeoxyglucose positron emission tomography

Kazuyuki Shimada · Hiroshi Kosugi · Satoko Shimada · Hiroto Narimatsu · Yoshitsugu Koyama · Nobuaki Suzuki · Masaaki Yuge · Hironori Nishibori · Yosuke Iwata · Shigeo Nakamura · Tomoki Naoe · Tomohiro Kinoshita

Received: 1 April 2008 / Revised: 22 April 2008 / Accepted: 28 April 2008
© The Japanese Society of Hematology 2008

Abstract To evaluate the role of ^{18}F -fluorodeoxyglucose positron emission tomography (FDG-PET) in intravascular large B-cell lymphoma (IVLBCL), we retrospectively analyzed four consecutive IVLBCL patients receiving FDG-PET before treatment between May 2006 and November 2007. Patients were two men and two women (median age 62 years, range 54–76 years). All patients received bone marrow biopsies and random skin biopsies and two of the four patients underwent renal biopsy for diagnosis. Accuracy of FDG-PET for the detection of organ involvements was analyzed by comparing results of pathological findings. Concordant results with respect to bone marrow involvement were accurately obtained for two patients. Skin and renal involvements were undetectable by FDG-PET regardless of positive pathological findings. One patient with a false-negative FDG-PET result

showed fewer lymphoma cells in the bone marrow specimen than patients with concordant FDG-PET results. These results suggest false-negative results for some types of organ involvement. Careful interpretation of the results of FDG-PET in IVLBCL is thus required.

Keywords Intravascular large B-cell lymphoma · FDG-PET · Diagnostic accuracy

1 Introduction

In the assessment of patients with Hodgkin lymphoma (HL) or non-Hodgkin's lymphoma (NHL), ^{18}F -fluorodeoxyglucose positron emission tomography (FDG-PET) has recently emerged as a powerful functional imaging tool [1]. The advantages of FDG-PET over conventional imaging techniques such as computed tomography (CT) and magnetic resonance imaging (MRI) lie in the ability to distinguish between viable tumor and necrosis or fibrosis in the residual masses that are often present after treatment [2]. This ability is thus expected to allow accurate assessment of pre-treatment staging and post-treatment effect. The recent revised response criteria for malignant lymphoma reveals that FDG-PET is highly recommended for initial and post-treatment assessment of diffuse large B-cell lymphoma (DLBCL) and HL [2].

Intravascular large B-cell lymphoma (IVLBCL) is a rare subtype of extranodal DLBCL as classified by the World Health Organization (WHO) [3]. IVLBCL is a rapidly progressive and often fatal disease, characterized by the selective growth of tumor cells in the lumina of small vessels in various organs [4]. If the efficacy of FDG-PET in IVLBCL is similar to that in nodal DLBCL, the technique will be useful for early diagnosis and prediction of organ

K. Shimada · H. Kosugi · Y. Koyama · N. Suzuki · M. Yuge
Department of Hematology,
Ogaki Municipal Hospital, Ogaki, Japan

K. Shimada (✉) · H. Narimatsu · T. Naoe · T. Kinoshita
Department of Hematology and Oncology,
Nagoya University Graduate School of Medicine,
65 Tsurumai-cho, Showa-ku, Nagoya 466-8550, Japan
e-mail: kshimada@med.nagoya-u.ac.jp

S. Shimada · S. Nakamura
Department of Pathology and Clinical Laboratories,
Nagoya University Hospital, Nagoya, Japan

H. Nishibori
Department of Radiology, Kizawa Memorial Hospital,
Minokamo, Japan

Y. Iwata
Department of Pathology, Ogaki Municipal Hospital,
Ogaki, Japan

damage in IVLBCL. However, the characteristics of extranodal expansion in IVLBCL may influence the ability of FDG-PET to detect disease involvement accurately [5–7]. Previous reports have revealed that FDG-PET is useful for the diagnosis of IVLBCL when this type of lymphoma is clinically suspected [8–11]. Unfortunately, these reports did not mention the accuracy of FDG-PET in detecting involvement of organs such as bone marrow, skin, liver, spleen or kidney, in which most cases of IVLBCL are diagnosed [12–14]. Whether FDG-PET is useful for initial assessment of disease involvement in IVLBCL is thus unclear.

To evaluate the accuracy of FDG-PET in detecting disease involvement of IVLBCL, we compared FDG-PET images with the results of pathological findings in four consecutive IVLBCL patients evaluated using FDG-PET before treatment.

2 Design and methods

2.1 Study design

To evaluate the role of FDG-PET in IVLBCL, we conducted a retrospective analysis of four consecutive patients (2 men, 2 women) with IVLBCL treated at Ogaki Municipal Hospital between May 2006 and November 2007. IVLBCL was diagnosed according to the WHO classification. Patients underwent FDG-PET and various organ biopsies for evaluation before the beginning of treatment. The accuracy of FDG-PET for detecting various organ involvements was analyzed by comparing the results of pathological findings.

2.2 Patients

Patient characteristics are shown in Table 1. Median age of patients at diagnosis was 62 years (range 54–76 years). In all patients, lymphoma displayed aggressive clinical behavior including high fever. Blood examination revealed high levels of serum lactate dehydrogenase (LDH), soluble interleukin-2 receptor (sIL-2R) and C-reactive protein (CRP).

2.3 FDG-PET

All patients underwent FDG-PET before beginning treatment. FDG-PET studies were acquired using two PET tomographs: a SET-3000 B/L (Shimadzu Corp., Kyoto, Japan) and an ADVANCE NXi Imaging System (General Electric Yokogawa Medical Systems, Tokyo, Japan). Patients had fasted ≥ 8 h and had no history of diabetes mellitus or blood glucose abnormalities at the time of

Table 1 Patient characteristics at FDG-PET study

Case	Age/sex	WBC (μl^{-1})	PLT ($\times 10^4 \mu\text{l}^{-1}$)	LDH (IU/l)	CRP (mg/dl)	Ferritin (ng/ml)	sIL-2R (U/l)	Disease site confirmed by pathological specimen	Positive imaging by FDG-PET	Therapy	Survival (day)
1	69/Female	970	4.4	2,118	16.11	NE	28,600	Bone marrow, skin, kidney	Spleen, stomach	PSL	11
2	54/Female	5,920	26.8	4,528	16.73	457	6,000	Kidney	Sternum, sacrum, bone, left iliac bone, left femur	R-CHOP	301+
3	76/Male	9,120	7.8	1,382	11.37	975	12,100	Bone marrow, skin	Diffuse bone	PSL, CPA + Dex	14
4	55/Male	3,980	6.5	607	13.68	564	5,880	Bone marrow	Diffuse bone, spleen	R-CHOP	62+

FDG-PET ^{18}F -fluorodeoxyglucose positron emission tomography, *WBC* white blood cell count, *PLT* platelet count, *LDH* lactate dehydrogenase, *CRP* C-reactive protein, *sIL-2R* soluble interleukin-2 receptor, *HPS* hemophagocytic syndrome, *PSL* prednisolone, *CPA* cyclophosphamide, *Dex* dexamethasone, *R-CHOP* rituximab, cyclophosphamide, vincristine, doxorubicin and prednisolone, *NE* not evaluated

FDG-PET. No patients had received any kind of hematopoietic growth factors or steroid therapies before diagnosis. The scan was started 60 min after administration of FDG (dose range 163–232 MBq) and performed from the proximal femur to the skull base. FDG-PET images were interpreted by two radiologists at Kizawa Memorial Hospital, Minokamo, Japan.

2.4 Pathological diagnosis

All patients received random skin and bone marrow biopsies. Skin biopsies were performed from three apparently healthy abdominal and femoral skin sites by dermatologists at Ogaki Municipal Hospital. Bone marrow biopsies were obtained from iliac bone. Renal biopsy was performed for two of the four patients. One patient (Patient 1) received biopsies including stomach according to the findings of FDG-PET. The other patients received biopsies before receiving FDG-PET. Tumor cells were confirmed by CD20 and/or CD79a immunohistochemical staining in organ biopsy specimens. Diagnoses were made by consensus agreement of three expert pathologists (Y.I., S.S. and S.N.) at Ogaki Municipal Hospital and Nagoya University Hospital.

3 Results

3.1 FDG-PET

All patients revealed various patterns on FDG-PET. Accumulation of FDG in the bone was observed in three of four patients (Fig. 1a), as patchy accumulation in one patient and diffuse accumulation two patients. The remaining patient without bone accumulation displayed spleen and stomach accumulation (Fig. 1b). No patient revealed renal or skin accumulation. The highest standardized uptake value (SUV) reached 8–14 in diffuse bone accumulation.

3.2 Site of pathological diagnosis of IVLBCL

Bone marrow and skin involvements were detected in three and two patients, respectively. Both patients who received renal biopsy displayed disease in the pathological specimens. No disease was detected in the gastric biopsy specimen.

3.3 Accuracy of disease detection by FDG-PET

FDG-PET images were further evaluated for accuracy of detecting various organ involvements by comparing results with various organ biopsies. These results are summarized

in Table 2. In two of the four patients, concordant results were obtained with respect to bone marrow involvement (Fig. 1c). In the remaining two patients, the results of pathological diagnosis and FDG-PET were discordant (Fig. 1d). False-negative and false-positive findings were observed in one patient each. One patient with a false-negative FDG-PET result showed fewer lymphoma cells in the bone marrow specimen than patients with concordant FDG-PET results (Fig. 1c, d). We were unable to detect renal or skin involvement by FDG-PET, despite positive pathological findings (Fig. 1e, f).

4 Discussion

In the assessment of IVLBCL, caution must be exercised when interpreting the results of FDG-PET. In our study, FDG-PET was able to detect only two of seven pathologically confirmed lesions (29%). Usefulness of FDG-PET in the initial assessment of IVLBCL and the evaluation of therapeutic effects may be limited.

In patients with nodal DLBCL, FDG-PET has been shown to detect at least one lesion 100% of the time [6, 7, 15]. Several reasons contribute to these extremely contrasting findings. First, FDG uptake may be lower in IVLBCL cells than in DLBCL cells. However, this seems unlikely given that IVLBCL is a subtype of DLBCL, and IVLBCL and DLBCL are histopathologically and genetically similar [3, 4, 12]. Furthermore, in our patients, the results of tests on the initial visit, such as markedly high LDH and rapidly progressing clinical course indicated rapidly proliferating IVLBCL cells, which would be associated with rapid sugar consumption due to high IVLBCL cell turnover. These findings suggest that FDG uptake of IVLBCL cells is no lower than DLBCL. Second, the difference may be due to the kinetics of FDG in the body. FDG accumulates in the brain, kidney and bladder, so lesions in these organs are difficult to identify [16]. In fact, renal lesions could not be detected in our study. In certain organs where FDG naturally accumulates, lymphoma infiltration may be underestimated. Third, differences may exist in the localization of tumor cells between DLBCL and IVLBCL. The biggest difference with nodal DLBCL is that tumor cells invade extranodal vessels in IVLBCL. Tumor cells invade diffusely in IVLBCL and compared to DLBCL, which comprises solid tumor, the volume of regional tumor is lower. In fact, in the present study, when FDG-PET and biopsy findings matched, the number of tumor cells tended to be higher. Moreover, even with DLBCL, FDG-PET is less reliable for extranodal cases, particularly marrow infiltration [7]. This indicates that the number of tumor cells per volume is lower for marrow infiltration than for nodal lesions, supporting our deduction.

Fig. 1 FDG-PET image and pathological findings of organ biopsies. **a** FDG-PET for Patient 3. Diffuse accumulation of FDG was observed in systemic bone. Maximum SUV reached 8 to 14. **b** FDG-PET for Patient 1. Accumulation of FDG was observed in the stomach and spleen, but not in bone. **c** Concordant results for bone marrow. Bone marrow aspiration revealed a number of CD20+ lymphoma cells with diffuse and intrasinusoidal pattern. Lymphoma cells were uniformly distributed in the specimen (CD20 immunostain $\times 200$). **d** Discordant (false-negative) results in bone marrow. Bone marrow aspiration revealed few CD20+ lymphoma cells with an intrasinusoidal pattern. Lymphoma cells were focally distributed in the specimen (CD20 immunostain $\times 200$, inset $\times 400$). **e** Discordant (false-negative) results in the kidney. Renal biopsy revealed lymphoma cells in glomerular capillaries (H&E $\times 200$). **f** Discordant (false-negative) results in the skin. Skin biopsy revealed lymphoma cell in small vessels of the dermis (H&E $\times 200$)

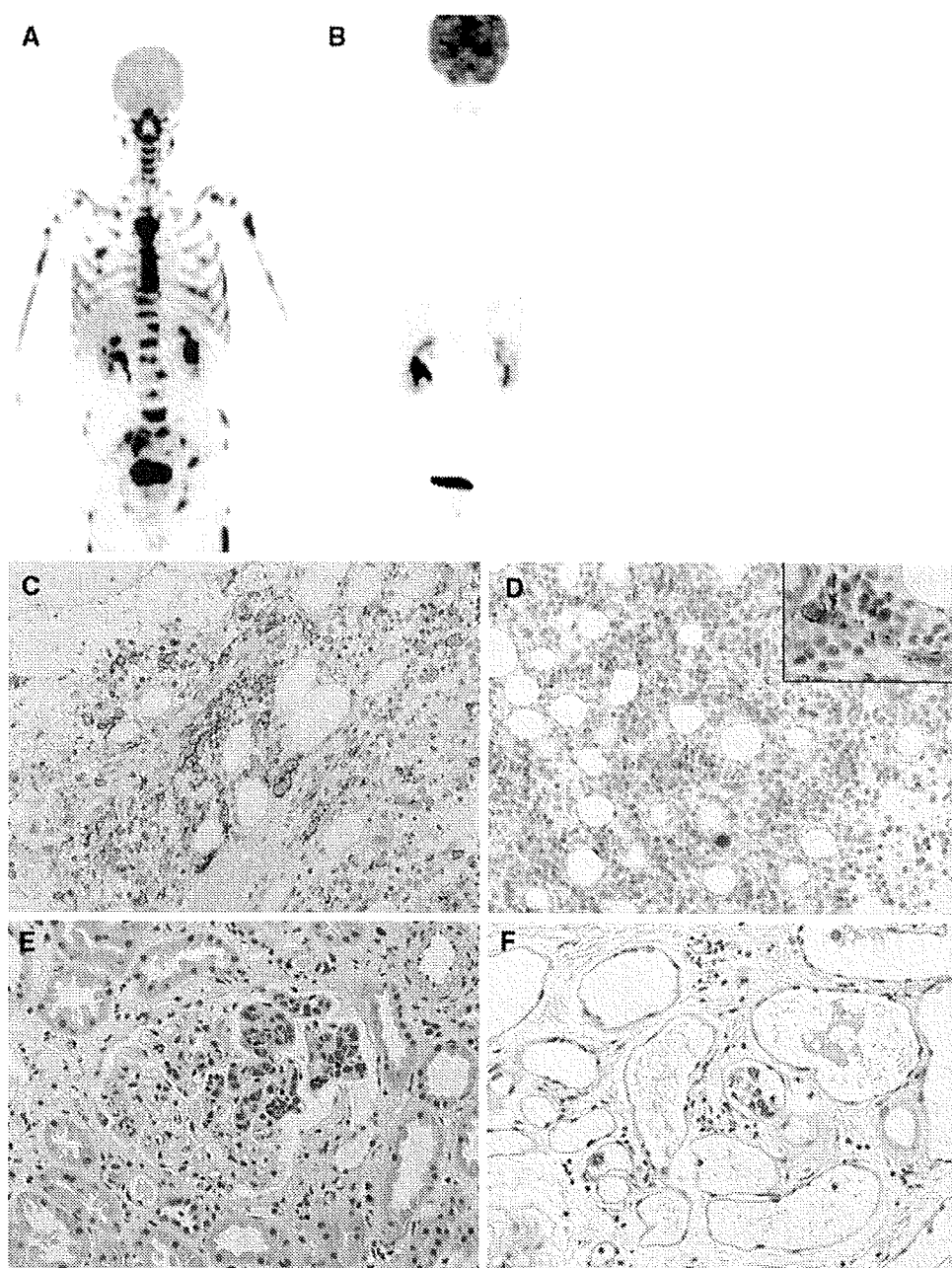


Table 2 Diagnostic accuracy of FDG-PET by anatomical site

Diagnostic site	Concordant		Discordant		Total
	Positive	Negative	FDG-PET-positive, biopsy-negative	FDG-PET-negative, biopsy-positive	
Bone marrow	2	0	1	1	4
Kidney	0	0	0	2	2
Skin	0	2	0	2	4
Stomach	0	0	1	0	1

All the numerical data indicate the number of patients

In the present study, although diagnostic accuracy was lower compared to nodal DLBCL, FDG-PET was useful in identifying IVLBCL in several regards. First, PET gathers useful information that cannot be obtained by conventional diagnostic methods. As no solid lesions are present with IVLBCL, CT cannot detect lesions. Biopsy thus offers the only other diagnostic method, but determining where to perform biopsy is often difficult. With PET, accurate diagnosis may be made sooner by examining areas with FDG accumulation. In fact, when affected areas could not be identified in patients exhibiting clinical symptoms associated with IVLBCL, FDG-PET was performed and accurate diagnoses were made by taking biopsy samples

from areas with FDG accumulation [9, 10]. Second, the use of FDG-PET may improve the safety of therapy for IVLBCL. Recently, we have reported the usefulness of rituximab-containing chemotherapies for IVLBCL [17], but about 30% of IVLBCL patients display respiratory symptoms [12, 17], and rituximab infusion can reportedly cause severe respiratory complications [18]. If FDG-PET shows a pulmonary lesion, premedication may avoid complications. In the future, investigation of the significance of PET in rituximab therapy will be necessary.

The present study revealed characteristic FDG-PET findings for IVLBCL. In the future, a study focusing on the usefulness of FDG-PET in IVLBCL is needed.

References

- Juweid ME, Stroobants S, Hoekstra OS, Mottaghy FM, Dietlein M, Guermazi A, et al. Use of positron emission tomography for response assessment of lymphoma: consensus of the Imaging Subcommittee of International Harmonization Project in Lymphoma. *J Clin Oncol*. 2007;25:571–8.
- Cheson BD, Pfistner B, Juweid ME, Gascoyne RD, Specht L, Horning SJ, et al. Revised response criteria for malignant lymphoma. *J Clin Oncol*. 2007;25:579–86.
- Gatter KC, Warnke RA. Intravascular large B-cell lymphoma. In: Jaffe ES, Harris NL, Stein H, Vardiman JW (eds) *World Health Organization: pathology and genetics of tumors of haematopoietic and lymphoid tissues*. Lyon: IARC;2001. pp. 177–8.
- Ponzoni M, Ferreri AJ, Campo E, Facchetti F, Mazzucchelli L, Yoshino T, et al. Definition, diagnosis, and management of intravascular large B-cell lymphoma: proposals and perspectives from an international consensus meeting. *J Clin Oncol*. 2007;25:3168–73.
- Wirth A, Seymour JF, Hicks RJ, Ware R, Fisher R, Prince M, et al. Fluorine-18 fluorodeoxyglucose positron emission tomography, gallium-67 scintigraphy, and conventional staging for Hodgkin's disease and non-Hodgkin's lymphoma. *Am J Med*. 2002;112:262–8.
- Hernandez-Maraver D, Hernandez-Navarro F, Gomez-Leon N, Coya J, Rodriguez-Vigil B, Madero R, et al. Positron emission tomography/computed tomography: diagnostic accuracy in lymphoma. *Br J Haematol*. 2006;135:293–302.
- Elstrom R, Guan L, Baker G, Nakhoda K, Vergilio JA, Zhuang H, et al. Utility of FDG-PET scanning in lymphoma by WHO classification. *Blood*. 2003;101:3875–6.
- Odawara J, Asada N, Aoki T, Yamakura M, Takeuchi M, Ohuchi T, et al. 18F-Fluorodeoxyglucose positron emission tomography for evaluation of intravascular large B-cell lymphoma. *Br J Haematol*. 2007;136:684.
- Lannoo L, Smets S, Steenkiste E, Delforge M, Moerman P, Stroobants S, et al. Intravascular large B-cell lymphoma of the uterus presenting as fever of unknown origin (FUO) and revealed by FDG-PET. *Acta Clin Belg*. 2007;62:187–90.
- Hoshino A, Kawada E, Ukita T, Itoh K, Sakamoto H, Fujita K, et al. Usefulness of FDG-PET to diagnose intravascular lymphomatosis presenting as fever of unknown origin. *Am J Hematol*. 2004;76:236–9.
- Hofman MS, Fields P, Yung L, Mikhael NG, Ireland R, Nunan T. Meningeal recurrence of intravascular large B-cell lymphoma: early diagnosis with PET-CT. *Br J Haematol*. 2007;137:386.
- Murase T, Yamaguchi M, Suzuki R, Okamoto M, Sato Y, Tamaru J, et al. Intravascular large B-cell lymphoma (IVLBCL): a clinicopathologic study of 96 cases with special reference to the immunophenotypic heterogeneity of CD5. *Blood*. 2007;109:478–85.
- Gill S, Melosky B, Haley L, Chan Yan C. Use of random skin biopsy to diagnose intravascular lymphoma presenting as fever of unknown origin. *Am J Med*. 2003;114:56–8.
- Asada N, Odawara J, Kimura S, Aoki T, Kamakura M, Takeuchi M, et al. Use of random skin biopsy for diagnosis of intravascular large B-cell lymphoma. *Mayo Clin Proc*. 2007;82:1525–7.
- Seam P, Juweid ME, Cheson BD. The role of FDG-PET scans in patients with lymphoma. *Blood*. 2007;110:3507–16.
- Rosenbaum SJ, Lind T, Antoch G, Bockisch A. False-positive FDG PET uptake—the role of PET/CT. *Eur Radiol*. 2006;16:1054–65.
- Shimada K, Matsue K, Yamamoto K, Murase T, Ichikawa N, Okamoto M, et al. A retrospective analysis of intravascular large B-cell lymphoma treated with rituximab-containing chemotherapies as reported by the IVL study group in Japan. *J Clin Oncol*. 2008 (in press)
- Wu SJ, Chou WC, Ko BS, Tien HF. Severe pulmonary complications after initial treatment with Rituximab for the Asian-variant of intravascular lymphoma. *Haematologica*. 2007;92:141–2.

Case Study

Sustained Remission after Rituximab-containing Chemotherapy for Intravascular Large B-cell Lymphoma

Kazuyuki Shimada,^{1,2)} Hiroshi Kosugi,¹⁾ Hiroto Narimatsu,²⁾ Satoko Shimada,³⁾ Tatsuya Suzuki,^{1,2)} Masafumi Ito,⁴⁾ Tomohiro Kinoshita,²⁾ Naoyoshi Mori,³⁾ and Tomoki Naoe²⁾

Intravascular large B-cell lymphoma (IVL) is rare aggressive disseminated lymphoma associated with poor outcomes. Rituximab is a novel molecular agent that can reportedly improve outcomes for patients with diffuse large B-cell lymphoma. However, the safety and efficacy of rituximab in patients with IVL are unclear. A 76-year-old woman was hospitalized due to altered consciousness, fever and respiratory abnormalities. Definitive diagnosis of IVL was obtained following repeated biopsies of bone marrow. The patient received chemotherapy consisting of cyclophosphamide, vincristine, doxorubicin, prednisolone, and rituximab (R-CHOP), and achieved complete remission after 3 courses of treatment. She has remained in complete remission for over 3 years after diagnosis. This report suggests that rituximab-containing regimens could be safe and effective for elderly patients with IVL. [*J Clin Exp Hematopathol* 48(1): 25-28, 2008]

Keywords: intravascular large B-cell lymphoma, rituximab, combination chemotherapy

INTRODUCTION

Intravascular large B-cell lymphoma (IVL) is a rare subtype of extranodal diffuse large B-cell lymphoma (DLBCL), as classified by the World Health Organization.¹ IVL is a rapidly aggressive disseminated disease, characterized by the presence of lymphoma cells only in the lumina of small vessels of the central nervous system, skin, lungs, kidneys, and bone marrow, without marked lymphadenopathy. The absence of IVL in traditional sites of lymphoma presentation makes accurate and timely diagnosis difficult. In previous reports, around half of patients have been diagnosed post mortem,² and repeated biopsies of skin, kidney, and bone marrow are often necessary for the diagnosis of this type of lymphoma.^{3,4}

Left untreated, IVL is uniformly fatal. Steroids generally

provided only transient improvement.² Most therapeutic regimens were ineffective, with a median survival of several months from the date of clinical presentation.^{4,5} Recently, anthracycline-containing chemotherapy has been reported to improve clinical outcomes of patients with IVL. Ferreri *et al.* reported an overall 3-year survival rate of 33% and a response rate of 59% in the patients who received anthracycline-containing chemotherapy.⁶ Murase *et al.* reported a median survival duration for IVL patients receiving anthracycline-based chemotherapy of 13 months.⁷ Considering that most IVL patients are categorized in the high-risk group according to the International Prognostic Index,⁷ the survival of IVL patients is probably comparable to that of patients with DLBCL.⁸ Thus anthracycline-containing chemotherapies appear to be useful, and that the poor prognosis of IVL⁹ might be attributable to delayed initiation of chemotherapy.

Rituximab is a novel monoclonal antibody against CD20 B-cell antigen. The addition of rituximab to the CHOP regimen has been found to improve treatment outcomes in patients with DLBCL.¹⁰ Recent reports suggest the efficacy of rituximab for the treatment of IVL,^{11,12} however, the scale of these studies was small and the long term outcomes remain unclear.

CASE REPORT

A 76-year-old woman with no past medical history of note was admitted to Ogaki Municipal Hospital in July 2003 with a one-week history of continuous malaise, headache, and leth-

Received : Mar 22, 2007

Revised : Jun 3, 2007

Accepted : Jul 3, 2007

¹⁾Department of Hematology, Ogaki Municipal Hospital, 4-86 Minaminokawa-cho, Ogaki-shi, Gifu 503-8502, Japan

²⁾Department of Hematology and Oncology, Nagoya University Graduate School of Medicine, 65 Tsurumai-cho, Showa-ku, Nagoya 466-8550, Japan

³⁾Department of Pathology of Biological Response, Nagoya University Graduate School of Medicine, 65 Tsurumai-cho, Showa-ku, Nagoya 466-8550, Japan

⁴⁾Department of Pathology, Japanese Red Cross, Nagoya First Hospital, 3-35 Michishita-cho, Nakamura-ku, Nagoya 453-8511, Japan

Address correspondence and reprint request to Kazuyuki Shimada, Department of Hematology and Oncology, Nagoya University Graduate School of Medicine, 65 Tsurumai-cho, Showa-ku, Nagoya 466-8550, Japan

E-mail : kshimada@med.nagoya-u.ac.jp

argy. After admission, she developed neurological signs including disorientation and unresponsiveness, in addition to a persistent fever. Blood examination revealed: white blood cell count, 6,280/ μ L; red blood cell count, 380 x 10⁴/ μ L; hemoglobin, 11.3 g/dL; and platelet count, 25.3 x 10⁴/ μ L. Laboratory studies showed: aspartate aminotransferase, 90 IU/L; alanine aminotransferase, 79 IU/L; C-reactive protein, 10.2 mg/dL; lactate dehydrogenase (LDH), 2249 IU/L (normal range: 130-450 IU/L); and ferritin, 846.5 ng/mL. Soluble IL-2 receptor (sIL-2R) was elevated to 7955 U/L. Physical examination showed no systemic lymphadenopathy, splenomegaly or focal neurological deficits. Arterial blood gas analysis demonstrated respiratory insufficiency with a partial pressure of arterial oxygen (PaO₂) of 48.5 mmHg without hypercapnia. Computed tomography (CT) of the abdomen revealed mild splenomegaly without lymphadenopathy or hepatomegaly. Transbronchial lung biopsy revealed no evidence of malignancy. CT of the brain showed no marked abnormalities. Bone marrow aspiration revealed hemophagocytic syndrome, but no evidence of malignancy.

In addition, skin and renal biopsies were negative. However, repeat bone marrow examination revealed CD20-positive lymphoma cells in the lumen of vessels (Fig. 1). These lymphoma cells were immunohistochemically negative for CD3, CD10, MUM-1, and Bcl-6. IVL was subsequently diagnosed on the basis of the CD20-positive intraluminal lymphoma cells in October 2003.

The patient's respiratory failure and neurological manifestations resolved spontaneously following her first admission within 4 weeks. The patient was then discharged from the hospital without the definitive diagnosis of IVL. Three months later, she developed fever with elevated sIL-2R and

chemotherapy was initiated. Initially she was treated with cyclophosphamide, doxorubicin, vincristine, and prednisolone (CHOP) alone as a first course. Subsequently, rituximab was added to CHOP regimen at the time of her second course of chemotherapy (R-CHOP). The patient received acetaminophen and diphenhydramine as premedication for rituximab. No infusion reaction occurred with any of the administrations. Her fever improved after starting chemotherapy, and sIL-2R and LDH levels normalized. The patient did not require any delay in administration or dose reduction and achieved complete remission after 3 cycles of R-CHOP with resolution of clinical symptoms, and normalization of clinical laboratory tests and bone marrow findings. As of the time of writing, the patient remains alive and in complete remission over 3 years after diagnosis.

DISCUSSION

The present report describes a sustained 3 year remission following a R-CHOP regimen for the treatment of IVL in an elderly patient. Our result is consistent with previous reports about rituximab therapy for IVL patients.^{11,12} These reports, in addition to ours, suggest that rituximab-containing regimens improve clinical outcomes for patients with IVL, as well as in patients with DLBCL.¹⁰

A recent report using cDNA microarrays has revealed that DLBCL can be divided into subgroups; germinal center B-cell (GCB) type and activated B-cell (ABC) type.¹³ Hans *et al.* found that these subtypes could be accurately identified according to immunohistochemical expression patterns of CD10, bcl-6, and MUM-1.¹⁴ In our patient, lymphoma cells were regarded as non-germinal center B-cell (non-GCB) type due to an immunoprofile negative for CD10, bcl-6, and MUM-1 staining. Murase *et al.* revealed that most IVL cells belong to the non-GCB type.⁷ Recent reports indicate that non-GCB type DLBCL benefits from the addition of rituximab to CHOP, whereas the GCB type does not.^{15,16} Our experience suggests that this classification is useful for predicting treatment responses in IVL. However, further large-scale studies are warranted.

Patients possessing a high number of tumor cells in their peripheral blood have been reported to develop severe infusion reactions induced by rituximab.¹⁷ IVL patients with a high tumor burden in their vessels possibly are at risk for infusion reactions. In addition, respiratory distress syndrome following rituximab infusion has been reported.¹⁸ In our patient, respiratory insufficiency with a low PaO₂ was observed at the time of her first admission. Thus, we omitted the addition of rituximab over concern of infusion reaction in the first course of chemotherapy. Due to our therapeutic strategies against infusion reactions, no infusion reactions occurred in the clinical course of our patient. The addition of rituximab during second course or later of chemotherapy was

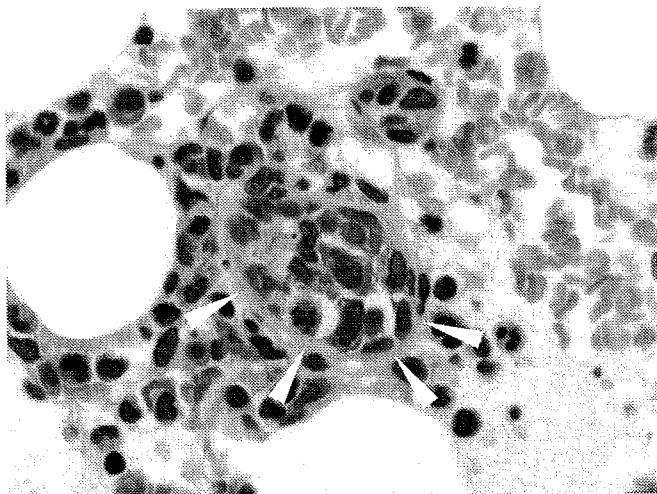


Fig. 1. Hematoxylin and eosin staining in bone marrow clot. The white arrows indicate tumor cells present in lumens of small vessels. These cells were highlighted by staining for CD20. Original magnification x400.

safe, without adverse events of rituximab.

Several reports have revealed long-term survival after autologous hematopoietic stem cell transplantation for IVL, not only in patients who achieved complete remission but also in patients with relapsed disease.¹⁹⁻²¹ However, transplantation is not a feasible option for most IVL patients of advanced age. Our patient was too elderly to receive autologous hematopoietic stem cell transplantation. Conversely, the R-CHOP regimen is reportedly feasible for elderly patients.¹⁰ Actually, the present patient completed 8 courses of R-CHOP regimen without any marked adverse effects. Considering the high median age for IVL (67 years), R-CHOP might be feasible for most IVL patients.⁶ The safety and efficacy of an R-CHOP regimen for elderly IVL patients should be investigated in further studies.

Several cases of central nervous system relapse were recently reported.^{22,23} Although our patient has maintained complete remission without intrathecal infusion, intrathecal chemotherapy as a precaution against central nervous system relapse may be worth investigating in future studies.

In summary, we report an elderly patient with IVL who achieved sustained remission after receiving R-CHOP without requiring steroids and antibiotics. Due to this atypical clinical course, further careful follow-up of this patient is needed.

REFERENCES

- Harris NL, Jaffe ES, Diebold J, Flandrin G, Muller-Hermelink HK, Vardiman J, Lister TA, Bloomfield CD: World Health Organization classification of neoplastic diseases of the hematopoietic and lymphoid tissues: report of the Clinical Advisory Committee meeting-Airlie House, Virginia, November 1997. *J Clin Oncol* 17: 3835-3849, 1999
- Domizio P, Hall PA, Cotter F, Amiel S, Tucker J, Besser GM, Levison DA: Angiotropic large cell lymphoma (ALCL): morphological, immunohistochemical and genotypic studies with analysis of previous reports. *Hematol Oncol* 7: 195-206, 1989
- Narimatsu H, Morishita Y, Saito S, Shimada K, Ozeki K, Kohno A, Kato Y, Nagasaka T: Usefulness of bone marrow aspiration for definite diagnosis of Asian variant of intravascular lymphoma: four autopsied cases. *Leuk Lymphoma* 45: 1611-1616, 2004
- DiGiuseppe JA, Nelson WG, Seifter EJ, Boitnott JK, Mann RB: Intravascular lymphomatosis: a clinicopathologic study of 10 cases and assessment of response to chemotherapy. *J Clin Oncol* 12: 2573-2579, 1994
- Murase T, Nakamura S, Kawauchi K, Matsuzaki H, Sakai C, Inaba T, Nasu K, Tashiro K, Suchi T, Saito H: An Asian variant of intravascular large B-cell lymphoma: clinical, pathological and cytogenetic approaches to diffuse large B-cell lymphoma associated with haemophagocytic syndrome. *Br J Haematol* 111: 826-834, 2000
- Ferreri AJ, Campo E, Ambrosetti A, Ilariucci F, Seymour JF, Willemze R, Arrigoni G, Rossi G, López-Guillermo A, Berti E,

- Eriksson M, Federico M, Cortelazzo S, Govi S, Frungillo N, Dell'Oro S, Lestani M, Asioli S, Pedrinis E, Ungari M, Motta T, Rossi R, Artusi T, Iuzzolino P, Zucca E, Cavalli F, Ponzoni M: Anthracycline-based chemotherapy as primary treatment for intravascular lymphoma. *Ann Oncol* 15: 1215-1221, 2004
- Murase T, Yamaguchi M, Suzuki R, Okamoto M, Sato Y, Tamaru J, Kojima M, Miura I, Mori N, Yoshino T, Nakamura S: Intravascular large B-cell lymphoma (IVLBCL): a clinicopathologic study of 96 cases with special reference to the immunophenotypic heterogeneity of CD5. *Blood* 109: 478-485, 2007
- Sonneveld P, de Ridder M, van der Lelie H, Nieuwenhuis K, Schouten H, Mulder A, van Reijswoud I, Hop W, Lowenberg B: Comparison of doxorubicin and mitoxantrone in the treatment of elderly patients with advanced diffuse non-Hodgkin's lymphoma using CHOP versus CNOP chemotherapy. *J Clin Oncol* 13: 2530-2539, 1995
- Zuckerman D, Seliem R, Hochberg E: Intravascular lymphoma: the oncologist's "great imitator". *Oncologist* 11: 496-502, 2006
- Coiffier B, Lepage E, Briere J, Herbrecht R, Tilly H, Bouabdallah R, Morel P, Van Den Neste E, Salles G, Gaulard P, Reyes F, Lederlin P, Gisselbrecht C: CHOP chemotherapy plus rituximab compared with CHOP alone in elderly patients with diffuse large-B-cell lymphoma. *N Engl J Med* 346: 235-242, 2002
- Bouzani M, Karmiris T, Rontogianni D, Delimpasi S, Apostolidis J, Mpakiri M, Nikiforakis E: Disseminated intravascular B-cell lymphoma: clinicopathological features and outcome of three cases treated with anthracycline-based immunochemotherapy. *Oncologist* 11: 923-928, 2006
- Bazhenova L, Higginbottom P, Mason J: Intravascular lymphoma: a role for single-agent rituximab. *Leuk Lymphoma* 47: 337-341, 2006
- Alizadeh AA, Eisen MB, Davis RE, Ma C, Lossos IS, Rosenwald A, Boldrick JC, Sabet H, Tran T, Yu X, Powell JJ, Yang L, Marti GE, Moore T, Hudson J Jr, Lu L, Lewis DB, Tibshirani R, Sherlock G, Chan WC, Greiner TC, Weisenburger DD, Armitage JO, Warnke R, Levy R, Wilson W, Grever MR, Byrd JC, Botstein D, Brown PO, Staudt LM: Distinct types of diffuse large B-cell lymphoma identified by gene expression profiling. *Nature* 403: 503-511, 2000
- Hans CP, Weisenburger DD, Greiner TC, Gascoyne RD, Delabie J, Ott G, Muller-Hermelink HK, Campo E, Braziel RM, Jaffe ES, Pan Z, Farinha P, Smith LM, Falini B, Banham AH, Rosenwald A, Staudt LM, Connors JM, Armitage JO, Chan WC: Confirmation of the molecular classification of diffuse large B-cell lymphoma by immunohistochemistry using a tissue microarray. *Blood* 103: 275-282, 2004
- Winter JN, Weller EA, Horning SJ, Krajewska M, Variakojis D, Habermann TM, Fisher RI, Kurtin PJ, Macon WR, Chhanabhai M, Felgar RE, Hsi ED, Medeiros LJ, Weick JK, Reed JC, Gascoyne RD: Prognostic significance of Bcl-6 protein expression in DLBCL treated with CHOP or R-CHOP: a prospective correlative study. *Blood* 107: 4207-4213, 2006
- Nyman H, Adde M, Karjalainen-Lindsberg ML, Taskinen M,

- Berglund M, Amini RM, Blomqvist C, Enblad G, Leppa S : Prognostic impact of immunohistochemically defined germinal center phenotype in diffuse large B-cell lymphoma patients treated with immunochemotherapy. *Blood* 109 : 4930-4935, 2007
- 17 Byrd JC, Waselenko JK, Maneatis TJ, Murphy T, Ward FT, Monahan BP, Sipe MA, Donegan S, White CA : Rituximab therapy in hematologic malignancy patients with circulating blood tumor cells : association with increased infusion-related side effects and rapid blood tumor clearance. *J Clin Oncol* 17 : 791-795, 1999
- 18 Wu SJ, Chou WC, Ko BS, Tien HF : Severe pulmonary complications after initial treatment with Rituximab for the Asian-variant of intravascular lymphoma. *Haematologica* 92 : 141-142, 2007
- 19 Koizumi M, Nishimura M, Yokota A, Munekata S, Kobayashi T, Saito Y : Successful treatment of intravascular malignant lymphomatosis with high-dose chemotherapy and autologous peripheral blood stem cell transplantation. *Bone Marrow Transplant* 27 : 1101-1103, 2001
- 20 Yamaguchi M, Kimura M, Watanabe Y, Taniguchi M, Masuya M, Kageyama S, Katayama N, Ohno T, Kita K, Shiku H : Successful autologous peripheral blood stem cell transplantation for relapsed intravascular lymphomatosis. *Bone Marrow Transplant* 27 : 89-91, 2001.
- 21 Sawamoto A, Narimatsu H, Suzuki T, Kurahashi S, Sugimoto T, Sugiura I : Long-term remission after autologous peripheral blood stem cell transplantation for relapsed intravascular lymphoma. *Bone Marrow Transplant* 37 : 233-234, 2006
- 22 Imai H, Kajimoto K, Taniwaki M, Miura I, Hatta Y, Hashizume Y, Watanabe M, Shiraishi T, Nakamura S : Intravascular large B-cell lymphoma presenting with mass lesions in the central nervous system : a report of five cases. *Pathol Int* 54 : 231-236, 2004
- 23 Ohno T, Sakamoto T, Mizumoto C, Miyoshi T, Ueda M, Takeoka T, Yamashita K, Hishita T, Hada S : Leukemic and meningeal relapse of CD5⁺ intravascular large B-cell lymphoma with down-modulation of CD20 after rituximab therapy. *Int J Hematol* 84 : 74-78, 2006

《悪性リンパ腫を極める：各病理組織型に基づく治療法》 Hodgkin リンパ腫

大間知 謙*

要旨

- 放射線療法や化学療法の進歩により、Hodgkin リンパ腫は約 80% の例で長期生存が見込めるようになってきている
- 適切な治療を行うためには予後因子に基づいた疾患の層別化が必須であり、限局期・予後良好群、限局期・予後不良群、進行期の 3 群に分けて治療戦略を考える必要がある。
- それぞれの病態に応じて、放射線療法、化学療法、化学療法と放射線療法の併用を使い分ける必要がある。

はじめに○

放射線療法や化学療法の進歩により、Hodgkin リンパ腫は約 80% の例で長期生存が見込めるようになってきている¹⁾。しかし、良好な転帰を得るためには適切な治療が必要であり、そのためには予後因子に基づいた疾患の層別化が必須である。Hodgkin リンパ腫の予後因子としては、臨床病期、浸潤リンパ節領域数、巨大病変の有無、B 症状、赤沈などがあげられている。その中でも臨床病期はもっとも重要な予後因子であり、病期に加えて他の予後因子の数などにより層別化がなされているのが現状である。

層別化は、① 限局期・予後良好群、② 限局期・予後不良群、③ 進行期、の 3 群に分けられている。予後因子の扱いが研究グループにより若干異なっているため国際的な共通の基準は存在しないが、おおむね、限局期・予後良好群は予後不良因子を有さない I～II 期、限局期・予後不良群は予後不良因子を有する I～II A 期、進行期は II B 期、III～IV 期とされている。Hodgkin リンパ腫に対する治

療形態は、放射線療法、化学療法、化学療法と放射線療法の併用 (combined modality treatment: CMT) 療法がある。いずれの方法を用いるかは、病期や予後因子を加味した先述の 3 群に分けて考える必要がある。

Hodgkin リンパ腫は、治療による長期生存が高率に望める疾患群であり、長期的にはリンパ腫の予後よりも晩期毒性による合併症が問題となる。よって現在の課題は、① 放射線の照射野や照射量を減らすことの可能性、② 化学療法単独療法の検討、③ より短期間、より毒性の少ない化学療法の探求、それに併用する放射線療法の適正量の検討、となっている。

本稿では、各病期別に対するエビデンス、それらから考えられる現在の標準療法について解説する。

限局期・予後良好群○

1. 放射線単独療法

放射線照射量に関する比較試験は、German Hodgkin Study Group (GHS) より報告されている。限局期・予後良好群の患者を、40 Gy の

* K. Oomachi: 東海大学血液腫瘍内科。

extended field radiotherapy (EF-RT) 群と、30 Gy の EF-RT に加え、それに続く 10 Gy の involved field radiotherapy (IF-RT) 群にランダム化して治療を行ったところ、5 年の freedom from treatment failure にて EF-RT 群で 70%、EF-RT+IF-RT 群で 81% と、放射線量を減量したほうが上回っており、限局期の Hodgkin リンパ腫に対する放射線単独療法は 30 Gy で十分である可能性が示唆された²⁾。

予後因子が考慮されていなかった時代の放射線療法では、上半身に対する広範囲な照射である mantle 照射であっても、長期の観察において約 5 割という高率な再発が認められていた。これは、限局期といえども約 20% に腹部リンパ節への浸潤が隠れていることに起因している。予後因子を考慮した照射野の範囲に関しては、The European Organization for Research and Treatment of Cancer (EORTC) で行われた、mantle 照射単独と mantle 照射と予防的腹部リンパ節への照射の併用の比較試験がある。腹腔鏡で腹部リンパ節浸潤陰性の限局期・予後良好群の患者のランダム化比較試験で、6 年無再発生存率が単独照射群 vs 拡大照射群で 74% vs 72% と、差は認められなかった³⁾。retrospective な検討でも、予後因子を考慮した場合の mantle 照射の有効性は複数報告されており、現在でも放射線単独療法は、有力な治療オプションであると考えられる。

2. 化学療法と放射線療法の併用

限局期・予後良好群は、放射線単独療法でも高率に治癒が期待できる。そのためこの疾患群では、長期的にみると原疾患そのものよりも発育障害、甲状腺機能低下、二次発癌などの放射線療法による晩期毒性が問題となることがしばしばある。そこで、毒性を減らした化学療法と限局した放射線療法の組み合わせにより、十分な局所制御と病変と隣接したリンパ節領域に対する予防的な治療を同時に行うことを目的とした、CMT が考案された。

EF-RT と CMT (EF-RT + 化学療法) の比較試

験であるが、GHSG による IA～II B 期の患者を対象とした EF-RT と EF-RT+ABVD 療法 (doxorubicin, bleomycin, vinblastine, dacarbazine) 2 コースの比較では、7 年の freedom from treatment failure で CMT が優っていた (67% vs 88%)⁴⁾ と報告されている。照射野を EF-RT から IF-RT へ縮小した CMT に関する比較試験がイタリアのグループから報告されているが、4 コースの ABVD 療法後に EF-ET、または IF-RT を行ったところ、12 年の freedom from progression rate でそれぞれ 93% vs 94% と、治療法により差がなかったとされている⁵⁾。

以上を踏まえ、限局期・予後良好群に対する標準療法は、放射線照射に IF-RT を併用した CMT であり、化学療法の適応とならない場合の治療オプションとしては、EF-RT であると考えられている。

限局期・予後不良群○

過去の放射線療法の試験で再発したのから予後因子が抽出されており、放射線単独療法は治療の選択肢とはならない。

化学療法と CMT の比較試験が Grupo Argentino de Tratamiento de la Leucemia Aguda より報告されているが、I、II 期の患者を対象に CVPP 療法 (cyclophosphamide, vinblastine, procarbazine, predonisone) 6 コースと、CVPP 療法 6 コース + IF-RT 30 Gy を行ったところ、予後良好群では両群に差はなかったが、予後不良群では無再発生存率で 34% vs 75%、全生存率で 66% vs 84% と、CVPP 群のほうが下回っており⁶⁾、この結果もあって、現状では化学療法単独よりも CMT 中心に治療開発が進められてきている。

CMT に用いられる化学療法のレジメンであるが、これは後述の進行期例に対する化学療法の変遷とともに変化してきており、現時点での標準は ABVD 療法と考えられている。CMT における化学療法のコース数、放射線の照射野に関しては、二つの大規模な比較試験の結果が参考になる。

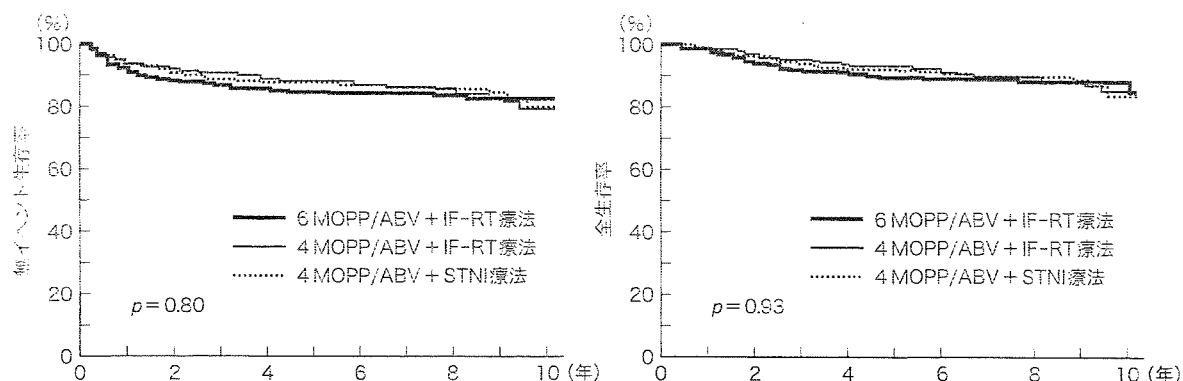


Fig. 1. 限局期・予後不良群に対する CMT 療法の生存曲線

GHSG により、COPP 療法 (cyclophosphamide, vincristine, procarbazine, prednisone) + ABVD 療法 4 コースと EF-RT 30 Gy または IF-RT の比較試験が行われ、5 年の freedom from treatment failure でそれぞれ 85.8% vs 84.2%、全生存率で 90.8% vs 92.4% と、差がなかったと報告された⁷⁾。またこの報告では、照射野を小さくすることで急性毒性の頻度を減らすことができるのみでなく、二次発癌のリスクも減らすことができた⁸⁾とされている。

EORTC と Groupe d'Etude des Lymphomes de l'Adulte により行われた intergroup study において、MOPP/ABV 療法 (nitrogen mustard, vincristine, procarbazine, prednisone/doxorubicin, bleomycin, vinblastine) 6 コース + IF-RT, MOPP/ABV 療法 4 コース + IF-RT, MOPP/ABV 療法 4 コース + EF-RT の比較試験では、5 年の無イベント生存率で 84% vs 88% vs 87%、10 年の全生存率で 88% vs 85% vs 84% と、3 群に差は認められなかった⁸⁾ (Fig. 1)。

これらの結果を踏まえ、現時点での限局期・予後不良群に対する標準療法は、ABVD 療法 4 コースと IF-RT 併用の CMT とされている。

進 行 期

1. 標準的な化学療法

第一世代の化学療法とされる MOPP 療法は、

約 80% という高い完全寛解率の割に長期生存は約 50% しか得られないこと、アルキル化薬を中心とした併用療法は不妊や二次性白血病のリスクを上昇させることなどから、第二世代の化学療法として、交差耐性や単剤での高い効果が考慮されて組み合わされた ABVD 療法が開発された。さらに第三世代の化学療法として、腫瘍細胞が耐性を獲得することを回避するために寛解導入の早期に多剤を用いるべきという Goldie-Coldman の理論、およびそれぞれの毒性が重複しなかったという事実に基づき、MOPP 療法と ABVD 療法を組み合わせ合わせた MOPP/ABVD (ハイブリッド) 療法が開発された。この治療は高い効果が認められていたが、急性毒性や二次発癌などの晩期毒性も、従来の化学療法よりも高い傾向にあった。

これらのレジメンを比較した試験が、Cancer And Leukemia Group B により報告されている。進行期の患者を MOPP 療法 6~8 コース, MOPP/ABVD 療法 12 コース, ABVD 療法 6~8 コースの 3 群にランダム化して治療を行ったところ、完全寛解率がそれぞれ 67% vs 83% vs 82%、5 年の failure free survival で 50% vs 65% vs 61% と、MOPP 療法よりほかの二つのレジメンより有意に上回っていた⁹⁾ (Fig. 2)。ほかにも ABVD 療法とハイブリッド療法を比較した試験がいくつかあるが、いずれの結果においても、有効性に関してはほぼ同等だが毒性に関してはハイブリッド療法

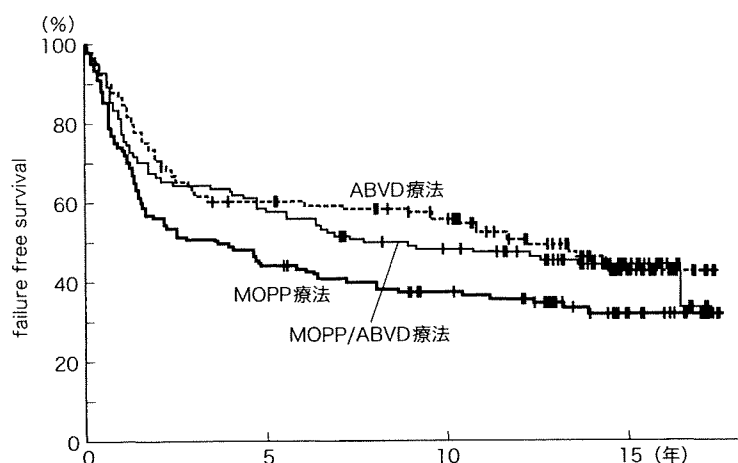


Fig. 2. MOPP vs ABVD vs MOPP/ABVD 療法における failure free survival

長期観察においても、ABVD および MOPP/ABVD 療法の優位性は変わらなかった。

が有意に多いとされており、これらの結果から、ABVD 療法はハイブリッド療法と同等の効果を有しながら毒性が少ないことが示され、進行期 Hodgkin リンパ腫に対する標準療法であると考えられている。

2. bulky mass に対する地固め療法としての放射線療法

悪性リンパ腫に対する日常診療では、治療開始時に bulky mass を有した例で、地固め療法としての放射線療法が行われることがしばしばあったが、その有用性を検討した比較試験がある。GHSG により、COPP/ABVD 療法 3 コースで完全寛解が得られたのちに IF-RT 20 Gy を行う群と、もう 1 コースの化学療法を行う群とでのランダム化が行われたが、無増悪生存率、全生存率のいずれも両群で差は認められなかったと報告された¹⁰⁾。

EORTC からは、MOPP/ABV 療法 6~8 コースで寛解が得られたのちに IF-RT を行う群と、無治療経過観察する群を比較した試験が報告されたが、5 年の無イベント生存率で 79% vs 84%、全生存率で 85% vs 91% と、ここでも治療により差はなかったとされた¹¹⁾。

これらのことから現在では、たとえ初発時に bulky mass を有したとしても、完全寛解後に放射線療法を加えることの意義は否定的と考えられている。

3. 治療強度を高めた化学療法

化学療法の強度が弱いと治療効果も下がることは古くから指摘されていたことであるが、治療強度を強めることで治療効果が上がるのかという疑問に対する明確な答えは存在しない。化学療法の治療強度を高めた治療の代表的な例が、自家造血幹細胞移植併用の大量化学療法であるが、Hodgkin リンパ腫に対する地固め療法としての大量化学療法の意義を検討した比較試験が、European Bone Marrow Transplant Registry を中心に、intergroup study として行われた。

進行期患者を対象に ABVD 療法、または類似レジメンを 4 コース行ったのちに、部分寛解以上の効果が得られた患者を自家造血幹細胞移植併用の大量化学療法を行う群と、さらに 4 コースの化学療法を行う群にランダム化して治療を行ったところ、5 年の failure free survival で 75% vs 82%、全生存率で 88% vs 88%、無再発生存率で 88% vs 94% と、両群に差は認められず、地固め療法とし

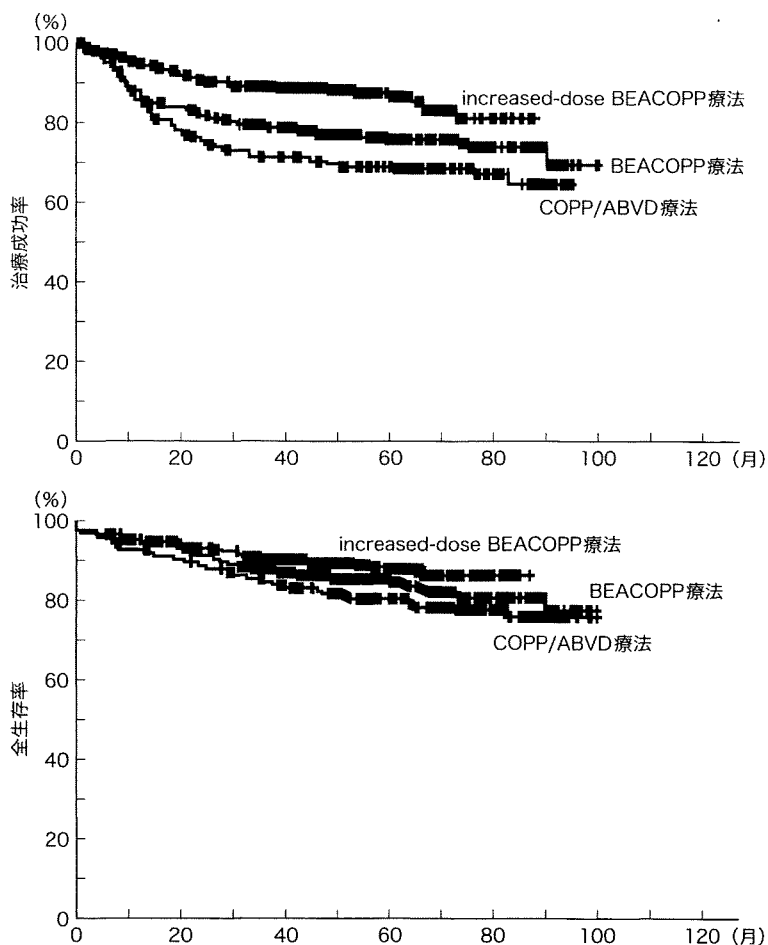


Fig. 3. 進行期 Hodgkin リンパ腫に対する COPP/ABVD 療法 vs BEACOPP 療法 vs increased-dose BEACOPP 療法の生存曲線
 中間解析の時点で、COPP/ABVD 療法群が劣っていることが判明したため、途中から登録中止となっている。

での大量化学療法を行う意義は証明されなかった¹²⁾。

GHSG からは、通常の化学療法の治療強度を強めた比較試験が報告されているが、そこでは進行期例を対象に COPP/ABVD 療法と BEACOPP 療法 (bleomycin, etoposide, doxorubicin, cyclophosphamide, vincristine, procarbazine, prednisone), increased-dose BEACOPP 療法の比較を行ったところ、5 年の freedom from treatment failure で 69% vs 76% vs 87%, 全生存率で 83% vs 88%

vs 91% と、有意に強度を高めた治療法である increased-dose BEACOPP 療法が上回っていたという結果であった¹³⁾ (Fig. 3)。しかし、血液毒性を含めて、毒性は 3 群に差はなかったが、increased-dose BEACOPP 療法で治療が行われた 9 例に急性骨髄性白血病・骨髄異形性症候群が認められており、この結果をそのまま日常診療に適応させるには注意が必要である。

そのほかにもさまざまな研究グループにより、治療期間の短縮、治療強度の向上、毒性の軽減な

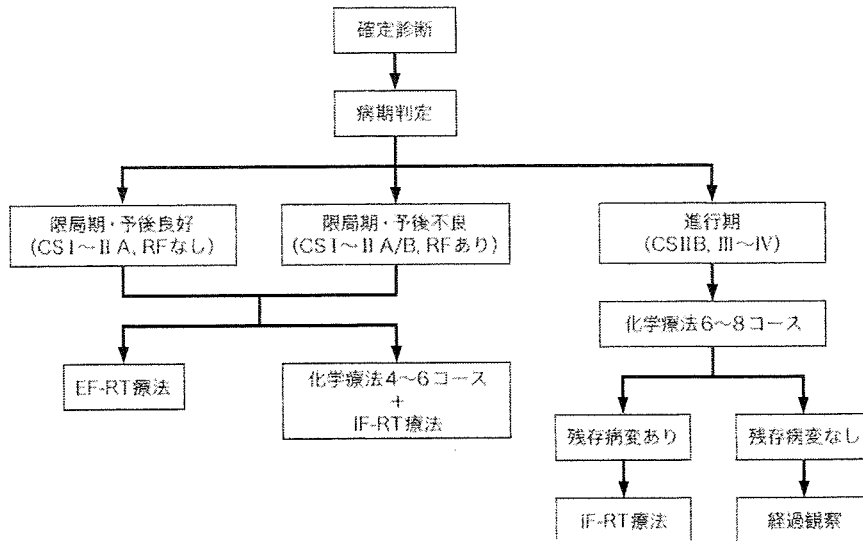


Fig. 4. Hodgkin リンパ腫に対する治療のフローチャート

CS : clinical stage, EF-RT : extended field irradiation, IF-RT : involved field irradiation, RF : risk factor (巨大縦隔腫瘍, 年齢, 赤沈亢進, 複数の浸潤リンパ節領域など).

などを目的とした、第四世代のレジメンが報告されているが、それらのものが ABVD 療法に代わる治療レジメンとなるかは、現在検証中である。

今後の展望

以上、現在の Hodgkin リンパ腫治療におけるエビデンスについて述べてきた。これらをフローチャートにすると、Fig. 4 のようになる。

しかしこれは現在検討中の新しい世代のレジメンを用いた比較試験の結果により、大きく変わっていくことも期待されている。また近年、悪性リンパ腫の診療に positron emission tomography (PET) が用いられるようになり、それを用いた治療戦略の可能性も検討されている。

Hodgkin リンパ腫は、PET がとくに有用である病型の一つであり、治療開始前の病期診断のみならず、治療の効果判定にも有用とされている。2 コースの化学療法後に PET を行い、その時点で PET 上完全寛解となっていた例と寛解となっていなかった例とに分けて予後を見たところ、寛解となっていた例のほうが有意に無増悪生存率およ

び全生存率が良好であったことが報告されており¹⁴⁾、今後はこれまで報告されてきたような予後因子以外に、治療の反応性に応じて早期に治療を完了したり、より強力な治療法を考慮するというような層別化がなされるようになるかもしれない。

文献

- 1) Connors JM : State-of-the-art therapeutics : Hodgkin's lymphoma. J Clin Oncol 23 : 6400, 2005
- 2) Duhmke E et al : Randomized trial with early-stage Hodgkin's disease testing 30 Gy vs 40 Gy extended field radiotherapy alone. Int J Radiat Oncol Biol Phys 36 : 305, 1996
- 3) Carde P et al : Clinical stages I and II Hodgkin's disease : a specifically tailored therapy according to prognostic factors. J Clin Oncol 6 : 239, 1988
- 4) Engert A et al : Two cycles of doxorubicin, bleomycin, vinblastine, and dacarbazine plus extended-field radiotherapy is superior to radiotherapy alone in early favorable Hodgkin's lymphoma : final results of the GHSG HD7 trial. J Clin Oncol 25 : 3495, 2007
- 5) Bonadonna G et al : ABVD plus subtotal nodal versus involved-field radiotherapy in early-stage Hodgkin's disease : long-term results. J Clin Oncol 22 : 2835, 2004

- 6) Pavlovsky S et al : Randomized trial of chemotherapy versus chemotherapy plus radiotherapy for stage I - II Hodgkin's disease. J Natl Cancer Inst **80** : 1466, 1988
- 7) Engert A et al : Involved-field radiotherapy is equally effective and less toxic compared with extended-field radiotherapy after four cycles of chemotherapy in patients with early-stage unfavorable Hodgkin's lymphoma : results of the HD8 trial of the German Hodgkin's Lymphoma Study Group. J Clin Oncol **21** : 3601, 2003
- 8) Ferme C et al : Chemotherapy plus involved-field radiation in early-stage Hodgkin's disease. N Engl J Med **357** : 1916, 2007
- 9) Canellos GP et al : Chemotherapy of advanced Hodgkin's disease with MOPP, ABVD, or MOPP alternating with ABVD. N Engl J Med **327** : 1478, 1992
- 10) Diehl V et al : Further chemotherapy versus low-dose involved-field radiotherapy as consolidation of complete remission after six cycles of alternating chemotherapy in patients with advance Hodgkin's disease : German Hodgkins' Study Group (GHSG). Ann Oncol **6** : 901, 1995
- 11) Aleman BM et al : Involved-field radiotherapy for advanced Hodgkin's lymphoma. N Engl J Med **348** : 2396, 2003
- 12) Federico M et al : High-dose therapy and autologous stem-cell transplantation versus conventional therapy for patients with advanced Hodgkin's lymphoma responding to front-line therapy. J Clin Oncol **21** : 2320, 2003
- 13) Diehl V et al : Standard and increased-dose BEACOPP chemotherapy compared with COPP-ABVD for advanced Hodgkin's disease. N Engl J Med **348** : 2386, 2003
- 14) Hutchings M et al : FDG-PET after two cycles of chemotherapy predicts treatment failure and progression-free survival in Hodgkin lymphoma. Blood **107** : 52, 2006

寄稿規定

- B 5 判 400 字詰原稿用紙を使用する。
- 症例報告 10 枚
- 執筆者名は 5 名までとする。
- 図・表および写真 1 枚につき原稿用紙 1 枚分に数えて規定枚数に含める。
- 引用文献は主要文献のみ 10 以内とし、規定枚数に含める。
- 原稿は正副 2 通お送り下さい。副原稿はオリジナル原稿のコピーで結構です(写真もコピーで可)。
- なお、お送りいただいた原稿は原則返却いたしません。

表紙体裁

表題* 執筆者名**

脚注：英文タイトル、発表学会名、ローマ字綴り執筆者名、役職名、所属(病院の場合は郵便番号、住所を入れる)

本文

1. ペン書き、口語体、常用漢字、新かなづかいを基準とし、ワープロ原稿の場合は 20×20 の字詰とする。データもお送り下さい(テキスト保存)。
2. 外国語はできるかぎり邦訳し、邦訳しえない外国語、外国人名のみ外国語綴りとする。

図・写真・表

1. X線フィルム、スライドは紙焼きし、大きさは手札以上とする。
2. 写真中に必要な文字、矢印などはトレーシングペーパーの上に記入する。
3. カラー写真は原則として受け付けません。
4. 図・表のネームは必ず和文とする。

文献

1. 記載順序は出拠順とし、1) 2) 3) 式に従う。
2. 筆者が 3 名以上の場合は筆頭者以外を「ほか」「et al」とする。
3. 外国人名は原語綴りとする。
4. 雑誌は著者名、論文題名、雑誌名、巻数、頁数、年号(西暦)の順で記載する。欧文雑誌名の省略は原則として『Index Medicus』による。
5. 書籍は和書、洋書ともに著者名、題名、書名、編集者名、発行所名、発行地名、版数、巻数、頁数、発行年号(西暦)の順で記載する。

掲載

- 二重投稿は堅く禁じます。
- 筆頭執筆者に本誌 1 部および別刷 30 部を贈呈。
- 本誌に掲載される著作物の複製権・翻訳権・上映権・譲渡権・公衆送信権(送信可能化権を含む)は、株式会社南江堂が保有いたします。

原稿送付先

〒113-8410 東京都文京区本郷三丁目 42 番 6 号
 (株)南江堂「内科」編集室

3-d

抗 CD20 抗体 rituximab による B 細胞腫瘍の治療

松本洋典, 西田一弘, 谷脇雅史

1 はじめに

分子標的治療薬は, 細胞内シグナル伝達阻害低分子化合物とモノクローナル抗体に大別される。モノクローナル抗体療法は, Milstein & Köhler のハイブリドーマの報告(1975)に始まる。彼らは, センダイウイルスによる細胞融合を利用して, 抗体産生マウス脾臓細胞と骨髄腫細胞を融合させた。これによって抗体産生機能と腫瘍性増殖が組み合わせられ, 永続的なモノクローナル抗体産生が可能となった。しかし, マウスモノクローナル抗体はヒト体内で異物として抗原認識されることから, 20年間余り臨床応用ができなかった。

しかし遺伝子工学技術の展開で, キメラ抗体やヒト化抗体が作製できるようになり医薬品化された。その後の発展は著しく, 現在治験中のモノクローナル抗体医薬品は, 全世界で100種類以上と言われており, その適応疾患も腫瘍から自己免疫疾患, 感染症と多岐にわたっている。

抗体療法は, 悪性リンパ腫治療の分野においてますます有望になってきている。本稿では, B細胞性リンパ腫に対する抗CD20抗体リツキシマブ(rituximab)について述べる。

2 抗CD20抗体の作用機序

リツキシマブをはじめとする抗体医薬品の作用機序として, 補体依存性細胞傷害(comple-

ment-dependent cytotoxicity; CDC), 抗体依存性細胞性細胞傷害(antibody-dependent cell-mediated cytotoxicity; ADCC), apoptosis誘導の3つが挙げられる。

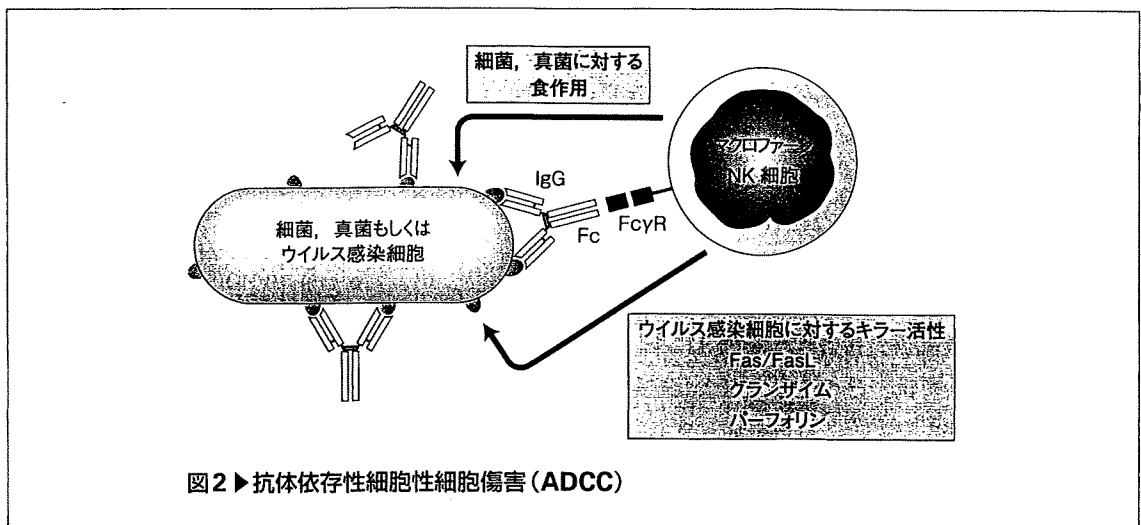
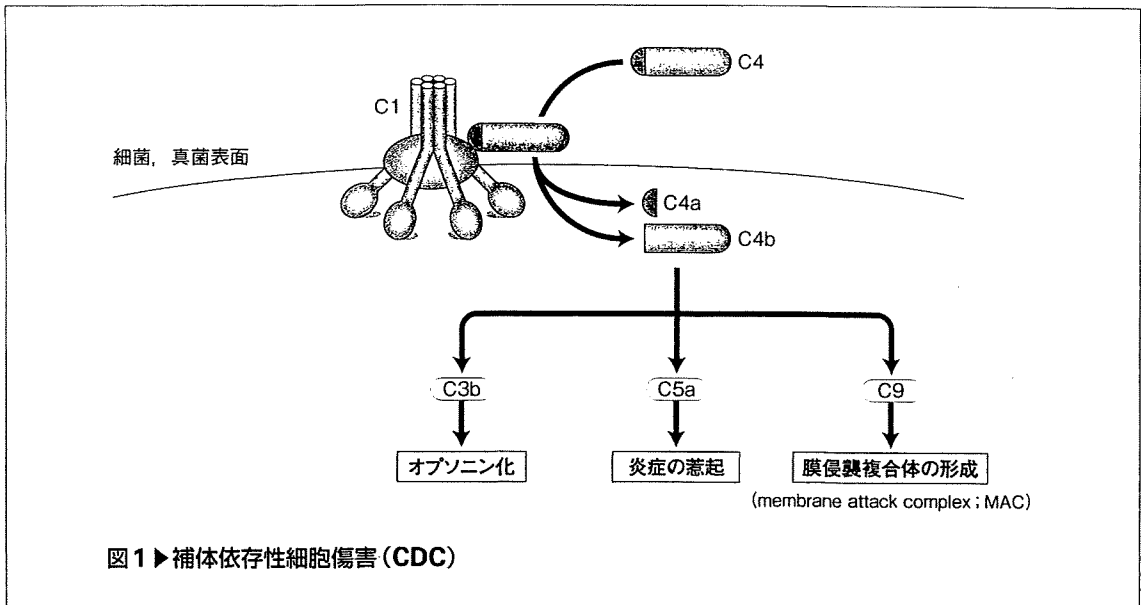
1. 補体依存性細胞傷害(CDC)

免疫系は, 抗原曝露の既往に関係なく, 幅広い病原体に対して働く自然免疫と, 曝露の既往があつて後に, その病原微生物に特異的に働く適応免疫の2つに分けられる。一方, 免疫系は, 抗原への攻撃の主体が細胞である細胞性免疫と, 抗体や補体といった蛋白成分が働く液性免疫にわけるという分類もある。補体系は, 細菌や真菌など, 主に細胞外で感染する病原体に対して非特異的に働く自然免疫をつかさどる。

補体系の活性化経路には古典経路, 副経路, マンノースレクチン経路の3つがある。このうち抗体が細胞外に感染した病原体に結合することによって誘導されるのは古典経路であり, リツキシマブもこの経路を活性化する。補体の効果としては, ①病原体の表面を覆って, 好中球・単球(マクロファージ)・樹状細胞の貪食能を促進するオプソニン化(補体成分のうち主にC3bが関与), ②炎症の惹起(主にC5aが関与), ③標的病原体の細胞膜に穴を開けて融解させる膜侵襲複合体(membrane attack complex; MAC)の形成(最終的にC9まで活性化)の3つが挙げられる(図1)。CDCを介したりツキシマブの抗腫瘍効果もこれら3つの効果によると考えられている。

2. 抗体依存性細胞性細胞傷害(ADCC)

ウイルスが宿主細胞内に感染すると, ウイルス抗原が感染細胞表面に発現する。この場合, 感染細胞表面に発現したウイルス由来の抗原に抗体が結合する。抗体に覆われたウイルス感染細胞は, NK細胞に認識されて破壊される。NK細胞は, 抗体被覆細胞を, NK細胞上に発現したIgGのFc部分に対する受容体Fcγレセ



プターによって認識する。NK 細胞による細胞傷害機序には、① 標的細胞の細胞膜を貫通する小孔を開けるパーフォリンの放出、② パーフォリンによる小孔を介して標的細胞内に侵入し、apoptosisを誘導するグランザイムの放出、③ apoptosisを誘導する標的細胞膜上の Fas と、NK 細胞上の Fas リガンド (FasL) の結合、などがある。

これら一連のNK 細胞によるウイルス感染細胞の破壊の機序を ADCC と言う。また、マク

ロファージや好中球は、抗体が被覆した細菌や真菌を FcγR によって認識し食食する (オプソニン化, 図2)。

リツキシマブの抗腫瘍効果として、抗体、つまりリツキシマブに被覆された B 細胞が NK 細胞によって破壊されたり、マクロファージや好中球によって食食されるという機序が挙げられる。

3. apoptosis誘導

リツキシマブの抗腫瘍効果としてapoptosisの誘導がある。その機序としては、①細胞内へのCa²⁺流入の促進^{1, 2)}, ②IL-10/JAK-STAT3/BCL2経路の抑制^{3, 4)}, ③NF-κB経路, ERK経路を介したBCL-XL抑制⁵⁾などが報告されている。

④ 抗CD20抗体の治療成績

リツキシマブはCD20を発現するB細胞性腫瘍に広く用いられており, 各疾患に対する治療成績も多数報告されている。低悪性度B細胞リンパ腫の約70%を濾胞性リンパ腫 (follicular lymphoma; FL) が占める。中・高悪性度B細胞リンパ腫では, びまん性大細胞型B細胞リンパ腫 (diffuse large B-cell lymphoma; DLBCL) が多数を占める。本稿ではこれら2疾患の, 特に初回治療について述べる。

初発の低悪性度B細胞リンパ腫に対するリツキシマブ単剤投与の報告⁶⁻⁹⁾を表1に, リツキシマブと化学療法との併用の報告^{10, 11)}を表2に, さらに化学療法とリツキシマブ併用化学療法の比較試験の報告¹²⁻¹⁶⁾を表3に挙げる。これらの報告では, リツキシマブと化学療法を併用したほうが奏効率, 長期成績いずれにおいてもまさっている。ただし, リツキシマブと併用す

る最適な化学療法については, 比較試験の報告がほとんどなく現在のところ不明である。

この点についてZinzaniらによる以下のような報告がある¹⁷⁾。臨床病期IIからIV, grade 1と2のFL 140例を各々6サイクルのFM療法 (フルダラビン, ミトキサントロン) とCHOP療法に割り付け, 微小残存病変 (MRD) 陰性例を除く完全寛解 (CR), 部分寛解 (PR) 例にリツキシマブを加えるという比較試験を行った。

FM療法, CHOP療法が終了した時点では, 奏効率に有意差はなかった (96% vs 98%) ものの, CR率とMRD陰性率は前者で高かった [各々68% vs 42% ($p = 0.003$), 47% vs 29% ($p = 0.030$)]。しかし, R-FM群とR-CHOP群の両者で無増悪生存率に有意差は認めなかった ($p = 0.20$)。

リツキシマブによる維持療法は, 未治療例, 既治療例, もしくは再発例いずれにおいても, 寛解期間が延長し, 全生存率 (OS) を上昇させている (表4)。また, 初回治療にリツキシマブを含んでいた場合でも, リツキシマブの維持療法は有効である¹⁸⁻²²⁾。

中・高悪性度B細胞リンパ腫, 中でも初発DLBCLに対するリツキシマブ投与の有用性の報告がいくつかみられる。Southwest Oncology Group (SWOG)-0014では限局期DLBCLを対象に, リツキシマブ併用CHOP × 3 + IFRT (in-

表1 ▶ 未治療低悪性度B細胞リンパ腫に対するリツキシマブ単剤投与の効果

対象疾患, 症例数	奏効率(完全寛解)(%)	無増悪期間中央値(月)	文献
濾胞性リンパ腫 (n = 49)	73 (26)	—	6
濾胞性リンパ腫 (臨床病期I~III, n = 64)	67 (9)	19 (無イベント生存期間中央値)	7
濾胞性リンパ腫 (grade 1, 臨床病期III/IV, n = 37)	72 (36)	26	8
低悪性度リンパ腫 (n = 60)	47 (7) (導入療法後) 73 (37) (維持療法後)	34	9

表2 ▶ 未治療低悪性度B細胞リンパ腫に対するリツキシマブと化学療法との併用効果

併用療法	症例数	奏効率(完全寛解)	無増悪生存率(%)	5年生存率(%)	分子寛解(%)	文献
R-CHOP	40	95 (55)	74 (29カ月)	—	88	10
R-flu	40	90 (80)	51 (5年)	80	88	11