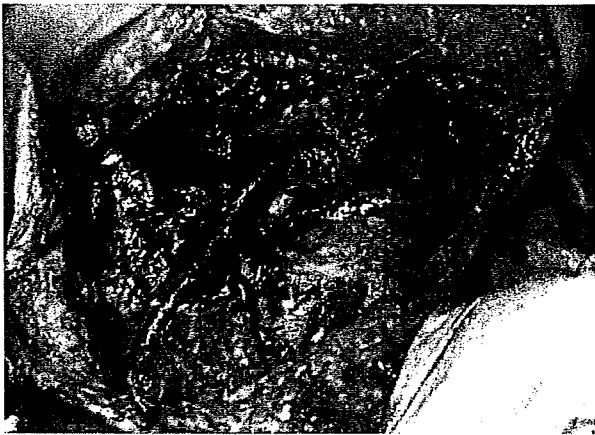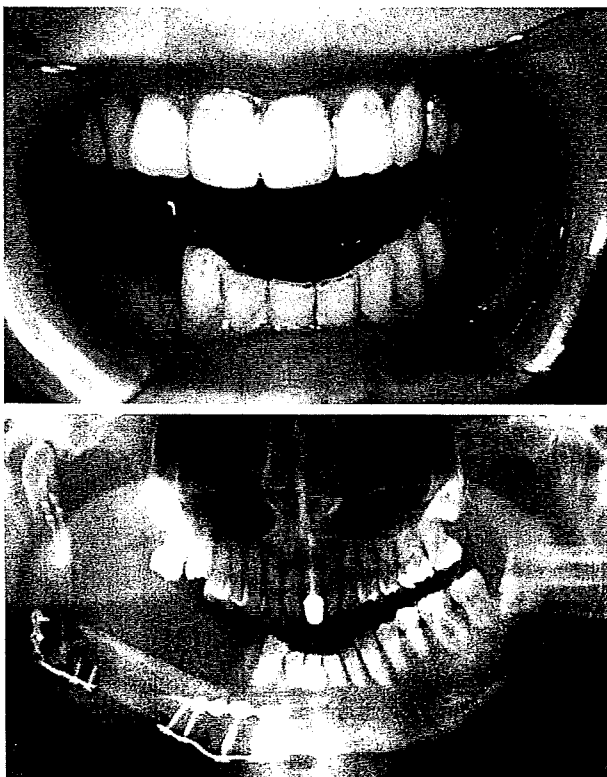




**Fig. 6.** Venous thrombosis detected during the reoperation.



**Fig. 7.** Six months after reoperation. The transferred tissue survived completely.

The ability to detect problems intraoperatively is considered to decrease the incidence of reexploration after free tissue transfer.<sup>9</sup> Intraoperative monitoring of venous pressure rapidly detected venous insufficiency found in two of our present 52 cases, and also in other cases where we have noticed transiently elevated venous pressure as the wound was closed or a dressing was applied, which

was then corrected immediately. In addition, this monitoring modality helped to facilitate postoperative care by avoiding critical elevations in venous pressure because of posturing and movement by the patient. Because the blood flow is derived from the pressure gradient between the arterial and venous sides, keeping the venous pressure at a lower level is important to ensure good perfusion in the transferred tissue. Despite the high-risk group indicated for venous pressure monitoring in our patient series, postoperative venous thrombosis occurred in only one of the 52 patients. The ability to detect critical venous pressure elevation during the intraoperative and/or postoperative period might lead to a lower incidence of venous thrombosis.

Reproducibility on an individual basis may be affected by potential artifacts, such as an unfavorable location of the catheter, motion, posturing, and obstruction of the line connected to the transducer. However, provided that one has a clear understanding of the technical background of this method, intraparenchymatous venous pressure monitoring can provide reproducible results in the assessment of venous compromise. This technique is not advocated for all cases of free-flap surgery because of potential complications in association with the pulling out of the catheter. Because we experienced only one case of postoperative venous thrombosis, further investigations were obviously required to discuss cost-effectiveness analysis of this technique. It would seem to be particularly indicated for high-risk patients, such as those demonstrated to have an abnormality in the venous anatomy, those undergoing reconstruction after lower leg trauma, and those requiring a vein graft.

#### CONCLUSIONS

Venous outflow abnormalities in instances of free composite tissue graft transfer can lead to devastating sequelae. Although various methods for monitoring the interstitial blood flow have been advocated, no single approach has been found to provide reliable information about incompetence of venous outflow. Monitoring the changes in the venous pressure is a method that is simple to implement, and the findings are, generally speaking, reliable and useful in helping the surgeon to decide when to reexplore the operative site. Although the venous pressure is in the range of 0 to 35 mmHg during the first 3 days after surgery, a subsequent trend to venous hypertension reaching a level of 50 mmHg clearly indicates venous outflow obstruction. Reexploration of the

wound is indicated if the "ailing" flap is to be rescued.

*Hiroyuki Sakurai, M.D., Ph.D.*  
 Department of Plastic and Reconstructive Surgery  
 Tokyo Women's Medical University  
 8-1 Kawada-cho, Shinjuku-ku  
 Tokyo 162-8666, Japan  
 bighiro@prs.twmu.ac.jp

#### ACKNOWLEDGMENT

*The authors thank Dr. Ted Huang for help in preparing the manuscript.*

#### DISCLOSURE

*None of the authors has a financial interest in any of the products, devices, or drugs mentioned in this article.*

#### REFERENCES

1. Kroll, S. S., Schusterman, M. A., Reece, G. P., et al. Timing of pedicle thrombosis and flap loss after free-tissue transfer. *Plast. Reconstr. Surg.* 98: 1230, 1996.
2. Yuen, J. C., and Feng, Z. Monitoring free flaps using the laser Doppler flowmeter: Five-year experience. *Plast. Reconstr. Surg.* 105: 55, 2000.
3. Disa, J. J., Cordeiro, P. G., and Hidalgo, D. A. Efficacy of conventional monitoring techniques in free tissue transfer: An 11-year experience in 750 consecutive cases. *Plast. Reconstr. Surg.* 104: 97, 1999.
4. Heller, L., Levin, L. S., and Klitzman, B. Laser Doppler flowmeter monitoring of free-tissue transfers: Blood flow in normal and complicated cases. *Plast. Reconstr. Surg.* 107: 1739, 2001.
5. Liss, A. G., and Liss, P. Use of a modified oxygen microelectrode and laser-Doppler flowmetry to monitor changes in oxygen tension and microcirculation in a flap. *Plast. Reconstr. Surg.* 105: 2072, 2000.
6. Yano, K., Hosokawa, K., Nakai, K., Kubo, T., and Hattori, R. Monitoring by means of color Doppler sonography after buried free DIEP flap transfer. *Plast. Reconstr. Surg.* 112: 1177, 2003.
7. Few, J. W., Corral, C. J., Fine, N. A., and Dumanian, G. A. Monitoring buried head and neck free flaps with high-resolution color-duplex ultrasound. *Plast. Reconstr. Surg.* 108: 709, 2001.
8. Karkowski, J., and Buncke, H. J. A simplified technique for free transfer of groin flaps, by use of a Doppler probe. *Plast. Reconstr. Surg.* 55: 682, 1975.
9. Kind, G. M., Buntic, R. F., Buncke, G. M., Cooper, T. M., Siko, P. P., and Buncke, H. J., Jr. The effect of an implantable Doppler probe on the salvage of microvascular tissue transplants. *Plast. Reconstr. Surg.* 101: 1268, 1998.
10. Swartz, W. M., Izquierdo, R., and Miller, M. J. Implantable venous Doppler microvascular monitoring: Laboratory investigation and clinical results. *Plast. Reconstr. Surg.* 93: 152, 1994.
11. Machens, H. G., Mailaender, P., Reimer, R., Pallua, N., Lei, Y., and Berger, A. Postoperative blood flow monitoring after free-tissue transfer by means of the hydrogen clearance technique. *Plast. Reconstr. Surg.* 99: 493, 1997.
12. Dunn, R. M., Kaplan, I. B., Mancoll, J., Terzis, J. K., and Trengove-Jones, G. Experimental and clinical use of pH monitoring of free tissue transfers. *Ann. Plast. Surg.* 31: 539, 1993.
13. Stack, B. C., Jr., Futran, N. D., Zang, B., and Scharf, J. E. Initial experience with personal digital assistant-based reflectance photoplethysmograph for free tissue transfer monitoring. *Ann. Plast. Surg.* 51: 136, 2003.
14. Wolff, K. D., Kolberg, A., and Mansmann, U. Cutaneous hemoglobin oxygenation of different free flap donor sites. *Plast. Reconstr. Surg.* 102: 1537, 1998.
15. Busic, V., and Das-Gupta, R. Temperature monitoring in free flap surgery. *Br. J. Plast. Surg.* 57: 588, 2004.
16. Hauge, E. M., Balling, E., Hartmund, T., and Hjortdal, V. E. Secondary ischemia caused by venous or arterial occlusion shows differential effects on myocutaneous island flap survival and muscle ATP levels. *Plast. Reconstr. Surg.* 99: 825, 1997.
17. Kerrigan, C. L., Wizman, P., Hjortdal, V. E., and Sampalis, J. Global flap ischemia: A comparison of arterial versus venous etiology. *Plast. Reconstr. Surg.* 93: 1485, 1994.
18. Clifton, G. D., Branson, P., Kelly, H. J., et al. Comparison of normal saline and heparin solutions for maintenance of arterial catheter patency. *Heart Lung* 20: 115, 1991.
19. Mailaender, P., Machens, H. G., Waurick, R., Rieck, B., and Berger, A. Routine monitoring in patients with free tissue transfer by laser-Doppler flowmetry. *Microsurgery* 15: 196, 1994.
20. Fischer, J. C., Parker, P. M., and Shaw, W. W. Waveform analysis applied to laser Doppler flowmetry. *Microsurgery* 7: 67, 1986.
21. Hudson, D. A., Engelbrecht, G., and Duminy, F. J. Another method to prevent venous thrombosis in microsurgery: An in situ venous catheter. *Plast. Reconstr. Surg.* 105: 999, 2000.

# Squamous Cell Carcinoma Arising in a Port-Wine Stain with a Remote History of Cryosurgery

HIROYUKI SAKURAI, MD, PHD,\* MOTOHIRO NOZAKI, MD, PHD,\* MASAKI TAKEUCHI, MD, PHD,\* TARO KONO, MD,\* KEIJIRO HORI, MD,\* AND KENJI SASAKI, MD, PHD<sup>†</sup>

---

*The authors have indicated no significant interest with commercial supporters.*

---

Port-wine stain (PWS) is a benign vascular malformation consisting of ectatic blood vessels situated predominantly in the superficial dermis, with a reported incidence of 0.3% of the population.<sup>1</sup> Currently developed laser treatment achieves observable lightening of PWS by reducing the number and size of the abnormal vessels without notable scar formation.<sup>2</sup> Previously applied methods, however, including surgical excision and grafting, radiation, dermabrasion, and cryotherapy, had produced unfavorable outcomes.

The development of malignancy within a PWS lesion is a rare condition, and the mechanism for malignant changes in PWSs is not fully understood. Magana-Garcia and Magana-Lozano<sup>3</sup> proposed that tumor development might involve an oncogenic factor produced by the abnormal vessels that makes the overlying epidermis more susceptible to ultraviolet light. In contrast, some authors have suggested that prior treatments such as radiation are involved in the development of malignant skin lesions.<sup>4</sup>


Although more than 20 cases of basal cell carcinoma associated with PWSs have been previously reported,<sup>3-6</sup> association of squamous cell carcinoma (SCC) is extremely rare, with only 3 cases<sup>7-9</sup> reported to date in the English literature. We present herein a case of SCC developing within a PWS with a remote history of cryosurgery and discuss the possible etiology.

## Case Report

A 69-year-old male patient visited our clinic in November 2004 with a chronic ulceration within the boundary of a PWS involving the V1 to V2 area of the right trigeminal nerve. The history of the case was carefully taken from not only himself but also his older sister. His history revealed that he had undergone cryosurgery several times when he was 5 to 7 years old. He did not receive any other therapy including radiotherapy, laser therapy, and surgical excision. The ulcer (3 cm in diameter), of 7 months duration, was associated with a surrounding atrophic scar (Figure 1). A biopsy specimen taken from the margin of the ulcer showed histologic features of well-differentiated SCC. No distinct metastases were detected by systemic evaluation.

With these findings, we performed local wide excision involving all scar tissue and the surrounding PWS in his right cheek on December 20, 2004. After affirmation of tumor-free margins on the basis of the pathologic report of frozen sections, a free deltopectoral flap sized 15 × 10 cm was raised based on the second and third anterior perforating branches of the internal mammary vessel. The second costal cartilage was removed at a point 1.5 to 2 cm from the sternal border to facilitate isolation of a 2-cm segment of the internal mammary vessels, including the perforating branches. The internal mammary artery and vein were anastomosed to the superior thyroid artery and external jugular vein, respectively.

\*Department of Plastic and Reconstructive Surgery, Tokyo Women's Medical University, Tokyo; <sup>†</sup>Department of Plastic and Reconstructive Surgery, Faculty of Medicine, Nihon University, Nihon, Japan




**Figure 1.** Ulcer formation is seen at the boundary of the port-wine stain.

Histology of the whole lesion revealed a well-differentiated SCC of 3-mm depth with satisfactory clearance. No abnormal vascular lesion indicative of PWS was observed around the ulceration; instead, a thick fibrous tissue was observed (Figure 2).

The postoperative course was uneventful, with total survival of the transferred flap. There have been neither complications nor evidence of recurrence during follow-up for 20 months. The facial appearance resulting from the flap was considered to be aesthetically satisfactory, with excellent color and texture matches (Figure 3).

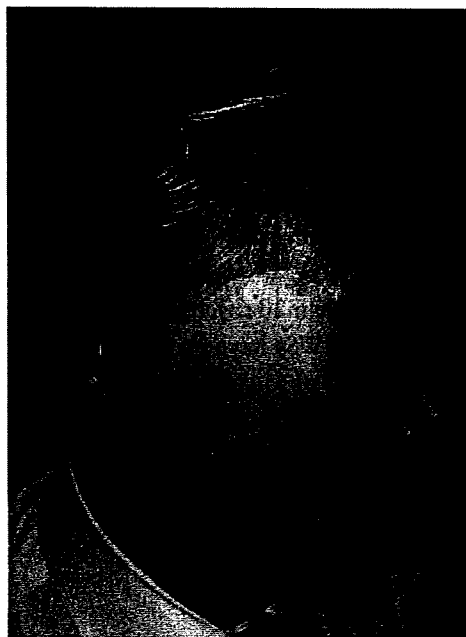
### Discussion

Although malignant lesions associated with PWSs have been reported previously,<sup>3-10</sup> the etiologic factors seem to be highly individual. In the present case, no residual vascular lesion was present at the site of ulceration, whereas thick fibrous tissue was noted surrounding the SCC lesion. Therefore, in this particular patient it is reasonable to surmise that the association of SCC with PWS is coincidental and the



**Figure 2.** Histopathologic view of the lesion, a squamous cell carcinoma (H&E; original magnification,  $\times 20$ ).

history of cryotherapy is a major factor in the causation of this malignancy. The use of low temperatures to treat cutaneous disease is not new. In 1907, Pusey<sup>11</sup> reported the use of carbon dioxide snow to treat small superficial hemangiomas, leukoplakia, and keloids. In the mid-20th century, cryotherapy was one of the common therapeutic options for PWSs, although it did not lead to a predictable outcome.<sup>12,13</sup> It is well known that cryotherapy may



**Figure 3.** Postoperative view after 18 months.

cause tissue damage depending on the temperature and duration of the treatment. Myers and Donovan<sup>14</sup> reported that a freeze of 3 minutes consistently led to full-thickness necrosis of the skin. We believe that the cryotherapy applied to this case in the 1940s, when fundamental knowledge was lacking, resulted in extensive skin necrosis and scar formation.

To date there have been no reports indicating that prior cryotherapy led to a malignant skin lesion. The association of scar carcinoma with previous cold injury, however, has been well documented.<sup>15-17</sup> Frostbite of the lower extremity, also known as "trench foot," is one of the etiologic factors of Marjolin's ulcer.<sup>15-17</sup> Most of the reported cases are veterans of World War II and victims of accidents. The long latent period and histologic findings of the present case are quite similar to those of a recently reported case.<sup>16</sup> Although the causality is not completely valid, this case of SCC developing within the boundaries of a PWS is most likely due to the remote history of cryosurgery.

In the natural course of aging, the surface of the PWS gradually becomes studded with nodular lesions, and the color becomes darker. It is likely therefore that a developing malignant skin lesion may not be recognized clinically, especially if it is slow growing. We suggest that physicians be constantly aware that PWSs can undergo malignant changes with time. Moreover, we believe that a detailed history of past treatments should be taken from patients with PWSs and skin biopsies should be performed for suspicious lesions after careful examination.


*Acknowledgments* The authors thank Dr Toshiro Nishikawa for his help in the presentation of the pathologic findings in this case report.

## References

- Jacobs AH, Walton RG. The incidence of birthmarks in the neonate. *Pediatrics* 1976;58:218-22.
- Kono T, Groff WF, Sakurai H. Treatment of port wine stains with the pulse dye laser. *Ann Plast Surg* 2006;56:460-3.
- Magana-Garcia M, Magana-Lozano M. Multiple basal cell carcinomas arising in port-wine haemangiomas. *Br J Dermatol* 1988;119:393-6.
- Wharton SM, Cole RP. Basal cell carcinomata in port wine stains. *Br J Plast Surg* 2001;54:156-8.
- Shah M, Lewis FM, Palmer IR. Three cases of multiple basal cell carcinoma arising in port-wine stains previously treated with thorium X. *Br J Dermatol* 1996;135:861-2.
- Silapunt S, Goldberg LH, Thurber M, et al. Basal cell carcinoma arising in a port-wine stain. *Dermatol Surg* 2004;30:1241-5.
- Kitajima T, Okuwa T, Imamura S. Spindle cell carcinoma arising in a port-wine stain. *Dermatology* 1993;187:270-2.
- Mikhail GR. Squamous cell carcinoma in hemangioma of lip. *J Dermatol Surg Oncol* 1986;12:524-5.
- De Simone C, Giampetruzzi AR, Guerriero C, et al. Squamous cell carcinoma arising in a venous ulcer as a complication of the Klippel-Trenaunay syndrome. *Clin Exp Dermatol* 2002;27:209-11.
- Jasim ZF, Woo WK, Walsh MY, et al. Multifocal basal cell carcinoma developing in a facial port wine stain treated with argon and pulsed dye laser: a possible role for previous radiotherapy. *Dermatol Surg* 2004;30:1155-7.
- Pusey WA. The use of carbon dioxide snow in the treatment of nevi and other skin lesions. *JAMA* 1907;49:1354-6.
- Goldwyn RM, Rosoff CB. Cryosurgery for large hemangiomas in adults. *Plast Reconstr Surg* 1969;43:605-11.
- Ohtsuka H, Shioya N, Tanaka S. Cryosurgery for hemangiomas of the body surface and oral cavity. *Ann Plast Surg* 1980;4:462-8.
- Myers B, Donovan W. Cryosurgery of the skin: an experimental and clinical study. *Ann Plast Surg* 1978;1:271-9.
- Katsas A, Agnantis J, Smyrnis S, Kakavoulis T. Carcinoma on old frostbites. *Am J Surg* 1977;133:377-8.
- Uysal A, Kocer U, Sungur N, et al. Marjolin's ulcer on frostbite. *Burns* 2005;31:792-4.
- DiPirro E, Conway H. Carcinoma after frostbite: a case report. *Plast Reconstr Surg* 1966;38:541-3.

---

Address correspondence and reprint requests to: Hiroyuki Sakurai, MD, PhD, Department of Plastic and Reconstructive Surgery, Tokyo Women's Medical University, 8-1 Kawada-cho, Shinjuku-ku, Tokyo, Japan 162-8666, or e-mail: bighiro@prs.twmu.ac.jp



ELSEVIER

available at [www.sciencedirect.com](http://www.sciencedirect.com)journal homepage: [www.elsevier.com/locate/burns](http://www.elsevier.com/locate/burns)

## Case reports

# Reconstruction of perioral burn deformities in male patients by using the expanded frontal scalp

Hiroyuki Sakurai\*, Kazutaka Soejima, Masaki Takeuchi, Taro Kono, Takashi Yamaki, Motohiro Nozaki

Department of Plastic and Reconstructive Surgery, Tokyo Women's Medical University, 8-1 Kawada-cho Shinjuku-ku, Tokyo 162-8666, Japan

## ARTICLE INFO

Article history:

Accepted 25 June 2007

## 1. Introduction

Cicatricial deformities that involve the lower part of the face, especially around the mouth, are not uncommon consequences of facial burns. Severe scarring of the lower face presents a formidable challenge to the reconstructive surgeon. Constriction of perioral tissue may lead to functional disability, with ectropion of the lips, oral incontinence and drooling [1]. Skin grafts are generally used during acute burn management, but they almost invariably contract over time. Because full supplementation of dermis and soft tissue is required to correct a fundamental problem, various flaps have been used to reconstruct the perioral area [2–6]. In addition to functional considerations, this area needs to be reconstructed within the concept of aesthetic unit [1,7]. The effort to leave unburned small areas often results in a rather patchwork, thus cosmetically unacceptable appearance.

Severe burns are characterized by a shortage of available donor tissue for reconstruction. The scalp is often preserved as a precious donor site in this circumstance: the skin is thick and, when burned, heals faster than other anatomic areas [8,9]. The scalp is the choice of the donor site for lower face reconstruction, as either a pedicle flap [10–12] or a free flap [13,14]. However, previous reports of lower face reconstruction using the scalp aimed at employing the hair-bearing skin to camouflage

unsightly scarring. Therefore, this method has not been applicable to patients who did not want to wear a moustache and/or beard. In this report we present three males who had no particular wish to grow a moustache and/or beard, but still underwent lower face reconstruction using an expanded scalp flap. Description of the technical details and the experience gained with these patients forms the basis of this report.

## 2. Materials and methods

Over the past 3 years, three men sought our care for of burn deformities around the mouth that extended to the chin and the neck. Their ages were 21, 36 and 46 years (Table 1). All had sustained extensive burns around the face. For the perioral deformities, all three had undergone conventional treatment for burn scar release and skin grafting. Despite repeated surgical attempts to release the contracture, the unsolved problems of the patients included tight scars on the lower face, ectropion of the lower lip and unsightly scarring.

The extent of perioral deformity and the area requiring skin replacement were assessed to determine the adequacy of the frontal scalp and the extent of scalp expansion that was needed. The size of the expander was determined to be 1000 cm<sup>3</sup> for one and 512 cm<sup>3</sup> for the other two. Using

\* Corresponding author. Tel.: +81 3 3353 8111; fax: +81 3 3225 0940.

E-mail address: [bighiro@prs.twmu.ac.jp](mailto:bighiro@prs.twmu.ac.jp) (H. Sakurai).

0305-4179/\$32.00 © 2007 Published by Elsevier Ltd and ISBI.

doi:10.1016/j.burns.2007.06.022

**Table 1 – Patients' profiles**

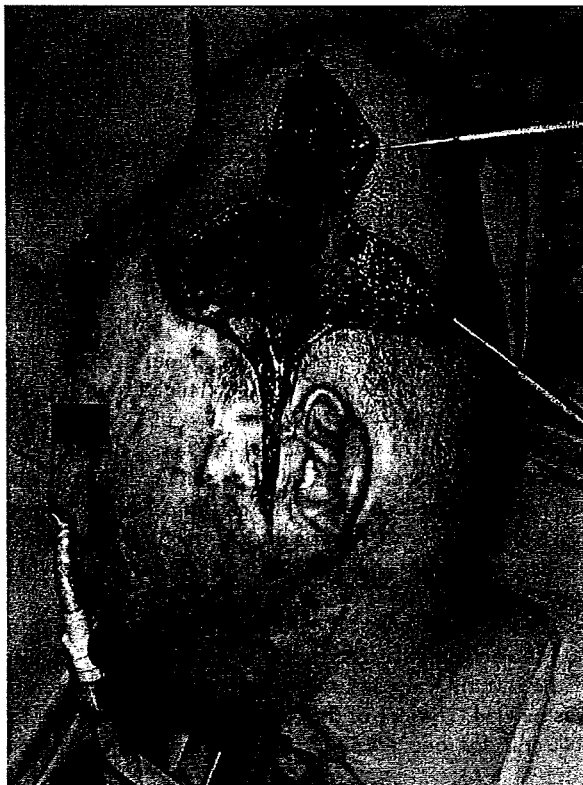No.	Age (y)	TBSA	Expander	Reconstruction site	Free/pedicle
1	36	DDB-DB 48%	512 ml	Lower lip	Free
2	21	DDB-DB 46%	512 ml × 2	Lower lip, upper lip	Pedicle
3	46	DDB-DB 32%	1000 ml	Lower lip, lower cheek	Pedicle

TBSA: total burn surface area (%), DDB: deep dermal burn, DB: dermal burn.

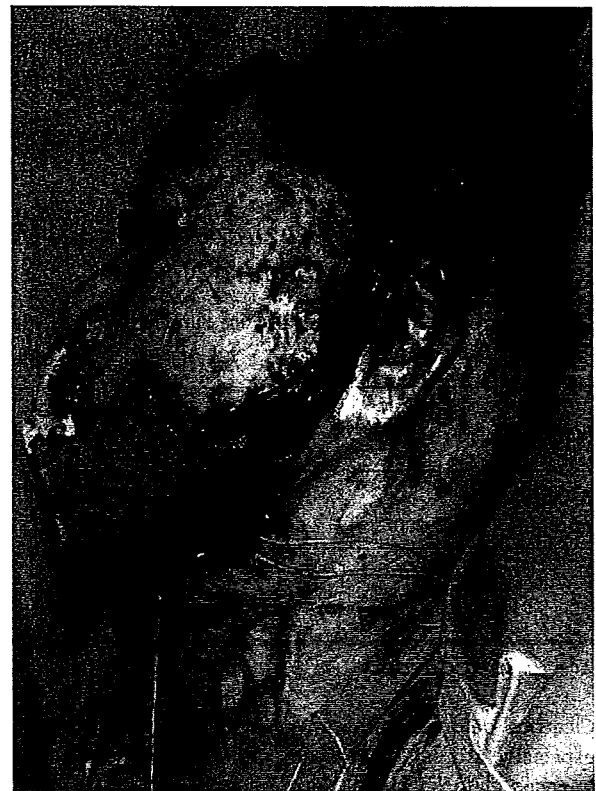
Doppler auscultation, the location of the superficial temporal arteries were traced. In one patient who presented with unstable scarring of the right temporal region after harvesting a split-thickness skin graft (STSG), only the left superficial temporal artery and vein were utilized as the vascular pedicle for a free expanded scalp flap. In a second patient who required both upper and lower lip reconstruction, two 512-cm<sup>3</sup> expanders were used. A subgaleal space sufficiently large to house the expander was created. The injection port was placed in the forehead for easy location and identification.

Inflation was started 2 weeks after the placement. An average of 11 sessions of fluid injection was required to attain maximal expansion. Once sufficient expansion of the scalp tissue was ascertained, the patient was scheduled for the next stage of the reconstruction.

The tissue expanders were removed, and the extent of scar contracture release was determined on the basis of the amount of expanded scalp tissue available for the reconstruction. The flap was raised on the temporoparietal fascia, which



**Fig. 1 – Intraoperative view of an expanded scalp flap. A pre-auricular incision allowed isolation of the vascular pedicle down to the level of the tragus.**



**Fig. 2 – The flap gained the long arch that reached the perioral area and did not require secondary division of the vascular pedicle.**

included the branches of the superficial temporal vessels. A pre-auricular incision allowed isolation of the vascular pedicle down to the level of the tragus (Fig. 1). With the skeletonization of the pre-auricular vascular pedicles, the flap gained the long arch that reached the perioral area and did not require secondary division of the vascular pedicle [10,11] (Fig. 2).

The initial step in the flap positioning was to restore the commissure of the mouth. Thereafter, the extent of scar removal from the upper lip and the chin was determined. Inset of the expanded flap was achieved by closing the wound edges in layers. After harvesting the expanded scalp flap, the donor site was closed primarily. Most dog-ears were ignored, and they flattened with time.

## 2.1. Case 1

A 36-year-old man sustained a 48% body surface area burn, including the anterior chest, neck and lower face. Sequential

debridement and skin grafting were required to close the burn wound primarily. Scalp skin was utilized twice as the donor site for STSG, resulting in an unstable scar in the right temporal region. After complete wound closure, the patient had severe scar contracture in his lower face, extending to the anterior chest (Fig. 3A). The authors initiated a plan to develop an expanded temporoparietal flap using two 512-ml tissue expanders 5 months after the injury. Prior to completion of the expansion, however, the right-side expander extruded through the unstable scar and was therefore removed. Following a 2-month expansion period, the temporoparietal flap was elevated as one large flap, 24 cm × 8 cm in size. The left superficial temporal artery and vein were anastomosed to the left facial artery and vein. The flap survived completely. Today, 3 years after the operation, the result is pleasing (Fig. 3B).

### 2.2. Case 2

This patient is a 21-year-old man who sustained a 46% TBSA burn in a gasoline explosion when he was 17 years old. He underwent multiple skin grafting for wound closure, and an expanded forehead flap had been used for nasal reconstruction. The scalp had been the donor site for the STSG in this case, as well. Although he did not present with perioral constriction, the remaining unburned skin and multistaged skin grafting using different donor sites resulted in a patchwork effect with pigment mismatch (Fig. 4A). He was eager to have a uniform color and texture for both the upper and lower

lips. Five years after the injury, two 512-cm<sup>3</sup> rectangular tissue expanders were inserted in the subgaleal plane. Three months after insertion, the expanders were removed, and bilateral temporoparietal flaps were raised individually based on the superficial temporal vessels. These flaps were transposed to the perioral area as island flaps. The donor defect was closed primarily without any difficulties. Although placing hair-bearing tissues on the lower face in this case did require more shaving than before, he was satisfied with the monotone skin that had a better color match with the surrounding skin (Fig. 4B).

### 2.3. Case 3

A 46-year-old male sustained a 36% TBSA flame burn involving his face and neck. In the acute phase the defect was treated with split skin grafts in a local hospital. When he was referred to our hospital 6 months after the injury, he presented with severe scarring of his face with ectropion of his lower eyelids and lower lip (Fig. 5A). The lower lip was severely pulled down, resulting in poor oral hygiene, excessive exposure of the oral mucosa and interference with the oral sphincter function. The frontal scalp had been left intact without previous use as a donor site for STSG, because he had male pattern baldness. After skin grafting to the anterior neck and bilateral lower eyelids, we designed a lower face reconstruction with an expanded visor flap. A 1000-cm<sup>3</sup> rectangular tissue expander was placed in the parietal region to expand the hairy skin. After a 3-month expansion period, we utilized the bald frontal

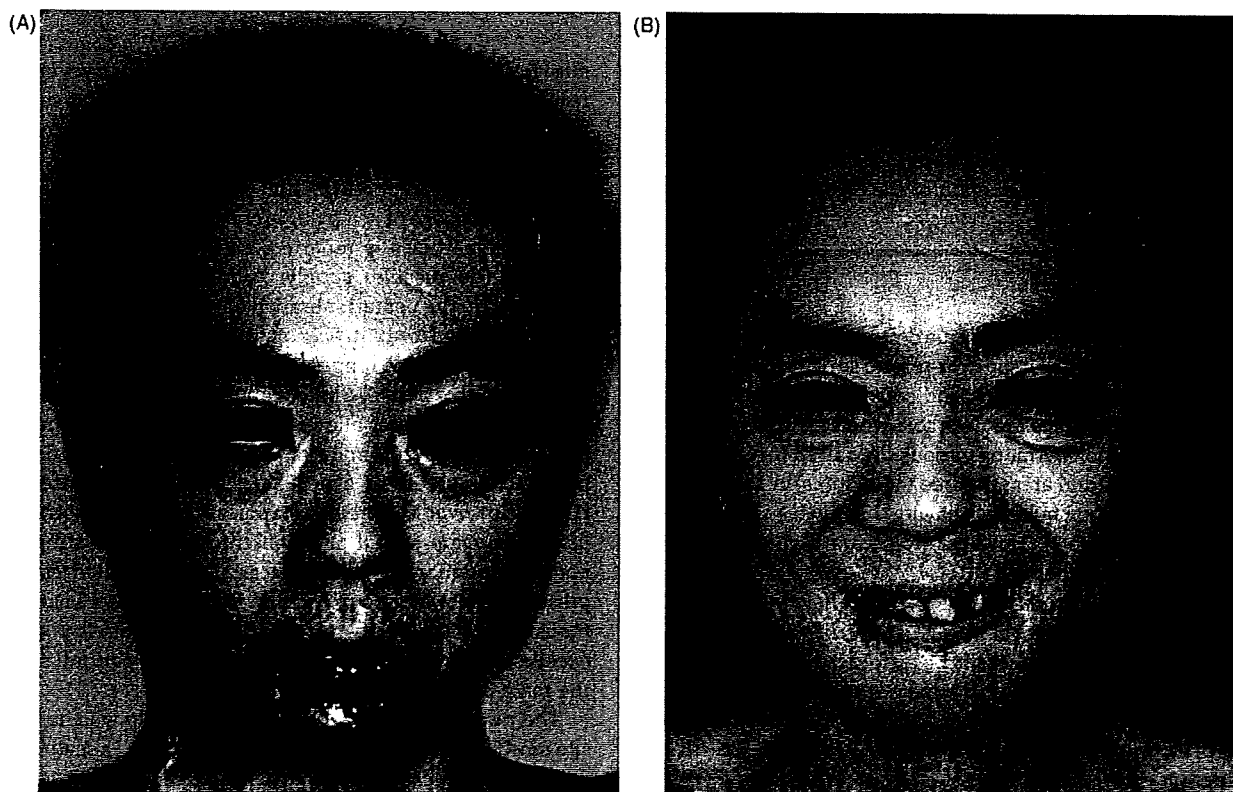


Fig. 3 - Case 1: A 36-year-old man sustained a 48% body surface area burn, including the anterior chest, neck and lower face. (A) Preoperative findings. (B) The results at 3 years after the surgery.



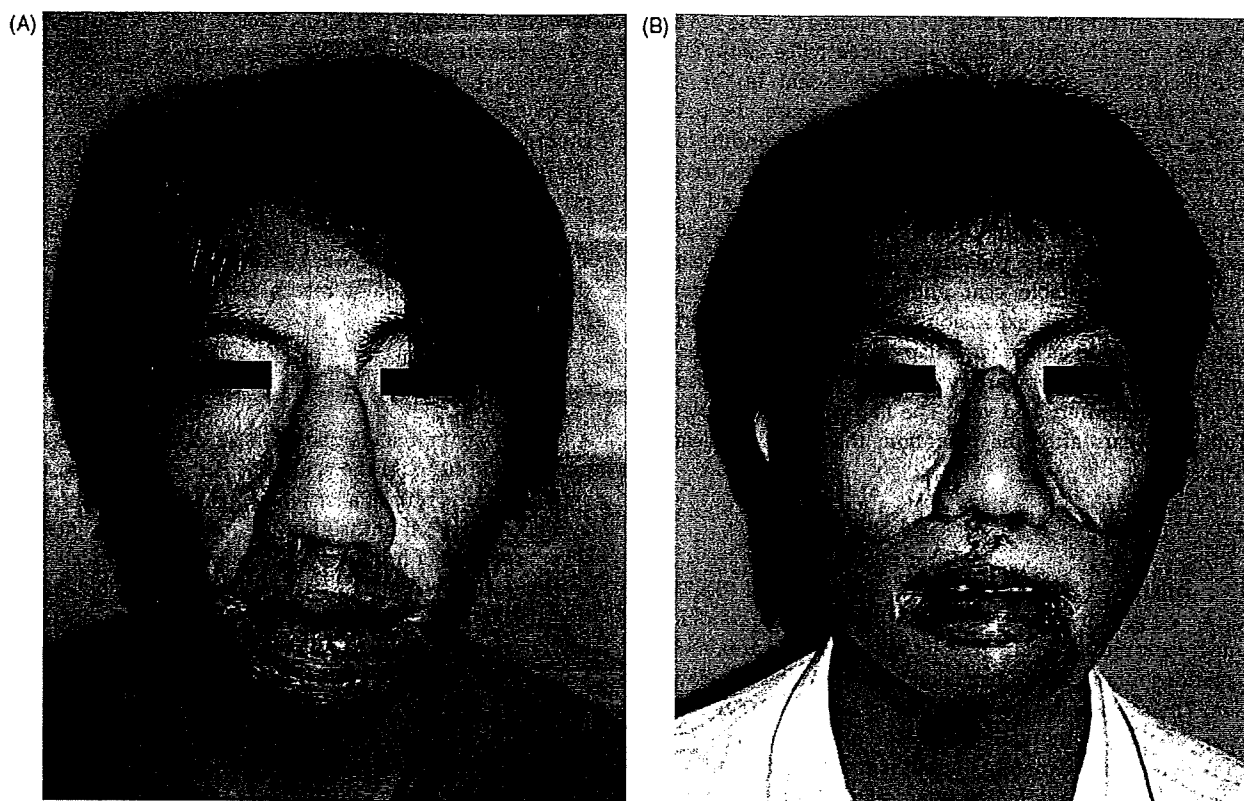


Fig. 4 – Case 2: A 21-year-old man sustained a 46% TBSA burn when he was 17 years old. (A) Preoperative findings. (B) The results at 6 months after the surgery.

skin as the donor site for the expanded visor flap, and the expanded hairy skin was advanced forward to resurface the frontal region (Fig. 5B). Today, 6 months after the operation the results are pleasing, not only in terms of the facial appearance (Fig. 5C) but also the reduction of the bald frontal area.

### 3. Discussion

Reconstruction of perioral tissue defects, especially after deep burns, remains challenging for plastic surgeons. Because full supplementation of dermis and soft tissue is required, thin fasciocutaneous flaps are desirable when resurfacing defects in perioral regions. Among various flaps used for reconstruction of the perioral area, the free radial forearm flap is one of the most common materials having thin pliable skin and long vascular pedicle [2]. However, it shows higher donor site morbidity than other flaps [15].

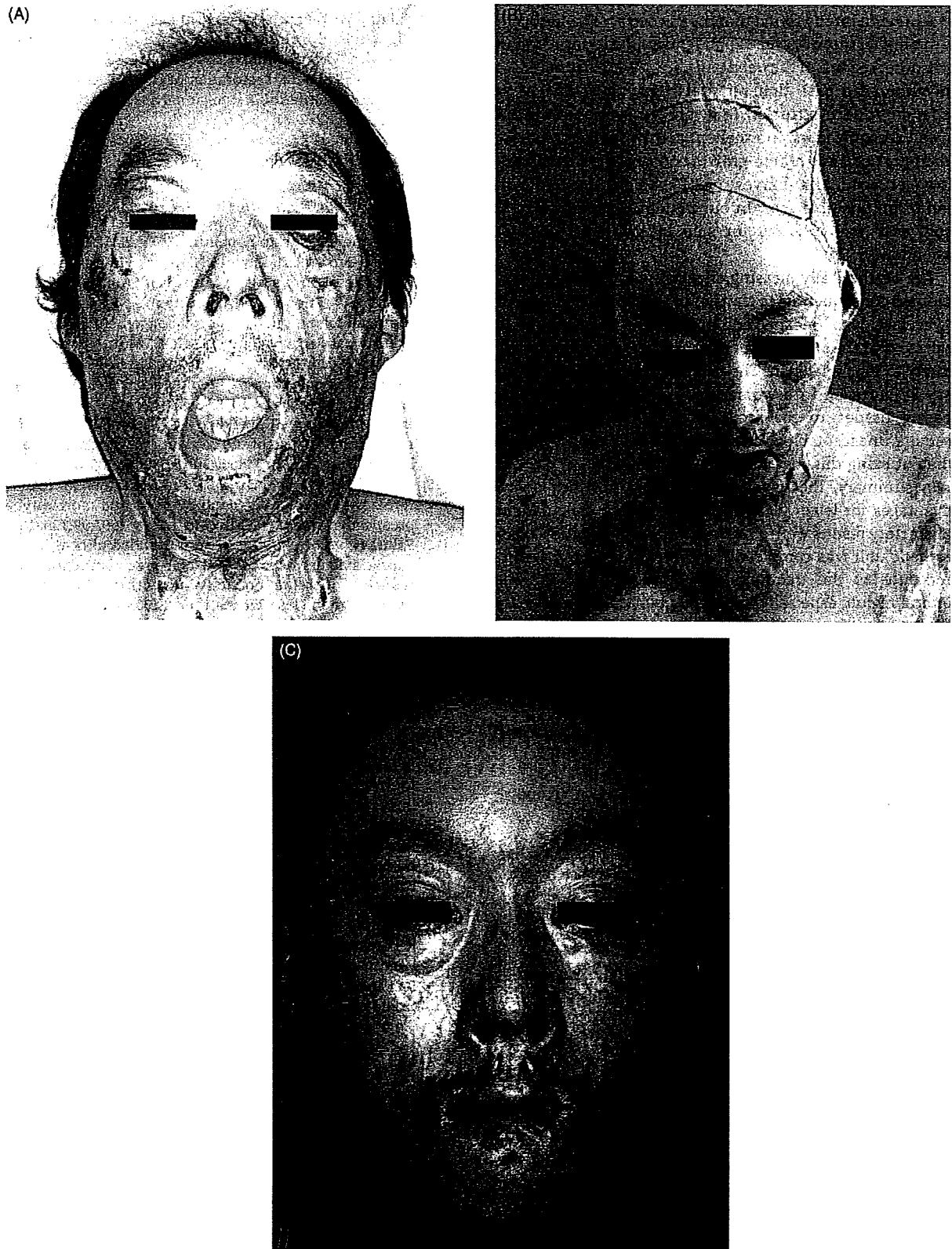
Use of back skin either as a pedicled flap or a free flap is another option to reconstruct post-burn facial deformities. When the whole face needs to be resurfaced, the dorsal skin is considered as a sole donor site that can provide a large amount of skin [6]. However, when the post-burn deformity is limited to the lower face, the dorsal skin is less ideal, due to the different color and texture as relates to facial skin.

Expansion of adjacent healthy tissues has proven to be an excellent method for flap resurfacing. Within this paradigm, the supraclavicular region can be selected as the best donor

site for lower face reconstruction [16,17]. However, this reconstructive procedure is often limited in cases of severely burned patients. In all three cases presented here, the burn involved the supraclavicular regions to some degree.

Since the first report of frontal visor flaps by Dufourmentel [18] in 1919, usage of scalp flaps for lower face reconstruction has been sporadically reported in the English literature. A study of the vascular supply of the scalp with particular emphasis on the posterior branch of the superficial temporal artery revealed that it was possible to transpose a hair-bearing flap on a long, highly mobile, narrow pedicle containing this vessel. Clinical application of this finding to post-burn deformities allowed reconstruction of the hairline [19], eyebrows [20] and various shapes of beards and moustaches as either a pedicle flap [10–12] or a free flap [13,14]. However, the previous reports of facial reconstruction using the scalp aimed at reconstructing hair-bearing skin and/or camouflaging unsightly scars. Although all three cases presented here had no particular desire to have a beard and moustache, a striking feature of the frontal scalp flap was its excellent color and texture matches with the perioral skin of the male patients.

The major criticism of the classic visor flap was its donor site morbidity and resultant alopecia. Expanding a scalp tissue for burn patients was originally used to reconstruct the scalp defect caused by the injury [21]. Therefore, expansion combined with a visor flap virtually eliminated morbidity at the donor site [11].



**Fig. 5 – Case 3: A 46-year-old man sustained a 36% TBSA burn involving his face and neck. (A) Preoperative findings. (B) The flap design was based on the bilateral superficial temporal vessels. (C) The results at 6 months after the surgery.**

A previous study found that the burned scalp is associated with a higher rate of tissue expander complications compared with other regions of the head and neck [22,23]. In practice, we encountered a case that required removal of one of two expanders due to extrusion. In severe burn patients, the scalp is well recognized as an excellent source for STSG, because healing is rapid and hair re-growth conceals the donor site [9]. However, sequential harvesting of the scalp for STSG may lead to an unstable scar. In our patient, maturation of the scalp scar was required for safe insertion of the tissue expander.

The aesthetically pleasing effect of reduced male pattern baldness consequential to transfer of the alopecic scalp to the lower face was unexpected in the case 3. Moreover, we realized that the skin color of non-hair bearing scalp matches closely to the facial skin. The usefulness, on the other hand, may be curtailed in a woman because transferring a hair-bearing tissues to the face could create a consequence cosmetic unacceptable. A complete laser depilation is required when utilizing this method for female patients.

In summary, the expanded scalp flap provides definite advantages for lower facial reconstruction in male patients. Satisfactory results were obtained in all cases in which a facial aesthetic unit was completely replaced. We recommend this procedure as the treatment of choice for reconstructing perioral region, especially in severely burned male patients.

#### REFERENCES

- [1] Neale HW, Billmire DA, Carey JP. Reconstruction following head and neck burns. *Clin Plast Surg* 1986;13:119-36.
- [2] Lee JW, Jang YC, Oh SJ. Esthetic and functional reconstruction for burn deformities of the lower lip and chin with free radial forearm flap. *Ann Plast Surg* 2006;56:384-6.
- [3] Hassanpour SE, Davami B. Reconstruction of nose and lips with tubed cervical flap in electrical injury: a case report. *Burns* 2005;31:510-3.
- [4] Hoekstra K, Hudson DA, Smith AW. The use of pedicled expanded flaps for aesthetic resurfacing of the burned face. *Ann Plast Surg* 2000;45:1-6.
- [5] Rose EH. Aesthetic restoration of the severely disfigured face in burn victims: a comprehensive strategy. *Plast Reconstr Surg* 1995;96:1573-85.
- [6] Sakurai H, Takeuchi M, Fujiwara O, Soejima K, Yamaki T, Kono T, et al. Total face reconstruction with one expanded free flap. *Surg Technol Int* 2005;14:329-33.
- [7] Gonzalez-Ulloa M. Restoration of the face covering by means of selected skin in regional aesthetic units. *Br J Plast Surg* 1956;9:212-21.
- [8] Berkowitz RL. Scalp-in search of the perfect donor site. *Ann Plast Surg* 1981;7:126-7.
- [9] Taylor JW, Wilmore DW, Peterson HD, Pruitt Jr BA. Scalp as a donor site. *Am J Surg* 1977;133:218-20.
- [10] Hafezi F, Naghibzadeh B, Nouhi A. Facial reconstruction using the visor scalp flap. *Burns* 2002;28:679-83.
- [11] Datubo-Brown DD, Khalid KN, Levick PL. Tissue-expanded visor flap in burn surgery. *Ann Plast Surg* 1994;32:205-8.
- [12] Marks MW, Friedman RJ, Thornton JW, Argenta LC. The temporal island scalp flap for management of facial burn scars. *Plast Reconstr Surg* 1988;82:257-61.
- [13] Chang KP, Lai CS, Tsai CC, Lin TM, Lin SD. Total upper lip reconstruction with a free temporal scalp flap: long-term follow-up. *Head Neck* 2003;25:602-5.
- [14] Lyons GB, Milroy BC, Lendvay PG, Teston LM. Upper lip reconstruction: use of the free superficial temporal artery hair-bearing flap. *Br J Plast Surg* 1989;42:333-6.
- [15] Richardson D, Fisher SE, Vaughan ED, Brown JS. Radial forearm flap donor-site complications and morbidity: a prospective study. *Plast Reconstr Surg* 1997;99:109-15.
- [16] Pallua N, von Heimburg D. Pre-expanded ultra-thin supraclavicular flaps for (full-) face reconstruction with reduced donor-site morbidity and without the need for microsurgery. *Plast Reconstr Surg* 2005;115:1837-44.
- [17] Khouri RK, Ozbek MR, Hruza GJ, Young VL. Facial reconstruction with prefabricated induced expanded (PIE) supraclavicular skin flaps. *Plast Reconstr Surg* 1995;95:1007-15.
- [18] Dufourmental L. Restauration plastique du menton avec un lambeau de cuir chevelu complete de griffes diverses. *Soc Dermat et Syph* 1919;12:180-5.
- [19] Silfen R, Hudson DA, Soldin MG, Skoll PJ. Tissue expansion for frontal hairline restoration in severe alopecia in a child. *Burns* 2000;26:294-7.
- [20] Motamed S, Davami B. Eyebrow reconstruction following burn injury. *Burns* 2005;31:495-9.
- [21] Da Matta A. Reconstruction of postburn sequelae with expanded flaps. *Burns* 1989;15:407-11.
- [22] Pisarski GP, Mertens D, Warden GD, Neale HW. Tissue expander complications in the pediatric burn patient. *Plast Reconstr Surg* 1998;102:1008-12.
- [23] Friedman RM, Ingram Jr AE, Rohrich RJ, Byrd HS, Hodges PL, Burns AJ, et al. Risk factors for complications in pediatric tissue expansion. *Plast Reconstr Surg* 1996;98:1242-6.

## Use of a Bipedicled Thin Groin Flap in Reconstruction of Postburn Anterior Neck Contracture

Hajime Matsumine, M.D.  
 Hiroyuki Sakurai, M.D., Ph.D.  
 Yumiko Nakajima, M.D.  
 Kazuyuki Kubo, M.D.  
 Ryouhei Higuchi, M.D.  
 Motohiro Nozaki, M.D.,  
 Ph.D.  
 Tokyo, Japan

For cases of scar contracture following cervical burn trauma, after the contracture has been released, reconstructive free flap transfer is preferred over skin grafting to avoid the recurrence of contracture. It is still necessary, though, to augment this thin flap with sufficient skin by reproducing the submentocervical angle in the central region.<sup>1</sup> However, by harvesting a bipedicled thin groin flap, vascularized on both sides by the superficial circumflex iliac arteries, we found that it became possible to thin the central area of this flap, making it suitable for use in the reconstruction of scar contractures following cervical burn trauma. We outline here the favorable results obtained through this technique.

### SURGICAL METHOD

We administer general anesthesia with the patient in the supine position and the neck hyperextended, and sufficiently release the cervical scar contracture. In many cases of contracture, both the subdermal tissue and platysma in the cervical region must also be sufficiently released. After ensuring that the contracture is released and that there is sufficient cervical extension, the right and left recipient vessels are isolated and exposed. Subsequently, as shown in Figure 1, a bipedicled thin groin flap is designed to match the size of the cervical skin defect and then harvested.

*From the Department of Plastic and Reconstructive Surgery, Tokyo Metropolitan Government Hospital, and the Department of Plastic and Reconstructive Surgery, Tokyo Women's Medical University.*

*Received for publication October 17, 2007; accepted January 16, 2008.*

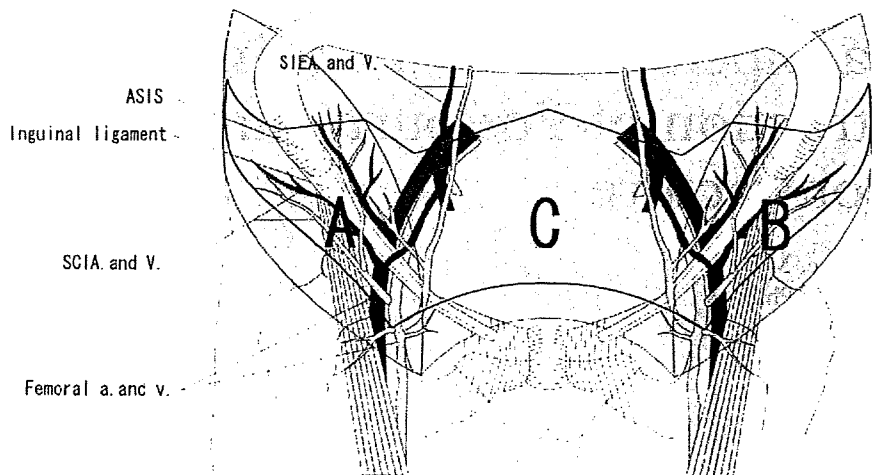
*Copyright ©2008 by the American Society of Plastic Surgeons*

DOI: 10.1097/PRS.0b013e318180ed43

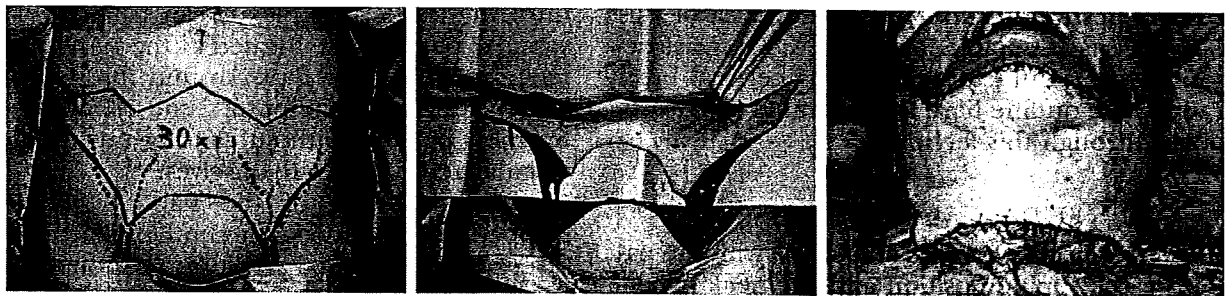
As shown in Figure 2, the superficial circumflex iliac artery and the superficial circumflex iliac vein are exposed in both pedicles at the inguinal region, and the bipedicled thin groin flap is harvested from the deep fascia. The thinning process of the flap is performed directly before division of the vascularized pedicles. The central region of the flap is located between the right and left superficial circumflex iliac arteries. The adipose tissue is removed from the medial section of this flap until the subdermal plexus can be seen. These vascular pedicles are located at the right and left lateral edges of the flap. Around these vascularized pedicles, the adipose tissue is removed as much as possible without causing trauma to the vascularized pedicles themselves.

After bleeding of the flap is sufficiently stopped, the superficial circumflex iliac artery is severed at the femoral artery bifurcation area and the superficial circumflex iliac vein is severed at the bifurcation area of the saphenous bulb. The flap is then transferred onto the anterior cervical burn area. When suturing the flap, to give form to the submentocervical angle, the flap is tacked to the soft tissue around the hyoid bone. Microvascular anastomosis is performed between the superficial circumflex iliac artery and the superior thyroid artery, and the superficial circumflex iliac vein and the common facial vein with 9-0 nylon. Primary closure is performed for the groin area of the donor site.

**Disclosure:** The authors declare that they have no conflicts of interest.



**Fig. 1.** Design of the bipedicled thin groin flap. The traditional definition of a groin flap is the area of skin 10 cm superior and inferior to the inguinal ligament, and bordered on the sides 10 cm lateral to each of the anterior superior iliac spine (ASIS). The right border of the groin flap is labeled *A* and the left is labeled *B* (both *A* and *B* are shown here as green areas), and *C* is the region located between *A* and *B* (shown here as the yellow area). This region (*C*) is in the hypogastric midline region. The bipedicled thin groin flap is designed within the region composed of *A*, *B*, and *C*. When harvesting the skin flap, it is possible to safely perform adipose tissue removal in region *C* down to the level of the subdermal plexus. However, in areas *A* and *B*, thinning of the adipose tissue should be performed as minimally as is necessary to avoid damaging the superficial circumflex iliac artery (SCIA) of the vascular pedicles.



**Fig. 2.** (Left) A bipedicled thin groin flap measuring 30 × 11 cm was planned. (Center) The flap was thinned by removing as much adipose tissue from the central region of the flap as possible and harvested. (Right) Transfer of the flap to the defect.

## CLINICAL CASES

### Case 1

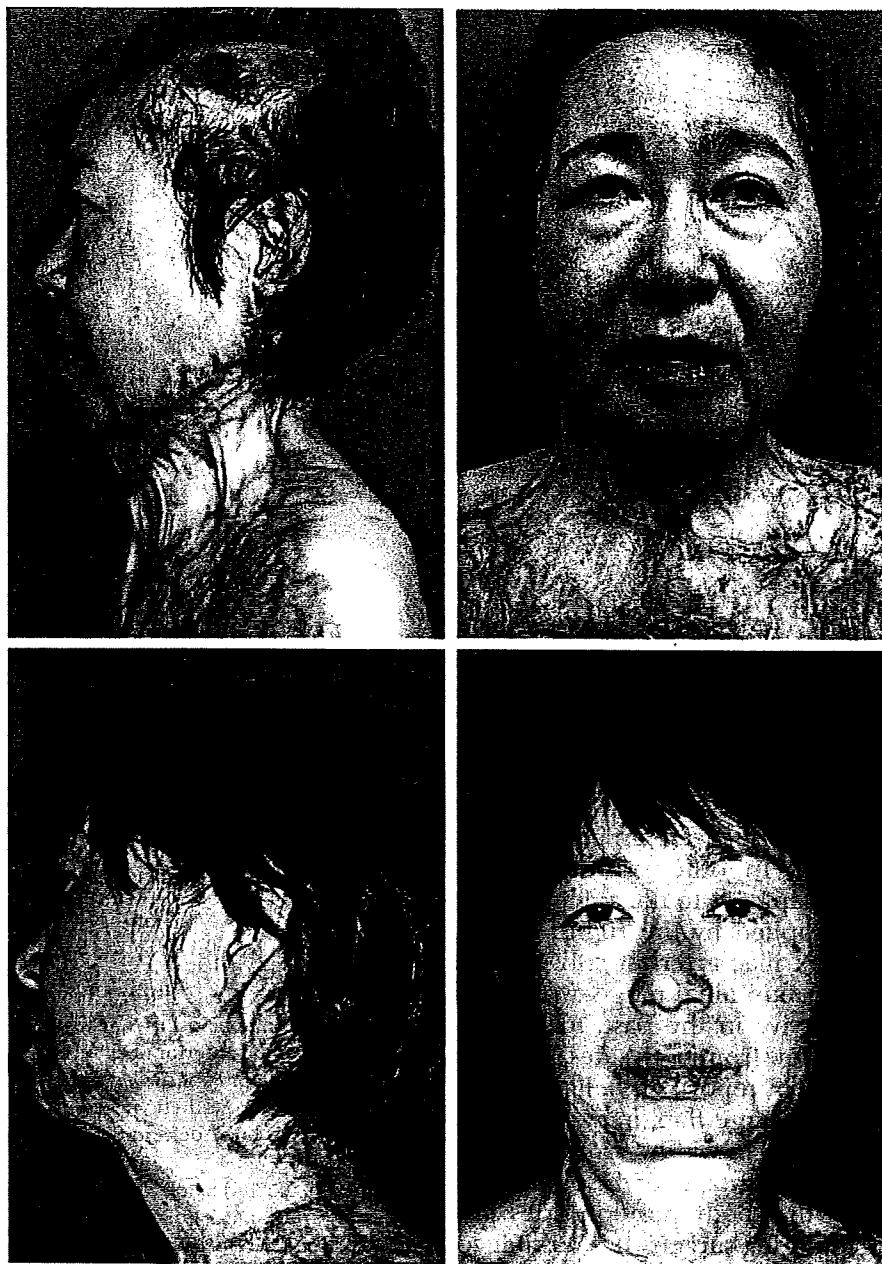A 51-year-old woman underwent repair of a cervical burn scar contracture resulting from a fire accident with a bipedicled thin groin flap. The dimensions of the flap were 30 × 11 cm. The flap took favorably, and the thinness and size were maintained even 1 year after surgery (Fig. 3).

### Case 2

A 50-year-old woman underwent repair of a cervical burn scar contracture caused by a fire accident with a bipedicled thin groin flap. The dimensions of the flap were 25 × 11 cm. Six months after reconstructive surgery, cervical extension was sufficiently possible and scarring of the mesh graft was replaced by normal skin (Fig. 4).

## DISCUSSION

Various challenges have been reported when attempting to use a thinner flap to create contour lines, particularly the submentocervical angle, through the use of free tissue transfer for reconstruction of scar contractures following cervical burn trauma.<sup>2-5</sup> In 1994, Hyakusoku et al. reported successfully using a technique of microvascular augmentation of the blood supply in the distal portion of the thinned flap, which allowed them to obtain a larger flap size.<sup>5</sup> In our patients, in place of this ultrathin flap to which blood flow was added, we used a bipedicled flap and thinned it between the vascular pedicles to the level of the subdermal

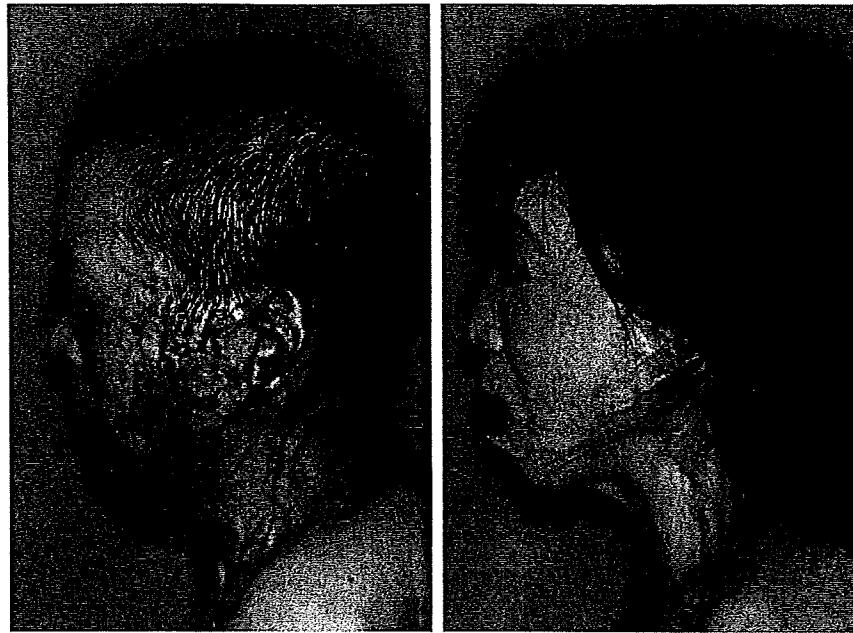

**Fig. 3.** Photographs of the patient in case 1. Preoperative lateral (*above, left*) and frontal (*above, right*) views, and postoperative lateral (*below, left*) and frontal (*below, right*) views at 1 year after neck reconstruction.

vascular network, which we could then use in the reconstructive surgery.

The angiosome of the superficial circumflex iliac artery at the vascular pedicle of the groin flap extends 10 cm higher and lower than the inguinal ligament, with the outer edges exceeding the anterior superior iliac spine at a range of 10 cm,<sup>6</sup> and the hypogastric central region is supplied by the superficial inferior epigastric artery and deep inferior epigastric artery. In contrast, after the

paraumbilical perforator arising from the main terminal branches of deep inferior epigastric artery pierces the rectus sheath, it fans out from the umbilical region in cranial, lateral, and caudal directions to form arterial network connections with the superficial circumflex iliac artery and superficial inferior epigastric artery.<sup>7</sup> Chang et al. used a circumferential skin flap from the lower abdomen to the back to study how an arterial supercharging procedure could generate large



**Fig. 4.** Photographs of the patient in case 2. (Left) Preoperative lateral view. (Right) Postoperative lateral view at 6 months after neck reconstruction.

flap survival areas with different supercharging positions in rats, and reported that distal arterial supercharging is more effective than proximal arterial supercharging.<sup>8</sup> In other words, the bipediced thin groin flap adds to the angiosome of both groin areas supplied by the right and left superficial circumflex iliac arteries, and enables the adjacent central abdominal range, which has not been able to survive in the past, to be supported by the blood flow from both sides. Thus, as described in the present report, we believe that it is possible to harvest a large flap, in excess of 30 cm in length and 10 cm in width.

Furthermore, the advantages of the bipediced thin groin flap are that body position does not need to be changed during surgery. It is possible to achieve primary closure of the donor site with a flap as wide as 12 cm, and when the flap is placed on the neck region, vascular anastomosis is performed very easily because the vascular pedicles are located at both distal edges of the flap, so they are close to the location of the cervical recipient vessels.

#### CONCLUSIONS

We have reported favorable results obtained using the bipediced thin groin flap in the reconstruction of scar contracture following cervical burn trauma. The central region of this flap can be thinned, which allows for superior formation of the submentocervical angle.

*Hajime Matsumine, M.D.*

Department of Plastic and Reconstructive Surgery  
Tokyo Metropolitan Government Hospital  
2-9-2 Musashidai  
Fuchu-shi, Tokyo 183-8524, Japan  
matsumine@hkg.odn.ne.jp

#### REFERENCES

1. Ohkubo, E., Kobayashi, S., Sekiguchi, J., and Ohmori, K. Restoration of the anterior neck surface in the burned patient by free groin flap. *Plast. Reconstr. Surg.* 87: 276, 1991.
2. Angrigiani, C. Aesthetic microsurgical reconstruction of anterior neck burn deformities. *Plast. Reconstr. Surg.* 93: 507, 1994.
3. Kimura, N., and Satoh, K. Consideration of a thin flap as an entity and clinical applications of the thin anterolateral thigh flap. *Plast. Reconstr. Surg.* 97: 985, 1996.
4. Sasaki, K., Nozaki, M., Honda, T., Morioka, K., Kikuchi, Y., and Huang, T. The deltopectoral skin flap as a free flap revisited. *Plast. Reconstr. Surg.* 107: 1134, 2001.
5. Hyakusoku, H., Pennington, D. G., and Gao, J. H. Microvascular augmentation of the super-thin occipito-cervico-dorsal flap. *Br. J. Plast. Surg.* 47: 465, 1994.
6. Hester, T. R., Jr., Nahai, F., Beegle, P., and Bostwick, J., III. Blood supply of the abdomen revisited, with emphasis on the superficial inferior epigastric artery. *Plast. Reconstr. Surg.* 74: 657, 1984.
7. Boyd, J. B., Taylor, G. I., and Corlett, R. The vascular territories of the superior epigastric and deep inferior epigastric systems. *Plast. Reconstr. Surg.* 73: 1, 1984.
8. Chang, H., Nobuaki, I., Minabe, T., and Nakajima, H. Comparison of three different supercharging procedures in a rat skin flap model. *Plast. Reconstr. Surg.* 113: 277, 2004.



ELSEVIER



## Effect of vascular augmentation on the haemodynamics and survival area in a rat abdominal perforator flap model

Yusuke Yamamoto \*, Hiroyuki Sakurai, Hiroaki Nakazawa, Motohiro Nozaki

Department of Plastic and Reconstructive Surgery, Tokyo Women's Medical University, Tokyo, Japan

Received 12 April 2007; accepted 24 November 2007

### KEYWORDS

DIEP flap;  
Vascular augmentation;  
Venous pressure;  
Rats

**Summary** A major drawback of the DIEP flap is the compromised venous drainage in the distal area, which is the rationale behind the creation of additional venous anastomoses for better flap survival. Although venous congestion is defined as an increase in the venous pressure, the effect of vascular augmentation on the venous pressure has not been elucidated. We investigated the effects of arterial supercharge and venous superdrainage on the venous pressure and the flap survival area in a rat abdominal perforator flap model.

An abdominal perforator flap was raised in each of 30 Wistar rats, with the contralateral superficial inferior epigastric artery (SIEA) and vein (SIEV) isolated for pressure measurements. The changes in the SIEV pressure were recorded while proximal sites of these vessels were opened and closed. Thereafter, the animals were divided into three groups: a control group ( $n = 10$ , both the SIEA and SIEV were ligated), an enhanced arterial inflow (EAI) group ( $n = 10$ , the SIEA was left intact) and a supplemental venous outflow (SVO) group ( $n = 10$ , the SIEV was left intact). The flap survival area was determined 7 days after surgery.

The SIEV pressure without vascular augmentation was only  $13.2 \pm 5.9$  mmHg. Compared with the control group, the flap survival area was significantly larger in the EAI group, but not in the SVO group. An extremely high venous pressure was noted when the SIEA was opened and the SIEV was occluded, but there was great variation among the individual animals (range: 21.2–79.6 mmHg). The necrotic area in the EAI group correlated well with the SIEV pressure ( $r = 0.861$ ).

These findings indicate that the major factor contributing to distal necrosis in this rat perforator flap model is arterial insufficiency rather than venous congestion. The results suggest that, as long as the arterial inflow is secure, the venous pressure is a reliable parameter for deciding the necessity of venous superdrainage.

© 2008 British Association of Plastic, Reconstructive and Aesthetic Surgeons. Published by Elsevier Ltd. All rights reserved.

\* Corresponding author. Address: Department of Plastic and Reconstructive Surgery, Tokyo Women's Medical University, 8-1 Kawada-cho, Shinjuku-ku, Tokyo 162-8666, Japan. Tel.: +81 3 3353 8111; fax: +81 3 3225 0940.

E-mail address: k-0135@prs.twmu.ac.jp (Y. Yamamoto).



A deep inferior epigastric perforator (DIEP) flap has been shown to be clinically useful as an autologous tissue material for soft tissue reconstruction, especially in breast mound reconstruction. The morbidities, such as pain and discomfort, experienced by patients are much less than with transverse rectus abdominis myocutaneous (TRAM) flaps.<sup>1-3</sup> On the other hand, the major drawbacks of the DIEP flap technique include increased operative complexity and compromised flap circulation, especially in the distal segment area, i.e. zone IV. Reduction of the number of perforating branches through the rectus abdominis muscle, which are intrinsic to the design of a DIEP flap, is thought to have the potential to cause flap necrosis.<sup>4</sup>

Since the compromised circulation in DIEP flaps occurs predominantly on the venous side, creation of an additional venous anastomosis, so-called 'superdrainage', on the side contralateral to the vascular pedicle, has been reported.<sup>5,6</sup> The superficial inferior epigastric vein (SIEV) was preferentially used as an additional venous drainage route. However, the effects of vascular augmentation on the arterial and/or venous side have not been fully elucidated. In addition, there is no objective standard for predicting the necessity of vascular augmentation during surgery.

Passive congestion is brought about by diminished venous outflow and causes an increase in the venous blood pressure.<sup>7</sup> Rooks et al.<sup>8</sup> showed a positive correlation between increased venous pressure and free flap failure in rabbits. We postulated that the venous pressure on the side contralateral to the vascular pedicle might be a reliable parameter for deciding the necessity of venous augmentation, since an increase in the venous pressure was the most sensitive parameter indicating venous insufficiency.<sup>9</sup>

Several experimental models have been developed to elucidate the physiology and haemodynamics in the DIEP flap.<sup>10,11</sup> The present study had two purposes. One was to evaluate the respective effects of arterial and venous enhancement on the survival area and the haemodynamics within the rat perforator flap. The other was to determine whether the venous pressure on the side contralateral to the vascular pedicle could serve as a reliable parameter for deciding the necessity of vascular augmentation.

## Materials and methods

The experimental protocol used in this study met the standards of, and was approved by, the Animal Welfare Committee of Tokyo Women's Medical University. Thirty male Wistar rats weighing between 408 and 560 g were used for this experimental study. Intraperitoneal injection of pentobarbital (35 mg/kg) and ketamine (100 mg/kg) was used to anaesthetise the animals for the procedures. The animals were housed in individual cages and fed standard rat chow and water ad libitum upon completion of the procedures. All rats were sacrificed on the seventh postoperative day. The condition of each flap and the extent of flap survival were assessed.

### Design of a perforator flap

The technique described by Oksar et al.<sup>10</sup> was applied to fabricate a DIEP flap in the animals. A perforator flap was

fabricated in the abdomen, based on the second perforator that penetrated the right rectus abdominis muscle as the main pedicle. The borders of the flap were superior to the horizontal line crossing from the tip of the xiphoid and inferior to the transverse line crossing from both anterosuperior iliac spines just above the pubis. The skin flap was elevated at a level beneath the panniculus carnosus. The left superficial inferior epigastric artery (SIEA) and SIEV were preserved for arterial and venous augmentation (Figure 1). Catheters (Sureflow™ Indwelling Needle; Terumo, Tokyo, Japan, 24 G, internal diameter of 0.47 mm) were inserted into the left femoral artery (FA) and vein (FV) at sites distal to the origins of the SIEA and SIEV. The FA and FV were isolated proximal to the origin of the superficial epigastric vessels. All other branches were ligated and severed. The pressure changes in the SIEA and SIEV were monitored through the catheters inserted into the FA and FV. The flap was sutured back in place during vascular pressure measurement.

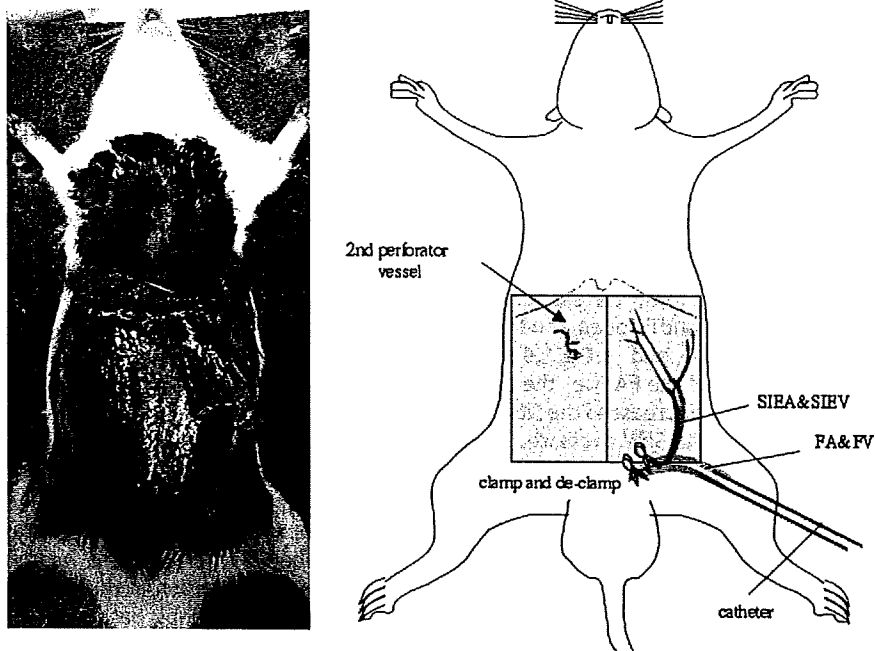
### Recording of the vascular pressure changes while manipulating proximal sites of the femoral artery and vein

The catheters were connected to a fluid pressure transducer (P231D, Statham Gould, Oxnard, CA, USA) and a physiological recorder (BSS-9800, Nihon Kohden Co., Tokyo, Japan). Zero calibrations were made at the level of the right atrium. The arterial and venous pressures were recorded continuously with a computerised data acquisition system (PowerLab™, ADInstruments Pty. Ltd, Australia).

To determine the effects of arterial inflow or venous outflow enhancement on the vascular pressure within the flap, the proximal sites of the FA and FV were manipulated as follows (Figure 2). Measurement was started with the FA and FV open, representing the status of arterial supercharge and venous superdrainage of the DIEP flap (the first manipulation). The FA was clamped once a stable haemodynamic status had been achieved, thus imitating the state of venous superdrainage without arterial supercharge (the second manipulation). The circulatory system in a clinical DIEP flap was mimicked by clamping the femoral vein without any extravascular manipulation (the third manipulation). The fourth manipulation, to examine the effect of augmented arterial inflow to the flap without providing supplemental efferent vessels, was achieved by releasing the femoral arterial clamp. Release of the femoral vein clamp, i.e. the fifth manipulation, represented restoration of the flap circulatory system to the initial state. The venous pressure and arterial pressure values were recorded using the customised programme included in the data acquisition system (PowerLab™).

### Flap viability

Upon completing measurement of the haemodynamic changes associated with the manipulations of the contralateral FA and FV, the animals were randomly divided into a control group and two treatment groups based on the type of vascular augmentation. The control animals had both the SIEA and SIEV ligated ( $n = 10$ ). The SIEA was retained in the enhanced arterial inflow (EAI) group



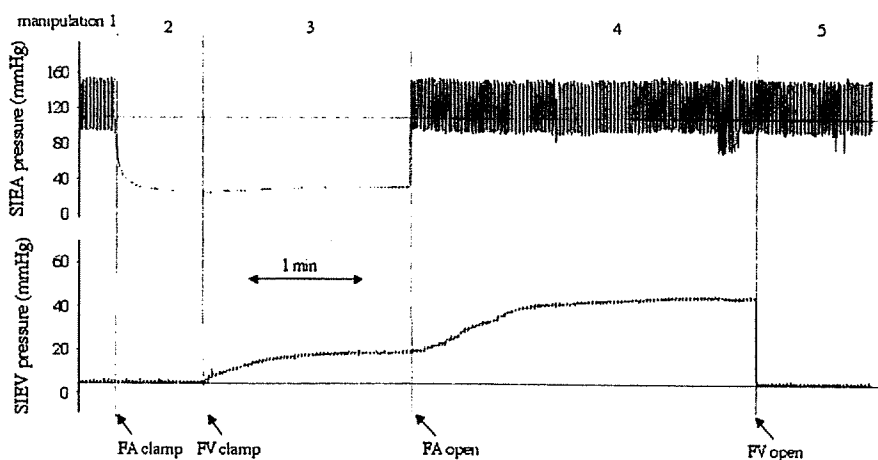
**Figure 1** The skin flap was based on the second cranial perforator penetrating the right rectus abdominal muscle. The left SIEA and SIEV were isolated for vascular augmentation and venous pressure measurement. The arrows indicate the perforating vessels.

( $n = 10$ ), and the SIEV was retained in the supplemental venous outflow (SVO) group ( $n = 10$ ). The animals were sacrificed on the 7th day, and the status of the DIEP flap was recorded by tracing the area of flap necrosis on a clear template. The templates were electronically scanned, and then the total flap area (TFA,  $\text{cm}^2$ ) and the necrotic area (NA,  $\text{cm}^2$ ) were calculated using computer software (NIH image 1.63). The percentage of the surviving area (SA%) was calculated using the following equation:

$$SA\% = 100 \times (TFA - NA) / TFA$$

**Statistical analysis**

Data are expressed as the mean  $\pm$  SD. Analysis of variance (Scheffe's test) was used to detect significant differences. Calculations were performed using the GLM procedure of



**Figure 2** A representative tracing of the SIEA and SIEV pressures during vascular manipulation. During the first and fifth manipulation, both the left SIEA and left SIEV were opened. When the proximal side of the femoral artery (FA) was closed (the second manipulation), the SIEA pressure decreased. Subsequent occlusion of the proximal side of the femoral vein (FV) led to a slight increase in the SIEV pressure (the third manipulation). A further increase in the SIEV was noted when the FA was opened (the fourth manipulation).

SAS<sup>®</sup> software, and  $P < 0.05$  was regarded as indicating statistical significance.

## Results

### Venous pressure elevation

Changes in the venous pressure were noted immediately in all flaps subjected to vascular manipulation. The venous pressure reached a plateau within a few minutes. During the first manipulation, with both the FA and FV open, the SIEA and SIEV pressures were  $106.2 \pm 10.0$  and  $6.0 \pm 1.6$  mmHg, respectively (Table 1). Occlusion of the FA (i.e. the second manipulation) led to an immediate decrease in the SIEA pressure. It did not, however, affect the SIEV pressure. Subsequent occlusion of the femoral vein (the third manipulation) led to a gradual increase in the SIEV. The SIEV eventually reached a plateau, which was considered to be the venous pressure without any vascular augmentation. Although the SIEV pressure was significantly increased compared with the value in the first manipulation (Table 1), the increment in the venous pressure compared with that in the first manipulation was only  $7.2 \pm 5.4$  (range: 0.7–19.5) mmHg. A further increase in the venous pressure was noted after the FA was opened. In this state (the fourth manipulation), the SIEV pressure was  $44.0 \pm 16.4$  mmHg. However, there was considerable individual variation in the extent of elevation (range: 21.2–79.6 mmHg). When the FV was reopened, the mean venous pressure immediately decreased to  $5.9 \pm 1.6$  mmHg. There were no significant differences in the vascular pressures among the three groups with any of the manipulations.

### Flap viability

Necrosis never occurred on the right side of the flap, where the perforating vascular pedicle was in place. In the control group, the SA% was  $77.0 \pm 11.3\%$ . The supplemental venous outflow created on the side opposite the perforator flap had a higher SA% ( $86.9 \pm 8.8\%$ ), although it was not significantly different from the control. Statistically significant improvement in the SA%, however, was noted in the EAI group ( $93.3 \pm 10.6\%$ ) (Figure 3). Moreover, no necrotic changes were observed in the flap in five of the 10 animals in this group. A close correlation with the SIEV pressure changes, as seen with the fourth manipulation, was noted for the extent of flap necrosis in animals with arterial supercharge (Figure 4).

## Discussion

Although the efficacy of vascular augmentation in the distal area has been well documented in rat abdominal flaps,<sup>12–15</sup> the relative importance of arterial supercharge versus venous superdrainage in enhancing flap survival has remained unclear. The rat skin is predominantly supplied by a superficial vascular system with direct cutaneous vessels running parallel to the longitudinal axis. Therefore, in previous studies rat abdominal flaps had been raised with the ipsilateral SIEA and SIEV as the vascular pedicles, and the effects of retaining the contralateral SIEA or SIEV on the surviving area were determined.<sup>12–15</sup> Miles et al.<sup>13</sup> demonstrated a significantly increased survival area with venous enhancement compared with a single-pedicle rat abdominal flap. However, when the relative importance of arterial versus venous augmentation was investigated, arterial supercharge consistently led to a wider survival area compared with venous superdrainage.<sup>14,15</sup> Therefore, it was believed that ischaemia was a more important factor than venous congestion in the causation of partial necrosis of rat abdominal flaps based on the superficial vascular system.<sup>16</sup>

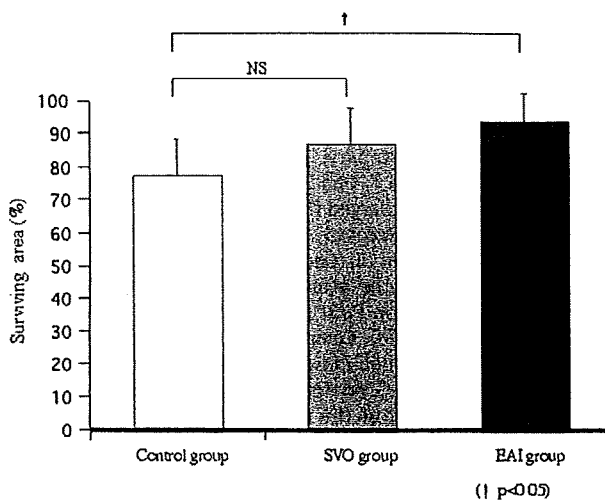
Breast reconstruction using DIEP flaps is a well-established method that is increasingly performed to reduce donor site morbidity.<sup>1–3</sup> In recent years, comparable rat abdomen flap models have been developed based on the cranial epigastric perforator<sup>10,11,17</sup> rather than on the superficial vascular system. Hallock et al.<sup>11</sup> demonstrated that retention of the contralateral SIEV resulted in significant enhancement of perforator flap viability. Although they did not test the effect of arterial supercharge using the contralateral SIEA, the survival area with SIEV retention was nearly 100%, demonstrating the importance of an additional venous route in any muscle perforator flap.

In our present study, we found the survival area to be larger with venous augmentation, although there was no statistically significant difference compared with the control flap. Inability to reproduce the effect of venous superdrainage may be attributable to the small number of animals as well as differences in the size of the flap and selection of the perforator depending on the flap model.<sup>11,17</sup> Another possible explanation for the discrepancy is the timing of assessment of the surviving area. We measured the surviving area at 7 days after flap elevation, a time when any necrosis would be fully developed and clearly demarcated, as described by Finseth et al.<sup>18</sup> On the other hand, Hallock et al.<sup>11</sup> determined flap viability at 48 h after flap elevation. Discoloration occurs earlier in

**Table 1** Superficial inferior epigastric artery and venous pressures ( $n = 30$ )

Measurement manipulation	Occlusion	Vascular augmentation		SIEV pressure (mmHg)	SIEA pressure (mmHg)
		SIEA	SIEV		
1	None	+	+	$6.0 \pm 1.6$ (3.6–11.9)	$106.2 \pm 10.0$ (85.5–124.4)
2	FA	–	+	$5.8 \pm 1.6$ (3.3–11.0)	$22.7 \pm 9.5$ (11.8–44.1)
3	FA & FV	–	–	$13.2 \pm 5.9$ (5.7–25.3)	$22.0 \pm 11.7$ (11.4–61.8)
4	FV	+	–	$44.0 \pm 16.4$ (21.2–79.6)	$102.9 \pm 10.8$ (84.9–126.4)
5	None	+	+	$5.9 \pm 1.6$ (3.2–11.7)	$101.8 \pm 11.3$ (84.5–126.8)

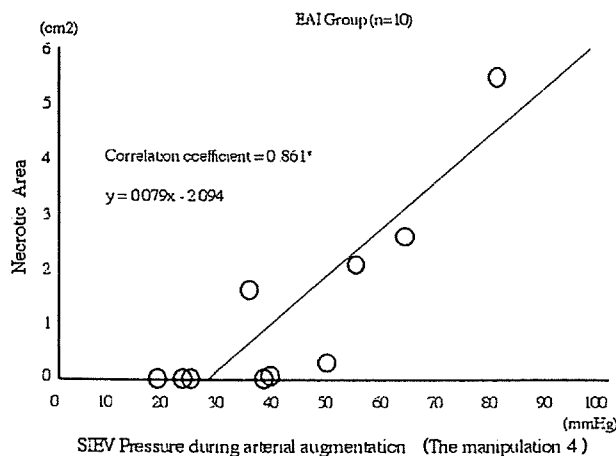
Data were represented as mean  $\pm$  SEM (ranges).



**Figure 3** The survival area in each group 7 days after flap elevation. † Significant difference ( $P < 0.05$ ) vs the control group.

the case of flap necrosis caused by venous congestion, and 48-h observation is sufficient to judge the necrotic area. However, this time frame may lead to underestimation of the necrotic area caused by insufficient arterial inflow, because the demarcation of ischaemic necrosis shows slower progression.<sup>18,19</sup>

In order to determine whether or not the distal area of the rat perforator flap showed passive congestion, we measured the contralateral SIEV pressure. However, the contralateral SIEV did not show a critically high pressure without vascular augmentation, as shown by the third manipulation reading. In conjunction with the data on the survival area, the major factor contributing to partial necrosis in the present rat perforator flap model seemed to be the arterial inflow rather than the venous outflow. These findings are in agreement with those of previous reports regarding rat abdominal flap models based on the superficial vascular system.<sup>13–15</sup> However, they are in conflict with clinical observations on DIEP flaps,<sup>5,20</sup> indicating that there are limitations on the



**Figure 4** The correlation between the necrotic area ( $\text{cm}^2$ ) and the SIEV pressure during arterial supercharge (the fourth manipulation) in the EAI group ( $n = 10$ ).

applicability of the rat perforator flap model to the clinical setting.<sup>21</sup>

An extremely high venous pressure in the distal part of the flap was noted when arterial augmentation was performed (in the fourth manipulation study), with quite high variability among the individual animals (range: 21.2–79.6 mmHg). In addition, partial necrosis of the distal region occurred in half of the animals in the arterial augmentation group, indicating that arterial supercharge alone may sometimes not be sufficient to achieve complete flap survival. Thus, some animals might also require venous superdrainage. It is conceivable that variations in the communicating veins crossing the midline underlie this phenomenon.<sup>15,20</sup>

In the clinical setting, the flap colour and bleeding from the margin are used to detect ischaemia or congestion, with the need for anastomosis of another vessel empirically decided on the basis of the findings. However, there has been no objective standard for judging the necessity of vascular augmentation. It is of interest that the results for the SIEV pressure during arterial supercharge (the fourth manipulation study) correlated well with flap viability in the EAI group. In this group, all four animals in which the SIEV pressure exceeded 50 mmHg showed partial necrosis of the distal area, whereas all three animals in which the SIEV was less than 30 mmHg showed survival of the entire flap (Figure 4). These findings suggest that the venous pressure is a reliable parameter for assessing the necessity of venous superdrainage as long as the arterial inflow is secure. Currently, we use intraparenchymatous pressure-monitoring to detect venous thrombosis after free tissue transfer.<sup>9</sup> We consider a venous pressure over 50 mmHg to be an absolute indication for re-exploration of the need for addition of an extra-efferent vessel to the circulatory system.

Although the venous pressure in the distal area is a reliable parameter for detecting passive congestion, its accuracy in predicting flap survival is limited, especially when the arterial inflow is compromised. Further investigations using other types of flap model are required to establish an objective standard for predicting the necessity of vascular augmentation during surgery.

## Acknowledgements

This work was funded in part by a Grant-in-aid for Scientific Research, Japan, and a Grant-in-aid for Cancer Research from the Japanese Ministry of Health, Labor and Welfare. The authors thank Dr Ted T. Huang for his help in the preparation of the manuscript.

## References

1. Hamdi M, Weiler-Mithoff EM, Webster MH. Deep inferior epigastric perforator flap in breast reconstruction: experience with the first 50 flaps. *Plast Reconstr Surg* 1999;103:86–95.
2. Blondeel PN, Vanderstraeten GG, Monstrey SJ, et al. The donor site morbidity of free DIEP flaps and free TRAM flaps for breast reconstruction. *Br J Plast Surg* 1997;50:322–30.
3. Gill PS, Hunt JP, Aldo MPH, et al. A 10-year retrospective review of 758 DIEP flaps for breast reconstruction. *Plast Reconstr Surg* 2004;113:1153–60.