

11. Fang WT, Chen WH, Chen Y, Jiang Y. Selective three-field lymphadenectomy for thoracic esophageal squamous carcinoma. *Dis Esophagus* 2007;20:206–11.
12. Kitagawa Y, Fujii H, Mukai M, Kubota T, Ando N, Ozawa S, et al. Intraoperative lymphatic mapping and sentinel lymph node sampling in esophageal and gastric cancer. *Surg Oncol Clin North Am* 2002;11:293–304.
13. Kato H, Miyazaki T, Nakajima M, Takita J, Sohda M, Fukai Y, et al. Sentinel lymph nodes with technetium-99m colloidal rhenium sulfide in patients with esophageal carcinoma. *Cancer* 2003;98:932–9.
14. Lamb PJ, Griffin SM, Burt AD, Lloyd J, Karat D, Hayes N. Sentinel node biopsy to evaluate the metastatic dissemination of oesophageal adenocarcinoma. *Br J Surg* 2005;92:60–7.
15. Arima H, Natsugoe S, Uenosono Y, Arigami T, Ehi K, Yanagita S, et al. Area of nodal metastasis and radioisotope uptake in sentinel nodes of upper gastrointestinal cancer. *J Surg Res* 2006;135:250–4.
16. Takeuchi H, Kitajima M, Kitagawa Y. Sentinel lymph node as a target of molecular diagnosis of lymphatic micrometastasis and local immunoresponse to malignant cells. *Cancer Sci* 2008;99:441–56.
17. Kitagawa Y, Mukai M, Nakahara T, Saikawa Y, Takeuchi H, Kubo A, et al. Clinical significance of molecular metastasis in sentinel lymph nodes of esophageal cancer. *Esophagus* 2007;4:19–22.
18. Kitajima M, Kitagawa Y. Surgical treatment of esophageal cancer: the advent of the era of individualization. *N Engl J Med* 2002;347:1705–9.
19. Ando N, Iizuka T, Ide H, Ishida K, Shinoda M, Nishimaki T, et al. Surgery plus chemotherapy compared with surgery alone for localized squamous cell carcinoma of the thoracic esophagus: a Japan Clinical Oncology Group study—JCOG 9204. *J Clin Oncol* 2003;21:4592–6.

Editorial

Sentinel Node Biopsy Without Scars

Does Natural Orifice Transluminal Endoscopic Surgery Herald a New Era for Early GI Cancer?

Hiroya Takeuchi, MD, PhD and Yuko Kitagawa, MD, PhD, FACS

Department of Surgery, Keio University School of Medicine, 35 Shinanomachi, Shinjuku-ku, Tokyo 160-8582, Japan

Histopathological status of regional lymph nodes is one of the most significant predictors of recurrence and overall survival for most clinical stage I/II gastrointestinal (GI) cancer, and is often used to justify stratification of patients for adjuvant therapy. More accurate and efficient diagnosis of lymphatic spread and prognostic information can be obtained from a small number of lymph nodes, by intraoperative sentinel node (SN) mapping and sentinel lymphadenectomy. SN navigation surgery is a novel method of minimally invasive surgery which avoids unnecessary lymph node dissection, following diagnosis of nodal metastasis targeting SN.

The clinical applications of SN mapping for GI cancer have been controversial. However, single-institutional results, including ours, of SN mapping for early colorectal cancer or gastric cancer are increasingly being considered acceptable in terms of detection rate and accuracy to determine regional lymph node status.^{1–3} Developing a novel laparoscopic minimally invasive colectomy or gastrectomy based on intraoperative SN mapping has been attempted.

Recently the philosophy of surgery has been dramatically revolutionized by the appearance of a new technique referred to as natural orifice transluminal endoscopic surgery (NOTES), because the transluminal approach can yield patient benefit by avoiding any scar on the body surface.^{4,5} NOTES might be figuratively regarded as a second coming of the laparoscopic surgery of the 1990s, and currently there

has been drastic acceleration in the exploration of new techniques.

The current article by Cahill et al.⁶ reports on lymphatic mapping and SN biopsy by transgastric NOTES in the porcine model. The authors describe that lymphatic mapping and SN biopsy in the colonic mesentery were easily performed with the transgastric NOTES technique, and concluded that SN biopsy is indeed feasible without abdominal incision. The article may represent a valuable signpost for the future direction of SN biopsy for early GI cancer. Combination of endoscopic mucosal resection (EMR) with SN biopsy by NOTES might be an ideal minimally invasive surgical strategy for cN0 early GI cancer. If the SN is reliably recognizable via transluminal access and is negative for cancer metastasis, unnecessary radical lymph node dissection with skin incisions could be avoided.

NOTES might herald a new era in surgery; however, there are many technical and ethical issues still to be solved. In fact, the authors already reported the first successful NOTES cholecystectomy in a human being in 2007,⁷ and they also mentioned that “we witnessed the introduction of NOTES into clinical practice with mixed feelings of excitement and caution.” Even now most endoscopic devices have limitations with regard to surgical procedures such as tissue resection, traction, or suturing. Other issues also remain as follows: Which organ provides the most suitable access route for NOTES? How should the access site be closed? How can we prevent intraperitoneal infection? Should the operators be surgeons or gastroenterologists or both? Several research groups in the USA and Europe have sequentially reported their advances, mainly in animal models.

Published online July 26, 2008.

Address correspondence and reprint requests to: Hiroya Takeuchi, MD, PhD; E-mail: hiroyatakeuchi@aol.com

Published by Springer Science+Business Media, LLC © 2008 The Society of Surgical Oncology, Inc.

Several problems for future clinical applications of SN biopsy by NOTES also remain. Although blue dye is useful for visualizing the lymphatic vessels and SN, it may be difficult for NOTES to visualize the dye due to fast transit and blind sites in dense fat, particularly in obese patients. Radioactive colloid such as technetium-99m-labeled tin colloid may be useful to identify the SN using the NOTES approach. However intraoperative gamma probing and a special gamma detector introducible endoscopically to locate the radioactive SN should be developed for NOTES as soon as possible. Furthermore, a well-designed feasibility study of SN mapping by NOTES for early GI cancer should be considered as the next step, because SN mapping has to be extremely accurate as a diagnostic tool for identification of clinically undetectable lymph node metastasis.

To date NOTES has not yet been guaranteed as a safe clinical procedure, and it might need several years for the development of new endoscopes and related devices. However we remember the worldwide explosion of laparoscopic surgery in the 1980s and 1990s. Further exploration may permit innovations

of surgical oncology for early GI cancer by SN mapping via NOTES.

REFERENCES

1. Saha S, Dan AG, Viehl CT, et al. Sentinel lymph node mapping in colon and rectal cancer: its impact on staging, limitations, and pitfalls. *Cancer Treat Res* 2005; 127:105-22.
2. Bilchik AJ, Saha S, Wiese D, et al. Molecular staging of early colon cancer on the basis of sentinel node analysis: a multicenter phase II trial. *J Clin Oncol* 2001; 19:1128-36.
3. Kitagawa Y, Fujii H, Mukai M, et al. The role of the sentinel lymph node in gastrointestinal cancer. *Surg Clin North Am* 2000; 80:1799-809.
4. Kalloo AN, Singh VK, Jagannath SB, et al. Flexible transgastric peritoneoscopy: a novel approach to diagnostic and therapeutic interventions in the peritoneal cavity. *Gastrointest Endosc* 2004; 60:114-7.
5. Allori AC, Leitman IM, Heitman E. Natural orifice transluminal endoscopic surgery. *Arch Surg* 2008; 243:333-4.
6. Cahill R, Perretta S, Leroy J, et al. Lymphatic mapping and sentinel node biopsy in the colonic mesentery by natural orifice transluminal endoscopic surgery (NOTES). *Ann Surg Oncol* (in press).
7. Marescaux J, Dallemagne B, Perretta S, et al. Surgery without scars. Report of transluminal cholecystectomy in a human being. *Arch Surg* 2007; 142:823-7.

Sentinel lymph node as a target of molecular diagnosis of lymphatic micrometastasis and local immunoresponse to malignant cells

Hiroya Takeuchi,¹ Masaki Kitajima and Yuko Kitagawa

Department of Surgery, Keio University School of Medicine, 35 Shinanomachi, Shinjuku-ku, Tokyo 160-8582, Japan

(Received August 17, 2007/Revised October 31, 2007/Accepted November 4, 2007/Online publication December 9, 2007)

The sentinel lymph node (SLN) is defined as the lymph node(s) first receiving lymphatic drainage from the site of the primary tumor. The histopathological status of SLN is one of the most significant predictors of recurrence and overall survival for most clinical stage I/II solid tumors. Recent progress in molecular techniques has demonstrated the presence of micrometastatic tumor cells in SLN. There is now a growing body of data to support the clinical relevance of SLN micrometastasis in a variety of solid tumors. Increasing the sensitivity of occult tumor cell detection in the SLN, using molecular-based analysis, should enable a more accurate understanding of the clinical significance of various patterns of micrometastatic nodal disease. The establishment of metastasis to SLN might not be simply reflected by the flow dynamics of lymphatic fluid that drains from the primary site to the SLN, and the transportation of viable cancer cells. Recent studies have demonstrated that primary tumors can actively induce lymphangiogenesis and promote SLN metastasis. Moreover chemokine receptors in tumor cells may facilitate organ-specific tumor metastasis in many human cancers and some experimental models. In contrast, recent clinical and preclinical studies regard SLN as the first lymphoid organ to respond to tumor antigenic stimulation. SLN dramatically show morphological, phenotypical and functional changes that indicate immune suppression by tumor cells. The immune suppression in SLN results in failure of prevention or eradication of tumor metastasis. The mechanism of immunomodulation remains unclear; however, several regulatory molecules produced by tumor cells and tumor-associated macrophages or lymphocytes are likely to be responsible for inducing the immune suppression in SLN. Further studies may develop a novel immunotherapy that overcomes tumor-induced immune suppression and can prevent or eradicate SLN metastasis. (*Cancer Sci* 2008; 99: 441–450)

In the history of the surgical treatment of malignant tumors, the standard procedure has been to perform complete dissection of regional lymph nodes in addition to the primary tumor. This has been believed to improve patients' survival.⁽¹⁾ However, the clinical significance of prophylactic lymph node dissection for patients without lymph node metastasis has been the subject of controversy over the past 10 years.^(2–4)

Given this background, the concept of the sentinel lymph node (SLN), intraoperative lymphatic mapping and sentinel lymphadenectomy appeared attractive.⁽⁵⁾ The SLN is defined as the lymph node(s) first receiving lymphatic drainage from the site of a tumor (Fig. 1).⁽⁵⁾ The pathological status of the SLN is thought to predict the status of all regional lymph nodes. If the SLN is recognizable and negative for cancer metastasis, unnecessary radical lymph node dissection could be avoided. The SLN hypothesis was advanced to specifically address those patients at

high risk of having lymph node (LN) metastasis based on the characteristics of their primary tumors, but who had no evidence of clinically detectable regional metastatic disease.

The histopathological status of tumor-draining regional LN is one of the most significant predictors of recurrence and overall survival for most clinical stage I/II solid tumors, and is often used to justify stratification of patients for adjuvant therapy.^(6,7) More efficient and accurate diagnosis of LN metastasis and prognostic information can be obtained from a small number of LN, by intraoperative lymphatic mapping and sentinel lymphadenectomy.^(5,8)

SLN mapping and biopsy was first applied to melanoma, and was subsequently extended to breast cancer and, more recently, to many other solid tumors including colorectal, gastric, esophageal, gynecologic, head and neck, thyroid, urologic, and non-small cell lung cancers.^(9–16) The SLN concept has revolutionized the approach to the surgical staging of both melanoma and breast cancer, and these techniques can yield patient benefit by avoiding various complications due to unnecessary prophylactic complete LN dissection in cases with negative SLN for cancer metastasis.

Hematoxylin and eosin (H&E) and immunohistochemical (IHC) staining have been commonly used, in combination with thin serial sectioning of frozen and paraffin-embedded specimens, for the detection of micrometastatic disease in the SLN/LN.^(17–19) The application of IHC has markedly improved the sensitivity of micrometastatic disease detection in the SLN/LN beyond the capability of routine H&E staining alone.^(17–19) The antibodies against tumor markers of interest must be highly specific and sensitive for detection of tumor cells, and virtually non-reactive to the adjacent non-tumor cells in the SLN/LN. The most commonly used IHC target for epithelial carcinomas are the cytokeratins (CK), which are ubiquitously expressed as intermediate filaments in normal eukaryotic epithelial cells.^(18–20) However, the risk of false positive results with the use of individual anti-CK antibodies and antibody cocktails has been described.⁽²¹⁾

In comparison, the use of IHC to detect micrometastatic deposits of melanoma has been less problematic due to the high specificity of antibodies to HMB-45 and S-100 proteins.⁽²²⁾ Because these antibodies also have their limitations, new antibodies such as melanoma antigens recognized by T-cells (MART-1) and microphthalmia-associated transcription factor (MITF) are being investigated.⁽²³⁾ IHC staining for detection of occult metastatic tumor cells in LN has been the gold standard.

¹To whom correspondence should be addressed. E-mail: htakeuch@sc.itc.keio.ac.jp

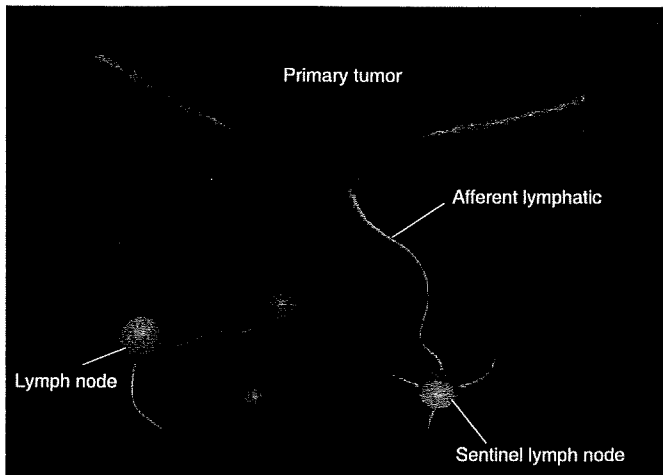


Fig. 1. Primary tumor and sentinel lymph node (SLN). The SLN is defined as one or more lymph nodes that first receive lymphatic drainage from the site of the primary tumor. For intraoperative lymphatic mapping and sentinel lymphadenectomy, blue dye and/or radioisotope-labeled colloid are injected intradermally (or submucosally) around the primary tumor site before surgery. Subsequently, the tracers pass through the afferent lymphatics, and blue-stained or radioactive nodes are regarded as the SLN.

More recently, molecular techniques have provided new approaches and demonstrated undetected metastatic tumor cells.⁽²⁴⁾

To date, SLN have been thought to be a preferential site of initial micrometastasis of solid tumors. In contrast, recent clinical and preclinical studies regard SLN as the first lymphoid organ to respond to tumor antigenic stimulation. However, immunologic roles of SLN in the development of tumor metastasis have not been elucidated yet. Tumor-induced immune modulation of SLN may facilitate LN metastasis by inhibiting immune cell activities. This review also focuses on the immunoresponse in the SLN against tumor metastasis.

Molecular Diagnosis for Micrometastasis of SLN

The molecular detection of tumor cells using RNA or DNA markers with various polymerase chain reaction (PCR) techniques has evolved exponentially in the last decade. The primary approach of molecular detection of tumor cells has been focused on the mRNA of tumor markers using reverse transcription (RT)-PCR assay. Detection of metastatic tumor cells has been clearly demonstrated in LN, organs, and body fluids. Using RT-PCR, it is now possible to reliably detect 1–10 tumor cells within a background of 10^6 – 10^7 normal cells.⁽²⁰⁾ The high sensitivity of the RT-PCR assay, compared with H&E and IHC, allows the detection of the occult tumor cells among the lymphoid cells in SLN/LN. However, molecular-based techniques require the stringent optimization of sample processing, reagents, molecular targets, RT and PCR reactions, and PCR cDNA product detection assays. Meticulous attention to techniques must be adhered to, throughout all stages of the assay, in order to ensure accurate results. One of the keys to the most efficient RT-PCR assay is the quality of the detection marker. Finding a good marker is of the utmost importance in molecular detection.

Quantitative RT-PCR assay is now being used more extensively to not only identify the presence of target mRNA but also to quantify the number of mRNA copies from tumor-associated genes. Quantitative RT-PCR analysis permits the rapid molecular analysis of multiple mRNA targets expressed in tumor cells, and these results can then be correlated to clinical outcomes in order to study the relationship between gene expression levels and

outcome.⁽²⁵⁾ Real-time PCR assay, which enables rapid analysis, is currently being attempted for intraoperative molecular diagnosis. LN along the recurrent laryngeal nerves obtained from patients with esophageal cancer were assessed prospectively using intraoperative histopathologic examination and real-time RT-PCR assay using multiple markers (carcinoembryonic antigen [CEA], squamous cell carcinoma [SCC] antigen, and MAGE-A3).⁽²⁶⁾ The whole procedure takes only 2.5 h from the time of tissue sampling to completion of the real-time RT-PCR assay. Genetic diagnosis by intraoperative real-time PCR assay can predict cervical LN metastasis and may be used to indicate subsequent cervical lymphadenectomy. Further improvements of the assay may allow the PCR-based intraoperative diagnosis to be applicable to other cancer surgeries. Taniyama *et al.* reported that the newly developed one-step nucleic acid amplification (OSNA) assay may allow rapid assessment for intraoperative diagnosis of LN metastasis.⁽²⁷⁾ At the present time, however, the techniques still need further validation.

The current definition of SLN/LN micrometastasis is a deposit of tumor cells measuring ≤ 2 mm. However, this definition has become somewhat arbitrary due to the high degree of sensitivity of IHC and RT-PCR. With the advent of increasingly more sensitive detection assays for occult metastasis, the actual definition of micrometastasis may need to be reconsidered. It has been demonstrated that the metastatic potential of individual tumor cells varies and that not all embolic tumor cells are capable of progressing to functional metastatic tumors.⁽²⁸⁾ There is also evidence to suggest that the number of tumor cells in the LN/SLN, as well as the location of nodal micrometastasis (i.e. single or a few occult tumor cells *vs* clumps of cells, and cells located within the subcapsular sinus *vs* the nodal parenchyma), may be pathologically relevant factors.^(23,29) Historically, the clinicopathological relevance of micrometastatic SLN/LN disease has been unclear and controversial. There is, however, growing evidence that LN/SLN micrometastasis may indeed mean a worse prognosis in many solid cancers, including breast, melanoma, colorectal, esophageal, gastric, lung, head and neck, gynecologic, and urologic cancers.

Breast cancer. A number of mRNA targets have been studied in breast cancer, including CEA, mammaglobin 1 and 2, MAGE-A, MUC-1, C-MET, $\beta 1 \rightarrow 4$ -N-acetylgalactosaminyltransferase ($\beta 1 \rightarrow 4$ -GalNAc-T), β -hCG, prostate specific antigen (PSA), c-myc, prolactin inducible protein (PIP), and various CK family markers.^(30–37) However, the specificity of several of these markers for breast cancer, including CEA, MUC-1, and CK-19 appears to be poor, because they sometimes show positive results for RT-PCR performed on LN and blood in healthy volunteers without breast cancer.^(38–40) MAGE-A3 may be a promising breast cancer molecular marker, although as it appears to be expressed by approximately 50% of breast cancers, but is not expressed in normal mammary epithelium, or in the LN or blood of healthy volunteer donors.⁽³¹⁾

Although not as extensive as the studies that were performed on melanoma, there is compelling evidence to suggest a clinically relevant impact of SLN/LN micrometastasis detected using molecular assays in breast cancer (Table 1). Bostick *et al.* reported significant correlation between the presence of positive RT-PCR markers $\beta 1 \rightarrow 4$ -GalNAc-T, C-MET, and P97) in the SLN and primary tumor estrogen receptor status and Bloom–Richardson histopathological grade, both of which are known prognostic factors.⁽³⁰⁾

Wascher *et al.* assessed MAGE-A3 mRNA as a molecular marker for the detection of occult tumor cells in the SLN of breast cancer patients.⁽⁴¹⁾ Serial frozen sections of SLN ($n = 121$) obtained from 77 American Joint Committee on Cancer (AJCC) stage I–IIIA breast cancer patients were assessed using RT-PCR and Southern blot analysis. Forty-one of 77 (53%) patients were positive for MAGE-A3. Interestingly, MAGE-A3 mRNA

Table 1. Representative SLN/LN RT-PCR studies for breast cancer

Author	No. of patients	Lymph node	RT-PCR marker(s)	H&E/IHC positive (%)	RT-PCR positive (%)	Clinical correlation of micrometastasis detected using RT-PCR
Lockett (1998) ⁽³⁷⁾	35	RLN	CK-19, c-myc, PIP	0	40	Primary tumor size, decreased 5-year survival
Bostick (1998) ⁽³⁰⁾	41	SLN	β1→4-GalNAc-T, C-MET, p97	30 [†]	95 [†]	Estrogen receptor status, histopathological grade
Masuda (2001) ⁽³²⁾	129	RLN	CEA	0	31	Decreased 10-year survival
Wascher (2001) ⁽⁴¹⁾	77	SLN	MAGE-A3	45	53	Infiltrating lobular carcinoma
Manzotti (2001) ⁽³³⁾	123	SLN	Maspin, CK-19, CEA, MUC-1, mammaglobin	33	53 [†]	Progesterone receptor status, peritumoral vascular invasion
Sakaguchi (2003) ⁽³⁴⁾	108	SLN	CK-19, epithelial glycoprotein 2	26	30	No correlation with disease-free survival
Ouellette (2004) ⁽³⁵⁾	42	SLN	Mammaglobin B1, mammaglobin B2	40	52	ND
Gillanders (2004) ⁽⁴²⁾	489	RLN	CEA, mammaglobin, mammaglobin B, PIP, CK-19, MUC-1, PDEF	30	49	Histologic grade, St. Gallen risk category
Nissan (2006) ⁽³⁶⁾	28	SLN	CK-19, NY-BR-1, mammaglobin B	27 [†]	50 [†]	ND

[†]Percentage of total number of SLN found to be positive. β1→4-GalNAc-T, β1→4-N-acetylgalactosaminyltransferase; CEA, carcinoembryonic antigen; CK-19, cytokeratin-19; H&E, hematoxylin and eosin; IHC, immunohistochemistry; LN, lymph node; ND, not determined; PDEF, prostate-derived Ets transcription factor; PIP, prolactin inducible protein; RLN, regional lymph node; RT-PCR, reverse transcription-polymerase chain reaction; SLN, sentinel lymph node.

expression in the SLN occurred more frequently with infiltrating lobular carcinoma than with infiltrating ductal carcinoma.

Others have studied non-SLN axillary LN in breast cancer patients and have reported similar findings. Lockett *et al.* assessed 61 consecutive breast cancer patients with H&E/IHC and a multiple marker RT-PCR assay (CK-19, c-myc, and PIP).⁽³⁷⁾ A total of 15 of 37 (40%) patients with H&E/IHC-negative LN were positive by RT-PCR. An increasing number of positive RT-PCR markers significantly correlated with both increased primary tumor size and decreased predicted 5-year survival.

Masuda *et al.* evaluated 149 breast cancer patients with negative LN using both H&E and IHC evaluation.⁽³²⁾ RT-PCR was performed using CEA as a marker, and 40 of 129 (31%) patients were found to have RT-PCR positive LN. Patients with RT-PCR negative LN had a 10-year disease-free survival rate of 88% versus 66% for RT-PCR positive patients ($P = 0.0008$) and an overall 10-year survival rate of 94% versus 68%, respectively ($P = 0.0024$). On multivariate analysis, patients with RT-PCR-positive LN micrometastasis were found to have a hazard ratio of 3.99 for relapse and 4.29 for death due to cancer. In view of the definition of the SLN, these compelling findings in the study of axillary LN would be expected to be highly applicable with regard to the molecular status of the SLN as well.

In 2004, Gillanders *et al.* reported on the clinical relevance of molecular detection of micrometastasis in axillary LN in the results of a prospective multi-institutional cohort study for 489 patients with breast cancer.⁽⁴²⁾ Seven markers were used for real-time RT-PCR assay: CEA, mammaglobin, mammaglobin B, PIP, CK-19, muc1, and prostate-derived Ets transcription factor (PDEF). Patients who were histopathologically negative but PCR positive were significantly associated with traditional indicators of prognosis, including histologic grade and St Gallen risk category. They concluded that molecular markers could serve as valid surrogates for the detection of occult micrometastasis in axillary LN.

In general, the prognosis for breast cancer patients with early intervention is relatively more favorable than for other carcinomas. Therefore the prognostic significance of molecular detection of micrometastasis in SLN for breast cancer patients remains unclear. One major problem in evaluating the prognostic value of micrometastasis detection in SLN is that patients who had undergone sentinel lymphadenectomy are often treated with postoperative adjuvant therapy. At least 8 years are required

for the follow up of a large number of patients to evaluate a significant number of events. Detection of occult tumor cells in the SLN has not shown clinical significance for patients with breast cancer to date.

Melanoma. The molecular detection of melanoma, using RT-PCR, is facilitated by the expression of melanogenesis-specific genes by melanoma tumors cells, including tyrosinase, MART-1, gp-100/pmel-17, MITF, and tyrosinase-related proteins 1 and 2 (TRP-1, TRP-2).⁽⁴³⁻⁵¹⁾ The expression of various mRNA transcripts of the human melanoma-associated antigen (MAGE-A) family have also been demonstrated in a variety of tumors, including melanoma and cancers of the breast and gastrointestinal tract.^(31,46)

Several studies have reported the use of RT-PCR to detect micrometastatic melanoma in the SLN, and have shown that RT-PCR can significantly upstage patients with SLN that are negative by H&E and IHC (Table 2). In addition to the accurate detection of micrometastatic melanoma cells in the SLN using molecular assays, there is persuasive evidence that the detection of such micrometastases has prognostic significance. Regarding the SLN in particular, Shivers *et al.* followed 114 patients with melanoma for a mean duration of 28 months.⁽⁴⁴⁾ Patients with SLN that were histopathologically and RT-PCR negative had a recurrence rate of 2%, while patients with histopathologically negative but RT-PCR positive SLN had a 13% recurrence rate ($P = 0.02$).

Bostick *et al.* reported on their study of the SLN of 72 patients with early stage melanoma, using a multiple marker RT-PCR assay (tyrosinase, MART-1, and MAGE-3).⁽⁴⁶⁾ Bisection and serial sectioning of SLN, prior to H&E/IHC and molecular analysis, was performed to reduce the false negative rate associated with random or limited sampling of the SLN. Twenty of 55 patients (36%) with SLN negative by H&E and IHC stains were positive for at least two of the three markers in the panel (44% of these 55 patients expressed MAGE-3, 36% expressed MART-1, and 29% expressed tyrosinase). By multivariate analysis, the presence of two or more RT-PCR markers in the SLN correlated with a significantly increased risk of recurrence.

Blaheta *et al.* evaluated 214 SLN from 116 patients with melanoma using IHC and single marker (tyrosinase) RT-PCR.⁽⁴⁷⁾ Using H&E and IHC alone, 15 of 116 (13%) patients were confirmed to have SLN micrometastasis. Of the remaining 101 patients with histopathologically negative SLN, 36 (36%) SLN were positive by RT-PCR for tyrosinase. Of the 15 patients with histopathologically detected SLN micrometastases, 10 (67%)

Table 2. Representative SLN/LN RT-PCR studies for melanoma

Author	No. of patients	Lymph node	RT-PCR marker(s)	H&E/IHC positive (%)	RT-PCR positive (%)	Clinical correlation of micrometastasis detected by RT-PCR
Goydos (1998) ⁽⁴³⁾	45	SLN	Tyrosinase, MART-1	22	29	ND
Shivers (1998) ⁽⁴⁴⁾	114	SLN	Tyrosinase	20	61	Decreased disease-free and overall survival
Blaheta (1999) ⁽⁴⁵⁾	73	SLN	Tyrosinase	18	49	Primary tumor thickness
Bostick (1999) ⁽⁴⁶⁾	72	SLN	Tyrosinase, MART-1, MAGE-A3	24	50 [†]	Increased risk of recurrence
Blaheta (2000) ⁽⁴⁷⁾	101	SLN	Tyrosinase	0	36	Increased risk of recurrence
Ribuffo (2003) ⁽⁴⁸⁾	134	SLN	Tyrosinase, MART-1	11	63	Decreased disease-free survival
Goydos (2003) ⁽⁴⁹⁾	175	SLN	Tyrosinase	19	58	Increased risk of recurrence
Kuo (2003) ⁽⁵⁰⁾	77	SLN	Tyrosinase, MART-1, TRP-1, TRP-2	48	55 [†]	Decreased disease-free and overall survival
Morton (2003) ⁽⁵¹⁾	215	SLN	Tyrosinase, MART-1, TRP-2, MITF	25	47	Decreased disease-free and overall survival

[†]Percentage of two or more markers positive. H&E, hematoxylin and eosin; IHC, immunohistochemistry; LN, lymph node; MART, melanoma antigens recognized by T-cells; MITF, microphthalmia-associated transcription factor; ND, not determined; RT-PCR, reverse transcription-polymerase chain reaction; SLN, sentinel lymph nodes; TRP, tyrosinase-related proteins.

Table 3. Representative SLN/LN RT-PCR studies for gastrointestinal cancers

Author	Tumor	No. of patients	Lymph node	RT-PCR marker(s)	H&E/IHC positive (%)	RT-PCR positive (%)	Clinical correlation of micrometastasis detected by RT-PCR
Noguchi (1996) ⁽⁶³⁾	Gastric	12	RLN	CK-19	7	21	ND
Ichikawa (1998) ⁽⁶⁵⁾	Colon	15	RLN	MMP-7	19	26	ND
Kijima (2000) ⁽⁶⁴⁾	Esophagus	21	RLN	CEA	52	86	ND
Bernini (2000) ⁽⁶⁷⁾	Colorectal	43	RLN	MUC-2	0	28	Advanced T-factor
Bilchik (2001) ⁽¹¹⁾	Colorectal	40	SLN	β-hCG, C-MET, MAGE-A	35	60	Advanced T-factor
Yoshioka (2002) ⁽²⁶⁾	Esophagus	50	RLN	CEA, SCC, MAGE-A3	20 (intraoperative diagnosis)	48 (intraoperative diagnosis)	Predict cervical LN metastasis
Noura (2002) ⁽⁵⁸⁾	Colorectal	64	RLN	CEA	55	30	Decreased disease-free and overall survival
Matsuda (2004) ⁽⁶⁶⁾	GI cancers	51	SLN	CK-19	25	45	ND
Arigami (2006) ⁽⁶⁵⁾	Gastric	53	SLN	CEA	0	25	ND

CEA, carcinoembryonic antigen; CK-19, cytokeratin-19; H&E, hematoxylin and eosin; IHC, immunohistochemistry; LN, lymph node; MMP, matrix metalloproteinase; ND, not determined; RLN, regional lymph node; RT-PCR, reverse transcription-polymerase chain reaction; SCC, squamous cell carcinoma antigen; SLN, sentinel lymph node.

had recurrence, compared with an overall recurrence rate of 20% among all 116 patients. During a 19-month median follow-up period, the recurrence rate for patients with RT-PCR-positive SLN was 25%, and the recurrence rate in patients with negative SLN using H&E, IHC and RT-PCR was only 6% ($P = 0.01$). By multivariate analysis, histopathological and RT-PCR SLN tumor status were the only significant predictors of disease-free survival.

Goydos *et al.* studied 175 patients with stage I or II melanoma using single marker (tyrosinase) RT-PCR.⁽⁴⁹⁾ At a median follow up of 34 months, 17 of 34 (50%) patients with histologically positive SLN had a recurrence. Of the 141 patients with histologically negative SLN, 73 patients were negative for tyrosinase using RT-PCR, and none of these patients had a recurrence. Of the 68 patients with histologically negative but RT-PCR-positive SLN, 14 patients (21%) had a recurrence.

Morton *et al.* assessed the paraffin-embedded SLN of 215 patients with AJCC stage I/II melanoma using a multiple marker quantitative real-time PCR assay.⁽⁵¹⁾ Tyrosinase, MART-1, TRP-2 and MITF were used as specific mRNA markers. Among 162 patients with histopathologically negative SLN, 49 (30%) patients showed PCR-positive and were upstaged. These patients had a significantly increased risk of disease recurrence and death compared with both histopathology and PCR-marker-negative patients using multivariate analysis. These studies demonstrated the clinicopathological utility of detecting micrometastatic melanoma in SLN.

The 5-year survival rate approaches 90% for patients with AJCC stage I malignant melanoma, and 70% for stage II melanoma, but decreases significantly to 25–50% for stage III melanoma. Therefore, accurate staging is highly important for optimal management of early stage disease. The clinicopathological relevance of micrometastatic melanoma in SLN detected using RT-PCR assay is still controversial, because melanoma mRNA markers for RT-PCR assay are often expressed in melanocytes or nevus cells. A recently reported large-scale multicenter study failed to prove the clinical relevance of molecular upstaging using RT-PCR in patients with melanoma.⁽⁵²⁾ A series of previous studies that reported prognostic significance of micrometastatic melanoma in SLN detected using RT-PCR, however, may show the clinical significance of molecular detection of micrometastasis in SLN.⁽⁵³⁾ Future investigations will validate the clinicopathological importance of micrometastatic melanoma in SLN.

Colorectal cancer. The application of molecular analysis to the SLN in colorectal cancer (CRC) is currently at an early stage (Table 3). However, with the recent and successful application of the SLN concept to this disease, preliminary data from molecular-based assays is now being generated. Molecular markers for SLN/LN analysis in CRC studied so far include CK, CEA, MAGE-A, C-MET, β-hCG, MUC-2, and matrix metalloproteinases.^(11,31,54–58)

CRC is being studied to evaluate the prognostic impact of micrometastatic SLN/LN disease. Liefers *et al.* evaluated 192

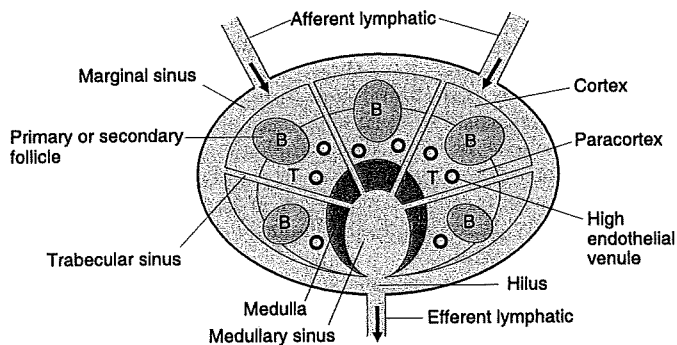


Fig. 2. Schema of lymph node. B, B-cell area; T, T-cell area.

LN from 26 stage II CRC patients using nested RT-PCR and CEA as a molecular marker.⁽⁵⁶⁾ In this study, 14 of 26 (54%) patients had LN that were RT-PCR positive. The 5-year survival rate for these 14 patients was 50%, while the survival rate among the remaining 12 patients was 91% ($P = 0.03$).

Bernini *et al.* recently studied the LN of 43 CRC patients, using MUC-2 as a molecular target for RT-PCR.⁽⁵⁷⁾ They found a correlation between RT-PCR LN positivity and the size of the primary tumor. None of the 10 Tis/T1 tumors and one of six (17%) T2 tumors were shown to be LN positive using RT-PCR, while 10 of 25 (40%) T3 tumors and one of two (50%) T4 tumors were positive using RT-PCR. These results are of clinical significance, because primary tumor T-stage is a known prognostic factor for CRC.

Interim results from the first multicenter phase II trial evaluating the molecular staging of the SLN in early colon cancer (clinical stage I/II) were recently reported by Bilchik *et al.*⁽¹¹⁾ Forty patients with histopathologically negative (by H&E) SLN were assessed using IHC for CK, and using a multiple-marker RT-PCR panel (β -hCG, C-MET, and MAGE-A3). In 10 (25%) cases, the SLN was positive by H&E. In four (10%) cases, the SLN were positive by IHC and negative by H&E. Of the remaining 26 patients with negative SLN by H&E and IHC, 12 (46%) were positive for at least two RT-PCR markers. This study also demonstrated a correlation between the number of markers detected and the tumor T-stage, which is, by itself, a significant prognostic factor for colon cancer. These results suggest that molecular staging can be successfully and meaningfully applied to the SLN in CRC, in addition to melanoma and breast cancer.

Noura *et al.* recently reported a comparative study of detection of micrometastasis using IHC and RT-PCR assay in H&E-negative LN of 64 AJCC stage II CRC patients.⁽⁵⁸⁾ CEA was used for RT-PCR assay and compared to an IHC study with anti-CK antibody. Micrometastases were detected in 19 of 64 (30%) patients using RT-PCR and in 35 of 64 (55%) patients using IHC. Patients who were PCR-positive in LN showed significantly worse disease-free and overall survival than PCR-negative patients. However, micrometastasis in LN using IHC did not correlate with prognosis. Although a larger prospective study may be required for the validation of the assay, the results suggested the prognostic utility of molecular detection of micrometastasis in LN/SLN of CRC patients.

Other carcinomas. Gastric, esophageal, prostate, biliary, head and neck, lung and gynecologic cancers have also been upstaged following RT-PCR analysis of LN/SLN and, in many cases, these results have correlated with known prognostic factors (Table 3).^(14,59-66) Arigami *et al.* reported that 13 of 53 (25%) gastric cancer patients with histopathology-negative SLN were upstaged using RT-PCR assay.⁽⁶⁵⁾ They concluded that the SLN concept is applicable to patients with cT1 and cN0 gastric cancer,

even when including the molecular diagnosis of micrometastasis. Other groups also suggested that nodal micrometastasis detected using RT-PCR assay has some clinical significance in gastrointestinal cancers.⁽⁶⁶⁾ Molecular assessment of the SLN may be a variable tool to complement histological examination for gastrointestinal cancers.

Immunoresponses in the SLN against Tumor Metastasis

The SLN are also known to be the first lymphoid organ to respond to tumor antigenic stimulation. The SLN is the site where immunoreactive lymphocytes initially encounter tumor-specific antigens and develop antitumor immunity. The SLN may have critical roles in the development of local immunity that could reject and eradicate metastatic cancer cells. Immune dysfunction in the SLN does not directly reflect generalized immune suppression against cancer. However, there are many possible mechanisms that may explain the reasons why the SLN has limited capability to prevent cancer metastasis.

Nagata *et al.* have made a metastasis model in the rat mesenteric LN, and visualized the migration of cancer cells *in vivo*.⁽⁶⁷⁾ Migrant cancer cells were initially arrested in the marginal sinus in the tumor-draining LN; therefore the marginal sinus was supposed to constitute a mechanical barrier against cancer cell passage (Fig. 2). The cancer cells filled the marginal sinus, and no cancer nests were found in the cortex, paracortex, or medulla before the marginal sinus was filled. Cancer cells subsequently invaded to the cortex and paracortex over the inner linings of the marginal sinus. Cytokines such as tumor necrosis factor- α , interleukin (IL)-1 β and IL-2 secreted by macrophages markedly increased at the early stages of metastasis, but gradually decreased according to the tumor proliferation in the LN. They suggested that parasinus macrophages may play a crucial role in the transient antimetastatic capability of the nodes, and deterioration of cytokine induction may be responsible for subsequent cancer proliferation.

Individual LN show the heterogeneous reactivity, frequency, and density of T-cells, dendritic cells (DC), and other lymphocytes in the paracortical area. Cytokine generation and cytotoxicity against tumor cells might vary among individual nodes. Cochran *et al.* have extended a series of studies to compare the cellular phenotype and physiology of metastasis-susceptible SLN with non-SLN from the same patient in melanoma and breast cancer.⁽⁶⁸⁾ They demonstrated that the immunoreactivity of SLN is entirely or segmentally down-regulated compared with non-SLN, that is to say that SLN are likely to be immunomodulated by tumor cells. Tumor-induced down-regulation of SLN immunity is certainly related to the survival of tumor cells and the development of clinically significant metastasis in SLN.

The cancer cells in the primary site produce immunomodulators that can lead to immunosuppression of the SLN affected via the direct lymphatic drainage pathway from the primary tumor (Table 4). In contrast, non-SLN in the regional basin are regarded to be less affected by the immunomodulators from the primary tumor site. The down-regulation of immunoreactivity in SLN is particularly obvious in the density and maturity of paracortical DC (PDC) and T-cells.⁽⁵¹⁾ Huang *et al.* reported a significant reduction in the aggregate area of the paracortex occupied by PDC, and less frequency, density and maturity of PDC in the SLN compared with non-SLN in studies of various solid tumors, in particular breast cancer and melanoma.⁽⁶⁹⁾ DC with long dendrites are considered to be more effective at antigen presentation; however, SLN show dendritic cells with short or no dendrites that are likely to reflect the down-regulation of antigen presentation. Cochran *et al.* also found that the formation of dendritic meshworks that are related to the interaction between mature DC and T-cells was markedly reduced in SLN compared with non-SLN.⁽⁶⁸⁾

Table 4. Representative factors that relate to sentinel lymph node metastasis produced by tumor cells

Factors	Molecules
Cytokines	IL-6, IL-8, IL-10, TGF- α , TGF- β
Growth factors	VEGF-A, VEGF-C, VEGF-D, basic fibroblast growth factor, platelet-derived growth factor, placental growth factor, hepatocyte-growth factor
Chemokine receptors	CCR7, CCR10, CXCR4

IL, interleukin; TGF, transforming growth factor; VEGF, vascular endothelial growth factor.

Huang *et al.* showed that T-cell density and activation markers for T-cells are markedly reduced within the paracortical area in the SLN compared with the non-SLN.⁽⁷⁰⁾ Naïve T-cells, which arrive to the paracortical area through the endothelium of high endothelial venules (HEV), are known to encounter antigen-presenting DC in the paracortex. Recent studies have demonstrated that HEV in SLN are fewer than in non-SLN, and also transendothelial migration of naïve T-cells is markedly reduced in SLN.⁽⁷¹⁾

Other studies also supported the concept that primary tumors enable suppression of the immune functions in the SLN and facilitate the development of LN metastasis. In SLN an increased level of IL-10, which is secreted from the primary tumor, markedly inhibits DC maturation, migration and translocation of major histocompatibility complex (MHC)-class II peptide complex into the plasma membrane of DC.⁽⁷²⁾ This result is consistent with other reports that IL-10 concentrations in SLN are significantly higher than those in non-SLN.⁽⁷³⁻⁷⁶⁾

Torisu-Itakura *et al.* investigated the nodal profile of immunoregulatory cytokines using cDNA microarray to confirm the identity of the SLN and non-SLN.⁽⁷⁶⁾ As a result, 57 genes were expressed at significantly different levels in SLN and non-SLN. The expression levels of IL-13, leptin, lymphotoxin β receptor, and macrophage inflammatory protein 1b were significantly higher for tumor-positive SLN and compared with tumor-negative SLN, and the expression of IL-11Ra was significantly lower for tumor-positive SLN. They concluded that SLN show a different immunoregulatory cytokine profile from non-SLN. Further investigations will be needed to clarify immunomodulation by the tumor cells for the development of nodal metastasis.

New Insights into the Mechanism of SLN Metastasis

Recent advances in molecular oncology have shown that various factors such as oncogenes, tumor suppressor genes, growth factors, apoptotic factors, adhesion molecules, angiogenic factors, and cytokines are related to the development of tumor metastasis. The SLN is directly situated in the lymphatic drainage pathway from the primary tumor site. Therefore the establishment of metastasis to SLN may be simply reflected by the flow dynamics of lymphatic fluid that drains from the primary site to the SLN, and the transportation of viable cancer cells.

However, recent studies have demonstrated that primary tumors can actively induce the formation of lymphatic vessels from host vessels, and that lymphangiogenesis is correlated with enhanced (sentinel) LN metastasis in various human carcinomas and some experimental models.⁽⁷⁷⁻⁸¹⁾ Moreover, tumor cells can induce peritumoral lymphangiogenesis and lymphatic vessel growth within SLN before and after they metastasize to the SLN, likely promoting further development of cancer metastasis.^(82,83)

The functionality of intratumoral and peritumoral lymphatic vessels for cancer metastasis has been discussed in recent years.

Intratumoral lymphatic vessels might not be functional with regard to lymphatic fluid transport and cancer metastasis.^(81,84,85) However, several studies have shown that peritumoral lymphatic vessels are more functional and important for promoting lymphatic metastasis.^(83,84,86) LYVE-1, podoplanin, and PROX-1 are useful markers for identifying lymphatic epithelial cells.⁽⁸⁷⁻⁸⁹⁾ The expression of these specific lymphatic markers in intratumoral and peritumoral lymphatic vessels has been known to vary heterogeneously, according to the maturity of lymphatic vessels and tumor progression.

Vascular endothelial growth factor (VEGF)-C and VEGF-D are, among the VEGF family, known as the first specific lymphangiogenic factors.^(90,91) Many studies have shown that VEGF-C or VEGF-D produced by tumor cells enable not only to induce lymphangiogenesis but also to enhance lymphatic metastasis to SLN.^(77,78,84,92,93) VEGF receptor (VEGFR)-3 is a lymphatic growth factor receptor of four VEGF receptors, and specifically binds to VEGF-C and VEGF-D, but not to VEGF-A.⁽⁹⁴⁾ VEGFR-3 expression is restricted to the lymphatic epithelium in normal tissues; however, some tumor blood vessels also express VEGFR-3.^(89,95) Activation of VEGFR-3 is known to promote lymphatic endothelial cell proliferation, migration, and cell survival through several signal pathways such as the phosphatidylinositol 3-kinase/AKT.⁽⁹⁶⁾ Recent studies have reported that VEGFR-3 is expressed in some types of cancer cells, and that generation of a paracrine loop involving VEGF-C and VEGFR-3 may promote cancer cell survival, lymphangiogenesis and LN metastasis.⁽⁹⁷⁾

Several studies have revealed that lymphangiogenesis and lymphatic metastasis promoted by VEGF-C or VEGF-D are significantly suppressed by blocking the VEGF-R3 signaling pathway.^(78,79,98) Skobe *et al.* reported that the human breast carcinoma cell line transfected with VEGF-C significantly promoted peritumoral and intratumoral lymphangiogenesis (but had no effect on angiogenesis) and lymphatic metastasis.⁽⁷⁸⁾ Other groups have also showed that another human breast carcinoma cell line, MCF-7 transfected with VEGF-C cDNA, was significantly correlated with lymphangiogenesis and lymphatic metastasis in SCID mice models.⁽⁹³⁾ Moreover the tumor-associated lymphangiogenesis promoted by VEGF-C significantly inhibited VEGFR-3 fusion protein,⁽⁹²⁾ suggesting that the VEGF-C (or VEGF-D) and VEGFR-3 pathway may be the therapeutic target of inhibiting tumor lymphangiogenesis.

Recent studies also suggest that binding of VEGF-C and VEGF-D to VEGFR-2 may stimulate lymphangiogenesis, and VEGF-A, which binds to VEGFR-2, markedly promotes tumor lymphangiogenesis.^(83,98) These results suggest that VEGF-A and/or VEGFR-2 may be another therapeutic target of inhibiting tumor lymphangiogenesis. Other molecular markers including hepatocyte growth factor, fibroblast growth factor-2, platelet-derived growth factor (PDGF), angiopoietin-1, and insulin-like growth factors 1/2, were recently identified as potent lymphangiogenic factors.⁽⁹⁴⁾ However, it is still unknown whether these newly identified lymphangiogenic factors markedly induce cancer metastasis to the SLN.

There is significant evidence that tumors of specific histology preferentially metastasize to LN.^(99,100) This preferential metastasis cannot be explained simply by the lymphatic drainage pattern from the tumor. The observation of an orderly, systematic targeting of organs by metastatic breast cancer led Paget to hypothesize the 'seed and soil' theory of cancer metastasis.⁽¹⁰¹⁾ In this model, organs that provide suitable environmental conditions for cancer growth are the preferential sites of cancer metastasis. Since Paget's original report more than one century ago, others have attempted to test, challenge, or supplement this theory. Recently, a novel mechanism for cancer metastasis has emerged that highlights the role of chemokines. There is evidence that antigen-presenting cells such as DC, T-cells, Langerhans cells, and

natural killer (NK) cells bearing chemokine receptors migrate from skin to the draining LN in response to specific chemotactic factors referred to as chemokines.⁽¹⁰²⁻¹⁰⁷⁾ In this signaling 'homing' mechanism, SLN produce and release specific chemokines that attract cancer cells bearing specific corresponding receptors in primary sites. The recent demonstration of specific chemokine receptors on tumor cells and respective chemokines has provided some insight into how tumor cells may home to SLN. Chemokine receptors have been suggested to play a pivotal role in regulating the recruitment of solid tumor cells to SLN.⁽¹⁰⁸⁾

Chemokines, grouped into CXC and CC subfamilies based on the arrangement of the two NH₂-terminal cysteine residues, are small secreted proteins that regulate the chemotactic response for a variety of cells.⁽¹⁰⁶⁾ These ligands and receptors have been predominantly investigated on lymphoid cells. Of particular interest is CCL21/SLC, also referred to as 6CKine or exodus, which is involved in recruiting CCR7(+) naïve T-cells, NK, memory T-cells, and DC.⁽¹⁰²⁻¹⁰⁷⁾ CCL21/SLC is constitutively expressed in the HEV of LN and lymphatic endothelial cells, Peyer's patches, thymus, spleen and mucosal tissue.^(105,109) It has a high affinity for CCR7, a member of the seven transmembrane-spanning G protein coupled receptor family.⁽¹¹⁰⁻¹¹²⁾ CCR7 is prevalent in various subsets of T-cells and DC.^(103,110-112) The release of CCL21/SLC by HEV cells recruits CCR7(+) cells to draining LN.^(103,107,109)

The concept that chemokine receptors promote organ-specific tumor metastasis was first experimentally addressed by Muller *et al.*⁽¹¹³⁾ They demonstrated that the chemokine receptor CXCR4 was highly expressed in human breast cancer, and its specific ligand CXCL12/SDF-1 was expressed in a variety of tissues such as bone marrow, lung, and LN where breast cancer cells preferentially metastasize. Moreover, breast cancer cell lines enabled to show chemotactic migration to CXCL12 *in vitro*, and a SCID mouse model showed that experimental metastasis of a breast cancer cell line to LN is significantly inhibited by neutralizing antibodies against CXCR4.

Human melanoma cells have been shown to express the chemokine receptors CCR7 and CXCR4.^(114,115) The expression of these receptors is variable among melanomas, as shown by molecular analysis, both in cell lines and in microdissected tumor tissues.^(114,115) Both chemokine receptors were shown to be functional to their specific ligands, CCL21 and CXCL12/SDF-1, respectively. To further examine the role of these chemokine receptor-ligands in metastasis, SLN were assessed because metastasis often occurs initially at these proximal tumor-draining LN.⁽¹¹⁴⁾ LN are known to produce the chemokines CXCL12 and CCL21. Activation of these chemokines attracts antigen-presenting cells, such as DC and T-cells, to help orchestrate an immune response in the nodes.^(115,116) We hypothesized that metastatic tumor cells may take advantage of chemokines activated in LN. To determine this, we examined SLN in melanoma patients with micrometastasis and those without it. Our studies demonstrated that CXCL12 and CCL21 production by SLN correlated with metastasis involvement. Interestingly, as the tumor burden increased in the SLN, chemokines were more suppressed.⁽¹¹⁴⁾ The results suggested that metastatic tumor cells or factors may suppress chemokine production through direct or indirect mechanisms. These mechanisms may be similar to inflammatory responses in LN in that, after initial activation, the nodes do not continually expand by recruiting immune cells. There appears to be a physiological mechanism of cells populating LN that regulate chemokine production.

Wiley *et al.* showed that the functional expression of CCR7 enhances the metastasis of B16 murine melanoma to SLN compared with control, and that the metastasis is inhibited by neutralizing antibodies against CCL21.⁽¹¹⁷⁾ Other groups have demonstrated that CCR7-positive cancer cells significantly

correlated with a high incidence of LN metastasis in gastric⁽¹¹⁸⁾ and esophageal carcinomas.⁽¹¹⁹⁾

Therapeutic Implications for SLN Metastasis

Malignant melanoma is one of the candidates for the investigation of immunotherapy because it is clinically resistant to chemotherapy and radiotherapy, and expresses many kinds of immunogenic molecules. To date, *Mycobacterium bovis* Bacillus Calmette-Guérin, IL-2, type II interferon (IFN), and granulocyte-macrophage colony-stimulating factor (GM-CSF) have been reported to have antitumor effects for melanoma after intratumoral injection.⁽¹²⁰⁻¹²³⁾ GM-CSF has been supposed to provide an antitumor effect by acting on DC, T-cells, and macrophages. GM-CSF is known to cause mature DC to migrate to regional LN and increase their resistance to apoptosis,⁽¹²⁴⁾ and also to induce T-cell mediated antitumor immunity by activated DC. Vuylsteke *et al.* reported that preoperative peritumoral injections of GM-CSF resulted in enlargement of DC and T-cell areas in the SLN.⁽¹²⁵⁾ These results suggest that GM-CSF may have the potential to prevent or eradicate tumor metastasis in the SLN. Many other molecules, including IL-13 and IFN- α , have been reported to be candidates for immunomodulation in the SLN.^(126,127) Further studies will prove the clinical significance of these immunomodulators for the treatment of SLN metastasis.

Several studies have shown that the VEGFR-3 and/or VEGFR-2 pathway might be the therapeutic target of inhibiting tumor lymphangiogenesis and cancer metastasis to SLN. To date, several antibodies and molecules including anti-VEGFR-3 antibody, anti-VEGF-C antibody, anti-VEGF-D antibody, soluble VEGFR-3 fusion protein, small interfering RNA to reduce VEGF-C mRNA expression, and a number of small molecule kinase inhibitors of VEGFR-2 have been investigated in animal models.^(79,92,94,98,128) Most of the studies using these antibodies or molecules have demonstrated that specific inhibition of the VEGFR-3 and/or the VEGFR-2 pathway markedly reduces lymphangiogenesis and lymphatic cancer metastasis, and likely also reduces the incidence of distant organ metastasis.

Chemokine receptors will be also as a target of therapeutic intervention using antibodies or small molecule inhibitors. Anti-CXCR4 monoclonal antibody significantly inhibits the metastasis of human breast carcinoma cells to the LN of SCID mice.⁽⁹²⁾ Systemic administration of the CXCR4 antagonist AMD3100, a potent blocker of HIV cell entry, inhibited the growth of intracranial glioblastoma and medulloblastoma xenografts by inducing tumor cell apoptosis.⁽¹²⁹⁾ However, systemic inhibition of CXCL12-CXCR4 signaling may have adverse effects on the hematopoietic stem cells, primitive germ cells and neural precursors.⁽¹³⁰⁾

Conclusion

The development of the SLN concept has radically altered the field of diagnosis and treatment of many solid tumors. As this paradigm shift receives validation from melanoma studies, greater attention on the histopathological microstaging of the SLN formalized the concept of LN/SLN micrometastasis. The use of serial sectioning and IHC analysis, and more recently, the use of RT-PCR, has enabled investigators to further study the potential clinical significance of micrometastatic LN/SLN disease. There is now a growing body of data to support the clinical relevance of LN/SLN micrometastasis in a variety of solid tumors. Increasing the sensitivity of occult tumor cell detection in the SLN, using molecular-based analysis, should enable a more accurate understanding of the clinical significance of various patterns of micrometastatic nodal disease. In the future, molecular staging of SLN should benefit and improve patient management.

Lymphangiogenesis and the 'chemokine-chemokine receptor network' are responsible for promoting lymphatic cancer metastasis. Metastasis to SLN might not be simply reflected only by the flow dynamics of lymphatic fluid that drains from the primary site to the SLN, but also by the diplomatic and active behavior of cancer cells. SLN dramatically show morphological, phenotypical and functional changes that indicate immune suppression by tumor cells. The immune suppression in SLN results in failure of prevention or eradication of tumor metastasis. The mechanism of immunomodulation remains unclear; however, several regulatory molecules produced by tumor cells and

tumor-associated macrophages or lymphocytes are likely to be responsible for inducing immune suppression in the SLN. Further preclinical and clinical studies may achieve the reversal of tumor-induced immune suppression that can prevent or eradicate LN metastasis.

Acknowledgments

The authors are indebted to Professor J. Patrick Barron of the International Medical Communications Center of Tokyo Medical University for his review of this manuscript.

References

- Gervasoni JE Jr, Taneja C, Chung MA, Cady B. Biologic and clinical significance of lymphadenectomy. *Surg Clin North Am* 2000; **80**: 1631-73.
- Fisher B, Redmond C, Fisher ER *et al*. Ten-year results of a randomized trial comparing radical mastectomy and total mastectomy with or without radiation. *N Engl J Med* 1985; **312**: 674-81.
- Veronesi U, Adamus J, Bandiera DC *et al*. Inefficacy of immediate node dissection in stage I melanoma of the limbs. *N Engl J Med* 1977; **297**: 627-30.
- Cascinelli N, Morabito A, Santinami M, MacKie RM, Belli F. Immediate or delayed dissection of regional nodes in patients with melanoma of the trunk: a randomized trial. WHO Melanoma Programme. *Lancet* 1998; **351**: 793-6.
- Morton DL, Wen DR, Wong JH *et al*. Technical details of intraoperative lymphatic mapping for early stage melanoma. *Arch Surg* 1992; **127**: 392-9.
- Eifel P, Axelson JA, Costa J *et al*. National Institutes of Health Consensus Development Conference Statement: adjuvant therapy for breast cancer, November 1-3, 2000. *J Natl Cancer Inst* 2001; **93**: 979-89.
- Yoshihino I, Nakanishi R, Osaki T *et al*. Unfavorable prognosis of patients with stage II non-small cell lung cancer associated with macroscopic nodal metastases. *Chest* 1999; **116**: 144-9.
- Giuliano AE, Kirgan DM, Guenther JM, Morton DL. Lymphatic mapping and sentinel lymphadenectomy for breast cancer. *Ann Surg* 1994; **220**: 391-401.
- Morton DL, Thompson JF, Essner R, Elashoff R, Stern SL, Nieweg OE. Validation of the accuracy of intraoperative lymphatic mapping and sentinel lymphadenectomy for early-stage melanoma: a multicenter trial. Multicenter Selective Lymphadenectomy Trial Group. *Ann Surg* 1999; **230**: 453-63.
- Krag D, Weaver D, Ashikaga T *et al*. The sentinel node in breast cancer - a multicenter validation study. *N Engl J Med* 1998; **339**: 941-6.
- Bilchik AJ, Saha S, Wiese D *et al*. Molecular staging of early colon cancer on the basis of sentinel node analysis: a multicenter phase II trial. *J Clin Oncol* 2001; **19**: 1128-36.
- Pelizzo MR, Boschin IM, Toniato A *et al*. The sentinel node procedure with Patent Blue V dye in the surgical treatment of papillary thyroid carcinoma. *Acta Otolaryngol* 2001; **121**: 421-4.
- Akduman B, Fleschner NE, Ehrlich L, Klotz L. Early experience in intermediate-risk penile cancer with sentinel node identification using the gamma probe. *Urology* 2001; **58**: 65-8.
- Van Trappen PO, Gyselman VG, Lowe DG *et al*. Molecular quantification and mapping of lymph-node micrometastases in cervical cancer. *Lancet* 2001; **357**: 15-20.
- Liptay MJ, Masters GA, Winchester DJ *et al*. Intraoperative radioisotope sentinel lymph node mapping in non-small cell lung cancer. *Ann Thorac Surg* 2000; **70**: 384-9.
- Kitagawa Y, Fujii H, Mukai M *et al*. The role of the sentinel lymph node in gastrointestinal cancer. *Surg Clin North Am* 2000; **80**: 1799-809.
- Cote RJ, Peterson HF, Chaiwun B *et al*. Role of immunohistochemical detection of lymph-node metastases in management of breast cancer. International Breast Cancer Study Group. *Lancet* 1999; **354**: 896-900.
- Czerniecki BJ, Scheff AM, Callans LS *et al*. Immunohistochemistry with pancytokeratins improves the sensitivity of sentinel lymph node biopsy in patients with breast carcinoma. *Cancer* 1999; **85**: 1098-103.
- Turner RR, Ollila DW, Krasne DL, Giuliano AE. Histopathologic validation of the sentinel lymph node hypothesis for breast carcinoma. *Ann Surg* 1997; **226**: 271-6.
- Pantel K, Cote RJ, Fodstad O. Detection and clinical importance of micrometastatic disease. *J Natl Cancer Inst* 1999; **91**: 1113-24.
- Xu X, Roberts SA, Pasha TL, Zhang PJ. Undesirable cytokeratin immunoreactivity of native nonepithelial cells in sentinel lymph nodes from patients with breast carcinoma. *Arch Pathol Laboratory Med* 2000; **124**: 1310-3.
- Cochran AJ, Balda BR, Starz H *et al*. The Augsburg Consensus. Techniques of lymphatic mapping, sentinel lymphadenectomy, and completion lymphadenectomy in cutaneous malignancies. *Cancer* 2000; **89**: 236-41.
- King R, Weibaecher KN, McGill G, Cooley E, Mihm M, Fisher DE. Microphthalmia transcription factor. A sensitive and specific melanocyte marker for Melanoma Diagnosis. *Am J Pathol* 1999; **155**: 731-8.
- Takeuchi H, Wascher RA, Kuo C, Turner RR, Hoon DS. Molecular diagnosis of micrometastasis in the sentinel lymph node. *Cancer Treat Res* 2005; **127**: 221-52.
- Takeuchi H, Kuo C, Morton DL, Wang HJ, Hoon DS. Expression of differentiation melanoma-associated antigen gene is associated with favorable disease outcome in advanced-stage melanomas. *Cancer Res* 2003; **15**: 441-8.
- Yoshioka S, Fujiwara Y, Sugita Y *et al*. Real-time rapid reverse transcriptase-polymerase chain reaction for intraoperative diagnosis of lymph node micrometastasis: clinical application for cervical lymph node dissection in esophageal cancers. *Surgery* 2002; **132**: 34-40.
- Taniyama K, Motoshita J, Sakane J *et al*. Combination analysis of a whole lymph node by one-step nucleic acid amplification and history for intraoperative detection of micrometastasis. *Pathobiology* 2006; **73**: 183-91.
- Nasser IA, Lee AK, Bosari S, Saganich R, Heatley G, Silverman ML. Occult axillary lymph node metastases in 'node-negative' breast carcinoma. *Hum Pathol* 1993; **24**: 950-7.
- Kamath VJ, Giuliano R, Dauway EL *et al*. Characteristics of the sentinel lymph node in breast cancer predict further involvement of higher-echelon nodes in the axilla: a study to evaluate the need for complete axillary lymph node dissection. *Arch Surg* 2001; **136**: 688-92.
- Bostick PJ, Huynh KT, Sarantou T *et al*. Detection of metastases in sentinel lymph nodes of breast cancer patients by multiple-marker RT-PCR. *Int J Cancer* 1998; **79**: 645-51.
- Miyashiro I, Kuo C, Huynh K *et al*. Molecular strategy for detecting metastatic cancers with use of multiple tumor-specific MAGE-A genes. *Clin Chem* 2001; **47**: 505-12.
- Masuda N, Tamaki Y, Sakita I *et al*. Clinical significance of micrometastases in axillary lymph nodes assessed by reverse transcription-polymerase chain reaction in breast cancer patients. *Clin Cancer Res* 2000; **6**: 4176-85.
- Manzotti M, Dell'Orto P, Maisonneuve P, Zurrida S, Mazzarol G, Viale G. Reverse transcription-polymerase chain reaction assay for multiple mRNA markers in the detection of breast cancer metastases in sentinel lymph nodes. *Int J Cancer* 2001; **95**: 307-12.
- Sakaguchi M, Virmani A, Dudak MW *et al*. Clinical relevance of reverse transcriptase-polymerase chain reaction for the detection of axillary lymph node metastases in breast cancer. *Ann Surg Oncol* 2003; **10**: 117-25.
- Ouellette RJ, Richard D, Maicas E. RT-PCR for mammaglobin genes, MGB1 and MGB2, identifies breast cancer micrometastases in sentinel lymph nodes. *Am J Clin Pathol* 2004; **121**: 637-43.
- Nissan A, Jager D, Roystacher M *et al*. Multimer-RT-PCR assay for the detection of minimal residual disease in sentinel lymph nodes of breast cancer patients. *Br J Cancer* 2006; **94**: 681-5.
- Lockett MA, Baron PL, O'Brien PH *et al*. Detection of occult breast cancer micrometastases in axillary lymph nodes using a multimarker reverse transcriptase-polymerase chain reaction panel. *J Am Coll Surg* 1998; **187**: 9-16.
- Yun K, Gunn J, Merrie AE, Phillips LV, McCall JL. Keratin 19 mRNA is detectable by RT-PCR in lymph nodes of patients without breast cancer. *Br J Cancer* 1997; **76**: 1112-13.
- Merrie AE, Yun K, Gunn J, Phillips LV, McCall JL. Analysis of potential markers for detection of submicroscopic lymph node metastases in breast cancer. *Br J Cancer* 1999; **80**: 2019-24.
- Bostick PJ, Chatterjee S, Chi DD *et al*. Limitations of specific reverse-transcriptase polymerase chain reaction markers in the detection of metastases in the lymph nodes and blood of breast cancer patients. *J Clin Oncol* 1998; **16**: 2632-40.
- Wascher RA, Bostick PJ, Huynh KT *et al*. Detection of MAGE-A3 in breast cancer patients' sentinel lymph nodes. *Br J Cancer* 2001; **85**: 1340-6.
- Gillanders WE, Mikhitarian K, Hebert R *et al*. Molecular detection of micrometastatic breast cancer in histopathology negative axillary lymph

- nodes correlates with traditional predictors of prognosis. An interim analysis of prospective multi-institutional cohort study. *Ann Surg* 2004; 239: 828–40.
- 43 Goydos JS, Ravikumar TS, Germino FJ, Yudd A, Bancila E. Minimally invasive staging of patients with melanoma. sentinel lymphadenectomy and detection of the melanoma-specific proteins MART-1 and tyrosinase by reverse transcriptase polymerase chain reaction. *J Am Coll Surg* 1998; 187: 182–8.
 - 44 Shivers SC, Wang X, Li W *et al.* Molecular staging of malignant melanoma. *JAMA* 1998; 280: 1410–15.
 - 45 Blaheta HJ, Schittek B, Breuninger H *et al.* Detection of melanoma micrometastasis in sentinel nodes by reverse transcription-polymerase chain reaction correlates with tumor thickness and is predictive of micrometastatic disease in the lymph node basin. *Am J Surg Pathol* 1999; 23: 822–8.
 - 46 Bostick PJ, Morton DL, Turner RR *et al.* Prognostic significance of occult metastases detected by sentinel lymphadenectomy and reverse transcriptase-polymerase chain reaction in early-stage melanoma patients. *J Clin Oncol* 1999; 17: 3238–44.
 - 47 Blaheta HJ, Ellwanger U, Schittek B *et al.* Examination of regional lymph nodes by sentinel node biopsy and molecular analysis provides new staging facilities in primary cutaneous melanoma. *J Invest Dermatol* 2000; 114: 637–42.
 - 48 Ribuffo D, Gradilone A, Vonella M *et al.* Prognostic significance of reverse transcriptase-polymerase chain reaction-negative sentinel nodes in malignant melanoma. *Ann Surg Oncol* 2003; 10: 396–402.
 - 49 Goydos JS, Patel KN, Shih WJ *et al.* Patterns of recurrence in patients with melanoma and histologically negative but RT-PCR-positive sentinel lymph nodes. *J Am Coll Surg* 2003; 196: 196–204.
 - 50 Kuo CT, Hoon DS, Takeuchi H *et al.* Prediction of disease outcome in melanoma patients by molecular analysis of paraffin-embedded sentinel lymph nodes. *J Clin Oncol* 2003; 21: 3566–72.
 - 51 Morton DL, Hoon DS, Cochran AJ *et al.* Lymphatic mapping and sentinel lymphadenectomy for early-stage melanoma: therapeutic utility and implications of nodal microanatomy and molecular staging for improving the accuracy of detection of nodal micrometastases. *Ann Surg* 2003; 238: 538–49.
 - 52 Scoggins CR, Ross MI, Reintgen DS *et al.* Prospective multi-institutional study of reverse transcriptase polymerase chain reaction for molecular staging of melanoma. *J Clin Oncol* 2006; 24: 2849–57.
 - 53 Moccellini S, Hoon DS, Pilati P, Rossi CR, Nitti D. Sentinel lymph node molecular ultrastaging in patients with melanoma: a systematic review and meta-analysis of prognosis. *J Clin Oncol* 2007; 25: 1588–95.
 - 54 Weitz J, Kienle P, Magener A *et al.* Detection of disseminated colorectal cancer cells in lymph nodes, blood and bone marrow. *Clin Cancer Res* 1999; 5: 1830–6.
 - 55 Ichikawa Y, Ishikawa T, Momiyama N *et al.* Detection of regional lymph node metastases in colon cancer by using RT-PCR for matrix metalloproteinase 7, matrilysin. *Clin Exp Metastasis* 1998; 16: 3–8.
 - 56 Liefers GJ, Cleton-Jansen AM, van de Velde CJ *et al.* Micrometastases and survival in stage II colorectal cancer. *N Engl J Med* 1998; 339: 223–8.
 - 57 Bernini A, Spencer M, Frizelle S *et al.* Evidence for colorectal cancer micrometastases using reverse transcriptase-polymerase chain reaction analysis of MUC2 in lymph nodes. *Cancer Detect Prev* 2000; 24: 72–9.
 - 58 Noura S, Yamamoto H, Ohnishi T *et al.* Comparative detection of lymph node micrometastases of stage II colorectal cancer by reverse transcriptase polymerase chain reaction and immunohistochemistry. *J Clin Oncol* 2002; 20: 4232–41.
 - 59 Mori M, Mimori K, Inoue H *et al.* Detection of cancer micrometastases in lymph nodes by reverse transcriptase-polymerase chain reaction. *Cancer Res* 1995; 55: 3417–20.
 - 60 Cortesina G, Martone T, Galeazzi E *et al.* Staging of head and neck squamous cell carcinoma using the MET oncogene product as marker of tumor cells in lymph node metastases. *Int J Cancer* 2000; 89: 286–92.
 - 61 Salerno CT, Frizelle S, Niehans GA *et al.* Detection of occult micrometastases in non-small cell lung carcinoma by reverse transcriptase-polymerase chain reaction. *Chest* 1998; 113: 1526–32.
 - 62 Ferrari AC, Stone NN, Eyler JN *et al.* Prospective analysis of prostate-specific markers in pelvic lymph nodes of patients with high-risk prostate cancer. *J Natl Cancer Inst* 1997; 89: 1498–504.
 - 63 Noguchi S, Hiratsuka M, Furukawa H *et al.* Detection of gastric cancer micrometastases in lymph nodes by amplification of keratin 19 mRNA with reverse transcriptase-polymerase chain reaction. *Jpn J Cancer Res* 1996; 87: 650–4.
 - 64 Kijima F, Natsugoe S, Takao S *et al.* Detection and clinical significance of lymph node micrometastasis determined by reverse transcription-polymerase chain reaction in patients with esophageal carcinoma. *Oncology* 2000; 58: 38–44.
 - 65 Arigami T, Natsugoe S, Uenosono Y *et al.* Evaluation of sentinel node concept in gastric cancer based on lymph node micrometastasis determined by reverse transcription-polymerase chain reaction. *Ann Surg* 2006; 243: 341–7.
 - 66 Matsuda J, Kitagawa Y, Fujii H *et al.* Significance of metastasis detected by molecular techniques in sentinel nodes of patients with gastrointestinal cancers. *Ann Surg Oncol* 2004; 11: 250–4S.
 - 67 Nagata H, Arai T, Soejima Y, Suzuki H, Ishii H, Hibi T. Limited capacity of regional lymph nodes to eradicate metastatic cancer cells. *Cancer Res* 2004; 64: 8239–48.
 - 68 Cochran AJ, Huang RR, Lee J, Itakura E, Leong SP, Essner R. Tumor-induced immune modulation of sentinel lymph nodes. *Nature Rev Immunol* 2006; 6: 659–70.
 - 69 Huang RR, Wang HJ, Lin LL, Wen DR, Itakura E, Cochran AJ. MHC-Class II molecules expression by dendritic cells correlates with activated OPD4 + T cell in of sentinel and non-sentinel nodes from melanoma patients. *Mod Pathol* 2004; 17: 382.
 - 70 Huang RR, Paul E, Wang HJ *et al.* Sentinel lymph nodes are immunosuppressed whether or not they contain metastatic melanoma. *Mod Pathol* 2005; 18: 379.
 - 71 Shu S, Cochran AJ, Huang RR, Morton DL, Maecher HT. Immune responses in the draining lymph nodes against cancer: Implications for immunotherapy. *Cancer Metastasis Rev* 2006; 25: 233–42.
 - 72 Hoon DS, Korn EL, Cochran AJ. Variation in functional immunocompetence of individual tumor-draining lymph nodes in humans. *Cancer Res* 1987; 47: 1740–4.
 - 73 Lee JH, Torisu-Itakura H, Cochran AJ *et al.* Quantitative analysis of melanoma-induced cytokine-mediated immunosuppression in melanoma sentinel nodes. *Clin Cancer Res* 2005; 11: 107–12.
 - 74 Botella-Estrada R, Dasi F, Ramos D *et al.* Cytokine expression and dendritic cell density in melanoma sentinel nodes. *Melanoma Res* 2005; 15: 99–106.
 - 75 Polak ME, Borthwick NJ, Gabriel FG *et al.* Mechanisms of local immunosuppression in cutaneous melanoma. *Br J Cancer* 2007; 96: 1879–87.
 - 76 Torisu-Itakura H, Lee JH, Scheri RP *et al.* Molecular characterization of inflammatory genes in sentinel and nonsentinel nodes in melanoma. *Clin Cancer Res* 2007; 13: 3125–32.
 - 77 Mandriota SJ, Jussila L, Jeltsch M *et al.* Vascular endothelial growth factor-C-mediated lymphangiogenesis promotes tumor metastasis. *EMBO J* 2001; 20: 672–82.
 - 78 Skobe M, Hawighorst T, Jackson DG *et al.* Induction of tumor lymphangiogenesis by VEGF-C promotes breast cancer metastasis. *Nat Med* 2001; 7: 192–8.
 - 79 Stacker SA, Caesar C, Baldwin ME *et al.* VEGF-D promotes the metastatic spread of tumor cells via the lymphatics. *Nat Med* 2001; 7: 186–91.
 - 80 Achen MG, McColl BK, Stacker SA. Focus on lymphangiogenesis in tumor metastasis. *Cancer Cell* 2005; 7: 121–7.
 - 81 Tobler NE, Detmer M. Tumor and lymph node lymphangiogenesis: impact on cancer metastasis. *J Leukoc Biol* 2006; 80: 691–6.
 - 82 Dadrass SS, Lange-Asschenfeldt B, Velasco P *et al.* Tumor lymphangiogenesis predicts melanoma metastasis to sentinel lymph nodes. *Mod Pathol* 2005; 18: 1232–42.
 - 83 Hirakawa S, Kodama S, Kunstfeld R, Kajiya K, Brown LF, Detmar M. VEGF-A induces tumor and sentinel lymph node lymphangiogenesis and promotes lymphatic metastasis. *J Exp Med* 2005; 201: 1089–99.
 - 84 Padera TP, Kadambi A, di Tomaso E *et al.* Lymphatic metastasis in the absence of functional intratumoral lymphatics. *Science* 2002; 296: 1883–6.
 - 85 Wong SY, Haack H, Crowley D *et al.* Tumor-secreted vascular endothelial growth factor-C is necessary for prostate cancer lymphangiogenesis, but lymphangiogenesis is unnecessary for lymph node metastasis. *Cancer Res* 2005; 65: 9789–98.
 - 86 Beasley NJ, Prevost R, Banerji S *et al.* Intratumoral lymphangiogenesis and lymph node metastasis in head and neck cancer. *Cancer Res* 2002; 62: 1315–20.
 - 87 Banerji S, Ni J, Wang SX *et al.* LYVE-1, new homologue of the CD44 glycoprotein, is a lymph-specific receptor for hyaluronan. *J Cell Biol* 1999; 144: 789–801.
 - 88 Breiteneder-Geleff S, Soleiman A, Kowalski H *et al.* Angiosarcomas express mixed endothelial phenotypes of blood and lymphatic capillaries: podoplanin as a specific marker for lymphatic endothelium. *Am J Pathol* 1999; 154: 385–94.
 - 89 Wigle JT, Oliver C. PROX-1 function is required for the development of the murine lymphatic system. *Cell* 1999; 98: 769–78.
 - 90 Joukov V, Pajusola K, Kaipainen A *et al.* A novel vascular endothelial growth factor, VEGF-C, as a ligand for Flt4 (VEGFR-3) and KDR (VEGFR-2) receptor tyrosine kinases. *EMBO J* 1996; 15: 290–8.
 - 91 Nathanson SD. Insights into the mechanisms of lymph node metastasis. *Cancer* 2003; 98: 413–23.
 - 92 Karpanen T, Egeblad M, Karkkainen MJ *et al.* Vascular endothelial growth factor C promotes tumor lymphangiogenesis and intralymphatic tumor growth. *Cancer Res* 2001; 61: 1786–90.
 - 93 Mattila MMT, Ruohola JK, Karpanen T, Jackson DG, Alituro K, Harkonen PL. VEGF-C induced lymphangiogenesis is associated with lymph node metastasis in orthotopic MCF-7 tumors. *Int J Cancer* 2002; 98: 946–51.

- 94 Wissmann C, Detmer M. Pathways targeting tumor lymphangiogenesis. *Clin Cancer Res* 2006; **12**: 6865–8.
- 95 Soker S, Takashima S, Miao H, Neufeld G, Klagsbrun M. Neuropilin is expressed by endothelial and tumor cells as isoform-specific receptor for vascular endothelial growth factor. *Cell* 1998; **92**: 735–45.
- 96 Salameh A, Galvagni F, Bardelli M, Bussolino F, Oliviero S. Direct recruitment of CRK and GRB2 to VEGFR-3 induce proliferation, migration and survival of endothelial cells through the activation of ERK, AKT and JNK pathways. *Blood* 2005; **106**: 3423–31.
- 97 Dias S, Choy M, Alituro K, Rafii S. Vascular endothelial growth factor (VEGF)-C signaling through FLT-4 (VEGFR-3) mediates leukemic cell proliferation, survival, and resistance to chemotherapy. *Blood* 2002; **99**: 2179–84.
- 98 Roberts N, Kloos B, Cassella M *et al.* Inhibition of VEGFR-3 activation with the antagonistic antibody more potently suppresses lymph node and distant metastases than inactivation of VEGFR-2. *Cancer Res* 2006; **66**: 2650–7.
- 99 Fidler IJ. Critical determinants of metastasis. *Semin Cancer Biol* 2002; **12**: 89–96.
- 100 Fidler IJ. Seed and soil revisited: contribution of the organ microenvironment to cancer metastasis. *Surg Oncol Clin N Am* 2001; **10**: 257–69.
- 101 Paget S. The distribution of secondary growth in cancer of the breast. *Lancet* 1989; **1**: 571–3.
- 102 Dieu MC, Vanbervliet B, Vicari A *et al.* Selective recruitment of immature and mature dendritic cells by distinct chemokines expressed in different anatomic sites. *J Exp Med* 1998; **188**: 373–86.
- 103 Förster R, Schubel A, Breitfeld D *et al.* CCR7 coordinates the primary immune response by establishing functional microenvironments in secondary lymphoid organs. *Cell* 1999; **99**: 23–33.
- 104 Nakano H, Tamura T, Yoshimoto T *et al.* Genetic defect in T lymphocyte-specific homing into peripheral lymph nodes. *Eur J Immunol* 1997; **27**: 215–21.
- 105 Willmann K, Legler DF, Loetscher M *et al.* The chemokine SLC is expressed in T cell areas of lymph nodes and mucosal lymphoid tissues and attracts activated T cells via CCR7. *Eur J Immunol* 1998; **28**: 2025–34.
- 106 Zlotnik A, Yoshie O. Chemokines: a new classification system and their role in immunity. *Immunity* 2000; **12**: 121–7.
- 107 Moretta A. Natural killer cells and dendritic cells: rendezvous in abused tissues. *Nat Rev Immunol* 2002; **2**: 957–65.
- 108 Chambers AF, Groom AC, MacDonald IC. Dissemination and growth of cancer cells in metastatic sites. *Nat Rev Cancer* 2002; **2**: 563–72.
- 109 Gunn MD, Tangemann K, Tam C, Cyster JG, Rosen SD, Williams LT. A chemokine expressed in lymphoid high endothelial venules promotes the adhesion and chemotaxis of naive T lymphocytes. *Proc Natl Acad Sci USA* 1998; **95**: 258–63.
- 110 Yoshida R, Nagira M, Imai T *et al.* EB11-ligand chemokine (ELC) attracts a broad spectrum of lymphocytes: activated T cells strongly up-regulate CCR7 and efficiently migrate toward ELC. *Int Immunol* 1998; **10**: 901–10.
- 111 Geissmann F, Dieu-Nosjean MC, Dezutter C *et al.* Accumulation of immature Langerhans cells in human lymph nodes draining chronically inflamed skin. *J Exp Med* 2002; **196**: 417–30.
- 112 Yanagihara S, Komura E, Nagafune J, Watarai H, Yamaguchi Y. EB11/CCR7 is a new member of dendritic cell chemokine receptor that is up-regulated upon maturation. *J Immunol* 1998; **161**: 3096–102.
- 113 Muller A, Homey B, Soto H *et al.* Involvement of chemokine receptors in breast cancer metastasis. *Nature* 2001; **410**: 50–6.
- 114 Takeuchi H, Fujimoto A, Tanaka M, Yamano T, Hsueh E, Hoon DS. CCL21 chemokine regulates chemokine receptor CCR7 bearing malignant melanoma cells. *Clin Cancer Res* 2004; **10**: 2351–8.
- 115 Mori T, Kim J, Yamano T *et al.* Epigenetic up-regulation of C-C chemokine receptor 7 and C-X-C chemokine receptor 4 expression in melanoma cells. *Cancer Res* 2005; **65**: 1800–7.
- 116 Hjelmstrom P, Fjell J, Nakagawa T, Sacca R, Cuff CA, Ruddle NH. Lymphoid tissue homing chemokines are expressed in chronic inflammation. *Am J Pathol* 2000; **156**: 1133–8.
- 117 Wiley HE, Gonzalez EB, Maki W, Wu MT, Hwang ST. Expression of CC chemokine receptor-7 and regional lymph node metastasis of B16 murine melanoma. *J Natl Cancer Inst* 2001; **93**: 1638–43.
- 118 Mashino K, Sadanaga N, Yamaguchi H *et al.* Expression of chemokine receptor CCR7 is associated with lymph node metastasis of gastric carcinoma. *Cancer Res* 2002; **62**: 2937–41.
- 119 Ding Y, Shimada Y, Maeda M *et al.* Association of CC chemokine receptor 7 with lymph node metastasis of esophageal squamous cell carcinoma. *Clin Cancer Res* 2003; **9**: 3406–12.
- 120 Eilber FR, Morton DL, Holmes EC, Sparks FC, Ramming KP. Adjuvant immunotherapy with BCG in treatment of regional-lymph-node metastases from malignant melanoma. *N Engl J Med* 1976; **294**: 237–40.
- 121 Radny P, Caroli UM, Bauer J *et al.* Phase II trial of intralesional therapy with interleukin-2 in soft-tissue melanoma metastases. *Br J Cancer* 2003; **89**: 1620–6.
- 122 Horton HM, Hernandez P, Parker SE, Barnhart KM. Antitumor effects of interferon- γ in vivo therapy of human tumor xenografts in nude mice. *Cancer Res* 1999; **59**: 4064–8.
- 123 Pan PY, Li Y, Li Q *et al.* In situ recruitment of antigen-presenting cells by intratumoral GM-CSF gene delivery. *Cancer Immunol Immunother* 2004; **53**: 17–25.
- 124 Dranoff G. GM-CSF-based cancer vaccines. *Immunol Rev* 2002; **188**: 147–54.
- 125 Vuylsteke RJ, Molenkamp BG, Gietema HA *et al.* Local administration of granulocyte/macrophage colony – stimulating factor increases the number and activation state of dendritic cells in the sentinel lymph node of early-stage melanoma. *Cancer Res* 2004; **64**: 8456–60.
- 126 Salcedo M, Bercovici N, Taylor R *et al.* Vaccination of melanoma patients using dendritic cells loaded with an allogeneic tumor cell lysate. *Cancer Immunol Immunother* 2006; **55**: 819–29.
- 127 Kuwashima N, Nishimura F, Eguchi J *et al.* Delivery of dendritic cells engineered to secrete IFN- α into central nervous system tumors enhances the efficacy of peripheral tumor cell vaccines: dependence on apoptotic pathways. *J Immunol* 2005; **175**: 2730–40.
- 128 Chen Z, Warney ML, Backora MW *et al.* Down-regulation of vascular endothelial cell growth factor-C expression using small interfering RNA vectors in mammary tumors inhibits tumor lymphangiogenesis and spontaneous metastasis and enhances survival. *Cancer Res* 2005; **65**: 9004–11.
- 129 Rubin JB, Kung AL, Klein RS *et al.* A small-molecule antagonist of CXCR4 inhibits intracranial growth of primary brain tumors. *Proc Natl Acad Sci USA* 2003; **100**: 13513–18.
- 130 Tanaka T, Bai Z, Srinoulprasert Y *et al.* Chemokines in tumor progression and metastasis. *Cancer Sci* 2005; **96**: 317–22.

早期胃癌に対する sentinel node 理論に基づく
リンパ行性癌転移診断・治療の新展開

竹内 裕也 才川 義朗 上田 政和 北川 雄光

脈管学 第48巻第5号
別 刷

日本脈管学会

(J Jpn Coll Angiol, 2008, 48: 415-418)

早期胃癌に対するsentinel node理論に基づく リンパ行性癌転移診断・治療の新展開

竹内 裕也 才川 義朗 上田 政和 北川 雄光

要 旨：cT1N0胃癌は、sentinel node(SN)理論を応用した機能温存・個別化縮小手術が最も期待されている疾患の一つである。低侵襲性と術後QOLの維持を目指し、今後は積極的に腹腔鏡下胃癌手術にsentinel node navigation surgeryを応用した縮小手術が取り入れられることが予想される。しかし、本来定型的な幽門側胃切除術で完治を目指すことが十分可能な病期であるだけに、安全性や精度の検証には慎重を期するべきである。SN転移診断に基づく縮小手術を行うには術中SN微小転移診断が必須であり、その臨床的有用性評価が待たれるところである。

(J Jpn Coll Angiol, 2008, 48: 415-418)

Key words: sentinel node, early gastric cancer, laparoscopic surgery, RT-PCR

はじめに

腫瘍から直接リンパ流を受けるリンパ節をsentinel node(SN)と呼んでいる。SN理論とはSNを最初のリンパ節微小転移が生じる場所とする考え方である。この理論が正しいと仮定すると、SNにリンパ節転移がなければその他のリンパ節にも転移は生じていないと判断することができ、SN以外のリンパ節郭清は不必要となる。sentinel node navigation surgery(SNNS)とは、このSNの分布(SN mapping)とSNの生検による転移の有無を指標として、リンパ節郭清を個別的に縮小ないし省略し、それに伴って臓器切除範囲を最小限とすることを目的とした手術である。

すでに乳癌や悪性黒色腫では、SN理論の妥当性、臨床的有用性が実証されており^{1,2)}、乳癌におけるSN転移診断に基づく腋窩リンパ節郭清の省略など個別化縮小手術が実践されている。早期胃癌は消化器癌のなかではSN理論研究が最も進んだ領域であり、SNNSによる機能温存・個別化縮小手術への応用が期待され、現在われわれはその開発に取り組んでいる³⁾。

一方、胃癌のような深部臓器の腫瘍でSN転移診断に

基づく縮小手術を行うには、術中のSN転移診断が必須である。術中SN迅速微小転移検出法についてもこれまでさまざまなシステムが開発され、われわれが開発した術中迅速real-time reverse transcription-polymerase chain reaction (RT-PCR)のシステムを含めて臨床的有用性評価が待たれるところである。

本稿では、早期胃癌におけるSN理論を応用した個別化縮小手術とSN微小転移診断の現況につき概説する。

早期胃癌に対するSN同定手技

SNは、トレーサー[色素あるいはradioisotope(RI)でラベルされたコロイド]を腫瘍原発巣周囲に投与し、ある一定時間後にトレーサーが集積したSNを視認、あるいはRI活性を測定することにより同定している。われわれは早期胃癌のSN同定には、現時点で色素法単独よりもRIと色素の併用法が適していると考えており、isosulfan blueと^{99m}テクネシウムスズコロイドによる併用法を実践している。色素はその粒子径が小さいため比較的短時間で遠位のリンパ節まで拡散する。そのため術中のリアルタイムなリンパ流の観察や、SN領域(SN basin)の視認性には優れているものの、厚い脂肪組織内に隠れたSNを同定する

には必ずしも適してはいない。一方^{99m}テクネシウムスズコロイドは、粒子径が比較的大きく、SNにおける滞留性に優れているため、深部脂肪組織内など色素による視認の困難な部位の検索を可能にし、腹腔鏡下手術におけるSN同定にも有用である。

トレーサー投与方法としてはisofluor blue, ^{99m}テクネシウムスズコロイドともに術前、術中内視鏡を用いた粘膜下注入法を採用している。この方法は漿膜側からは触知しにくいcT1病変についても正確なトレーサー投与が可能であり、腹腔鏡下手術においても応用可能である点があり、有利である。

通常、手術前日内視鏡下に^{99m}テクネシウムスズコロイドを病変直下の粘膜下層に全周4カ所に注入し、約4時間後にSN同定のための術前リンフォシンチグラフィーを行っている。注入したRIトレーサーが正しく粘膜下層に注入されることが重要である。

実際の手術中のSN同定手技につき概説する。手術開始直後に内視鏡を用いて、isofluor blueを腫瘍周囲の粘膜下層に0.5mlずつ全周4カ所注入する。すると色素注入後より病巣部から青く染まったリンパ管が視認できるので、色素注入15分後にこれをたどっていきと青く染まったリンパ節(blue node)が同定される。さらに小型ガンマプローブによりRIの集積したSN(hot node)を同定する。blue nodeとhot nodeは一致することがほとんどであるが、一致しない例もあるため注意を要する。

次いでSNのサンプリングあるいはSNを含むそのリンパ領域(SN basin)の切除を行う。摘出したSNはback tableでRI集積を測定、術中迅速病理診断とRT-PCR診断を行っている。

早期胃癌に対するSNNS臨床応用の展望

消化器癌領域において現時点で、機能温存・個別化縮小手術への応用が最も期待される対象はcT1N0胃癌である。近年、胃癌に対するSN同定手技は飛躍的に向上し、これまでに多数の単施設研究で良好なSN同定率、転移検出感度が報告されている。さらには腹腔鏡下胃癌手術手技の向上により、内視鏡下手術による低侵襲性の確保とQOL維持を目指したSNNSによる機能温存・縮小手術の組み合わせが技術的に可能となってきた⁴⁻⁶⁾。2008年3月でSNNS研究会/厚生労働省がん研究助成金研究班による多施設共同研究が登録完了し、今後SNNS標準手術手技の確立に向けてその結果が注目されている。

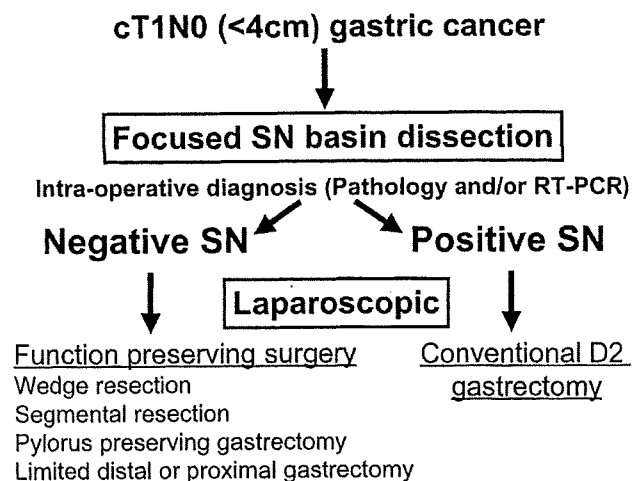


Figure 1 Current approaches for early gastric cancer based on SN navigation.

SN転移陰性早期胃癌は、郭清の完全省略、胃原発巣の局所切除だけで根治術とすることが理論的には可能である。しかし、偽陰性(SNには転移がみられないのにSN以外のリンパ節に転移を認める)の問題が完全には解決されていない現状では、より安全域のある根治性を損なわない術式が求められる。すなわち、現時点ではSNを含むそのリンパ領域(SN basin)を選択的に郭清する術式(SN basin dissection)がよいと考えられる⁷⁾(Fig. 1)。これまでの検討では、SN同定の技術的問題や術中迅速診断の見逃しにより偽陰性が生じた場合でも、実際のリンパ節転移はSN basin内に存在した限定される可能性が高い。術中にSNが1領域に限定される場合は、その領域のbasin dissectionと原発巣を含む胃局所切除が可能である。またSNが2領域(小彎、大彎)にわたる場合は、その2領域のbasin dissectionと原発巣を含む胃分節切除が可能と考えられる。一方、SNに明らかな転移が認められる症例ではSN領域外にも転移が存在する可能性が否定できないため、現時点では標準的な切除郭清術が必要である。

今後、早期胃癌に対するSNNSの臨床応用に向け、術中SN同定技術、微小転移診断技術の精度向上が必須であるが、われわれは現時点で安全性を損なわない方策として前項のSN basin dissectionの施行と術中迅速RT-PCR法の実用化が重要であると考えている。今後、胃癌におけるSN理論の妥当性が実証され、SN生検標準手術手技が確立すれば、今後は積極的に腹腔鏡下胃癌手術にSNNSを応用した縮小手術が取り入れられることが予想される。しかし腹腔鏡下に行う場合の標準手技の確立や

精度の検証も慎重に進める必要がある。

胃癌SN術中迅速病理診断

SNにおける胃癌微小転移検出のための術中迅速病理診断は、従来リンパ節の最大断面を含む数切片に限られたスライドの顕微鏡下での検索であり、ヘマトキシリン・エオジン(H&E)染色だけではその検出感度に限界があった。これまでにH&E染色に抗サイトケラチン抗体カクテルなどの免疫組織染色を加えることでSN微小転移検出感度が著しく向上することが報告されている。しかしながら、H&E染色と同様に数切片に限られたスライドの検索であることや、frozen sectionはパラフィン包埋切片と比べ病理診断が困難である点があり、SN内の微小転移を見落とす可能性を完全には否定できない。

われわれの約250例の検討では、H&E染色だけの術中迅速病理診断では、永久標本診断と比べ約20%の症例で転移陽性の診断ができなかった。これに術中免疫組織染色を加えても10%弱の症例がやはり転移陽性を診断できなかった。このような従来の病理組織学的な術中転移診断の限界から、分子生物学的手法を用いた新たな術中転移診断法の開発が進められている。

分子生物学的手法を用いた 胃癌センチネルリンパ節術中診断

近年RT-PCR法やone-step nucleic acid amplification (OSNA)法など分子生物学的手法を用いて形態学的には捕捉しえない癌細胞まで検出することが可能となってきている^{8,9)}。これらは従来の病理学的診断法よりも高感度であることや、数スライドだけの検索ではなくリンパ節全体を一度に検索できる点で優れた手法であるといえる。しかし、こうした高感度な手法で検出された目に見えない“癌細胞”，つまり癌細胞特異的DNAや癌細胞特異的mRNA発現を、果たしてどこまで癌転移と判断してよいのかは慎重であるべきと考えている。たとえばRT-PCR法におけるmRNA抽出からRT, PCRにいたる過程でのコンタミネーションや、手技の不確実さによる偽陰性の問題、PCRの再現性の問題など注意すべき点は多い。

これまでに、RT-PCR法を用いた胃癌のSN微小転移検索についていくつかの論文報告がなされている。Osaka¹⁰⁾は早期胃癌患者57例から切除された計345個のリンパ節(blue node 150個と非blue node 195個)を検討した。切除されたリンパ節は半割され、片方は病理組織学的

検索、もう半分はCEAとCK20をマーカーとしたreal time RT-PCR法に用いられた。通常のH&E染色では全てのリンパ節が転移陰性であったが、うち8個のリンパ節が抗サイトケラチン染色陽性であった。またRT-PCR法で陽性と判定されたものは、計21個(10症例)のリンパ節であった。この10人はblue nodeのうちいずれか1つはRT-PCR陽性であったことから、molecular levelでも偽陰性症例は認められず、blue nodeはSNと考えられると結論付けている。

Arigami¹¹⁾は、RI法によるSN生検を施行したcT1, cT2N0胃癌患者61例の計1,410個のリンパ節で同様の検討を行っている。それによるとSNのH&E染色で転移陽性と診断された患者は5例(8.2%)、SN抗サイトケラチン染色陽性例は8例(13.1%)に認められた。SNの免疫組織染色陰性例53例のうち、SNのRT-PCR法で陽性であったものは13例(25%)であった。SNのRT-PCRが陰性であった40例のうち、非SNでRT-PCRが陽性であった、つまりmolecular levelでの偽陰性例はcT2症例1例のみであった。この結果は、cT1N0症例であれば、molecular levelでも偽陰性症例は認められないということとなり、cT1N0症例におけるSN理論の妥当性や、彼らのSN生検から微小転移診断に至る手技の正確性を評価できる報告である。また、今後これらの結果をもとに胃機能温存・個別化縮小手術の開発が期待される。

われわれも胃癌に対するSN微小転移診断法としてRoche Diagnostics社とCK19, CK20, CEAをマーカーとしたreal time RT-PCR法を共同開発し、その臨床的有用性を検証中である。この方法は検体採取から結果が出るまで約60分と術中迅速診断に有用である。これまでに約100例のSN生検施行例について検討を行い、molecular levelでの偽陰性症例を4%に認めている。しかしながら、これら偽陰性を生じた非SNはいずれもSNと同一のlymphatic basin内に認められており、今後SN転移診断に基づく個別化縮小手術において最も重要な点である安全性の担保としてSN basin dissectionは不可欠であると考えられる。

早期胃癌における癌微小転移やisolated tumor cellsの臨床的意義についてはいまだ明らかではなく、長期予後の検討も含め今後さらなる検証が必要である。

おわりに

今後早期胃癌に対して機能温存・個別化縮小治療を

目指すうえで、腹腔鏡下SNNSの臨床応用が積極的になされていくものと考えられる。一方、機能温存・縮小手術と同時に安全性、根治性の確保は必要不可欠であり、術中のSN微小転移診断能の向上が求められている。今後はSN生検から微小転移診断まで共通の手技、プロトコルを用いた大規模な多施設共同研究が必要であろうと考えられる。

文 献

- 1) Morton DL, Wen DR, Wong JH et al: Technical details of intraoperative lymphatic mapping for early stage melanoma. *Arch Surg*, 1992, **127**: 392-399.
- 2) Giuliano, AE Kirgan DM, Guenther JM et al: Lymphatic mapping and sentinel lymphadenectomy for breast cancer. *Ann Surg*, 1994, **220**: 391-398.
- 3) Kitagawa Y, Fujii H, Mukai M et al: The role of the sentinel lymph node in gastrointestinal cancer. *Surg Clin North Am*, 2000, **80**: 1799-1809.
- 4) Saikawa Y, Otani Y, Kitagawa Y et al: Interim results of sentinel node biopsy during laparoscopic gastrectomy: possible role in function-preserving surgery for early cancer. *World J Surg*, 2006, **30**: 1962-1968.
- 5) Kitagawa Y, Fujii H, Mukai M et al: Intraoperative lymphatic mapping and sentinel lymph node sampling in esophageal and gastric cancer. *Surg Oncol Clin N Am*, 2002, **11**: 293-304.
- 6) Kitagawa Y, Fujii H, Mukai M et al: Sentinel lymph node mapping in esophageal and gastric cancer. *Cancer Treat Res*, 2005, **127**: 123-139.
- 7) 竹内裕也, 才川義朗, 和田則仁 ほか: 早期胃癌におけるセンチネルリンパ節生検の手法と課題. *消化器外科*, 2007, **30**: 1481-1487.
- 8) Takeuchi H, Kitajima M, Kitagawa Y: Sentinel lymph node as a target of molecular diagnosis of lymphatic micrometastasis and local immunoresponse to malignant cells. *Cancer Sci*, 2008, **99**: 441-450.
- 9) 竹内裕也, 才川義朗, 和田則仁 ほか: 術前・術中のリンパ節転移診断の方法とその有用性 胃癌における術前・術中のリンパ節転移診断の方法とその有用性. *臨床外科*, 2008, **63**: 347-352.
- 10) Osaka H, Yashiro M, Sawada T et al: Is a lymph node detected by the dye-guided method a true sentinel node in gastric cancer? *Clin Cancer Res*, 2004, **10**: 6912-6918.
- 11) Arigami T, Natsugoe S, Uenosono Y et al: Evaluation of sentinel node concept in gastric cancer based on lymph node micrometastasis determined by reverse transcription-polymerase chain reaction. *Ann Surg*, 2006, **243**: 341-347.

New Insights into the Diagnosis and Management of Lymphatic Spread Based on the Sentinel Node Concept for Early Gastric Cancer

Hiroya Takeuchi, Yoshiro Saikawa, Masakazu Ueda, and Yuko Kitagawa

Department of Surgery, Keio University School of Medicine, Tokyo, Japan

Key words: sentinel node, early gastric cancer, laparoscopic surgery, RT-PCR

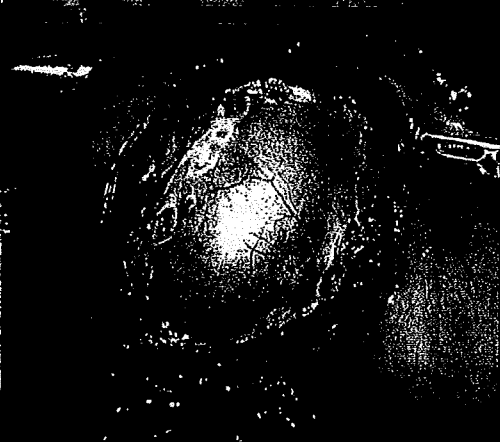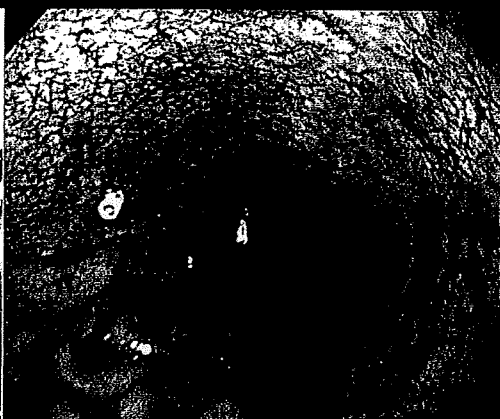

For cT1NO early gastric cancer, in which better prognosis generally has been achieved by conventional surgical approaches, an individualized minimally invasive surgery should be considered as the next surgical challenge. Although some issues still need to be resolved, a combination of laparoscopic gastrectomy with sentinel node (SN) navigation surgery has the potential to achieve this goal. Increasing the sensitivity of occult tumor cell detection in the SN using molecular-based analysis should provide a more accurate understanding of the clinical significance of various patterns of micrometastatic nodal disease. (*J Jpn Coll Angiol*, 2008, **48**: 415-418)

消化器内視鏡

E N D O S C O P I A D I G E S T I V A

オーダーメイド医療を 可能にする胃癌診断

Individualized Therapy for Gastric Cancer



特集

オーダーメイド医療を可能にする 胃癌診断

698 序説——竹下公矢

↳

699 胃癌のオーダーメイド医療をめぐる

—「胃癌取扱い規約」,「胃癌治療ガイドライン」からみて——竹下公矢

↳

[早期胃癌]

703 早期胃癌の治療法を左右する病理所見—EMR/ESDの適応を中心に

——大倉康男

709 EMR/ESD 適応早期胃癌の診断—近年のX線検査の進歩と

術前精密検査におけるX線検査の位置づけ——長浜 孝ほか

719 EMR/ESD 適応早期胃癌の診断—通常内視鏡による拾い上げ——中村仁紀ほか

725 EMR/ESD 適応早期胃癌の診断(術前診断):内視鏡——豊泉博史ほか

735 EMR/ESD 適応早期胃癌の診断(術前診断):内視鏡(EUS)——芳野純治ほか

742 EMR 後遺残再発病変の内視鏡診断——光永 篤ほか

749 腹腔鏡下手術の適応基準—EMR/ESD か腹腔鏡下手術か?

その間を埋める新しい治療法の提案——井上晴洋ほか

755 腹腔鏡下胃切除術の適応規準

—Sentinel Node Navigation Surgery の立場から——竹内裕也ほか

759 腹腔鏡下幽門側胃切除術—標準手術と適応拡大の可能性——石田善敬ほか

763 機能温存手術の適応基準およびその応用からみた

各種診断法の意義づけ——藤村 隆ほか

[進行胃癌]

771 標準的胃癌根治手術における診断的側面——藤田晃司ほか

779 進行胃癌に対する個別的化学療法の効果判定——吉田和弘ほか

788 胃癌に対する分子標的治療と個別化医療——北台靖彦ほか