

Table 6 Multivariate analyses for tumor recurrence and death according to nodal status

Model 1: LVTEs identified by HE staining					Model 2: LVTEs identified by D2-40 staining				
Parameter	Cases	TRR (%)	HR (95% CI)	P	Parameter	Cases	TRR (%)	HR (95% CI)	P
<i>Lymph node metastasis-negative cases (65 cases)</i>									
LVTEs in the nontumor stroma area					LVTEs in the nontumor stroma area				
Absent	60	8 (13)	Referent		Absent	58	8 (14)	Referent	
Present	5	3 (60)	20.9 (3.2-137.2)	.002	Present	7	3 (43)	12.3 (1.7-87.4)	0.011
Fibrotic focus					Fibrotic focus				
Absent	37	4 (11)	Referent		Absent	37	4 (11)	Referent	
Present	28	7 (25)	6.9 (1.3-37.8)	.027	Present	28	7 (25)	7.0 (1.2-41.4)	0.033
<i>Lymph node metastasis-positive cases (83 cases)</i>									
Histologic grade					LVTEs in the advance area				
1 and 2	56	18 (32)	Referent		Absent	37	13 (35)	Referent	
3	27	20 (74)	3.1 (1.5-6.1)	.001	Present	46	25 (54)	2.8 (1.4-5.9)	.004
ER and PR					Histologic grade				
Negative	34	19 (56)	Referent		1 and 2	56	18 (32)	Referent	
Positive	49	19 (39)	0.3 (0.2-0.7)	.002	3	27	20 (74)	4.3 (2.1-9.0)	<.001
Tumor size (mm)					ER and PR				
≤20	23	4 (17)	Referent		Negative	34	19 (56)	Referent	
>20	60	34 (57)	3.7 (1.2-11.2)	.018	Positive	49	19 (39)	0.3 (0.2-0.7)	.002
Fibrotic focus					Tumor size (mm)				
Absent	27	8 (30)	Referent		≤20	23	4 (17)	Referent	
Present	56	30 (54)	2.4 (1.1-5.3)	.035	>20	60	34 (57)	3.9 (1.3-11.3)	.015
					Fibrotic focus				
					Absent				
					Present				
					Referent				
					2.5 (1.1-5.5)				
					.030				
Parameter	Cases	MR (%)	HR (95% CI)	P	Parameter	Cases	MR (%)	HR (95% CI)	P
LVTEs in the intratumor area					LVTEs in the intratumor area				
Absent	67	22 (33)	Referent		Absent	60	17 (28)	Referent	
Present	16	10 (63)	2.3 (1.1-5.0)	.031	Present	23	15 (65)	3.3 (1.6-6.6)	.001
Histologic grade					Histologic grade				
1 and 2	56	14 (25)	Referent		1 and 2	56	14 (25)	Referent	
3	27	18 (67)	4.0 (1.9-8.2)	<.001	3	27	18 (67)	4.4 (2.1-9.0)	<.001
ER and PR					ER and PR				
Negative	34	18 (53)	Referent		Negative	34	18 (53)	Referent	
Positive	49	14 (29)	0.3 (0.2-0.7)	.003	Positive	49	14 (29)	0.4 (0.2-0.8)	.007

Abbreviations: TRR, tumor recurrence rate; MR, mortality rate; CI, confidence interval.

The numbers of LVTEs identified by HE and D2-40 staining in the intratumor area were significantly correlated with the number of LVTEs identified by HE and D2-40 staining in the advance and in the nontumor area (Fig. 3A-F). In addition, the numbers of LVTEs identified by HE staining in each area were significantly correlated with the numbers of LVTEs identified by D2-40 staining (Fig. 3G-I).

In terms of the concordance between the results of LVTE identified by HE and D2-40 staining, very high specificity, positive predictive values, and negative predictive values were obtained in cases with true LVTE in each tumor observed in this study (Table 3). In addition, cases in which an LVTE identified by HE or D2-40 staining in the intratumor area had significantly higher mean numbers of LVTEs identified by HE or D2-40 staining in the advance

area and in the nontumor area than in which cases no LVTEs were identified by HE or D2-40 staining (Table 3).

3.3. Multivariate analyses for lymph node metastasis, tumor recurrence, and death

Multivariate analyses clearly demonstrated that identification of LVTEs by HE staining or D2-40 staining and the presence of a fibrotic focus or blood vessel invasion were significantly associated with the presence of lymph node metastasis (Table 4).

The multivariate analyses showed that in IDCs that were ER or PR positive or positive for both and in which HE or D2-40 staining detected an LVTE, the presence of an LVTE in the nontumor area and tumor size greater than 20 mm significantly increased the hazard rates (HRs) of tumor

Table 7 Multivariate analyses for tumor recurrence and death according to ER and PR status

Model 1: LVTEs identified by HE staining and blood vessel invasion					Model 2: LVTEs identified by D2-40 staining and blood vessel invasion				
Parameter	Cases	TRR (%)	HR (95% CI)	P	Parameter	Cases	TRR (%)	HR (95% CI)	P
<i>ER or PR positive or both positive (90 cases)</i>									
LVTEs in the nontumor stroma area and blood vessel invasion					Tumor size (mm)				
Absent	60	12 (20)	Referent		≤20	32	4 (13)	Referent	
Present	30	14 (47)	2.2 (1.1-4.2)	.022	>20	58	22 (38)	3.5 (1.2-10.2)	.023
Tumor size (mm)									
≤20	32	4 (13)	Referent						
>20	58	22 (38)	3.2 (1.1-9.4)	.036					
<i>ER and PR negative (57 cases)</i>									
LVTEs in the intratumor area and blood vessel invasion					LVTEs in the advance area and blood vessel invasion				
Absent	37	10 (27)	Referent		Absent	23	2 (9)	Referent	
Present	20	14 (70)	2.9 (1.3-6.2)	.006	Present	34	22 (65)	3.4 (1.6-7.1)	.001
Histologic grade					Histologic grade				
1 and 2	34	10 (29)	Referent		1 and 2	34	10 (29)	Referent	
3	23	14 (61)	6.2 (2.4-16.0)	<.001	3	23	14 (61)	7.6 (2.8-20.1)	<.001
Lymph node metastasis					Lymph node metastasis				
Absent	23	5 (22)	Referent		Absent	23	5 (22)	Referent	
Present	34	19 (56)	5.5 (1.7-17.6)	.004	Present	34	19 (56)	4.7 (1.4-15.1)	.010
Parameter	Cases	MR (%)	HR (95% CI)	P	Parameter	Cases	MR (%)	HR (95% CI)	P
LVTEs in the intratumor area and blood vessel invasion					LVTEs in the intratumor area and blood vessel invasion				
Absent	37	10 (27)	Referent		Absent	33	8 (24)	Referent	
Present	20	14 (70)	3.4 (1.6-7.4)	.002	Present	24	16 (67)	3.1 (1.7-5.9)	<.001
Histologic grade					Histologic grade				
1 and 2	34	10 (29)	Referent		3 and 2	34	10 (29)	Referent	
3	23	14 (61)	4.5 (1.8-11.2)	<.001	1	23	14 (61)	3.9 (1.6-9.5)	.003
Lymph node metastasis					Tumor size (mm)				
Absent	22	5 (23)	Referent		≤20	23	4 (17)	Referent	
Present	34	18 (53)	3.3 (1.2-9.4)	.024	>20	34	20 (59)	4.2 (1.4-12.5)	.011

Abbreviations: TRR, tumor recurrence rate; MR, mortality rate; CI, confidence interval.

recurrence (Table 5, Fig. 4A and B). The presence of an LVTE identified by HE or D2-40 staining failed to increase the HR for tumor death, but histologic grade 3 and the presence of nodal metastasis significantly increased the HRs for tumor death (Table 5).

The multivariate analyses showed that in IDCs that were both ER and PR negative and wherein HE-staining identified an LVTE, the presence of an LVTE in the intratumor area significantly increased the HRs of tumor recurrence (Table 5). On the other hand, in IDCs in which D2-40 staining detected an LVTE, a significant increase in the HR for tumor recurrence was observed when an LVTE was present in the advance area (Table 5). The presence of an LVTE identified by HE or D2-40 staining in the intratumor area significantly increased the HRs for tumor death in the multivariate analyses (Table 5, Fig. 4C and D).

In IDCs without nodal metastasis and in which HE or D2-40 staining detected an LVTE, the presence of an LVTE in the nontumor area and the presence of a fibrotic focus significantly increased the HRs of tumor recurrence (Table 6).

Although no significant association between the presence of an LVTE identified by HE staining and tumor recurrence was observed in IDCs with nodal metastasis, the presence of an LVTE, identified by D2-40 staining in the advance area as well as histologic grade 3, ER/PR-negative status, tumor size greater than 20 mm, and presence of a fibrotic focus, significantly increased the HRs of tumor recurrence in the multivariate analysis (Table 6). As for tumor death, the presence of an LVTE in the intratumor area, identified by HE or D2-40 staining, significantly increased the HRs of tumor death in the multivariate analysis (Table 6).

Combined assessment of the presence of an LVTE and the presence of blood vessel invasion revealed that the presence of an LVTE identified by HE staining in the nontumor stroma area in IDCs that were ER or PR positive or positive for both remained significantly associated with tumor recurrence in the multivariate analysis, but that the presence of a lymph vessel invasion identified by D2-40 staining in the nontumor stroma area lost its significant association with tumor recurrence (Table 7). Histologic grade 3 and the presence of lymph node metastasis

Table 8 Multivariate analyses for tumor recurrence and death according to nodal status

Model 1: LVTEs identified by HE staining and blood vessel invasion					Model 2: LVTEs identified by D2-40 staining and blood vessel invasion				
Parameter	Cases	TRR (%)	HR (95% CI)	P	Parameter	Cases	TRR (%)	HR (95% CI)	P
Lymph node metastasis-positive cases (83 cases)									
Histologic grade					LVTEs in the intratumor area and blood vessel invasion				
1 and 2	56	18 (32)	Referent	.001	Absent	45	14 (31)	Referent	.004
3	27	20 (74)	3.1 (1.5-6.1)		Present	38	24 (63)	2.2 (1.3-3.7)	
ER and PR					Histologic grade				
Negative	34	19 (56)	Referent	.002	1 and 2	56	18 (32)	Referent	<.001
Positive	49	19 (39)	0.3 (0.2-0.7)		3	27	20 (74)	4.3 (2.2-8.4)	
Tumor size (mm)					ER and PR				
≤20	23	4 (17)	Referent	.018	Negative	34	19 (56)	Referent	.011
>20	60	34 (57)	3.7 (1.2-11.2)		Positive	49	19 (39)	0.4 (0.2-0.8)	
Fibrotic focus					Parameter				
Absent	27	8 (30)	Referent	.035	Cases	MR (%)	HR (95% CI)	P	
Present	56	30 (54)	2.4 (1.1-5.3)						
Parameter					Parameter				
Cases	MR (%)	HR (95% CI)	P	Cases	MR (%)	HR (95% CI)	P		
LVTEs in the intratumor area and blood vessel invasion					LVTEs in the intratumor area and blood vessel invasion				
Absent	50	14 (28)	Referent	.015	Absent	45	10 (22)	Referent	.001
Present	33	18 (55)	2.2 (1.2-4.2)		Present	38	22 (58)	2.5 (1.4-4.3)	
Histologic grade					Histologic grade				
1 and 2	56	14 (25)	Referent	<.001	1 and 2	56	14 (25)	Referent	<.001
3	27	18 (67)	4.0 (2.0-8.4)		3	27	18 (67)	4.6 (2.2-9.3)	
ER and PR					ER and PR				
Negative	34	18 (53)	Referent	.002	Negative	34	18 (53)	Referent	.004
Positive	49	14 (29)	0.3 (0.2-0.7)		Positive	49	14 (29)	0.3 (0.2-0.7)	

Abbreviations: TRR, tumor recurrence rate; MR, mortality rate; CI, confidence interval.

significantly increased the HRs of tumor death (data not shown).

In IDCs that were both ER and PR negative, the combined presence of a lymph vessel invasion and blood vessel invasion showed that the same tumor area of the presence of an LVTE identified by HE or D2-40 staining significantly increased the HRs of tumor recurrence or death in the multivariate analyses (Table 7).

In IDCs without nodal metastasis, the combined presence of an LVTE identified by HE or D2-40 staining and blood vessel invasion failed to significantly increase the HRs of tumor recurrence in the multivariate analyses (data not shown). The combined assessment of the presence of an LVTE identified by HE or D2-40 staining and the presence of blood vessel invasion in IDCs with nodal metastasis showed that the same tumor area of the presence of an LVTE identified by HE or D2-40 also significantly increased the HRs of tumor recurrence or death in the multivariate analyses (Table 8).

4. Discussion

The results of this study clearly demonstrated that LVTEs were actually present in the intratumor area of IDCs and that

the cumulative numbers of LVTEs identified by HE staining and D2-40 staining gradually increased from the intratumor area to the nontumor area. Indeed, LVTEs were detected by staining with D2-40 in each tumor area that were not detected by HE staining alone, for example, approximately 60% of IDC LVTEs in the intratumor area. However, the results of this study also clearly demonstrated a very high positive predictive value of LVTEs in each tumor area, especially in the intratumor area (95%), and significant correlations were observed between the numbers of LVTEs identified by HE staining and by D2-40 staining in each of the 3 areas. This strongly suggests that pathologists can fairly accurately determine whether LVTEs are present in each tumor area, if they are going to strictly determine whether any LVTEs are present in each tumor area. Furthermore, because the presence of a true LVTE by D2-40 staining can be confirmed, if pathologists find tumor nests that they suspect of being LVTEs in any of the tumor areas, especially in the intratumor area, they should perform D2-40 staining to accurately determine whether an LVTE is present.

From the standpoint of an individual case with the presence or the absence of an LVTE identified by HE staining in each tumor area, although the sensitivity values of each tumor area were not high, the positive or negative

predictive value of the presence or absence of an LVTE in each tumor area in all of the IDCs was very high. We can therefore conclude that pathologists can fairly accurately determine whether LVTEs are present in each tumor area in every patient with IDC by HE staining alone, and that was confirmed by the fact that in this study, the presence of an LVTE in any of the tumor areas had similar prognostic value, independent of the staining method used. These findings also strongly suggest that LVTEs identified by HE staining alone in each tumor area could very well be extremely important prognostic parameters for patients with IDC when all of the LVTEs cannot be identified. Because it would be difficult to routinely perform D2-40 staining of all IDCs to accurately count the LVTEs or identify an LVTE, it can be concluded that a routine method for determining whether an LVTE is present in each tumor area in each IDC would probably be adequate to accurately predict the outcome of patients with IDC, and detection of the presence of an LVTE in the intratumor area or nontumor area by HE staining is a very useful prognostic factor for patients with IDCs, independent of their ER/PR status or nodal status.

Although our approach to the assessment of LVTEs would probably enable pathologists to perform a high rate of agreement between the results of examination for the presence of LVTEs in each tumor area in HE- and D2-40-stained specimens, this study also showed very important evidence to judge whether there are LVTEs in the intratumor area in IDCs. In this study, cases with an LVTE in the intratumor area had significantly higher mean numbers of LVTEs in the advance area and in the nontumor stroma area, independent of the staining method. This strongly suggests a high probability that cases with many LVTEs in the advance area or in the nontumor stroma area have LVTEs in the intratumor area. Thus, when pathologists encounter IDCs, like an inflammatory breast cancer, with many LVTEs in the advance area or in the nontumor stroma area, they should carefully examine the intratumor area for the presence of an LVTE.

We studied the value of the combined examination of tumors for the presence of an LVTE and the presence of a blood vessel tumor embolus, because it has been reported that their presence is an important prognostic parameter for patients with IDCs [19]. However, the results of the combined examination were not better than the results of the examination for the presence of an LVTE alone in this study. Because the presence of blood vessel invasion had no predictive value for tumor recurrence or death in the multivariate analyses in this study, the results of the combined assessment of the presence of a lymph vessel invasion and the presence of a blood vessel invasion failed to add prognostic power to the results of the assessment of the presence of an LVTE alone. Thus, the results of this study clearly show that combined assessment of the presence of an LVTE and the presence of a blood vessel tumor embolus does not always provide greater prognostic power than assessment of the presence of an LVTE alone.

In contrast to the number of LVTEs, the mean D2-40 lymph vessel density values in the 3 tumor areas decreased from the nontumor area to the intratumor area, and lymph vessel density determined by D2-40 staining in the 3 tumor areas was of no significance for predicting the outcome of the patients with IDC in this study. Although it has been reported that lymph vessel density may or may not be a good prognostic parameter for patients with breast cancer [21-23] and that lymphangiogenesis may or may not occur in breast cancer tissues [24], our results clearly demonstrate no prognostic value of lymph vessel density for patients with IDC, and that lymphangiogenesis did not occur in our patients with IDC of the breast.

In conclusion, this study clearly demonstrated (1) that intratumoral LVTEs are present in IDCs, and (2) that the presence of LVTEs in the intratumor area and nontumor area has prognostic significance, independent of the stain used. Although it is somewhat difficult to determine whether intratumoral LVTEs are present by HE staining alone, to accurately assess the true malignant potential of IDCs of the breast, if pathologists find tumor nests that they suspect of being LVTEs in the intratumor area, they should examine the tumor for intratumoral LVTEs by using a combination of HE and D2-40 staining.

References

- [1] Alessandro F, Oreste G, Daniela M, et al. Tumor lymphangiogenesis in head and neck squamous cell carcinoma. *Cancer* 2004; 10:973-8.
- [2] Cursiefen C, Schlotzer SU, Kuchle M, et al. Lymphatic vessels in vascularized human corneas: immunohistochemical investigation using LYVE-1 and podoplanin. *Invest Ophthalmol Vis Sci* 2002;43: 2127-35.
- [3] Ebata N, Nodasaka Y, Sawa Y, et al. Desmoplakin as a specific marker of lymphatic vessels. *Microvasc Res* 2001;61:40-8.
- [4] Jussila L, Alitalo K. Vascular growth factors and lymphangiogenesis. *Physiol Rev* 2002;82:673-700.
- [5] Wigle JT, Oliver G. Prox1 function is required for the development of the murine lymphatic system. *Cell* 1999;98:769-78.
- [6] Kahn HJ, Bailey P, Marks A. Monoclonal antibody D2-40, a new marker of lymphatic endothelium, reacts with Kaposi's sarcoma and a subset of angiosarcomas. *Mod Pathol* 2002;15:434-40.
- [7] Giorgadze TA, Zhang PJ, Pasha T, et al. Lymphatic vessel density is significantly increased in melanoma. *J Cutan Pathol* 2004;31:672-7.
- [8] Franchi A, Gallo O, Massi D, Baroni G, Santucci M. Tumor lymphangiogenesis in head and neck squamous cell carcinoma: a morphometric study with clinical correlations. *Cancer* 2004;101:973-8.
- [9] Niakosari F, Kahn HJ, Marks A, From I. Detection of lymphatic invasion in primary melanoma with monoclonal antibody D2-40: a new selective immunohistochemical marker of lymphatic endothelium. *Arch Dermatol* 2005;141:440-4.
- [10] Fukunaga M. Expression of D2-40 in lymphatic endothelium of normal tissues and in vascular tumours. *Histopathology* 2005;46:396-402.
- [11] Evangelou E, Kyzas PA, Trikalinos TA. Comparison of the diagnostic accuracy of lymphatic endothelium markers: Bayesian approach. *Mod Pathol* 2005;18:1490-7.
- [12] Tavassoli FA, Devilee P. Invasive ductal carcinoma, not otherwise specified. Pathology and genetics of tumors of the breast and female genital organs. In: Tavassoli FA, Devilee P, editors. *The*

- World Health Organization classification of tumors. Lyon: IARC Press; 2003. p. 19-23.
- [13] Bloom HJG, Richardson WW. Histological grading and prognosis in breast cancer. *Br J Cancer* 1957;11:359-77.
- [14] Hasebe T, Mukai K, Tsuda H, Ochiai A. New prognostic histological parameter of invasive ductal carcinoma of the breast: clinicopathological significance of fibrotic focus. *Pathol Int* 2000;50:263-72.
- [15] Hasebe T, Sasaki S, Imoto S, et al. Prognostic significance of fibrotic focus in invasive ductal carcinoma of the breast: a prospective observational study. *Mod Pathol* 2002;15:502-16.
- [16] Sobin LH, Wittekind CH. TNM classification of malignant tumors. 6th ed. New York: Wiley-Liss; 2002. p. 131-41.
- [17] Truett J, Cornfield J, Kannel W. A multivariate analysis of the risk of coronary heart disease in Framingham. *J Chronic Dis* 1967;20:511-24.
- [18] Cox DR. Regression models and life-tables. *J R Stat Soc* 1972;34:187-220.
- [19] Goldhirsh A, Glick JH, Geber RD, et al. Meeting highlights: international expert consensus on the primary therapy of early breast cancer 2005. *Ann Oncol* 2005;1-15.
- [20] Kaplan EL, Meier P. Nonparametric estimation from incomplete observations. *J Am Stat Assoc* 1958;53:457-81.
- [21] Williams CS, Leek RD, Robson AM, et al. Absence of lymphangiogenesis and intratumoural lymph vessels in human metastatic breast cancer. *J Pathol* 2003;200:195-206.
- [22] Skobe M, Hawighors T, Jackson DG, et al. Induction of tumor lymphangiogenesis by VEGF-C promotes breast cancer metastasis. *Nat Med* 2001;7:192-8.
- [23] Vleugel MM, Bos R, Groep P, et al. Lack of lymphangiogenesis during breast carcinogenesis. *J Clin Pathol* 2004;57:746-51.
- [24] William WLC, Melinda ML, Diane L, et al. Angiogenic and lymphangiogenic microvessel density in breast carcinoma: correlation with clinicopathologic parameters and VEGF-family gene expression. *Mod Pathol* 2004;17:1-10.

Smaller Regional Volumes of Brain Gray and White Matter Demonstrated in Breast Cancer Survivors Exposed to Adjuvant Chemotherapy

Masatoshi Inagaki, MD, PhD¹
 Eisho Yoshikawa, MD, PhD²
 Yutaka Matsuoka, MD, PhD³
 Yuriko Sugawara, MD, PhD⁴
 Tomohito Nakano, MD⁵
 Tatsuo Akechi, MD, PhD⁶
 Noriaki Wada, MD⁷
 Shigeru Imoto, MD, PhD⁷
 Koji Murakami, MD, PhD⁸
 Yosuke Uchitomi, MD, PhD¹
 and The Breast Cancer Survivors'
 Brain MRI Database Group

¹ Psycho-Oncology Division, Research Center for Innovative Oncology, National Cancer Center Hospital East, Chiba, Japan.

² Division of Psycho-Oncology, Shizuoka Cancer Center, Shizuoka, Japan.

³ Division of Adult Mental Health, National Institute of Mental Health, National Center of Neurology and Psychiatry, Tokyo, Japan.

⁴ Department of Psychiatry and Behavioral Science, Tokai University School of Medicine, Kanagawa, Japan.

⁵ Department of Psychiatry, Kitasato Institute Hospital, Tokyo, Japan.

⁶ Department of Psychiatry and Cognitive-Behavioral Medicine, Nagoya City University Graduate School of Medical Sciences, Nagoya, Japan.

⁷ Division of Breast Surgery, National Cancer Center Hospital East, Chiba, Japan.

⁸ PET Center, Dokkyo University School of Medicine, Tochigi, Japan.

Supported in part by a third-term comprehensive control research for cancer fund from the Japanese Ministry of Health, Labor, and Welfare; supported in part by a grant from the Japan Society for the Promotion of Science; and supported in part by a grant from the Japanese Ministry of Education, Culture, Science, and Technology. The funding sources had no involvement in study design, data collection, data

BACKGROUND. Previous studies have shown cognitive impairment in breast cancer survivors who were exposed to adjuvant chemotherapy. Neural damage by chemotherapy might have played some part in these findings. The current study explored the regional brain volume difference between breast cancer survivors exposed to adjuvant chemotherapy (C+) and those unexposed (C-).

METHODS. High-resolution 1.5-tesla brain magnetic resonance imaging (MRI) databases of breast cancer survivors and healthy controls were used. Brain images were preprocessed for optimal voxel-based morphometry. Comparisons of gray matter and white matter were performed between the C+ and the C- groups, by using MRI scans from within 1 year (the 1-year study, n = 51 and n = 55, respectively) or 3 years after their cancer surgery (the 3-year study, n = 73 and n = 59, respectively). As exploratory analyses, correlation analyses were performed between indices of the Wechsler Memory Scale-Revised and regional brain volume where the volumes were significantly smaller. As a reference, MRI scans of cancer survivors were compared with those of healthy controls (n = 55 for the 1-year study and n = 37 for the 3-year study).

RESULTS. The C+ patients had smaller gray matter and white matter including prefrontal, parahippocampal, and cingulate gyrus, and precuneus in the 1-year study. However, no difference was observed in the 3-year study. The volumes of the prefrontal, parahippocampal gyrus, and precuneus were significantly correlated with indices of attention/concentration and/or visual memory. Comparisons with healthy controls did not show any significant differences.

CONCLUSIONS. Adjuvant chemotherapy might have an influence on brain structure, which may account for previously observed cognitive impairments. *Cancer* 2007;109:146-56. © 2006 American Cancer Society.

KEYWORDS: regional brain volume, magnetic resonance imaging, adjuvant chemotherapy, breast cancer, voxel-based morphometry.

analyses, or data interpretations, or in writing the report, or in the decision to submit the current study for publication.

Eisho Yoshikawa, Makoto Kobayakawa, and Maiko Fujimori are Awardees of a Research Resident Fellowship of the Foundation for Promotion of Cancer Research in Japan.

We thank Ms. Nobue Taguchi, Yuko Kojima, Yukiko Kozaki, and Ryoko Katayama for their research assistance.

The members of the Breast Cancer Survivors' Brain MRI Database Group are Makoto Kobayakawa, MD, PhD (Department of Psychiatry, Hiroshima University Hospital, Hiroshima, Japan); Nobuya Akizuki, MD,

PhD, and Maiko Fujimori, PhD (Psycho-Oncology Division, Research Center for Innovative Oncology, National Cancer Center Hospital East, Chiba, Japan); in addition to the authors listed above. All members of the group are authors of the current study and meet criteria for authorship.

Address for reprints: Yosuke Uchitomi, MD, PhD, Psycho-Oncology Division, Research Center for Innovative Oncology, National Cancer Center Hospital East, Kashiwanoha 6-5-1, Kashiwa, Chiba 277-8577 Japan; Fax: (011) 81-4-7134-7026; E-mail: yuchitom@east.ncc.go.jp

Received September 6, 2006; revision received October 4, 2006; accepted October 6, 2006.

The survival rate of breast cancer patients is increasing with the development of systemic chemotherapy. In this situation, management of long-term side effects of potentially curative breast cancer treatment is of substantial importance to optimal quality of life of breast cancer survivors. Recently, impairments of cognitive function, which is a prerequisite for functioning in daily life, have been recognized as a possible long-term adverse effect, which has been termed "chemobrain".^{1,2} Previous reviews have shown that most of these studies have consistently indicated impairments of various cognitive domains in breast cancer survivors exposed to adjuvant chemotherapy.³⁻⁶ However, the neural mechanisms have not been fully studied.

Neural impairments caused by chemotherapeutic agents as shown in animals may play a part in these mechanisms. Although chemotherapeutic agents were thought initially to have little ability to penetrate the blood-brain barrier, recent studies have indicated higher concentrations than were expected in cerebrospinal fluid and brain tissue.⁷⁻⁹ Chemotherapeutic agents are hypothesized to have neurotoxic potential through their ability to interfere with DNA and RNA synthesis and function, inhibition of microtubule formation, and/or immunosuppressive properties.^{10,11} In animals, intracerebroventricularly injected methotrexate was reported to cause learning and memory impairments and damage to the hippocampal CA4 region.¹² Injection of doxorubicin into the caudate-putamen indicated neuronal death in the ventral tegmentum and thalamus.¹³ Intraperitoneal injection of cyclophosphamide produced lesions within the cortex, thalamus, hippocampal dentate gyrus, and caudate nucleus in a dose-dependent fashion.¹⁴ In the same report, cyclophosphamide and methotrexate showed a concentration-dependent neurotoxic effect on neuronal cell cultures. Another study has demonstrated that free radicals are a possible mechanism for the toxic effect of chemotherapeutic agents.¹⁵

Recently, neuroimaging techniques have developed dramatically, thus enabling investigation of brain structure in humans. In a preliminary investigation that used structural magnetic resonance imaging (MRI), Saykin et al. reported regional brain volumes in breast and lymphoma cancer survivors who lived more than 5 years after their initial treatment.¹⁰ Results suggest that chemotherapy may be associated with reductions in regional brain volume. However, a further study is needed with a comparison group of cancer patients unexposed to chemotherapy to control for the impact of cancer diagnosis. Contrary to results of the Saykin et al. investigation,

our study showed no significant difference in regional and whole-brain volumes between breast cancer survivors exposed to adjuvant chemotherapy and those unexposed 3 years after their breast cancer surgery.¹⁶ Although a previous study indicated long-term cognitive impairment,¹⁷ by taking previous reports that show recovery of cognitive impairments over time into consideration,^{4,18-20} adverse changes in the brain structure may recover.

In the current study, we explore the regional brain volume difference between cancer survivors exposed to adjuvant chemotherapy and those unexposed in a 2-study setting (the 1-year study of <1 year after surgery and the 3-year study of >3 years after surgery). Our hypothesis was that smaller regional brain volumes would be associated with adjuvant chemotherapy. For secondary analysis, associations were examined between memory functions (as 1 of the cognitive functions) and the regional brain volume, where the volumes are significantly smaller in cancer survivors exposed to adjuvant chemotherapy.

MATERIALS AND METHODS

This study was approved by the Institutional Review Board and the Ethics Committee of the National Cancer Center of Japan and was performed after obtaining written informed consent from patients. This study was conducted by using 2 databases of brain MRI scans from breast cancer survivors. One database (Long-Term-Survivors Database) comprised brain MRI scans of patients 3 years after their breast cancer surgery.¹⁶ The other database (Follow-up Database) comprised brain MRI scans from 3-15 months after patients' breast cancer surgery and additional scans from 2 years after their first scan.

Subjects and Procedures

The 1-year study used baseline data from the Follow-up Database (Fig. 1). Subjects were recruited during follow-up visits to the Division of Breast Surgery, National Cancer Center Hospital East. We selected all patients who underwent their breast cancer surgery and who survived >3-15 months. The inclusion criteria were 1) female sex to minimize sex-based brain differences and 2) ages between 18 and 55 years. Exclusion criteria were 1) a history of cancer other than breast cancer or double cancer, 2) bilateral breast cancer, 3) clear evidence of residual or recurrent cancer, 4) current chemotherapy or radiation therapy, 5) a history of any neurological disorders, traumatic brain injury, or psychiatric disorders other than affective and anxiety disorders, 6) psychotropic

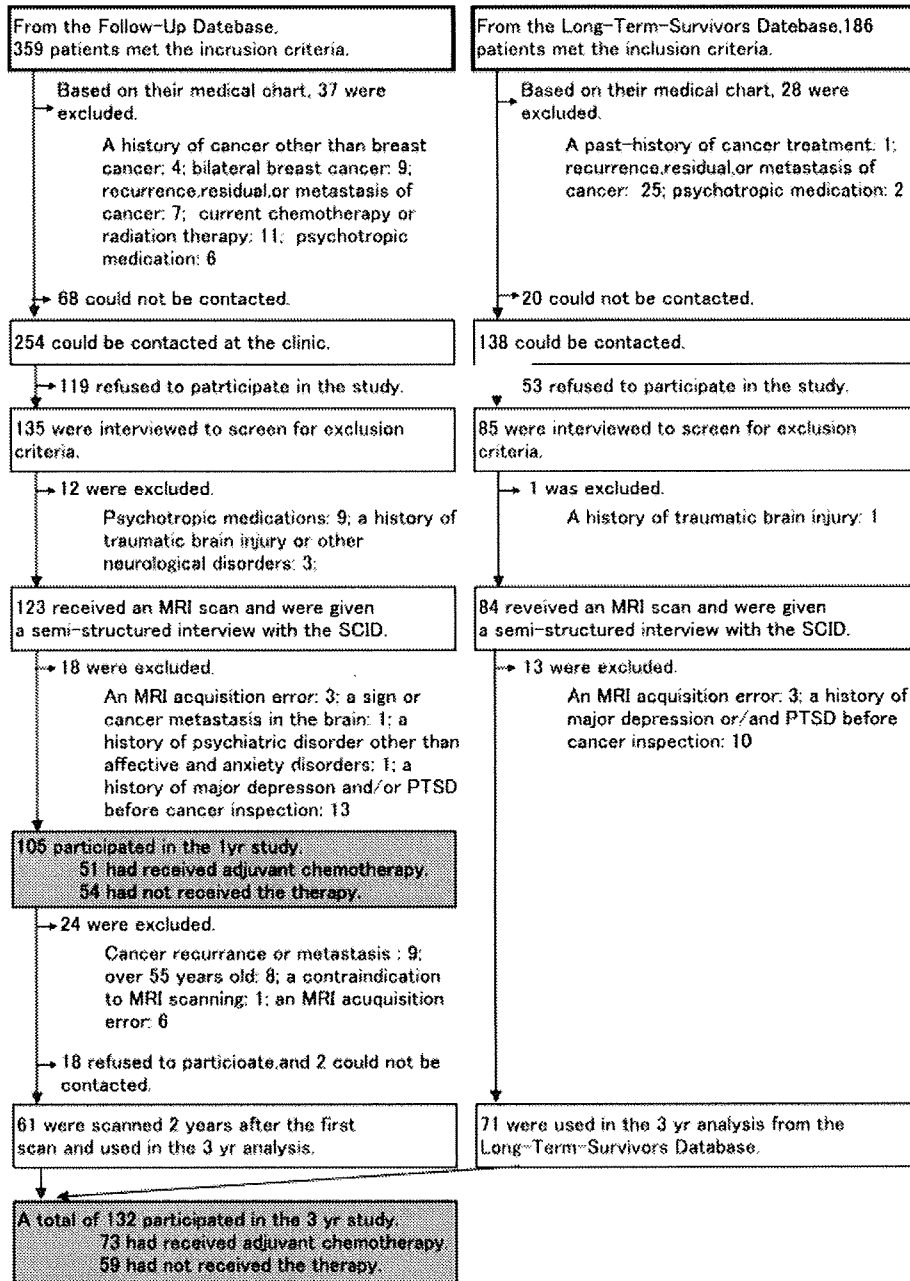


FIGURE 1. Subject sampling in the 1-year study and the 3-year study. SCID indicates the Structured Clinical Interview for DSM-IV Axis I Disorder, clinician version; MRI, magnetic resonance imaging; PTSD, post-traumatic stress disorder. In the 1-year study, the age and medical factors significantly differ between the 105 subjects and the 190 patients who did not participate because of our mistake to make contact with patients, patient refusal to participate, or MRI examination error were positive lymph node metastases found in their surgical tissue (31% versus 44%, $\chi^2 = 4.4, P = .04$), poor histological grade (27% versus 56%, $\chi^2 = 21.1, P < .01$), and receiving adjuvant chemotherapy (49% versus 62%, $\chi^2 = 5.1, P = .02$), respectively. In the 3-year study, age and medical factors that differed significantly between 132 subjects who participated in the study and 300 cancer survivors who did not participate were age (mean 44 years versus 46 years, $t = 3.7, P < .001$), presence of positive lymph node metastases (32% versus 43%, $\chi^2 = 4.9, P = .03$), poor histological grade (37% versus 49%, $\chi^2 = 4.9, P = .03$), and receiving hormonal therapy (35% versus 23%, $\chi^2 = 7.0, P = .01$), respectively.

TABLE 1
Demographic Information of Cancer Patients With and Without Adjuvant Chemotherapy, and Healthy Control Samples in the 1-Year and 3-Year Studies

Characteristics	Sample 1 (1-Year study)			Sample 2 (3-Year study)		
	Patients		Healthy controls	Patients		Healthy controls
	Adjuvant chemotherapy +	Adjuvant chemotherapy -		Adjuvant chemotherapy +	Adjuvant chemotherapy -	
	(n = 51)	(n = 54)	(n = 55)	(n = 73)	(n = 59)	(n = 37)
Age, mean ± SD, y	47.3 ± 5.2	46.3 ± 6.1	46.2 ± 6.7	48.2 ± 5.6	48.4 ± 4.8	48.0 ± 6.4
Handedness: right-handedness, no. (%)	51 (100)	51 (94.4)	51 (92.7)	73 (100)	55 (93.2)*	33 (89.2)
Height, mean ± SD, cm	155.0 ± 5.6	157.9 ± 5.8*	157.2 ± 5.0	156.4 ± 5.6	157.5 ± 6.0	156.6 ± 5.2
Weight, mean ± SD, kg	54.8 ± 6.6	56.9 ± 8.6	54.1 ± 7.9	55.1 ± 6.5	58.2 ± 8.7*	53.9 ± 8.0 [§]
Education, mean ± SD, y	13.2 ± 1.7	13.2 ± 2.0	14.1 ± 1.9 [§]	12.8 ± 1.7	13.2 ± 2.0	14.1 ± 1.7
Smoking, no. (%)	5 (9.8)	6 (11.1)	2 (3.6)	12 (16.4)	7 (11.9)	2 (5.4)
Accumulated alcohol consumption, mean ± SD, g × 10 ³	27 ± 87	39 ± 59	29 ± 59	16 ± 42	47 ± 75 [†]	38 ± 66
Postmenopausal, no. (%)	40 (78.4)	20 (37.0) [†]	16 (29.1) [§]	47 (64.4)	19 (32.2) [†]	15 (40.5)
Performance status: 0, no. (%)	30 (60.0)	43 (81.1)*	36 (97.3) [§]	67 (94.4)	57 (98.3) [†]	35 (97.2)
Clinical stage: 0-I, no. (%)	14 (27.5)	25 (46.3)*	NA	14 (19.2)	30 (50.8) [†]	NA
Lymphnode metastasis, positive, no. (%)	29 (56.9)	4 (7.4) [†]	NA	41 (56.2)	1 (1.7) [†]	NA
Histological type, no. (%)						
Carcinoma in situ	2 (3.9)	4 (7.4)	NA	1 (1.4)	4 (6.8)	NA
Invasive carcinoma	42 (82.4)	41 (75.9)	NA	61 (83.6)	49 (83.1)	NA
Special type	7 (13.7)	9 (16.7)	NA	11 (15.1)	6 (10.2)	NA
Histological grade: poor, no. (%)	21 (41.2)	7 (13.0) [†]	NA	36 (49.3)	13 (22.0) [†]	NA
Surgical type: partial mastectomy, no. (%)	25 (49.0)	32 (59.3)	NA	27 (37.0)	30 (50.8)	NA
Axillary lymphadectomy, no. (%)	42 (82.4)	28 (51.9) [†]	NA	68 (93.2)	43 (72.9) [†]	NA
Days after surgery, mean ± SD, d	345 ± 71	234 ± 103 [†]	NA	1641 ± 360	1416 ± 316	NA
Protocol of adjuvant chemotherapy, no. (%)						
AC	3 (5.9)	NA	NA	15 (20.5)	NA	NA
CMF	40 (78.4)	NA	NA	37 (50.7)	NA	NA
EC	2 (3.9)	NA	NA	1 (1.4)	NA	NA
PTX	2 (3.9)	NA	NA	1 (1.4)	NA	NA
5-FU	0 (0)	NA	NA	9 (12.3)	NA	NA
5'-DFUR	0 (0)	NA	NA	1 (1.4)	NA	NA
HCFU	0 (0)	NA	NA	2 (2.7)	NA	NA
UFT	5 (9.8)	NA	NA	7 (9.6)	NA	NA
Days after adjuvant chemotherapy, mean ± SD, d	119 ± 47	NA	NA	1189 ± 359	NA	NA
Hormonal therapy	20 (39.2)	11 (20.4)*	NA	21 (28.8)	5 (8.5) [†]	NA
Radiation therapy, no. (%)	25 (49.0)	26 (48.1)	NA	23 (31.5)	19 (32.2)	NA
WMS-R index, mean ± SD						
Attention	99.4 ± 12.5	99.5 ± 11.5	99.6 ± 13.0	98.6 ± 10.4	103.0 ± 11.1*	NA
Verbal memory	96.9 ± 13.0	101.7 ± 14.5	99.2 ± 14.4	100.4 ± 15.6	103.3 ± 14.7	NA
Visual memory	101.9 ± 12.1	102.7 ± 11.4	101.4 ± 10.3	103.7 ± 10.4	104.1 ± 12.7	NA
Delayed recall	100.3 ± 10.4	102.5 ± 12.2	100.7 ± 12.6	103.9 ± 12.6	105.5 ± 11.5	NA
History of major depression, No. (%)	6 (11.8)	2 (3.7)	NA	20 (27.4)	8 (13.6)	0 (0)
History of PTSD, No. (%)	5 (9.8)	4 (7.4)	NA	5 (6.8)	2 (3.4)	0 (0)

NA indicates not applicable; PTSD, post-traumatic stress disorder; AC, regimen with doxorubicin and cyclophosphamide; CMF, regimen with cyclophosphamide, methotrexate and fluorouracil; EC, regimen with epirubicin and cyclophosphamide; PTX, paclitaxel; 5-FU, fluorouracil; 5'-DFUR, doxifluridine; HCFU, carmofer; UFT, tegafur/uracil; WMS-R, the Wechsler Memory Scale-Revised.

* Indicates significant difference ($P < .05$) between adjuvant chemotherapy group and no-adjuvant chemotherapy group.

[†] indicates significant difference ($P < .01$) between adjuvant chemotherapy group and no-adjuvant chemotherapy group.

[§] Indicates significant difference ($P < .01$) between cancer patients group and healthy control group.

medication taken within 1 month before participation in the study, 7) a history of substance abuse or dependence, 8) a family history of early dementia, 9) any physical symptoms that interfered with daily life, 10) possible dementia defined as a score of <24 on the Mini-Mental State Examination,^{21,22} 11) a history of major depression and/or post-traumatic stress disorder (PTSD) before inspection for cancer diagnosis to exclude regional brain volume changes brought about by these disorders,²³ and 12) any contraindication to undergoing an MRI scan.

For the 3-year study, subjects were collected from the Follow-Up Database and the Long-Term-Survivor Database. From the Follow-Up Database, 105 subjects who participated in the 1-year study were asked to participate in the follow-up more than 2 years after their 1-year study.¹⁶ Figure 1 indicates a summary of the recruitment of participants to the 1-year study and to the 3-year study.

We recruited healthy subjects, who lived in the same geographic areas as the patients, by using advertisements in the local newspaper. The inclusion and exclusion criteria were the same as those for cancer patients except for the requirement of a history of breast cancer surgery. Fifty-five healthy controls participated in the 1-year study. After 2 years, 37 of 55 healthy controls participated again in the 3-year study.

Neuropsychological Measurements

The Wechsler Memory Scale-Revised Japanese version was performed. The Wechsler Memory Scale-Revised (WMS-R),²⁴ a memory function scale validated in Japanese,^{25,26} consists of indices of Attention/Concentration, Immediate Visual Memory, Immediate Verbal Memory, and Delayed Recall to estimate memory function. This scale is among the most generalized and widely used in the world.

Image Data Processing for Optimized Voxel-based Morphometry

MRI scans were conducted on a 1.5-tesla MRI unit (Signa Scanner, GE Medical Systems, Milwaukee, Wis), with 3-dimensional, spoiled gradient-recalled acquisition of 1.5-mm contiguous sections under the following conditions: field of view = 230 mm, matrix = 256 × 256 pixels, repetition time = 25 milliseconds, echo time = 5 milliseconds, and flip angle = 45°.¹⁶

The theory and algorithm of voxel-based morphometry (VBM) for Statistical Parametric Mapping 2 (SPM2) software (Wellcome Department of Cognitive Neurology, London, UK) have been well documen-

ted.²⁷ VBM was carried out by using an optimized method.²⁸ First, optimized study-specific template sets for the 1-year study and for the 3-year study comprising a T1 image and a priori gray matter, white matter, and cerebrospinal fluid images were created on the basis of brain images of participants in the 1-year study and the 3-year study, respectively. All scans were spatially normalized to customized templates, and then they were smoothed with an 8-mm, full-width half-maximum (FWHM) smoothing kernel, followed by averaging to create customized templates. Next, for the study group MRI scans, a brain extraction procedure that incorporated a segmentation step was used to remove nonbrain tissue from the MRI images.^{28,29} Extracted gray matter and white matter images were normalized to the gray matter and white matter templates.^{27,30} The normalization parameters were then reapplied to the original structural images to maximize optimal segmentation of fully normalized images, and these normalized images were segmented into gray matter/white matter and cerebrospinal fluid/noncerebrospinal fluid partitions.³¹ Segmented images were modulated by the Jacobian determinants from spatial normalization to correct for volume changes that were introduced during nonlinear spatial transformations.²⁸ Finally, images were smoothed with a 12-mm FWHM kernel.^{27,32}

Statistical Analysis

Student *t* test, Mann-Whitney *U* test, or χ^2 tests were used for comparison of background and medical factors. α levels were set at $P < .05$ (2-tailed).

By using SPM2, group differences in each of the gray matter and white matter scans were compared between the cancer patients exposed to their adjuvant chemotherapy and those unexposed, by using ANCOVA models, respectively, with age, alcohol consumption, intracranial volume, and background characteristics significantly different between these 2 groups (in the 1-year study, number of days after surgery and current hormonal therapy; in the 3-year study, handedness and current hormonal therapy) as nuisance variables. The intracranial volumes (sum of the gray matter, white matter, and cerebrospinal fluid volumes) were calculated from non-normalized segmented images during optimized-VBM preprocessing. Height and weight were not included as nuisance variables because intracranial volumes were modeled. Medical factors that seemed to be causes or results of adjuvant chemotherapy were not included as nuisance variables to avoid overmatching between the 2 groups. The groups were compared

using statistical *t*-test contrasts within SPM2. The distribution of morphological differences across each of the total gray matter or white matter was assessed initially on a voxel-by-voxel basis; clusters of over 400 voxels were used to suppress small clusters possibly arising by chance, and a threshold of $P < .001$ was used, uncorrected for multiple comparisons. Inference was centered on differences that achieved a significance of $P < .05$, after family-wise error correction for multiple comparisons.³³ In all analyses, we reported the Montreal Neurological Institute (MNI) coordinates of voxels of statistical significance.³⁴

To see the effect of cancer on the brain structure as a reference, MRI scans of cancer survivors were compared with those of healthy controls, by using ANCOVA models with age, alcohol consumption, intracranial volume, and background characteristics significantly different between these 2 groups (in the 1-year study, year of education and menopausal state; in the 3-year study, no additional covariate) as nuisance variables.

For subanalyses, we examined the correlations between indices of the WMS-R and regional brain volume of the voxel where cancer survivors exposed to adjuvant chemotherapy had a significantly smaller brain region. Regional brain volumes of the voxels were calculated by using the region of interest (ROI) function in the SPM2 software as a substitution for the regional brain volume index.

RESULTS

Table 1 shows the background and medical factors of each group in both the 1-year study and the 3-year study. Eight percent of the survivors in the 1-year study and 8% of those in the 3-year study received tegafur and uracil (UFT) for <80 days. Ten percent of survivors in the 1-year study and 7% in the 3-year study received 5 of 6 cycles of their cyclophosphamide, methotrexate, and 5-fluorouracil regimen, and others completed their regimen in the 1-year study and in the 3-year study, respectively. In other cases, quantities of each of the administered chemotherapeutic agents complied with the protocols of each regimen.

The peak voxel coordinates of the smaller regions in cancer survivors exposed to adjuvant chemotherapy compared with those unexposed using corrected $P < .05$ are presented in Table 2. Figures 2 and 3 indicate superimposed images of the statistical *t* map (regional brain volume in cancer survivors exposed to adjuvant chemotherapy less than regional brain volume in those unexposed) on the template T1 image in the 1-year study. There was no signifi-

TABLE 2
Regions of Smaller Gray Matter and Nearest Gray Matter to Smaller White Matter in Breast Cancer Survivors With Adjuvant Chemotherapy Compared With Those Without Adjuvant Chemotherapy

1-year study (3 to 15 months after breast cancer surgery)							
	Coordinates of peak difference			Side	<i>t</i> score*	Corrected <i>P</i>	Region [†]
	x	y	z				
Gray matter	30	66	8	Right	4.77	.031	Middle frontal gyrus
	10	71	4	Right	4.73	.035	Superior frontal gyrus
	13	65	-12	Right	4.66	.045	Superior frontal gyrus
	21	-40	-11	Right	4.63	.048	Parahippocampal gyrus
White matter	-11	-60	64	Left	5.38	.005	Precuneus
	35	43	30	Right	5.12	.013	Middle frontal gyrus
	-13	-33	-5	Left	4.97	.023	Parahippocampal gyrus
	10	49	-1	Right	4.95	.025	Cingulate gyrus
	-10	49	44	Left	4.93	.026	Middle frontal gyrus
3-year study (27 to 39 months after breast cancer surgery)							
Gray matter							None
White matter							None

* All scores significant ($P < .05$) after family-wise error correction for multiple comparisons over each area of gray or white matter.

† Gray matter or nearest gray matter regions were indicated.

cantly bigger region in cancer survivors exposed to adjuvant chemotherapy in the 1-year study. As an ad hoc analysis, we performed comparisons of gray matter and white matter between cancer survivors exposed to a cyclophosphamide, methotrexate, and 5-fluorouracil regimen ($n = 40$) and those unexposed to any adjuvant chemotherapy ($n = 54$). The distributions of regional brain volume difference were similar to those observed in the primary comparisons in the 1-year study (data not shown). There were no significantly smaller regions in gray matter and white matter when we used a corrected $P < .05$ in cancer survivors exposed to adjuvant chemotherapy in the 3-year study, as shown in Table 2.

In referential analyses, there were no significantly smaller or bigger regions in gray matter and white matter between cancer survivors and healthy controls in the 1-year study and in the 3-year study.

Table 3 indicates that significant correlations between memory functions and regional brain volumes

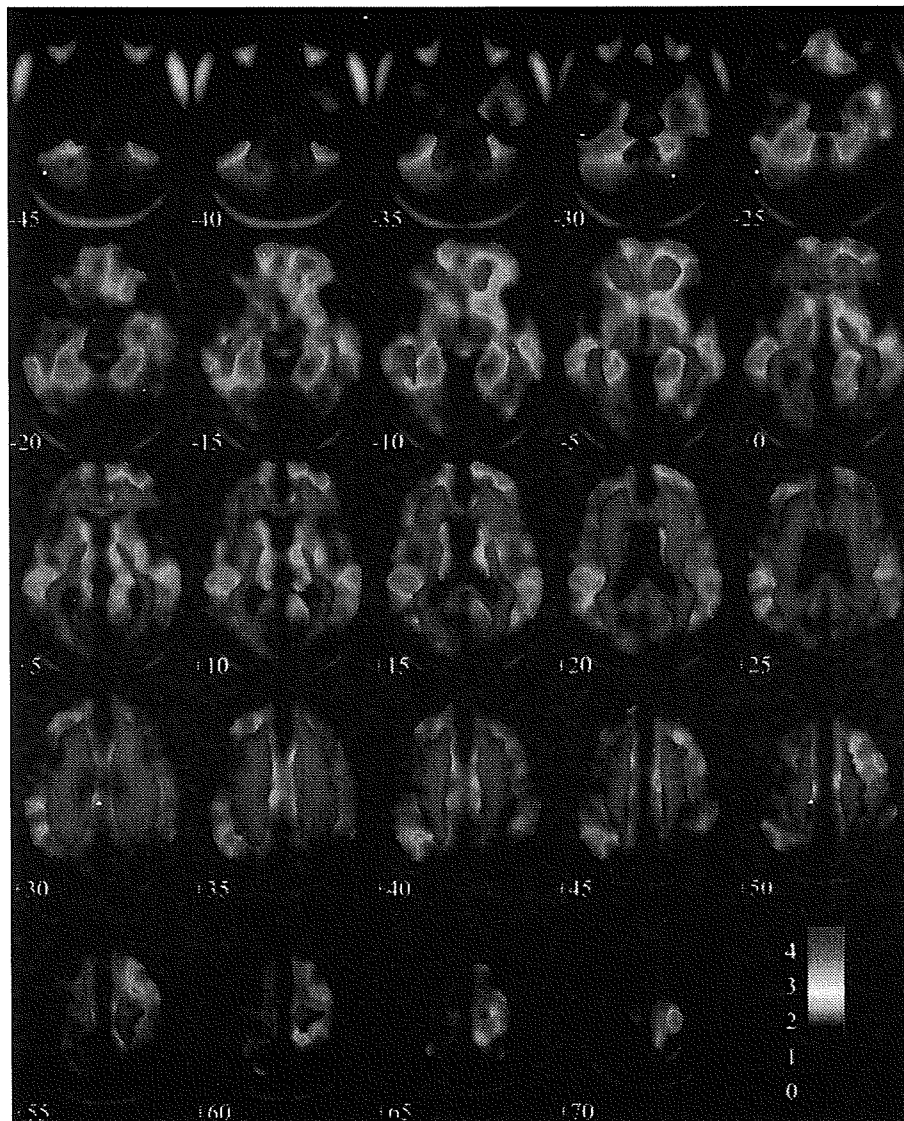


FIGURE 2. The superimposition of the *t*-value map of smaller gray matter in cancer survivors exposed to their adjuvant chemotherapy compared with those unexposed onto coronal slices of the customized T1 template image in the 1-year study. The color bar indicates the *t* value.

at the coordinates are significantly smaller in cancer survivors exposed to adjuvant chemotherapy in the 1-year study.

DISCUSSION

The current study showed smaller right prefrontal and parahippocampal gyrus in cancer survivors who were exposed to adjuvant chemotherapy before the mean of 4 months, compared with those unexposed. These volume differences were not found in cancer survivors at a mean of 4.2 years after completion of

their adjuvant chemotherapy. In subanalyses, the volumes of the right superior frontal gygearus, 1 of the smaller regions in cancer survivors exposed to adjuvant chemotherapy, were associated with memory functions. These results indicate a potential effect of adjuvant chemotherapy on brain structure, and the change of the brain structure may be associated with memory function.

A previous report using VBM in 10 breast cancer and 2 lymphoma survivors (>5 years) exposed to chemotherapy showed smaller regional gray matter and cortical and subcortical white matter brain

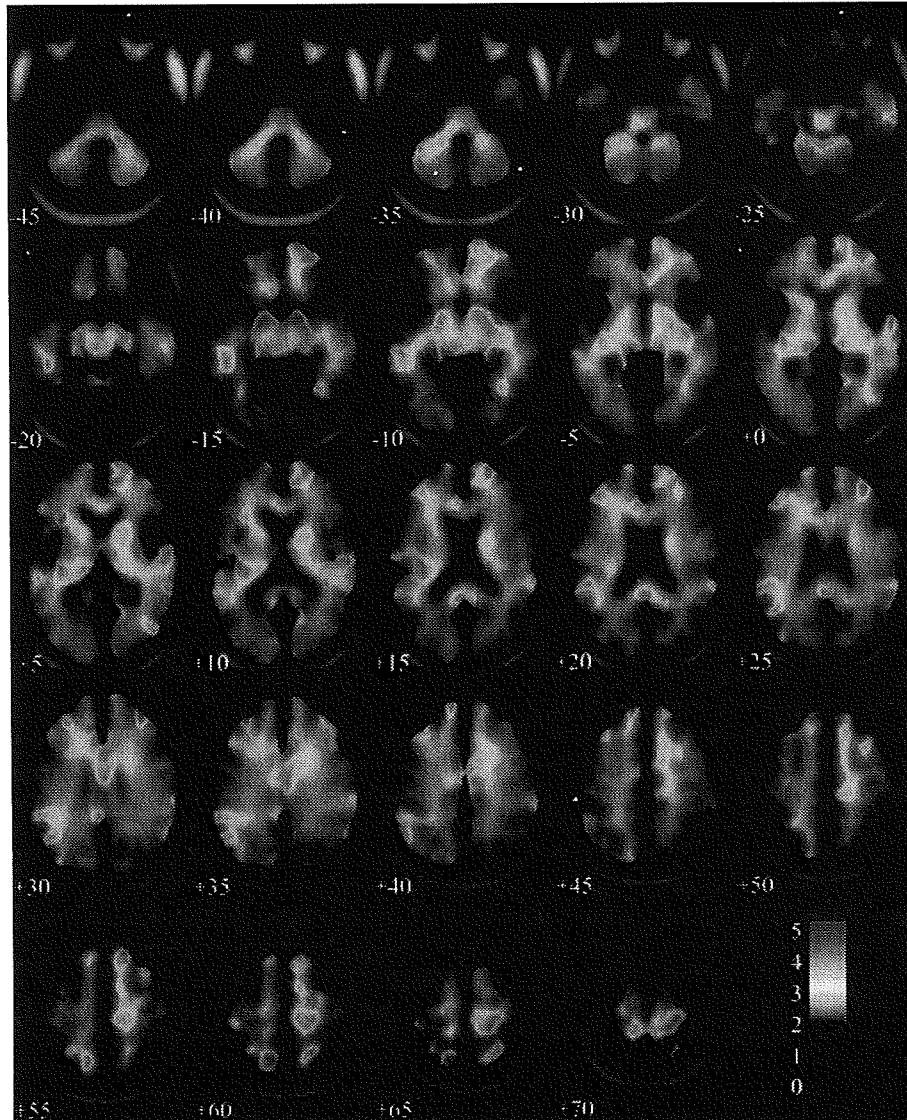


FIGURE 3. The superimposition of the t -value map of smaller white matter in cancer survivors exposed to their adjuvant chemotherapy compared with those unexposed onto coronal slices of the customized T1 template image in the 1-year study. The color bar indicates the t value.

regions compared with healthy controls.¹⁰ Chemotherapeutic agents included in the previous report were similar to those in the current study. Contrary to results of the previous report, the results of the current study did not show any significant difference in regional brain volume as shown in the 3-year study. These findings were consistent with our previous study where we used a manual tracing method, which is a different method from the VBM, to measure regional brain volume.¹⁶ That study indicated that there were no significantly smaller hippocampal

and amygdalar volumes among breast cancer survivors who had survived >3 years since their surgery. This difference in results may be caused by differences in the methods, such as number and characteristics of subjects, comparisons with cancer survivors unexposed to chemotherapy, and/or use of corrections for multiple comparisons, as in the current study.

The current study indicated regional brain volume differences in the superior and middle frontal gyri, parahippocampal gyrus, cingulate gyrus, and

TABLE 3
Correlations Between Memory Functions and the Regional Brain Volume in the 1-Year Study

	x-y-z coordinate (Region)								
	Gray matter regions				White matter regions				
	30 66 8 (mFG)	10 71 4 (sFG)	13 65 -12 (sFG)	21 -40 11 (pHG)	11 60 64 (Pc)	35 43 30 (mFG)	13 33 -5 (pHG)	10 49-1 (CG)	-10 49 44 (mFG)
WMS-R index									
Attention/concentration	0.15	0.25*	0.08	0.12	0.21*	-0.03	0.06	0.09	0.12
Visual memory	0.10	0.24*	0.12	0.20*	0.13	-0.02	0.11	0.04	0.08
Verbal memory	-0.01	0.11	0.09	0.06	0.16	0.05	0.03	0.02	0.01
Delayed recall	-0.03	0.09	-0.01	-0.01	0.13	-0.02	-0.02	-0.08	-0.08

WMS-R indicates the Wechsler Memory Scale-Revised; mFG, middle frontal gyrus; sFG, superior frontal gyrus; pHG, parahippocampal gyrus; Pc, precuneus; CG, cingulate gyrus. Data indicate *r* value of the Pearson correlation test.

* Indicates significant association ($P < .05$).

precuneus. The significantly smaller volume of the superior frontal gyrus in the current study was correlated with the attention/concentration and visual memory indices of the WMS-R. The prefrontal cortex, including superior and middle frontal gyri, has been reported to have roles in various functions including memory, planning, execution, monitoring of cognitive processing and behavior, and inhibition and change in circumstantial behavior.³⁵ Not all, but many, of the studies in cancer survivors exposed to adjuvant chemotherapy have reported impairments in various cognitive domains including attention/concentration and visual memory functions.³⁻⁶ The structural differences of the superior and middle prefrontal gyrus may partly account for some of the previously reported cognitive impairments and complaints referred to as "chemobrain". A previous positron emission tomography study of breast cancer survivors in whom the researchers had found significant neurocognitive changes associated with adjuvant chemotherapy, including impairment of verbal learning, demonstrated hypometabolism in the superior frontal gyrus. In addition to the prefrontal cortex, the parahippocampal gyrus is associated with cognitive functions, such as memory function.³⁶ Recently, the precuneus was also thought to have important roles in self-centered mental imagery strategies and episodic memory retrieval,³⁷ and these concepts lead us to suppose the potential engagement of structural changes in these brain regions in cognitive impairments caused by adjuvant chemotherapy.

The distribution of the regional brain volume differences observed in the 1-year study did not reappear in the 3-year study. Results from the 1-year and 3-year studies can lead us to speculate that the brain

volume change related to adjuvant chemotherapy may well recover over the course of time. Although a previous report showed cognitive impairments in cancer survivors even after a long period following completion of adjuvant chemotherapy,¹⁷ several longitudinal studies¹⁸⁻²⁰ and a review article⁴ have demonstrated recovery from cognitive impairment in breast cancer survivors exposed to adjuvant chemotherapy. Regional brain structural changes and cognitive impairments observed in cancer survivors exposed to adjuvant chemotherapy may recover in time.

In reference comparisons between cancer survivors and healthy controls both in the 1-year study and in the 3-year study, there were no significant differences in regional brain volume. These results support the idea that cancer had little influence on the main analyses of the current study. We did not include healthy controls in the primary comparisons. We did not make a model, such as a 2-factorial ANCOVA in which 1 factor is cancer survivors versus healthy controls and the other factor is whether chemotherapy was received or not, because of the lack of any healthy controls exposed to adjuvant chemotherapy.

The current study has several limitations. 1) Background and medical factors were entered into statistical models as nuisance variables, and medical factors usually used to judge the application of adjuvant chemotherapy and factors reported as a result of adjuvant chemotherapy were not entered to avoid overadjustment. Given potential biases, results need to be interpreted with caution. 2) Effects of each regimen or each chemotherapeutic agent on regional brain volumes were unclear. 3) Pathophysiological mechanisms of volume differences were unclear. The

other reason we did not explore effects of each chemotherapeutic agent in the study setting was that interactions between each chemotherapeutic agent may exist and may make our inference difficult. 4) The VBM has several limitations. A method with higher sensitivity, such as a manual tracing method like those reported previously,¹⁶ should be used. 5) The current study did not have any specific functional targets related to each of the detected regions. Functions related to brain regions significantly different in volume from those in the current study need to be examined by using specific neuropsychological tasks and neuroimaging of brain function.

In conclusion, the current study showed significantly smaller regional brain volumes in areas related to cognitive functions in cancer survivors who received adjuvant chemotherapy. The smaller regional brain volumes were not observed at more than 3 years after completion of adjuvant chemotherapy. Results lead to the idea that adjuvant chemotherapy could have a temporary effect on brain structure. These findings can provide new insights for future research to improve the quality of life of cancer patients who receive adjuvant chemotherapy.

REFERENCES

- Phillips KA, Bernhard J. Adjuvant breast cancer treatment and cognitive function: current knowledge and research directions. *J Natl Cancer Inst.* 2003;95:190-197.
- Wefel JS, Lenzi R, Theriault R, Buzdar AU, Cruickshank S, Meyers CA. 'Chemobrain' in breast carcinoma? A prologue. *Cancer.* 2004;101:466-475.
- Jansen CE, Miaskowski C, Dodd M, Dowling G, Kramer J. A metaanalysis of studies of the effects of cancer chemotherapy on various domains of cognitive function. *Cancer.* 2005;104:2222-2233.
- Falletti MG, Sanfilippo A, Maruff P, Weih L, Phillips KA. The nature and severity of cognitive impairment associated with adjuvant chemotherapy in women with breast cancer: a meta-analysis of the current literature. *Brain Cogn.* 2005;59:60-70.
- Anderson-Hanley C, Sherman ML, Riggs R, Agocha VB, Compas BE. Neuropsychological effects of treatments for adults with cancer: a meta-analysis and review of the literature. *J Int Neuropsychol Soc.* 2003;9:967-982.
- Matsuda T, Takayama T, Tashiro M, Nakamura Y, Ohashi Y, Shimozuma K. Mild cognitive impairment after adjuvant chemotherapy in breast cancer patients-evaluation of appropriate research design and methodology to measure symptoms. *Breast Cancer.* 2005;12:279-287.
- Tuxen MK, Hansen SW. Neurotoxicity secondary to anti-neoplastic drugs. *Cancer Treat Rev.* 1994;20:191-214.
- Troy L, McFarland K, Littman-Power S, et al. Cisplatin-based therapy: a neurological and neuropsychological review. *Psychooncology.* 2000;9:29-39.
- Choi SM, Lee SH, Yang YS, Kim BC, Kim MK, Cho KH. 5-fluorouracil-induced leukoencephalopathy in patients with breast cancer. *J Korean Med Sci.* 2001;16:328-334.
- Saykin AJ, Ahles TA, McDonald BC. Mechanisms of chemotherapy-induced cognitive disorders: neuropsychological, pathophysiological, and neuroimaging perspectives. *Semin Clin Neuropsychiatry.* 2003;8:201-216.
- Rugo HS, Ahles T. The impact of adjuvant therapy for breast cancer on cognitive function: current evidence and directions for research. *Semin Oncol.* 2003;30:749-762.
- Madhyastha S, Somayaji SN, Rao MS, Nalini K, Bairy KL. Hippocampal brain amines in methotrexate-induced learning and memory deficit. *Can J Physiol Pharmacol.* 2002;80:1076-1084.
- van der Kooy D, Zito KA, Roberts DC. Evidence on the retrograde neurotoxicity of doxorubicin. *Neurosci Lett.* 1985;53:215-219.
- Rzeski W, Pruskil S, Macke A, et al. Anticancer agents are potent neurotoxins in vitro and in vivo. *Ann Neurol.* 2004;56:351-360.
- Joshi G, Sultana R, Tangpong J, et al. Free radical mediated oxidative stress and toxic side effects in brain induced by the anti cancer drug adriamycin: insight into chemobrain. *Free Radic Res.* 2005;39:1147-1154.
- Yoshikawa E, Matsuoka Y, Inagaki M, et al. No adverse effects of adjuvant chemotherapy on hippocampal volume in Japanese breast cancer survivors. *Breast Cancer Res Treat.* 2005;92:81-84.
- Ahles TA, Saykin AJ, Furstenberg CT, et al. Neuropsychologic impact of standard-dose systemic chemotherapy in long-term survivors of breast cancer and lymphoma. *J Clin Oncol.* 2002;20:485-493.
- Fan HG, Houede-Tchen N, Yi QL, et al. Fatigue, menopausal symptoms, and cognitive function in women after adjuvant chemotherapy for breast cancer: 1- and 2-year follow-up of a prospective controlled study. *J Clin Oncol.* 2005;23:8025-8032.
- Schagen SB, Muller MJ, Boogerd W, et al. Late effects of adjuvant chemotherapy on cognitive function: a follow-up study in breast cancer patients. *Ann Oncol.* 2002;13:1387-1397.
- Wefel JS, Lenzi R, Theriault RL, Davis RN, Meyers CA. The cognitive sequelae of standard-dose adjuvant chemotherapy in women with breast carcinoma: results of a prospective, randomized, longitudinal trial. *Cancer.* 2004;100:2292-2299.
- Folstein ME, Folstein SE, McHugh PR. "Mini-mental state". A practical method for grading the cognitive state of patients for the clinician. *J Psychiatr Res.* 1975;12:189-198.
- Mori E, Mitani Y, Yamadori A. [Usefulness of a Japanese version of the Mini-Mental State in neurological patients]. (Japanese). *Shinkeishinrigaku.* 1985;1:82-90.
- Sapolsky RM. Glucocorticoids and hippocampal atrophy in neuropsychiatric disorders. *Arch Gen Psychiatry.* 2000;57:925-935.
- Wechsler D. Wechsler Memory Scale-Revised. New York: Psychological Corp; 1987.
- Sugishita M. Wechsler Memory Scale-Revised (Japanese). Tokyo: Nihonbunkagakakusya; 2001.
- Omura K, Sugishita M. Simultaneous confirmatory factor analysis of the Wechsler memory scale - revised for two standardization samples: a comparison of groups from Japan and the United States. *J Clin Exp Neuropsychol.* 2004; 26:645-652.
- Ashburner J, Friston KJ. Voxel-based morphometry-the methods. *Neuroimage.* 2000;11(6 pt 1):805-821.

28. Good CD, Johnsrude IS, Ashburner J, Henson RN, Friston KJ, Frackowiak RS. A voxel-based morphometric study of ageing in 465 normal adult human brains. *Neuroimage*. 2001;14(1 pt 1):21-36.
29. Good CD, Johnsrude I, Ashburner J, Henson RN, Friston KJ, Frackowiak RS. Cerebral asymmetry and the effects of sex and handedness on brain structure: a voxel-based morphometric analysis of 465 normal adult human brains. *Neuroimage*. 2001;14:685-700.
30. Ashburner J, Neelin P, Collins DL, Evans A, Friston K. Incorporating prior knowledge into image registration. *Neuroimage*. Nov 1997;6:344-352.
31. Ashburner J, Friston KJ. Nonlinear spatial normalization using basis functions. *Hum Brain Mapp*. 1999;7:254-266.
32. Worsley KJ, Marrett S, Neelin P, Vandal AC, Friston KJ, Evans AC. A unified statistical approach for determining significant voxels in images of cerebral activation. *Hum Brain Mapp*. 1996;4:58-73.
33. Friston KJ, Holmes A, Poline JB, Price CJ, Frith CD. Detecting activations in PET and fMRI: levels of inference and power. *Neuroimage*. Dec 1996;4(3 pt 1):223-235.
34. Brett M, Johnsrude IS, Owen AM. The problem of functional localization in the human brain. *Nat Rev Neurosci*. 2002;3:243-249.
35. Petrides M. Mapping prefrontal cortical systems for the control of cognition. In: Toga AW, Mazziotta JC, eds. *Brain mapping: the systems*. 1st ed. New York: Academic Press; 2000:159-176.
36. Witter MP, Wouterlood F. Parahippocampal region: organization and role in cognitive functions. New York and London: Oxford University Press; 2002.
37. Cavanna AE, Trimble MR. The precuneus: a review of its functional anatomy and behavioural correlates. *Brain*. 2006;129(pt 3):564-583.

症 例

2007.6.28受付

術前化学療法後のセンチネルリンパ節生検にて術中迅速
病理診断が偽陰性となった浸潤性小葉癌の1例田中仁寛*¹ 井本 滋*¹ 和田徳昭*¹ 酒村智子*¹
長谷部 孝裕*²**False-Negative Intraoperative Frozen Section Diagnosis of Sentinel Lymph Nodes in Case with Invasive Lobular Carcinoma After Neoadjuvant Chemotherapy** : Tanaka K*¹, Imoto S*¹, Wada N*¹, Sakemura N*¹ and Hasebe T*² (*¹Breast Surgery Division, National Cancer Center Hospital East, *²Surgical Pathology Section, Clinical Laboratory Division, National Cancer Center Hospital East)

The patient was a 48-year-old female who consulted our hospital complaining of left nipple deformity. Core needle biopsy demonstrated invasive lobular carcinoma and the clinical diagnosis was T2N0M0. Neoadjuvant chemotherapy was effective and partial response was confirmed. She underwent partial mastectomy and sentinel lymph node (SLN) biopsy. Because intraoperative frozen section diagnosis of SLNs was negative, axillary lymph node dissection (ALND) was not performed. However, final permanent section diagnosis demonstrated dispersed lobular carcinoma cells 4 mm in diameter in the SLN with immunohistochemical staining. Additional ALND was performed, but there was no other nodal metastasis in the axilla. Detailed pathological diagnosis should be required in a case of invasive lobular carcinoma, especially after neoadjuvant chemotherapy.

Key words : Breast cancer, Neoadjuvant chemotherapy, Invasive lobular carcinoma, Sentinel lymph node
Jpn J Breast Cancer 22 (5) : 409~412, 2007

はじめに

浸潤性小葉癌 (invasive lobular carcinoma : ILC) は、小型で特有の細胞形態や浸潤様式のために、hematoxylin and eosin (HE) 染色でのリンパ節転移診断が困難な場合がある¹⁾。センチネルリンパ節 (sentinel lymph node : SLN) への転移診断に関しても同様のことが推測される。一方、術前化学療法 (neoadjuvant chemotherapy : NAC) は現在乳癌の標準治療であるが、時にNACによる変性が加わった腫瘍とリンパ節の治療効果判定が困難な場合がある。今回、NAC施行後のILCに対するSLN生検において、HE染色での術中迅速病理診断及び永久病理診断上、リンパ節転

移の診断が困難であり、免疫組織染色にて腫瘍細胞が確認できた症例を経験したので報告する。

症 例

症 例 : 48歳, 女性。

主 訴 : 左乳頭のひきつれ。

既往歴 : 乳腺疾患の既往なし。

家族歴 : 特記すべきことなし。

現病歴 : 2005年12月, 左乳頭のひきつれを主訴に近医受診した。左乳癌が疑われ, 当院へ紹介初診となった。

初診時現症 : 左乳房ACE領域に3 cm大の境界不明瞭な腫瘍を触知した。可動性良好であり, 皮膚の変化は認めず, 腋窩リンパ節は触知しなかった。

超音波検査所見 : 左乳房ACE領域に大きさ35×22×24mmの不整形で, 辺縁は粗雑でconnec-

*1 国立がんセンター東病院乳腺科

*2 国立がんセンター東病院臨床検査部病理検査室

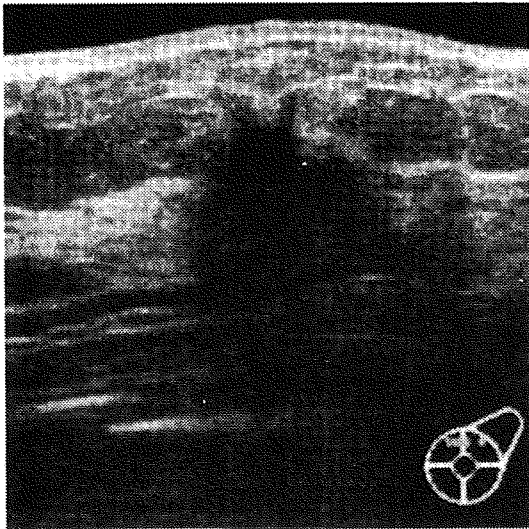


図1 超音波検査所見

左乳房ACE領域に大きさ $35 \times 22 \times 24$ mmの不整形で、辺縁は粗雑でconnective tissue signを有する低エコー腫瘤を認めた。

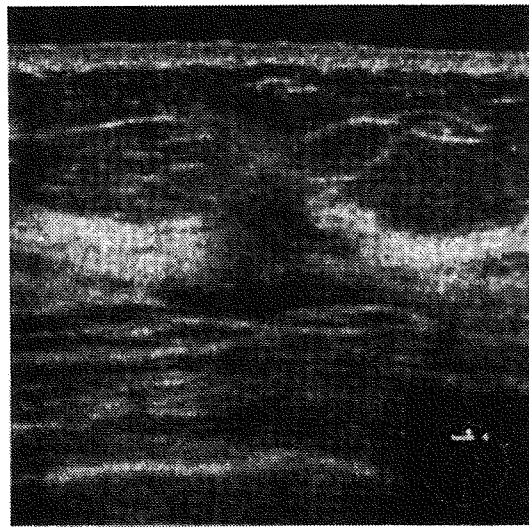


図3 超音波検査所見（化学療法後）

左乳房12時に残存する大きさ $10 \times 7 \times 8$ mmの低エコー領域を認めた。



図2 針生検組織診所見（HE染色，対物10倍）

乳腺内に小胞巣ならびに細索状に配列して浸潤増殖を示す小型の核を有する小型の腫瘍細胞を認め、ILCと考えられた。



図4 SLN1迅速病理組織所見（HE染色，対物10倍）

線維化を認め、細胞密度の上昇を認めたが、明らかな腫瘍細胞を認めなかった。

tive tissue signを有する低エコー腫瘤を認めた。腋窩リンパ節腫大、胸骨傍リンパ節腫大は認めなかった（図1）。

針生検組織診所見：乳腺内に小胞巣ならびに細索状に配列して浸潤増殖を示す小型の核を有する小型の腫瘍細胞を認め、ILCと考えられた（図2）。

以上より、T2N0M0 Stage IIAの診断にてNACを行った。Adriamycin ($60\text{mg}/\text{m}^2/3$ 週毎)、Cyclophosphamide ($600\text{mg}/\text{m}^2/3$ 週毎)を4サイクル投与後、Paclitaxel ($80\text{mg}/\text{m}^2/$ 毎週)を12サイクル投与した。

超音波検査所見（NAC後）：左乳房12時に残存する大きさ $10 \times 7 \times 8$ mmの低エコー領域を認めた（図3）。

触診上は非触知であったが、画像診断上、癌遺残ありと判断し、効果は臨床的部分奏効とした。

手術：左乳房温存手術と併用法にてSLN生検を行い、2個のSLN（SLN1，SLN2）を同定した。

SLN迅速病理組織所見：SLN1に線維化を認め、細胞密度の上昇を認めたが、明らかな腫瘍細胞を認めなかった（図4）。SLN2は脂肪組織のみで、こ

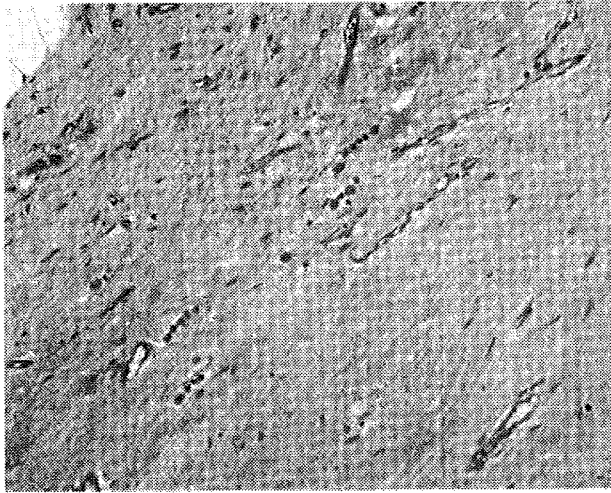


図5 切除標本病理組織所見 (HE染色, 対物10倍)
 切除乳腺内に微小塊から細索状となり浸潤する小型の腫瘍細胞ならびに孤在性に浸潤する小型の腫瘍細胞を認めた。組織異型度2で、リンパ管侵襲と静脈侵襲は認めなかった。効果判定はGrade 2であった。

の断面にはリンパ組織を認めなかった。

SLN転移陰性と診断して、腋窩リンパ節郭清を省略した。

切除標本肉眼所見：切除乳腺内に明らかな腫瘍の遺残を認めなかった。

切除標本病理組織所見：切除乳腺内に微小塊から細索状となり浸潤する小型の腫瘍細胞ならびに孤在性に浸潤する小型の腫瘍細胞を認めた。組織異型度2で、リンパ管侵襲と静脈侵襲は認めなかった。日本乳癌取扱い規約に基づく効果判定はGrade 2であった (図5)。

SLN永久病理組織所見：永久標本の新しい断面では、SLN1, 2ともに高度の線維化と少数の異型細胞を認めたため (図6a), 癌細胞も否定できず免疫組織染色を行った。

SLN免疫組織染色所見：SLN1は、4 mmの範囲内に (図6b), SLN2は、1 mmの範囲内に散在する孤立性腫瘍細胞集塊を認め、AE1/3 (+), CAM5.2 (+), 34betaE (+), CD68 (-), Vimentin (-) であり、癌細胞の転移であることを確認した。

以上から、SLN転移陽性と診断し、後日腋窩リンパ節郭清を施行したが、郭清したリンパ節26個にはHE染色並びに免疫組織染色にて癌細胞の転移は認めなかった。

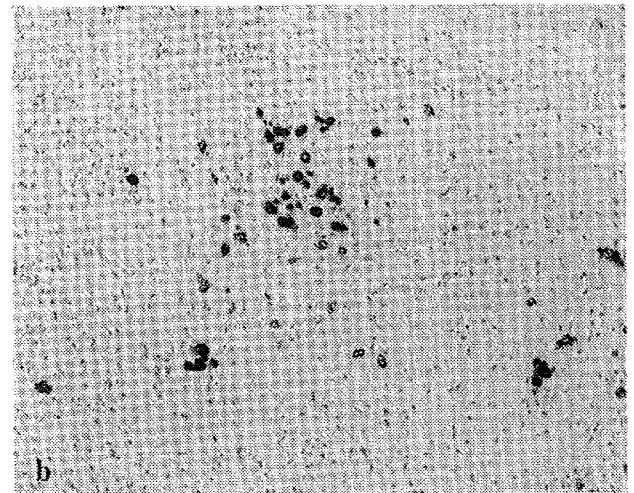
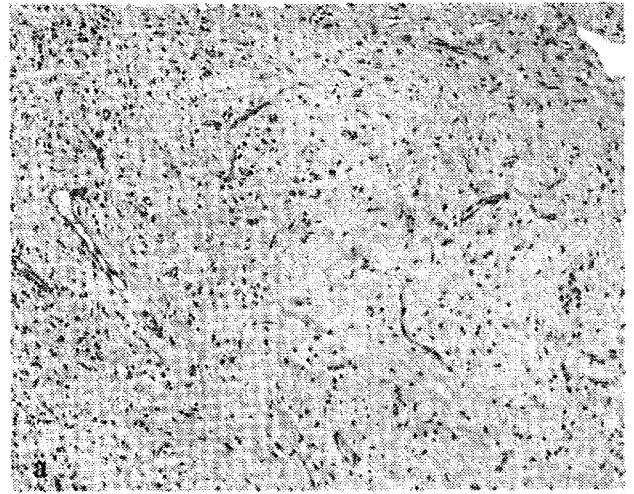

図6

- a : SLN 1 永久病理組織所見 (HE染色, 対物10倍)
 高度の線維化と少数の異型細胞を認めた。
- b : SLN 1 免疫組織染色所見 (AE1/3, 対物10倍)
 4 mmの範囲内に散在する腫瘍細胞集塊を認め、AE1/3 (+)であった。その他CAM5.2 (+), 34 betaE (+), CD68 (-), Vimentin (-) であり、癌細胞の転移であることを確認した。

考 察

今回、NAC施行後のILC症例に対するSLN生検において、HE染色での術中迅速病理診断が偽陰性となり、免疫組織染色にて腫瘍細胞が確認できた症例を経験した。NAC後ILC症例の術中迅速SLN診断が偽陰性となった理由に関して、NAC後のSLN生検の診断精度、ILC症例におけるSLN生検の妥当性と術中迅速病理診断精度の3点が考えられた。

NAC後乳癌症例に対するSLN生検の診断精度に関してさまざまな報告があるが、Xingらは21研究1273症例のMeta-analysisを施行し、同定率91

%, 感度88%, 偽陰性率12%であった。この成績は早期乳癌におけるSLN生検との比較において有意差を認めず, NAC後のSLN生検の実行可能性を支持する結果であった²⁾。

ILC症例へのSLN生検適応の妥当性に関する報告では, ILC症例35例とIDC症例208例のSLN生検を比較し, SLNの同定率はそれぞれ94.3%と93.2%, 偽陰性率は9.0%と7.6%であり, 両群間に有意差を認めていない³⁾。一方ILC症例のSLN生検に免疫組織染色を加えることで微小な転移を発見し偽陰性が減らせる可能性がある。Cserniらは189例のSLNの転移診断においてHE染色で陰性の場合, 免疫組織染色を施行し, isolated tumor cells症例の89%, micrometastases症例の63%, macrometastases症例の8%をそれぞれ同定できたと報告した⁴⁾。しかし同時に, リンパ球や組織球などの正常細胞が染色されるため偽陽性につながる危険性も指摘されている。またLeikolaらは, ILC症例のSLN診断において術中迅速時から免疫組織染色併用することで, 感度が66%から87%へ上昇したと報告している⁵⁾。

以上をまとめると, ILC症例におけるSLN生検は妥当であるが, 微小な転移巣を見落とさないように免疫組織染色の有効性が示唆された。しかし今回検索し得た限りではNAC後ILC症例のみを対象とし, SLN生検が可能かどうか多数例で検討した報告はなく, このような特殊例に対する症例の集積が待たれる。

結 語

ILC症例のNAC後のSLN生検は, NACによる腫瘍細胞の変性とILC自体のリンパ節転移診断の難しさから, 術中迅速病理診断が陰性であっても永久病理診断HE標本で悩ましい場合には免疫組織染色を併用することが推奨される。

文 献

- 1) Rosen PP: Rosen's breast pathology, 2nd edn. Lippincott Williams & Wilkins, Philadelphia, PA, 483-495, 2001
- 2) Xing Y, Foy M, Cox DD, et al: Meta-analysis of sentinel lymph node biopsy after preoperative chemotherapy in patients with breast cancer. *Br J Surg* 93: 539-546, 2006
- 3) Classe JM, Loussouarn D, Champion L, et al: Validation of axillary sentinel lymph node detection in the staging of early lobular invasive breast carcinoma: a prospective study. *Cancer* 100: 935-941, 2004
- 4) Cserni G, Bianchi S, Vezzosi V, et al: The value of cytokeratin immunohistochemistry in the evaluation of axillary sentinel lymph nodes in patients with lobular breast carcinoma. *J Clin Pathol* 59: 518-522, 2006
- 5) Leikola JP, Toivonen TS, Krogerus LA, et al: Rapid immunohistochemistry enhance the intraoperative diagnosis of sentinel lymph node metastases in invasive lobular breast carcinoma. *Cancer* 104: 14-19, 2005