


図2 八光社製ダブルバスケットカテーテル



先端部分（ダブルバスケット）の拡大

では染色体検査も行った。次に胸水の再貯留を認めない場合は定期的な経過観察を行い、再貯留を認める場合は胎児胸腔羊水腔シャント術を試みるが、シャント留置ができない場合は同時に胸腔穿刺を行った。胎児胸腔羊水腔シャント術は局所麻酔もしくは硬膜外麻酔下で八光社製のダブルバスケットカテーテルを使用し超音波ガイド下に施行した（図2、3）。

肺低形成の有無を予測する指標として胸水穿刺前後での肺面積肺拡張率を算出した（図4：肺拡張率（%）＝穿刺後肺面積（穿刺前肺面積×100）。死亡症例においては剖検にて肺低形成を確認した（28週未満は0.016以下、28週以降は0.012未満を肺低形成とした）。以上の管理方針のもとに11症例に胸腔穿刺、7症例に胎児胸腔羊水腔シャント術を施行し、診断例数、穿刺前後での肺拡張率、肺低形成の有無、胎児水腫の有無、原疾患、予後について検討した。統計解析はstudent T検定を行った。

結果

結果を表1に示す。診断例数は16週から38週（中央値29.5週）であった。原疾患の内訳は乳び胸8例、肺分画症2例、カサバツハ・スリット症候群1例。穿刺を行わず自然消失したため原因不明の1例であった。乳び胸症例のうち1例は21トリソミーであった。胎児水腫は両側胸水貯留の3症例、経過中に片側から両側胸水貯留に移行した3症例、片側性胸水貯留の1例の計7例に認めた。胎児胸水穿刺前後での両側肺拡張率は、肺低形成群で106.3 ± 3.9%（中央値：106.3%、103.5 - 109.0%）、非肺低形成群で129.3 ± 18.4%（中央値：129.0%、100.0 - 157.5%）であり、肺低形成群に拡張率が有意に低かった（ $p < 0.05$ ）（図5）。胸水が自然消失した1例を除き11例に胎児胸水穿刺を行った。穿刺後早期に分娩になった症例（症例1・9）以外では症例2のみが1回の穿刺で治療が終了した。この症例は肺分画症であり、乳び胸の8例は全例胸水の再貯留を認め、症例1は穿刺後3時間で分娩となり、出生後再貯留している。

図3 分娩直後のレントゲン（症例4：妊娠38週32S-10）

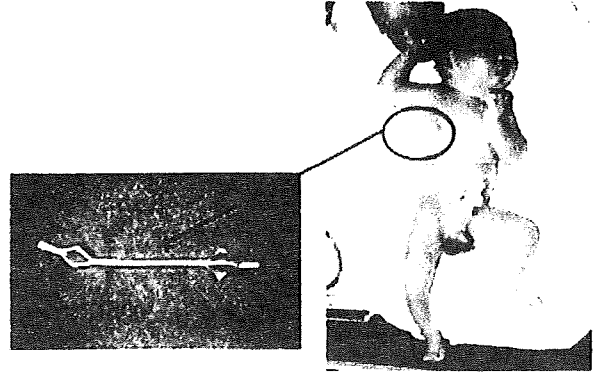
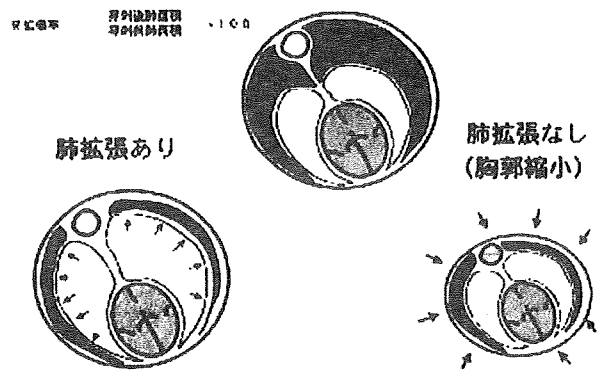


図4 胸腔穿刺前後の肺拡張率の有無



胎児胸腔羊水シャント術を施行した7例のうち2例で、シャント術後の胸水の再貯留を認めなかった。

産婦は7症例（58.3%）が生存、5症例（41.7%）が死亡した。死亡例は全症例が胎児水腫を合併しており、うち2例は肺低形成であった。胎児水腫となった7例のうち4例が新生児死亡となっている。カサバツハ・スリット症候群を合併した症例は出生時より重篤なDICを認め、生後5日に死亡した。


考察

胎児胸水の頻度は約12,000例に1例と報告されている。胎児胸水を採取し、その細胞成分でリンパ球が80%以上であれば乳び胸といわれるが、実際には胎内での胸水液はリンパ球優位でないにもかかわらず、出生後の食事摂取により乳び胸であると診断される例もあり、胎児期の診断は困難である。また胸水が自覚する前の胸水の性状で乳び胸を診断するのは不可能との報告もある。二次性胎児胸水症の原因は染色体異常、心血管疾患、感染症、貧血、胸部疾患、代謝疾患、腫瘍、胎盤もしくは胎帯の奇形など多彩である。さらに、剖検を行っても原因が不明な場合もある。胎児胸水症の診断は比較的容易であり、超音波検査で、正位された胎児肺周囲の無エコー領域や気子の偏位に伴った羊水過多などの所見として確認できる。肺

表1 結果

例	胎週 (週)	胎水 側	胸水抽出量 (mL)	肺長径 (mm) (右/左)	胎動 記録	分娩 時期	分娩 経路	分娩 時期	胎動 記録	胎動 記録	胎動 記録	胎動 記録	胎動 記録	胎動 記録
1	38	左	30	118/130		1	経産科	38週	胎動記録あり	胎動記録あり	胎動記録あり	胎動記録あり	胎動記録あり	胎動記録あり
2	31	左	7	107/65		1	経産科	31週	胎動記録あり	胎動記録あり	胎動記録あり	胎動記録あり	胎動記録あり	胎動記録あり
3	40	右	480	133/115		0	経産科	40週	胎動記録あり	胎動記録あり	胎動記録あり	胎動記録あり	胎動記録あり	胎動記録あり
4	34	右	70	133/115		1	経産科	34週	胎動記録あり	胎動記録あり	胎動記録あり	胎動記録あり	胎動記録あり	胎動記録あり
5	16	左	0	100/100		2	経産科	16週	胎動記録あり	胎動記録あり	胎動記録あり	胎動記録あり	胎動記録あり	胎動記録あり
6	25	右	45	110/105		3	経産科	25週	胎動記録あり	胎動記録あり	胎動記録あり	胎動記録あり	胎動記録あり	胎動記録あり
7	33	右・左	72	110/108		2	経産科	33週	胎動記録あり	胎動記録あり	胎動記録あり	胎動記録あり	胎動記録あり	胎動記録あり
8	31	左・両側	20	100/130		3	経産科	31週	胎動記録あり	胎動記録あり	胎動記録あり	胎動記録あり	胎動記録あり	胎動記録あり
9	29	両側	右25左30	102/90		1	経産科	29週	胎動記録あり	胎動記録あり	胎動記録あり	胎動記録あり	胎動記録あり	胎動記録あり
10	27	左側	24	95/100		1	経産科	27週	胎動記録あり	胎動記録あり	胎動記録あり	胎動記録あり	胎動記録あり	胎動記録あり
11	29	両側	78	111/181		1	経産科	29週	胎動記録あり	胎動記録あり	胎動記録あり	胎動記録あり	胎動記録あり	胎動記録あり
12	30	両側	10	100/110		1	経産科	30週	胎動記録あり	胎動記録あり	胎動記録あり	胎動記録あり	胎動記録あり	胎動記録あり

図5 胎動張率



胎動張率は自然消失することもあるが、多くは胎内もしくは娩出後に治療が必要になってくる。特に妊娠28週以前の症例において、多量の胸水が持続すれば肺を圧迫し、胎児の肺形成のリスクが増す。肺低形成を合併すれば予後はきわめて不良となる。出生前における肺低形成の診断は超音波検査を用いたさまざまな計測法のほか、MRIによる診断等があるが、すべて確立された診断方法とはいえない。我々は、胸水穿刺前後の肺断面長の拡張率を簡便な肺低形成の有無を予

測する方法の一つとして独自に使用している。自験例で肺低形成となった症例では、胸水穿刺前後での両側肺拡張率が、103.5%および109.0%と、非肺低形成例の129.3% (標準偏差18.4%) と比較して有意に低かった。計測の誤差等を考慮し、cut off値を110%未満に設定した場合、今回の11症例での検討では肺低形成に対して、sensitivity 100%、specificity 88.9%、positive predictive value 66.7%、negative predictive value 100%であり、肺低形成の予測としては簡便で有用な検査法と考えられた。肺低形成の有無を事前に予想することは、新生児治療、両親への対応にも大きく寄与するものと考えられる。

また今回我々が経験した症例の中で、右肺134%、左肺181% (両側157.5%) と肺拡張率が高いにもかかわらず新生児死亡した症例が存在した。この症例は死亡後の剖検でも肺低形成は認められていない。急速な胸水の貯留とこれに続く胎児水腫を認め、循環不全による死亡と考えられ、肺低形成以外でも予後不良因子は存在すると考えられた。Langakerらによれば、片側性の胎児胸水は縦隔偏位のような緊張性の徴候を伴わなければ100%の生存率で、両側性の胎児胸水症の生存率は52%との報告を行っている。実際我々の症例でも胎児胸水症全体では66%の生存率だが、このうち片側性の胎児胸水は胎児治療の有無にかかわらず100%の生存率であるのに対し、両側性の胎児胸水症は33%と低い生存率であった。この結果から、両側性の胎児胸水は肺低形成も生じやすく、さらに胎児水腫に移行しやすいことが考えられた。胸水貯留に伴い、循環血液量の低下、心拍出量の低下、血圧の低下が起こると、さらに虚脱した心臓や縦隔の圧迫による静脈系の閉鎖は進行し、子宮内胎児死亡にもつながると推

表2 シヤントトラブルの一覧

症例	シヤントによる合併症	対応
5	前期破水	自然閉鎖(妊娠継続)
10	子宮内内・脱着	Xpにて皮下挿入・娩後後に抜去
11	胎児胸腔内へ脱落	剖検時抽出

測される。妊娠32週以降であれば肺底形成の発症も考えにくい。胎児の未熟性が治療に占める割合も低くなってくるので、娩出して体外治療を開始することも十分に考えられる。しかし未熟性を考慮しなければならぬ週数の胎児で、まだ肺底形成を発症していない症例に対しては、胸水穿刺やシヤント術を行うことは胎児水腫への移行を遅延させたり、肺底形成を予防することによって予後を改善するのに効果的な治療の一つだと我々は考えている。シヤント術のメリットとしては、1) 胸水の軽減、もしくは消失、2) 妊娠期間の延長、3) 肺底形成の予防、4) 穿刺回数の減少があげられる。デメリットとしては1) 前期破水のリスクが高くなること(穿刺針が比較的太いため)、2) シヤントトラブル、3) 比較的習熟した技術が必要であること、4) シヤント後胎児低タンパク血症による胎児水腫の進行などがあげられる。我々がシヤント術を行った群では診断から分娩までの期間は平均4.5週間(1-22週)だった。シヤントトラブルについては表2に示したが、症例10では子宮内に脱落し分娩後に抜去した。症例11では胎児胸腔内に脱落したが、新生児死亡となったため剖検時に抽出した。症例5では17週で高位破水を認めたと、2週間の自然経過で羊水流出が止まったため38週まで妊娠を継続し、自然経産分娩となっている。胎児治療を行うには、これらのメリット(治療効果)とデメリット(合併症)に関して、十分なインフォームドコンセントを行うことが必要である。胎児胸水腫においては他の胎児疾患と同様に早期発見、早期治療が予後を改善する上で非常に重要である。症例7や9のように診断・治療の開始が遅れることで胎児水腫に移行し、出生後の治療に非常に苦慮する症例も経験した。胎児に対してのinterventionは、安易に行える治療ではないが、症例に応じてこれらの治療を積極的に考慮することも必要であろう。

特に胎児胸水症例においては肺底形成の予防および胎児水腫の予防に関して効果が期待できる可能性があると考えられた。また、シヤントだけでなく胎児胸腔

内にOK-432を注入する胸膜癒着術なども注目され、今後の比較検討が望まれる。

文 献

- 1) Storie NJ, et al. Thoracoamniotic shunting for fetal pleural effusions. Current Perspectives on the fetus as a Patient. New York: Parthenon Publishing Group, Inc. 1996; 317-20
- 2) Enid G. Potter's Pathology of the Fetus, Infant and Child Second Edition
- 3) Longaker MT, et al. Primary fetal hydrothorax: Natural history and management. J Pediatr Surg 1980; 24: 573-6
- 4) Charles H Rodeck, Nichols M Fisk, David I Fraser, Umberto Nicolini. Long-term in utero drainage of fetal hydrothorax. N Eng J Med 1988; 319: 1135
- 5) Chernick V, Reed MH. Pneumo- and chylothorax in the neonatal period. J Pediatr 1970; 76: 264-9
- 6) Foote KD, Vickers DW. Congenital pleural effusion in Down's syndrome. Br J Radiol 1986; 59: 609-13
- 7) Gardner TW, Domin AC, Brock GE, et al. Congenital pulmonary lymphangiectasis: a case complicated by chylothorax. Clin Pediatr 1983; 22: 75-81
- 8) Grenou-Ausotegui J, Rey-Otero A, Alliser-Andrade J. Quilothorax espontaneo neonatal: a proposito de cinco observaciones. Ann Esp Pediatr 1984; 20: 49-53
- 9) Nicolaides KH, Azar GB. Thoraco-amniotic shunting. Fetal Diagn Ther 1990; 5: 153-64
- 10) Petres RE, Redwine FO, Crunkshank DP. Congenital bilateral chylothorax: antepartum diagnosis and successful intrauterine surgical management. JAMA 1982; 248: 1360-2
- 11) Van Gerde J, Campbell AN, Symth JA, et al. Spontaneous chylothorax in new borns. Am J Dis Child 1984; 138: 961-7
- 12) Keeping JW, Gough DJ, Hitt PJ. The pathology of nonbubous hydrops. Diagn Histopathol 1983; 6: 89-111
- 13) Nicolaides KH, Rodeck CH, Lange J, et al. Fetoscopy in the assessment of unexplained fetal hydrops. Br J Obstet Gynecol 1985; 92: 671-9
- 14) 桑島成子. 先天性横膈膜ヘルニアにおける胎児肺底形成の評価—肺のMRI信号強度. NIPPON ACTA RADIOLOGICA 2005; 65: 105-8
- 15) Longaker MT, Laberge JM, Dansereau J, Langer JC, Crombleholme TM, Callen PW, Golbus MS, Harrison MR. Primary fetal hydrothorax: natural history and management. J Pediatr Surg 1980; 24: 573-6
- 16) Tamamura M, Nishikawa N, Kojima K, et al. A case of successful fetal therapy for congenital chylothorax by intrapleural injection of OK-432. Ultrasound in Obstetrics and Gynecology 2000; 18: 371-5

Clinical Analysis of 12 fetal pleural effusions

Toshiko Ueda, Takeshi Murakoshi, Masahiro Nunata, Kaori Tubokura, Minako Matsumoto,
Hiroshi Adachi, Shinichi Shibuya, Hiroo Naruse, Yuichi Tsurii and Masayo Ueda

Division of Perinatology, Maternal and Perinatal Care Center, Seirei Hamamatsu General Hospital

We investigated treatment outcomes of 12 fetal hydrop cases which received perinatal period management in our institution (including aspiration of fetal pleural fluid and Thoraco amniotic shunting). The mean number of diagnosed weeks was 29.5 (ranging 16 to 38 weeks). The primary diseases were chylothorax (8 cases), pulmonary sequestration (2 cases), Kasabach-Merritt syndrome (1 case), and unknown cause (1 case). Except for one case of natural elimination of the pleural fluid, 11 of the 12 cases underwent aspiration of pleural fluid, and 9 of the cases, which had re-retention of the fluid, underwent Thoraco-amniotic shunting. Due to the fetal treatment, prolongation of the gestation period (mean 4.5 weeks) was achieved. Among them, 7 cases (58.3%) survived, whereas 5 cases (41.7%) died. In two of the death cases, lung hypoplasia presented. Bilateral enlargement of the lungs in the lung hypoplasia cases was seen (106.3 ± 3.9% ; median : 106.3%, 103.5-109.0%), and in the non hypoplasia of lung cases (129.3 ± 18.4% ; median : 129.0%, 100.0-157.5%), showing a significantly low enlargement ratio before and after the aspiration in the hypoplasia of lung cases ($p = 0.011$). In fetal pleural fluid cases, prognosis was bad when bilateral pleural fluids and fetal hydrops were present, or hypoplasia of lung was present. Some cases showed improvement of prognosis owing to fetal pleural fluid aspiration and Thoraco amniotic shunting, suggesting that fetal treatment should be case-dependent. When the bilateral lung enlargement ratio is low in cases of fetal pleural fluid, it is possible to predict the occurrence of lung hypoplasia, thus we consider it an important index for future cases.

Validation of Quintero stage III sub-classification for twin–twin transfusion syndrome based on visibility of donor bladder: characteristic differences in pathophysiology and prognosis

T. MURAKOSHI*, K. ISHII*†, M. NAKATA‡, H. SAGO§, S. HAYASHI§, Y. TAKAHASHI¶, J. MUROTSUKI***, M. MATSUSHITA*, T. SHINNO*, H. NARUSE*, Y. TORII* and The Japan Fetoscopy Group

*Division of Perinatology, Fetal Diagnosis and Therapy, Maternal and Perinatal Care Center, Seirei Hamamatsu General Hospital, Hamamatsu, †Department of Obstetrics and Gynecology, Niigata University Graduate School of Medical and Dental Science, Niigata, ‡Perinatal Care Center, Yamaguchi University Hospital, Ube, §Division of Fetal Medicine, National Center for Child Health and Development, Tokyo, ¶Department of Fetal-Maternal Medicine, Nagara Medical Center, Gifu, Japan and ***The Japan Fetoscopy Group

KEYWORDS: arterioarterial anastomosis; Doppler; fetal therapy; Quintero staging system; TTTS; twin–twin transfusion syndrome

ABSTRACT

Objective To validate the Quintero stage III subclassification for twin–twin transfusion syndrome (TTTS) based on visibility of the bladder of the donor twin.

Methods Between July 2002 and August 2006, there were 131 pregnant Japanese women affected by severe TTTS before 26 weeks' gestation, treated with fetoscopic laser surgery at five centers in Japan, whose pregnancies continued beyond 22 weeks. Outcome data were available in all cases and surviving infants were followed up for at least 6 years. This study focused on the Stage III TTTS patients. These were subclassified into Stage III atypical (abnormal Doppler flow with visible donor bladder) and Stage III classical (abnormal Doppler flow with non-visible donor bladder) groups. Perioperative data and postnatal outcomes were compared between the groups.

Results Seven Stage I, 22 Stage II, 82 Stage III and 20 Stage IV pregnancies continued beyond 22 weeks. There was a significantly higher incidence of absent or reversed end-diastolic velocity in the umbilical artery (UA-AREDV) of the donor in Stage III atypical than in Stage III classical patients (83.8% vs. 53.3%, $P = 0.004$). Stage III atypical cases also had a significantly higher incidence of arterioarterial (AA) anastomoses (72.9% vs. 17.8%, $P < 0.001$) and intrauterine fetal demise (IUID) of the donor (43.2% vs. 13.3%, $P = 0.002$). However, there were no differences in overall survival or in abnormal brain scans of surviving infants. Donors with both UA-AREDV and AA anastomoses had a significantly higher incidence of IUID compared with the others (53.3%, $P < 0.001$).

Conclusions Quintero stage III atypical was characterized by a high incidence of AA anastomoses and UA-AREDV of the donor, resulting in IUID. Subclassification of Stage III based on visibility of the bladder of the donor twin was adequate for and compatible with differentiating prognosis and pathophysiology. Copyright © 2008 ISUOG. Published by John Wiley & Sons, Ltd.

INTRODUCTION

Twin–twin transfusion syndrome (TTTS) affects 10–15% of monochorionic twin pregnancies, and cases left untreated are associated with high perinatal morbidity and mortality^{1,2}. The anatomical basis for this syndrome is unequal blood distribution between twins and the recent advent of fetoscopic laser ablation of placental anastomoses has proved very useful in its treatment. With its significantly higher perinatal survival rate compared with amnioreduction and the reduced risk of neurological complications in surviving children^{3–6}, fetoscopic laser surgery for severe TTTS has evolved as the best therapeutic option.

The concept of staging a disease was developed to help describe and compare prognoses. Quintero's staging system⁷ for TTTS is simple and useful for describing the severity of the syndrome; however, while Stages I, II and IV correspond well to perinatal outcome after laser surgery^{4–6}, there is a considerable range of potential outcomes associated with Stage III. Stages I and II focus on the renal function of the donor, with visibility of the donor bladder reflecting donor morbidity, and Stage IV

Correspondence to: Dr T. Murakoshi, Division of Perinatology, Fetal Diagnosis and Therapy, Maternal and Perinatal Care Center, Seirei Hamamatsu General Hospital, 1-12-12 Sumiyoshi, Hamamatsu City 430-8558, Japan (e-mail: t-murakoshi@sis.seirei.or.jp)

Accepted: 21 April 2008

reflects morbidity in hydropic affected fetuses, usually recipients, while Stage III is associated with critically abnormal Doppler findings in either or both twins. Although Quintero *et al.*⁷ originally subclassified Stage III into two substages based on visibility of the donor bladder, they did not discuss the prognosis for these substages⁷.

The aim of this study, therefore, was to validate the Quintero stage III subclassification based on whether the donor bladder is visible and to investigate the clinical characteristics and perinatal outcomes of the two subgroups.

METHODS

Between July 2002 and August 2006, 138 pregnant Japanese women affected by severe TTTS before 26 weeks' gestation were treated with fetoscopic laser surgery at five centers in Japan. Seven (5.1%) cases resulted in miscarriage (< 22 weeks) and were excluded. Outcome data were available in all cases and surviving infants were followed up for at least 6 months by the Japan Fetoscopy Group, established in 2002 to record follow-up data of TTTS patients treated by laser surgery. TTTS was diagnosed based on standard criteria: monochorionic twin pregnancy with discordant amniotic fluid volume, the deepest vertical pocket measuring at least 8.0 cm in the recipient twin and at most 2.0 cm in the donor twin. All patients met the following criteria for laser surgery⁷: (1) gestational age < 26 weeks and (2) TTTS classified as being Quintero stage I–IV. All participating institutions followed the same clinical protocol for laser surgery of placental communicating vessels, based on a published method⁸. Briefly, after adequate anesthesia (including general, regional and local as appropriate for the patient) was achieved in the mother, a 3.8-mm trocar was inserted into the recipient's amniotic sac. All communicating vessels, including arteriovenous (AV), arterioarterial (AA) and venovenous (VV) anastomoses were ablated by Nd:YAG (neodymium:yttrium-aluminum-garnet) laser under fetoscopic guidance. After intensive counseling, all patients provided written consent to undergo surgery and to participate in the study, which was approved by the ethics committee of each institution.

The current study focused on the 82 Quintero stage III patients whose pregnancies continued beyond 22 weeks. Quintero stage III was classified into two substages on the basis of whether the donor bladder was visible on ultrasound^{7,9}: Stage III 'atypical' was defined as abnormal Doppler flow in either twin and visible donor bladder ($n = 37$) and Stage III 'classical' was defined as abnormal Doppler flow in either twin without visible donor bladder ($n = 45$). Perioperative data, including gestational age at laser surgery, operation time, placental location, characteristics of anastomoses and Doppler findings were noted.

Principal outcome measures were intrauterine fetal demise (IUFD), neonatal survival rate (number of fetuses

surviving 6 months postnatally/total number of fetuses), survival rate per pregnancy (two survivors, one survivor, no survivors) and abnormal findings on brain scan (e.g. Grade III or IV intraventricular hemorrhage or periventricular leukomalacia). Brain ultrasonography was performed in all infants routinely and magnetic resonance imaging was performed when ultrasound suggested an abnormality or when the delivery was very premature. The perioperative data and outcomes were compared between Stage III atypical and Stage III classical subgroups.

Statistical analysis

The chi-square test or Fisher's exact test was used as appropriate for comparison of categorical variables. Continuous variables were examined for normality, and expressed as mean \pm SD or median (range). Student's *t*-test or the Mann–Whitney *U*-test were used as appropriate. $P < 0.05$ was considered statistically significant. All statistical analyses were performed using JMP software (JMP 5.1.2 for Macintosh; SAS Institute, Cary, NC, USA).

RESULTS

Of the 131 TTTS cases treated with laser surgery and delivered (either live or stillborn following IUFD) after 22 weeks' gestation, surviving infants being followed up for at least 6 months, seven were Quintero stage I, 22 were Stage II, 82 were Stage III and 20 were Stage IV. The overall survival rate of infants was 78.2%. Abnormal brain scans were observed in 4.4% of the live infants (3.4% of all fetuses).

Table 1 compares the perioperative clinical characteristics between Quintero stage III atypical and classical cases. The two groups did not differ with respect to gestational age at laser surgery, operation time or placental location. Stage III atypical donors had significantly more amniotic fluid (1.3 cm vs. 0.4 cm), and were more likely to have absent or reversed end-diastolic velocity in the umbilical artery (UA-AREDV) (83.8% vs. 53.3%) and AA anastomoses (72.9% vs. 17.8%) compared with Stage III classical donors.

Perinatal outcomes corresponding to Quintero Stage III subgroup are summarized in Table 2. There were no significant differences between groups in terms of gestational age at delivery and birth weight of donor or recipient. The survival of donors at 6 months was significantly lower in Stage III atypical than in Stage III classical cases (54.1% vs. 77.8%), while there was no such difference in recipients. The rate of IUFD in donors was also significantly greater in Stage III atypical than in Stage III classical cases (43.2% vs. 13.3%), while there was no such difference in recipients or in both twins combined. In particular, the rate of IUFD in donors with UA-AREDV was significantly higher in Stage III atypical compared with Stage III classical cases (51.6% vs. 20.8%). The incidence of abnormal brain scan findings in surviving infants was no different (3.8% vs. 2.8%) between Stage III atypical and Stage III classical cases.

Table 1 Comparison of clinical characteristics, incidence of vascular anastomoses and preoperative Doppler findings in 82 pregnancies with Quintero stage III twin-twin transfusion syndrome, between atypical and classical subgroups⁷

Characteristic	Stage III atypical (n = 37)	Stage III classical (n = 45)	P
GA at laser surgery (weeks)	21.7 ± 2.5	21.0 ± 2.5	0.21
Operation time (min)	87.1 ± 48.5	73.9 ± 28.9	0.15
Anterior placenta	20 (54.1)	22 (48.9)	0.64
MVP			
Donor (cm)	1.3 (0–2.0)	0.4 (0–2.0)	<0.01
Recipient (cm)	9.8 (8.0–12.4)	10.0 (8.0–16.5)	0.24
FFW			
Donor (g)	313 ± 182	261 ± 168	0.18
Donor (Z-score*)	-2.3 ± 0.9	-2.3 ± 1.1	0.71
Recipient (g)	489 ± 240	403 ± 223	0.10
Recipient (Z-score*)	0.2 ± 0.9	-0.2 ± 0.9	0.09
Weight discordance (%)†	37.3 ± 12.5	35.4 ± 16.0	0.66
Anastomoses			
AA	27 (72.9)	8 (17.8)	<0.01
VV	6 (16.2)	4 (8.9)	0.31
AV	37 (100)	45 (100)	—
Abnormal Doppler flow in donor	31 (83.8)	27 (60.0)	0.02
UA-AREDV	31 (83.8)	24 (53.3)	0.004
UV pulsation	3 (8.1)	7 (15.6)	0.31
DV reversed flow	0 (0)	2 (4.4)	0.19
Abnormal Doppler flow in recipient	14 (37.8)	38 (84.4)	<0.01
UA-AREDV	1 (2.7)	3 (6.7)	0.41
UV pulsation	13 (35.1)	33 (73.3)	<0.01
DV reversed flow	2 (5.4)	22 (48.9)	<0.01
Presence of AA anastomoses			
With UA-AREDV of donor	24 (64.9)	6 (13.3)	<0.01
Without UA-AREDV of donor	3 (8.1)	2 (4.4)	0.49
Absence of AA anastomoses			
With UA-AREDV of donor	7 (18.9)	18 (40.0)	0.04
Without UA-AREDV of donor	3 (8.1)	19 (42.2)	<0.01

Data are shown as mean ± SD, median (range), or n (%). Stage III defined as abnormal Doppler flow in either twin, 'atypical' subgroup having visible donor bladder and 'classical' subgroup being without visible donor bladder⁷. *Z-scores were calculated with reference to the Japanese standard singleton growth formula (Japan Society of Ultrasonics in Medicine). †Weight discordance = (estimated fetal weight of recipient - estimated fetal weight of donor)/estimated fetal weight of recipient. AA, arterioarterial; AREDV, absent or reversed end-diastolic velocity; AV, arteriovenous; DV, ductus venosus; FFW, estimated fetal weight; GA, gestational age; MVP, maximum vertical pocket; UA, umbilical artery; UV, umbilical vein; VV, venovenous.

Table 3 focuses on donor IUFD rates, divided into different subgroups with respect to donor UA-AREDV and AA anastomoses. There was a significantly higher incidence of IUFD in donors with UA-AREDV in Stage III atypical than in Stage III classical cases (52% vs. 21%). Donors with both UA-AREDV and AA anastomoses had a significantly higher incidence of IUFD compared with the others (53.3%, $P < 0.001$), although showed no difference between Stage III atypical and classical subgroups (54% vs. 50%). In addition, UA-AREDV of donors and presence of AA anastomoses were associated in all Stage III patients ($P < 0.001$), and 64.9% of Stage III atypical cases were characterized by the presence of both UA-AREDV of the donor and AA anastomoses (Table 1).

DISCUSSION

The Quintero stage III atypical subgroup was characterized by a high incidence of AA anastomoses, UA-AREDV of the donor and IUFD of the donor, whereas the Stage III classical subgroup was characterized by a lower

incidence of AA anastomoses, abnormal Doppler flow in the recipient, and a similar incidence of IUFD between the donor and the recipient.

The incidence of AA anastomoses in TTTS is generally considered to be lower (19–31%) than it is in uncomplicated monochorionic diamniotic twins (73–89%)^{9–13}. However, similar to another study⁹, we found the incidence of AA anastomoses to be 73% in the Stage III atypical subgroup, while in our Stage III classical subgroup it was 18%. Quintero Stage III atypical was defined as abnormal Doppler findings with visible donor bladder. Although the reasons for the donor bladder being visible in Stage III atypical cases are not clear, the fact that AA anastomoses behave functionally like AV anastomoses^{9,14} (so-called 'rescue transfusion') suggests a possible explanation. Through this behavior, the donor twin could receive part of the recipient's blood volume¹⁵, which could be sufficient to rescue renal function, resulting in the increased maximum vertical pocket seen in the Stage III atypical cases.

Our data revealed the different Doppler findings characteristic of each substage. The fact that Stage III atypical

Table 2 Comparison of perinatal outcomes in 82 pregnancies with Quintero stage III twin–twin transfusion syndrome, between atypical and classical subgroups⁷

Outcome	Stage III atypical (n = 37)	Stage III classical (n = 45)	P
GA at delivery (weeks)	32.2 ± 4.0	32.3 ± 4.5	0.46
Time from procedure to delivery (days)	78.1 ± 37.3	78.8 ± 36.5	0.93
Birth weight (g)			
Donor	1270 ± 703	1438 ± 607	0.26
Recipient	1813 ± 696	1679 ± 572	0.39
Survival rate at 6 months			
Donor	20 (54.1)	35 (77.8)	0.02
Recipient	32 (86.5)	36 (80.0)	0.44
IUFD			
Donor	16 (43.2)	6 (13.3)	0.002
Recipient	4 (10.8)	6 (13.3)	0.73
Both	2 (5.4)	1 (2.2)	0.45
Donor with UA-AREDV	16/31 (51.6)	5/24 (20.8)	0.02
Donor with normal UA Doppler	0/6 (0)	1/21 (4.8)	0.59
Abnormal brain scan of live infant*	2/52 (3.8)	2/71 (2.8)	0.75
Donor	1/20 (5)	0/35 (0)	0.18
Recipient	1/32 (3.1)	2/36 (5.6)	0.63
Pregnancy			
2 survivors	18 (48.7)	30 (66.7)	0.10
1 survivor only	16 (43.2)	11 (24.4)	0.07
0 survivors	3 (8.1)	4 (8.9)	0.90
At least 1 survivor	34 (91.9)	41 (91.1)	0.90

Data are shown as mean ± SD or n (%). Stage III defined as abnormal Doppler flow in either twin, 'atypical' subgroup having visible donor bladder and 'classical' subgroup being without visible donor bladder⁷. *Abnormal brain scan defined as Grade III or IV intraventricular hemorrhage or periventricular leukomalacia. AREDV, absent or reversed end-diastolic velocity; GA, gestational age; IUFD, intrauterine fetal demise; UA, umbilical artery.

Table 3 Donor intrauterine fetal death rates in 82 pregnancies with Quintero stage III twin–twin transfusion syndrome⁷ according to different subgroups

Subgroup	IUFD (n (%))	UA Doppler		AAA		AREDV with AAA (n = 30)
		AREDV (n = 55)	Normal (n = 27)	Present (n = 35)	Absent (n = 47)	
Stage III atypical (n = 37)	16 (43)	16/31 (52)*†	0/6 (0)*	13/27 (48)	3/10 (30)	13/24 (54)
Stage III classical (n = 45)	6 (13)	5/24 (21)†	1/21 (5)	3/8 (38)	3/37 (8)	3/6 (50)
All Stage III (n = 82)	22 (27)			16/35 (46)	6/47 (13)	
UA-AREDV (n = 55)	21 (38)			16/30 (53)‡ § ¶	5/25 (20)§ ¶	
Normal UA Doppler (n = 27)	1 (4)			0/5 (0)‡ ¶	1/22 (5)¶	

Data are shown as n (%). Overall donor IUFD rate was 27% (22/82). Symbols indicate which results were compared by chi-square test to produce the following P-values: *P = 0.02; †P = 0.02; ‡P = 0.03; §P = 0.01; ¶P < 0.001. AAA, arterioarterial anastomoses; AREDV, absent or reversed end-diastolic velocity; IUFD, intrauterine fetal demise; UA, umbilical artery.

was characterized by a significantly higher incidence of abnormal Doppler in the donor than in the recipient, while Stage III classical was characterized by a similar incidence of abnormal Doppler findings in donor and recipient, may suggest that Stage III atypical has more uniform characteristics than does Stage III classical TTTS. In singleton and dichorionic twin pregnancies, UA-AREDV usually reflects placental insufficiency and fetal hypoxia¹⁶; however, the changes in UA Doppler waveforms which manifest as UA-AREDV in monochorionic diamniotic twins cannot be interpreted in the same manner^{15,17–19}, as they represent a combination of the effects of placental insufficiency and intertwin vascular connections²⁰. Despite this, it can be a prognostic factor predicting

donor IUFD following laser surgery^{21–26}, which has a high incidence (41–75%) of donor IUFD. Donors with UA-AREDV recovering to positive diastolic flow after laser surgery had a good chance of survival^{20,22,27}, implying that elimination of anastomoses can improve donor hypotension and/or hypovolemia by increasing the hemodynamic volume of the donor^{27,28}.

In our Stage III series, donors with UA-AREDV and AA anastomoses had a significantly higher incidence of IUFD after laser surgery than did those with UA-AREDV without AA anastomoses (53.3% vs. 20.0%). Kontopoulos *et al.*²⁶ also reported that 31% of donors that died after laser surgery had AA anastomoses compared with 17% of donors that survived. One explanation for the poorer

prognosis associated with the presence of AA anastomoses may be that their elimination by laser therapy can lead to insufficient circulation in the donor, such as severe hypovolemia or hypotension, since rescue transfusion is performed mainly by these anastomoses¹⁵. On the other hand, paradoxically, while the donor's circulation could have adequate blood volume (visible bladder and amniotic fluid) thanks to rescue transfusion by AA anastomoses, the donor could also have UA-AREDV (signifying insufficient blood flow). It is possible that there is some as yet unknown mechanism involved.

Subclassification of Quintero's stages based on the presence or absence of AA anastomoses was reported by Tan *et al.*²⁹. They explained that in Stages I–III, fetal survival was higher at each stage in fetuses with AA anastomoses than in those without; however, the majority of their cases were treated conservatively or by amnioreduction therapy and there was no description of neurological morbidity. Furthermore, their sensitivity of 67% would seem to indicate that the sonographic detection of AA anastomoses is rather difficult and inadequate for the subclassification of Quintero stages in TTTS.

Quintero's subclassification system for Stage III based on visibility of the donor bladder is not ideal because of its limited pathophysiological nature; however, it may be helpful clinically because it is associated with prognosis, particularly in the donor. This could prove important in preoperative counseling regarding Stage III, particularly when there is UA-AREDV of the donor with AA anastomoses, which is associated with the potential risk of donor IUFD after laser surgery. One possibility in these cases is conservative management; however, if AA anastomoses are left intact and one fetus dies, the other fetus will have less chance of survival. Further prospective study is required to improve the poor prognosis of these cases.

In conclusion, the Quintero stage III atypical subgroup is characterized by a high incidence of AA anastomoses and UA-AREDV, resulting in IUFD of the donor after laser therapy. A simple subclassification based on whether the donor bladder is visible (Stage III atypical) or not (Stage III classical) may thus help in clearly differentiating Stage III subgroups with respect to fetal prognosis following laser surgery and help in understanding the pathophysiology of Stage III TTTS.

ACKNOWLEDGMENT

This work was supported by Health and Labor Sciences Research Grant 2007-CR-G-009, Japan.

REFERENCES

- Gonsoulin W, Moise KJ, Jr, Kirshon B, Cotton DB, Wheeler JM, Carpenter RJ, Jr. Outcome of twin-twin transfusion diagnosed before 28 weeks of gestation. *Obstet Gynecol* 1990; 75: 214–216.
- Saunders NJ, Snijders RJ, Nicolaides KH. Therapeutic amniocentesis in twin-twin transfusion syndrome appearing in the second trimester of pregnancy. *Am J Obstet Gynecol* 1992; 166: 820–824.
- Hecher K, Plath H, Bregenzer T, Hansmann M, Hackeloer BJ. Endoscopic laser surgery versus serial amniocenteses in the treatment of severe twin-twin transfusion syndrome. *Am J Obstet Gynecol* 1999; 180: 717–724.
- Quintero RA, Dickinson JE, Morales WJ, Bornick PW, Bermudez C, Cincotta R, Chan FY, Allen MH. Stage-based treatment of twin-twin transfusion syndrome. *Am J Obstet Gynecol* 2003; 188: 1333–1340.
- Senat MV, Deprest J, Boulvain M, Paupe A, Winer N, Ville Y. Endoscopic laser surgery versus serial amnioreduction for severe twin-twin transfusion syndrome. *N Engl J Med* 2004; 351: 136–144.
- Huber A, Diehl W, Bregenzer T, Hackeloer BJ, Hecher K. Stage-related outcome in twin-twin transfusion syndrome treated by fetoscopic laser coagulation. *Obstet Gynecol* 2006; 108: 333–337.
- Quintero RA, Morales WJ, Allen MH, Bornick PW, Johnson PK, Kruger M. Staging of twin-twin transfusion syndrome. *J Perinatol* 1999; 19: 550–555.
- Quintero RA, Morales WJ, Mendoza G, Allen M, Kalter CS, Giannina G, Angel JL. Selective photocoagulation of placental vessels in twin-twin transfusion syndrome: evolution of a surgical technique. *Obstet Gynecol Surv* 1998; 53: S97–S103.
- Murakoshi T, Quintero RA, Bornick PW, Allen MH. In vivo endoscopic assessment of arterioarterial anastomoses: insight into their hemodynamic function. *J Matern Fetal Neonatal Med* 2003; 14: 247–255.
- Denbow ML, Cox P, Talbert D, Fisk NM. Colour Doppler energy insonation of placental vasculature in monochorionic twins: absent arterio-arterial anastomoses in association with twin-to-twin transfusion syndrome. *Br J Obstet Gynaecol* 1998; 105: 760–765.
- Taylor MJ, Farquharson D, Cox PM, Fisk NM. Identification of arterio-venous anastomoses in vivo in monochorionic twin pregnancies: preliminary report. *Ultrasound Obstet Gynecol* 2000; 16: 218–222.
- Denbow ML, Cox P, Taylor M, Hammal DM, Fisk NM. Placental angioarchitecture in monochorionic twin pregnancies: relationship to fetal growth, fetofetal transfusion syndrome, and pregnancy outcome. *Am J Obstet Gynecol* 2000; 182: 417–426.
- Diehl W, Hecher K, Zikulnig L, Vetter M, Hackeloer BJ. Placental vascular anastomoses visualized during fetoscopic laser surgery in severe mid-trimester twin-twin transfusion syndrome. *Placenta* 2001; 22: 876–881.
- Bermudez C, Becerra CH, Bornick PW, Allen MH, Arroyo J, Quintero RA. Placental types and twin-twin transfusion syndrome. *Am J Obstet Gynecol* 2002; 187: 489–494.
- Gratacos E, Lewi L, Munoz B, Acosta-Rojas R, Hernandez-Andrade E, Martinez JM, Carreras E, Deprest J. A classification system for selective intrauterine growth restriction in monochorionic pregnancies according to umbilical artery Doppler flow in the smaller twin. *Ultrasound Obstet Gynecol* 2007; 30: 28–34.
- Sebire NJ. Umbilical artery Doppler revisited: pathophysiology of changes in intrauterine growth restriction revealed. *Ultrasound Obstet Gynecol* 2003; 21: 419–422.
- Gaziano E, Gaziano C, Brandt D. Doppler velocimetry determined redistribution of fetal blood flow: correlation with growth restriction in diamniotic monochorionic and dizygotic twins. *Am J Obstet Gynecol* 1998; 178: 1359–1367.
- Wee LY, Taylor MJ, Vanderheyden T, Talbert D, Fisk NM. Transmitted arterio-arterial anastomosis waveforms causing cyclically intermittent absent/reversed end-diastolic umbilical artery flow in monochorionic twins. *Placenta* 2003; 24: 772–778.
- Gratacos E, Lewi L, Carreras E, Becker J, Higuera T, Deprest J, Cabero L. Incidence and characteristics of umbilical artery intermittent absent and/or reversed end-diastolic flow in complicated and uncomplicated monochorionic twin pregnancies. *Ultrasound Obstet Gynecol* 2004; 23: 456–460.

20. Chang YL, Chmait RH, Bornick PW, Allen MH, Quintero RA. The role of laser surgery in dissecting the etiology of absent or reverse end-diastolic velocity in the umbilical artery of the donor twin in twin-twin transfusion syndrome. *Am J Obstet Gynecol* 2006; 195: 478–483.
21. Ville Y, Hecher K, Gagnon A, Sebire N, Hyett J, Nicolaides K. Endoscopic laser coagulation in the management of severe twin-to-twin transfusion syndrome. *Br J Obstet Gynaecol* 1998; 105: 446–453.
22. Zikulnig L, Hecher K, Bregenzer T, Baz E, Hackeloer BJ. Prognostic factors in severe twin-twin transfusion syndrome treated by endoscopic laser surgery. *Ultrasound Obstet Gynecol* 1999; 14: 380–387.
23. Martinez JM, Bermudez C, Becerra C, Lopez J, Morales WJ, Quintero RA. The role of Doppler studies in predicting individual intrauterine fetal demise after laser therapy for twin-twin transfusion syndrome. *Ultrasound Obstet Gynecol* 2003; 22: 246–251.
24. Ishii K, Hayashi S, Nakata M, Murakoshi T, Sago H, Tanaka K. Ultrasound assessment prior to Laser photocoagulation for twin-twin transfusion syndrome for predicting intrauterine fetal demise after surgery in Japanese patients. *Fetal Diagn Ther* 2006; 22: 149–154.
25. Cavicchioni O, Yamamoto M, Robyr R, Takahashi Y, Ville Y. Intrauterine fetal demise following laser treatment in twin-to-twin transfusion syndrome. *BJOG* 2006; 113: 590–594.
26. Kontopoulos EV, Quintero RA, Chmait RH, Bornick PW, Russell Z, Allen MH. Percent absent end-diastolic velocity in the umbilical artery waveform as a predictor of intrauterine fetal demise of the donor twin after selective laser photocoagulation of communicating vessels in twin-twin transfusion syndrome. *Ultrasound Obstet Gynecol* 2007; 30: 35–39.
27. Gratacos E, Van Schoubroeck D, Carreras E, Devlieger R, Roma E, Cabero L, Deprest J. Impact of laser coagulation in severe twin-twin transfusion syndrome on fetal Doppler indices and venous blood flow volume. *Ultrasound Obstet Gynecol* 2002; 20: 125–130.
28. Ishii K, Chmait RH, Martinez JM, Nakata M, Quintero RA. Ultrasound assessment of venous blood flow before and after laser therapy: approach to understanding the pathophysiology of twin-twin transfusion syndrome. *Ultrasound Obstet Gynecol* 2004; 24: 164–168.
29. Tan TY, Taylor MJ, Wee LY, Vanderheyden T, Wimalasundera R, Fisk NM. Doppler for artery-artery anastomosis and stage-independent survival in twin-twin transfusion. *Obstet Gynecol* 2004; 103: 1174–1180.

RESEARCH LETTER

Anemia in a recipient twin unrelated to twin anemia–polycythemia sequence subsequent to sequential selective laser photocoagulation of communicating vessels for twin–twin transfusion syndrome

Keisuke Ishii^{1*}, Takeshi Murakoshi¹, Satoshi Hayashi², Kentaro Matsuoka³, Haruhiko Sago², Mitsuru Matsushita¹, Takashi Shinno¹, Hiroo Naruse¹ and Yuichi Torii¹

¹Division of Perinatology, Fetal Diagnosis and Therapy, Maternal and Perinatal Care Center, Seirei Hamamatsu General Hospital, Hamamatsu, Japan

²Division of Fetal Medicine, National Center for Child Health and Development, Tokyo, Japan

³Department of Pathology, National Center for Child Health and Development, Tokyo, Japan

KEY WORDS: twin–twin transfusion syndrome; laser therapy; fetal anemia

A 34-year-old woman, gravida 2, para 2, was admitted to our hospital following the diagnosis of twin–twin transfusion syndrome (TTTS) at 22 weeks of gestation. Ultrasonography was performed, revealing normal gross anatomy in the recipient twin. Estimated fetal weight (EFW) was 528 g, and maximum vertical pocket (MVP) of the amniotic fluid measured 9.3 cm. Doppler studies for the umbilical artery, umbilical vein, and *ductus venosus* yielded normal results. The donor twin also displayed normal gross anatomy, with a visible small bladder and an EFW of 400 g. No measurable pocket of amniotic fluid was noted. Doppler ultrasonography yielded normal results in the donor twin. The patient was diagnosed with Quintero stage I TTTS (Quintero *et al.*, 1999) with posterior placenta. Peak systolic velocity in the middle cerebral artery peak systolic doppler velocimetry (MCA-PSV) was 0.90 multiples of median (MoM) in the recipient twin and 0.88 MoM in the donor twin, respectively (Mari *et al.*, 2000). Fetoscopic laser photocoagulation (FLP) was performed at 22 + 5 weeks of gestation under epidural anesthesia. The patient provided written informed consent and the Institutional Review Board at the institute approved all study protocols. Eleven placental vascular anastomoses including an arterioarterial (AA) anastomosis and a venovenous (VV) anastomosis were identified and coagulated in the same way described as sequential selective laser photocoagulation of communicating vessels (SQLPCV) (Quintero *et al.*, 2007). While MVP of each twin normalized within 3 days, MCA-PSV of the recipient twin increased to 1.84 MoM by 3 days after FLP and continued to remain at high levels from at least 1.80 MoM

up to 2.37 MoM. Conversely, MCA-PSV of the donor generally continued to be flat at 0.94–1.16 MoM.

Percutaneous umbilical blood sampling for the recipient twin 42 days after FLP indicated that hemoglobin (Hb) level was 7.2 g/dL and hematocrit (Ht) was 22.4%. MCA-PSV of the recipient twin decreased to <1.5 MoM just after subsequent intrauterine red blood-cell transfusion. The twins were delivered by emergent cesarean section because of fetal bradycardia due to abruptio placenta at 33 weeks of gestation. The recipient twin weighed 1440 g and Apgar scores were 9/9. No hypovolemic shock developed, although she was managed in the NICU for the prematurity. Meanwhile, the donor twin weighed 1380 g and died due to severe asphyxia. Hb values of the recipient and donor were 10.2 and 14.9 g/dL and Ht were 31.4 and 47.2% in umbilical venous blood at birth, respectively. Reticulocyte counts were 6.8% in the recipient and 3.8% in the donor. Placental vascular casting by allowing dissolution of placental tissue with retention of the vasculature (Wee *et al.*, 2005) as well as macroscopic investigation of the placental surface revealed complete obliteration of placental vascular anastomoses (Figure 1). No neurological complications in the recipient twin had been recognized as of 1 year after birth.

Twin anemia–polycythemia sequence (TAPS), characterized by an isolated marked discordance in Hb levels without marked amniotic fluid discordance, has been described as a late complication subsequent to laser surgery and was thought to be associated with patent small arteriovenous anastomoses (Robyr *et al.*, 2006; Lopriore *et al.*, 2007). The frequency of TAPS as a complication after laser surgery was 13% according to a previous study. The pathophysiology in this case appears to differ from a type of TAPS, as the donor twin was not polycythemic and patent placental vascular anastomosis was undetected by vascular casting. Laser therapy is defined as SQLPCV, if all arteriovenous

*Correspondence to: Keisuke Ishii, Division of Perinatology, Fetal Diagnosis and Therapy, Maternal and Perinatal Care Center, Seirei Hamamatsu General Hospital, 2-12-12, Sumiyoshi, Nakaku, Hamamatsu City, 430-8558, Japan, E-mail: keisui@sis.seirei.or.jp

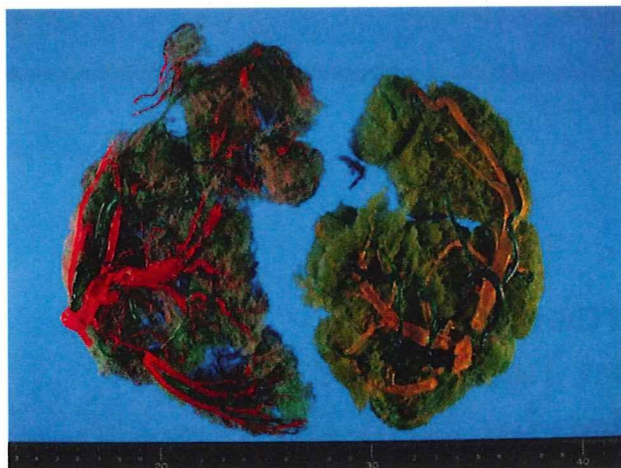

Figure 1—No patent placental vascular anastomosis was detectable according to placental vascular casting. Green, artery of donor twin; red, vein of the donor twin; blue, artery of the recipient twin; yellow, vein of the recipient twin

anastomoses from donor to recipient (AVDR) are coagulated in sequence prior to arteriovenous anastomoses from recipient to donor (AVRD), followed by obliteration of AA or VV (Quintero *et al.*, 2007). The aim of SQLPCV is principally to prevent the donor from hypotension and decrease the likelihood of IUFD of the donor. However, SQLPCV could be associated with an intraoperative transfusion from recipient to donor in theory. It remains possible that the recipient twin might conceivably lose blood volume during laser therapy and thus develop recipient anemia in this case.

In conclusion, this pathological condition with isolated fetal anemia in one twin, in addition to TAPS, should be considered as a clinical entity of fetal anemia when MCA-PSV is increased especially after SQLPCV. Further research is required to determine the incidence and discuss the etiology.

ACKNOWLEDGEMENTS

This work was supported by Health and Labour Sciences Research Grants 2007-CR-G-009, Japan.

REFERENCES

- Lopriore E, Middeldorp JM, Oepkes D, Kanhai HH, Walther FJ, Vandebussche FP. 2007. Twin anemia-polycythemia sequence in two monochorionic twin pairs without oligo-polyhydramnios sequence. *Placenta* **28**: 47–51.
- Mari G, Deter RL, Carpenter RL, *et al.* 2000. Noninvasive diagnosis by Doppler ultrasonography of fetal anemia due to maternal red-cell alloimmunization. Collaborative Group for Doppler Assessment of the Blood Velocity in Anemic Fetuses. *N Engl J Med* **342**: 9–14.
- Quintero RA, Morales WJ, Allen MH, Bornick PW, Johnson PK, Kruger M. 1999. Staging of twin-twin transfusion syndrome. *J Perinatol* **19**: 550–555.
- Quintero RA, Ishii K, Chmait RH, Bornick PW, Allen MH, Kontopoulos EV. 2007. Sequential selective laser photocoagulation of communicating vessels in twin-twin transfusion syndrome. *J Matern Fetal Neonatal Med* **20**: 763–768.
- Robyr R, Lewi L, Salomon LJ, *et al.* 2006. Prevalence and management of late fetal complications following successful selective laser coagulation of chorionic plate anastomoses in twin-twin transfusion syndrome. *Am J Obstet Gynecol* **194**: 796–803.
- Wee LY, Taylor M, Watkins N, Franke V, Parker K, Fisk NM. 2005. Characterisation of deep arterio-venous anastomoses within monochorionic placentae by vascular casting. *Placenta* **26**: 19–24.

Transitory Increase in Middle Cerebral Artery Peak Systolic Velocity of Recipient Twins after Fetoscopic Laser Photocoagulation for Twin-Twin Transfusion Syndrome

Keisuke Ishii Takeshi Murakoshi Mitsuru Matsushita Takashi Sinno
Hiroo Naruse Yuichi Torii

Division of Perinatology, Fetal Diagnosis and Therapy, Maternal and Perinatal Care Center, Seirei Hamamatsu General Hospital, Hamamatsu, Japan

Key Words

Fetoscopic laser photocoagulation · Middle cerebral artery peak systolic velocity · Twin-twin transfusion syndrome

Abstract

Objective: It was the aim of this study to elucidate the clinical features of recipient twins with increased middle cerebral artery peak systolic velocity (MCA-PSV) after fetoscopic laser photocoagulation (FLP) for twin-twin transfusion syndrome. **Methods:** Serial Doppler velocimetry of the MCA was performed in 30 recipient twins before and after FLP. Clinical data and perinatal outcome were compared between cases with and without increased MCA-PSV. **Results:** Increased MCA-PSV was observed in 7 recipients (23.3%) within 14 days after FLP. MCA-PSV gradually decreased to <1.5 multiples of median in 6 recipients; however, 1 patient resulted in fetal demise subsequent to the demise of the co-twin. The incidences of fetal and neonatal demise and neurological morbidity were similar. No recipient was diagnosed as anemic at birth. **Conclusions:** The increase in MCA-PSV in recipients following FLP appeared to be generally transitory; this differs from twin anemia-polycythemia sequence.

Copyright © 2008 S. Karger AG, Basel

Introduction

Twin-twin transfusion syndrome (TTTS) develops in approximately 15% of monochorionic twin pregnancies [1] and is associated with a high mortality and morbidity [2, 3]. The existence of intertwin placental vascular anastomoses has been recognized as the anatomical prerequisite of this pathological condition [4, 5]. The development of unbalanced blood flow from the donor twin to the recipient twin through the placental communicating vessels can result in hemodynamic disturbances in both twins.

Recently, large clinical studies including a randomized multicenter study reported the efficacy and advantage of fetoscopic laser photocoagulation (FLP) of the placental communicating vessels for treating TTTS, compared with serial amniodrainage [6–9]. Meanwhile, the prevalence of late complications of laser treatment has been recognized in recent years [10]. Twin anemia-polycythemia sequence (TAPS) is characterized by an isolated marked discordance in hemoglobin levels with both severe anemia and polycythemia without marked amniotic fluid discordance [11]. This situation was also described as a complication subsequent to laser surgery and was caused by patent vascular anastomoses due to failure of surgery [10]. In our clinical experience, several recipients exhibit increased middle cerebral artery peak systolic velocity (MCA-PSV)

KARGER

Fax +41 61 306 12 34
E-Mail karger@karger.ch
www.karger.com

© 2008 S. Karger AG, Basel
1015–3837/08/0244–0470\$24.50/0

Accessible online at:
www.karger.com/fdt

Keisuke Ishii, MD
Department of Perinatology
Maternal and Perinatal Care Center, Seirei Hamamatsu General Hospital
2-12-12 Sumiyoshi, 430-8558 Hamamatsu (Japan)
Tel. +81 53 474 2222, Fax +81 53 471 6050, E-Mail keisui@sis.seirei.or.jp

Table 1. Preoperative and perioperative data in cases with and without increased MCA-PSV of recipient twins

	With increase in MCA-PSV (n = 7)	Without increase in MCA-PSV (n = 23)	
GA at surgery, weeks	21 [18–24]	19 [18–25]	NS
Quintero stage, n			NS
I	0	2	
II	5	5	
III	1	1	
IV	0	2	
DR, %	31.0 [13.1–47.7]	40.5 [4.1–63.9]	NS
Deepest AMP, cm	11 [9–13]	10 [8–16]	NS
Anterior placenta, n	3 (42.9)	10 (43.5)	NS
MCA-PSV, MoM	1.1 [0.8–1.5]	0.9 [0.2–1.2]	NS
Operation time, min	54 [37–79]	65 [29–154]	NS

Data are medians, with ranges in brackets. Figures in parentheses are percentages. GA = Gestational age; NS = not significant; DR = estimated fetal weight discordant rate; AMP = amniotic fluid pocket.

after FLP for TTTS; however, they are not anemic at birth. The objective of this study was to document the clinical features and perinatal outcome of recipient twins with increased MCA-PSV after FLP.

Methods

From July 2002 to March 2007, 68 patients were diagnosed with TTTS and underwent FLP at our center. Patients whose sonographic data could not be completely obtained and cases of single or double intrauterine fetal demise or miscarriage within 24 h of the procedure were excluded. Of those, 30 patients who were treated by laser from February 2004 and were followed up at our division for at least 14 days were eligible for this study. TTTS was diagnosed on the basis of sonographic diagnostic criteria in monochorionic twin pregnancies: presence of polyhydramnios and an amniotic pocket ≥ 8 cm in the recipient's sac and oligohydramnios and an amniotic pocket ≤ 2 cm in the donor's sac. All patients met the following criteria for FLP: (1) gestational age < 26 weeks, and (2) Quintero stage I, II, III or IV [12]. Laser surgery was performed using a previously reported method [9, 13].

Preoperative ultrasound assessment, including fetal biometry and estimation of the amniotic fluid volume and placental location were performed. The examinations were carried out using Voluson 730 Expert (GE Healthcare, Kretztechnik, Zipf, Austria). The presence or absence of the fetal bladder in donor twins was assessed, and that of fetal hydropic signs documented. The discordant rate of the estimated fetal weight was calculated as $(A - B)/A \cdot 100$, where A is the estimated fetal weight of the larger twin, and B is that of the smaller twin. This was followed by MCA-PSV of the recipient twins just before surgery and at 3, 7 and 14 days

after FLP. Measurements of MCA-PSV were performed as described by Mari et al. [14]. Increased MCA-PSV was defined as at least 1 measurement value > 1.5 multiples of median (MoM) within 14 days of surgery. Once increased MCA-PSV was recorded, additional measurements of MCA-PSV were performed weekly until the value decreased to < 1.5 MoM.

Perinatal outcome included intrauterine fetal demise, neonatal death, transient hydropic signs in donor twins, gestational age at delivery, anemia in recipient twins at birth, and neurological morbidity in recipient twins at the age of 6 months. Dye injection tests were performed in cases with both fetal survival to confirm whether vascular anastomoses were interrupted. Statistical computations were performed using the Statistical Package for the Social Sciences version 12.0 (Chicago, Ill., USA) software. The Mann-Whitney test was used for nonparametric variables. Qualitative variables were compared by means of the χ^2 or Fisher's exact test as appropriate. The p value for the analysis was set at < 0.05 . The study was approved by the institutional review board, and the patients provided informed written consent.

Results

There were no statistical differences between these groups regarding perioperative data (table 1). Recurrence of TTTS after surgery was not observed in these cases.

MCA-PSV > 1.5 MoM was recorded in 7 recipients (23.3%) within 14 days of FLP on days 3 (n = 3), 7 (n = 1) and 14 (n = 3), while it was < 1.5 MoM in all recipients before surgery. MCA-PSV in 6 recipients gradually decreased to < 1.5 MoM within 28 days of FLP, except in 1 case of fetal demise subsequent to the demise of the donor twin. MCA-PSV in these 6 recipients continued to remain < 1.5 MoM since then, without reversed flow for ductus venosus, cardiomegaly or hydropic sign. Conversely, MCA-PSV in 3 co-twins continued to be flat (at least 0.9 up to 1.3 MoM) though MCA-PSV in the other 3 donor twins could not be measured continually due to technical problems.

The perinatal outcome of each group is shown in table 2, and the outline of cases with increased MCA-PSV in the recipients is shown in table 3. There were no statistical differences in both groups. Transient hydropic signs after FLP were noted in 2 of the 6 surviving donors (33.3%) in cases with increased MCA-PSV of recipients and in 4 of 16 donors (25.0%) in cases without increased MCA-PSV of recipients. No recipient was diagnosed with anemia at birth in both groups.

The obliteration of the vascular anastomoses was a confirmed dye injection test for all cases not complicated with fetal demise after surgery.

Table 2. Perinatal outcome in cases with and without increased MCA-PSV of recipient twins

	With increase in MCA-PSV (n = 7)	Without increase in MCA-PSV (n = 23)	
IUFD or NND in recipient twin	1 (14.3)	2 (8.7)	NS
IUFD or NND in donor twin	1 (14.3)	9 (39.1)	NS
Transient hydropic sign in donor twin	2/7 (28.6)	4/16 (25.0)	NS
Median GA at delivery	32 [21–37]	33 [23–40]	NS
Anemia in recipient twin at birth	0/6 (0.0)	0/15 (0.0)	NS
Neurological morbidity in recipient twin	0/6 (0.0)	0/14 (0.0)	NS

Figures in parentheses are percentages; data in brackets indicate ranges.

IUFD = Intrauterine fetal demise; NND = neonatal demise; NS = not significant; GA = gestational age.

Table 3. Data on cases with increased MCA-PSV of recipient twins

No.	Quin-tero stage	GA at surgery weeks	AMP cm	DR %	Placenta	Operative time min	Day MCA-PSV increased	Day MCA-PSV normalized	Maximum MCA-PSV MoM	IUFD of recipient	IUFD of donor	Hydrops of donor	GA at delivery weeks	Anemia of recipient	Neurological morbidity of recipient
1	3	24	11	29.8	anterior	67	14	28	1.67	no	no	no	33	no	no
2	2	24	12	47.7	posterior	43	3	21	1.66	no	no	no	37	no	no
3 ¹	2	18	9	13.1	posterior	37	10	NA	2.69	yes	yes	yes	21	NA	NA
4	2	17	9	39.1	posterior	49	7	28	1.64	no	no	no	33	no	no
5	3	22	16	39.2	anterior	59	3	7	1.87	no	no	no	35	no	no
6	2	19	10	31.0	anterior	65	14	28	1.57	no	no	no	36	no	no
7	2	23	13	18.1	posterior	79	3	21	1.58	no	no	yes	29	no	no

GA = Gestational age; AMP = amniotic fluid pocket; DR = estimated fetal weight discordant rate; IUFD = intrauterine fetal demise; NA = not applicable. Anemia of recipient indicates the presence of neonatal anemia at birth in surviving recipient twin, and neurological morbidity of recipient indicates the presence of neurological morbidity at 6 months of age in surviving recipient twin.

¹ Acute fetofetal hemorrhage subsequent to fetal demise of co-twin was suspected as a cause of fetal demise of recipient twin in case 3.

Discussion

Increased MCA-PSV has been regarded as a consequence of increased cardiac output and decreased blood viscosity due to fetal anemia [14, 15]. Mari et al. [14] suggested that fetal MCA-PSV >1.5 MoM indicated moderate or severe anemia, which corresponded to a hemoglobin concentration <0.65 MoM. MCA-PSV >1.5 MoM was noted in several recipients with TTTS within 14 days of FLP. Increased MCA-PSV in 6 cases regressed to <1.5 MoM; the longest duration required for this regression was 28 days after FLP. This phenomenon, namely, the transitory increase in MCA-PSV in recipients, must reflect fetal anemia. The clinical outcomes of these 6 cases were more favorable than those of TAPS without abnormal amniotic fluid discrepancy as a late complication of laser surgery as described by Robyr et al. [10]. The pathophysiology of this phenomenon might be different from a type of TAPS. This is simply because the increase in

MCA-PSV in these twins was transient; no fetus suffered from fetal anemia or fetal polycythemia at birth, and patent placental vascular anastomoses were not detected. We should consider both this transitory benign condition and TAPS when the MCA-PSV increases in the recipient twin after laser surgery. This may conceivably forestall unnecessary invasive intervention in some cases, although fetal blood sampling in cases with increased MCA-PSV after surgery is recommended [10].

Although the etiology of the transient increase in MCA-PSV in recipient twins is obscure, this phenomenon is likely to be associated with not only fetal anemia but also hypovolemia. Transient hydropic signs in 25% of the donor twins after laser surgery were considered to be benign conditions as described by Gratacos et al. [16]. This transient phenomenon is speculated to be a consequence of fetal hypervolemia after the interruption of intertwin transfusion via vascular anastomoses. Immediate increase in the venous blood flow in the umbilical vein of

the donor twins after laser surgery, as has been previously described [17, 18], may have caused the hypervolemia. Meanwhile, the decrease in the venous flow of the recipient twins after surgery has also been reported [18]. This change in blood flow can decrease the total blood volume in recipient twins, and perhaps, the MCA-PSV increases as fetal hypovolemia and subsequent anemia worsen. The association between the transient hydrops in the donors and the transitory increase in the MCA-PSV in the recipients could not be defined because in this study, the incidences of transient hydrops were similar between the cases with and without increased MCA-PSV in the recipients. Unlike TAPS, this increase in MCA-PSV might be transitory and specific for recipient twins. Once intertwin vascular anastomoses were completely obliterated, recipient twins could gradually recover their blood volume, including the blood lost after laser surgery.

This study has some limitations as MCA-PSV in the donor twins after FLP could not always be measured ac-

curately because of the sampling difficulties posed due to the small fetal size or fetal position. The possibility of a false positive of an increased MCA-PSV for fetal anemia should also be considered because of a false-positive rate of 12% and a positive predictive value of 65% on the prediction of fetal anemia due to maternal red-cell alloimmunization [14]. However, a pathological condition different from TAPS, which does not appear to be associated with a poor prognosis in recipient twins, may exist. Further research such as a prospective cohort study which includes the variation in the MCA-PSV of donor twins is required to accurately determine the incidence and discuss the etiology of this condition.

Acknowledgement

This work was supported by Health and Labor Sciences Research Grants 2007-CR-G-009, Japan.

References

- 1 Sebire NJ, Souka A, Skentou H, Geerts L, Nicolaides KH: Early prediction of severe twin-to-twin transfusion syndrome. *Hum Reprod* 2000;15:2008–2010.
- 2 Mahony BS, Petty CN, Nyberg DA, Luthy DA, Hickok DE, Hirsch JH: The 'stuck twin' phenomenon: ultrasonographic findings, pregnancy outcome, and management with serial amniocenteses. *Am J Obstet Gynecol* 1990;163:1513–1522.
- 3 Saunders NJ, Snijders RJ, Nicolaides KH: Therapeutic amniocentesis in twin-twin transfusion syndrome appearing in the second trimester of pregnancy. *Am J Obstet Gynecol* 1992;166:820–824.
- 4 Diehl W, Hecher K, Zikulnig L, Vetter M, Hackeloer BJ: Placental vascular anastomoses visualized during fetoscopic laser surgery in severe mid-trimester twin-twin transfusion syndrome. *Placenta* 2001;22:876–881.
- 5 Bermudez C, Becerra C, Bornick PW, Allen MH, Arroyo J, Quintero RA: Placental types and twin-twin transfusion syndrome. *Am J Obstet Gynecol* 2002;187:489–494.
- 6 Ville Y, Hecher K, Gagnon A, Sebire N, Hyett J, Nicolaides K: Endoscopic laser coagulation in the management of severe twin-to-twin transfusion syndrome. *Br J Obstet Gynaecol* 1998;105:446–453.
- 7 Hecher K, Plath H, Bregenzler T, Hansmann M, Hackeloer BJ: Endoscopic laser surgery versus serial amniocenteses in the treatment of severe twin-twin transfusion syndrome. *Am J Obstet Gynecol* 1999;180:717–724.
- 8 Quintero RA, Dickenson JE, Morales WJ, Bornick PW, Bermudez C, Cincotta R, Chan FY, Allen MH: Stage-based treatment of twin-twin transfusion syndrome. *Am J Obstet Gynecol* 2003;188:1333–1340.
- 9 Senat MV, Deprest J, Boulvain M, Paupe A, Winer N, Ville Y: Endoscopic laser surgery versus serial amnioreduction for severe twin-to-twin transfusion syndrome. *N Engl J Med* 2004;351:136–144.
- 10 Robyr R, Lewi L, Salomon LJ, Yamamoto M, Bernard JP, Deprest J, Ville Y: Prevalence and management of late fetal complications following successful selective laser coagulation of chorionic plate anastomoses in twin-to-twin transfusion syndrome. *Am J Obstet Gynecol* 2006;194:796–803.
- 11 Lopriore E, Middeldorp JM, Oepkes D, Kanhai HH, Walther FJ, Vandenbussche FP: Twin anemia-polycythemia sequence in two monochorionic twin pairs without oligopolyhydramnios sequence. *Placenta* 2007;28:47–51.
- 12 Quintero RA, Morales WJ, Allen MH, Bornick PW, Johnson PK, Kruger M: Staging of twin-twin transfusion syndrome. *J Perinatol* 1999;19:550–555.
- 13 Quintero RA, Morales WJ, Mendoza G, Allen MH, Kalter CS, Giannina G, Angel JL: Selective photocoagulation of placental vessels in twin-twin transfusion syndrome: evolution of a surgical technique. *Obstet Gynecol Surv* 1998;53:s97–s103.
- 14 Mari G, Deter RL, Carpenter RL, Rahman F, Zimmerman R, Moise KJ Jr, Dorman KE, Ludomirsky A, Gonzalez R, Gomez R, Oz U, Detti L, Copel JA, Bahado-Singh R, Berry S, Martinez-Poyer J, Blackwell SC: Noninvasive diagnosis by Doppler ultrasonography of fetal anemia due to maternal red-cell alloimmunization. Collaborative Group for Doppler Assessment of the Blood Velocity in Anemic Fetuses. *N Engl J Med* 2000;342:9–14.
- 15 Senat MV, Bernard JP, Loizeau S, Ville Y: Management of single fetal death in twin-to-twin transfusion syndrome: a role for fetal blood sampling. *Ultrasound Obstet Gynecol* 2002;20:360–363.
- 16 Gratacos E, Van Schoubroeck D, Carreras E, Devlieger R, Roma E, Cabero L, Deprest J: Transient hydropic signs in the donor fetus after fetoscopic laser coagulation in severe twin-twin transfusion syndrome: incidence and clinical relevance. *Ultrasound Obstet Gynecol* 2002;19:449–453.
- 17 Gratacos E, Van Schoubroeck D, Carreras E, Devlieger R, Roma E, Cabero L, Deprest J: Impact of laser coagulation in severe twin-twin transfusion syndrome on fetal Doppler indices and venous blood flow volume. *Ultrasound Obstet Gynecol* 2002;20:125–130.
- 18 Ishii K, Chmait RH, Martinez JM, Nakata M, Quintero RA: Ultrasound assessment of venous blood flow before and after laser therapy: approach to understanding the pathophysiology of twin-twin transfusion syndrome. *Ultrasound Obstet Gynecol* 2004;24:164–168.

Fetoscopic laser photocoagulation of placental communicating vessels for twin-reversed arterial perfusion sequence

Masahiko Nakata¹, Masahiro Sumie¹, Susumu Murata¹, Ichiro Miwa², Masakazu Matsubara² and Norihiro Sugino²

¹Perinatal Care Center, Yamaguchi University Hospital, Ube, and ²Department of Obstetrics and Gynecology, Yamaguchi University Graduate School of Medicine, Yamaguchi, Japan

Abstract

Twin-reversed arterial perfusion (TRAP) sequence is a rare and compromised complication in monochorionic pregnancies. The retrograde blood flow through placental communicating vessels is mainly involved to develop the syndrome. Increased cardiac output in the pump twin can lead to severe clinical manifestations. Various surgical techniques to occlude vascular communications between the pump twin and acardiac twin have been reported. A woman with TRAP sequence, at 22 weeks of gestation, complicated with progressive polyhydramnios underwent fetoscopic laser photocoagulation of vascular communications on the placental surface. Fetoscopic observation demonstrated one artery-to-artery anastomosis and one venous-to-venous anastomosis from the pump twin to the acardiac twin, and these communications were successfully photocoagulated. The patient delivered a 2308-g female infant at 34 weeks and 1 day of gestation, following premature rupture of membrane. The infant is now 1 year old without any neurological problem. Fetoscopic laser photocoagulation of placental communicating vessels can be the procedure of choice for TRAP sequence.

Key words: fetal therapy, fetoscopic laser photocoagulation, monochorionic twin, twin-reversed arterial perfusion sequence.

Introduction

Twin-reversed arterial perfusion (TRAP) sequence is a rare and compromised complication in monochorionic pregnancies, which affects approximately one in 35 000 births.¹ Although the pathophysiology of TRAP sequence is not clearly understood, it has been considered that retrograde blood flow through an artery-to-artery (AA) anastomosis from a pump twin to an acardiac twin, returning through a venous-to-venous (VV) anastomosis into the pump twin, is mainly involved to develop the syndrome.² Increased cardiac output in the pump twin caused by extra perfusion into the acardiac twin can lead to severe clinical mani-

festations such as hydrops fetalis or progressive polyhydramnios, resulting in poor perinatal outcomes.

Various surgical techniques to occlude vascular communications between the pump twin and acardiac twin have been reported.^{3–5} However, the optimal surgical management tailored to patients' situations has not been established yet.

We report a case of TRAP sequence complicated with progressive polyhydramnios at 22 weeks of gestation who underwent fetoscopic laser photocoagulation of vascular communications on the placental surface, which resulted in a favorable perinatal outcome.

Received: December 6 2007.

Accepted: March 4 2008.

Reprint request to: Dr Masahiko Nakata, Perinatal Care Center, Yamaguchi University Hospital, 1-1-1 Minamikogushi, Ube 755-8505, Japan. Email: miyabi@yamaguchi-u.ac.jp

Case Report

A 39-year-old primigravida woman was referred to our hospital for evaluation of an acardiac twin pregnancy. Initial fetal ultrasound examination at 20 weeks of gestation demonstrated TRAP sequence with color flow Doppler imaging, by which retrograde pulsatile flow toward the acardiac twin was documented. The pump twin was of normal appearance without any sign of cardiac failure and amniotic fluid volume was normal for gestation (5.6 cm maximal vertical pocket [MVP]). The amniotic septum was displayed between two fetal sacs, indicating diamniotic twinning. After detailed counseling about the potential cardiac failure in the pump twin or the progressive growth of the acardiac twin, the patient visited to our hospital 2 weeks later, at 22 weeks and 0 days of gestation, with symptomatic signs of polyhydramnios. The ultrasound examination showed progressive polyhydramnios in the sac of pump twin (12 cm MVP) and apparent hydropic changes in the acardiac twin as well as increasing overall mass (ratio of abdominal circumference of the acardiac twin to that of the pump twin was 1.5), but the acardiac to pump twin weight ratio was 24%. The acardiac twin was stuck to the surface of anterior placenta owing to oligohydramnios. Color flow Doppler imaging showed apparent pulsatile flow into the acardiac twin (ratio of the pulsatility index of the acardiac twin to that of pump twin was 0.62). Insertion sites of both umbilical cords could be identified, which were approximately 5 cm apart. The blood flow toward the acardiac twin through the feeding artery running on

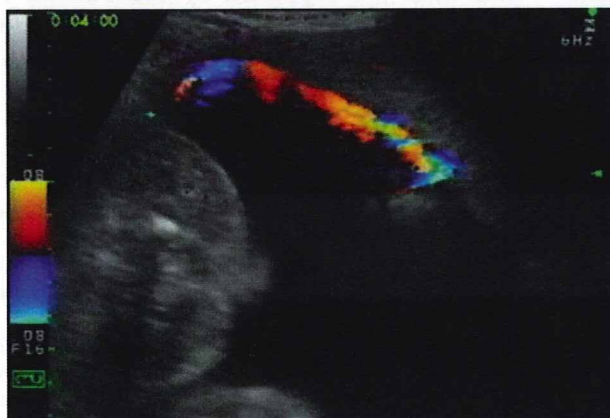

Figure 1 Color Doppler ultrasonography demonstrates the feeding artery from the pump twin to the acardiac twin running on the placental surface.

the placental surface was clearly documented by color flow Doppler study (Fig. 1).

After extensive discussion of the risk and benefits of alternative management options, the patient and her family decided to undergo fetoscopic laser photocoagulation of vascular communications and gave their written consent. The procedure was approved by the ethical committee in our hospital.

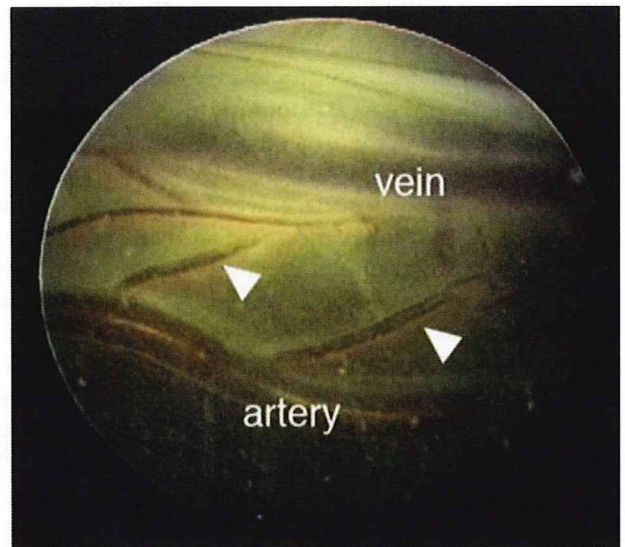


Figure 2 Fetoscopic observation of placental surface. One large artery-to-artery anastomosis and one large venous-to-venous anastomosis between the pump twin and the acardiac twin are shown. Small artery-to-venous communications between the two anastomoses are also noted (arrowhead).

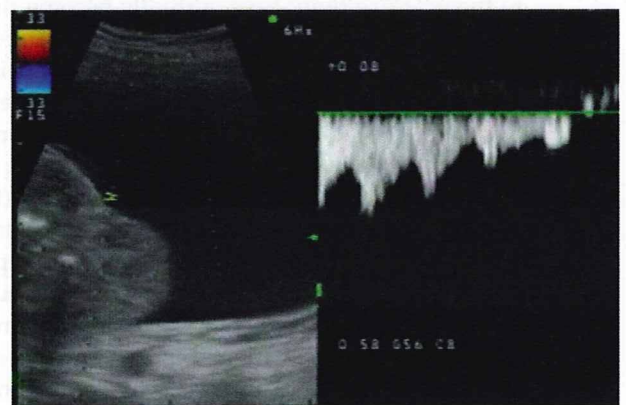


Figure 3 Continuous Doppler examination in the umbilical artery of the acardiac twin shows complete cessation of blood flow after fetoscopic laser photocoagulation of placental communicating vessels.

Under the local and i.v. anesthesia, a 3.8-mm trocar (Richard Wolf, Vernon Hills, IL, USA) was introduced into the amniotic cavity under ultrasound guidance. Fetoscopic observation by a 3.3-mm diagnostic endoscope (Richard Wolf) demonstrated one AA anastomosis and one VV anastomosis on the placental surface. In addition, there were several artery-to-venous (AV) communications between these AA and VV anastomoses (Fig. 2). A 550- μ m neodymium:yttrium-aluminum-garnet laser fiber (Slimline; Lumenis Japan, Tokyo, Japan) was inserted through the operating channel of a 3.3-mm operating endoscope (Richard Wolf) and all anastomoses were photocoagulated, in which an AA anastomosis was coagulated first followed by a VV anastomosis. As a consequence, all AV communications between AA and VV anastomoses on the placental surface were coagulated. Cessation of blood flow into the acardiac twin was confirmed by color flow Doppler imaging (Fig. 3). Before removal of the trocar sleeve, 1350 mL of amniotic fluid was drained.

After the surgery, ultrasound examination revealed normal growth of the pump twin without progressive polyhydramnios. The patient delivered a 2308-g female infant with Apgar scores of 9 and 9 at 1 and 5 min, respectively, at 34 weeks and 1 day of gestation, following premature rupture of membrane. The neonate had no sign of cardiac failure. The infant is now 1 year old without any neurological problems.

Discussion

Minimally invasive intrauterine treatments, in which the therapeutic strategy is to interrupt the blood supply to the acardiac twin, have currently become the main strategy to prevent perinatal death of the pump twin. Although various techniques for cord occlusion and intrafetal ablation have been reported, there seem to be two main procedures to occlude the blood communication between the acardiac and pump twin in current status: (i) intrafetal radiofrequency ablation (RFA),⁵⁻⁸ and (ii) fetoscopic laser coagulation of placental anastomoses or the umbilical cord.^{9,10} Tan and Sepulveda compared the cases treated by heterogeneous cord occlusion techniques such as embolization, cord ligation, laser coagulation, bipolar and monopolar diathermy with the cases treated by various intrafetal ablation techniques such as alcohol, monopolar diathermy, interstitial laser and radiofrequency, and concluded that intrafetal ablation is associated with a higher clinical success rate than the cord occlusion

technique, with an overall pump twin survival rate of 76%.¹¹ On the other hand, fetoscopic laser photocoagulation of placental anastomoses or the umbilical cord also showed favorable outcome of 77–80% in recent studies.^{9,10} The results of a recent two reports^{6,7} of RFA were also as successful as those of fetoscopic laser photocoagulation. Recently, ultrasound-guided bipolar cord coagulation was also reported useful for TRAP with a 65% survival rate.¹² Thus, we can conclude that these technical approaches to occlude blood flow communication bring benefits to cases with TRAP. In the present case, we performed fetoscopic laser photocoagulation because we had already equipped modalities for laser surgery and had experienced laser surgery for twin-twin transfusion syndrome.¹³

The main complication associated with these techniques is premature rupture of membrane (PROM). Hecher *et al.* reported that PROM occurred in only 18% of cases at a median interval of 9 weeks after the laser surgery, and PROM rate before 34 weeks was reported as 24% if the bipolar coagulation was indicated.¹⁰ At the time, it seems that which therapeutic modalities should be used depends on which technique physicians are familiar with. Further studies are needed regarding which is the best modality to interrupt the blood supply to the acardiac twin in TRAP sequence.

In conclusion, we experienced a case of TRAP sequence and achieved favorable outcome by fetoscopic laser photocoagulation of placental communicating vessels.

Acknowledgments

This work was supported by Grant-in-Aid 18591802 from the Ministry of Education, Science and Culture, and by Health and Labor Sciences Research Grants 2007-CR-G-009, Japan.

References

1. James WH. A note on the epidemiology of acardiac monsters. *Teratology* 1977; 16: 211–216.
2. Van Allen MI, Smith DW, Shepard TH. Twin reversed arterial perfusion (TRAP) sequence: A study of 14 twin pregnancies with acardius. *Semin Perinatol* 1983; 7: 285–293.
3. Ville Y, Hyett JA, Vandenbussche FP, Nicolaides KH. Endoscopic laser coagulation of umbilical cord vessels in twin reversed arterial perfusion sequence. *Ultrasound Obstet Gynecol* 1994; 4: 396–398.
4. Sepulveda W, Bower S, Hassan J, Fisk NM. Ablation of acardiac twin by alcohol injection into the intra-abdominal umbilical artery. *Obstet Gynecol* 1995; 86: 680–681.

5. Hirose M, Murata A, Kita N, Aotani H, Takebayashi K, Noda Y. Successful intrauterine treatment with radiofrequency ablation in a case of acardiac twin pregnancy complicated with a hydropic pump twin. *Ultrasound Obstet Gynecol* 2004; **23**: 509–512.
6. Lee H, Wagner AJ, Sy E *et al.* Efficacy of radiofrequency ablation for twin-reversed arterial perfusion sequence. *Am J Obstet Gynecol* 2007; **196**: e1–e4.
7. Livingston JC, Lim FY, Polzin W, Mason J, Crombleholme TM. Intrafetal radiofrequency ablation for twin reversed arterial perfusion (TRAP): A single-center experience. *Am J Obstet Gynecol* 2007; **197**: e1–e3.
8. Tsao K, Feldstein VA, Albanese CT *et al.* Selective reduction of acardiac twin by radiofrequency ablation. *Am J Obstet Gynecol* 2002; **187**: 635–640.
9. Quintero RA, Chmait RH, Murakoshi T *et al.* Surgical management of twin reversed arterial perfusion sequence. *Am J Obstet Gynecol* 2006; **194**: 982–991.
10. Hecher K, Lewi L, Gratacos E, Huber A, Ville Y, Deprest J. Twin reversed arterial perfusion: Fetoscopic laser coagulation of placental anastomoses or the umbilical cord. *Ultrasound Obstet Gynecol* 2006; **28**: 688–691.
11. Tan TY, Sepulveda W. Acardiac twin: A systematic review of minimally invasive treatment modalities. *Ultrasound Obstet Gynecol* 2003; **22**: 409–419.
12. Robyr R, Yamamoto M, Ville Y. Selective feticide in complicated monochorionic twin pregnancies using ultrasound-guided bipolar cord coagulation. *BJOG* 2005; **112**: 1344–1348.
13. Ishii K, Hayashi S, Nakata M, Murakoshi T, Sago H, Tanaka K. Ultrasound assessment prior to laser photocoagulation for twin-twin transfusion syndrome for predicting intrauterine fetal demise after surgery in Japanese patients. *Fetal Diagn Ther* 2006; **22**: 149–154.