

At necropsy, enlargement of the liver was observed in 3/16 males and 6/16 females at 250mg/kg/day, and in 11/16 males and 8/16 females at 500mg/kg/day. Absolute and relative organ weights are shown in Table 6. In males, absolute and relative liver weights and relative kidney weight were significantly increased at 250 and 500mg/kg/day. Absolute weights of the heart and lungs, and absolute and relative weights of the spleen and adrenals, were significantly decreased at both doses in males. Similar changes, except for no significant change in the relative adrenal weight, were found in organ weights of females at both doses.

Histopathological findings in the liver are presented in Table 7. In males, hypertrophy, eosinophilic granular change, single cell necrosis, and decreased glycogen in hepatocytes were observed at 250 and 500mg/kg/day. These findings were also detected with nearly identical incidences in females at either dose.

**Table 6:** Organ weights of male and female preweaning rats given DBHCB by gavage for 18 days.

Dose (mg/kg/day)	0 (control)	250	500
No. of males	16	16	16
Body weight (g)	64.0 ± 4.1	51.9 ± 7.0	55.0 ± 7.1
Heart (g)	0.32 ± 0.03 (0.51 ± 0.06)	0.26 ± 0.04** (0.50 ± 0.04)	0.29 ± 0.04** (0.52 ± 0.04)
Lungs (g)	0.54 ± 0.04 (0.85 ± 0.06)	0.46 ± 0.09** (0.89 ± 0.16)	0.47 ± 0.06** (0.86 ± 0.10)
Liver (g)	2.56 ± 0.33 (3.99 ± 0.33)	3.75 ± 0.71** (7.21 ± 0.61**)	4.28 ± 0.62** (7.78 ± 0.41**)
Spleen (g)	0.38 ± 0.05 (0.60 ± 0.06)	0.19 ± 0.04** (0.36 ± 0.05**)	0.21 ± 0.07** (0.38 ± 0.10**)
Kidneys (g)	0.69 ± 0.06 (1.09 ± 0.07)	0.66 ± 0.10 (1.26 ± 0.11**)	0.67 ± 0.09 (1.21 ± 0.06**)
Adrenals (mg)	17.4 ± 2.1 (28.8 ± 3.4)	12.1 ± 3.4** (22.7 ± 7.0**)	13.3 ± 3.3** (23.8 ± 5.0*)
No. of females	16	16	16
Body weight (g)	61.8 ± 4.2	50.2 ± 7.7	52.2 ± 5.0
Heart (g)	0.33 ± 0.03 (0.54 ± 0.05)	0.26 ± 0.03** (0.51 ± 0.05)	0.27 ± 0.02** (0.52 ± 0.04)
Lungs (g)	0.51 ± 0.03 (0.83 ± 0.09)	0.41 ± 0.08** (0.82 ± 0.10)	0.43 ± 0.04** (0.82 ± 0.08)
Liver (g)	2.55 ± 0.33 (4.13 ± 0.33)	3.71 ± 0.75** (7.36 ± 0.65**)	4.02 ± 0.58** (7.67 ± 0.54**)
Spleen (g)	0.36 ± 0.06 (0.58 ± 0.09)	0.18 ± 0.05** (0.36 ± 0.06**)	0.18 ± 0.05** (0.34 ± 0.07**)
Kidneys (g)	0.68 ± 0.06 (1.09 ± 0.10)	0.64 ± 0.09 (1.29 ± 0.10**)	0.65 ± 0.06 (1.26 ± 0.09**)
Adrenals (mg)	16.5 ± 2.5 (25.6 ± 5.1)	11.4 ± 2.7** (23.1 ± 6.0)	11.8 ± 2.0** (21.9 ± 4.0)

Values are expressed as the mean ± SD.

Values in parentheses are relative organ weights (g or mg/100g body weight).

\*Significantly different from the control group ( $p < 0.05$ ).

\*\*Significantly different from the control group ( $p < 0.01$ ).

**Table 7:** Histopathological findings in the liver of male and female preweaning rats given DBHCB by gavage for 18 days.

	Grade	Dose (mg/kg/day)		
		0 (control)	250	500
No. of males		4	4	4
Hypertrophy of hepatocytes	+	0	2]	1]
	++	0	2]*	1]
	+++	0	0]	2]*
Eosinophilic granular change of hepatocytes	+	0	2]	1]
	++	0	2]*	1]
	+++	0	0]	2]*
Decreased glycogen in hepatocytes	++	0	4]*	2]
	+++	0	0]	2]*
Single cell necrosis of hepatocytes	+	0	4*	4*
No. of females		4	4	4
Hypertrophy of hepatocytes	+	0	3]	1]
	++	0	0]*	2]*
	+++	0	1]	1]
Eosinophilic granular change of hepatocytes	+	0	0]	1]
	++	0	3]*	2]*
	+++	0	1]	1]
Decreased glycogen in hepatocytes	++	0	4]*	3]*
	+++	0	0]	1]
Single cell necrosis of hepatocytes	+	0	4*	4*

Values represent the number of animals with findings.

+: Very slight.

++: Slight.

+++ : Moderate.

\*Significantly different from the control,  $p < 0.05$ .

## DISCUSSION

The current study was designed to investigate the role of sex steroids in the mediation of gender-related differences in DBHCB toxicity. As expected from the results of our previous study of DBHCB (Ema et al., 2008), male rats showed much higher susceptibility to the toxic effects of DBHCB than females. This gender-related difference in the toxicity of DBHCB was markedly reduced by castration and abolished in preweaning rats.

Following DBHCB administration to young intact rats, the relative liver weight was increased by more than 100% in males but only by less than 10% in females. Histopathological changes in hepatocytes, including hypertrophy, decreased glycogen, and eosinophilic granular cytoplasm, were observed in males but not in females. Decreased glycogen could be considered another manifestation of hypertrophy, because glycogen is occasionally obscured by the proliferation of subcellular organelles (for example, smooth endoplasmic reticulum). Eosinophilic granular cytoplasm suggests peroxisome proliferation in hepatocytes because this change is widely known to be a characteristic

change observed in rodents administered with peroxisome proliferators, such as fibrate hypolipidemic drugs and phthalate plasticizers (Cattley and Popp, 2002). In order to ensure the precise mechanism of DBHCB hepatotoxicity, further study is needed to clarify the ultrastructural change or alteration in peroxisome-associated enzymes. In our previous combined study using adult rats, no histopathological change of hepatocytes was detected at the same dose of 250 mg/kg/day, the highest dose tested (Ema et al., 2008). Therefore, it is possible that young rats are more susceptible to DBHCB-induced hepatotoxicity than adult rats.

Castration of male rats reduced the degree of increased relative liver weight from 110% (intact males) to 42% (castrated males). Histopathology of the liver was not affected by DBHCB administration in castrated rats. These findings suggest an enhancing effect of testosterone on the hepatotoxicity of DBHCB in rats. In preweaning rats, DBHCB caused histopathological changes in the liver in both sexes with similar incidence and degree. Comparable increase in the relative liver weight of males (81–95%) and females (78–86%) clearly indicated a lack of gender-related difference in DBHCB hepatotoxicity in preweaning rats. Based on these findings, it seems likely that unknown factors developing at around 3–6 weeks of age under the influence of testosterone may participate in the induction of DBHCB toxicity.

Histopathological changes observed in the liver of preweaning rats included single cell necrosis of hepatocytes, which was not detected in young intact animals given DBHCB in the present study. Increased plasma levels of AST, ALT, and ALP are considered to result from such hepatic damage. In our previous comparative study of the toxicity of 1,3-dibromopropane in young and preweaning rats, single cell necrosis of hepatocytes was also observed only in preweaning rats (Hirata-Koizumi et al., 2005). Alexander et al. (1997) noted that the liver structure dramatically changed toward a highly regulated and structured regime on PNDs 8–28 in rats. These findings indicate that an immature and rapidly developing liver might be vulnerable to necrotic effects by chemicals.

In the current preweaning rat study, DBHCB also caused an inhibition of body weight gain, mainly during the late administration period. Such changes in body weight gain were not found in the previous combined study using adult rats (Ema et al., 2008) or in the present 28-day study using young intact rats. DBHCB would inhibit body weight gain more effectively during the preweaning period because rapid weight gain occurs during this period (Koizumi et al., 2001, 2002, 2003; Hirata-Koizumi et al., 2005). In the present study, the blood glucose level decreased; therefore, nutritional intake might be reduced by DBHCB administration. Changes in absolute heart and lung weights and relative kidney weight are considered to be secondary effects due to the inhibition of body weight gain, because the corresponding absolute or relative weight was not changed.



Increased plasma levels of total bilirubin and BUN found in the present preweaning rat study suggests hemolytic action and renal effects of DBHCB, respectively. Decreased spleen and adrenal weights might indicate specific effects on these organs. These changes were not observed in the previous combined study (Ema et al., 2008). In order to investigate the adverse effects of DBHCB on the blood, kidneys, spleen, and adrenals during the preweaning period, further studies, including hematological examination and histopathological observation of these organs, are required.

Alteration of gender-related differences by castration and age was also found in the toxicity of a structural analog, 2-(2'-hydroxy-3',5'-di-*tert*-butylphenyl)benzotriazole (HDBB), which is also used as UV absorber (Hirata-Koizumi et al., 2007, 2008a, 2008b, 2008c). In a 28-day repeated-dose toxicity study using young rats, HDBB principally affected the liver at much lower doses than DBHCB and also exerted adverse effects on the blood, heart, kidneys, and thyroids. Male rats consistently showed higher susceptibility to the toxic effects of HDBB; therefore, sexual variation in the toxicity of these benzotriazole UV absorbers might be explained by the difference in the blood concentration of causative substances (DBHCB, HDBB, or these metabolites) between sexes.

A number of reports have been published on gender-related variation in toxicokinetic determinants in rats, such as hepatic metabolism (Gad, 2006) and membrane transporter in various organs, including the kidneys and intestine (Morris et al., 2003). In particular, many mechanistic studies have been reported on the metabolic enzyme, cytochrome P450 (Waxman and Chang, 2005). In rats, a subset of P450s is expressed in a sex-dependent fashion, and gonadal hormones play an essential role in determining the expression of the major sex-specific rat liver P450 forms. Castration of male rats at birth abolishes the normal adult expression of male-specific P450s, and that of female rats reduces the expression of female-specific/predominant liver P450 enzymes (Bandiera and Dworschak, 1992; Dannan et al., 1986; McClellan-Green et al., 1989; Waxman et al., 1988). Because the current results showed that the higher susceptibility of male rats to DBHCB toxicity was markedly reduced by castration, there is a possibility that male-specific metabolic enzymes may be closely involved in the toxic activation of DBHCB. Interestingly, in the rat liver, the difference in P450 expression between sexes is not apparent until puberty (Waxman and Chang, 2005). For example, one of the male-specific liver P450s, the steroid 6 $\beta$ -hydroxylase CYP3A2, is expressed in the prepubertal rat liver at similar levels in both sexes, but is selectively suppressed at puberty in females. One possible explanation for DBHCB exerting equivalent effects on the liver of male and female preweaning rats in the present study might be the contribution of such a male-specific P450 enzyme to the toxic activation of DBHCB. Gustafsson et al. (1981) reported that brain centers involved in the hypothalamo-pituitary control of hepatic sex-dependent

metabolism in adults are irreversibly programmed by neonatal androgen exposure, which might explain why sexual variation in DBHCB toxicity was not completely abolished by castration at PNDs 25–29 in the present study.

In order to clarify the cause of the gender-related difference in the toxicity of DBHCB, a toxicokinetic study is required. The study should include the identification of metabolites and related metabolic enzymes, as well as the measurement of the blood concentration of DBHCB after administration to both young and preweaning rats.

## CONCLUSION

The current results showed that the oral administration of DBHCB for 28 days to young rats caused hepatotoxicity, and male rats had a much higher susceptibility to the toxic effects than females. This gender-related difference was markedly reduced by castration and abolished in preweaning rats.

## ACKNOWLEDGMENT

This study was supported by the Ministry of Health, Labour and Welfare, Japan.

## REFERENCES

- Agarwal, D. K., Misra, D., Agarwal, S., Seth, P. K., Kohli, J. D. (1982). Influence of sex hormones on parathion toxicity in rats: antiacetylcholinesterase activity of parathion and paraoxon in plasma, erythrocytes, and brain. *J. Toxicol. Environ. Health.* 9:451–459.
- Alexander, B., Guzail, M. A., Foster, C. S. (1997). Morphological changes during hepatocellular maturity in neonatal rats. *Anat. Rec.* 248:104–109.
- Bandiera, S., Dworschak, C. (1992). Effects of testosterone and estrogen on hepatic levels of cytochromes P450 2C7 and P450 2C11 in the rat. *Arch. Biochem. Biophys.* 296:286–295.
- Carlson, G. P., DuBois, K. P. (1970). Studies on the toxicity and biochemical mechanism of action of 6-methyl-2, 3-quinoxalinedithiol cyclic carbonate (morestan). *J. Pharmacol. Exp. Ther.* 173:60–70.
- Cattley, R. C., Popp, J. A. (2002). Liver: In Handbook of Toxicologic Pathology, 2nd ed. Haschek, W.M., Rousseaux, C.G., Wallig, M.A. eds, Vol. 2, San Diego, California, USA: Academic Press, pp. 187–225.
- Coleman, M. D., Tingle, M. D., Winn, M. J., Park, B. K. (1990). Gonadal influence on the metabolism and haematological toxicity of dapsone in the rat. *J. Pharm. Pharmacol.* 42:698–703.
- Dannan, G. A., Guengerich, F. P., Waxman, D. J. (1986). Hormonal regulation of rat liver microsomal enzymes. Role of gonadal steroids in programming, maintenance, and suppression of delta 4-steroid 5 alpha-reductase, flavin-containing monooxygenase, and sex-specific cytochromes P-450. *J. Biol. Chem.* 261:10728–10735.



- Ema, M., Fukunishi, K., Matsumoto, M., Hirose, A., Kamata, E. (2006). Evaluation of developmental toxicity of ultraviolet absorber 2-(3',5'-di-tert-butyl-2'-hydroxyphenyl)-5-chlorobenzotriazole in rats. *Drug Chem. Toxicol.* 29:215-225.
- Ema, M., Fukunishi, K., Hirose, A., Hirata-Koizumi, M., Matsumoto, M., Kamata, E. (2008). Combined repeated dose toxicity study with the reproductive/developmental toxicity screening test of ultraviolet absorber 2-(3',5'-di-tert-butyl-2'-hydroxyphenyl)-5-chlorobenzotriazole in Rats. *Drug Chem Toxicol.* in press.
- Everlight Chemical Industrial Corporation. (2002). Safety Data Sheet on EVERSORB 75. Taipei, Taiwan. Available at: <http://www.hansonco.net/EVERSORB-75-MSDS.pdf>, accessed on December 10, 2007.
- Gad, S.C. (2006). Metabolism: In: *Animal Models in Toxicology*, 2nd ed. Gad, S.C. ed., Boca Raton, Florida, USA: CRC Press, pp. 217-247.
- Great Lakes Chemical Corporation. (2007). Technical information on Lowilite 27 West Lafayette, Indiana, USA. Available at: <http://www.el.greatlakes.com/pdf/datasheet/Lowilite%2027%20ds.PDF>, accessed on December 10, 2007.
- Gustafsson, J. A., Eneroth, P., Hökfelt, T., Mode, A., Norstedt, G., Skett, P. (1981). Role of the hypothalamo-pituitary-liver axis in sex differences in susceptibility of the liver to toxic agents. *Environ. Health Perspect.* 38:129-141.
- Harris, R. Z., Benet, L. Z., Schwartz, J. B. (1995). Gender effects in pharmacokinetics and pharmacodynamics. *Drugs* 50:222-239.
- Hirata-Koizumi, M., Kusuoka, O., Nishimura, N., Wada, H., Ogata, H., Fukuda, N., Ito, Y., Kamata, E., Ema, M., Hasegawa, R. (2005). Susceptibility of newborn rats to hepatotoxicity of 1,3-dibromopropane and 1,1,2,2-tetrabromoethane, compared with young rats. *J. Toxicol. Sci.* 30:29-42.
- Hirata-Koizumi, M., Watari, N., Mukai, D., Imai, T., Hirose, A., Kamata, E., Ema, M. (2007). A 28-day repeated dose toxicity study of ultraviolet absorber 2-(2'-hydroxy-3',5'-di-tert-butylphenyl)benzotriazole in rats. *Drug Chem. Toxicol.* 30:327-341.
- Hirata-Koizumi, M., Ogata, H., Imai, T., Hirose, A., Kamata, E., Ema, M. (2008a). A 52-week repeated dose toxicity study of ultraviolet absorber 2-(2'-hydroxy-3',5'-di-tert-butylphenyl)benzotriazole in rats. *Drug Chem. Toxicol.* 31, 81-96.
- Hirata-Koizumi, M., Matsuyama, T., Imai, T., Hirose, A., Kamata, E., Ema, M. (2008b). Gonadal influence on the toxicity of 2-(2'-hydroxy-3',5'-di-tert-butylphenyl)benzotriazole in rats. *Drug Chem. Toxicol.* 31, 115-126.
- Hirata-Koizumi, M., Matsuyama, T., Imai, T., Hirose, A., Kamata, E., Ema, M. (2008c). Lack of gender-related difference in the toxicity of 2-(2'-hydroxy-3',5'-di-tert-butylphenyl)benzotriazole in preweaning rats. *Drug Chem. Toxicol.* 31, 275-287.
- Knuckles, M. E., Inyang, F., Ramesh, A. (2004). Acute and subchronic oral toxicity of fluoranthene in F-344 rats. *Ecotoxicol. Environ. Saf.* 59:102-108.
- Koizumi, M., Yamamoto, Y., Ito, Y., Takano, M., Enami, T., Kamata, E., Hasegawa, R. (2001). Comparative study of toxicity of 4-nitrophenol and 2,4-dinitrophenol in newborn and young rats. *J. Toxicol. Sci.* 26:299-311.
- Koizumi, M., Nishimura, N., Enami, T., Sunaga, M., Horikawa, H., Kamata, E., Hasegawa, R. (2002). Comparative toxicity study of 3-aminophenol in newborn and young rats. *J. Toxicol. Sci.* 27:411-421.
- Koizumi, M., Noda, A., Ito, Y., Furukawa, M., Fujii, S., Kamata, E., Ema, M., Hasegawa, R. (2003). Higher susceptibility of newborn than young rats to 3-methylphenol. *J. Toxicol. Sci.* 28:59-70.

- McClellan-Green, P. D., Linko, P., Yeowell, H. N., Goldstein, J. A. (1989). Hormonal regulation of male-specific rat hepatic cytochrome P-450g (P-450IIC13) by androgens and the pituitary. *J. Biol. Chem.* 264:18960-18965.
- Morris, M. E., Lee, H. J., Predko, L. M. (2003). Gender differences in the membrane transport of endogenous and exogenous compounds. *Pharmacol. Rev.* 55:229-240.
- Muraoka, Y., Itoh, F. (1980). Sex difference of mercuric chloride-induced renal tubular necrosis in rats—from the aspect of sex differences in renal mercury concentration and sulfhydryl levels. *J. Toxicol. Sci.* 5:203-214.
- Stern, S. T., Tallman, M. N., Miles, K. K., Ritter, J. K., Dupuis, R. E., Smith, P. C. (2007). Gender-related differences in mycophenolate mofetil-induced gastrointestinal toxicity in rats. *Drug Metab. Dispos.* 35:449-454.
- Wang, R. H., Schorer-Apelbaum, D., Weinstock, M. (2001). Testosterone mediates sex difference in hypothermia and cholinesterase inhibition by rivastigmine. *Eur. J. Pharmacol.* 433:73-79.
- Waxman, D. J., Chang, T. K. (2005). Hormonal Regulation of Liver Cytochrome P450 Enzymes. In: *Cytochrome P450 - Structure, Mechanism, and Biochemistry*, 3rd ed. Ortiz de Montellano, P.R. eds, New York: Kluwer Academic/Plenum Publishers, pp. 347-376.
- Waxman, D. J., LeBlanc, G. A., Morrissey, J. J., Staunton, J., Lapenson, D. P. (1988). Adult male-specific and neonatally programmed rat hepatic P-450 forms RLM2 and 2a are not dependent on pulsatile plasma growth hormone for expression. *J. Biol. Chem.* 263:11396-11406.

# Lack of Gender-Related Difference in the Toxicity of 2-(2'-Hydroxy-3',5'-di-*tert*-butylphenyl)benzotriazole in Prewaning Rats

Mutsuko Hirata-Koizumi,<sup>1</sup> Takashi Matsuyama,<sup>2</sup> Toshio Imai,<sup>1</sup>  
Akihiko Hirose,<sup>1</sup> Eiichi Kamata,<sup>1</sup> and Makoto Ema<sup>1</sup>

<sup>1</sup>Division of Risk Assessment, Biological Safety Research Center, National Institute of Health Sciences, Tokyo, Japan

<sup>2</sup>Drug Safety Research Laboratories, Shin Nippon Biomedical Laboratories, Ltd. (SNBL DSR), Kagoshima, Japan

In our previous toxicity studies using young rats, we showed that an ultraviolet absorber, 2-(2'-hydroxy-3',5'-di-*tert*-butylphenyl)benzotriazole (HDBB), principally affected the liver, and male rats had nearly 25 times higher susceptibility to the toxic effects than females. In the present study, the toxicity of HDBB was investigated in preweaning rats. HDBB was administered by gavage to male and female CD(SD) rats from postnatal days 4 to 21 at a dose of 0, 0.1, 0.5, 2.5, or 12.5 mg/kg/day. No substance-related deaths, clinical signs of toxicity, or body-weight changes were observed. Increased levels of albumin, AST and ALP in both sexes, BUN in males, and LDH in females were found at 12.5 mg/kg. Liver weights increased at 2.5 mg/kg and above in both sexes. Histopathologically, hepatocellular findings, such as nucleolar enlargement, anisokaryosis, increased mitosis, and/or hypertrophy, were observed at 2.5 mg/kg and above in both sexes. These results indicate no gender-related differences in the susceptibility to the toxic effects of HDBB in preweaning rats.

**Keywords** Benzotriazole UV absorber, Prewaning rat, Gender-related difference, Hepatotoxicity.

---

Address correspondence to Makoto Ema, Division of Risk Assessment, Biological Safety Research Center, National Institute of Health Sciences, 1-18-1, Kamiyoga, Setagaya-ku, Tokyo 158-8501, Japan; E-mail: ema@nihs.go.jp



## INTRODUCTION

A number of reports have been published on gender-related differences in the toxic effects of chemicals in rats (Agarwal et al., 1982; Coleman et al., 1990; McGovren et al., 1981; Muraoka and Itoh, 1980; Nishino et al., 1998; Ogirima et al., 2006; Raheja et al., 1983). For example, fluoranthene, a polycyclic aromatic hydrocarbon, showed greater effects on male rats than females, especially on the kidneys, in a subchronic toxicity study (Knuckles et al., 2004). In contrast, female rats exhibited greater susceptibility to hypothalamic cholinesterase inhibitory and hypothermic effects of a carbamate cholinesterase inhibitor, rivastigmine (Wang et al., 2001). Such gender-related variations are also reported in humans, mostly for medicines (Harris et al., 1995). Examples include more severe adverse effects, but with greater improvement in response, to antipsychotic drugs such as chlorpromazine and fluspirilene in women.

Previously, we reported that male and female rats showed markedly different susceptibilities to the toxicity of 2-(2'-hydroxy-3',5'-di-*tert*-butylphenyl)benzotriazole (HDBB), which is an ultraviolet absorber used in plastic resin products, such as building materials and automobile components (METI, 2006). In a 28-day repeated-dose toxicity study, male and female rats were administered HDBB by gavage, and adverse effects on the liver, heart, blood, kidneys, and thyroids were found (Hirata-Koizumi et al., 2007). The no observed adverse effect level (NOAEL) for females was 2.5 mg/kg/day based on histopathological changes in the liver and heart detected at 12.5 mg/kg, but the NOAEL for males could not be determined because hepatic changes were noted even at the lowest dose of 0.5 mg/kg. In the 52-week repeated-dose toxicity study, chronic oral administration of HDBB principally affected the liver, and the NOAEL was concluded to be 0.1 mg/kg/day in males and 2.5 mg/kg/day in females (Hirata-Koizumi et al., 2008a), showing that male rats have approximately 25 times higher susceptibility to HDBB toxicity than females.

For such gender differences in toxic responses, sexual hormones are likely to play important roles. In fact, Wang et al. (2001) reported that orchidectomy completely abolished the above-mentioned sex differences in hypothalamic cholinesterase inhibition induced by rivastigmine, and testosterone treatment to gonadectomized males and females decreased the cholinesterase inhibitory effects of rivastigmine; therefore, it is apparent that testosterone interferes with the effects of rivastigmine. On the other hand, estrogen has been shown to act as a dopamine antagonist (Harris et al., 1995), which is considered to contribute, at least in part, to sex differences in response to antipsychotic drugs.

In order to investigate the role of sex steroids in the mediation of sex differences in the susceptibility to the toxic effects of HDBB, we recently performed a 28-day repeated-dose toxicity study using male and female

castrated rats (Hirata-Koizumi et al., 2008b). As expected, castration markedly reduced the sexual variation in HDBB toxicity, but some difference, less than five times, remained between male and female castrated rats. It is speculated that the determinants of susceptibility to HDBB toxicity are already differentiated between sexes by four weeks of age, when the castration was performed; therefore, in the present study, we determined the sexual difference in the susceptibility to HDBB toxicity in preweaning rats.

## MATERIALS AND METHODS

This study was performed at Shin Nippon Biomedical Laboratories, Ltd., Drug Safety Research Laboratories (SNBL DSR; Kagoshima, Japan) in 2006–2007. The experiment was approved by the Institutional Animal Care and Use Committee of SNBL DSR and was performed in accordance with the ethics criteria contained in the bylaws of the Committee.

### Animals and Housing Conditions

Eleven-week-old male and 10-week-old female CrI:CD(SD) rats were purchased from Hino Breeding Center, Charles River Laboratories Japan, Inc. (Yokohama, Japan) and individually housed in stainless steel cages suspended over a cage board. After a seven-day acclimation, females were cohabited overnight with one male each. Females with vaginal plugs were regarded as pregnant, and this day was designated as Day 0 of gestation. On gestation day 20, the pregnant females were transferred to aluminum cages with wooden chips as bedding (White Flake; Charles River Laboratories Japan, Inc.) and allowed to deliver spontaneously and rear their pups. The day of birth was defined as postnatal day (PND) 0. On PND 4, the sex of the pups was determined, and the litters were adjusted randomly to four males and four females. Five litters were selected and randomly assigned to each of five dose groups, including control groups; the initial number of pups for treatment was 20/sex/group.

Throughout the study, the animals were maintained in an air-conditioned room at 21.5–22.4°C, with a relative humidity of 43–55%, a 12-h light/dark cycle, and ventilation with 15 air changes/hour. A basal diet (CE-2; CLEA Japan, Inc., Tokyo, Japan) and water, which met the drinking water standard under the Water Works Law of Japan, were provided *ad libitum*.

### Chemicals and Doses

HDBB (CAS No. 3846-71-7, Lot no. AY11) was 100% pure and was obtained from Tokyo Chemical Industry Co., Ltd. (Tokyo, Japan); it was kept in a dark place at room temperature under airtight conditions. Dosing



solutions were prepared as a suspension in corn oil (Wako Pure Chemical Industries, Ltd., Osaka, Japan) once or twice a week and kept cool in a dark place under airtight conditions until dosing. Stability under refrigerated conditions was confirmed for seven days in the previous 28-day repeated-dose toxicity study using young animals (Hirata-Koizumi et al., 2007).

Male and female preweaning rats were given HDBB by gavage once-daily from PNDs 4 to 21. Control rats received the vehicle only. A nutrient catheter (Type 3Fr; Atom Medical Corporation, Tokyo, Japan), attached to a disposable syringe, was used for dosing. The volume of each dose was adjusted to 10 mL/kg of body weight, based on the latest body weight.

The dosage levels of HDBB were determined to be 0.1, 0.5, 2.5, or 12.5 mg/kg/day, based on the results of our previous 28-day repeated-dose toxicity study using young rats (Hirata-Koizumi et al., 2007). In this previous study, male and female young rats were given HDBB by gavage at 0.5, 2.5, 12.5, or 62.5 mg/kg/day, and adverse effects, mainly on the liver and heart, were found at all doses in males and at 12.5 mg/kg and above in females.

## Observations

All dams were observed daily for clinical signs of toxicity, and body weight was recorded on Days 0, 10, and 20 of pregnancy and on Days 0, 10, 20, and 22 after delivery. On Day 22 after delivery, they were euthanized by exsanguination under deep ether anesthesia, and the surface, organs, and tissues of the entire body were macroscopically observed.

All pups were observed daily before and three to four hours after dosing for clinical signs of toxicity. Body weight was recorded on PNDs 0, 4, 6, 8, 10, 12, 14, 16, 18, 21, and 22. On PND 22, blood was collected from the caudal vena cava in the abdomen of two male and two female pups per litter under deep ether anesthesia. Plasma separated from the blood by centrifugation was examined for total protein, albumin, glucose, total cholesterol, triglycerides, total bilirubin, blood urea nitrogen (BUN), creatinine, aspartate aminotransferase (AST), alanine aminotransferase (ALT), alkaline phosphatase (ALP), lactate dehydrogenase (LDH), creatine phosphokinase, calcium, inorganic phosphorus, sodium, potassium, and chlorine. Following the collection of blood, all pups (four males and four females per litter) were euthanized by exsanguination under deep ether anesthesia, and the surface, organs, and tissues of the entire body were macroscopically observed. The heart, lungs, liver, spleen, kidneys, and adrenals were then collected and weighed. The liver and heart were histopathologically examined in one male and one female per litter. The organs were fixed in 10% neutral-buffered formalin, and paraffin sections for microscopic examination were routinely prepared and stained with hematoxylin-eosin.



## Data Analysis

Body weight, blood biochemical parameters, and organ weights of pups were analyzed by Bartlett's test (Bartlett, 1937) for homogeneity of distribution ( $p < 0.01$ ). When homogeneity was recognized, Dunnett's test (Dunnett, 1964) was conducted to compare between control and individual treatment groups ( $p < 0.01$  or  $0.05$ ). If not homogenous, data were analyzed using the mean rank test of Dunnett's type (Hollander and Wolfe, 1973) ( $p < 0.01$  or  $0.05$ ). Histopathological findings were analyzed using Wilcoxon's rank sum test (Wilcoxon, 1945) ( $p < 0.01$  or  $0.05$ ).

## RESULTS

HDBB, orally administered to pups from PNDs 4 to 21, did not induce any clinical signs of toxicity or affect the body weight of maternal rats (data not shown). At necropsy, no gross abnormality was found in the dams.

One male pup each at 0 or 0.5 mg/kg and one female pup each at 0, 0.5, or 12.5 mg/kg died, which was confirmed to be due to gavage error. No substance-related clinical signs of toxicity were found in pups of any groups. There were also no significant changes in the body weight of male and female pups, as shown in Figure 1.

Principle blood biochemical values are summarized in Table 1. In males, the levels of albumin, AST, ALP, and BUN were significantly increased at 12.5 mg/kg. In females, significant increases in the levels of albumin, AST, ALP, and LDH were found at the same dose. There were no substance-related changes in other blood biochemical parameters.

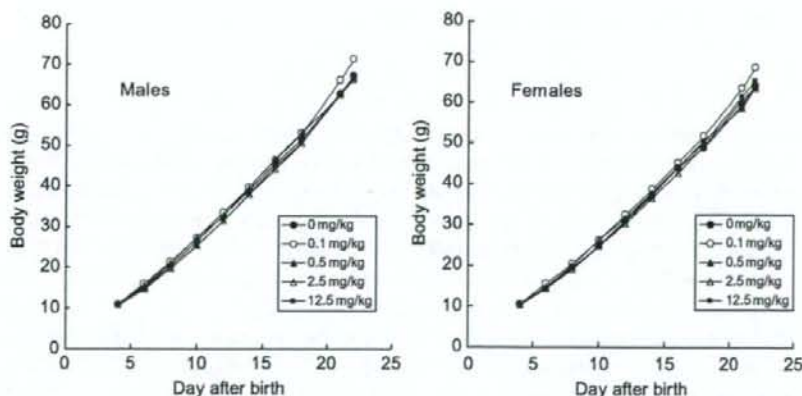


Figure 1: Body weight curves of male and female preweaning rats given HDBB by gavage.

**Table 1:** Principle blood biochemical values in male and female preweaning rats given HDDB by gavage.

Dose (mg/kg/day)	0	0.1	0.5	2.5	12.5
No. of males	10	10	10	10	10
Total protein (g/dL)	4.49 ± 0.28	4.53 ± 0.22	4.48 ± 0.26	4.43 ± 0.17	4.42 ± 0.18
Albumin (g/dL)	3.62 ± 0.24	3.60 ± 0.24	3.59 ± 0.21	3.74 ± 0.27	4.04 ± 0.17**
BUN (mg/dL)	11.4 ± 1.5	14.1 ± 2.6	13.7 ± 5.3	12.9 ± 1.8	14.7 ± 2.3**
AST (IU/L)	91.4 ± 15.9	85.2 ± 4.8	88.7 ± 5.2	91.6 ± 12.2	100.2 ± 8.5*
ALT (IU/L)	34.8 ± 5.7	34.0 ± 6.3	29.4 ± 5.3	30.7 ± 5.5	35.9 ± 6.1
ALP (IU/L)	1557 ± 203	1529 ± 240	1412 ± 279	1286 ± 249	2054 ± 444**
LDH (IU/L)	198 ± 123	165 ± 16	184 ± 40	236 ± 170	326 ± 221
No. of females	10	10	10	10	10
Total protein (g/dL)	4.49 ± 0.24	4.54 ± 0.24	4.53 ± 0.28	4.55 ± 0.18	4.50 ± 0.14
Albumin (g/dL)	3.59 ± 0.28	3.66 ± 0.24	3.70 ± 0.26	3.80 ± 0.25	4.04 ± 0.16**
BUN (mg/dL)	12.5 ± 2.0	15.4 ± 1.5	13.5 ± 4.0	14.1 ± 4.1	15.5 ± 3.3
AST (IU/L)	87.3 ± 9.4	85.1 ± 8.2	86.5 ± 6.3	85.2 ± 6.6	101.3 ± 9.2**
ALT (IU/L)	30.7 ± 5.9	30.7 ± 3.6	27.1 ± 5.5	27.1 ± 4.5	35.9 ± 4.2
ALP (IU/L)	1470 ± 136	1394 ± 215	1287 ± 105	1339 ± 183	1872 ± 259**
LDH (IU/L)	175 ± 52	176 ± 36	179 ± 35	139 ± 28	370 ± 295*

Values are expressed as the mean ± SD.

BUN, blood urea nitrogen; AST, aspartate aminotransferase; ALT, alanine aminotransferase; ALP, alkaline phosphatase; LDH, lactate dehydrogenase.

\*Significantly different from the control group ( $p < 0.05$ ).

\*\*Significantly different from the control group ( $p < 0.01$ ).

At necropsy, no gross abnormality was observed. Absolute and relative organ weights of scheduled sacrifice animals are shown in Table 2. In males, absolute liver weight at 12.5 mg/kg and relative weight at 2.5 mg/kg and above were significantly increased. In addition, absolute and relative weights of the lungs and spleen were significantly decreased at 12.5 mg/kg. In females, significant increases in absolute liver weight at 12.5 mg/kg and relative liver weight at 2.5 mg/kg and above, and decreases in relative spleen weight and absolute and relative adrenal weight at 12.5 mg/kg, were found. No substance-related changes were detected in other organ weights.

Histopathological findings in the liver are presented in Table 3. In males, nucleolar enlargement, anisokaryosis, and increased mitosis of hepatocytes were observed at 2.5 mg/kg and above. In the 12.5 mg/kg group, hypertrophy of hepatocytes accompanied with eosinophilic granular changes was also observed. Further, increased incidence and/or severity of decreased glycogen in hepatocytes was found at 2.5 mg/kg and above. Similarly, in females, nucleolar enlargement, anisokaryosis, and increased mitosis of hepatocytes at 2.5 mg/kg and above, and hypertrophy and eosinophilic granular change of hepatocytes at 12.5 mg/kg were detected, and the incidence and/or severity of decreased glycogen in hepatocytes was higher at 12.5 mg/kg. No substance-related histopathological changes were detected in the heart in both sexes.

Table 2: Organ weights of male and female preweaning rats given HDBB by gavage.

Dose (mg/kg/day)	0	0.1	0.5	2.5	12.5
No. of males	19	20	19	20	20
Body weight (g)	67.2 ± 7.3	71.3 ± 6.9	67.3 ± 5.8	66.2 ± 9.6	66.2 ± 5.0
Heart (g)	0.37 ± 0.04 (0.55 ± 0.04)	0.37 ± 0.04 (0.52 ± 0.04)	0.36 ± 0.05 (0.53 ± 0.05)	0.36 ± 0.05 (0.54 ± 0.03)	0.35 ± 0.04 (0.53 ± 0.04)
Lung (g)	0.58 ± 0.07 (0.87 ± 0.07)	0.58 ± 0.04 (0.82 ± 0.09)	0.53 ± 0.03 (0.80 ± 0.06*)	0.59 ± 0.08 (0.90 ± 0.09)	0.53 ± 0.04 (0.80 ± 0.06*)
Liver (g)	2.83 ± 0.47 (4.19 ± 0.36)	2.88 ± 0.34 (4.04 ± 0.26)	2.75 ± 0.44 (4.07 ± 0.42)	3.24 ± 0.68 (4.87 ± 0.40**)	4.54 ± 0.61** (6.84 ± 0.53**)
Spleen (g)	0.37 ± 0.09 (0.55 ± 0.10)	0.40 ± 0.05 (0.57 ± 0.06)	0.34 ± 0.08 (0.51 ± 0.10)	0.38 ± 0.77 (0.57 ± 0.08)	0.29 ± 0.05** (0.44 ± 0.06**)
Kidneys (g)	0.72 ± 0.09 (1.07 ± 0.07)	0.74 ± 0.06 (1.04 ± 0.07)	0.72 ± 0.08 (1.07 ± 0.08)	0.68 ± 0.10 (1.03 ± 0.05)	0.71 ± 0.07 (1.07 ± 0.08)
Adrenals (mg)	17.5 ± 3.7 (26.2 ± 5.1)	19.3 ± 3.7 (27.3 ± 5.8)	18.1 ± 3.3 (27.4 ± 5.8)	21.5 ± 5.2* (32.4 ± 6.8**)	17.0 ± 2.4 (25.6 ± 3.3)
No. of females	19	20	19	20	19
Body weight (g)	64.0 ± 7.1	68.6 ± 7.5	63.6 ± 4.7	63.6 ± 8.9	65.3 ± 4.1
Heart (g)	0.35 ± 0.05 (0.54 ± 0.04)	0.35 ± 0.05 (0.51 ± 0.05)	0.33 ± 0.03 (0.52 ± 0.06)	0.34 ± 0.05 (0.53 ± 0.04)	0.35 ± 0.04 (0.53 ± 0.04)
Lung (g)	0.54 ± 0.08 (0.85 ± 0.11)	0.54 ± 0.06 (0.80 ± 0.09)	0.55 ± 0.06 (0.86 ± 0.10)	0.57 ± 0.09 (0.90 ± 0.12)	0.51 ± 0.05 (0.78 ± 0.06)
Liver (g)	2.72 ± 0.47 (4.23 ± 0.43)	2.77 ± 0.41 (4.02 ± 0.24)	2.62 ± 0.38 (4.12 ± 0.44)	3.01 ± 0.54 (4.71 ± 0.27*)	4.47 ± 0.39** (6.84 ± 0.41**)
Spleen (g)	0.36 ± 0.12 (0.55 ± 0.15)	0.37 ± 0.06 (0.53 ± 0.07)	0.32 ± 0.07 (0.50 ± 0.10)	0.33 ± 0.06 (0.52 ± 0.08)	0.28 ± 0.07 (0.43 ± 0.09*)
Kidneys (g)	0.70 ± 0.07 (1.09 ± 0.06)	0.71 ± 0.07 (1.04 ± 0.04**)	0.67 ± 0.06 (1.05 ± 0.05)	0.66 ± 0.09 (1.04 ± 0.05*)	0.72 ± 0.07 (1.10 ± 0.07)
Adrenals (mg)	19.2 ± 3.7 (29.9 ± 4.6)	18.8 ± 4.5 (27.5 ± 6.8)	16.9 ± 2.3 (26.8 ± 4.2)	19.9 ± 3.7 (31.4 ± 5.2)	15.4 ± 3.5** (23.5 ± 4.8**)

Values are expressed as the mean ± SD.

Values in parentheses are relative organ weights (g or mg/100 g body weight).

\*Significantly different from the control group ( $p < 0.05$ ).\*\*Significantly different from the control group ( $p < 0.01$ ).



**Table 3:** Histopathological findings in the liver of male and female preweaning rats given HDBB by gavage.

	Grade	Dose (mg/kg/day)				
		0	0.1	0.5	2.5	12.5
No. of males		5	5	5	5	5
Nucleolar enlargement in hepatocytes	±	0	0	0	1	4
	+	0	0	0	0	1
Anisokaryosis of hepatocytes	±	0	0	0	1	2
	+	0	0	0	0	3
Increased mitosis of hepatocytes	±	0	1	0	2	1
	+	0	0	0	1	3
	++	0	0	0	0	1
Hypertrophy of hepatocytes	±	0	0	0	0	4
	+	0	0	0	0	1
Eosinophilic granular change of hepatocytes	+	0	0	0	0	5
Decreased glycogen in hepatocytes	±	1	1	2	4	2
	+	0	0	0	0	3
No. of females		5	5	5	5	5
Nucleolar enlargement in hepatocytes	±	0	0	0	2	4
	+	0	0	0	0	1
Anisokaryosis of hepatocytes	±	0	0	0	1	3
	+	0	0	0	0	2
Increased mitosis of hepatocytes	±	0	1	0	1	1
	+	0	0	0	2	3
	++	0	0	0	0	1
Hypertrophy of hepatocytes	±	0	0	0	0	3
	+	0	0	0	0	2
Eosinophilic granular change of hepatocytes	±	0	0	0	0	1
	+	0	0	0	0	4
Decreased glycogen in hepatocytes	±	1	0	2	2	3
	+	0	0	0	0	2

Values represent the number of animals with the finding.

±, very slight; +, slight; ++, moderate.

\*Significantly different from the control ( $p < 0.05$ ).

\*\*Significantly different from the control ( $p < 0.01$ ).

## DISCUSSION

In the current study, the toxicity of HDBB was investigated in preweaning rats. Based on our previous results of a 28-day repeated-dose toxicity study using young rats (Hirata-Koizumi et al., 2008a), the dosage of HDBB used in this study was sufficiently high to be expected to induce adverse effects on the liver and heart. As expected, increased absolute and/or relative liver weight and histopathological changes of hepatocytes were observed at 2.5 mg/kg and above in both sexes.

Although degeneration and hypertrophy of the myocardium or cell infiltration in the heart were observed at 2.5 mg/kg and above in the previous 28-day study (Hirata-Koizumi et al., 2007), such changes were not detected even at the highest dose of 12.5 mg/kg in the present study. Considering that histopathological changes in the heart were also not found in the previous 52-week study of HDBB using young rats (Hirata-Koizumi et al., 2008a) and a 28-day study using young castrated rats (Hirata-Koizumi et al., 2008b), it could not be concluded that preweaning rats were less susceptible to the cardiac effects of HDBB than young rats. In order to investigate the toxicological effects of HDBB on the heart in more detail, the effects on cardiac function (e.g., electrocardiographic parameters, blood pressure, etc.) should be evaluated because they are considered to be more susceptible parameters than histopathology of the heart (Glaister, 1992).

In the present study, some blood biochemical parameters increased in both sexes in the 12.5 mg/kg group. The degree of change was mostly slight, but it was considered to be HDBB related because similar changes were found in previous studies of HDBB (Hirata-Koizumi et al., 2007, 2008a, 2008b). A simultaneous increase in hepatic enzymes (AST, ALP, and LDH) might result from hepatic damage caused by HDBB. Increased BUN suggests renal effects of HDBB, although histopathology of the kidneys was not examined in the present study. As a matter of fact, hypertrophy of the tubular epithelium was noted at 12.5 mg/kg and above in males and at 62.5 mg/kg in females in the previous 28-day study of HDBB using young rats (Hirata-Koizumi et al., 2007).

No effects on the lungs, spleen, and adrenals were found both in previous 28-day and 52-week studies of HDBB using young rats (Hirata-Koizumi et al., 2007, 2008a), whereas decreased weight of these organs was found in preweaning rats given HDBB. In rats, many organs develop rapidly during the early period after birth (Vidair, 2004; Walthall et al., 2005; Zoetis and Hurtt, 2005a). For example, rat lungs have no alveoli at birth, but they develop rapidly, with most lung development complete within the first two weeks after birth (Zoetis and Hurtt, 2005b). It is conceivable that immature and/or rapidly developing organs show different susceptibility from mature organs. Considering these findings together suggests that HDBB might influence these organs, specifically in the preweaning period. Further studies are required to investigate the adverse effects of HDBB on the lungs, spleen, and adrenals during the preweaning period.

Histopathological changes in the liver detected in the current study included nucleolar enlargement, anisokaryosis, increased mitosis, and hypertrophy of hepatocytes. Nucleolar enlargement of hepatocytes indicates the enhancement of protein synthesis and is identified most frequently in hepatocytes that are undergoing rapid cell proliferation (Cattley and Popp, 2002). Anisokaryosis is also considered to correlate at least partly with cell



proliferation. In the present study, nucleolar enlargement, anisokaryosis, and increased mitosis of hepatocytes were observed at 2.5 mg/kg and above in both sexes, whereas hypertrophy of hepatocytes was observed only at the highest dose of 12.5 mg/kg. On the other hand, in the previous 28-day study of HDBB using young rats, hypertrophy of hepatocytes was observed at 0.5 mg/kg and above in males and 12.5 mg/kg and above in females, and increased mitosis of hepatocytes was observed at 62.5 mg/kg and 12.5 mg/kg and above in males and females, respectively, indicating that young rats are more susceptible to the HDBB-induced hypertrophic response of hepatocytes than the mitotic response (Hirata-Koizumi et al., 2007). The higher susceptibility of preweaning rats to such proliferative changes might be associated with dramatic changes of the liver structure during the preweaning period (Alexander et al., 1997).

In previous studies using young rats (five to six weeks of age), we showed that male rats were much more susceptible to the toxic effects of HDBB than females (Hirata-Koizumi et al., 2007, 2008a). Based on histopathological findings in the liver, which is a major target of HDBB toxicity, differences in susceptibility between sexes was approximately 25 times. Subsequently, we showed that castration markedly reduced the gender-related differences in HDBB hepatotoxicity in rats (Hirata-Koizumi et al., 2008b). Comparing the histopathological findings of the liver observed in the previous 28-day studies using young intact and castrated rats, it became clear that the castration of male rats exerted no effect but that of female rats enhanced the adverse effects of HDBB on the liver, suggesting suppressive effects of estrogen on the hepatotoxicity of HDBB in rats. Despite the marked reduction of gender-related differences in the toxic effects of HDBB by castration, a difference, less than five times, remained in castrated rats. The sexual differences in castrated rats are considered to be due to the exposure to sexual hormones before four weeks of age, when castration was conducted. In the present study, following the administration of HDBB during the preweaning period, similar changes in all examined parameters were observed at the same doses in both sexes. These findings clearly show no gender-related differences in HDBB toxicity in preweaning rats, suggesting that a development at around three to six weeks of age contributes to sexual variations in HDBB toxicity, at least in part.

Gender-related differences in HDBB toxicity were found not only for hepatotoxicity, but also for the reduction of body weight, hematotoxicity, cardiac toxicity, etc., in the previous 28-day and/or 52-week studies using young rats (Hirata-Koizumi et al., 2007, 2008a). Thus, they might be caused by differences in the blood concentration of causative substances (e.g., HDBB or its metabolites) between sexes. A number of reports have been published on the sexual variations in toxicokinetic determinants, such as hepatic metabolism (Gad, 2006) and membrane transporter in various organs, including the kidneys and intestine (Morris et al., 2003). Coleman et al. (1990) reported that



higher sensitivity of male rats to hematotoxicity of dapsone, which is a major component of the multidrug regimen for the treatment of leprosy, was due to the greater capacity for the N-hydroxylation. Another example was an amino acid antitumor agent, acivicin, of which the LD<sub>50</sub> was much higher in male mice than that in females. McGovren et al. (1981) showed that the plasma half-time was much longer in female mice and speculated that the sexual variation may be related to differences in the renal excretion.

For gender-related differences in toxicokinetic determinants, many mechanistic studies have been reported on the metabolic enzyme cytochrome P450 (CYP) (Waxman and Chang, 2005). In rats, a subset of CYPs is expressed in a sex-dependent fashion. It was reported that ovariectomy reduced the hepatic expression of female-specific/predominant CYPs, but this did not lead to the expression of male-specific CYP enzyme in female rats. If female-specific/predominant metabolic enzymes have an intimate involvement in the detoxication of HDBB, our previous results, showing the higher susceptibility of male young rats to HDBB toxicity than females, and increased susceptibility by castration of females, could be explained. Interestingly, in rat liver, the difference in CYP expression between sexes is not apparent until puberty (Waxman and Chang, 2005). This is consistent with our present results that there was no gender-related difference in HDBB hepatotoxicity in preweaning rats. Mode and Gustafsson (2006) reported that brain centers involved in the hypothalamo-pituitary control of hepatic sex-dependent metabolism in adults are irreversibly programmed by neonatal androgen exposure, which might explain why sexual variation in HDBB toxicity was not completely abolished by castration at four weeks of age.

In order to clarify the cause of gender differences, we are currently performing a toxicokinetic study of HDBB, which includes the identification of metabolites and the related metabolic enzyme as well as measurement of the blood concentration of HDBB both after single and repeated administration of HDBB to young and preweaning rats.

## CONCLUSION

The current results showed that oral administration of HDBB to preweaning rats caused hepatotoxicity at 2.5 mg/kg and above in both sexes. The gender-related difference in toxic susceptibility to HDBB, which was observed in young rats, was not detected in preweaning rats.

## ACKNOWLEDGMENTS

This study was supported by the Ministry of Health, Labour and Welfare, Tokyo, Japan.

## REFERENCES

- Agarwal, D. K., Misra, D., Agarwal, S., Seth, P. K., Kohli, J. D. (1982). Influence of sex hormones on parathion toxicity in rats: antiacetylcholinesterase activity of parathion and paraoxon in plasma, erythrocytes, and brain. *J. Toxicol. Environ. Health*. 9:451-459.
- Alexander, B., Guzail, M. A., Foster, C. S. (1997). Morphological changes during hepatocellular maturity in neonatal rats. *Anat. Rec.* 248:104-109.
- Bartlett, M. S. (1937). Properties of sufficiency and statistical tests. *Proc. R. Soc. Lond. Ser. A* 160:268-282.
- Cattley, R. C., Popp, J. A. (2002). Liver: In: Haschek, W. M., Rousseaux, C. G., Wallig, M. A., eds. *Handbook of Toxicologic Pathology*, 2nd ed., Vol. 2. San Diego, California, USA: Academic Press, pp. 187-225.
- Coleman, M. D., Tingle, M. D., Winn, M. J., Park, B. K. (1990). Gonadal influence on the metabolism and haematological toxicity of dapsone in the rat. *J. Pharm. Pharmacol.* 42:698-703.
- Coleman, M. D., Winn, M. J., Breckenridge, A. M., Park, B. K. (1990). Sex-dependent sensitivity to dapsone-induced methaemoglobinaemia in the rat. *Biochem. Pharmacol.* 39:805-809.
- Dunnett, C. W. (1964). New tables for multiple comparisons with a control. *Biometrics* 20:482-491.
- Gad, S. C. (2006). Metabolism. In: Gad, S. C., ed. *Animal Models in Toxicology*, 2nd ed. Boca Raton, Florida, USA: CRC Press, pp. 217-247.
- Glaister, J. R. (1992). Histopathology of target organs—cardiovascular: In: *Principles of Toxicological Pathology (Japanese version supervised by Takahashi, M.J.)*. Tokyo: Soft Science Inc., pp.135-142.
- Harris, R. Z., Benet, L. Z., Schwartz, J. B. (1995). Gender effects in pharmacokinetics and pharmacodynamics. *Drugs* 50:222-239.
- Hirata-Koizumi, M., Watari, N., Mukai, D., Imai, T., Hirose, A., Kamata, E., Ema, M. (2007). A 28-day repeated dose toxicity study of ultraviolet absorber 2-(2'-hydroxy-3',5'-di-tert-butylphenyl)benzotriazole in rats. *Drug Chem. Toxicol.* 30: 327-341.
- Hirata-Koizumi, M., Ogata, H., Imai, T., Hirose, A., Kamata, E., Ema, M. (2008a). A 52-week repeated dose toxicity study of ultraviolet absorber 2-(2'-hydroxy-3',5'-di-tert-butylphenyl)benzotriazole in rats. *Drug Chem. Toxicol.* 31:81-96.
- Hirata-Koizumi, M., Matsuyama, T., Imai, T., Hirose, A., Kamata, E., Ema, M. (2008b). Gonadal influence on the toxicity of 2-(2'-hydroxy-3',5'-di-tert-butylphenyl) benzotriazole in rats. *Drug Chem. Toxicol.* 31:115-126.
- Hollander, M., Wolfe, D. A. (1973). *Nonparametric Statistical Methods*. New York: John Wiley and Sons.
- Knuckles, M. E., Inyang, F., Ramesh, A. (2004). Acute and subchronic oral toxicity of fluoranthene in F-344 rats. *Ecotoxicol. Environ. Saf.* 59:102-108.
- McGovren, J. P., Neil, G. L., Chan, P. J., Stewart, J. C. (1981). Sex- and age-related mouse toxicity and disposition of the amino acid antitumor agent, acivicin. *J. Pharmacol. Exp. Ther.* 216:433-440.
- METI (Ministry of Economy, Trade and Industry of Japan). (2006). 2-(2H-1,2,3-benzotriazole-2-yl)-4,6-di-tert-butylphenol (In Japanese), document distributed in Committee on Safety of Chemical Substances, Chemical

- Substances Council, 30 June 2006. Available at: <http://www.meti.go.jp/committee/materials/g60705aj.html> Accessed on September 19, 2007.
- Mode, A., Gustafsson, J. A. (2006). Sex and the liver—a journey through five decades. *Drug Metab. Rev.* 38:197–207.
- Morris, M. E., Lee, H. J., Predko, L. M. (2003). Gender differences in the membrane transport of endogenous and exogenous compounds. *Pharmacol. Rev.* 55:229–240.
- Muraoka, Y., Itoh, F. (1980). Sex difference of mercuric chloride-induced renal tubular necrosis in rats—from the aspect of sex differences in renal mercury concentration and sulfhydryl levels. *J. Toxicol. Sci.* 5:203–214.
- Nishino, H., Nakajima, K., Kumazaki, M., Fukuda, A., Muramatsu, K., Deshpande, S. B., Inubushi, T., Morikawa, S., Borlongan, C. V., Sanberg, P. R. (1998). Estrogen protects against while testosterone exacerbates vulnerability of the lateral striatal artery to chemical hypoxia by 3-nitropropionic acid. *Neurosci. Res.* 30:303–312.
- Ogirima, T., Tano, K., Kanehara, M., Gao, M., Wang, X., Guo, Y., Zhang, Y., Guo, L., Ishida, T. (2006). Sex difference of adenine effects in rats: renal function, bone mineral density, and sex steroidogenesis. *Endocr. J.* 53:407–413.
- Raheja, K. L., Linscheer, W. G., Cho, C. (1983). Hepatotoxicity and metabolism of acetaminophen in male and female rats. *J. Toxicol. Environ. Health.* 12:143–158.
- Vidair, C. A. (2004). Age dependence of organophosphate and carbamate neurotoxicity in the postnatal rat: extrapolation to the human. *Toxicol. Appl. Pharmacol.* 196:287–302.
- Walthall, K., Cappon, G. D., Hurtt, M. E., Zoetis, T. (2005). Postnatal development of the gastrointestinal system: a species comparison. *Birth Defects Res. B Dev. Reprod. Toxicol.* 74:132–156.
- Wang, R. H., Schorer-Apelbaum, D., Weinstock, M. (2001). Testosterone mediates sex difference in hypothermia and cholinesterase inhibition by rivastigmine. *Eur. J. Pharmacol.* 433:73–79.
- Waxman, D. J., Chang, T. K. (2005). Hormonal regulation of liver cytochrome P450 enzymes. In: Ortiz de Montellano, P. R., ed. *Cytochrome P450—Structure, Mechanism, and Biochemistry*, 3rd ed. New York: Kluwer Academic/ Plenum Publishers, pp. 347–376.
- Wilcoxon, F. (1945). Individual comparisons by ranking methods. *Biometrics Bull.* 1:80–83.
- Zoetis, T., Hurtt, M. E. (2005a) Species comparison of anatomical and functional renal development. *Birth Defects Res. B Dev. Reprod. Toxicol.* 68:111–120.
- Zoetis, T., Hurtt, M. E. (2005b) Species comparison of lung development. *Birth Defects Res. B Dev. Reprod. Toxicol.* 68:121–124.