FIGURE LEGENDS

FIGURE 1. Cross sections of rat soleus muscles after 16 days of saline or chloroquine treatment. The left denervated muscle of saline- **(c)** and chloroquine **(d)**-treated rat shows moderate muscle fiber atrophy. A large number of dense granular bodies and vacuoles (arrowhead) are present in the denervated muscle from chloroquine-treated rats **(d)** but are absent in denervated muscles from saline-treated rats (c) and innervated muscles from saline- (a) and chloroquine-treated rats **(b)**. Stained with hematoxylin-eosin (H&E). *Bar* = 50μm

FIGURE 2. Immunofluoresence for anti-20S proteasome **(a, b)** and anti-ubiquitin **(c, d)** antibodies in innervated and denervated rat soleus muscles after 16 days of chloroquine treatment. A strong positive reaction for proteasome **(b)** and ubiquitin **(d)** is often observed in the cytoplasm, primarily in small atrophic fibers, and within the vacuoles in the denervated muscles of chloroquine-treated rats. *Bar* = 50μm

FIGURE 3. **(a)** Changes in ubiquitin mRNA levels in innervated and denervated rat soleus muscles on days 4, 8 and 16 of saline or chloroquine treatment. Points represent means ± standard deviations (vertical lines). Number of rats per group = 5. ○, innervated muscle from saline-treated rats; ●, denervated muscles from saline-treated rats; □, innervated muscle from chloroquine-treated rats; ■, denervated muscle from chloroquine-treated rats. $^{*}p < 0.05$; $^{**}p < 0.02$; $^{***}p < 0.01$ versus the value for innervated muscle from saline-treated rats.

FIGURE 4. Changes in MuRF1 mRNA levels in innervated and denervated soleus muscles on days 4, 8 and 16 of saline and chloroquine treatment. Points represent means ± standard deviations (vertical lines). Number of rats per group = 5. ○, innervated muscle from saline-treated rats; ●, denervated muscle from saline-treated rats; □, innervated muscle from chloroquine-treated rats; ■, denervated muscle from chloroquine-treated rats. $^{*}p < 0.05$; $^{**}p < 0.02$; $^{***}p < 0.01$ versus the value for innervated muscle from saline-treated rats.

FIGURE 5. Changes in atrogin-1/MAFbx mRNA in innervated and denervated rat soleus muscles on days 4, 8 and 16 of saline or chloroquine treatment. Points represent means ± standard deviations (vertical lines). Number of rats per group = 5. ○, innervated muscles from saline-treated rats; ●, denervated muscles from saline-treated rats; □, innervated muscle from chloroquine-treated rats; ■, denervated muscle from chloroquine-treated rats. $^{*}p < 0.05$; $^{**}p < 0.02$; $^{***}p < 0.01$ versus the value for innervated muscle from saline-treated rats

For Peer Review Only

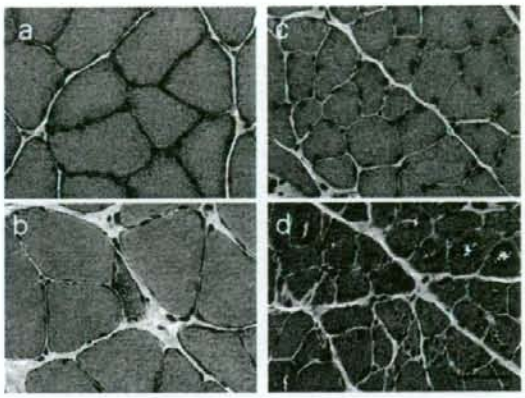

FIGURE 1. Cross sections of rat soleus muscles after 16 days of saline or chloroquine treatment. The left denervated muscle of saline- (c) and chloroquine (d)-treated rat shows moderate muscle fiber atrophy. A large number of dense granular bodies and vacuoles (arrowhead) are present in the denervated muscle from chloroquine-treated rats (d) but are absent in denervated muscles from saline-treated rats (c) and innervated muscles from saline- (a) and chloroquine-treated rats (b). Stained with hematoxylin-eosin (H&E). Bar = 50□Êm

275x190mm (96 x 96 DPI)

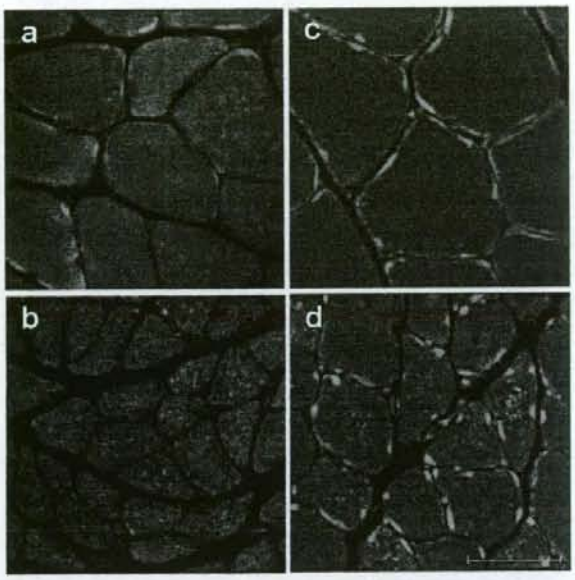

FIGURE 2. Immunofluoresence for anti-20S proteasome (a, b) and anti-ubiquitin (c, d) antibodies in innervated and denervated rat soleus muscles after 16 days of chloroquine treatment. A strong positive reaction for proteasome (b) and ubiquitin (d) is often observed in the cytoplasm, primarily in small atrophic fibers, and within the vacuoles in the denervated muscles of chloroquine-treated rats. Bar = 50□Êm
254x190mm (96 x 96 DPI)

Fig. 3

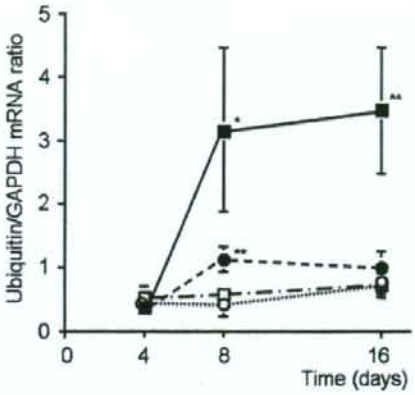

FIGURE 3. (a) Changes in ubiquitin mRNA levels in innervated and denervated rat soleus muscles on days 4, 8 and 16 of saline or chloroquine treatment. Points represent means □} standard deviations (vertical lines). Number of rats per group = 5. □□, innervated muscle from saline-treated rats; □□, denervated muscles from saline-treated rats; □ , innervated muscle from chloroquine-treated rats; □I, denervated muscle from chloroquine-treated rats. *p < 0.05; **p < 0.02; ***p < 0.01 versus the value for innervated muscle from saline-treated rats.

275x190mm (96 x 96 DPI)

Fig. 4

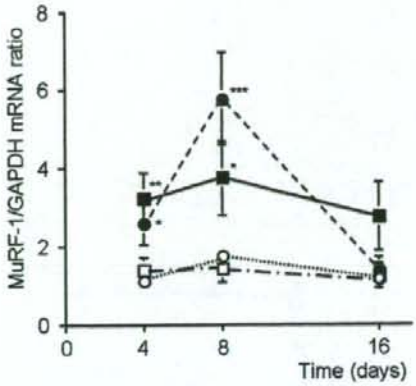

FIGURE 4. Changes in MuRF1 mRNA levels in innervated and denervated soleus muscles on days 4, 8 and 16 of saline and chloroquine treatment. Points represent means □} standard deviations (vertical lines). Number of rats per group = 5. □□, innervated muscle from saline-treated rats; □□, denervated muscle from saline-treated rats; □ , innervated muscle from chloroquine-treated rats; □i, denervated muscle from chloroquine-treated rats. *p < 0.05; **p < 0.02; ***p < 0.01 versus the value for innervated muscle from saline-treated rats.

275x190mm (96 x 96 DPI)

Fig. 5

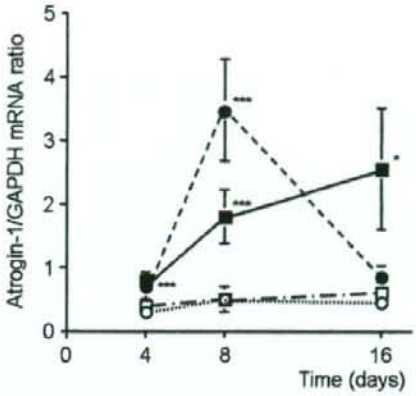

FIGURE 5. Changes in atrogin-1/MAFbx mRNA in innervated and denervated rat soleus muscles on days 4, 8 and 16 of saline or chloroquine treatment. Points represent means □} standard deviations (vertical lines). Number of rats per group = 5. □□, innervated muscles from saline-treated rats; □□, denervated muscles from saline-treated rats; □ , innervated muscle from chloroquine-treated rats; □I, denervated muscle from chloroquine-treated rats. *p < 0.05; **p < 0.02; ***p < 0.01 versus the value for innervated muscle from saline-treated rats

275x190mm (96 x 96 DPI)

Outlet Shoppers Elbow

To the Editor:

Elbow pain is a relatively common patient complaint. The following case illustrates a possibly overlooked cause.

CASE HISTORY

A 54-year-old healthy right-handed woman presented with severe elbow pain. She had traveled to Maine to visit her daughter who was attending college. During the afternoon, she visited a local town that is famous for outlet shopping. After a 3-hour shopping expedition in which she used her credit card repeatedly and also carried multiple bulky paper bags, she began to notice a twinge of pain on the extensor aspect of her forearm just distal to the right elbow. She showed her elbow to her husband (a rheumatologist) at dinner. On examination, there was exquisite tenderness located at the common extensor origin. In addition, there was pain with full extension and with resisted extension of the wrist and fingers. A diagnosis of lateral epicondylitis was made and the woman was treated conservatively with good results.

This case illustrates that among other hazards, shopping can be a potential cause of painful elbow tendonitis. Although it is still unclear as to what the pathophysiologic mechanism was, there are possible theories:

First, the usual method used to present a credit card is with a grip using the first 3 digits, followed by extension of the hand and wrist towards the cashier. Repetitive extension of the credit card is 1 possible cause.

Another possible reason is the use of forearm muscles to carry bulky bags.

Also, it seems that most shoppers lift the arms up and down (with the bags) when looking through the sales racks. Trying on clothes in the dressing room also requires repetitive use of the forearms. As pointed out by the woman's daughter, "shopping is a true sport."

Regardless of the mechanism though, it seems that shopping—particularly heroic shopping- is not an innocuous activity. I would like to term this condition "Outlet Shoppers Elbow." As some physicians seem to favor the use of eponyms, I suggest this condition be known as, "Freeport Forearm syndrome."

Nathan Wei, MD, FACP, FACR
Arthritis and Osteoporosis Center of Maryland

Rheumatoid Arthritis Accompanied by Parkinson Disease

To the Editor:

A recent report in the JCR noted that Parkinson disease (PD) can cause deformities mimicking rheumatoid arthritis (RA).[1] PD can also coexist with RA. Extrapyramidal symptoms are thought to be uncommon in patients with RA[2–4] but one report described about 25% of RA patients with extrapyramidal symptoms.[5] This letter describes a patient with a primary diagnosis of RA and coexisting Parkinson disease, and discuss a possible pathogenetic link between RA and PD.

A 52-year-old woman had developed polyarthritis and was diagnosed as having RA. Although she was treated with bucillamine and methotrexate, pain persisted. After 8 years, she consulted our hospital with a request for herbal medicine. She had moderate pain, slight deformity and swelling of multiple joints of both hands. The duration of her morning stiffness was about 45 minutes, and x-ray of both hands revealed erosions at the wrist joints. There were no significant findings on physical examination of the neck, chest, and abdomen. Laboratory data were as follow: hemoglobin:10.9g/dL, erythrocyte sedimentation rate: 37mm/h, C-reactive protein: 0.8mg/dl, rheumatoid factor: 199IU/mL. Hepatic, renal and thyroid function was normal.

Traditional herbal medicine[6] (Keishinieppiitto-ka-ryojutubu; Uchida Co. Ltd, Tokyo, Japan) was prescribed per mouth daily. Two years later, she complained of disturbance in walking, although her joint symptoms had improved and C-reactive protein was reduced to 0.1mg/dL. The patient did not demonstrate hypertension, diabetes, hypercholesterolemia, or other atherosclerotic risk factors. Although doing well with her RA, neurologic examination demonstrated masked face and rigidity in the left limbs with bradykinesia. Hyper-reflexia was detected at the knees. There was no resting tremor on mental calculation loading. Although there were no findings on brain MRI, treatment with pergolide mesilate improved neurologic symptoms. Thus, her symptoms were diagnosed as due to PD (Yahr II–III) accompanying RA. After 2 years follow-up, treatment with pergolide mesilate (450

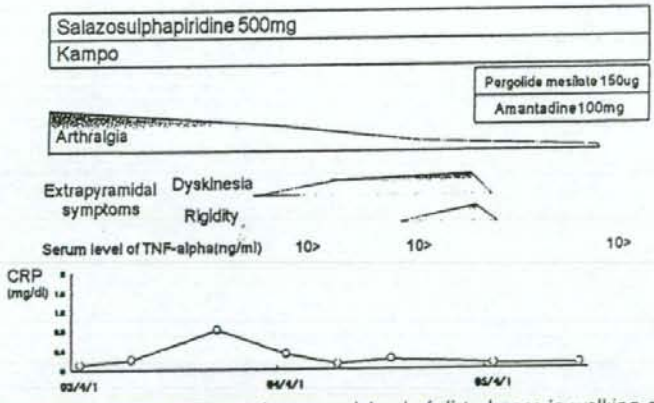

FIGURE 1. Clinical course. The patient complained of disturbance in walking due to rigidity in the left limbs with bradykinesia in January 2005. Treatment with pergolide mesilate improved the extrapyramidal symptoms. There was no elevation of the serum TNF-alpha level during the disease course. CRP, C-reactive protein; TNF, tumor necrosis factor.

μg/d), levodopa (150mg/d), salazosulfapyridine (500mg/d) and Keishinieppiittoka-ryojutubu had resulted in remission of RA and yahr III PD (Fig. 1).

The frequency of PD among RA patients was reported to be 2/87 (2.3%).[5] Thus, we considered that patients with RA and coexisting PD are not less prevalent than conventionally understood.

It would seem that extrapyramidal type rigidity in patients with RA might be detected easily, because joint examination in arthritis patients includes passive movement of the extremities by the examiner. However, as RA patients usually complain of stiffness, swelling and pain in the joints of the extremities, we speculate that it may be difficult to detect slight extrapyramidal symptoms such as lead-pipe phenomenon until cogwheel rigidity appears.

We propose that it is possible that there is a copathogenetic link between RA and PD in the present case. Parkinsonism associated with immunologic diseases was previously reported in systemic lupus erythematosus,[7] Behcet disease[8] and RA, and an inflammatory pathomechanism for PD was proposed. There can be up-regulation of major histocompatibility complex molecules in PD brains,[9] and that the levels of beta2-microglobulin, the light-chain of major histocompatibility complex, can be increased in striata of PD patients.[10] Subsequently, the accumulation of inflammatory cytokines in the substantia nigra of PD patients further supported a role in chronic inflammation.[11] Epidemiological evidence has also shown that chronic treatment with NSAIDs reduces the risk of PD.[12]

TNF-α, which is strongly involved in the development of joint inflammation in RA patients, is also associated with neuron-death. TNF-α may be toxic to mesencephalic dopamine neurons.[13] Inactivation of TNF-α receptors attenuated cell death in the experimental model of PD.[14,15] These data suggest that a high serum level of TNF-α in RA patients may be associated with coexisting PD. In contrast, Hrycaj et al reported a patient with severe PD in RA after treatment with infliximab.[5] Therefore, we checked the serum levels of TNF-α in the present patient. As shown in the clinical course (Fig. 1), when the extrapyramidal symptoms occurred, we did not find a high concentration of TNF-α. Generally, neuroinflammation is not only detrimental to neurons but also associated with neuroprotection. When systemic inflammation in RA patients impedes neuroprotection, PD may simultaneously occur in RA patients. To elaborate this hypothesis, further surveillance and basic studies will be required.

Toshiaki Kogure, MD, PhD
Takeshi Tatsumi, MD, PhD
Department of Integrated Japanese Oriental Medicine
Gunma University Graduate School of Medicine
Showa-machi Maebashi Gunma 371-8511
Japan

Yuka Kaneko, MD, PhD
Koich Okamoto, MD, PhD
Department of Neurology
Gunma University Graduate School of Medicine
Showa-machi Maebashi Gunma 371-8511
Japan
tkogure@showa.gunma-u.ac.jp

REFERENCES

1. Melikoglu MA, Sezer I, Kacar C. Rheumatoid like hand deformities in Parkinson disease. *J Clin Rheumatol*. 2007;13:236–237.
2. Hrycaj P, Korczowska I, Lacki K. Severe Parkinson's disease in rheumatoid arthritis patient treated with infliximab. *Rheumatology*. 2003;42:702–703.
3. Machtey I. Neurological signs in RA patients receiving gold. *Br J Rheumatol*. 1996;35:804.
4. Rizzo G, Scaglione C, Lopane G, et al. Parkinsonism in Caplan's syndrome. *Neurol Sci*. 2006;27:67–69.
5. Ertan S, Fresko I, Apaydm H, et al. Extrapyramidal type rigidity in rheumatoid arthritis. *Rheumatology*. 1999;38:627–630.
6. Terasawa K. Introduction. In: KAMPO *Japanese Oriental Medicine; insights from clinical cases*. Tokyo: KK Standard McIntyre; 1993:1–13.
7. Garcia-Moreno JM, Charcon J. Juveniele parkinsonism as a manifestation of systemic lupus erythematosus: case report and review of the literature. *Mov Disord*. 2002;17:1329–1335.
8. Bogdanova D, Milanov I, Georgiev D. Parkinsonian syndrome as a neurogical manifestation of Behcet's disease. *Can J Neuro Sci*. 1998;25:82–85.
9. Akiyama H, Itagaki S, McGeer PL. Major histocompatibility complex antigen expression on rat microglia following epidural kainic acid lesions. *J Neurosci Res*. 1988;20:147–157.
10. Mogi M, Harada M, Kondo T, et al. Brain beta 2-microglobulin levels are elevated in the striatum in Parkinson's disease. *J Neural Transm Park Dis Dement Sect*. 1995;9:87–92.
11. Hartmann A, Hunot S, Hirsch EC. Inflammation and dopaminergic neuronal loss in Parkinson's disease: a complex matter. *Exp Neurol*. 2003;184:561–564.
12. Schiess M. Non steroidal anti-inflammatory drugs protect against Parkinson neurodegeneration: can an NSAID a day keep Parkinson disease away? *Arch Neurol*. 2003;60:1043–1044.
13. McGuire SO, Ling ZD, Lipton JW, et al. Tumor necrosis factor alpha is toxic to embryonic mesencephalic dopamine neurons. *Exp Neurol*. 2001;169:219–230.
14. Wu DC, Jackson-Lewis V, Vila M, et al. Blockade of microglial activation is neuroprotective in the 1-methyl-4-phenyl-1,2,3,6- tetrahydropyridine mouse model of Parkinson disease. *J Neurosci*. 2002;22:1763–1771.
15. Gayle DA, Ling Z, Tong C, et al. Lipopolysaccharide (LPS)-induced dopamine cell loss in culture: roles of tumor necrosis factor-alpha, interleukin-1beta, and nitric oxide. *Brain Res Dev Brain Res*. 2002;31:133:27–35.

Brief Communication

Journal of Child Neurology
Volume 23 Number 2
February 2008 228-230
© 2008 Sage Publications
10.1177/0883073807307973
http://jcn.sagepub.com
hosted at
http://online.sagepub.com

Steroid-Responsive Chronic Cerebellitis With Positive Glutamate Receptor δ2 Antibody

Masaya Kubota, MD, PhD, and Yukitoshi Takahashi, MD, PhD

We report the clinical course of a 4-year-old girl with chronic cerebellitis (onset 2 days after diphtheria-pertussis-tetanus vaccination at 1 year and 7 months old) associated with anti-glutamate receptor δ2 antibody, who improved dramatically with steroid therapy (methylprednisolone pulse therapy plus oral prednisolone). Recently, it has been reported that the anti-glutamate receptor δ2 selectively expressed at the postsynaptic site of parallel fiber–Purkinje cell synapses has an important role in cerebellar function in the developing brain. The present case suggests that anti-glutamate receptor δ2 antibody plays a primary role in an immune-mediated process causing chronic cerebellar symptoms, and the lesion site seems to be localized to the parallel fiber–Purkinje cell synapse. Because the cerebellum is strongly involved in language acquisition as well as motor development, treatment must facilitate time for language learning while reducing the side effects of the corticosteroid therapy.

Keywords: chronic cerebellitis; glutamate receptor δ2

Because postinfectious acute cerebellar ataxia in childhood is generally benign and self-limited, no specific treatment is required. However, in some cases unlike acute cerebellar ataxia, unusual long-term cerebellar symptoms persist and therapeutic intervention is necessary. Recently, extensive molecular genetic studies have revealed the essential role of glutamate receptor δ2 in cerebellar functions, and glutamate receptor δ2 mutant mice or mice treated with specific antibody to glutamate receptor δ2 showed impairments in various cerebellar functions.[1–6] At present, the clinical relevance of glutamate receptor δ2 dysfunction is not fully understood. We herein report the clinical course of a 4-year-old girl with chronic cerebellitis associated with anti-glutamate receptor δ2 antibody who improved dramatically with steroid treatment, despite the absence of any therapy for 1 year and 8 months after onset.

From the Department of Pediatrics (Pediatric Neurology), Metropolitan Hachioji Children's Hospital, Hachioji-city, Tokyo, Japan.

Address correspondence to: Masaya Kubota, MD, PhD, Department of Pediatrics (Pediatric Neurology), Metropolitan Hachioji Children's Hospital, Hachioji-city, Tokyo, Japan. e-mail: mkmegped@opal .plala.or.jp.

Kubota M, Takahashi Y. Steroid-responsive chronic cerebellitis with positive glutamate receptor δ2 antibody. *J Child Neurol*. 2008;23:228-230.

Case Report

This 4-year-old Korean girl had been quite healthy with normal psychomotor development until nystagmus and ataxic gait appeared at the age of 1 year and 7 months. Her family history was unremarkable. Two days later, she showed an unstable wide-based gait and could not sit steadily. She was given a diphtheria-pertussis-tetanus vaccination 2 days before onset of the cerebellar symptoms. Despite the diagnosis of acute cerebellar ataxia, the symptoms gradually worsened. A study of the cerebrospinal fluid showed cell count of 20/μL (15 lymphocytes), protein 10 mg/dL, and glucose 60 mg/dL. Two weeks after onset, prednisolone (1 mg/kg weight) was given every day for 2 weeks, but the symptoms persisted. Thereafter, the patient was not given any medication for 1 year and 8 months.

When she was admitted to our hospital for further evaluation at the age of 2 years and 9 months, she could not stand or walk without help due to cerebellar ataxia and could not speak at all. Excessive salivation was noticed. No definite nystagmus was observed. Basically, muscle tone of the extremities was hypotonic and intentional tremor of the upper extremities was observed. Deep tendon reflexes were induced normally, and no pathological reflexes were evident. On brain magnetic resonance imaging (MRI) and single-photon emission computed tomography (SPECT),

Table 1. Anti-Glutamate Receptor δ2 and ε2 Antibody Before and After Steroid Introduction (at 2 y and 9 mo, and 3 y and 9 mo)

	IgG-ε2	IgM-ε2	IgG-δ2	IgM-δ2
Cerebrospinal fluid (2 y and 9 mo)	−	−	−	+
Cerebrospinal fluid (3 y and 9 mo)	−	−	+	+
Serum (2 y and 9 mo)	−	−	−	−
Serum (3 y and 9 mo)	−	−	−	−

no structural or metabolic abnormalities were demonstrated. Urine vanilmandelic acid and homovanillic acid were within normal limits, and no abnormal mass was found on an abdominal ultrasound study. As shown in Table 1, anti-glutamate receptor δ2–immunoglobulin (Ig) M in cerebrospinal fluid was found to be positive and anti-glutamate receptor δ2-IgG was still negative. At that time, serum (simultaneously studied serum) anti-glutamate receptor-IgM and anti-glutamate receptor-IgG were negative. (For details regarding the detection of anti-glutamate receptor-IgM and -IgG, see the Methods section of Takahashi et al.[7]) Because the production of anti-glutamate receptor δ2 antibody in the central nervous system might be closely related to the patient's cerebellar symptoms, we selected corticosteroid therapy, with a high-dose methylprednisolone as a first-line treatment (at the age of 3 years and 3 months). Three weeks after the methylprednisolone pulse therapy (30 mg/kg weight divided for 3 days), the parents recognized a gradual improvement in truncal ataxia, resulting in walking with help more smoothly than before, and excess salivation disappeared. Subsequently, we started oral prednisolone (1 mg/kg weight, on alternate days) for further improvement. Surprisingly, 2 months later, she could walk without help and could eat food with a spoon by herself. Five months after the beginning of corticosteroid therapy, the truncal and limb ataxia almost disappeared so that she could walk fast and steadily. Concerning articulation, she could imitate a single phoneme or limited words and occasionally began to speak some words 6 months after therapy. One year later (at the age of 4 years and 2 months), she could run steadily and walk up stairs well, and began to speak two-word sentences. At present (4 years and 8 months of age), she has begun to speak intelligible Japanese and Korean. Then we started to taper the dose of corticosteroid. Thus, corticosteroid therapy improved the long-term cerebellar symptoms without any adverse effects, despite the treatment interval of 1 year and 8 months. At the age of 3 years and 9 months, anti-glutamate receptor δ2-IgM in the cerebrospinal fluid was found to be still positive and anti-glutamate receptor δ2-IgG had converted to positive (Table 1). Anti-glutamate receptor ε2 antibody was not detected in cerebrospinal fluid or serum.

Lymphocyte Stimulation Test by Glutamate Receptor δ2 and Diphtheria-Pertussis-Tetanus Vaccine

The patient's peripheral blood mononuclear cells were cultured in the presence of D33 (cell line expressing glutamate receptor δ2 subunits) alone and 6250 × diluted diphtheria-pertussis-tetanus vaccine alone, and in the presence of D33 and 6250 × diluted diphtheria-pertussis-tetanus vaccine at the age of 4 years. Responses were assessed by [^{3}H]thymidine incorporation in lymphocytes. Results were expressed as counts per minute (cpm) and as stimulation indexes (= cpm of cultures with drug/cpm of cultures without drug). Results were considered positive when the stimulation index was higher than 2. As shown in Table 2, stimulation index for the mixture of D33 (glutamate receptor δ2 subunits) and diphtheria-pertussis-tetanus vaccine was 5.17, whereas stimulation index for diphtheria-pertussis-tetanus vaccine alone was 2.7 and stimulation index for D33 alone was 1.32.

Discussion

Because the long-term cerebellar symptoms in our case differed from simple acute cerebellar ataxia, we diagnosed her as having chronic cerebellitis associated with anti-glutamate receptor δ2 antibody. Since Takahashi et al[7] reported opsoclonus-myoclonus syndrome with positive anti-glutamate receptor δ2 antibody, our case may be categorized in the broad opsoclonus-myoclonus syndrome spectrum, but the main symptoms in our case were limb and truncal ataxia and language developmental delay without apparent myoclonic movement in ocular and limb muscle.

The present case suggests that anti-glutamate receptor δ2 antibody plays a primary role in the pathogenesis of chronic cerebellar ataxia; furthermore, the lesion was functional and not destructive, because a dramatic improvement in cerebellar symptoms was brought about by corticosteroid therapy, despite the absence of any therapy for 1 year and 8 months after onset. The absence of structural and metabolic abnormality in MRI and SPECT also supports this idea. The anti-glutamate receptor δ2 antibody was generated exclusively in the central nervous system because the antibody was positive only in the cerebrospinal fluid before and after corticosteroid introduction. In cases with persistent cerebellar symptoms, the presence of anti-glutamate receptor δ2 antibody in cerebrospinal fluid should be checked.

The glutamate receptor δ2 was selectively expressed at the postsynaptic site of parallel fiber–Purkinje cell synapses,[1] and glutamate receptor δ2 mutant mice showed impairments in long-term depression at these synapses,[2] motor learning,[3,5] stabilization of the parallel fiber–Purkinje cell synapse,[2,4] and refinement of climbing fiber innervation

Table 2. Results of Lymphocyte Stimulation Test by Glutamate Receptor δ2 and Diphtheria-Pertussis-Tetanus Vaccine at the Age of 4

	Control	Phytohemagglutinin	D33 (glutamate receptor δ2 subunit) (400 μg)	6250 × diluted diphtheria-pertussis-tetanus	D33 (glutamate receptor δ2 subunits) (400 μg) + 6250 × diluted diphtheria-pertussis-tetanus
Count per minute	320	83 453	423	863	1654
Stimulation index			1.32	2.7	5.17

to Purkinje cells.[2] In addition to these developmental abnormalities, Hirai et al[6] showed that application of an antibody specific for glutamate receptor δ2 to cultured Purkinje cells induced α-amino-3-hydroxy-5-methyl-4-isoxazolepropionic acid (AMPA) receptor endocytosis, attenuated synaptic transmission and abrogated long-term depression; moreover, adult mice treated with this antibody revealed cerebellar dysfunction without apparent morphological changes in Purkinje cells.

Taken together with these basic data, and positive anti-glutamate receptor δ2 antibody and dramatic effect of corticosteroid therapy on cerebellar symptoms in our case, the lesion site seems to be localized at the parallel fiber– Purkinje cell synapse.

Sugiyama et al[8] reported a similar case of chronic cerebellitis associated with anti-glutamate receptor δ2 antibody but the cerebellar symptoms fluctuated, despite a high-dose intravenous immunoglobulin and corticosteroid pulse therapy. The long-term use of corticosteroids may be necessary to suppress the disease process, because short-term corticosteroid therapy 2 weeks after the onset in our patient was not effective for the cerebellar symptoms.

The lymphocyte stimulation test showed that the mixture of D33 (glutamate receptor δ2 subunits) and diphtheria-pertussis-tetanus vaccine activated lymphocytes more intensely than D33 (glutamate receptor δ2 subunits) or diphtheria-pertussis-tetanus vaccine alone. Lymphocytes stimulated by the lymphocyte stimulation test are usually T cells. Although we could not confirm a subset of stimulated T cells (CD4+ or CD8+) by glutamate receptor δ2, activated effector T cells that could invade the central nervous system beyond the blood-brain barrier definitively exist in peripheral blood circulation. We speculate that these activated T cells are produced by cross-reaction using molecular mimicry after a diphtheria-pertussis-tetanus vaccination and play an important role in the subsequent onset of chronic cerebellitis.

On the retarded language development in our case, we must not regard it as a simple dysarthria but as a learning problem in which the cerebellum is strongly involved. The internal model was introduced to extend the cerebellar functions in voluntary movement, perception, and language. Ito[9,10] maintains the hypothesis that reorganization of the neuronal circuit by error-driven induction of long-term depression constitutes the major memory and learning mechanisms of the cerebellum. Therefore, treatment must facilitate time for language learning while reducing the side effects of corticosteroid therapy.

References

1. Araki K, Meguro H, Kushiya E, et al. Selective expression of the glutamate receptor channel delta 2 subunit in cerebellar Purkinje cells. *Biochem Biophys Res Commun*. 1993;197:1267-1276.
2. Kashiwabuchi N, Ikeda K, Araki K, et al. Impairment of motor coordination, Purkinje cell synapse formation, and cerebellar long-term depression in GluR δ2 mutant mice. *Cell*. 1995;81:245-252.
3. Funabiki K, Mishina M, Hirano T. Retarded vestibular compensation in mutant mice deficient in δ2 glutamate receptor subunit. *Neuroreport*. 1995;7:189-192.
4. Kurihara H, Hashimoto K, Kano M, et al. Impaired parallel fiber-Purkinje cell synapse stabilization during cerebellar development of mutant mice lacking the glutamate receptor δ2 subunit. *J Neurosci*. 1997;17:9613-9623.
5. Kishimoto Y, Kawahara S, Suzuki M, et al. Classical eyeblink conditioning in glutamate receptor subunit δ2 mutant mice is impaired in the delay paradigm but not in the trace paradigm. *Eur J Neurosci*. 2001;13:1249-1253.
6. Hirai H, Launey T, Mikawa S, et al. New role of delta2-glutamate receptors in AMPA receptor trafficking and cerebellar function. *Nat Neurosci*. 2003;6:869-876.
7. Takahashi Y, Nishimura S, Sakaguti N, et al. Autoantibodies against GluRδ2 in patients with opsoclonus-Myoclonus syndrome. *Neuroimmunology*. 2003;11:78.
8. Sugiyama N, Hamano S, Mochizuki M, et al. A case of chronic cerebellitis with anti-glutamate receptor delta 2 antibody. *No To Hattatsu*. 2004;36:60-63.
9. Ito M. *The Cerebellum and Neural Control*. New York, NY: Raven: 1984.
10. Ito M. Mechanisms of motor learning in the cerebellum. *Brain Res*. 2000;886:237-245.

ADAM8 in Allergy

Osamu Matsuno[*,1,2], Toshihide Kumamoto[3] and Yasunori Higuchi[4]

[1]*Division of Respiraory Disease, Osaka Minami Medical Center, Kawachinagano-City, Osaka 586-8521, Japan*

[2]*Division of Respiratory Disease and* [3] *Neurology, Department of Brain and Nerve Science, Oita University Faculty of Medicine, Ufu-City, Oita 879-5593, Japan*

[4]*Research Center for Applied Medical Engineering, Oita University, Yufu-City, Oita 879-5593, Japan*

Abstract: ADAM (a disintegrin and metalloprotease) family members are membrane-anchored proteins with wide ranging functions, including proteolytic cleavage of cell surface molecules, cell fusion, cell adhesion and intracellular signaling. ADAM8, also known as CD156a, is expressed mainly in cells of the immune system, such as monocytes, neutrophils, eosinophils, dendritic cells, and B cells. It can cleave a variety of substrates and is a sheddase for CD23 and L-selectin. ADAM8 has an important role in allergic inflammation.

ADAM8 mRNA expression is increased with disease progression in asthma. ADAM8 is strongly induced by allergens and Th2 cytokines in the lung in experimental asthma. Soluble ADAM8 is elevated in the bronchoalveolar lavage fluid of patients with eosinophilic pneumonia and has a physiologic role in protecting against allergic pulmonary disease in experimental murine asthma. Together, these findings support the view that ADAM8 might be a therapeutic target for allergic respiratory diseases. This review discusses novel strategies for immune intervention in allergic respiratory disease.

Keywords: ADAM8, inflammation, allergy, asthma, eosinophilic pneumonia.

INTRODUCTION

To date, 40 ADAM (a disintegrin and metalloprotease) membrane-anchoredproteins have been identified; of these 23 are human, and 7 of these (ADAM8, 9, 10, 17,19, 28, and 33) are expressed on cells that are potentially involved in the pathogenesis of asthma or allergy [1-2]. The basic structure of an ADAM family protein is well conserved and comprises a cysteine-rich domain, a disintegrin domain with adhesive properties, and a metalloprotease domain responsible for the ectodomain shedding of membrane proteins and for the cleavage of extracellular matrix components (Fig. **1**) [3]. These domains contain motifs with proline-rich SH3 binding sequences, suggesting that they are involved in intracellular signaling. Approximately half of the ADAMs contain the catalytic consensus sequence HEXXHHXXGXXHD in their metalloprotease domains and are therefore predicted to be catalytically active. Catalytically active ADAMs are usually activated by furin-catalyzed removal of the prodomain. ADAMs possess broad substrate specificities, as shedding of growth factors, cytokines, cell adhesion molecules, and receptors is often performed by these proteins. ADAMs substrates related to allergy and inflammatory diseases are implicated in the processing of precursor forms of proteins such as tumor necrosis factor (TNF)-α [4,5], amphiregulin [6,7], Interleukin (IL)-6R [8], IL-1RII [9], CD163 [10], TNF receptor I (TNFRI) [8-9], TNFRII [11,12], mononuclear phagocyte colony-stimulating factor receptor [13], CX3CL1 [14], CD23 [15, 16], and L-selectin [11-17].

Several ADAMs interact with integrins, and the disintegrin-like domain may be crucial for this function [18, 19]. Integrins are a cell-cell and cell-matrix receptor åsuperfamily composed of non-covalently linked heterodimers. Integrins have broad and significant biological roles in processes such as embryonic development, hematopoiesis, wound repair and immune response. The disintegrin-like domains of many ADAMs are capable of acting as integrin ligands. Integrins that interact with ADAM disintegrin-like domains include α4β1 [20, 21], α4β7 [22], α5β1 [23], α6β1 [24-27], α9β1 [28, 29], αvβ3 [30, 31], and αvβ5 [32]. Human ADAM15 is the only metaloprotease-disintegrin containing an Arg-Gly-Asp (RGD) sequence within the integrin-binding loop of the disintegrin domain [33], and this sequence binds to integrins αvβ3 [30] and α5β1 [23]. This integrin-mediated interaction of the disintegrin-like domains with the cell surface suggests that ADAMs function as cellular counter receptors.

DESCRIPTION OF ADAM8

ADAM8 (CD156a) is an 824-amino acid transmembrane protein coded by a gene located on chromosome 10q26.3 [33]. As embryonic development of the ADAM8-deficient mouse appears normal, ADAM8 does not seem to be essential for developmental processes. ADAM8-deficient mice do not exhibit any evident pathologic phenotype and the immune system does not appear to be impaired [34].

ADAM8 expression can be upregulated on various cell types by TNFα [35], interferon (IFN)γ, and lipolysaccharides (LPS) [36]. The expression of ADAM8 is increased after activation of the peroxisome proliferator-activated receptor γ (PPARγ) in the Mφ cell line [37]. PPARγ activation reduces the release of inflammatory cytokines, such as TNFα, IL-1α, and IL-6, and suppresses the expression of matrix metalloprotease 9 and inducible nitric oxide synthase [37]. In addition, mouse ADAM8 mRNA levels are increased by IL-4 and IL-13 stimulation [38]. ADAM8 has a very distinct expression pattern in Mφ, granulocytes, B cells, dendritic cells,

*Address correspondence to this author at the Division of Respiraory Disease, Osaka Minami Medical Center, Kawachinagano-city, Osaka 586-8521, Japan; Fax: +81-097-549-6502;
E-mail: matsuno@med.oita-u.ac.jp or matsuno@ommc-hp.jp

1871-5281/08 $55.00+.00 © 2008 Bentham Science Publishers Ltd.

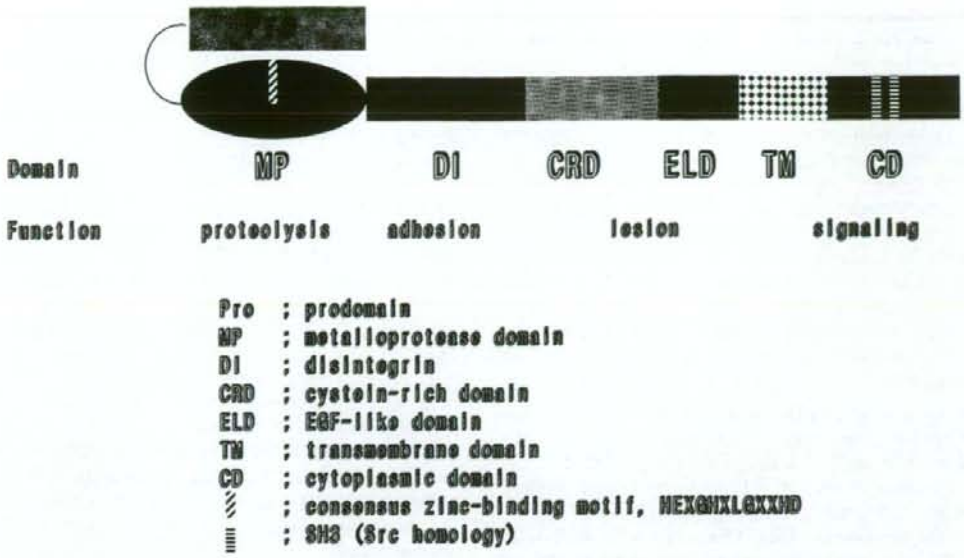

Fig. (1). Structure of ADAMs family protein.

neurons, and reactive glia cells [35, 39]. In the latter cell types, expression of ADAM8 is regulated by TNF-α in a dose-dependent manner [40]. Transcriptional regulation of ADAM8 by TNFα in several cell lines argues for a feedback mechanism in which ADAM8 regulates the TNFα susceptibility of cells by TNFRI cleavage; cleavage of TNFRI peptide, but not of TNFRII peptide, has already been demonstrated by peptide analysis [41, 42]. In contrast, the RNA expression pattern of ADAM8 does not change after *in vitro* incubation with different cytokines (IFNγ, TNFα, IL-4, IL-10) and LPS in human mononuclear cells [43].

Catalytically-active ADAMs are usually activated by furin-catalyzed removal of the prodomain. ADAM8 is not catalyzed by furin-like protease [35]. ADAM8 is processed by autocatalysis into two forms; one derived by the removal of a prodomain (90 kDa processed form) and the other a remnant protein (60 kDa) composed of the extracellular region, with a disintegrin domain at the aminoterminus. The processed form contains the metalloprotease (MP) domain responsible for the proteolytic activity of ADAM8, and the remnant form mediates cell adhesion [35]. ADAM8 might be processed into two soluble forms: a metalloprotease domain form and an ectodomain form. Soluble ADAM8 (sADAM8) forms are also possible serum markers in certain tumors, such as lung adenocarcinoma and renal cell carcinoma [44, 45]. ADAM8 overexpression is associated with a higher-stage lung cancer, prostate cancer, and pancreatic cancer, with shorter patient survival in renal cell carcinoma, and with increased invasiveness of brain tumors[44-47].Soluble ADAM8 levels concentration found in the synovial fluid of patients with rheumatoid arthritis are proportional to the degree of joint neutrophilic inflammation [48]. These findings suggest that ADAM8 is involved in tumor and inflammatory cell migration and invasion. In addition, recent reports demonstrate that a high concentration of ADAM8 in mid-trimester amniotic fluid is a risk factor for preterm delivery [49].

Biochemical characterization of recombinant expressed sADAM8 confirmed that it possesses catalytic activity and demonstrated that ADAM8 is activated through autocatalytic removal of its inhibitory prodomain [35, 50]. Naus *et al.* performed cleavage assays with recombinant sADAM8 and demonstrated strongly cleaved peptides, such as β-amyloid precursor protein (APP), low affinity IgG receptor (CD16, Fcγ-RIII), low affinity IgE receptor (CD23, FCεRII), fractalkine CX3CL1, L-selectin, P-selectin, glycoprotein ligand (PSGL-1), transforming growth factor (TGF-α), a close homologue of L1 (CHL1), myelin basic protein (MBP), and TNFα [41]. The metalloprotease domain with its proteolytic function is not inhibited by tissue inhibitors of metalloprotease (TIMPs), which is in contrast to the other proteolytic properties of ADAMs [50].

The disintegrin domain of ADAM8 affects cell adhesion [35, 51]. The ADAM8 disintegrin domain might be involved in neural cell adhesion and play an important role in experimental encephalomyelitis [51]. sADAM8 induces the formation of bone-resorbing osteoclasts and acts at the later stage of osteoclast differentiation and precursor fusion. Structure-function studies indicated that the disintegrin domain of ADAM8 mediates its effects on osteoclast formation. Recently, Rao *et al.* have identified the receptor for ADAM8 to be α9β1 integrin [52, 53].

INVOLVEMENT OF ADAM8 IN INFLAMMATION AND ALLERGY

A transgenic mouse overexpressing the ectodomain of ADAM8 under the control of the α1-antitrypsin (AT-MS2) was generated. These animals have attenuated casein-induced peritoneal leukocyte infiltration and downregulated the expression of L-selectin. The transgenic mice, however, are more susceptible to an oxazolone-induced contact hyper-

sensitivity reaction [54]. Thus, the response of AT-MS2 differs depending on the type of inflammation. Membrane-bound and active sADAM8 cleave L-selectin and CD23 from the plasma membrane [15]. ADAM8 cell surface expression is upregulated by the physical interaction of neutrophils with endothelial cells, suggesting a regulatory role for this metalloprotease in the initial phase of the adhesion cascade through the shedding of surface molecules that participate in the early neutrophil-endothelium interaction during the inflammatory response [48]. Keramiddaris *et al.* demonstrated a role for L-selectin in lymphocyte migration to the lung during an allergic inflammatory response [55]. Soluble L-selectin decreases neutrophil migration [56,57]. Thus, ADAM8-mediated L-selectin shedding might modulate the recruitment of additional leukocytes, acting as a negative feedback regulator.

The expression of L-selectin on the surface of lymphocytes and neutrophils may be modulated by an IgE-dependent mechanism. L-Selectin is downregulated from the lymphocyte surface in an anti-IgE antibody dose-dependent manner with a concomitant upregulation of soluble L-selectin in the supernatant [58]. Challenge with antibodies against CD23 induces the downregulation of L-selectin on the neutrophil surface [59]. Thus, the IgE-dependent mechanism might lead to direct neutrophil and lymphocyte extravasation into local inflammatory sites in allergic pathologic situations.

In lymphocytes, CD23 is an important component of the regulatory mechanism controlling IgE synthesis. The level of human and mouse sCD23 in the serum correlates directly with the level of serum and BAL IgE produced [60-63]. sCD23 acts to upregulate or downregulate the level of IgE produced by an activated human B cell [64-66], possibly by interacting with or without the CD21/CD19 complex [67-69], suggesting a regulatory role for sCD23 in the regulation of IgE levels [69-70]. CD23-deficient mice have increased serum IgE and bronchial hyperresponsiveness when compared with wild-type mice, suggesting a negative regulatory role for membrane CD23 in regulating IgE production [71,72]. Thus, ADAM8-mediated CD23 shedding might modulate the production of IgE, acting as an allergy regulator.

ADAM8 is highly expressed in eosinophils [15, 73]. A principal adhesive structure of the eosinophil is the podosome. Eosinophils have high cell-surface expression of ADAM8, which is concentrated in podosomes upon eosinophil adherence to VCAM-1. VCAM-1 supports specific eosinophil adhesion *via* α4β1 integrin. α9β1 integrin also mediates the migration of neutrophils through an activated human umbilical vein endothelial cell monolayer by interacting with VCAM-1 [74]. Adherent eosinophils clear VCAM-1 from the underlying substrate by a mechanism that is blocked by a metalloprotease inhibitor. Eosinophils degrade VCAM-1 in a metalloprotease-dependent manner [73].

Using a microarray detection system for gene expression in a murine model of asthma, King *et al.* demonstrated that ADAM8 is overexpressed in experimental asthmatic lung [38]. ADAM8 is an allergen-induced gene expressed during the induction of experimental asthma by a mechanism largely downstream of IL-4, IL-13, and STAT6 signaling [38]. Foley *et al.* demonstrated that ADAM8 mRNA is increased in asthma compared with control subjects and that protein expression is predominantly in the submucosal inflammatory cells and the lung epithelium in humans [75]. Expression of ADAM8 genes increases as asthma severity increases [75]. ADAM8 mRNA expression in sputum cells from patients with asthma was negatively correlates with the forced expiratory volume at the first second (FEV1.0) and positively correlates with eosinophils in the sputum, as well as neutrophils (76). We previously reported that sADAM8 has a physiologic role in protecting against experimental asthma in AT-MS2 [77]. Further, the sADAM8 and sVCAM-1 concentrations in the BALF are increased in acute eosinophilic pneumonia (AEP) and chronic eosinophilic pneumonia (CEP). The sCD23 concentration was elevated in AEP. In AEP, but not CEP, the sADAM8 concentration significantly correlates with the concentrations of both sVCAM and sCD23. sADAM8, sVCAM-1, and sCD23 concentrations in the BALF are not elevated, however, in drug-induced eosinophilic pneumonia (drug-EP). The pathogenesis of AEP, CEP, and drug-EP is distinct with regard to ADAM8 [78]. These results provide evidence for the involvement of ADAM8 in the orchestration of allergic lung inflammation.

ADAM8 is strongly expressed in inflammatory cells in asthma and eosinophilic pneumonia. Furthermore, the ADAM8-dependent activation of CD23, leading to the production of IgE and inflammatory cytokines, supports the potential role for ADAM8 in allergic and inflammatory processes. ADAM8 may have a role in leukocyte recruitment and mobilization and contribute to ectodomain shedding of CD23 and L-selectin, thereby making it a potential target for therapeutic intervention.

REFERENCES

[1] Huovila, A.P.; Turner, A.J.; Pelto-Huikko, M.; Kärkkäinen, I.; Ortiz, R.M. *Trends Biochem. Sci.*, **2005**, *30*, 41.

[2] Seals, D.F.; Courtneidge, S.A. *Genes Dev.*, **2003**, *17*, 7.

[3] White, J.M. *Curr. Opin. Cell Biol.*, **2003**, *15*, 598.

[4] Black, R.A.; Rauch, C.T.; Kozlosky, C.J.; Peschon, J.J.; Slack, J.L.; Wolfson, M.F.; Castner, B.J.; Stocking, K.L.; Reddy, P.; Srinivasan, S.; Nelson, N.; Boiani, N.; Schooley, K.A.; Gerhar, M.; Davis, R.; Fitzner, J.N.; Johnson, R.S.; Paxton, R.J.; March, C.J.; Cerretti, D.P. *Nature*, **1997**, *385*, 729.

[5] Moss, M.L.; Jin, S.L.; Milla, M.E.; Bickett, D.M.; Burkhart, W.; Carter, H.L.; Chen, W.J.; Clay, W.C.; Didsbury, J.R.; Hassler, D.; Hoffman, C.R.; Kost, T.A.; Lambert, M.H.; Leesnitzer, M.A.; McCauley, P.; McGeehan, G.; Mitchell, J.; Moyer, M.; Pahel, G.; Rocque, W.; Overton, L.K.; Schoenen, F.; Seaton, T.; Su, J.L.; Becherer, J.D. *Nature*, **1997**, *385*, 733.

[6] Hinkle, C.L.; Sunnarborg, S.W.; Loiselle, D.; Parker, C.E.; Stevenson, M.; Russell, W.E.; Lee, D.C. *J. Biol. Chem.*, **2004**, *279*, 24179.

[7] Gschwind, A.; Hart, S.; Fischer, O.M.; Ullrich, A. *EMBO J.*, **2003**, *22*, 2411

[8] Müllberg, J.; Durie, F.H.; Otten-Evans, C.; Alderson, M.R.; Rose-John, S.; Cosman, D.; Black, R.A.; Mohler, K.M. *J. Immunol.*, **1995**, *155*, 5198.

[9] Reddy, P.; Slack, J.L.; Davis, R.; Cerretti, D.P.; Kozlosky, C.J.; Blanton, R.A.; Shows, D.; Peschon, J.J.; Black, R.A. *J. Biol. Chem.*, **2000**, *275*, 14608.

[10] Hintz, K.A.; Rassias, A.J.; Wardwell, K.; Moss, M.L.; Morganelli, P.M.; Pioli, P.A.; Givan, A.L.; Wallace, P.K.; Yeager, M.P.; Guyre, P.M. *J. Leukoc. Biol.*, **2002**, *72*, 711.

[11] Peschon, J.J.; Slack, J.L.; Reddy, P.; Stocking, K.L.; Sunnarborg, S.W.; Lee, D.C.; Russell, W.E.; Castner, B.J.; Johnson, R.S.; Fitzner, J.N.; Boyce, R.W.; Nelson, N.; Kozlosky, C.J.; Wolfson, M.F.; Rauch, C.T.; Cerretti, D.P.; Paxton, R.J.; March, C.J.; Black, R.A. *Science*, **1998**, *282*, 1281.

[12] Mohan, M.J.; Seaton, T.; Mitchell, J,; Howe, A,; Blackburn, K.; Burkhart, W, ; Moyer, M,; Patel, I,; Waitt, G.M.; Becherer, J.D.; Moss, M.L.; Milla, M.E. *Biochemistry*, **2002**, *41*, 9462.

[13] Rovida, E.; Paccagnini, A., Del Rosso, M.; Peschon, J.; Dello Sbarba, P. *J. Immunol.*, **2001**, *166*, 1583.

[14] Garton, K.J.; Gough, P.J.; Blobel, C.P.; Murphy, G.; Greaves, D.R.; Dempsey, P.J.; Raines, E.W. *J. Biol. Chem.*, **2001**, *276*, 37993.

[15] Fourie, A.M.; Coles, F.; Moreno, V.; Karlsson, L. *J. Biol. Chem.*, **2003**, *278*, 30469.

[16] Weskamp, G.; Ford, J.W.; Sturgill, J.; Martin, S.; Docherty, A.J.; Swendeman, S.; Broadway, N.; Hartmann, D.; Saftig, P., Umland, S.; Sehara-Fujisawa, A.; Black, R.A.; Ludwig, A.; Becherer, J.D.; Conrad, D.H.; Blobel, C.P. *Nat. Immunol.*, **2006**, *7*, 1293.

[17] Gómez-Gaviro, M.; Dominguez-Luis, M.; Canchado, J.; Calafat, J.; Janssen, H.; Lara-Pezzi, E.; Fourie, A.; Tugores, A.; Valenzuela-Fernández, A.; Mollinedo, F.; Sánchez-Madrid, F.; Díaz-González, F. *J. Immunol.*, **2007**, *178*, 8053.

[18] Mochizuki, S.; Okada, Y. *Cancer Sci.*, **2007**, *98*, 621.

[19] Moss, M.L.; Bartsch, J.W. *Biochemistry*, **2004**, *43*, 7227.

[20] Tomczuk, M.; Takahashi, Y.; Huang, J.; Murase, S.; Mistretta, M.; Klaffky, E.; Sutherland, A.; Bolling, L.; Coonrod, S.; Marcinkiewicz, C.; Sheppard, D.; Stepp, M.A.; White, J.M. *Exp. Cell Res.*, **2003**, *290*, 68.

[21] Bridges, L.C.; Tani, P.H.; Hanson, K.R.; Roberts, C.M.; Judkins, M.B.; Bowditch, R.D. *J. Biol. Chem.*, **2002**, *277*, 3784.

[22] Bridges, L.C.; Sheppard, D.; Bowditch, R.D. *Biochem. J.*, **2005**, *387*, 101.

[23] Nath, D.,; Slocombe, P.M.; Stephens, P.E.; Warn, A.; Hutchinson, G.R.; Yamada, K.M.; Docherty, A.J.; Murphy, G. *J. Cell Sci.*, **1999**, *112*, 579.

[24] Almeida, E.A.; Huovila, A.P.; Sutherland, A.E.; Stephens, L.E.; Calarco, P.G.; Shaw, L.M.; Mercurio, A.M.; Sonnenberg, A.; Primakoff, P.; Myles, D.G.; White, J.M. *Cell*, **1995**, *81*,1095.

[25] Nath, D.; Slocombe, P.M.; Webster, A.; Stephens, P.E.; Docherty, A.J.; Murphy, G. *J. Cell Sci.*, **2000**, *113*, 2319.

[26] Bigler, D.; Takahashi, Y.; Chen, M.S.; Almeida, E.A.; Osbourne, L.; White, J.M. *J. Biol. Chem.*, **2000**, *275*, 11576.

[27] Takahashi, Y.; Bigler, D.; Ito, Y.; White, J.M. *Mol. Biol. Cell*, **2001**, *12*, 809.

[28] Eto, K.; Puzon-McLaughlin, W.; Sheppard, D.; Sehara-Fujisawa, A.; Zhang, X.P., Takada Y. *J. Biol. Chem.*, **2000**, *275*, 34922.

[29] Rao, H.; Lu, G.; Kajiya, H.; Garcia-Palacios, V.; Kurihara, N.; Anderson, J.; Patrene, K.; Sheppard, D.; Blair, H.C.; Windle, J.J.; Choi, S.J.; Roodman, G.D. *J. Bone Miner Res.*, **2006**, *21*,1657.

[30] Nath, D.; Slocombe, P.M.; Stephens, P.E.; Warn, A.; Hutchinson, G.R.; Yamada, K.M.; Docherty, A.J.; Murphy, G. *J. Cell Sci.*, **1999**, *112*, 579.

[31] Cal, S.; Freije, J.M.; López, J.M.; Takada, Y.; López-Otín, C. *Mol. Biol. Cell*, **2000**, *11*, 1457.

[32] Zhou, M.; Graham, R.; Russell, G.; Croucher, P.I. *Biochem. Biophys. Res. Commun.*, **2001**, *280*, 574.

[33] Yoshiyama, K.; Higuchi, Y.; Kataoka, M.; Matsuura, K.; Yamamoto, S. *Genomics*, **1997**, *41*, 56.

[34] Kelly, K.; Hutchinson, G.; Nebenius-Oosthuizen, D.; Smith, A.J.; Bartsch, J.W.; Horiuchi, K.; Rittger, A.; Manova, K.; Docherty, A.J.; Blobel, C.P. *Dev. Dyn.*, **2005**, *232*, 221.

[35] Schlomann, U.; Wildeboer, D.; Webster, A.; Antropova, O.; Zeuschner, D.; Knight, C.G.; Docherty, A.J.; Lambert, M.; Skelton, L.; Jockusch, H.; Bartsch, J.W. *J. Biol. Chem.*, **2002**, *277*, 48210.

[36] Kataoka, M.; Yoshiyama, K.; Matsuura, K.; Hijiya, N.; Higuchi, Y.; Yamamoto, S. *J. Biol. Chem.*, **1997**, *272*, 18209.

[37] Hodgkinson, C.P.; Ye, S. *Biochem. Biophys. Res. Commun.*, **2003**, *308*, 505.

[38] King, N.E.; Zimmermann, N.; Pope, S.M.; Fulkerson, P.C.; Nikolaidis, N.M.; Mishra, A.; Witte, D.P.; Rothenberg, M.E. *Am. J. Respir. Cell Mol. Biol.*, **2004**, *31*, 257.

[39] Richens, J.; Fairclough, L.; Ghaemmaghami, A.M.; Mahdavi, J.; Shakib, F.; Sewell, H.F. *Immunobiology*, **2007**, *212*, 29.

[40] Schlomann, U.; Rathke-Hartlieb, S.; Yamamoto, S.; Jockusch, H.; Bartsch, J.W. *J. Neurosci.*, **2000**, *20*, 7964.

[41] Naus, S.; Reipschläger, S.; Wildeboer, D.; Lichtenthaler, S.F.; Mitterreiter, S.; Guan, Z.; Moss, M.L.; Bartsch, J.W. *Biol. Chem.*, **2006**, *387*, 337.

[42] Moss, M.L.; Bartsch, J.W. *Biochemistry*, **2004**, *43*, 7227.

[43] Dehmel, T.; Janke, A.; Hartung, H.P.; Goebel, H.H.; Wiendl, H.; Kieseier, B.C. *Neurobiol. Dis.*, **2007**, *25*, 665.

[44] Ishikawa, N.; Daigo, Y.; Yasui, W.; Inai, K.; Nishimura, H.; Tsuchiya, E.; Kohno, N.; Nakamura, Y. *Clin. Cancer Res.*, **2004**, *10*, 8363.

[45] Roemer, A.; Schwettmann, L.; Jung, M.; Stephan, C.; Roigas, J.; Kristiansen; G.; Loening, S.A.; Lichtinghagen, R.; Jung, K. *J. Urol.*, **2004**, *172*, 2162.

[46] Wildeboer, D.; Naus, S.; Amy Sang, Q.X., Bartsch, J.W.; Pagenstecher, A. *J. Neuropathol. Exp. Neurol.*, **2006**, *65*, 516.

[47] Valkovskaya, N.; Kayed, H.; Felix, K.; Hartmann, D.; Giese, N.A.; Osinsky, S.P.; Friess, H.; Kleeff, J. *J. Cell Mol. Med.*, **2007**, *11*, 1162.

[48] Gómez-Gaviro, M.; Dominguez-Luis, M.; Canchado, J.; Calafat, J.; Janssen, H.; Lara-Pezzi, E.; Fourie, A.; Tugores, A.; Valenzuela-Fernández, A.; Mollinedo, F.; Sánchez-Madrid, F.; Díaz-González, F. *J. Immunol.*, **2007**, *178*, 8053.

[49] Vrachnis, N.; Malamitsi-Puchner, A.; Samoli, E.; Botsis, D.; Iliodromiti, Z.; Baka, S.; Hassiakos, D.; Creatsas, G. *J. Soc. Gynecol. Investig.*, **2006**, *13*, 186.

[50] Amour, A.; Knight, C.G.; English, W.R.; Webster, A.; Slocombe, P.M.; Knäuper, V.; Docherty, A.J.; Becherer, J.D.; Blobel, C.P.; Murphy, G. *FEBS Lett.*, **2002**, *524*, 154.

[51] Schluesener, H.J. *J. Neuroimmunol.*, **1998**, *87*, 197.

[52] Rao, H.; Lu, G.; Kajiya, H.; Garcia-Palacios, V.; Kurihara, N.; Anderson, J.; Patrene, K.; Sheppard, D.; Blair, H.C.; Windle, J.J.; Choi, S.J.; Roodman, G.D. *J. Bone Miner. Res.*, **2006**, *21*, 1657.

[53] Roodman, G.D. *Ann. N. Y. Acad. Sci.*, **2006**, *1068*, 100.

[54] Higuchi, Y.; Yasui, A.; Matsuura, K.; Yamamoto, S. *Pathobiology*, **2002**, *70*, 47.

[55] Keramidaris, E.; Merson, T.D.; Steeber, D.A.; Tedder, T.F.; Tang, M.L. *J. Allergy Clin. Immunol.*, **2001**, *107*, 734.

[56] Ferri, L.E.; Swartz, D.; Christou, N.V. *Crit. Care Med.*, **2001**, *29*, 117.

[57] Watson, S.R.; Fennie, C.; Lasky, L.A. *Nature*, **1991**, *349*, 164.

[58] Monteseirín, J.; Llamas, E.; Sánchez-Monteseirín, H.; Bonilla, I.; Camacho, M.J.; Conde, J.; Sobrino, F. *Allergy*, **2001**, *56*, 164.

[59] Monteseirín, J.; Chacón, P.; Vega, A.; Sánchez-Monteseirín, H.; Asturias, J.A.; Martínez, A.; Guardia, P.; Pérez-Cano, R.; Conde, J. *Clin. Exp. Allergy*, **2005**, *35*, 1204.

[60] Lecoanet-Henchoz, S.; Plater-Zyberk, C.; Graber, P.; Gretener, D.; Aubry, J.P.; Conrad, D.H.; Bonnefoy, J.Y. *Eur. J. Immunol.*, **1997**, *27*, 2290.

[61] Christie, G.; Barton, A.; Bolognese, B.; Buckle, D.R.; Cook, R.M.; Hansbury, M.J.; Harper, G.P.; Marshall, L.A.; McCord, M.E.; Moulder, K.; Murdock, P.R.; Seal, S.M.; Spackman, V.M.; Weston, B.J.; Mayer, R.J. *Eur. J. Immunol.*, **1997**, *27*, 3228.

[62] Pène, J.; Rousset, F.; Brière, F.; Chrétien, I.; Wideman, J.; Bonnefoy, J.Y.; De Vries, J.E. *Eur. J. Immunol.*, **1988**, *18*, 929.

[63] Di Lorenzo, G.; Drago, A.; Pellitteri, M.E.; Candore, G.; Colombo, A.; Potestio, M.; Di Salvo, A.; Mansueto, S.; Caruso, C. *Allergy Asthma Proc.*, **1999**, *20*, 119.

[64] Mayer, R.J.; Bolognese, B.J.; Al-Mahdi, N.; Cook, R.M.; Flamberg, P.L.; Hansbury, M.J.; Khandekar, S.; Appelbaum, E.; Faller, A.; Marshall, L.A. *Clin. Exp. Allergy*, **2000**, *30*, 719.

[65] Saxon, A.; Ke, Z.; Bahati, L.; Stevens, R.H. *J. Allergy Clin. Immunol.*, **1990**, *86*, 333.

[66] Gould, H.J.; Sutton, B.J.; Beavil, A.J.; Beavil, R.L.; McCloskey, N.; Coker, H.A.; Fear, D.; Smurthwaite, L. *Annu. Rev. Immunol.*, **2003**, *21*, 579.

[67] Aubry, J.P.; Pochon, S.; Graber, P.; Jansen, K.U.; Bonnefoy, J.Y. *Nature*, **1992**, *358*, 505.

[68] Hibbert, R.G.; Teriete, P.; Grundy, G.J.; Beavil, R.L.; Reljic, R.; Holers, V.M.; Hannan, J.P.; Sutton, B.J.; Gould, H.J.; McDonnell, J.M. *J. Exp. Med.*, **2005**, *202*, 751.

[69] Pongratz, G.; McAlees, J.W.; Conrad, D.H.; Erbe, R.S.; Haas, K.M.; Sanders, V.M. *J. Immunol.*, **2006**, *177*, 2926.

[70] Bonnefoy, J.Y.; Gauchatm, J.F.; Life, P.; Graber, P.; Aubry, J.P.; Lecoanet-Henchoz, S. *Int. Arch. Allergy Immunol.*, **1995**, *107*, 40.

[71] Yu, P.; Kosco-Vilbois, M.; Richards, M.; Köhler, G.; Lamers, M.C. *Nature* **1994**, *369*, 753.

[72] Riffo-Vasquez, Y.; Spina, D.; Thomas, M.; Gilbey, T.; Kemeny, D.M.; Page, C.P. *Clin. Exp. Allergy*, **2000**, *30*, 728.

[73] Johansson, M.W.; Lye, M.H.; Barthel, S.R.; Duffy, A.K.; Annis, D.S.; Mosher, D.F. *Am. J. Respir. Cell Mol. Biol.*, **2004**, *31*, 413.

[74] Taooka, Y.; Chen, J.; Yednock, T.; Sheppard, D. *J. Cell Biol.*, **1999**, *145*, 413.

[75] Foley, S.C.; Mogas, A.K.; Olivenstein, R.; Fiset, P.O.; Chakir, J.; Bourbeau, J.; Ernst, P.; Lemière, C.; Martin, J.G.; Hamid, Q. *J. Allergy Clin. Immunol.*, **2007**, *119*, 863.

[76] Paulissen, G.; Rocks, N.; Quesada-Calvo, F.; Gosset, P.; Foidart, J.M.; Noel, A.; Louis, R.; Cataldo, D.D. *Mol. Med.*, **2006**, *12*, 171.

[77] Matsuno, O.; Miyazaki, E.; Nureki, S.; Ueno, T.; Kumamoto, T.; Higuchi, Y. *Immunol. Lett.*, **2006**, *102*, 67.

[78] Matsuno, O,; Miyazaki, E.; Nureki, S.; Ueno, T.; Ando, M.; Ito, K.; Kumamoto, T.; Higuchi, Y. *Int. Arch. Allergy Immunol.*, **2007**, *142*, 285.

Received: April 21, 2008 **Revised: May 9, 2008** **Accepted: May 12, 2008**

Journal of Neuroimmunology 205 (2008) 155–159

Contents lists available at ScienceDirect

Journal of Neuroimmunology

journal homepage: www.elsevier.com/locate/jneuroim

CSF neurofilament and soluble TNF receptor 1 levels in subacute sclerosing panencephalitis

Takeshi Matsushige [a], Takashi Ichiyama [a,*], Banu Anlar [b], Jun Tohyama [c], Keiko Nomura [d], Yushiro Yamashita [e], Susumu Furukawa [a]

[a] Department of Pediatrics, Yamaguchi University Graduate School of Medicine, Yamaguchi, Japan
[b] Department of Pediatrics, Hacettepe University Faculty of Medicine, Turkey
[c] Department of Pediatrics, Nishi-Niigata Chuo National Hospital, Japan
[d] Department of Child Development, Kumamoto University School of Medicine, Japan
[e] Department of Pediatrics and Child Health, Kurume University School of Medicine, Japan

ARTICLE INFO

Article history:
Received 20 June 2008
Received in revised form 16 September 2008
Accepted 16 September 2008

Keywords:
Cerebrospinal fluid
Neurofilament
Soluble tumor necrosis factor receptor 1
Subacute sclerosing panencephalitis

ABSTRACT

Neurofilament (NF) is one of the major cytoskeleton proteins of neurons and sTNFR1 is thought to reflect the true biological activity of TNF-α. To evaluate the levels of the heavy subunit of neurofilament (NF-H) and soluble TNF receptor 1 (sTNFR1) in cerebrospinal fluid (CSF) as biomarkers of clinical severity of subacute sclerosing panencephalitis (SSPE), concentrations of NF-H and sTNFR1 in CSF of 34 patients with SSPE and in control subjects were measured by ELISA. The CSF NF-H levels were significantly higher in patients with SSPE than in controls ($p<0.0001$), and those in patients in Jabbour stage III were significantly higher than in patients in stage II ($p=0.015$). The CSF sTNFR1 levels in SSPE patients were significantly higher than those in controls ($p=0.004$), but there were no significant differences in CSF sTNFR1 levels between patients in Jabbour stages II and III. There was a significant correlation between CSF NF-H and sTNFR1 levels in patients with SSPE ($p=0.011$). We suggest that CSF NF-H levels can be used as a marker of development of neuronal degeneration in SSPE, and that TNF-α modifies the neurodestructive pathogenesis in SSPE.

© 2008 Elsevier B.V. All rights reserved.

1. Introduction

Subacute sclerosing panencephalitis (SSPE) is a fatal progressive neurodegenerative disorder of childhood caused by persistent infection of measles virus. Brain biopsies and postmortem histopathological examinations show evidence of neuronal loss, demyelination, astrogliosis, neurofibrillary tangles and infiltration of inflammatory cells (Garg, 2002). Neurofilament (NF) is a major structural element of neurons and is composed of three subunits: the light (NF-L), medium (NF-M) and heavy (NF-H) subunits (Petzold, 2005). NF is a specific biomarker for axonal injury, degeneration and neuronal loss, and detection of NF in CSF provides information on the degree of neuronal injury (Petzold, 2005). The phosphorylated forms of NF-H are resistant to proteases and are particularly concentrated in larger diameter axons (Petzold, 2005; Shaw et al., 2005). NF-H is released into CSF in axonal injury and can be detected by enzyme-linked immunosorbent assay (ELISA) (Petzold, 2005; Shaw et al., 2005). It has been reported that NF-L or NF-H in CSF is increased in neurological diseases, including multiple sclerosis, hydrocephalus, subarachnoid hemorrhage, brain damage after cardiac arrest, AIDS dementia complex, Parkinsonian syndromes, and Guillain–Barré syndrome (Abdulle et al., 2007; Brettschneider et al., 2006; Lewis et al., 2008; Mellgren et al., 2007; Nylén et al., 2006; Petzold, 2005; Petzold et al., 2005, 2006; Rosén et al., 2004; Tullberg et al., 2007; Zetterberg et al., 2007b).

Tumor necrosis factor-α (TNF-α) increases blood-brain vascular permeability, damages vascular endothelial cells, and induces necrosis of myelin and oligodendrocytes (Mustafa et al., 1989; Salmaj and Raine, 1988; Sato et al., 1988). Moreover, it has been suggested that TNF-α modifies the pathogenesis of SSPE (Anlar et al., 2001; Hofman et al., 1991; Ichiyama et al., 1997; Ichiyama et al., 2006; Nagano et al., 1994), and expression of TNF-α has been shown in endothelial and glial cells in the brain of SSPE patients (Anlar et al., 2001; Hofman et al., 1991; Nagano et al., 1994). We previously reported that the CSF level of soluble TNF receptor 1 (sTNFR1), which reflects the true biological activity of TNF-α (Duncombe and Brenner, 1988; Engelmann et al., 1990; Seckinger et al., 1988), was elevated in a boy with SSPE (Ichiyama et al., 1997). In the present study, we investigated the usefulness of CSF NF-H and sTNFR1 levels as biomarkers for SSPE, and

* Corresponding Author. Department of Pediatrics, Yamaguchi University Graduate School of Medicine, 1-1-1 Minamikogushi, Ube, Yamaguchi 755-8505, Japan. Tel.: +81 836 22 2258; fax: +81 836 22 2257.
E-mail address: ichiyama@yamaguchi-u.ac.jp (T. Ichiyama).

0165-5728/$ – see front matter © 2008 Elsevier B.V. All rights reserved.
doi:10.1016/j.jneuroim.2008.09.011

Table 1
Clinical characteristics of SSPE patients and control subjects

	SSPE patients $N=34$	Control subjects $N=27$
Age (median, range)	8.0 years, 3–23 years	6.0 years, 2–14 years
Gender (male: female)	26:8	18:9
Jabbour stage	Stage I $N=1$ Stage II $N=24$ Stage III $N=9$	

we analyzed the relationship between the levels of CSF NF-H and sTNFR1.

2. Patients and methods

2.1. Subjects with subacute sclerosing panencephalitis (SSPE)

CSF samples were obtained from 34 children with SSPE (27 in Turkey from 2001 to 2007; 7 in Japan from 1994 to 2007) (Table 1). The criteria for diagnosis of SSPE were (1) progressive neurological disorder, particularly mental or motor deterioration, associated with a positive history or the presence of myoclonic jerks; (2) positive CSF measles antibody titer determined by ELISA; (3) high serum ELISA values comparable to those of cases that fulfilled criteria 1 and 2. All samples for ELISA were stored at −70 °C.

The SSPE patients were separated into groups based on the Jabbour stage (Jabbour et al., 1975): one patient was in Jabbour stage I, which is characterized by psychointellectual dysfunction; 24 were in stage II, characterized by convulsive and motor signs; 9 were in stage III, characterized by deterioration of the state of consciousness to coma; and none were in stage IV, characterized by coma.

We were able to obtain serial CSF samples from a 10-year-old Japanese boy with SSPE (Fig. 1). He had acute measles at the age of three months and his first symptoms were frequent falls and impaired attention. Brain MRI showed no abnormal findings at that time. His serum anti-measles IgG value was >128 and CSF was >12.8 ng/ml by EIA, and SSPE was diagnosed 2 weeks after the onset of falls. Intraventricular human leukocyte interferon-α (Sumiferon, Dainippon Sumitomo Pharma, Osaka, Japan) therapy (300×10^4 IU once weekly to 100×10^4 IU once daily for 5 consecutive days) and ribavirin (virazole; ICN Pharmaceuticals, Costa Mesa, CA, USA) therapy (1 to 3 mg/kg once daily for 5 consecutive days) were started via an Ommaya reservoir. However, the course was progressive with deterioration of intellectual and motor function, and difficulties with speech and standing. MRI showed brain atrophy 20 weeks after onset, the patient fell into a coma after 40 weeks, and MRI showed severe brain atrophy at 51 weeks after onset.

2.2. Control subjects

The control subjects were 27 afebrile and noninfectious Japanese children with neurological disorders such as psychomotor delay or epilepsy (Table 1). CSF samples were obtained in routine analysis and all the controls had normal CSF cell counts. There was no significant difference in age or sex between the SSPE patients and controls by the Mann–Whitney U test or Chi-square test. Informed consent was obtained from the parents of the patients and controls.

2.3. Determination of NF-H and sTNFR1 concentrations

The CSF concentrations of NF-H were measured with a phosphorylated NF-H ELISA kit (EnCor Biotechnology Inc., Gainesville, FL, USA) (Shaw et al., 2005). An anti-phosphorylated NF-H rabbit monoclonal coating antibody was adsorbed onto polystyrene microwells. NF-H present in the samples or the standard bound to the adsorbed antibodies, and the NF-H / antibody complex was detected with an alkaline phosphatase-conjugated secondary antibody. The amount of captured NF-H was measured by determining the color produced by reagents using an ELISA plate reader, and the absorbance was measured at 405 nm. The detection limit was 0.1 ng/ml. The samples were analyzed in duplicate. The intra-assay coefficient of variation (CV) and the inter-assay CV were calculated to be 2.2% and 8.9%, respectively. The analyst was blinded to all other data. The CSF concentrations of sTNFR1 were measured with a sTNFR1 ELISA kit (Bender Medsystems, Vienna, Austria) as described previously (Ichiyama et al., 1996a,b). The lower detection limit for sTNFR1 was 0.05 ng/ml.

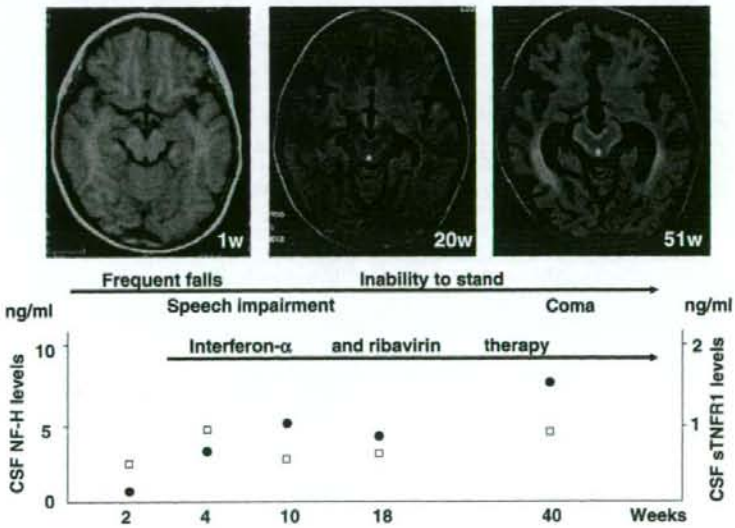

Fig. 1. Clinical course, serial brain MRI, CSF NF-H and sTNFR1 levels in a 10-year-old Japanese boy with SSPE. Circles and squares indicate CSF NF-H and sTNFR1 levels, respectively.

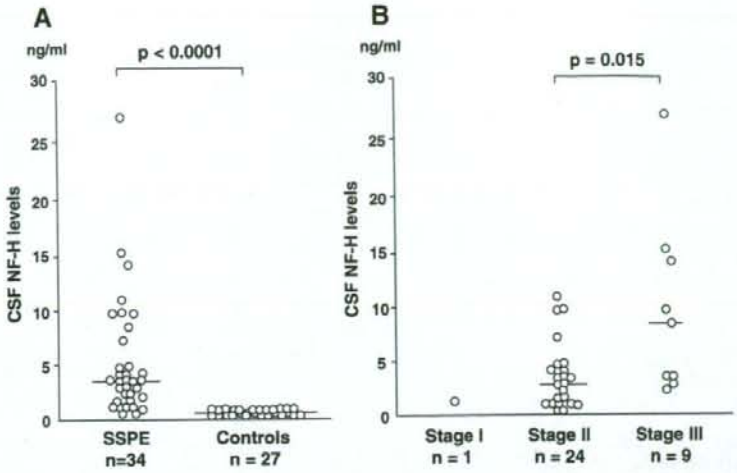

Fig. 2. A, CSF NF-H levels of SSPE patients and control subjects. B, CSF NF-H levels of SSPE patients at each Jabbour stage. Horizontal lines indicate median values.

2.4. Statistical analysis

Data below the lower detection limits were regarded as half values of the limits. Differences between SSPE patients and controls and among SSPE groups were analyzed with Chi-square test. Correlations between CSF NF-H and sTNFR1 levels were analyzed by Spearman's rank correlation coefficient test. p-values less than 0.05 were taken to be significant. Analysis and calculations were performed using SPSS v. 12.0 (SPSS, Inc., Chicago, IL, USA).

3. Results

The CSF NF-H levels in SSPE patients (3.3 ng/ml, <0.1–26.9 ng/ml as median, range) were significantly higher than those in control subjects (0.05 ng/ml, <0.1–0.58 ng/ml) as shown in Fig. 2A ($p<0.0001$). The median values of the CSF NF-H levels of patients in Jabbour stages I, II and III were 2.0, 3.3, and 8.3 ng/ml, respectively (Fig. 2B), with the CSF NF-H levels in stage III being significantly higher than those in stage II ($p=0.015$). The CSF sTNFR1 levels in SSPE patients (0.97 ng/ml, 0.23–2.06 ng/ml as median, range) was also significantly higher than that in controls (0.44 ng/ml, <0.05–1.54 ng/ml as median, range) as shown in Fig. 3A ($p=0.004$), but there was no significant difference in the CSF sTNFR1 level between SSPE patients in Jabbour stages II and III (Fig. 3B). There was a significant correlation between CSF NF-H and sTNFR1 levels in SSPE patients ($p=0.011$) (Fig. 4).

The clinical course, serial brain MRI, CSF NF-H and sTNFR1 levels of a 10-year-old Japanese boy with SSPE are shown in Fig. 1. His CSF NF-H level was 0.94 ng/ml two weeks after onset, and increased to 4.5, 6.5 and 4.9 ng/ml at 4, 10, and 18 weeks, respectively. The patient fell into a coma after 40 weeks, with a CSF NF-H level of 8.3 ng/ml. The CSF sTNFR1 levels 2, 4, 10, 18 and 40 weeks after onset were 0.50, 0.97,

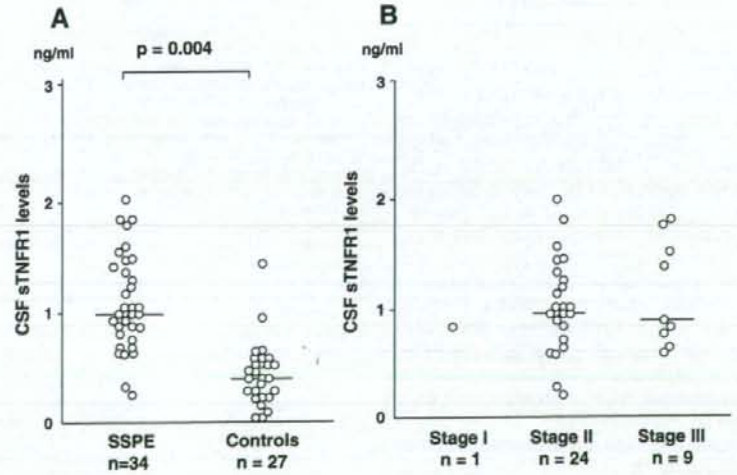

Fig. 3. A, CSF sTNFR1 levels of SSPE patients and control subjects. B, CSF sTNFR1 levels of SSPE patients at each Jabbour stage. Horizontal lines indicate median values.