

disease (65 [44%] vs 113 [75%]); myelosuppression and other adverse events (41 [28%] vs 25 [17%]); withdrawal of consent (13 [9%] vs 6 [4%]); and indications for surgery (seven [5%] vs one [0.7%]). Similar proportions of patients in the two groups received second-line chemotherapy (S-1 plus cisplatin: 110 of 148 [74%] patients; and S-1 alone: 113 of 150 [75%] patients). After the end of treatment with S-1 and cisplatin or S-1 alone, taxane-based regimens were given to 75 of 148 (51%) patients assigned to S-1 plus cisplatin and 60 of 150 (40%) of those assigned S-1 alone; and irinotecan-based regimens were given to 21 of 148 (14%) patients assigned to S-1 plus cisplatin and 22 of 150 (15%) of those assigned to S-1 alone. Additionally, 14 of 150 (9%) patients in the S-1 group received cisplatin.

In exploratory subgroup analyses by use of a Cox proportional-hazards model, the effect of S-1 plus cisplatin on overall survival was greater in patients with peritoneal metastasis than in those without peritoneal metastasis, and also in patients without target tumours than in those with target tumours. Interactions of treatment group with these factors were significant, ie, $p=0.02$ with peritoneal metastasis and $p=0.01$ with target tumours (figure 3). Target tumours were absent in a larger proportion of patients assigned to S-1 plus cisplatin (61 of 148 [41%] patients) than in those assigned to S-1 alone (44 of 150 [29%]), but those assigned to S-1 plus cisplatin had slightly higher proportions of patients with unfavourable prognostic factors, such as peritoneal metastases (51 of 148 [34%] patients vs 36 of 150 [24%] patients) and diffuse-type carcinomas (103 of 148 [70%] patients vs 89 of 150 [59%] patients).

Discussion

Our study shows that median survival was significantly longer in patients with advanced gastric cancer assigned to S-1 plus cisplatin (13.0 months) than in those assigned to S-1 alone (11.0 months; $p=0.04$). In previous phase III clinical trials in patients with gastric cancer, median survival of 9.2 months was reported for docetaxel and cisplatin plus fluorouracil (DCF) by the V325 Study Group,¹¹ 10.5 months was reported for combined capecitabine and cisplatin (XP) by Kang and colleagues,¹⁴ and 9.9 months was reported for combined epirubicin, cisplatin, and fluorouracil (ECF) and 11.2 months for combined capecitabine, oxaliplatin, and epirubicin (EOX) by Cunningham and co-workers.¹⁵ To our knowledge, no previously reported well-tolerated chemotherapy regimen in patients with advanced gastric cancer has obtained a median survival time of 12 months or longer. We postulated that median survival time of longer than 12 months and median progression-free survival of 6.0 months was ascribable to synergism between S-1 and cisplatin. Furthermore, to our knowledge, our trial is the first phase III trial to show better findings with combination chemotherapy than with monotherapy for the treatment of advanced gastric cancer. The addition of cisplatin to S-1 was well-tolerated, and treatment could be continued as specified in the protocol; we recorded no treatment-related deaths. These findings suggest that S-1 plus cisplatin might be a

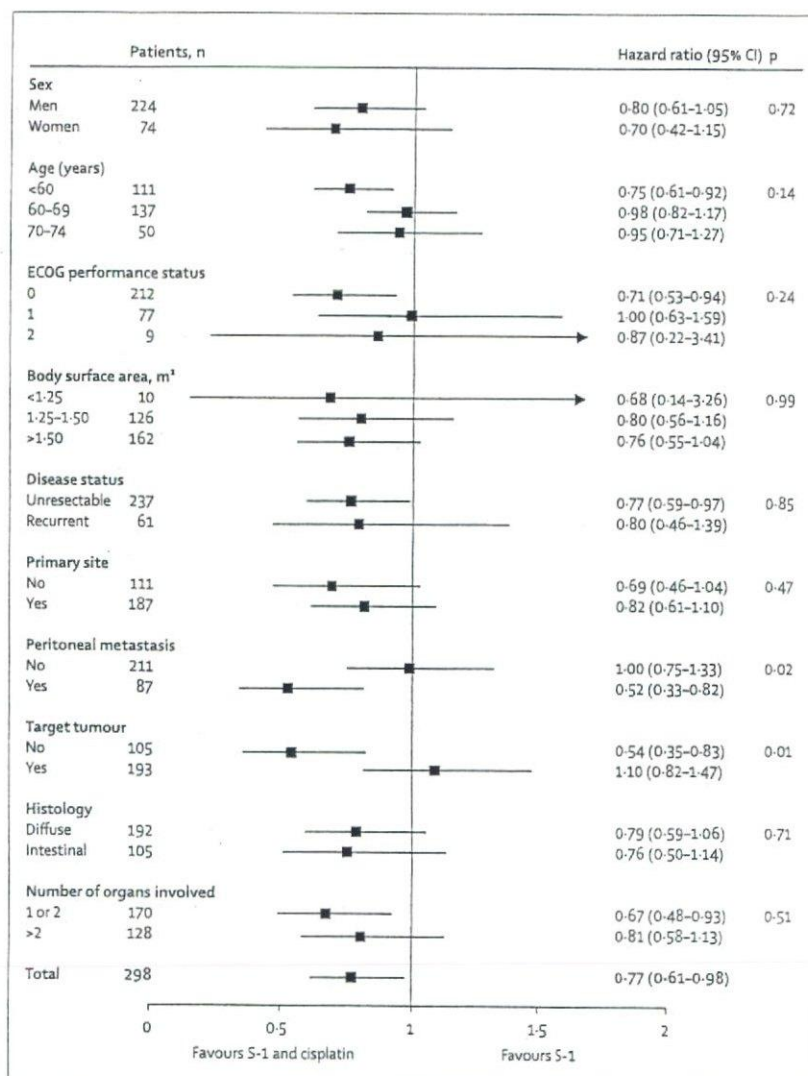


Figure 3: Hazard ratios for death and 95% CIs
*Histology data were missing for one patient.

step forward in the development of a standard treatment for advanced gastric cancer, although therapeutic trials with S-1 in Japan have generally shown more promising findings than those done in western countries.²³

289 of our 298 (97%) patients had a performance status of 0 or 1, but 187 of 298 (63%) had primary tumours and 128 of 298 (43%) patients had involvement of three or more organs in both groups. Notably, all patients had metastases and none had locally advanced disease only (table 1). Target tumours were absent in a larger proportion of patients assigned to S-1 plus cisplatin than in those assigned to S-1 alone, but those assigned to S-1 plus cisplatin had slightly higher proportions of patients with unfavourable prognostic factors, such as peritoneal metastases and diffuse-type carcinomas. Even though our subgroup analysis suggested that presence of peritoneal metastases and absence of target tumours were indications for chemotherapy with S-1 plus

cisplatin, this finding needs further study because our sample size was small and effects were estimated without consideration of other covariates.

Incidence of adverse events in patients assigned to S-1 plus cisplatin were higher than those assigned S-1 alone, but was lower than incidences of adverse events in the V325 study,¹³ the trial by Cunningham and colleagues,¹⁵ and the trial by Kang and co-workers,¹⁴ especially for myelosuppression. Only five of the 148 (3%) patients assigned to S-1 plus cisplatin and two of the 150 (1%) of those assigned to S-1 alone had febrile neutropenia (table 2), which are much lower than the reported incidence of 29% for treatment with combined docetaxel, cisplatin, and fluorouracil.^{13,15} For nonhaematological toxicity, incidences of anorexia and nausea were higher in patients assigned to S-1 plus cisplatin than in those assigned to S-1 alone. Diarrhoea (grade 3 or 4) was uncommon in both groups (six of 148 [4%] patients assigned to S-1 plus cisplatin and five of 150 [3%] patients assigned to S-1 alone). In a phase I trial of S-1 plus cisplatin done in the USA by Ajani and co-workers,²⁴ the recommended dose of S-1 was 25 mg/m² twice daily, which was lower than the actual starting dose in our trial because of the main dose-limiting toxicity of diarrhoea. The difference in dosage might be attributed to the higher activity of cytochrome P-450 2A6 enzyme systems (which catalyse the conversion of tegafur to fluorouracil) in white than in Japanese people,²⁵ and larger body surface area in north American people, leading to higher serum concentrations of 5-chloro-2,4-dihydropyridine and fluorouracil. In a multicentre phase II trial of S-1 (25 mg/m² twice daily) plus cisplatin (75 mg/m²), Ajani and colleagues²⁶ showed that response was high (51% of patients) and survival was good (10.9 months) in patients with advanced adenocarcinoma of the gastric or gastro-oesophageal junction, which was consistent with findings of Japanese clinical trials.

In our trial, relative dose intensity of S-1 was 93.3% in the group assigned to S-1 plus cisplatin (median of four cycles administered) and 98.0% in the group assigned to S-1 alone (median of three cycles administered). Therefore, treatment could be continued safely in both groups. About 75% of patients in each group were given second-line chemotherapy after the study. This high proportion of patients who continued treatment with other regimens will probably contribute to better overall survival in both groups than in those who did not receive further chemotherapy.

Similar to our trial, the Japan Clinical Oncology Group (JCOG) study (JCOG9205)⁹ obtained median survival times of about 7 months with both fluorouracil alone and with fluorouracil plus cisplatin in patients with unresectable, advanced gastric cancer. Therefore, concurrent treatment with cisplatin did not improve survival, and was also less well-tolerated and associated with higher incidences of myelosuppression and other toxic effects. Consequently, after the publication of the JCOG9205 study, clinical trials started in Japan included fluorouracil monotherapy as the control treatment. The JCOG9912

study by Boku and co-workers²³ was designed to assess whether S-1 alone was as good as fluorouracil alone (control treatment), and whether irinotecan plus cisplatin was better than fluorouracil alone in patients with advanced, unresectable or recurrent gastric cancer. Although irinotecan plus cisplatin was not better than fluorouracil alone, S-1 was no worse than fluorouracil. Boku and colleagues reported that in the S-1 group, median survival was 11.4 months, progression-free survival was 4.2 months, and 28% of patients responded; these findings are generally in accordance with our findings. In Japan, S-1 is the most widely used drug for the treatment of gastric cancer, and the Adjuvant Chemotherapy Trial of TS-1 for Gastric Cancer (ACTS-GC) study²⁷ has shown that S-1 alone is effective as post-operative adjuvant treatment in patients with gastric cancer. Furthermore, a Japanese post-marketing survey²⁸ in patients with advanced gastric cancer has shown that S-1 is well-tolerated. Given that S-1 is widely used for the treatment of gastric cancer in Japan, we believe our findings that S-1 plus cisplatin is better than S-1 alone in terms of survival are clinically meaningful.

A large randomised controlled trial—the First-Line Advanced Gastric Cancer Study (FLAGS)—is underway in 24 countries to assess whether treatment with S-1 plus cisplatin is better than fluorouracil plus cisplatin. In FLAGS, enrolment of about 1000 patients has been completed and findings are expected after follow-up has been completed next year.²⁹ The findings of this study might clarify the role of the combination of S-1 and cisplatin in the treatment of patients with gastric cancer.

In conclusion, we believe that our findings will establish S-1 plus cisplatin as a standard treatment for gastric cancer in Japan. Findings of other international studies are awaited.

Contributors

WK was the chief investigator of the trial and chaired the trial management group. WK and MT designed the trial, wrote the protocol, and prepared the report with input from all members of the trial management group. All authors, except MT, identified patients for the trial and critically reviewed the report. MT was responsible for the data management, analysis, statistical analysis, and interpretation.

SPIRITS trial members

Tetsuo Taguchi (medical adviser); Masahiro Takeuchi (statistical analyst); Wasaburo Koizumi (coordinating investigator).

Principal investigators

Kitasato University School of Medicine (Sagamihara, Japan)—WK; Osaka Medical Centre for Cancer and Cardiovascular Diseases (Osaka, Japan)—HN, Hiroyasu Iishi; Kouseiren Takaoka Hospital (Takaoka, Japan)—Makoto Hirano, TH; Iwate Medical University (Morioka, Japan)—AT; Hisataka Fujiwara; Gunma Prefectural Cancer Centre (Ota, Japan)—TA; Shizuoka General Hospital (Shizuoka, Japan)—MT; National Hospital Organization Nagasaki Medical Centre (Omura, Japan)—KM; Matsuyama Red Cross Hospital (Matsuyama, Japan)—Toshimitsu Matsusaka, TN; Kanagawa Cancer Centre (Yokohama, Japan)—Motonori Sairenji, OK; Hiroshima City Asa Hospital (Hiroshima, Japan)—WT; National Kyushu Cancer Centre (Fukuoka, Japan)—Takeshi Okamura, Masaru Haraguchi, YT; Aso Iizuka Hospital (Iizuka, Japan)—TN; Kanagawa Cancer Centre (Yokohama, Japan)—Atsushi Kiyohashi, ST; Aichi Cancer Centre Hospital (Nagoya, Japan)—YY; Wakayama Medical University (Wakayama, Japan)—KY; Saga

Prefectural Hospital Koseikan (Saga, Japan)—Tetsuya Kusumoto, HO; National Hospital Organization Tokyo Medical Centre (Tokyo, Japan)—Kiyoshi Kubochi; Osaka Saiseikai Nakatsu Hospital (Osaka, Japan)—Kiyoshi Ashida; Aichi Cancer Centre, Aichi Hospital (Okazaki, Japan)—Hiroshi Kojima; The Fraternity Memorial Hospital (Tokyo, Japan)—Kazuhiro Furuta; University of Tokai School of Medicine (Isehara, Japan)—Tetsuya Mine; Gifu Municipal Hospital (Gifu, Japan)—Hiromi Tanemura; Toranomon Hospital (Tokyo, Japan)—Harushi Udagawa; Kumamoto Rosai Hospital (Yatsushiro, Japan)—Kenji Okamura, Katsuhiko Inoue; Showa University Northern Yokohama Hospital (Yokohama, Japan)—Atsushi Sato, Ken Shimada; Kobe City Medical Centre General Hospital (Kobe, Japan)—Akio Orino; Kawaguchi Municipal Medical Centre (Kawaguchi, Japan)—Hiroyuki Yamazaki; Nara Prefectural Nara Hospital (Nara, Japan)—Akihiko Watanabe; Fukuoka University Chikushi Hospital (Chikushino, Japan)—Kitaro Futami; Kanto Medical Centre, NTT EC (Tokyo, Japan)—Toshiro Konishi; Kyoto University (Kyoto, Japan)—Chiharu Kawanami, Akiyoshi Nishio, Shigemitsu Matsumoto; Kinki University School of Medicine (Osakasayama, Japan)—Kazuhiro Nakagawa; Yamagata Prefectural Central Hospital (Yamagata, Japan)—Norimasa Fukushima; National Hospital Organization Fukuoka-Higashi Medical Centre (Koga, Japan)—Yoshihisa Sakaguchi, Takahiro Ezaki, Ikuo Takahashi; Kouri Hospital, Kansai Medical University (Neyagawa, Japan)—Hideho Takada; Sendai Kosei Hospital (Sendai, Japan)—Yasushi Mitachi; Tokyo Women's Medical University Medical Centre East (Tokyo, Japan)—Kenji Ogawa; Kokura Memorial Hospital (Kitakyushu, Japan)—Yozo Iida; Niigata City General Hospital (Niigata, Japan)—Satoshi Tsukioka.

Conflicts of interest

WK, HN, AT, OK, YT, MT, YY, and MT have received lecture fees from Taiho Pharmaceutical (Tokyo, Japan). WK and OK have received lecture fees from Bristol-Myers Squibb (New York, NY, USA). MT and OK have received lecture fees from Nippon Kayaku (Tokyo, Japan). All other authors declared no conflicts of interest.

Acknowledgments

This trial was funded by Taiho Pharmaceutical. We thank J Patrick Barron of the International Medical Communications Centre of Tokyo Medical University (Tokyo, Japan) for his review of this report. We thank Yuh Sakata, Junji Tanaka, Atsushi Sato, Minoru Kurihara, Keisuke Aiba, Atsushi Ohtsu, and Fumiaki Takahashi for their kind advice. We also thank Koichiro Hoashi, Tomohiro Kanno, and Kaku Saito for their helpful advice.

References

- Muñoz N, Franceschi S. Epidemiology of gastric cancer and perspectives for prevention. *Salud Publica Mex* 1997; 39: 318–30.
- Kamangar F, Dores GM, Anderson WF. Patterns of cancer incidence, mortality, and prevalence across five continents: Defining priorities to reduce cancer disparities in different geographic regions of the world. *J Clin Oncol* 2006; 24: 2137–50.
- Inoue M, Tsugane S. Epidemiology of gastric cancer in Japan. *Postgrad Med J* 2005; 81: 419–24.
- Murad AM, Santiago FF, Petroianu A, Rocha PRS, Rodrigues MAG, Rausch M. Modified therapy with 5-fluorouracil, doxorubicin, and methotrexate in advanced gastric cancer. *Cancer* 1993; 72: 37–41.
- Glimelius B, Hoffman K, Haglund U, Nyren O, Sjoden PO. Initial or delayed chemotherapy with best supportive care in advanced gastric cancer. *Ann Oncol* 1994; 5: 189–90.
- Pyrhönen S, Kuitunen T, Nyandoto P, Kouri M. Randomised comparison of fluorouracil, epidoxorubicin and methotrexate (FEMTX) plus supportive care with supportive care alone in patients with non-resectable gastric cancer. *Br J Cancer* 1995; 71: 587–91.
- Macdonald JS, Schein PS, Woolley PV, et al. 5-fluorouracil, doxorubicin and mitomycin (FAM) combination chemotherapy for advanced gastric cancer. *Ann Intern Med* 1980; 93: 533–36.
- Vanhoefer U, Rougier P, Wilke H, et al. Final results of a randomized phase III trial of sequential high-dose methotrexate, fluorouracil, and doxorubicin versus etoposide, leucovorin, and fluorouracil versus infusional fluorouracil and cisplatin in advanced gastric cancer: A trial of the European Organization for Research and Treatment of Cancer Gastrointestinal Tract Cancer Cooperative Group. *J Clin Oncol* 2000; 18: 2648–57.
- Ohtsu A, Shimada Y, Shirao K, et al. Randomized phase III trial of fluorouracil alone versus fluorouracil plus cisplatin versus uracil and tegafur plus mitomycin in patients with unresectable, advanced gastric cancer: The Japan Clinical Oncology Group Study (JCOG9205). *J Clin Oncol* 2003; 21: 54–59.
- Preusser P, Wilke H, Achterath W, et al. Phase II study with the combination etoposide, doxorubicin, and cisplatin in advanced measurable gastric cancer. *J Clin Oncol* 1989; 7: 1310–17.
- Wilke H, Preusser P, Fink U, et al. High dose folinic acid/etoposide/5-fluorouracil in advanced gastric cancer—a phase II study in elderly patients or patients with cardiac risk. *Invest New Drugs* 1990; 8: 65–70.
- Findlay M, Cunningham D, Norman A, et al. A phase II study in advanced gastro-esophageal cancer using epirubicin and cisplatin in combination with continuous infusion 5-fluorouracil (ECF). *Ann Oncol* 1994; 5: 609–16.
- Cutsem EV, Moiseyenko VM, Tjulandin S, et al. Phase III study of docetaxel and cisplatin plus fluorouracil compared with cisplatin and fluorouracil as first-line therapy for advanced gastric cancer: a report of the V325 Study Group. *J Clin Oncol* 2006; 24: 4991–97.
- Kang Y, Kang WK, Shin DB, et al. Randomized phase III trial of capecitabine/cisplatin (XP) vs. continuous infusion of 5-FU/cisplatin (FP) as first-line therapy in patients (pts) with advanced gastric cancer (AGC): Efficacy and safety results. *Proc Am Soc Clin Oncol* 2006; LBA4018 (abstr).
- Cunningham D, Starling N, Rao S, et al. Capecitabine and Oxaliplatin for Advanced Esophagogastric Cancer. *N Engl J Med* 2008; 358: 36–46.
- Shirasaka T, Shimamoto Y, Ohshimo H, et al. Development of a novel form of an oral 5-fluorouracil derivative (S-1) directed to the potentiation of the tumour selective cytotoxicity of 5-fluorouracil by two biochemical modulators. *Anticancer Drugs* 1996; 7: 548–57.
- Sugimachi K, Maehara Y, Horikoshi N, et al. An early phase II study of oral S-1, a newly developed 5-fluorouracil derivative for advanced and recurrent gastrointestinal cancers. *Oncology* 1999; 57: 202–10.
- Sakata Y, Ohtsu A, Horikoshi N, Sugimachi K, Mitachi Y, Taguchi T. Late phase II study of novel oral fluoropyrimidine anticancer drug S-1 (1M tegafur-0.4M gimestat-1M otastat potassium) in advanced gastric cancer patients. *Eur J Cancer* 1998; 34: 1715–20.
- Koizumi W, Kurihara M, Nakano S, Hasegawa K. Phase II study of S-1, a novel oral derivative of 5-fluorouracil, in advanced gastric cancer. *Oncology* 2000; 58: 191–97.
- Koizumi W, Tanabe S, Saigenji K, et al. Phase I/II study of S-1 combined with cisplatin in patients with advanced gastric cancer. *Br J Cancer* 2003; 89: 2207–12.
- Japanese Gastric Cancer Association. Japanese classification of gastric carcinoma, 2nd English edn. *Gastric Cancer* 1998; 1: 10–24.
- Therasse P, Arbuck SG, Eisenhauer EA, et al. New guidelines to evaluate the response to treatment in solid tumors. *J Natl Cancer Inst* 2000; 92: 205–16.
- Boku N, Yamamoto S, Shirao K, et al. Randomized phase III study of 5-fluorouracil (5-FU) alone versus combination of irinotecan and cisplatin (CE) versus S-1 alone in advanced gastric cancer. (JCOG9912). *Proc Am Soc Clin Oncol* 2007; LBA4513 (abstr).
- Ajani JA, Faust J, Ikeda K, et al. Phase I pharmacokinetic study of S-1 plus cisplatin in patients with advanced gastric carcinoma. *J Clin Oncol* 2005; 23: 6957–65.
- Shimada T, Yamazaki H, Guengerich FP. Ethnic-related differences in coumarin 7-hydroxylation activities catalyzed by cytochrome P4502A6 in liver microsomes of Japanese and Caucasian populations. *Xenobiotica* 1996; 26: 395–403.
- Ajani JA, Lee FC, Singh DA, et al. MultiCentre phase II trial of S-1 plus cisplatin in patients with untreated advanced gastric or gastroesophageal junction adenocarcinoma. *J Clin Oncol* 2006; 24: 663–67.
- Sakuramoto S, Sasako M, Yamaguchi T, et al. Adjuvant chemotherapy for gastric cancer with S-1, an oral fluoropyrimidine. *N Engl J Med* 2007; 357: 1810–20.
- Nagashima F, Ohtsu A, Yoshida S, Ito K. Japanese nationwide post-marketing survey of S-1 in patients with advanced gastric cancer. *Gastric Cancer* 2005; 8: 6–11.
- Ison DH. Docetaxel, cisplatin, and fluorouracil in gastric cancer: does the punishment fit the crime? *J Clin Oncol* 2007; 25: 3188–90.

New technique for the retraction of the liver in laparoscopic gastrectomy

Yoshihisa Sakaguchi · Osamu Ikeda · Yasushi Toh · Yoshiro Aoki ·
Norifumi Harimoto · Junya Taomoto · Takaaki Masuda · Takefumi Ohga ·
Eisuke Adachi · Takeshi Okamura

Received: 13 August 2007 / Accepted: 24 January 2008 / Published online: 5 March 2008
© Springer Science+Business Media, LLC 2008

Abstract We developed a new technique for the retraction of the liver using a Penrose drain and a J-shaped retractor, which is both an easy and time-saving method that provides a good view during laparoscopic gastrectomy without damaging the liver.

Keywords Liver retraction · Penrose drain · J-shaped retractor · Laparoscopic gastrectomy

In laparoscopic surgery, it is extremely important to establish a sufficient operative field and ensure an adequate working space. In this way, more delicate operations can be performed than by conventional open surgery. Therefore, the accuracy and safety of the laparoscopic surgery depends on the establishment of a wide and good operative field. In laparoscopic surgery for the upper gastrointestinal tract, particularly the stomach, it is necessary to displace the liver in order to obtain a good field of view. Accordingly, we have developed a simple and protective technique for lifting up the liver using a Penrose drain and a J-shaped retractor.

Surgical technique

Creation of a device for lifting up the liver

Fold a Penrose drain (width 6 mm, length 18 cm) in two so that one half is 8 cm long and the other half is 10 cm long.

Y. Sakaguchi (✉) · O. Ikeda · Y. Toh · Y. Aoki ·
N. Harimoto · J. Taomoto · T. Masuda · T. Ohga · E. Adachi ·
T. Okamura
Department of Gastroenterological Surgery, National Kyushu
Cancer Center, 3-1-1 Notame, Minami-ku, Fukuoka 811-1395,
Japan
e-mail: ysakaguchi@nk-cc.go.jp

At a point 3 cm from the fold, ligate with a thread to form three sides: namely measuring 3 cm, 5 cm, and 7 cm in length. Tie 10-cm-long threads to each end (Fig. 1a). Fix the end of the thread tied to the 3-cm side to the end of a J-shaped retractor (ENDO RETRACT MAXI; United States Surgical Corporation, Norwalk, CT) (Fig. 1b). The construction process takes only 5 min.

Procedure during surgery

Lift up the lateral segment of the liver with forceps to expand the dorsal area of the coronary ligament of the left lobe and then make a small incision (Fig. 2b). Insert the tip of the hook of the retractor into the incision (Fig. 2c, d), advance the hook to the ventral side of the coronary ligament (Fig. 2e), and then remove the retractor while holding the thread with forceps. Pull the thread out through the abdominal wall using an ENDO CLOSE (United States Surgical Corporation, Norwalk, CT) (Fig. 2f) and fix the center of the Penrose drain to be placed on the margin of the liver (Fig. 2g). Next, lift up the 7-cm side so as to pull up the round ligament, and in a similar manner, fix it to the abdominal wall with a thread at a position for lifting up the medial segment (Fig. 2h). Finally, fix it so that the 5-cm side lifts up the lateral segment (Fig. 2i). The procedure is usually accomplished within 10 min. Thus, the left lobe of the liver will be protectively lifted up and fixed, thereby ensuring a favorable field of view of the lesser curvature of the stomach and around the esophageal hiatus.

Discussion

In laparoscopic surgery, a favorable expansion of the operative field is essential for intraperitoneal procedures.

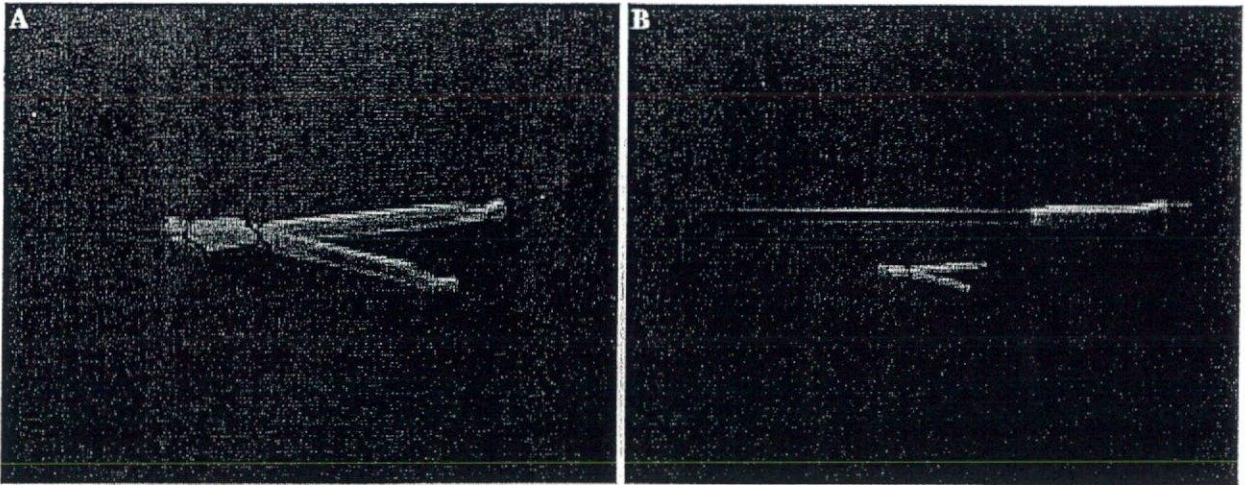
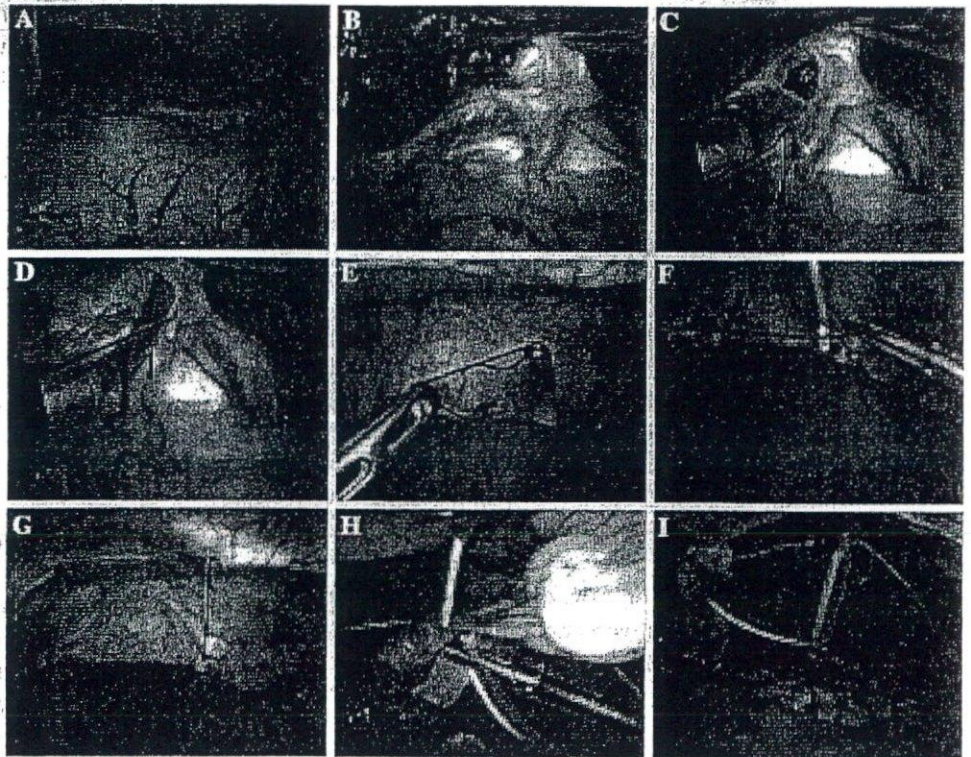


Fig. 1 Creation of the device. (a) Formation of a Penrose drain. (b) Connecting with a J-shaped retractor

Fig. 2 Procedure for lifting up the liver. (a) State before lifting up the liver. (b) Make an incision in the dorsal coronary ligament of the left lobe of the liver. (c) Insert the tip of the hook of the retractor into the incision. (d, e) Advance the hook to the ventral coronary ligament. (f) Pull the thread up through the abdominal wall. (g) Fix a Penrose drain with a thread. (h) Lift up the medial segment. (i) Lift up the lateral segment



To facilitate this, it is necessary to displace the adjacent organs appropriately. On the other hand, a laparoscope provides the field of view from all angles. Therefore, it can be effective for displacing organs ventrally. In surgery for gastric cancer, when performing either a gastrectomy or lymphadenectomy, it is important to lift up the liver to obtain a favorable field of view of the lesser curvature of the stomach and around the esophageal hiatus.

When displacing an organ, it is also important to select appropriate tools based on the characteristics of the organ.

For the purpose of displacing the liver, some kinds of retractors have generally been used [1]. However, during surgery, an assistant must hold the retractor in one hand. The assistant is thus able to manipulate only one pair of forceps, thereby decreasing the precision and safety of the surgical procedures. A table-mounted clamp can also free the assistant's hand, but an additional trocar or skin incision is necessary. There is also a risk of causing damage to the liver, because the retractors and clamps are hard devices. In order not to interfere with forceps manipulation,

the round ligament of the liver is lifted up and fixed to the abdominal wall using threads [2]. However, this technique does not allow for the sufficient expansion of the area around the lateral segment of the liver, which is necessary for operating on the lesser curvature of the stomach and around the esophageal hiatus. As a procedure for solving these problems, a technique of lifting the left lobe of the liver up ventrally using a Penrose drain has recently been utilized [3]. This technique is extremely useful, but often results in difficulty in passing the tape or Penrose drain through the coronary ligament of the left lobe of the liver.

With the technique that we have developed, a Penrose drain is formed into three radial sides for lifting up the liver, thereby enabling the retraction of the left lobe evenly without damaging the liver. Because there is consequently no need to adjust the position during surgery, it does not affect the forceps manipulation. Furthermore, by using a J-shaped retractor, it is possible to successfully lift up the liver easily and quickly. We have utilized this technique for

over 100 cases and encountered no complications requiring any treatments.

In conclusion, our technique is easy, secure, and low cost, compared to other methods. This procedure can be performed by anyone without requiring any specific techniques, so we believe that it will be useful in laparoscopic surgery for the upper gastrointestinal tract.

References

1. Uyama I, Sugioka A, Matsui H et al (2001) Laparoscopic side-to-side esophagogastrostomy using a linear stapler after proximal gastrectomy. *Gastric Cancer* 4:98–102
2. Kojima K, Yamashita T, Inokuchi M et al (2002) Technical standardization of laparoscopy-assisted distal gastrectomy. How to approach and dissect lymph nodes stations? (in Japanese) *J Jpn Soc Endosc Surg* 7:254–258
3. Uyama I, Sakurai Y, Komori Y et al (2005) Laparoscopy-assisted uncut Roux-en-Y operation after distal gastrectomy for gastric cancer. *Gastric Cancer* 8:253–257

SPECIAL ARTICLE

Hiroyuki Kuwano · Yasumasa Nishimura · Atsushi Ohtsu
Hiroyuki Kato · Yuko Kitagawa · Setsuo Tamai
Yasushi Toh · Hisahiro Matsubara

Guidelines for Diagnosis and Treatment of Carcinoma of the Esophagus

April 2007 edition: part I

Edited by the Japan Esophageal Society

Preface to the revised “*Guidelines for Treatment of Carcinoma of the Esophagus*” into “*Guidelines for Diagnosis and Treatment of Carcinoma of the Esophagus*”

Guidelines for Treatment of Carcinoma of the Esophagus were developed by an outstanding group of experts designated the Committee to Develop Guidelines for Treatment of Carcinoma of the Esophagus set up in the Japanese Society for Esophageal Diseases (presently the Japan Esophageal Society) and published in December 2002. As mentioned in the first edition, these guidelines were developed to provide recommendations concerning standard treatments for carcinoma of the esophagus that are currently most appropriate and generally applicable in most institutions, facilitating the daily clinical practice of esophageal carcinoma treatment. However, as esophageal carcinoma treatments have been changing, and treatment recommendations may include a variety of issues, it is often difficult to prescribe uniform treatments. Specific issues to be addressed are as follows.

1. Because esophageal carcinoma generally occurs more often in the elderly, dysfunction of various organs may be involved, and the recommended treatment is sometimes refused by the patient. Thus, therapeutic strategies are often greatly influenced by patient-specific factors.

H. Kuwano (✉) · H. Kato
Department of General Surgical Science, Gunma University Graduate School of Medicine, 3-39-22
Showa-machi, Maebashi 371-8511, Japan
Tel. +81-27-220-8224; Fax +81-27-220-8230
e-mail: hkuwano@med.gunma-u.ac.jp

Y. Nishimura
Department of Radiology, Kinki University School of Medicine, Osakasayama, Japan

A. Ohtsu
Division of Internal Medicine, National Cancer Center Hospital East, Kashiwa, Japan

Y. Kitagawa
Department of Surgery, School of Medicine, Keio University, Tokyo, Japan

S. Tamai
Hiratsuka Health and Welfare Office, Hiratsuka, Japan

Y. Toh
Department of Gastroenterological Surgery, National Kyushu Cancer Center, Fukuoka, Japan

H. Matsubara
Department of Frontier Surgery, Graduate School of Medicine, Chiba University, Chiba, Japan

This article originally appeared in Japanese as *Shokudo gan shindan · chiryo gaidorain* (Guidelines for Diagnosis and Treatment of Carcinoma of the Esophagus), published by Kanehara, Tokyo, April 2007.

Table 1. Classifications of the recommendation level

-
- A. Implementation is strongly recommended.
 - B. Implementation is recommended.
 - C. There is no clear evidence for recommending implementation.
 - D. Avoiding implementation is recommended.
-

2. Surgery for carcinoma of the esophagus is highly invasive. On the other hand, chemotherapy is often more effective in esophageal carcinoma than in other gastrointestinal carcinomas. Thus, esophageal carcinoma may be amenable to various types of treatment from the early to the advanced stage of the disease, and currently there is a considerable range of treatments accompanied by many options for each stage.
3. Under these circumstances, it is expected to be difficult to obtain highly reliable evidence, and in actuality, reports in the literature providing such evidence have been less than adequate.
4. Even where surgical treatments are concerned, we have many options such as larynx preservation in surgery for carcinoma of the cervical esophagus, various organs and routes for reconstruction following esophagectomy, and adjuvant therapy before or after the operation.

On the basis of the foregoing specific issues related to the clinical practice of esophageal carcinoma, revision of the *Guidelines for Treatment of Carcinoma of the Esophagus* has been carried out by the Exploratory Committee on Guidelines for Diagnosis and Treatment of Carcinoma of the Esophagus, a committee newly set up by the Japan Esophageal Society, with the aim of improving practice guidelines. We also take into consideration the guiding principles provided by the Study on Application and Evaluation of Guidelines for Clinical Practice of Cancer, a multidisciplinary research project for evaluation of medical technology supported by the Ministry of Health, Labor, and Welfare.

In view of these circumstances, the guidelines were revised in the following ways.

1. Sections on "Diagnosis," "Follow-Up After the Treatment of Carcinoma of the Esophagus," and "Palliative Medicine" have been added. In particular, in the section on Diagnosis, "evaluations of the general condition" as well as the diagnosis of lesions are now mentioned.
2. "Clinical Questions" are listed for each section, and recommendations concerning respective clinical questions are described, with the level for each recommendation shown according to the classifications (A to D) (Table 1) devised by the Center for Evidence-Based Medicine (EBM) and the Exploratory Committee's criteria.
3. References have been listed at the end of each section.
4. The Guideline Evaluation Committee was newly set up by the Japan Esophageal Society to prepare the system of objective evaluation.

In addition to these revisions, these guidelines will be reviewed for further improvement.

February 2008

I. Introduction

1. Purpose

These guidelines are intended for use by doctors who are dealing with clinical practice for carcinoma of the esophagus, and aim to (1) provide indications for standard procedures in clinical practice of carcinoma of the esophagus according to evidence-based medicine (EBM), (2) promote the improvement of therapeutic safety and efficacy while reducing disparities in treatment results among different institutions, (3) avoid unnecessary treatments, and (4) ensure that patients can easily avail themselves of necessary treatments.

These guidelines provide only rough indications for treatment, and neither inhibit nor deny any treatment that deviates from the indications described in the guidelines.

2. Liability

The Japan Esophageal Society is responsible for the content of the statements in these guidelines. However, liability for treatment results is not imputed to this Society, but rather to the clinical care provider in charge of treating the patient.

3. Fundamental policy for the development of guidelines

These guidelines are restricted to treatment indications, rather than the technical issues of each treatment procedure. To present proper treatment, the authors followed the following principles: (1) treatments are introduced in relation to the progression of carcinoma, without excess or deficiency; (2) evaluation of therapeutic efficacy is evidence based; (3) although the treatment procedure is judged decisively in terms of the survival period, attention is also paid to remission of symptoms, reduction of tumor size, and the patient's quality of life (QOL); and (4) evaluations are carried out in relation to the site of esophageal carcinoma. These guidelines are revised as needed according to advances in medicine.

4. Selection of the treatment and patient consent

When selecting the treatment for esophageal carcinoma, informed consent of the patient is necessary. Namely, regardless of whether or not the treatment is consistent with the guidelines, the doctor in charge should explain to the patient the content of the treatment, reasons for choosing the treatment, possible complications, and treatment results, and should obtain the patient's full understanding and consent.

II. Diagnosis of carcinoma of the esophagus

[A] Diagnosis of the stage of carcinoma

- Summary

The stage of carcinoma of the esophagus is determined by various diagnostic imaging procedures in terms of depth of tumor invasion, lymph node metastasis, and distant metastasis. The patient should be informed of the therapeutic strategies based on assessment of the characteristic features of the lesion (grade of malignancy) and the patient's general condition. The therapeutic strategies are decided on the basis of the patient's understanding and consent after sufficient explanation of the rationale and the diagnostic process (Fig. 1).

[B] Assessment of general condition

- Summary

Radical surgery for esophageal carcinoma, particularly one accompanied by thoracotomy, is the most invasive of the various operations for gastrointestinal carcinoma. Recent advances in surgical techniques, anesthetic procedures, postoperative management, and other aspects have led to increased safety of radical surgery for esophageal carcinoma. However, the incidence of postoperative complications, in-hospital mortality, and operation-related mortality is still higher than the corresponding rates for other diseases. It should also be noted that esophageal carcinoma occurs most frequently in people 65–70 years of age, and that this age group is more likely to have various lifestyle-related diseases (hypertension, diabetes mellitus, hyperlipidemia, etc.). Therefore, it is desirable that application of a radical surgery be decided with due caution after evaluation of the functions of vital organs. When chemotherapy,

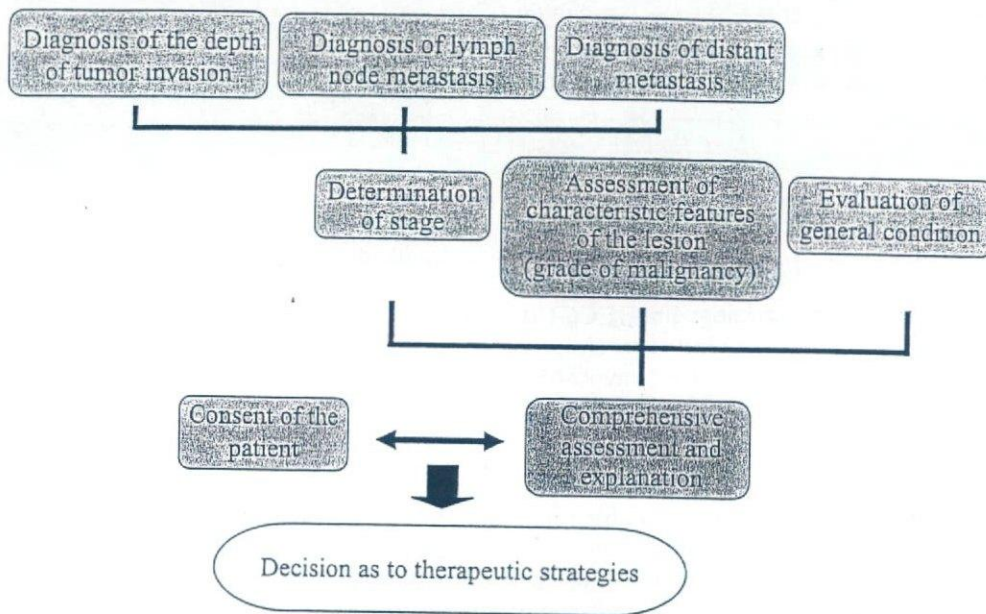


Fig. 1. Flow of therapeutic strategy for esophageal carcinoma

radiotherapy, or chemoradiotherapy is used, it is desirable that the levels of vital organ function meet certain criteria for the implementation of therapy.

Several tests that are necessary for evaluating the general conditions and functions of vital organs, with rough guides for judging the test results, are shown below. However, application of therapy based on the patient's general condition should follow comprehensive evaluation. Clinicians should keep in mind that it is not easy to establish accurate numerical standards.

1. Performance status (PS)

Performance status is a simple and useful index commonly used for comprehensive evaluation of a patient's general condition. Patients with a PS score of 0–2 are generally considered to be reasonable candidates for a radical surgery, chemotherapy, or radiotherapy for carcinoma of the esophagus.

Eastern Cooperative Oncology Group (ECOG) Performance Status score

- PS 0: Fully active, able to carry out all predisease performance without restriction
- PS 1: Restricted in physically strenuous activity, but ambulatory, and able to carry out work of a light or sedentary nature, e.g., light housework, office work
- PS 2: Ambulatory and capable of all self-care but unable to carry out any work activities; up and about more than 50% of waking hours
- PS 3: Capable of only limited self-care, confined to bed or chair more than 50% of waking hours
- PS 4: Completely disabled; cannot carry out any self-care; totally confined to bed or chair

2. Pulmonary function testing

Aging and smoking history are risk factors in patients with carcinoma of the esophagus, and the prevalence of chronic obstructive lung disease is relatively high among these individuals. These conditions are important indices when deciding the propriety of thoracotomy. Whether or not a thoracotomy is applicable should be judged comprehensively, taking into account the results of spirometry (%VC, FEV 1.0%, %RV/TLC), arterial blood gas analysis, chest radiology findings, computed tomography (CT) findings, smoking

history, and past medical history. Application of thoracotomy should be considered carefully if the values of %VC, %FEV 1.0, FEV, and %RV/TLC are 40% or less, 50% or less, less than 1.5 l, and 56% or more, respectively, and the arterial oxygen tension is 60 Torr or less.

3. Heart function testing

Heart failure resulting from valvular disease or cardiomyopathy, severe arrhythmia, and myocardial infarction within 3 months of onset basically render a patient unsuitable for surgery. In principle, resting or exercise electrocardiography (ECG) is carried out, and if any abnormality is found, the patient should be subjected to Holter ECG monitoring, echocardiography, cardiac catheterization, or exercise stress myocardial scintigraphy.

4. Liver function testing

Severe or fulminant hepatitis basically renders a patient unsuitable for surgical treatment. In cases of chronic hepatitis or hepatic cirrhosis, surgical treatment is considered based on comprehensive evaluation of blood counts and the results of blood coagulation tests, blood biochemistry tests, the ICG (indocyanine green) stress test (15 min), and hepatitis screening. Excluding special conditions, surgery is basically not applied to patients who have an ICG retention rate of 40% or more at 15 min. If the value is 20%–40%, application of minimally invasive surgery may be considered with due caution.

5. Renal function tests

Evaluation of renal function includes general urinalysis, serum creatinine, blood urea nitrogen (BUN), electrolytes, and creatinine clearance (Ccr). Although it is relatively rare for surgery to be excluded only because renal function has deteriorated, it is desirable to explain to the patient the possibility of requiring dialysis therapy if serum Cr level is 2.0 mg/dl or more and Ccr is 30% or less.

6. Glucose tolerance testing

Perioperative blood glucose control should be strict in patients with diabetes or decreased glucose tolerance. Measurement of fasting glucose levels, oral 75 g glucose tolerance test, HbA1c measurement, quantitative urinary glucose measurement, and the urine ketone test should be performed. Preoperative control targets include fasting blood glucose <140 mg/dl, daily urinary glucose excretion \leq 10 g, and negative urine ketones.

7. Other factors

Central nervous system function including the presence/absence of mental disorders should be evaluated comprehensively. In general, radical surgery is not indicated for patients with carcinoma of the esophagus when there is a concomitant acute-phase cerebrovascular disorder. It is desirable that patients suffering from depression, anxiety, delirium, or dementia be referred for professional evaluation by a psychiatrist.

III. Endoscopic treatment

- Summary

Indications for endoscopic resection: among lesions that do not infiltrate beyond the mucosal layer (T1a), those remaining in the mucosal epithelium (EP) or the lamina propria mucosae (LPM) are extremely rarely accompanied by lymph node metastasis; endoscopic resection is therefore a sufficiently radical treatment for these lesions.

Because circumferential mucosal resection is likely to be associated with postoperative cicatricial stenosis, this procedure is indicated for lesions not exceeding two-thirds of the circumference (Fig. 2). Lesions reaching the muscularis mucosae (MM) or infiltrating the submucosa (SM) (up to 200 μm) may be associated with lymph node metastasis. However, mucosal resection is feasible for patients without clinical evidence of lymph node metastasis (relative indication). Lesions requiring circumferential mucosal resection also represent a relative indication. Lesions showing deep invasion (more than 200 μm) of the submucosa (T1b) are associated with metastasis at a frequency of about 50%, and even superficial carcinomas are treated in the same manner as advanced carcinomas (carcinomas exceeding the muscularis propria).

Diagnosis of resected tissue specimens: there are limitations in diagnosing the depth of tumor invasion. It is also difficult to accurately determine the depth of invasion of extensive lesions. Thus, the use of resected tissue specimens is essential.

Treatment of lesions not amenable to endoscopic mucosal resection (EMR): for patients not amenable to endoscopic resection, such as those in whom elevation of the mucosa is difficult because of residual lesions at the EMR margin, residual or recurrent lesions after radiotherapy or chemotherapy, etc., or those with a bleeding tendency, photodynamic therapy (PDT) and argon plasma coagulation (APC) should be considered.

Superiority of en bloc resection: en bloc resection is desirable for histological diagnosis of the resected specimen. Endoscopic submucosal dissection (ESD) has allowed en bloc resection of lesions that were formerly subjected to fractional resection. Further development of equipment and the spread of improved techniques are anticipated.

Morbidity: various complications associated with endoscopic resection procedures including ESD, such as bleeding, esophageal perforation, and cicatricial stenosis, have been reported. Prevention, countermeasures and treatment of these complications should be well recognized. There has been extensive discussion of the need for additional treatment after diagnostic evaluation of resected tissue specimens.

Endoscopic resection (ER) includes the conventional endoscopic mucosal resection (EMR) by which the affected mucosa is held or aspirated, and resected with a snare, and endoscopic submucosal dissection (ESD), which allows en bloc resection of an extensive lesion using an IT knife or a hooking knife. Other endoscopic treatments include photodynamic, argon plasma coagulation, and electromagnetic coagulation therapies.

IV. Surgical treatments

- Summary

Therapeutic strategies vary widely according to factors such as the location of the tumor, depth of invasion, presence/absence of metastasis, and general condition of the patient. Surgical treatments are broadly divided into those available in the clinical setting in view of the disease stage and those examined in the clinical research phase and supported by limited evidence.

There are various options, depending on the institution, as to the distance to the proximal end in esophageal resection, the extent of lymph node dissection, the organ and route used for esophageal reconstruction, and the drugs and doses of chemotherapy and radiotherapy administered. It is difficult to choose the only and currently most appropriate standard therapy based on evidence.

Esophageal carcinomas with a depth of invasion defined as EP or LPM and not exceeding two-thirds of the circumference are generally amenable to EMR, and sufficient radicality is expected from this treatment. Esophagectomy and reconstruction not accompanied by lymph node dissection may be indicated for extensive early carcinomas. When the lesion reaches the muscularis mucosa, the frequency of lymph node metastasis is about 9.3%. This percentage increases as the depth of invasion increases. When the lesion invades deep

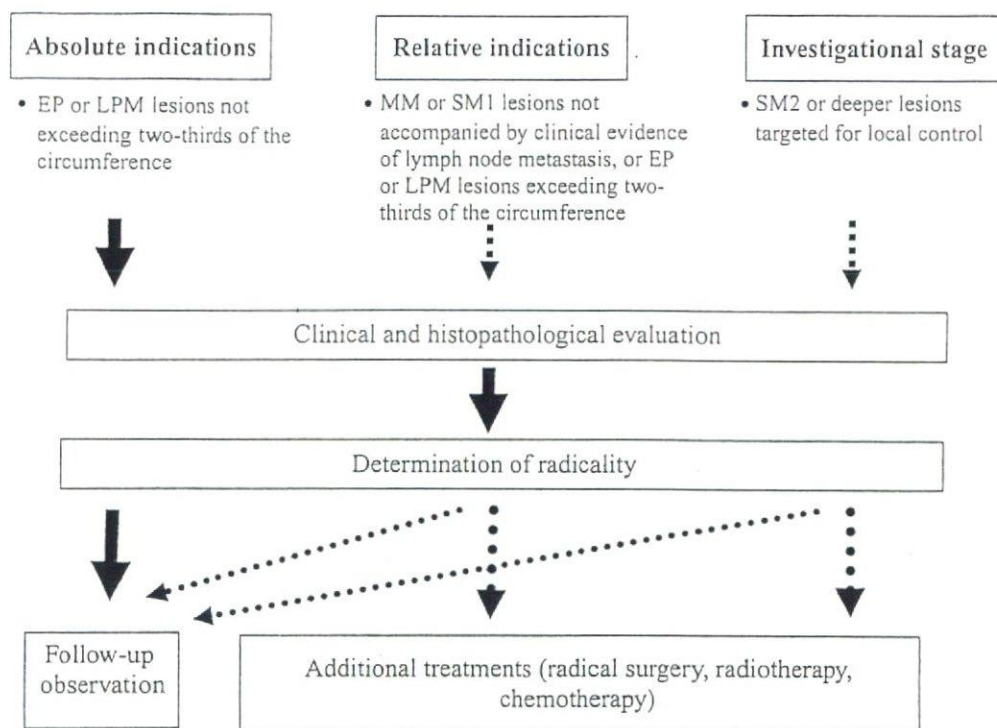


Fig. 2. Indications for endoscopic resection

into the submucosal tissue, the rate of metastasis is about 50%. The general view is that, if lymph node metastasis can reasonably be suspected, lymph node dissection should be carried out even for superficial lesions in accordance with the treatment for T2 or deeper carcinomas. Surgery may be considered in patients with T4 lesions only when curative resection is judged to be applicable.

[A] Surgery for cervical esophageal carcinoma

• Summary

The anatomical structure and physiological function of the hypopharynx relative to the cervical esophagus are complicated. Because the loss of vocal function caused by combined laryngectomy affects the patient's postoperative QOL, the surgical procedure should be determined carefully, after due consideration of the balance between the radicality of the treatment and QOL.

1. Resection

It is common for carcinoma of the cervical esophagus to already be advanced at the time of presentation, accompanied by a high incidence of lymph node metastasis, and infiltration into other organs is likely to occur. However, the extent of lymph node metastasis tends to be restricted to the cervical region, and thus radical surgery is often applicable. Patients who have extensive distant metastasis and metastasis to a number of superior mediastinal lymph nodes are usually not suitable candidates for radical resection.

(1) Larynx-conserving surgery

This operation is indicated for patients who do not have tumor invasion into the larynx and trachea and in whom the proximal end of the tumor is confined to the portion of the esophagus inferior to the orifice.

Larynx-conserving surgery is divided into larynx-conserving cervical esophagectomy and larynx-conserving total esophagectomy according to the need for thoracic esophagectomy. Resection of the thoracic esophagus may be combined with these larynx-conserving approaches when the tumor has invaded the thoracic esophagus, when there are multiple lesions not endoscopically resectable, or when there is metastasis to a number of mediastinal lymph nodes. When preoperative treatment has achieved reduction of the carcinoma, this surgical technique may be employed with the aim of preserving the larynx.

(2) *Laryngopharyngeal esophagectomy (combined laryngectomy)*

Laryngopharyngeal esophagectomy is indicated for patients with tumors invading the larynx, trachea, and hypopharynx, or those for whom sufficient preservation of the cervical esophagus is difficult.

This type of operation is divided into laryngopharyngectomy plus cervical esophagectomy and laryngopharyngectomy plus total esophagectomy, according to the need for thoracic esophagectomy. Thoracic esophagectomy may be combined with these approaches when the tumor has invaded the thoracic esophagus, when there are multiple lesions not endoscopically resectable, or when there is metastasis to a number of mediastinal lymph nodes.

2. Lymph node dissection

According to the *Guidelines for Clinical and Pathologic Studies on Carcinoma of the Esophagus*, cervical lymph nodes include superficial cervical lymph nodes [No. 100], cervical paraesophageal lymph nodes [No. 101], deep cervical lymph nodes [No. 102], peripharyngeal lymph nodes [No. 103], and supraclavicular lymph nodes [No. 104]. Major thoracic lymph nodes are recurrent nerve lymph nodes [No. 106-rec] and upper thoracic paraesophageal lymph nodes [No. 105].

Among these lymph nodes, [No. 101] and [No. 106-rec] lymph nodes belong to group 1, and [No. 102], [No. 104] and [No. 105] lymph nodes belong to group 2 of cervical esophageal carcinoma. It is preferable to remove them whenever possible.

3. Method of reconstruction

Although reconstruction using a free intestinal graft is common when the operation involves cervical manipulation alone, gastric tube reconstruction may be employed in some cases. Myocutaneous flaps or skin rolls may also be used for reconstruction. When thoracic esophagectomy is combined with other procedures, the stomach or colon is used for reconstruction as in patients undergoing routine reconstruction following resection of the thoracic esophageal carcinoma. However, a free jejunal graft may be added if the distance to the proximal end is not sufficient.

[B] Surgery for thoracic esophageal carcinoma

• Summary

Thoracic esophageal carcinoma is often accompanied by extensive lymph node metastasis in the cervical, thoracic, and abdominal regions. Right thoracotomy and total extirpation of the thoracoabdominal esophagus combined with lymph node dissection are generally carried out. The margin width for resection of the tumor should be decided in terms of both the possibility of residual tumor in the remaining esophageal wall and the extent of lymph node dissection.

With thoracic esophageal carcinoma, the extent of lymph node dissection should be decided for each case based upon preoperative evaluation of the location, size, and depth of invasion of the carcinoma by imaging modalities including computed tomography (CT), ultrasonography (US), and magnetic resonance imaging (MRI).

Three routes of reconstruction, i.e., the antethoracic, retrosternal, and posterior mediastinal routes, are available. Although each of these routes has its own advantages and disadvantages, the posterior mediastinal route has recently been employed most frequently. Reconstruction using the stomach is most common.

1. Resection

Thoracic esophageal carcinoma is often accompanied by extensive metastasis to lymph nodes in the cervical, thoracic, and abdominal regions. Because the need for sufficient dissection of mediastinal lymph nodes exists, right thoracotomy and lymph node dissection plus total extirpation of the thoracoabdominal esophagus are generally performed, and the resection usually includes gastric lesser curvature lymph nodes, which are associated with a high incidence of metastasis. Because metastasis to the upper mediastinal lymph nodes is less frequent in patients with superficial carcinoma of the lower thoracic esophagus, there is the view that lymph node dissection of a lesser extent can be applied as compared with patients that have carcinomas of the upper or middle thoracic esophagus.

The margin width for resection of the tumor should be decided in terms of both the possibility of residual tumor in the remaining esophageal wall and the extent of lymph node dissection. Issues involved in residual tumor of the esophageal wall include intramural spread, extension in situ, vascular invasion, and intramural metastasis. Submucosal invasion becomes more extensive as the depth of invasion increases, reportedly reaching 30 mm in T2 carcinoma cases. There is no standard extent of resection established for all the types of cases already described, and the proximal end of the resection may not be sufficiently long according to the location of the tumor. Thus, the extent of resection should be decided on the basis of preoperative esophagography and endoscopy, intraoperative rapid diagnosis of frozen sections, and intraoperative macroscopic evaluation by thoracotomy.

2. Lymph node dissection

Thoracic esophageal carcinoma is commonly accompanied by lymph node metastasis in extensive areas from the cervical to the abdominal region. However, the distribution and incidence of lymph node metastasis both vary according to the location, size, and depth of tumor invasion. Therefore, preoperative evaluation using CT, US, or MRI for each patient is important for determining the extent of lymph node dissection.

The radical surgery approach to thoracic esophageal carcinoma generally uses one of three routes, i.e., cervical, thoracic, or abdominal. For dissection of cervical paraesophageal lymph nodes [No. 101], the mediastinal as well as the cervical approach has been proposed.

(1) *Upper thoracic esophageal carcinoma (Ut)*

In relation to the location of the tumor, Ut cases are usually accompanied by lymph node metastasis mainly in the cervical to upper mediastinal region, and lymph node dissection thus includes the cervical region. It has also been proposed that median sternotomy or manubriotomy be added to secure a better field of view in the cervicothoracic junctional region. Although metastasis to lower mediastinal or abdominal lymph nodes is less frequent in Ut cases, dissection usually covers all three regions, i.e., cervical, thoracic, and abdominal regions, including the left gastric artery lymph nodes.

(2) *Middle thoracic esophageal carcinoma (Mt)*

In general, metastatic lymph nodes in Mt cases are relatively evenly distributed over the cervical to upper, middle and lower mediastinal, and abdominal regions. As most cases with cervical lymph node metastasis involve cervical paraesophageal lymph nodes

Table 2. Advantages and disadvantages of each route of reconstruction

Route	Antethoracic	Retrosternal	Posterior mediastinal or intrathoracic
Advantages	<ol style="list-style-type: none"> 1. Proximal esophagectomy at a higher level is possible. 2. The anastomotic technique is simple. 3. Two-stage anastomosis is possible. 4. The procedure for suture rupture, if any, is easy and safe. 5. Treatment of carcinoma occurring in the reconstructed organ is easy. 	<ol style="list-style-type: none"> 1. Proximal esophagectomy at a higher level is possible. 2. Reconstruction length is shorter than with the antethoracic route. 3. The procedure for treatment of suture rupture, if any, is easier than in intrathoracic anastomosis. 4. Treatment of carcinoma occurring in the reconstructed organ is relatively easy. 	<ol style="list-style-type: none"> 1. Closest to the physiological route. 2. Surgical stress is minimal. 3. The frequency of suture rupture is low.
Disadvantages	<ol style="list-style-type: none"> 1. Reconstruction length is long. 2. The frequency of suture rupture is high. 3. The reconstructed organ is likely to be distorted. 4. There are esthetic issues. 5. Blockage caused by organ distortion or dislocation is apt to occur. 	<ol style="list-style-type: none"> 1. Compression of the heart and lung by the reconstructed organ. 2. Difficult procedures in cases with stapled anastomosis. 3. It is difficult to deal with large suture failures. 4. Risk of pressure necrosis in the reconstructed organ. 5. Bilateral thoracotomy may be required. 	<ol style="list-style-type: none"> 1. Suture failure is likely to be fatal (intrathoracic route). 2. There may be restrictions to proximal esophagectomy (intrathoracic route). 3. Perforation or severe ulcers may occur. 4. Treatment of carcinoma occurring in the reconstructed organ is difficult.

[No. 101], lymph node dissection employing the intrathoracic approach has been proposed. There is also the view that the cervical approach is necessary to achieve secure dissection of cervical lymph nodes, including those of the supraclavicular region [No. 104].

(3) Lower thoracic esophageal carcinoma (Lt)

In Lt cases, lymph node metastasis occurs mainly in the mediastinal and abdominal regions, but metastasis to cervical lymph nodes may also occur at a lower frequency. Much as with Mt cases, the dissection approach is controversial: some advocate the cervical approach, whereas others regard the thoracic approach as the most adequate procedure.

3. Method of reconstruction

(1) Route of reconstruction

Three routes, i.e., antethoracic, retrosternal, and posterior mediastinal (including intrathoracic), are available (Table 2). The route of reconstruction chosen varies among patients and institutions, and each route has advantages and disadvantages. Although the retrosternal route was formerly most common, the posterior mediastinal route has recently become most frequent for reconstruction when high intrathoracic anastomosis is included.

(2) Organ used for reconstruction

The stomach is most frequently used for reconstruction of the esophagus. In postgastrectomy patients, those with concomitant gastric carcinoma, or those in whom the stomach is preserved, colic, ileocolic, or jejunal grafts may be used.

[C] Surgery for carcinoma of the esophagogastric junction (abdominal esophageal carcinoma)

• Summary

As with surgery for thoracic esophageal carcinoma, various techniques are available for the surgical treatment of carcinoma of the esophagogastric junction (E, EG), such as dissection via a right thoracotomy including upper mediastinal lymph nodes, reconstruction using the gastric tube, lower esophagectomy with proximal gastrectomy or lower esophagectomy with total gastrectomy via a left thoracolaparotomy or serial left thoracoabdominal incisions, and a transhiatal approach to the lower mediastinum without thoracotomy. Metastasis involving lower paraesophageal to upper abdominal lymph nodes is frequent. Intrathoracic anastomosis using the gastric tube or jejunum is most common.

1. Resection and lymph node dissection

The 10th edition of the *Guidelines for the Clinical and Pathologic Studies on Carcinoma of the Esophagus* defined the esophagogastric junction region as that 2 cm above and below the esophagogastric junction, and esophagogastric junction carcinoma is a tumor centered in this region. According to this definition, abdominal esophageal carcinoma is included in this category. In esophagogastric junction carcinoma extending more to the esophageal than to the gastric side (E, EG), right thoracotomy with dissection including upper mediastinal lymph nodes and reconstruction using the gastric tube, or cervical or upper mediastinal lymph node dissection, performed in the same manner as in cases of thoracic esophageal carcinoma, may be of less significance. Instead, lower esophagectomy with proximal gastrectomy or lower esophagectomy with total gastrectomy via left thoracolaparotomy or serial left thoracoabdominal incisions is sometimes carried out. A transabdominal approach to the lower mediastinum via dilation of the esophageal hiatus without thoracotomy is also available. Metastases to the lower thoracic paraesophageal [No. 110], cardiac [No. 1, 2], lesser curvature [No. 3], left gastric artery [No. 7], and celiac artery [No. 9] lymph nodes are frequent.

In esophagogastric junction carcinoma extending more to the gastric than to the esophageal side (G, GE), the frequency of metastasis to mediastinal lymph nodes is low, making their dissection less effective. Therefore, these lymph nodes are classified into group 3 in the 10th edition of the *Guidelines for the Clinical and Pathologic Studies on Carcinoma of the Esophagus*.

2. Method of reconstruction

Intrathoracic anastomosis using the gastric tube, jejunal interposition by elevation of the jejunum, and intrathoracic anastomosis by the Roux-en-Y method are available.

In patients with esophagogastric anastomosis following lower esophagectomy with proximal gastrectomy, postoperative reflux esophagitis is a possible problem and requires countermeasures.

[D] Other treatments

• Summary

Although radical surgery for esophageal carcinoma basically consists of resection, lymph node dissection, and reconstruction, other treatments may be carried out if it is difficult or not necessary to complete these procedures because of various factors such as the stage and malignancy of the carcinoma and the general condition of the patient. Transhiatal esophagectomy has been used as a radical surgery for mucosal carcinoma or abdominal esophageal carcinoma that is difficult to treat with an endoscopic

procedure and which presumably does not require mediastinal node dissection. This procedure has also been a palliative operation for patients who are poor candidates for thoracotomy and mediastinal node dissection because of poor pulmonary function or other reasons. However, the indications for this procedure have recently been limited as a result of widening of the application of endoscopic treatment and the spread of chemoradiotherapy aimed at preserving the esophagus.

Along with the recent spread of endoscopic operations, it has become possible for a thoracoscope or laparoscope to be used for radical surgery on esophageal carcinomas. This procedure currently remains in the clinical research phase, however, and no definite conclusions have been drawn as to whether it is less invasive and has better radicality than the conventional standard procedure. Further improvement of surgical instruments and techniques is expected.

Esophageal stenting is a palliative treatment for patients who have difficulty with oral intake because of esophageal stenosis from esophageal carcinoma or changes after treatment for esophageal carcinoma. The advent of self-expandable metallic stents has allowed safer implementation of stenting procedures. However, adverse events such as bleeding and fistula formation often reportedly occur in patients undergoing radiotherapy or chemoradiotherapy after esophageal stenting, or esophageal stenting after radiotherapy or chemoradiotherapy. Thus, it is desirable to basically avoid such combinations. In these patients, bypass surgery or gastrointestinal tubing should be considered.

1. Transhiatal esophagectomy and reconstruction

By this method, the esophageal hiatus of the diaphragm is incised after laparotomy, and the thoracic esophagus is removed by cervical and abdominal approaches without thoracotomy. This technique was first reported by Turner in 1933. Akiyama et al. introduced this method in Japan in 1971, and it has since come into widespread clinical use in this country. This technique has been employed for resection and reconstruction in patients with cervical esophageal carcinoma, those with thoracic or abdominal esophageal carcinoma who are not appropriate candidates for thoracotomy because of severe adhesions or poor pulmonary function, those of advanced age, and those with mucosal carcinoma not requiring lymph node dissection. Although this technique allows dissection of abdominal to lower mediastinal lymph nodes to some extent, upper to middle mediastinal dissection is difficult.

2. Endoscopic esophagectomy and reconstruction

Thoracoscopy- or laparoscopy-assisted esophagectomy with reconstruction and mediastinoscopy- or laparoscopy-assisted transhiatal esophagectomy have been reported as promising surgical procedures, although both are still in the investigational stage in terms of their lower invasiveness, radicality, and long-term results. Endoscopy-assisted esophagectomy is a method of resection accompanied by lymph node dissection. Indications for this operation vary among different institutions, and it is used for T3 cancer in some institutions. Endoscopic esophagectomy is reportedly comparable to the conventional standard thoracotomy in terms of operating time, amount of bleeding, and the number of dissected lymph nodes, and is advantageous for achieving rapid relief of postoperative pain and restoration of vital capacity so long as institutions with extensive clinical experience carry out the procedures. On the other hand, recurrent nerve paralysis is reportedly more frequent than in patients undergoing standard thoracotomy.

To implement endoscopic surgery safely with reduced operating time and improved accuracy of node dissection, application of video-assisted thoracoscopic surgery (VATS) and hand-assisted laparoscopic surgery (HALS), which allows direct manipulations or one-handed manipulations via access through a small incision, is under consideration. Transhiatal esophagectomy with mediastinal dissection using a mediastinoscope inserted via a cervical incision or with mediastinal dissection using laparotomy has also been proposed. Endoscopic surgery reportedly allows node dissection with improved accuracy

because of its higher power vision. However, no definite conclusions have yet been obtained as to the long-term outcomes of this form of surgery as compared with the conventional esophagectomy via thoracotomy with node dissection, and this issue awaits further investigations employing randomized controlled trials.

3. Treatment for unresectable cases

Advanced esophageal carcinomas that are unresectable because of infiltration into other organs or distant metastasis are first subjected to radiotherapy or chemotherapy. However, patients who have esophageal stenosis or an esophago-airway fistula not responding to these treatments have difficulty with oral ingestion, resulting in a markedly decreased QOL. Palliative treatments to achieve oral or tube feeding in these patients with malignant obstruction include the following.

(1) Bypass surgery

By this method, the thoracic esophagus is defunctionalized to reconstruct the digestive tract. This procedure is used for patients with severe stenosis or esophago-airway fistula not suitable for stenting.

The route of digestive tract reconstruction is antethoracic or retrosternal. As most patients have advanced carcinoma and are in a poor nutritional condition, anastomotic leaks occur frequently and require particular caution. In recent years, this procedure has been employed as a palliative operation in patients whose major lesions are judged to be unresectable during salvage surgery following definitive chemoradiotherapy.

(2) Esophageal stenting

Esophageal stenting is a procedure to deliver a stent to the stenotic site in the esophagus using an endoscope under X-ray observation to dilate the lumen and thereby permit oral feeding. This procedure allows oral feeding in a short period of time and with minimal stress. Recently, self-expandable mesh or Z-shaped flexible metallic stents have been developed. These stents can be delivered more easily and safely than conventional plastic stents. Covered stents have been shown to be superior to noncovered stents for prevention of restenosis resulting from tumor growth. Stents of this type are used for patients with severe stenosis accompanied by metastasis to distant organs (not suitable for radical resection or chemoradiotherapy) or cases with esophago-airway fistula formation. In patients with esophago-airway fistula formation, it is desirable to consider the use of an airway stent according to the circumstances and the site of stenosis.

(3) Intestinal or gastric fistula formation

In patients with severe stenosis after definitive chemoradiotherapy or radiotherapy who are not good candidates for radical surgery, gastrointestinal tubing is carried out with the aim of making the transition to home care when esophageal stenting is difficult or risky. Formation of a gastric fistula, which is usually feasible with less stress under endoscopy, should be the first choice. Percutaneous endoscopic gastrostomy may be carried out before multidisciplinary therapy in patients with severe stenosis. Laparotomic gastrostomy or jejunostomy is performed in patients with severe stenosis that does not allow a small-caliber endoscope to pass through or those who are not good candidates for percutaneous endoscopic gastrostomy because of a history of abdominal surgery.

SPECIAL ARTICLE

Hiroyuki Kuwano · Yasumasa Nishimura · Atsushi Ohtsu
Hiroyuki Kato · Yuko Kitagawa · Setsuo Tamai
Yasushi Toh · Hisahiro Matsubara

Guidelines for Diagnosis and Treatment of Carcinoma of the Esophagus

April 2007 edition: part II

Edited by the Japan Esophageal Society

V. Preoperative adjuvant therapy

- Summary

Preoperative chemotherapy: there have been three reports of meta-analyses based on randomized controlled trials carried out in Europe or North America that compared surgical resection with preoperative chemotherapy and surgical resection alone. However, the conclusions are conflicting: one found that preoperative chemotherapy does not improve 1-year and 2-year survival rates, whereas the other showed preoperative chemotherapy to slightly improve the 2-year survival rate. At present, the efficacy of preoperative chemotherapy for resectable cases (T1–3, N0,1, M0; 2002 edition of UICC classification) is unclear.

Preoperative chemoradiotherapy: the results of a meta-analysis of randomized controlled trials comparing surgery alone and surgery combined with preoperative chemoradiotherapy carried out in Europe and North America showed that preoperative concurrent chemoradiotherapy (20–45 Gy) for resectable cases (T1–3, N0,1, M0) caused a significant increase in operation-related mortality while significantly improving the 3-year survival rate. However, when the 1-year or 2-year survival rate was the endpoint, there was no clear survival benefit of preoperative chemoradiotherapy. Thus, the results of this meta-analysis of randomized controlled trials performed in Europe and North America suggest that preoperative chemoradiotherapy combined with surgery has the potential to improve the long-term survival of patients undergoing surgical resection of esophageal carcinoma. In Japan, this therapy is performed for locally advanced cases in a number of institutions. However, no high-level evidence is available concerning Japanese patients, and there is no firm basis for recommending the use of preoperative chemoradiotherapy in Japan.

The rationale for preoperative adjuvant therapy is the expectation that it will regress the primary lesion, control lymph node metastasis and micrometastasis, and allow downstaging before surgical resection, leading to better long-term results of the surgery. Besides downstaging, preoperative adjuvant therapy is also advantageous in that it allows tests of sensitivity to chemotherapy and radiotherapy by histological investigation of the resected specimen. On the other hand, preoperative adjuvant therapy has the following