

A simple, noninvasively determined index predicting hepatic failure following liver resection for hepatocellular carcinoma

Tsuyoshi Ichikawa · Takahiro Uenishi · Shigekazu Takemura · Kazuki Oba · Masao Ogawa · Shintaro Kodai · Hiroji Shinkawa · Hiromu Tanaka · Takatsugu Yamamoto · Shogo Tanaka · Satoshi Yamamoto · Seikan Hai · Taichi Shuto · Kazuhiro Hirohashi · Shoji Kubo

Received: 15 October 2007 / Accepted: 16 January 2008
© Springer 2008

Abstract

Background A novel index, the serum aspartate aminotransferase activity/platelet count ratio index (APRI), has been identified as a biochemical surrogate for histological fibrogenesis and fibrosis in cirrhosis. We evaluated the ability of preoperative APRI to predict hepatic failure following liver resection for hepatocellular carcinoma.

Methods Potential preoperative risk factors for postoperative hepatic failure (hepatic coma with hyperbilirubinemia, four patients; intractable pleural effusion or ascites, 30 patients; and variceal bleeding, one patient) as well as APRI were evaluated in 366 patients undergoing liver resection for hepatocellular carcinoma. Prognostic significance was determined by univariate and multivariate analyses.

Results Hepatic failure developed postoperatively in 30 patients, causing death in four. APRI correlated with histological intensity of hepatitis activity and degree of hepatic fibrosis, and was significantly higher in patients who developed postoperative hepatic failure than in others without failure. Risk of postoperative hepatic failure increased as the serum albumin concentration and platelet count decreased and as indocyanine green retention rate at

15 min, aspartate and alanine aminotransferase activities, and APRI increased. Only APRI was an independent preoperative factor on multivariate analysis. Of the four patients who died of postoperative hepatic failure, three had an APRI of at least 10.

Conclusions Preoperative APRI independently predicted hepatic failure following liver resection for hepatocellular carcinoma. Patients with an APRI of 10 or more have a high risk of postoperative hepatic failure.

Keywords Liver resection · Hepatocellular carcinoma · Liver failure · APRI · Platelet count

Abbreviations

HCC	Hepatocellular carcinoma
APRI	Aspartate aminotransferase/platelet count ratio index
Anti-HCV	Anti-hepatitis C virus antibody
HBsAg	Hepatitis B surface antigen
ICGR ₁₅	Indocyanine green retention rate at 15 min
AST	Aspartate aminotransferase
ALT	Alanine aminotransferase
AFP	α -Fetoprotein
HAI	Histological activity index

Introduction

Liver resection in patients with hepatocellular carcinoma (HCC) may result in postoperative hepatic failure, since most patients with HCC also have chronic liver disease including cirrhosis [1–9]. To avoid resection likely to lead to postoperative hepatic failure, various methods have been developed for preoperative assessment of liver function [4,

T. Ichikawa (✉) · S. Takemura · K. Oba · M. Ogawa · S. Kodai · H. Shinkawa · H. Tanaka · S. Yamamoto · S. Hai · S. Kubo

Department of Hepato-Biliary-Pancreatic Surgery, Osaka City University Graduate School of Medicine, 1-4-3 Asahimachi, Abeno-ku, Osaka 545-8585, Japan
e-mail: t-ichikawa@msic.med.osaka-cu.ac.jp

T. Uenishi · T. Yamamoto · S. Tanaka
Department of Surgery, Ishikiri-Seiki Hospital, Osaka, Japan

T. Shuto · K. Hirohashi
Department of General Practice, Osaka City University Hospital, Osaka, Japan

5, 9–19]. However, some of these are complex and require calculations involving multiple formulas.

Previous studies have identified hepatic fibrosis and active hepatitis as negative predictive factors for effective liver regeneration and as risk factors for postoperative hepatic failure [3, 9, 20, 21]. Histopathologic examination of liver biopsy specimens presently remains the "gold standard" for assessing degree of active hepatitis and hepatic fibrosis. However, liver biopsy cannot be performed in all candidates for liver surgery because of its cost and risk of complications. Recently, a novel index, the aspartate aminotransferase (AST)/platelet count ratio index (APRI), has been identified as a biochemical marker for histological fibrogenesis and fibrosis in cirrhosis [22, 23]. APRI has been reported to correlate with hepatic fibrosis and magnitude of abnormalities in liver function tests [22, 23]. This simple ratio is calculated from results of routinely available, noninvasive, and inexpensive laboratory tests.

In the present study, we evaluated the relationship between preoperative APRI and postoperative hepatic failure following liver resection, and the ability of the ratio to serve as a marker to identify candidates who cannot safely undergo liver resection for HCC.

Patients and methods

Patients and determination of APRI

From the beginning of 1994 to the end of 2004, liver resection for HCC was performed for 372 patients in our department. Patients excluded from this study included five who underwent concomitant resection of a synchronous second tumor, and one who underwent liver resection combined with right atrial tumor thrombectomy requiring extracorporeal circulation. The 366 patients remaining as subjects in this study included 297 men and 69 women; their ages ranged from 30 to 85 years (mean \pm SD, 63.6 ± 8.2). In total, 249 patients were positive for anti-hepatitis C antibody (anti-HCV) alone, 54 patients for hepatitis B surface antigen (HBsAg) alone, four patients for both anti-HCV and HBsAg, and 59 patients were negative for both viral markers. APRI was calculated as AST activity (IU/L)/platelet count ($10^4/\mu\text{l}$) [22].

The study was conducted in accordance with the Helsinki Declaration and the guidelines of the Ethics Committee at our institution.

Postoperative hepatic failure

Variables previously shown to predict postoperative hepatic failure included hepatic coma with hyperbilirubinemia (total serum bilirubin concentration >5 mg/dl for more than

5 days); intractable pleural effusion or ascites requiring use of diuretics or thoracentesis, or abdominal paracentesis on two or more occasions or institution of continuous abdominal drainage; or variceal bleeding [24, 25].

Operative procedure

The operative procedures is outlined below (major hepatectomy; segmentectomy or greater, minor hepatectomy; smaller than segmentectomy, anatomic hepatectomy; subsegmentectomy or greater, nonanatomic hepatectomy; smaller than subsegmentectomy).

Pathologic examination

Surgical specimens were cut serially into tissue blocks 5 mm thick, fixed in 10% formalin, and stained with hematoxylin and eosin. Histologic grade with respect to tumor differentiation was assigned using a modification of the classification by Edmondson and Steiner [26, 27]. The histologic activity index (HAI) was used with some modifications [28, 29] to evaluate severity of active hepatitis (histologic activity grade) and degree of hepatic fibrosis (histologic fibrosis grade). HAI scores consist of four components: component 1, periportal necrosis with or without bridging necrosis; component 2, intralobular degeneration and focal necrosis; component 3, portal inflammation; and component 4, fibrosis. Summed HAI scores of 0 for (components 1–3) indicated no activity (histologic activity score, 0); scores of 1–3, minimal activity (histologic activity score, 1); scores of 4–8, mild activity (histologic activity score, 2); scores of 9–12, moderate activity (histologic activity score, 3); and score of 13 or more indicated severe activity (histologic activity score, 4). The degree of fibrosis (histologic fibrosis score) was determined from component 4 of the HAI score. A histologic fibrosis grade of 1 indicated portal fibrous expansion; a grade of 2 indicated the presence of portal-portal septa without architectural distortion; a grade of 3 indicated portocentral septa with architectural distortion; and a grade of 4 indicated cirrhosis.

Statistics

Student's *t* test was used to examine differences in age and tumor size. The Mann-Whitney *U* test was used to examine differences in laboratory test results. Fisher's exact test or the χ^2 test was used to compare categorical data between groups. Correlations between APRI and results of other laboratory tests were determined using Pearson's correlation coefficient. The correlation between the APRI and histologic activity score or fibrosis score in noncancerous liver was determined by Spearman's rank correlation. Odds ratios were used to estimate relative risk for postoperative hepatic failure.

Logistic regression was used for univariate analysis, while multiple logistic regression analysis was used for multivariate analysis. For multivariate analysis, variables possibly significant ($P < 0.1$) on univariate analysis were evaluated. P values less than 0.05 were considered significant.

Table 1 Correlations between APRI and results of other laboratory tests

Laboratory test	Correlation coefficient	P value
Total bilirubin	0.306	<0.0001
Albumin	-0.248	<0.0001
ICGR ₁₅	0.280	<0.0001
AST	0.756	<0.0001
ALT	0.625	<0.0001
Platelet count	-0.555	<0.0001
Prothrombin test (%)	-0.132	0.0119

ICGR₁₅ Indocyanine green retention rate at 15 min, AST aspartate aminotransferase, ALT alanine aminotransferase

Table 2 Demographic and clinicopathologic features of patients with and without hepatic failure after liver resection

Parameter	Hepatic failure		P value
	No, $n = 336$	Yes, $n = 30$	
Age, years, mean \pm SD	63.6 \pm 8.4	64.0 \pm 6.9	0.8912
Gender, M:F	274:62	23:7	0.5125
Alcohol abuse	115	10	0.9593
History of blood transfusion	75	8	0.5922
Anti-HCV	229	24	0.1784
HBsAg	54	4	0.6940
Diabetes mellitus	55	7	0.4562
Total bilirubin (mg/dl)	0.8 (0.5, 1.3)	0.9 (0.5, 1.4)	0.3008
Albumin (g/dl)	3.7 (3.3, 4.2)	3.6 (2.9, 4.1)	0.0309
ICGR ₁₅ (%)	15.0 (7.5, 25.2)	17.8 (7.0, 34.5)	0.2434
AST (IU/l)	52 (30, 96)	64 (46, 107)	0.0208
ALT (IU/l)	56 (26, 113)	70 (38, 129)	0.0232
Platelet count ($\times 10^4/\mu$ l)	14.3 (8.4, 22.9)	11.6 (5.6, 20.5)	0.0068
Prothrombin test (%)	94 (73, 135)	94 (76, 131)	0.9798
APRI	3.8 (1.6, 9.0)	5.3 (2.6, 13.3)	0.0039
AFP, >20 ng/ml	180	18	0.5200
Tumor size, cm, mean \pm SD	3.8 \pm 2.8	4.2 \pm 2.8	0.4504
Operative procedure, major:minor	125:211	14:16	0.3061
Operative procedure, anatomic:nonanatomic	170:166	17:13	0.2571
Intraoperative blood loss (g)	725 (196, 2595)	1450 (478, 3662)	0.0002
Time of operation (min)	282 (180, 440)	317 (213, 500)	0.1016
Histologic activity grade			
0-2	300	20	0.0003
3	34	10	
Histologic fibrosis grade			
0-3	194	11	0.0247
4, representing cirrhosis	141	19	

Most laboratory results, intraoperative blood loss, and time of operation are given as medians (with 10th and 90th percentiles)

Anti-HCV Anti-hepatitis C virus antibody, HBsAg hepatitis B surface antigen, ICGR₁₅ indocyanine green retention rate at 15 min, AST aspartate aminotransferase, ALT alanine aminotransferase, AFP α -fetoprotein

Results

Preoperative APRI, which ranged from 0.6 to 51.3 (mean \pm SD, 5.0 \pm 4.4), correlated with serum concentrations of total bilirubin and albumin, indocyanine green retention test results at 15 min (ICGR₁₅), serum activities of AST and alanine aminotransferase (ALT), platelet count, and prothrombin test (Table 1).

APRI also correlated with both histologic activity score ($P = 0.0003$) and histologic fibrosis score ($P = 0.0247$).

Postoperative hepatic failure developed in 30 patients (hepatic coma with hyperbilirubinemia in four patients; intractable pleural effusion or ascites in 30 patients; and variceal bleeding in one patient). Four of these patients died of hepatic failure while still in the hospital. Clinicopathologic findings were compared between the 30 patients with postoperative hepatic failure and the 336 patients without failure (Table 2). These groups were similar in age, gender, percentage of patients with a history of alcohol abuse (defined as an estimated daily intake of 86 g of

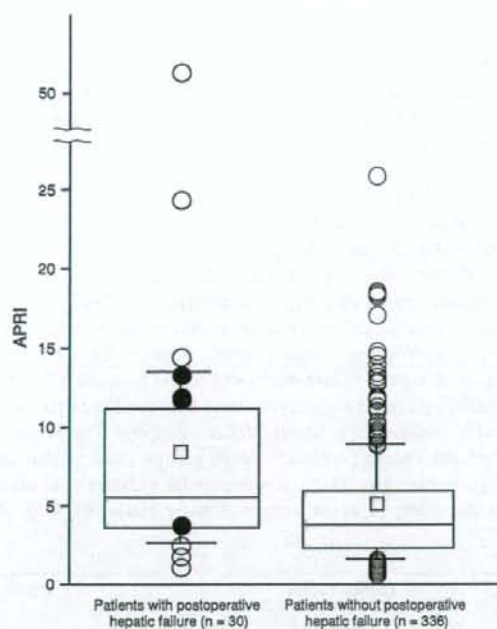


Fig. 1 APRI in two groups of patients who underwent liver resection for hepatocellular carcinoma. APRI values of patients with and without postoperative hepatic failure ranged from 0.6 to 26 and from 1.1 to 51.3, respectively (mean \pm SD, means shown as small squares, 8.3 \pm 9.3 and 4.7 \pm 3.5). Bars, 10th and 90th percentiles; bottoms and tops of boxes, 25th and 75th percentiles; lines across boxes, medians; circles, outliers; closed circles, patients who died of postoperative hepatic failure

ethanol for at least 10 years, according to the criteria of the Liver Cancer Study Group of Japan [30]), diabetes mellitus, blood transfusion, and anti-HCV and HBsAg positivity. Although serum total bilirubin concentration, ICGR₁₅, and prothrombin test results did not differ between groups, serum albumin concentration and platelet count were significantly lower in patients with postoperative hepatic failure than in those without it. Serum activities of AST and ALT and also the APRI (Fig. 1) were significantly higher in patients with than without postoperative hepatic failure. Although no difference was noted in tumor size, operative procedure, or operative time was noted between them, intraoperative blood loss was significantly greater in patients who developed postoperative hepatic failure. The percentage of patients with moderate hepatitis activity (histologic activity grade 3) or cirrhosis (histologic fibrosis grade 4) was significantly greater in patients who developed postoperative hepatic failure.

Table 3 shows odds ratios (OR) for the candidate risk factors associated with postoperative hepatic failure as

Table 3 Risk factors for hepatic failure after liver resection for hepatocellular carcinoma, evaluated by univariate analysis

Variable	Odds ratio	95% CI	P value
Age (per 1 year)	1.003	0.958–1.050	0.8908
Gender			
Female	1.000		
Male	0.743	0.305–1.810	0.5138
Alcohol abuse			
(–)	1.000		
(+)	0.979	0.441–2.177	0.9593
History of blood transfusion			
(–)	1.000		
(+)	1.261	0.539–2.947	0.5929
Anti-HCV			
(–)	1.000		
(+)	1.869	0.742–4.707	0.1844
HBsAg			
(–)	1.000		
(+)	0.803	0.270–2.395	0.6945
Diabetes mellitus			
(–)	1.000		
(+)	1.406	0.572–3.456	0.4580
AFP (ng/ml)			
≤ 20	1.000		
> 20	1.283	0.599–2.748	0.5208
Total bilirubin (per 1 mg/dl)	1.788	0.616–5.184	0.2848
Albumin (per 1 g/dl)	0.241	0.086–0.678	0.0070
ICGR ₁₅ (per 1%)	1.046	1.005–1.088	0.0272
AST (per 1 IU/l)	1.008	1.000–1.017	0.0459
ALT (per 1 IU/l)	1.008	1.000–1.016	0.0572
Platelet count (per $1 \times 10^4/\mu\text{l}$)	0.925	0.860–0.996	0.0385
Prothrombin test (per 1%)	0.999	0.983–1.016	0.9279
APRI (per 1)	1.125	1.045–1.211	0.0017
Operative procedure			
Minor	1.000		
Major	1.477	0.697–3.129	0.3085
Operative procedure			
Non-anatomic	1.000		
Anatomic	1.529	0.736–3.175	0.2545
Intraoperative blood loss (per 1 g)	1.000	1.000–1.001	0.0147
Time of operation (per 1 min)	1.003	1.000–1.006	0.0804
Histologic activity grade			
0–2	1.000		
3	4.286	1.858–9.888	0.0006
Histologic fibrosis grade			
1–3	1.000		
4, representing cirrhosis	2.377	1.096–5.152	0.0283

Anti-HCV Anti-hepatitis C virus antibody, HBsAg hepatitis B surface antigen, ICGR₁₅ indocyanine green retention rate at 15 min, AST aspartate aminotransferase, ALT alanine aminotransferase, AFP α -fetoprotein

calculated by univariate analysis. Serum albumin concentration (OR = 0.241), ICGR₁₅ (OR = 1.046), AST (OR = 1.008), ALT (OR = 1.008), platelet count (OR = 0.925), APRI (OR = 1.125), histologic activity grade 3 (OR = 4.286), and cirrhosis (OR = 2.377) were risk factors for postoperative hepatic failure. APRI in three of the four patients who died of postoperative hepatic failure was 10 or more. Risk of postoperative hepatic failure increased as serum albumin concentration and platelet count decreased, and as ICGR₁₅, AST, and ALT activities and APRI increased. Risk of postoperative hepatic failure also increased with greater intraoperative blood loss, and was also high in patients with moderately active hepatitis or cirrhosis according to histopathologic examination. Risk of postoperative hepatic failure correlated closely with both severity of active hepatitis and degree of hepatic fibrosis.

Multivariate analysis was used to estimate the adjusted odds ratio for postoperative hepatic failure based on preoperative data (Table 4). Because the aim of this study was to evaluate the role of the APRI as preoperative prediction

Table 4 Risk factors for hepatic failure after liver resection for hepatocellular carcinoma, evaluated by multivariate analysis

Variable	Odds ratio	95% CI	P value
Albumin (per 1 g/dl)	0.360	0.114–1.140	0.0823
ICGR ₁₅ (per 1%)	1.026	0.975–1.081	0.3222
Prothrombin test (per 1%)	1.007	0.990–1.025	0.4052
APRI	1.098	1.018–1.184	0.0149

ICGR₁₅ Indocyanine green retention rate at 15 min, APRI AST to platelet ratio index

Table 5 Features of hepatic failure in patients with high or low APRI

Feature	APRI		P value
	≤10 (n = 333)	>10 (n = 33)	
Hepatic coma	2	2	0.0422
Intractable pleural effusion or ascites	23	10	<0.0001
Variceal bleeding	0	1	0.0902
Death from hepatic failure	1	3	0.0025

Table 6 Results of laboratory tests and operative methods in four patients who died of postoperative hepatic failure

Patient no.	Age (year)	T-bil (mg/dl)	Albumin (g/dl)	ICGR ₁₅ (%)	Prothrombin test (%)	APRI	Operative method
1	72	0.3	3.0	37.4	74	11.0	Partial
2	62	0.9	3.0	13.0	94	12.7	Partial
3	59	1.4	3.8	23.1	100	3.96	Rt. lobectomy
4	55	1.3	2.9	26.9	104	11.5	Partial

T-bil Total bilirubin, ICGR₁₅ indocyanine green retention rate at 15 min, APRI AST to platelet ratio index

of postoperative hepatic failure; significant risk factors on univariate analysis which were acquired postoperatively were eliminated. APRI was the only independent preoperative risk factor for postoperative hepatic failure (adjusted OR = 1.098, 95% CI: 1.018–1.184).

We next compared the 330 patients with a low APRI (<10) with the 33 patients whose APRI was high (≥10) (Table 5). A cut-off line for APRI of 10 yielded the most significant differences in cut off lines (counting number) which we decided. The sensitivity, specificity, and positive predictive value of APRI ≥ 10 for postoperative hepatic failure were 27.3%, 7.8%, and 27.3%, respectively. The prevalence of hepatic coma and intractable pleural effusion or ascites was significantly higher among patients with a high APRI than in those with a low APRI. Variceal bleeding developed in only one patient, who had an elevated APRI (≥10). Although only 1 of the 333 patients with a low APRI died of postoperative hepatic failure, 3 of 33 patients with a high APRI died of this complication (P = 0.0025). APRI was ≥10 in three of four patients who died of postoperative hepatic failure. The serum concentrations of total bilirubin and albumin, ICGR₁₅, and prothrombin test results were distributed over wide ranges in these four patients (Table 6).

The clinical significance of the APRI in the determination of operative methods was investigated. The APRI was 10 or greater in only 4 of 139 patients who underwent major hepatectomy; it is thus not possible to evaluate the role of APRI in only patients who underwent major hepatectomy. For the 227 patients who underwent minor hepatectomy, APRI was a significant risk factor for postoperative hepatic failure.

Discussion

In this study, we attempted to develop a preoperative risk marker for predicting postoperative hepatic failure in patients with hepatocellular carcinoma who are candidates for hepatic resection using only routine laboratory tests. High APRI was a risk factor for postoperative hepatic failure on univariate analysis and the only independent preoperative risk factor on multivariate analysis.

Cirrhosis is a well-known risk factor for postoperative hepatic failure [3, 10, 13, 20, 31, 32]. Degree of hepatic fibrosis is a negative predictor of liver regeneration and restoration of liver function after liver resection [33] that also influences the risk of postoperative ascites and pleural effusion [34] and duration of postoperative hepatic failure [9]. Active hepatitis has also been reported to be a potential risk factor for hepatic failure following liver resection [9, 31, 35]. We previously reported that active hepatitis and severe hepatic fibrosis are each risk factors for postoperative hepatic failure [25]. However, since biopsy specimens of noncancerous hepatic tissue are not readily obtainable preoperatively from all patients for reasons of safety and other issues, less invasive markers are needed. Recently, the APRI, which is calculated from AST activity and the platelet count, has been reported to correlate with histologic degree of hepatic fibrosis [22, 23]. In the present study we confirmed that APRI correlated with both histologic activity grade and histologic fibrosis grade in patients with HCC. Thus, preoperative determination of the APRI informs the surgeon about severity of active hepatitis and degree of fibrosis, and provides a measure of the risk of postoperative hepatic failure.

The indocyanine green clearance test has been used to develop guidelines for extent of liver resection [3, 5, 7, 18, 21, 36–42]. In this study, the role of the APRI in decision-making concerning extent of liver resection since remained unclear. In fact, it was not possible to evaluate the role of the APRI, since the APRI was 10 or greater in only 4 of 139 patients who underwent major hepatectomy. The percentage of patients with postoperative hepatic failure was significantly higher among those with a high APRI (≥ 10) than among those with a low APRI (< 10). The percentage of patients who died of hepatic failure also was significantly higher among those with a high APRI than among those with a low APRI. We suggest that APRI ≥ 10 is a more useful marker for postoperative death than any other laboratory tests (total bilirubin, albumin, ICG₁₅, and prothrombin test). The APRI was thus useful for determining whether liver resection itself is indicated in patients with chronic liver disease. Since patients who have a high APRI have active hepatitis and severe hepatic fibrosis, care is needed to avoid postoperative hepatic failure. Treatments for HCC include locoregional treatment including percutaneous ethanol injection, microwave coagulation therapy, and radiofrequency ablation therapy and transarterial therapy, including transcatheter arterial embolization and hepatic arterial infusion chemotherapy [43]. These alternatives can be considered for patients with a high APRI.

Other reported risk factors for postoperative hepatic failure include patient age [10, 31], diabetes mellitus [13], and excessive intraoperative blood loss [7, 13, 18, 21, 32, 33]. Although excessive intraoperative blood loss was a

risk factor on univariate analysis, age and diabetes mellitus were not found to be risk factors in the present study.

In conclusion, preoperative APRI was correlated with postoperative hepatic failure; in particular, APRI of ten or more carries a high risk of postoperative hepatic failure.

References

- Lai EC, Fan ST, Lo CM, Chu KM, Liu CL, Wong J. Hepatic resection for hepatocellular carcinoma. An audit of 343 patients. *Ann Surg.* 1995;221:291–8.
- Takenaka K, Kawahara N, Yamamoto K, Kajiyama K, Maeda T, Itasaka H, et al. Results of 280 liver resections for hepatocellular carcinoma. *Arch Surg.* 1996;131:71–6.
- Wu CC, Ho WL, Yeh DC, Huang CR, Liu TJ, P'Eng FK. Hepatic resection of hepatocellular carcinoma in cirrhotic livers: is it unjustified in impaired liver function? *Surgery.* 1996;120:34–9.
- Cohnert TU, Rau HG, Buttler E, Hernandez-Richter T, Sauter G, Reuter C, et al. Preoperative risk assessment of hepatic resection for malignant disease. *World J Surg.* 1997;21:396–400.
- Lau H, Man K, Fan ST, Yu WC, Lo CM, Wong J. Evaluation of preoperative hepatic function in patients with hepatocellular carcinoma undergoing hepatectomy. *Br J Surg.* 1997;84:1255–9.
- Lise M, Bacchetti S, Da Pian P, Nitti D, Pilati PL, Pigato P. Prognostic factors affecting long term outcome after liver resection for hepatocellular carcinoma: results in a series of 100 Italian patients. *Cancer.* 1998;82:1028–36.
- Nonami T, Nakao A, Kurokawa T, Inagaki H, Matsushita Y, Sakamoto J, et al. Blood loss and ICG clearance as best prognostic markers of post-hepatectomy liver failure. *Hepatogastroenterology.* 1999;46:1669–72.
- Pol B, Campan F, Hardwigen J, Botti G, Pons J, Le Treut YP. Morbidity of major hepatic resections: a 100-case prospective study. *Eur J Surg.* 1999;165:446–53.
- Farges O, Malassagne B, Flejou JF, Balzan S, Sauvanet A, Belghiti J. Risk of major liver resection in patients with underlying chronic liver disease: a reappraisal. *Ann Surg.* 1999;229:210–5.
- Yamanaka N, Okamoto E, Kuwata K, Tanaka N. A multiple regression equation for prediction of posthepatectomy liver failure. *Ann Surg.* 1984;200:658–63.
- Didolkar MS, Fitzpatrick JL, Elias EG, Whitley N, Keramati B, Suter CM, et al. Risk factors before hepatectomy, hepatic function after hepatectomy and computed tomographic changes as indicators of mortality from hepatic failure. *Surg Gynecol Obstet.* 1989;169:17–26.
- Noguchi T, Imai T, Mizumoto R. Preoperative estimation of surgical risk of hepatectomy in cirrhotic patients. *Hepatogastroenterology.* 1990;37:165–71.
- Shimada M, Matsumata T, Akazawa K, Kamakura T, Itasaka H, Sugimachi K, et al. Estimation of risk of major complications after hepatic resection. *Am J Surg.* 1994;167:399–403.
- Kwon AH, Ha-Kawa SK, Uetsuji S, Kamiyama Y, Tanaka Y. Use of technetium 99 m diethylenetriamine-pentaacetic acid-galactosyl-human serum albumin liver scintigraphy in the evaluation of preoperative and postoperative hepatic functional reserve for hepatectomy. *Surgery.* 1995;117:429–34.
- Bruix J, Castells A, Bosch J, Feu F, Fuster J, Garcia-Pagan JC, et al. Surgical resection of hepatocellular carcinoma in cirrhotic patients: prognostic value of preoperative portal pressure. *Gastroenterology.* 1996;111:1018–22.

16. Zimmermann H, Reichen J. Hepatectomy: preoperative analysis of hepatic function and postoperative liver failure. *Dig Surg.* 1998;15:1-11.
17. Kubota K, Makuuchi M, Kusaka K, Kobayashi T, Miki K, Hasegawa K, et al. Measurement of liver volume and hepatic functional reserve as a guide to decision-making in resectional surgery for hepatic tumors. *Hepatology.* 1997;26:1176-81.
18. Miyagawa S, Makuuchi M, Kawasaki S, Kakazu T. Criteria for safe hepatic resection. *Am J Surg.* 1995;169:589-94.
19. Belghiti J, Ogata S. Assessment of hepatic reserve for indication of hepatic resection. *J Hepatobiliary Pancreat Surg.* 2005;12:1-3.
20. Nagasue N, Yukaya H, Ogawa Y, Kohno H, Nakamura T. Human liver regeneration after major hepatic resection. A study of normal liver and livers with chronic hepatitis and cirrhosis. *Ann Surg.* 1987;206:30-9.
21. Das BC, Isaji S, Kawarada Y. Analysis of 100 consecutive hepatectomies: risk factors in patients with liver cirrhosis or obstructive jaundice. *World J Surg.* 2001;25:266-72. discussion 272-273.
22. Wai CT, Greenson JK, Fontana RJ, Kalbfleisch JD, Marrero JA, Conjeevaram HS, et al. A simple noninvasive index can predict both significant fibrosis and cirrhosis in patients with chronic hepatitis C. *Hepatology.* 2003;38:518-26.
23. Castera L, Vergniol J, Foucher J, Le Bail B, Chanteloup E, Haaser M, et al. Prospective comparison of transient elastography, fibrotest, APRI, and liver biopsy for the assessment of fibrosis in chronic hepatitis C. *Gastroenterology.* 2005;128:343-50.
24. Horii K, Kubo S, Hirohashi K, Kinoshita H. Changes in erythrocyte deformability after liver resection for hepatocellular carcinoma associated with chronic liver disease. *World J Surg.* 1999;23:85-90.
25. Kubo S, Tsukamoto T, Hirohashi K, Tanaka H, Shuto T, Takemura S, et al. Correlation between preoperative serum concentration of type IV collagen 7 s domain and hepatic failure following resection of hepatocellular carcinoma. *Ann Surg.* 2004;239:186-93.
26. Liver Cancer Study Group of Japan. Classification of primary liver cancer. 1st English ed. Tokyo: Kanehara; 1997.
27. Edmondson HA, Steiner PE. Primary carcinoma of the liver: a study of 100 cases among 48,900 necropsies. *Cancer.* 1954;7:462-503.
28. Knodell RG, Ishak KG, Black WC, Chen TS, Craig R, Kaplowitz N, et al. Formulation and application of a numerical scoring system for assessing histological activity in asymptomatic chronic active hepatitis. *Hepatology.* 1981;1:431-5.
29. Desmet VJ, Gerber M, Hoofnagle JH, Manns M, Scheuer PJ. Classification of chronic hepatitis: diagnosis, grading and staging. *Hepatology.* 1994;19:1513-20.
30. Liver Cancer Study Group of Japan. Primary liver cancer in Japan: clinicopathological features and results of surgical treatment. *Ann Surg.* 1990;211:277-87.
31. Nagasue N, Kohno H, Tachibana M, Yamanoi A, Ohmori H, El-Assal ON. Prognostic factors after hepatic resection for hepatocellular carcinoma associated with child-Turcotte class B and C cirrhosis. *Ann Surg.* 1999;229:84-90.
32. Takenaka K, Kanematsu T, Fukuzawa K, Sugimachi K. Can hepatic failure after surgery for hepatocellular carcinoma in cirrhotic patients be prevented? *World J Surg.* 1990;14:123-7.
33. Miyazaki S, Takasaki K, Yamamoto M, Tsugita M, Otsubo T. Liver regeneration and restoration of liver function after partial hepatectomy: the relation of fibrosis of the liver parenchyma. *Hepatogastroenterology.* 1999;46:2919-24.
34. Tanaka S, Kubo S, Tsukamoto T, Hirohashi K, Tanaka H, Shuto T, et al. Risk factors for intractable pleural effusion after liver resection. *Osaka City Med J.* 2004;50:9-18.
35. Eguchi H, Umeshita K, Sakon M, Nagano H, Ito Y, Kishimoto SI, et al. Presence of active hepatitis associated with liver cirrhosis is a risk factor for mortality caused by posthepatectomy liver failure. *Dig Dis Sci.* 2000;45:1383-8.
36. Fan ST, Lai EC, Lo CM, Ng IO, Wong J. Hospital mortality of major hepatectomy for hepatocellular carcinoma associated with cirrhosis. *Arch Surg.* 1995;130:198-203.
37. Matsumata T, Kanematsu T, Yoshida Y, Furuta T, Yanaga K, Sugimachi K. The indocyanine green test enables prediction of postoperative complications after hepatic resection. *World J Surg.* 1987;11:678-81.
38. Fujio N, Sakai K, Kinoshita H, Hirohashi K, Kubo S, Iwasa R, et al. Results of treatment of patients with hepatocellular carcinoma with severe cirrhosis of the liver. *World J Surg.* 1989;13:211-7. discussion 217-218.
39. Hemming AW, Scudamore CH, Shackleton CR, Pudek M, Erb SR. Indocyanine green clearance as a predictor of successful hepatic resection in cirrhotic patients. *Am J Surg.* 1992;163:515-8.
40. Yasui M, Harada A, Torii A, Nakao A, Nonami T, Takagi H. Impaired liver function and long-term prognosis after hepatectomy for hepatocellular carcinoma. *World J Surg.* 1995;19:439-43.
41. Midorikawa Y, Kubota K, Takayama T, Toyoda H, Ijichi M, Torzilli G, et al. A comparative study of postoperative complications after hepatectomy in patients with and without chronic liver disease. *Surgery.* 1999;126:484-91.
42. Imamura H, Sano K, Sugawara Y, Kokudo N, Makuuchi M. Assessment of hepatic reserve for indication of hepatic resection: decision tree incorporating indocyanine green test. *J Hepatobiliary Pancreat Surg.* 2005;12:16-22.
43. Poon RT, Fan ST, Tsang FH, Wong J. Locoregional therapies for hepatocellular carcinoma: a critical review from the surgeon's perspective. *Ann Surg.* 2002;235:466-86.

CLINICAL STUDIES

Differences in molecular alterations of hepatocellular carcinoma between patients with a sustained virological response and those with hepatitis C virus infection

Takehiro Hayashi^{1,2}, Akihiro Tamori¹, Manabu Nishikawa³, Hiroyasu Morikawa¹, Masaru Enomoto¹, Hiroki Sakaguchi¹, Daiki Habu¹, Norifumi Kawada¹, Shoji Kubo⁴, Shuhei Nishiguchi⁵ and Susumu Shiomi²

1 Department of Hepatology, Osaka City University Graduate School of Medicine, Osaka, Japan

2 Department of Nuclear Medicine, Osaka City University Graduate School of Medicine, Osaka, Japan

3 Department of Biochemistry and Molecular Pathology, Osaka City University Graduate School of Medicine, Osaka, Japan

4 Department of Surgery, Osaka City University Graduate School of Medicine, Osaka, Japan

5 Department of Internal Medicine, Hyogo College of Medicine, Nishinomiya, Japan

Keywords

hepatitis C virus – hepatocellular carcinoma – hypermethylation – interferon – mitochondrial DNA – p16 – p53 – sustained virological response

Correspondence

Akihiro Tamori, MD, Department of Hepatology, Osaka City University Graduate School of Medicine, 1-4-3 Asahimachi, Abeno-ku, Osaka 545-8585, Japan
Tel: +81 6 6645 2292
Fax: +81 6 6645 1433
e-mail: atamori@med.osaka-cu.ac.jp

Received 16 January 2008

Accepted 16 March 2008

DOI:10.1111/j.1478-3223.2008.01772.x

Abstract

Background/Aims: The mechanism of hepatocarcinogenesis remains unclear in patients in whom hepatitis C virus (HCV) disappears after interferon (IFN) therapy. We compared molecular alterations in hepatocellular carcinoma (HCC) between patients with a sustained virological response (SVR) to IFN and patients with HCV. **Methods:** The study group comprised 44 patients with HCV and 13 patients with SVR. One patient in the SVR group had two tumour nodules, both of which were examined. Mitochondrial DNA (mtDNA) mutations in displacement-loop lesions were directly sequenced. Mutation of the TP53 gene was examined by direct sequencing. The methylation status of p16, p15, p14, RB and PTEN genes was evaluated by a methylation-specific polymerase chain reaction. **Results:** The average number of mtDNA mutations was 4.2 in 44 HCCs with HCV and 2.0 in 14 HCCs with SVR ($P=0.0021$). mtDNA mutation was less frequently detected in HCCs from patients with SVR than in patients with HCV. TP53 mutations were detected in 12 (27%) of 44 HCCs with HCV and 2 (14%) of 14 SVR-HCCs. Hypermethylation of the p16, p15, p14, RB and PTEN promoters was, respectively, detected in 34, 13, 8, 12 and 11 of 44 HCCs from patients with HCV and 14, 0, 0, 2 and 2 of 14 HCCs from patients with SVR ($P=0.049, 0.021, 0.085, 0.322$ and 0.402). Hypermethylation of p16 was one of the most important alterations in SVR-HCC. **Conclusions:** Molecular alterations in hepatocarcinogenesis of patients with SVR-HCC were different from those of patients with continuous HCV infection.

Hepatitis C virus (HCV) is one of the most important risk factors for hepatocellular carcinoma (HCC). Clinical studies have suggested that HCV induces inflammation in the liver, followed by the accumulation of reactive oxygen species (ROS), which promote mutations in the human genome (1, 2). Persistent inflammation also results in repeated hepatocyte death and regeneration, leading to the gradual accumulation of DNA mutations in hepatocytes. Point mutations in tumour suppressor genes, including TP53, have been confirmed in hepatic cirrhosis in patients with HCV (3). Epigenetic alterations, such as methylation of the promoter of cell cycle gene inhibitors with the resulting loss of its expression, have been frequently detected in liver cirrhosis with viral infection (4, 5). Continuous inflammation induces genetic or epigenetic alterations, or both, in hepatocytes, culminating in a preneoplastic condition. HCV itself is an oncogenic virus. HCV core protein or HCV NS5A protein has oncogenic potential function in animal models without inflammation (6, 7). *In vitro* studies have suggested that HCV protein modifies host immunity to sustain infection (8). The suppression of immunological response is attributed to the failure to eliminate neoplastic cells from the liver. These findings suggest that cooperation between

virus-induced chronic inflammation and HCV coding proteins accelerates carcinogenesis in the liver.

Interferon (IFN) has potent antiviral activity against HCV. Antiviral therapy with pegylated IFN in combination with ribavirin produces a sustained virological response (SVR) in approximately 60% of patients with chronic hepatitis C (9, 10). Complete eradication of HCV by antiviral therapy is associated with a considerable reduction in the incidence of HCC (11, 12). Nevertheless, recent studies have shown that HCC develops in 2.5–4.2% of patients after eradication of HCV by IFN therapy (13–15). It is therefore important to delineate important features of HCC that develop after the elimination of HCV as compared with those established during sustained HCV infection. Makiyama *et al.* (15) speculated that cancer cells already exist in the liver before HCV eradication by IFN treatment. The integration of HBV DNA because of past HBV infections (16) or occult HCV infections (17) may be linked to SVR-HCC. However, the molecular mechanism leading to the development of SVR-HCC remains obscure.

In the present study, we compared genetic alterations in surgically resected specimens of HCCs between patients with SVR and those with continuous HCV infection. Our results might contribute to a better understanding of the molecular changes in

the liver of patients in whom HCC develops after the eradication of HCV.

Patients and methods

Patients

Thirteen consecutive patients who underwent surgical resection of HCC in Osaka City University Hospital after eradication of HCV by IFN monotherapy from 1998 June through 2007 July (SVR group) were studied (Table 1). One patient in the SVR group had two tumour nodules, both of which were examined. As a control, 44 HCV-RNA-positive patients with HCC were studied. Thus, 58 HCC samples and 57 noncancerous tissue samples were evaluated. One portion of each sample was frozen in liquid nitrogen immediately after resection and stored at -80°C until analysis. Total RNA and DNA were extracted from these portions by conventional methods as described previously (18). None of the patients had a history of exposure to aflatoxin B₁, more than 30 g/day of alcohol intake, insulin administration, hereditary haemochromatosis or other liver diseases such as hepatitis B, autoimmune hepatitis and primary biliary cirrhosis. The activity of hepatitis and stage of fibrosis were determined according to a modified version of Desmet's classification in liver tissue specimens before IFN therapy and in noncancerous liver tissue obtained intra-operatively (19).

Sequencing the displacement-loop region of mitochondrial DNA

Each DNA sample (50 ng) was subjected to amplification by polymerase chain reaction (PCR) with the use of overlapping sets of primers to screen the entire mitochondrial genome. To avoid coamplification of nuclear pseudogenes, the primers were selected with the use of mitochondrial DNA (mtDNA)-depleted cells established as described previously (2, 20). PCR (an initial incubation at 94°C for 5 min, followed by 35 cycles of 94°C for 30 s, 55°C for 30 s and 72°C for 1 min) was performed in a final volume of 50 μl with a GeneAmp PCR system 9600 (Perkin-Elmer Life Sciences Japan, Tokyo, Japan). Aberrant PCR products were purified with a QIAquick PCR purification kit (Qiagen, Tokyo, Japan) and sequenced with an Applied Biosystems DNA sequencer (Perkin-Elmer Life Sciences Japan) and a Dye Terminator Cycle Sequencing FS Ready Reaction kit (Applied Biosystems, Tokyo, Japan). The sequence of the displacement (D)-loop (nucleotides 100–600) was examined for all 57 patients with HCC. All mutations were confirmed by repeated DNA sequencing.

Direct sequencing for TP53

We directly sequenced exons 5 through 8 of TP53 genes, in which 98% of TP53 mutations are detected (21), in 58 tumours. One hundred nanograms of genomic DNA was subjected to 35 PCR cycles (94°C for 30 s, 55°C for 0.5, 0.5 and 1 min respectively) with rTaq DNA polymerase (TakaraBio Co. Ltd, Otsu, Japan). After the PCR products were purified with a QIAquick PCR purification kit, we sequenced the amplified products with a DNA sequencing system and a Dye Terminator Cycle Sequencing FS Ready Reaction kit.

Methylation-specific polymerase chain reaction

Bisulphite modification of genomic DNA was performed as described by Herman *et al.* (22). Briefly, 1 μg of DNA was

Table 1. Clinical characteristics of patients with sustained virological response-hepatocellular carcinoma and hepatitis C virus-hepatocellular carcinoma

	SVR-HCC	HCV-HCC	P-value
<i>n</i>	13	44	
Male/female	13/0	44/0	
Age	64.3 (55–73)	64.0 (34–79)	0.977
Anti-HCV(+) HCV-RNA(–)	13/0	44/44	
HbS antigen positivity	0	0	
IFN therapy	13	0	
ALT (IU/L)	35.0 (17–81)	73.2 (13–188)	0.0001
Diabetes mellitus			
With/without/ unknown	2/11/0	13/28/3	0.25
Alcohol habits			
Positive/negative/ unknown	5/8/0	23/17/4	0.23
Tumour differentiation			
Well/moderately/ poorly	0/4/10	5/20/19	0.066
Noncancerous liver			
Cirrhosis/noncirrhosis	4/9	20/24	0.34
Tumour diameter (mm) (average)	43.1 (12–125)	38.3 (10–180)	0.756
Extrahepatic metastasis	0	0	

ALT, alanine aminotransferase; HbS antigen, hepatitis B surface antigen; HCC, hepatocellular carcinoma; HCV, hepatitis C virus; IFN, interferon; SVR, sustained virological reaction.

denatured with NaOH, and 10 mM hydroquinone and 3 M sodium bisulphite were successively added to the mixture. The sample was incubated at 50°C for 16 h. Modified DNA was purified with the use of Wizard DNA purification resin (Promega Corporation, Madison, WI, USA), followed by ethanol precipitation. DNA methylation patterns were determined by chemical modification of the unmethylated cytosines to uracil and subsequent PCR, using primers specific for either methylated or modified unmethylated DNA. The primers used in this study are shown in Table 2 (23, 24). The PCR amplification procedure has been described previously (5). Ten microlitres of each PCR product was loaded directly onto nondenaturing 2% agarose gels, stained with ethidium bromide and visualized under ultraviolet illumination.

Semiquantitative reverse-transcription polymerase chain reaction analysis

To investigate *p16* mRNA expression, we performed reverse-transcription PCR (RT-PCR) with total RNA from 35 tumours and 27 noncancerous lesions. Briefly, 1 μg of the RNA was used as a template to generate complementary DNA (cDNA) using random hexamers and reverse transcriptase. The cDNA was used for PCR amplification. Primer sequences were 5'-CCACCCCGC TTTCGTAGT TTT-3' (upper primer) and 5'-TGCGAGGCTCG CAAGAAAT-3' (lower primer) for *p16* and 5'-CCTGCGCTT TGCCGATCC-3' (upper primer) and 5'-GGATCTTCATGAGG TAGTCAGTC-3' (lower primer) for β -actin. The PCR procedure for *p16* consisted of one cycle at 95°C for 12 min, 30 cycles at 95°C for 30 s, 51°C for 1 min and 72°C for 30 s, and one cycle at

Table 2. Primers used for methylation-specific polymerase chain reaction

Gene		Sequence
p16	Unmethylated	5'-TTATTAGAGGGTGGGGTGGATTGT-3' (sense) 5'-CAACCCCAAAACCAACATAA-3' (antisense)
	Methylated	5'-TTATTAGAGGGTGGGGCGGATCGC-3' (sense) 5'-GACCCCGAACCCGACCGTAA-3' (antisense)
p15	Unmethylated	5'-TGTGATGTGTTTGTATTTGTGGTT-3' (sense) 5'-CCATACAATAACCAACCAACAA-3' (antisense)
	Methylated	5'-GCGTTCGTATTTGCGGT-3' (sense) 5'-CGTACAATAACCGAACGACCGA-3' (antisense)
p14	Unmethylated	5'-TTTTTGGTGTAAAGGGTGGTGTAGT-3' (sense) 5'-CACAAAAACCCCTCACTCACAACAA-3' (antisense)
	Methylated	5'-GTGTTAAAGGGCGCGTAGC-3' (sense) 5'-AAAACCCCTCACTCGCGACGA-3' (antisense)
RB		5'-CTTTGTATAGCCCGTTAAGTG-3' (sense) 5'-GTCATGAGGAATAACTGGGA-3' (antisense)
PTEN	Unmethylated	5'-GTGTTGGTGGAGGTAGTGT-3' (sense) 5'-ACCACTTAACCTAAACCAACCA-3' (antisense)
	Methylated	5'-TTCGTTCTGTCGTCGTATT-3' (sense) 5'-GCCGCTTAACCTAAACCGAACCG-3' (antisense)

72 °C for 3 min. That for β -actin consisted of one cycle at 94 °C for 3 min, 24 cycles at 95 °C for 30 s, 60 °C for 1 min and 72 °C for 30 s, and one cycle at 72 °C for 3 min. Ten microlitres of each PCR product was loaded directly onto nondenaturing 8% polyacrylamide gels, and the gels were stained with SYBR Greene (BioWhittaker Molecular Applications, Rockland, ME, USA) according to the manufacturer's protocol. The intensity of the bands was quantified by densitometry.

Statistical analysis

Age, tumour size, liver function and mtDNA mutations were compared between the two groups with the Mann-Whitney *U* test. Histological findings, diabetes mellitus, alcohol use, tumour differentiation, TP53 mutation and methylation status were compared between the two groups with the χ^2 test.

Ethical considerations

This study protocol complied with the ethical guidelines of the Declaration of Helsinki (1975) and was approved by the Ethics

Committee of Osaka City University Graduate School of Medical.

Results

Histological findings in patients with sustained virological response

In patients with SVR, the period from the end of IFN treatment to hepatectomy for HCC ranged from 13 to 156 months. Histological examinations, performed in 11 of the 13 patients with SVR-HCCs, showed that the staging of hepatic fibrosis improved in five patients and the grade of hepatic activity improved in eight patients (Table 3).

Mitochondrial DNA mutations of hepatocellular carcinoma

Mutations of mtDNA were found in both HCC and noncancerous liver tissue. Previously, three mutation sites in mtDNA have been reported to be unique for the Japanese. Excluding these sites, we evaluated the average number of mtDNA mutations in D-loop lesions (Table 4). The average number of mtDNA mutations in D-loop lesions was 4.2 in 44 HCCs with HCV and 2.0 in 14 HCCs from SVR patients. The average number of mtDNA mutations in D-loop lesions was 2.8 in 44 noncancerous lesions with HCV and 1.3 in 13 noncancerous lesion from SVR patients. No specific mutation in mtDNA of SVR-HCC was found in the present study. The frequency of mtDNA mutations in HCC was significantly lower in SVR patients than in HCV patients ($P=0.0021$). The frequency of mtDNA mutations was also lower in noncancerous livers of SVR patients ($P=0.007$). In the present study, no regularity of mtDNA mutations was found in the D-loop region.

TP53 mutation analysis

TP53 mutations were detected in 12 (27.3%) of 44 HCCs with HCV (Table 4). In detail, TP53 was mutated in codon 123, TAT to TTC; codon 132, AAG to TTG; codon 133, ATG to TTG; codon 158, CGC to CTC; codon 189, GCC to GTC; codon 220, TAT to TGT; codon 246, ATG to GTG; codon 272, GAG to GTG; codon 275, TGT to TAT; and codon 271, CAT to CGT. Two cases were mutated by insertion in exons 5 and 8. The histological findings showed that HCCs with TP53 mutations consisted of seven moderately differentiated and five poorly differentiated HCCs. TP53 mutations were detected in two (14.3%) of 14 HCCs from the 13 patients in whom HCV was eradicated by IFN therapy. In detail, TP53 was mutated in codon 135, TGC to TGG and codon 242, TGC to TTC. The histological findings showed that HCCs with TP53 mutations in SVR patients consisted of two poorly differentiated HCCs.

Methylation pattern of hepatocellular carcinoma

In patients with HCV, hypermethylation of p16, p15, p14, RB and the PTEN promoter was, respectively, detected in 34 (77.3%), 13 (29.5%), 8 (18.2%), 12 (27.3%) and 11 (25.0%) of 44 HCCs and 13 (29.5%), 14 (31.8%), 4 (9.1%), 11 (25.0%) and 5 (11.4%) of 44 noncancerous liver samples (Fig. 1A). In patients with SVR, hypermethylation of p16, p15, p14, RB and the PTEN promoter was, respectively, detected in 14 (100%), 0 (0%), 0 (0%), 2 (14.3%) and 2 (14.3%) of 14 HCCs and 2 (15.4%), 0 (0%), 0 (0%), 2 (15.4%) and 0 (0%) of 13

Table 3. Clinical course of patients with sustained virological response-hepatocellular carcinoma

Case	Pre-IFN therapy				Span for carcinogenesis after IFN therapy (months)	At operation		BMI
	Genotype	HCV-RNA	F factor	A factor		F factor	A factor	
56	1b	1 MEq	2	2	45	2	1	23.7
101	2a	+	3	2	19	4	2	23.7
149	2a	1.1 MEq	4	3	20	4	2	23.6
196	2b	+	2	2	41	1	2	23.4
198	2a	0.4 MEq	2	2	103	1	1	21.5
200	2a	1.1 MEq	2	2	13	2	1	24.6
221	2a	0.9 MEq	2	3	80	2	2	18.1
268	Unknown	+	Unknown	Unknown	144	1	1	20.3
269	2a	0.4 MEq	2	3	156	0	0	23.6
271	1b	+	4	1	156	3	1	28.1
325	1b	300 KIU	3	2	15	2	1	25.2
327	2b	160 KIU	3	3	36	4	2	26.8
328	1b	+	Unknown	Unknown	14	4	2	27.6

BMI, body mass index; HCV, hepatitis C virus; HCC, hepatocellular carcinoma; IFN, interferon; SVR, sustained virological response.

Table 4. Comparison of mutation in the displacement-loop of mitochondrial DNA, mutation in TP53 and methylation between sustained virological response-hepatocellular carcinoma and hepatitis C virus-hepatocellular carcinoma

	SVR-HCC	HCV-HCC	P-value
Mean mutation number in D-loop of mtDNA	2.0	4.2	0.0021
TP53 mutation	14.3%	27.3%	0.322
Methylation			
<i>p16</i>	100.0%	77.3%	0.049
<i>p15</i>	0.0%	29.5%	0.021
<i>p14</i>	0.0%	18.2%	0.085
<i>RB</i>	14.3%	27.3%	0.322
<i>PTEN</i>	14.3%	25.0%	0.402

D-loop, displacement-loop; HCC, hepatocellular carcinoma; HCV, hepatitis C virus; mtDNA, mitochondrial DNA; SVR, sustained virological response.

noncancerous liver samples (Fig. 1B). Methylation of *p14*, *p15*, *RB* and *PTEN* was thus slightly but not significantly more frequent in HCV-HCC than in SVR-HCC.

Expression of *p16* mRNA in hepatocellular carcinoma

Expression of *p16* mRNA was examined in 29 patients with HCV-HCC and six with SVR-HCC. In six SVR-HCCs with *p16* promoter methylation, *p16* mRNA expression was lower than that in the noncancerous liver (Fig. 2). In 29 HCV-HCCs with *p16* methylation, *p16* mRNA expression was lower than that in HCC without *p16* methylation.

Discussion

In agreement with previous studies, all patients with SVR-HCC were males in the present study (15), suggesting that sex-related factors have a role in SVR-HCC. We, therefore, studied male

patients with HCV-HCC and matched subjects with SVR-HCC. First of all, mtDNA mutations were frequent in HCC as well as in noncancerous liver tissues from patients with HCV (2, 25). Chronic viral inflammation induces ROS production, followed by mtDNA damage in the liver, which is speculated to contribute to hepatocarcinogenesis (25). In contrast to mtDNA mutations, the frequency of mtDNA mutations was low in SVR liver. Histological examination of noncancerous liver tissue showed that persistent inflammation was minimal or absent in SVR patients. Nishikawa *et al.* reported that IFN therapy reduces the frequency of mtDNA mutations in the liver of patients with chronic hepatitis C. In their study, a reduced frequency of mtDNA mutations was detected only in patients whose transaminases were normalized by IFN therapy in association with HCV elimination (26). Our study also showed that the frequency of mtDNA mutations was reduced in the liver of SVR patients. In the present study, no patient with HCV-HCC received IFN. Therefore, we could not exactly clarify which factor was more closely related to fewer mtDNA mutations in SVR-HCC, IFN or HCV eradication. However, we speculate that chronic inflammation was not related to the development of HCC in SVR patients.

Destruction of tumour suppressor gene function is thought to be a critical step in carcinogenesis. Previous studies showed that TP53 mutations were detected in 27% (21) and 38.3% (27) of HCCs with viral infection. These high rates were apparently related to the late stage of hepatocarcinogenesis. In agreement with these previous reports, TP53 was mutated in seven moderately differentiated HCC and five poorly differentiated HCC (27.7%) in the 44 patients with HCV in our study. To our knowledge, no previous study has reported TP53 mutations in SVR-HCC. We found two TP53 mutations in 14 SVR-HCC, including dedifferentiated lesions. mtDNA damage induced by chronic viral hepatitis correlates with genomic injury. It was speculated that a decrease in mtDNA mutations followed loss of TP53 mutations. Although the small number of the SVR-HCCs examined in our study precludes firm conclusions, TP53 alterations might differ between SVR-HCC and HCV-HCC.

Next, we showed epigenetic alterations in both HCV-HCC and SVR-HCC. Previous studies have reported that *p16*, *p15*,

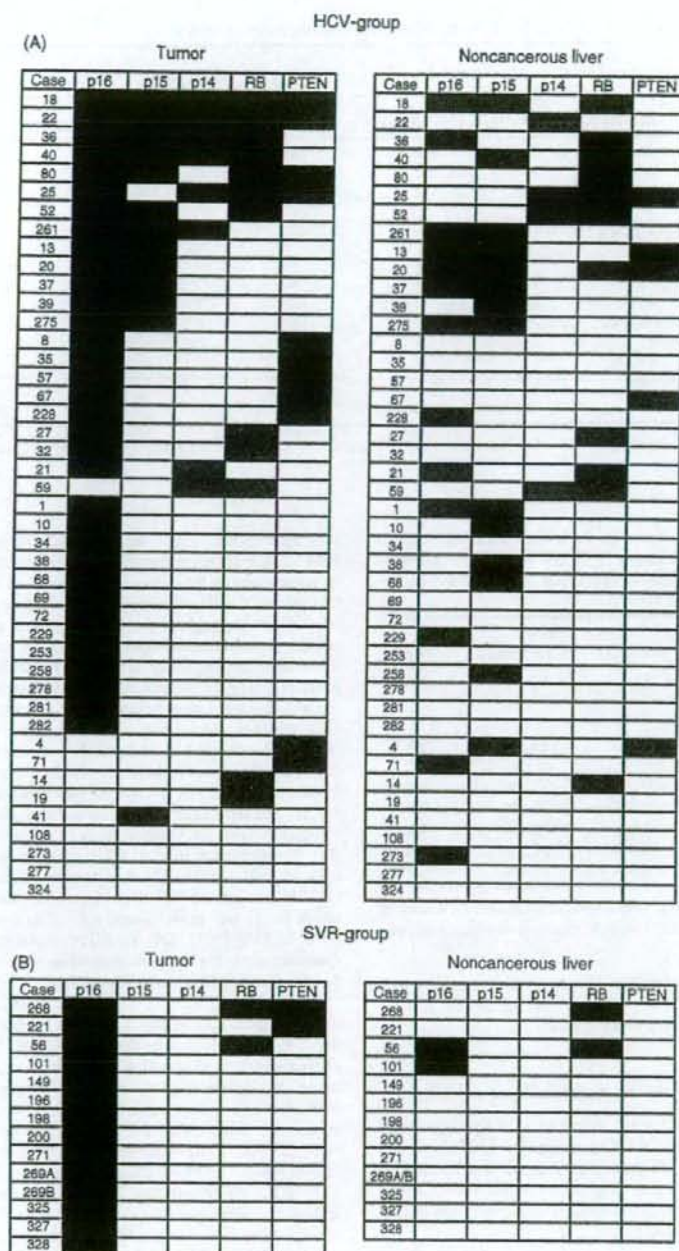


Fig. 1. Methylation patterns of *p16*, *p15*, *p14*, *RB* and *PTEN* promoter in 44 hepatocellular carcinomas (HCCs) and 44 noncancerous liver samples from the hepatitis C virus (HCV) group were examined by methylation-specific polymerase chain reaction (MSP) (A). Methylation patterns were also examined by MSP for 14 HCCs and 13 noncancerous liver samples from the sustained virological response (SVR) group (B). Black boxes indicate methylated sequences, whereas blank boxes indicate unmethylated sequences.

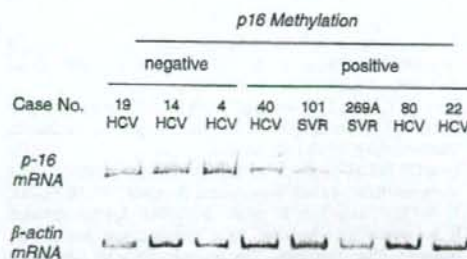


Fig. 2. Expression of *p16* mRNA in hepatocellular carcinoma (HCC). The promoter of *p16* was methylated in cases 40, 101, 269A, 80 and 22. In these tumours, *p16* expression was lower than that in HCC without methylation. β -actin expression was examined as a control. HCV, hepatitis C virus; SVR, sustained virological response.

p14, *RB* and *PTEN* are, respectively, methylated in 58–82% (4, 5, 28–32), 5–64% (5, 32–34), 0–36% (5, 32), 21% (5) and 17% (28) of HCCs from patients with viral infections. In our study, methylation of *p16*, *p15*, *p14*, *RB* and *PTEN* was, respectively, detected in 34 (77.3%), 13 (29.5%), eight (18.2%), 12 (27.3%) and 11 (25.0%) of 44 HCV-HCCs. Our findings are thus consistent with those of previous studies. In SVR-HCC, *p16* was methylated in all samples, whereas *RB* and *PTEN* were methylated in only two samples and methylation of *p15* and *p14* was not detected. This was a novel methylation profile that differed from that of SVR-HCC and HCV-HCC. We showed that promoter methylation of the *p16* gene, leading to the loss of *p16* expression, was frequently observed not only in HCV-HCC but also in SVR-HCC. These data suggested that aberrant *p16* methylation might contribute to the development of SVR-HCC.

Epidemiological studies have shown that past exposure to *Helicobacter pylori* is closely associated with an increased risk of gastric cancer and that most cases of *H. pylori*-negative gastric cancer have a history of exposure to *H. pylori* (35, 36). Maekita and colleagues reported that permanent methylation of specific CpG islands in gastric mucosae is associated with a heightened risk of gastric cancer in *H. pylori*-negative patients (37, 38). It was speculated that methylation of CpG islands in gastric stem cells led to a continuous high level of methylation in gastric mucosae (39). It was well known that HCV was spontaneously eradicated in 20% of patients with the acute infection (40). To our knowledge, there has been no report about HCC development in patients who had been cured in acute hepatitis. In the present study, *p16* was methylated in both HCC infected with HCV and HCC after eradication of HCV. We speculate that *p16* in hepatic stem cells might be methylated in the continuous presence of HCV. These cells with methylated *p16* might survive and grow after eradication of HCV by IFN therapy. Future studies should examine the methylation status of genes in successive liver specimens obtained before and after IFN therapy.

In conclusion, epigenetic alterations of some genes in SVR-HCC differed from those in HCV-HCC. Moreover, mutation of mtDNA was less common in SVR-HCC than in HCV-HCC. The present results suggest that the development of HCC in patients cured of HCV infection by IFN therapy might be associated with particular molecular alterations.

Acknowledgements

We acknowledge Ms Mayumi Shinzaki for her excellent technical assistance. This study was supported in part by a grant-in-aid from the Japan Society of the Promotion of Science (no. 16590619 to A. T.).

References

- Marrogi AJ, Khan MA, van Gijssel HE, et al. Oxidative stress and p53 mutations in the carcinogenesis of iron overload-associated hepatocellular carcinoma. *J Natl Cancer Inst* 2001; 93: 1652–5.
- Nishikawa M, Nishiguchi S, Shiomi S, et al. Somatic mutation of mitochondrial DNA in cancerous and noncancerous liver tissue in individuals with hepatocellular carcinoma. *Cancer Res* 2001; 61: 1843–5.
- Minouchi K, Kaneko S, Kobayashi K. Mutation of p53 gene in regenerative nodules in cirrhotic liver. *J Hepatol* 2002; 37: 231–9.
- Kaneto H, Sasaki S, Yamamoto H, et al. Detection of hypermethylation of the p16 (INK4A) gene promoter in chronic hepatitis and cirrhosis associated with hepatitis B or C virus. *Gut* 2001; 48: 372–7.
- Roncalli M, Bianchi P, Bruni B, et al. Methylation framework of cell cycle gene inhibitors in cirrhosis and associated hepatocellular carcinoma. *Hepatology* 2002; 36: 427–32.
- Moriya K, Fujie H, Shintani Y, et al. The core protein of hepatitis C virus induces hepatocellular carcinoma in transgenic mice. *Nat Med* 1998; 4: 1065–7.
- Majumder M, Ghosh AK, Steele R, et al. Hepatitis C virus NS5A physically associates with p53 and regulates p21/waf1 gene expression in a p53-dependent manner. *J Virol* 2001; 75: 1401–7.
- Larsson M, Babcock E, Grakoui A, et al. Lack of phenotypic and functional impairment in dendritic cells from chimpanzees chronically infected with hepatitis C virus. *J Virol* 2004; 78: 6151–61.
- McHutchison JG, Gordon SC, Schiff ER, et al. Interferon alfa-2b alone or in combination with ribavirin as initial treatment for chronic hepatitis C. Hepatitis Interventional Therapy Group. *N Engl J Med* 1998; 339: 1485–92.
- Manns MP, McHutchison JG, Gordon SC, et al. Peginterferon alfa-2b plus ribavirin compared with interferon alfa-2b plus ribavirin for initial treatment of chronic hepatitis C: a randomised trial. *Lancet* 2001; 358: 958–65.
- Bruno S, Stroffolini T, Colombo M, et al. Sustained virological response to interferon-alpha is associated with improved outcome in HCV-related cirrhosis: a retrospective study. *Hepatology* 2007; 45: 579–87.
- Yoshida H, Shiratori Y, Moriyama M, et al. Interferon therapy reduces the risk for hepatocellular carcinoma: national surveillance program of cirrhotic and noncirrhotic patients with chronic hepatitis C in Japan. IHIT Study Group. Inhibition of Hepatocarcinogenesis by Interferon Therapy. *Ann Intern Med* 1999; 131: 174–81.
- Toyoda H, Kumada T, Tokuda A, et al. Long-term follow-up of sustained responders to interferon therapy, in patients with chronic hepatitis C. *J Viral Hepat* 2000; 7: 414–9.
- Enokimura N, Shiraki K, Kawakita T, et al. Hepatocellular carcinoma development in sustained viral responders to interferon therapy in patients with chronic hepatitis C. *Anticancer Res* 2003; 23: 593–6.
- Makiyama A, Itoh Y, Kasahara A, et al. Characteristics of patients with chronic hepatitis C who develop hepatocellular carcinoma after a sustained response to interferon therapy. *Cancer* 2004; 101: 1616–22.
- Tamori A, Nishiguchi S, Shiomi S, et al. Hepatitis B virus DNA integration in hepatocellular carcinoma after interferon-induced

- disappearance of hepatitis C virus. *Am J Gastroenterol* 2005; 100: 1748-53.
17. Radkowski M, Gallegos-Orozco JF, Jablonska J, et al. Persistence of hepatitis C virus in patients successfully treated for chronic hepatitis C. *Hepatology* 2005; 41: 106-14.
 18. Tamori A, Yamanishi Y, Kawashima S, et al. Alteration of gene expression in human hepatocellular carcinoma with integrated hepatitis B virus DNA. *Clin Cancer Res* 2005; 11: 5821-6.
 19. Desmet VJ, Gerber M, Hoofnagle JH, et al. Classification of chronic hepatitis: diagnosis, grading and staging. *Hepatology* 1994; 19: 1513-20.
 20. King MP, Attardi G. Human cells lacking mtDNA: repopulation with exogenous mitochondria by complementation. *Science* 1989; 246: 500-3.
 21. Hayashi H, Sugio K, Matsumata T, et al. The clinical significance of p53 gene mutation in hepatocellular carcinomas from Japan. *Hepatology* 1995; 22: 1702-7.
 22. Herman JG, Graff JR, Myohanen S, et al. Methylation-specific PCR: a novel PCR assay for methylation status of CpG islands. *Proc Natl Acad Sci USA* 1996; 93: 9821-6.
 23. Zysman MA, Chapman WB, Bapat B. Considerations when analyzing the methylation status of PTEN tumor suppressor gene. *Am J Pathol* 2002; 160: 795-800.
 24. To KF, Leung WK, Lee TL, et al. Promoter hypermethylation of tumor-related genes in gastric intestinal metaplasia of patients with and without gastric cancer. *Int J Cancer* 2002; 102: 623-8.
 25. Tamori A, Nishiguchi S, Nishikawa M, et al. Correlation between clinical characteristics and mitochondrial D-loop DNA mutations in hepatocellular carcinoma. *J Gastroenterol* 2004; 39: 1063-8.
 26. Nishikawa M, Nishiguchi S, Kioka K, et al. Interferon reduces somatic mutation of mitochondrial DNA in liver tissues from chronic viral hepatitis patients. *J Viral Hepat* 2005; 12: 494-8.
 27. Huang LR, Hsu HC. Cloning and expression of CD24 gene in human hepatocellular carcinoma: a potential early tumor marker gene correlates with p53 mutation and tumor differentiation. *Cancer Res* 1995; 55: 4717-21.
 28. Schagdarsurengin U, Wilkens L, Steinemann D, et al. Frequent epigenetic inactivation of the RASSF1A gene in hepatocellular carcinoma. *Oncogene* 2003; 22: 1866-71.
 29. Matsuda Y, Ichida T, Matsuzawa J, et al. p16(INK4) is inactivated by extensive CpG methylation in human hepatocellular carcinoma. *Gastroenterology* 1999; 116: 394-400.
 30. Liew CT, Li HM, Lo KW, et al. High frequency of p16INK4A gene alterations in hepatocellular carcinoma. *Oncogene* 1999; 18: 789-95.
 31. Li X, Hui AM, Sun L, et al. p16INK4A hypermethylation is associated with hepatitis virus infection, age, and gender in hepatocellular carcinoma. *Clin Cancer Res* 2004; 10: 7484-9.
 32. Fukui K, Yokosuka O, Imazeki F, et al. Methylation status of p14ARF, p15INK4b, and p16INK4a genes in human hepatocellular carcinoma. *Liver Int* 2005; 25: 1209-16.
 33. Jin M, Piao Z, Kim NG, et al. p16 is a major inactivation target in hepatocellular carcinoma. *Cancer* 2000; 89: 60-8.
 34. Wong IH, Lo YM, Yeo W, et al. Frequent p15 promoter methylation in tumor and peripheral blood from hepatocellular carcinoma patients. *Clin Cancer Res* 2000; 6: 3516-21.
 35. Forman D, Webb P, Parsonnet J. *H. pylori* and gastric cancer. *Lancet* 1994; 343: 243-4.
 36. Forman D, Newell DG, Fullerton F, et al. Association between infection with *Helicobacter pylori* and risk of gastric cancer: evidence from a prospective investigation. *BMJ* 1991; 302: 1302-5.
 37. Maekita T, Nakazawa K, Mihara M, et al. High levels of aberrant DNA methylation in *Helicobacter pylori*-infected gastric mucosae and its possible association with gastric cancer risk. *Clin Cancer Res* 2006; 12: 989-95.
 38. Tatematsu M, Tsukamoto T, Mizoshita T. Role of *Helicobacter pylori* in gastric carcinogenesis: the origin of gastric cancers and heterotopic proliferative glands in Mongolian gerbils. *Helicobacter* 2005; 10: 97-106.
 39. Ushijima T, Nakajima T, Maekita T. DNA methylation as a marker for the past and future. *J Gastroenterol* 2006; 41: 401-7.
 40. Alter MJ. Epidemiology of hepatitis C in the West. *Semin Liver Dis* 1995; 15: 5-14.

Impact of Hepatoma-derived Growth Factor on Hepatocellular Carcinoma

Hideji Nakamura *

Division of Hepatobiliary and Pancreatic Medicine, Department of Internal Medicine, Hyogo College of Medicine, Mukogawa-cho 1-1, Nishinomiya, Hyogo 663-8501, Japan

Abstract

Hepatoma-derived growth factor (HDGF) is a new type growth factor which was cloned from a human hepatocellular carcinoma (HCC) cell line. HDGF is the main member of HDGF family which has a nuclear targeting potential and PWWP domain in their N-terminal region. HDGF was highly expressed in various organs including liver in the fetal stage, and significantly decreased near birth and adult stage. HDGF was

strongly expressed in HCC cells, compared with the adjacent tissues, and exogenously supplied and endogenously over-expressed HDGF enhanced the proliferation of HCC cells. In mouse hepato-carcinogenesis model, HDGF was significantly induced in the liver tissues at an early stage before liver tumor development. HDGF-over-expressing cells generated red tumors rich in vasculature in nude mice. HDGF has an angiogenic potential. HDGF enhanced tumor growth *in vivo* through both its direct angiogenic

*Correspondence to: Hideji Nakamura; E-mail:nakamura@hyo-med.ac.jp

activity and induction of VEGF. Furthermore, the higher expression of HDGF showed more malignant potential for cancer progression. By immunohistochemistry, HDGF should be a useful prognostic factor for disease-free and/or overall survivals in patients who have undergone the resection of HCC. This review will describe the current information about the molecular characteristics and physiological functions of HDGF in HCC development and progression, and its possible clinical utility for the regulation of HCC.

Introduction

Hepatocellular carcinoma (HCC) have appeared at high incidence in cirrhotic liver with chronic inflammation infected with hepatitis C virus (HCV) or hepatitis B virus (HBV). HCC develop by the accumulation of dysregulated gene expression from multistep genetic mutations of oncogenes and/or suppressor genes. These oncogenic proteins and tumor suppressor proteins generally include growth factors, their receptors, intracellular signal transduction molecules and transcriptional regulatory factors. In liver, p53 and retinoblastoma gene is well known to be involved in hepatocarcinogenesis. Over-expression of several factors and/or down-expression of some growth suppressors induced carcinogenesis and cancer progression. As for growth

factors and growth factor receptors, transforming growth factor (TGF)-alpha, TGF-beta, epidermal growth factor (EGF), heparin binding-EGF-like growth factor (HB-EGF), fibroblast growth factor (FGF)-1, FGF-2, platelet-derived growth factor (PDGF), vascular endothelial growth factor (VEGF) and their receptors, EGFR, FGFR, PDGFR, VEGFR have been reported to be deeply involved in HCC development and progression. If it is possible to regulate the expression and activity of these proteins, new effective tools would be developed for cancer regulation. We cloned a new type of growth factor from human HCC cell line, HuH-7, which can proliferate autonomously in a serum-free chemically-defined medium (1,2). We have called it hepatoma-derived growth factor (HDGF).

Recently, some interesting experimental and clinical approaches for HDGF have clarified the possible roles of HDGF on cancer development and progression. In the following review, we focus on HDGF and describe its roles on hepato-carcinogenesis and HCC progression and its potential clinical utility for regulation of HCC.

Molecular characteristics of HDGF

HDGF is a unique growth factor of an acidic 26kDa protein with unique physical and chemical characteristics, which is

categorized in the nuclear targeting growth factors (2-4). HDGF has high affinity to the glycosaminoglycans heparin and heparan sulphate (1,2,5,6). Amino acid sequence analysis demonstrated the presence of two nuclear localization signals (NLS) in the molecule of HDGF. The first functional nuclear localization signal (NLS1) resided in the *hath* region (described below) of the N-terminal region and the second NLS (NLS2) in gene-specific regions of the C-terminal region of the HDGF molecule (3). The ability for trafficking to the nucleus is essential to display growth stimulating activity in HDGF-over-expression cells. In particular, the gene-specific region of HDGF, at least the bipartite NLS sequence and both the N- and C-terminal neighboring portions, is essential for the mitogenic activity (3). HDGF's mitogenic activity depends on its nuclear targeting (3,4).

HDGF Family

HDGF is the primary member of the HDGF family proteins. The N-terminal region of HDGF was highly conserved among the other five HDGF-related proteins (HRP) (5, 7-10). This region is called *hath* (homologous to the amino terminus of HDGF) region. HDGF family members are characterized based on the presence of the *hath* region and NLS in their gene-specific regions and the targeting potential to the nucleus (7,11). Of the HDGF family

proteins, HDGF, HRP-3, HRP-4 and lens epithelial cell-derived growth factor (LEDGF) have the growth stimulating activity (5,8,9). LEDGF, one of two HDGF family members with high molecular weight, is identical to p54/72, which is an RNA-binding protein and transcriptional cofactor for regulating general transcriptional factors (10). Thus, HDGF may be an interesting bifunctional factor in the exertion of its function via signaling pathway from cell membrane binding and its direct action on DNA after nuclear translocation.

Hath domain

Recently, HDGF family has been shown to belong to the PWWP domain containing protein family (12,13). *Hath* region, which is well-conserved in the HDGF family proteins contains the PWWP domain (14,15). The PWWP motif was first described in a candidate gene WHSC1 in Wolf-Hirschhorn syndrome. Among the HDGF family proteins, the PWWP domain in the *hath* region is well-conserved, but a clear divergence in the PWWP domains can be detected among the HDGF family and the other PWWP domain containing proteins. The DNA binding ability of PWWP domain suggests that the HDGF family proteins bind to some component of chromatin via this domain (14,15). Indeed, DNA binding was confirmed in the *hath* region of HDGF (16). Furthermore, surface

plasma resonance analysis shows that this *hath* domain is primarily responsible for heparin binding (6). HDGF may work another function in the nucleus in addition to the growth stimulating activity, especially for apoptosis or cell survivals.

In contrast, exogenously supplied HDGF stimulated the proliferation of fibroblasts, endothelial cells and fetal hepatocytes (2,17-20). These facts suggest that receptor-mediated signal transduction systems work to exert HDGF activity to some degree in some physiological conditions. In our study, possible receptor-binding site or membrane binding region for internalization presumed to be resided in the *hath* region (3). A possible receptor-binding site is estimated to be residing at amino acid residues 81-100 within the *hath* region, however, HDGF which had deleted these 20 amino acid residues still had proliferation activity (21). Exogenous HDGF stimulated the Erk phosphorylation in endothelial cells (22). Thus, the putative receptor-binding site is considered to reside in the *hath* region, and extensive research on the function of the *hath* domain should be performed in the future. These findings suggest that HDGF exerts its proliferating activity via two different pathways; 1) via a plasma membrane-located HDGF receptor for which signaling depends on the *hath* region, especially amino acid residues 81-100, resulting in MAP kinase activation, and 2)

via targeting to the nucleus by NLS. Thus, another membrane receptor for HDGF should be present in the plasma membrane for HDGF, although a probable receptor has not yet been identified.

Biological activity of HDGF

HDGF has a growth stimulating activity.

HDGF stimulates the proliferation of several cells including fibroblasts, smooth muscle cells, endothelial cells, bronchial and colon epithelial cells, and hepatocytes (1-4, 17,18,20,22-24). HDGF stimulated the DNA synthesis, increased the cell number, and enhanced the cell migration. Furthermore, HDGF is expressed more abundantly in various human cancers including HCC, and stimulates the proliferation of several cancer cells. Antisense HDGF oligonucleotides and anti-HDGF antibody suppressed the proliferation of cancer cells (23,25). Over-expression of HDGF stimulates the cell proliferation in vitro and generated tumor in nude mice in vivo. On the other hand, knock-down of HDGF expression by HDGF-specific small interfering RNA (siRNA) in cancer cells resulted in lesser invasion activity in vitro and lower growth in vivo (24,26).

HDGF is a developmentally regulated gene.

In the fetus, HDGF was abundantly expressed in the liver, heart, kidney, lungs,

and gut (17,18,20,27-29). In the fetus, HDGF was also expressed abundantly in the cardiovascular systems, including heart and aorta (18,27). HDGF was expressed in endothelial cells from fetal rat aorta, and disappeared in adult aorta. Immunocytochemistry revealed HDGF in hind gut epithelia as well as atrial myocytes in the fetal rat (27). HDGF was reported to be widely distributed in the renal anlage at the early stages of renal development and disappeared from the adult kidney except for a small portion of the renal distal tubules (17). HDGF mRNA was most abundant at sites of nephron morphogenesis and ureteric bud cells in embryonic kidneys. HDGF was induced by airway pressure during lung development in the *in vitro* murine fetal lung model with airway ligation (28). HDGF expression was enhanced dominantly in the bronchial and alveolar epithelial cells including type II pneumocytes by bleomycin-instillation in mice (24). HDGF expressed prominently in early gut tissue, and its overexpression inhibited the maturation in fetal intestine explants (29). Furthermore, HDGF was expressed in the nucleus of the colonic epithelial cells, dominantly in the bottom of the intestinal crypts by immunohistochemical analysis (23).

HDGF was highly expressed in fetal liver of the mid-gestation stage, and was markedly decreased near birth. HDGF expression was significantly decreased with

differentiation in fetal hepatocytes induced by oncostatin M treatment in *in vitro* primary culture differentiation system (20). Adenoviral introduction of HDGF antisense cDNA into the fetal hepatocytes suppressed their proliferation, and the inhibitory effects of the HDGF antisense virus were recovered by exogenous HDGF (20). These findings suggested that HDGF play important roles in the proliferation of immature hepatocytes and hepatic progenitor cells including oval cells.

Roles of HDGF in hepatocellular carcinoma

HDGF is involved in hepato-carcinogenesis

The Fatty Liver Shionogi (FLS) mouse is an inbred strain that develops spontaneous fatty liver without obesity. In these mice, liver tumors develop at 40 weeks after birth, with the number and size increasing with age to about 45% in 52 weeks and 90% at 72 weeks after birth in male mice; these tumors have been histologically diagnosed as hepatocellular adenoma and carcinoma (30,31). HDGF was expressed more abundantly in these tumor cells than the adjacent hepatocytes (32). In the liver of FLS mice, Northern analysis revealed that HDGF expression increased gradually from the age of 24 weeks at the basal expression through to 52 weeks after birth, showing that HDGF expression

had already increased at an early stage before the tumors developed microscopically in the liver (32). In the non-tumorous liver, HDGF is more dominantly expressed in hepatocytes with fat droplets than the non-parenchymal cells. Interestingly, in the non-tumorous liver with abundant fatty change, the foci that expressed HDGF appeared at 24 weeks of age, and the number of these foci increased with age, before tumor developmental stage. Immunohistochemical studies showed these high HDGF-expressing foci were the activated macrophage clusters with enhanced DNA synthesis (32). The roles of these activated macrophage foci on the carcinogenesis has not yet been clarified. However, these findings give a hint for the mechanism of development of HCC in non-alcoholic steatohepatitis (NASH) in human. These studies suggest that HDGF may be induced and secreted or released from the activated hepatocytes and/or these foci, and enhance the cell cycle progression of hepatocytes, and induce their transformation in an intracrine, autocrine and/or paracrine manner. Then, when HCC has developed HDGF promotes the proliferation of HCC cells and induced more malignant potentials in HCC. Furthermore, HDGF is highly expressed in oval cells, which are a bi-functional progenitor cells and can differentiate to the bile duct cells and hepatocytes. Oval cells are also considered to be a candidate progenitor cell developing

to HCC cells. By differential subtractive chain reaction from strong anchorage-independent growth to its negative HCC cells, HDGF was cloned as one of the genes related to anchorage-independency (33). Conversely, down regulation of HDGF by use of HDGF-siRNA has minimal effect on anchorage-dependent growth but reduces significantly anchorage-independent growth of NSCLC cells in soft agar (26). On the other hand, in our experiments, HDGF-over-expressing NIH3T3 cells can develop more small colonies than parent or neomycin-resistant cells, but significantly large colonies in soft agar assay (19). HDGF-over-expressing NIH3T3 cells generated sarcomatous tumors in nude mice, suggesting that HDGF is an oncogenic protein. Therefore, HDGF should play an important role at least as one step to let cells gain the transforming activity and anchorage-independent growth. These findings strongly suggest that HDGF potentially participates in hepato-carcinogenesis and in the early stage of HCC.

HDGF enhances HCC progression

HDGF protein was abundantly expressed in various human HCC cell lines. Indeed, HDGF expression was higher than in the adjacent liver tissues in humans and rodents (32,34). Recombinant HDGF significantly stimulated the proliferation of HCC cells (25). The HDGF-over-