

28. Sobin LH, Wittekind CH: *TNM Classification of Malignant Tumours* 6th edition. Wiley, New York; 2002.
29. Siewert JR, Kestlmeier R, Busch R, et al: **Benefits of D2 lymph node dissection for patients with gastric cancer and pN0 and pN1 lymph node metastases.** *Br J Surg* 1996, **83**:1144-1147.
30. Isozaki H, Okajima K, Fujii K: **Histological evaluation of lymph node metastasis on serial sectioning in gastric cancer with radical lymphadenectomy.** *Hepatogastroenterology* 1997, **44**:1133-1136.
31. Natsugoe S, Mueller J, Stein HJ, Feich M, Hoffer H, Siewert JP: **Micrometastasis and tumor cell microinvolvement of lymph nodes from esophageal squamous cell carcinoma: frequency, associated tumor characteristics, and impact on prognosis.** *Cancer* 1998, **83**:858-866.
32. Matsumoto M, Natsugoe S, Ishigami S, Uenosono Y, Takao S, Aikou T: **Rapid immunohistochemical detection of lymph node micrometastasis during operation for upper gastrointestinal carcinoma.** *Br J Surg* 2003, **90**:563-566.
33. Marutsuka T, Shimada S, Shiomori K, et al: **Mechanisms of peritoneal metastasis after operation for non-serosa-invasive gastric carcinoma: an ultrarapid detection system for intraperitoneal free cancer cells and a prophylactic strategy for peritoneal metastasis.** *Clin Cancer Res* 2003, **9**:678-685.

ORIGINAL ARTICLE

Shinichi Kinami · Takashi Fujimura · Eisuke Ojima
Sachio Fushida · Toshihiko Ojima · Hiroshi Funaki
Hideto Fujita · Hiroyuki Takamura · Itasu Ninomiya
Genichi Nishimura · Masato Kayahara · Tetsuo Ohta
Zen Yoh

PTD classification: proposal for a new classification of gastric cancer location based on physiological lymphatic flow

Received: August 17, 2007 / Accepted: December 17, 2007

Abstract

Background. We propose a new classification for the location of gastric cancer – the PTD classification (i.e., zones P, T, and D; see below), with the zones classified according to the physiological lymphatic flow.

Methods. Three hundred and thirty-six patients with T1 or small T2 gastric cancer who underwent sentinel node mapping at our hospital were enrolled. The relationship between the location of the gastric cancer and the physiological lymphatic flow derived from sentinel node mapping was investigated. Lymphatic basins were defined as lymphatic zones divided by the stream of stained lymphatic canals.

Results. One hundred and forty-six patients underwent standard gastrectomy with more than D2 dissection and the other 190 patients underwent function-preserving gastrectomy with the omission of lymph node dissection outside the lymphatic basin. In the former group, the progression pattern of lymph node metastasis was observed; nodal metastasis occurred in sentinel nodes first, and rarely extended outside the lymphatic basin. In the latter group, none of the patients have had a recurrence. The PTD classification we propose is as follows: the dividing line between the proximal region (zone P) and the transitional region (zone T) is the line that links the point of the watershed between the left gastroepiploic artery and right gastroepiploic artery, to the point that is the inflow point of the first descending branch of the left gastric artery; and the dividing line between zone T and the distal region (zone D) is an arc at a radius of 8 cm from the pylorus. There were no lym-

phatic basins within the right gastric artery area for tumors located in zone T.

Conclusion. The advantage of the PTD classification is that if the PTD classification were to be used as a guide for gastric resection procedures, preservation of the pylorus would become possible without diminishing the prognosis in patients with cT1N0 cancer located in zone T.

Key words Gastric cancer · Gastrectomy · Sentinel node · Pylorus-preserving gastrectomy

Introduction

In the *Japanese classification of gastric carcinoma*,¹ the location of gastric cancer is classified according to the three portions and cross-sectional circumference of the stomach. The three portions of the stomach are upper (U), middle (M), and lower (L), and they are delimited by dividing the lesser and greater curvature at two equidistant points, then joining these corresponding points. Therefore, this UML classification merely divides the stomach into three equal areas, and the areas are not defined according to anatomical specificity. However, in the *Japanese classification of gastric carcinoma*, the regional lymph nodes of the stomach are strictly classified into stations according to anatomical structure. Thus, the lymph node groups for dissection, classified according to the UML classification, are complicated, and in part, the classification is not clear for denoting the frequency of lymph node metastasis. Consequently, the UML classification is simpler, and remains useful regardless of the various stomach shapes encountered, though it is unsuitable as a guide for strict lymph node dissection and function-preserving limited gastrectomy for early gastric cancer. In order to perform function-preserving gastrectomy radically and lymph node dissection appropriately, a new classification for the location of gastric cancer, along the long axis of the stomach, based on the physiological lymphatic flow, seems to be needed to replace the UML classification.

Sentinel node biopsy for early gastric cancer is now widely used to predict nodal status and to enable the

S. Kinami (✉) · T. Fujimura · E. Ojima · S. Fushida · T. Ojima · H. Funaki · H. Fujita · H. Takamura · I. Ninomiya · G. Nishimura · M. Kayahara · T. Ohta
Department of Gastroenterologic Surgery, Kanazawa University Hospital, 13-1 Takara-machi, Kanazawa, Ishikawa 920-8641, Japan
Tel. +81-76-265-2362; Fax +81-76-234-4260
e-mail: kinami@surg2.m.kanazawa-u.ac.jp

Z. Yoh
Division of Pathology, Kanazawa University Hospital, Kanazawa, Japan

employment of function-preserving gastrectomy with the omission of the standard lymph node dissection.²⁻¹⁰ A sentinel node is defined as a lymph node that afferent lymphatics directly enter. We developed a method for sentinel node mapping named IELM (intraoperative endoscopic lymphatic mapping) and we have performed IELM for patients with early-stage gastric cancer.² IELM is a method for obtaining the vital dyeing of afferent lymphatics in early gastric cancer, and we have demonstrated the proper pattern of lymphatic flow in early gastric cancer using IELM.

In this article, we propose a new classification for the location of gastric cancer, based on the physiological lymphatic flow, derived from the proper pattern of afferent lymphatics in sentinel node mapping.

Patients and methods

Patients

Between February 1993 and March 2007, 348 patients with gastric cancer underwent sentinel node mapping at our hospital. The eligibility criteria for mapping were T1 cancers, or T2 cancers less than 5 cm in diameter, diagnosed by preoperative gastrofiberscopy. The methods used for mapping at our department were dye mapping, radioisotope (RI) mapping, and combination mapping. Our dye mapping was named the IELM technique,² and consisted of injecting a vital blue dye into the submucosa intraoperatively, using a gastrofiberscope. RI mapping is a technique in which a radio-labeled colloid is injected into the submucosa the day before surgery, using a gastrofiberscope. Combination mapping is a method of performing both dye mapping and RI mapping. We began with dye mapping in 1993, then adopted combination mapping from November 2000. Of the 348 patients in this series, 208 underwent dye mapping, 4 underwent RI mapping, and the remaining 136 underwent combination mapping. Detection of the sentinel nodes by dye mapping failed in 8 of these patients during the learning phase. During dye mapping and combination mapping, the dye immediately appeared on the gastric serosal surface and gradually stained the lymphatic basins and the sentinel nodes in the lymphatic basins, while it was not possible to detect the lymphatic basins by RI mapping only. Eight patients in whom we failed to detect the sentinel node and 4 patients who underwent RI mapping only were excluded from the study. Finally, 336 patients who underwent either dye mapping or combination mapping were enrolled. The characteristics and clinicopathological features of the patients are listed in Table 1. In this series, 146 patients underwent standard gastrectomy with lymph node dissection to the extent of D2 or D3, and the other 190 underwent function-preserving gastrectomy with limited lymph node dissection of D0 or D1. The surgical and histological findings were assessed in accordance with the guidelines of the Japanese Research Society for Gastric Cancer.¹¹ Before sentinel node mapping was performed, written informed consent was obtained from each patient; all procedures were con-

Table 1. Patients' characteristics

Median age, years (range)	62 (26-86)
Male:female	226:110
Depth of invasion	
T1	275
T2	51
T3	10
Tumor size, cm (range)	2.3 (0.2-9.8)
Pathological typing	
Differentiated type	193
Undifferentiated type	143
Surgical procedure	
Standard gastrectomy D2-3	146
Limited gastrectomy D0-1	190

ducted in accordance with the ethical standards of the institution's Committee on Human Experimentation.

Mapping technique

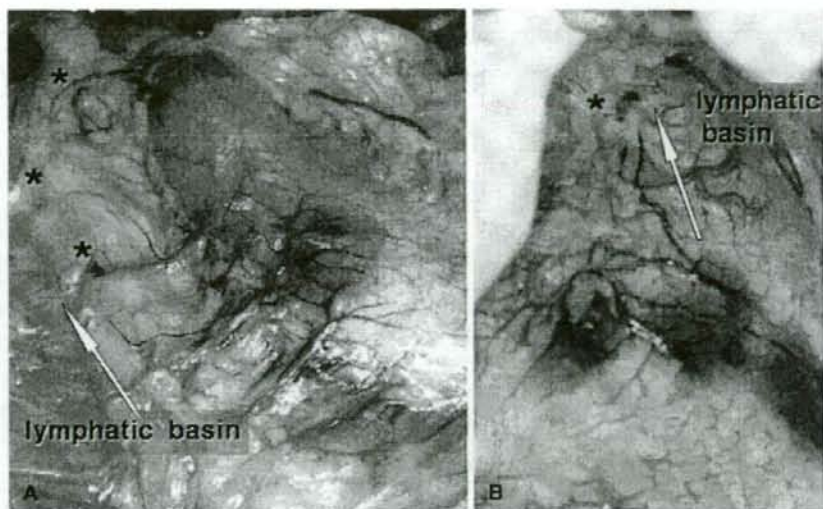
For dye mapping, we applied the IELM technique developed by Miwa et al.² First, at the time of preoperative gastrofiberscopy for close examination, a sniping biopsy was obtained from four points surrounding the tumor, 1 cm from the tumor edges, to confirm the cancer-free region, and four metallic marking clips were attached to the sampling sites. These clips served as a guide for tracer injection and for gastrectomy with a safe margin. After laparotomy, the stomach was mobilized from the lesser and greater omenta, and 0.2 ml of 2% patent blue dye (Wako Pure Chemical Industries, Osaka, Japan), or 0.5 ml 1% Lymphazulin (Ben Venue Laboratories, Bedford, OH, USA) was injected into the submucosal layer at each of the four points marked by the clips, using a gastrofiberscope inserted through the mouth. The dye immediately appeared as four blue spots on the serosal surface bordering the carcinoma, and gradually stained the lymphatic basins (Fig. 1).

Between November 2000 and March 2002, for RI mapping, we injected 4 mCi of 99m-Tc-phytate into the submucosal layer at the four points marked by the clips (as described above), using a gastrofiberscope, the day before surgery. In April 2002, we changed to 4 mCi of 99m-Tc-Tin colloid.

Sentinel node biopsy

Sentinel node biopsy was performed under close observation of the spread of staining to the lymph nodes and lymphatic canals during a 10- to 15-min period after injection. In dye mapping, the nodes stained blue during this period were regarded as sentinel node candidates. Blue nodes were defined as those nodes that were stained blue within 20 min after injection. Lymphatic basins were defined as the lymphatic zones divided by the stream of the stained lymphatic canals; the proximal border was the fatty tissue attached to the stomach wall, and the distal border was the front of the blue node most distal from the carcinoma 20 min after dye injection. The lymphatic basins were thought to be the primary lymphatic drainage area in each patient, and

Fig. 1A, B. Intraoperative pictures of sentinel node mapping for early gastric cancer. The dye gradually stained the lymphatic basins, the most important lymphatic area in which lymph node metastasis tends to appear first and in which lymph node dissection should be performed. **A** Mapping in a patient who had an early gastric cancer located in the greater curvature of the lower body. In this patient, the blue nodes belonged to the lymphatic basin within the lymphatic compartment of the right gastroepiploic artery area. **B** In another patient, the tumors were located in the lesser curvature of the middle body, and the blue node was in the lymphatic basin within the lymphatic compartment of the left gastric artery area. Asterisks, blue nodes



patients with gastric cancer often had two or three basins. The blue nodes were found at the end of stained lymphatic canals within the lymphatic basins. We adopted two procedures for sentinel node biopsy, the pick-up method and lymphatic basin dissection. The pick-up method, the same method as an ordinary lymph-node biopsy procedure, was performed from February 1993 to March 2000, during the early phase of our series when dye mapping alone was performed. Lymphatic basin dissection is a procedure for sentinel node biopsy in gastric cancer developed by Miwa et al.² This method consists of en-bloc dissection of the lymphatic basin and *ex vivo* examination of the sentinel nodes. The procedure was performed as follows: first, the principal gastric blood vessels at the site proximal to the blue node most distal from the carcinoma were ligated and divided. Next, the omental fatty tissue, including the lymphatic basins, was removed from the gastric wall by careful division of the individual vessels supplying the anterior and posterior gastric walls. Finally, the resected tissues were immediately dissected on a back table by a surgeon familiar with gastrointestinal anatomy, and blue nodes and "hot" nodes were detected. Hot nodes, also regarded as candidate sentinel nodes, were defined as nodes having radioactivity above 10 counts per 10 s, measured with a gamma-probe (Navigator GPS; Tyco Healthcare Japan, Tokyo, Japan). We adopted this technique beginning in April 2000. The blue nodes and hot nodes were sent immediately for histological examination as frozen sections.

Surgical procedures

At our department, the surgical procedures for sentinel node navigation of gastric cancer progressed in five phases. The early phase was a feasibility study of dye mapping, done between February 1993 and March 1996. At first, we adopted the pick-up method and then we performed stan-

dard D2 gastrectomy regardless of the findings on frozen section diagnosis. After the accuracy of sentinel node biopsy was confirmed, we shifted to the second phase, i.e., the clinical application of sentinel node navigation to decision-making regarding limited surgery in selected patients with mucosal cancer, starting in April 1996. The patients underwent sentinel node biopsy using the pick-up method, and function-preserving limited surgery associated with back-up lymph node dissection of the lymphatic basin was performed when the sentinel nodes were negative for metastasis on frozen section. If the sentinel nodes demonstrated metastasis on frozen section, the patient underwent the standard D2 gastrectomy. From April 2000, we changed the method of sentinel node biopsy from the pick-up method to lymphatic basin dissection, and expanded the eligibility for limited surgery, according to the sentinel node biopsy, to all patients with early-stage gastric cancer. The patients underwent lymphatic basin dissection after mapping, and function-preserving gastrectomy without additional lymphadenectomy was performed in patients whose samples were node-negative on frozen section. For patients whose samples were node-positive, standard D2 gastrectomy was performed. The fourth phase was the introduction of combination mapping, in November 2000. From April 2005, the fifth phase involved laparoscopic sentinel node navigation surgery, which consisted of combination mapping, lymphatic basin dissection, and function-preserving gastrectomy for patients whose samples were node-negative on frozen section. If the sample was node-positive on frozen section, the operation was converted to open surgery, and D2 gastrectomy was performed.

Pathological examination

Each blue or hot node was bisected at the maximal dimension, and a frozen section was obtained. The slice was

Table 2. Results of sentinel node biopsy for gastric cancer in patients who underwent standard gastrectomy with D2 or D3

Frozen section diagnosis of blue or hot nodes	Permanent diagnosis of all dissected nodes	
	Node-positive	Node-negative
Metastasis	44	0
No cancer cells	5	97

stained with hematoxylin and eosin. The remaining node tissues were processed separately in individual blocks for permanent sectioning. The non-blue nodes, harvested in back-up dissection, were cut into 2-mm sections parallel to the maximal dimension, and embedded in paraffin. Permanent slices were cut into 5- μ m sections and stained with hematoxylin and eosin.

The pathological diagnosis was carried out by the pathologists at the Division of Pathology, Kanazawa University Hospital.

Analysis of physiological lymphatic flow

In this study, we analyzed the relationship between the location of the gastric cancer and the physiological lymphatic flow, derived from sentinel node mapping. The relationship between the lymphatic flow and the proper pattern of lymph node metastasis was also investigated. The location of the tumor was expressed according to both the UML classification and the distance between the pylorus and the distal margin. From these findings, the outlines of a new longitudinal classification for the location of gastric cancer, based on the physiological lymphatic flow, were proposed.

Results

Results of sentinel node biopsy for gastric cancer in patients who underwent standard gastrectomy

Of the 146 patients who underwent standard gastrectomy with lymph node dissection, 49 demonstrated nodal metastasis on permanent histological examination. Forty-four of these 49 patients were intraoperatively diagnosed as having nodal metastasis by blue or hot node biopsy. Accordingly, the sensitivity of the sentinel node biopsy was 89.8% (44/49), the specificity was 100% (97/97), and the accuracy was 96.6% (141/146; Table 2). All 5 patients with false-negative findings had a large clinically apparent metastatic node, and it was easy to diagnose metastasis intraoperatively. The stained vessels ran from the tumor directly to the nodes in the lymphatic basins, but the metastatic node was not stained. Therefore, in this series, all patients who had pathological metastasis were diagnosed intraoperatively by sentinel node biopsy, except for those with macroscopic metastasis.

Table 3. Locations of metastatic lymph nodes in patients with metastasis

Blue node or hot node	Non-blue and cold node within lymphatic basin	Non-blue and cold node outside lymphatic basin	No. of patients
○	-	-	19
○	○	-	24
○	○	○	1
-	○	-	5*
-	○	○	0
-	-	○	0

○, presence of metastasis; -, no metastasis

*These five patients had clinically apparent metastasis

Nodal status in patients who underwent standard gastrectomy

In patients who underwent standard gastrectomy, regional lymph nodes could be divided into three categories: blue or hot nodes, non-blue and cold nodes within lymphatic basins, and nodes outside the lymphatic basins. All blue nodes and all hot nodes were within the lymphatic basin. Table 3 shows the locations of the metastatic nodes in the 49 node-positive patients. In 19 patients, metastatic nodes were confined to only blue or hot nodes; 24 patients showed metastasis in both blue/hot nodes and non-blue and cold nodes, though all metastatic nodes were within the lymphatic basin. In 5 patients demonstrating macroscopic metastasis, all metastatic nodes were also restricted to within the lymphatic basins. In this series, there was only 1 patient who had nodal metastasis beyond the lymphatic basin. This patient had advanced cancer with a large number of metastatic nodes: M, Gr, Φ 3 cm, small Borrmann 3 type, pT2 (SS), pN1 (10/44), H0, P0, CYX, M0, por2, scirrhous, INFy, ly2, v0. The lymphatic basin of this patient was near the right gastroepiploic artery. The numbers and stations of the metastatic nodes were: 6 number 4d nodes (lymph nodes along the right gastroepiploic artery) within the basin and 4 number 3 nodes (lymph nodes along the lesser curvature) outside the basin. There was no patient with metastasis outside the lymphatic basin only.

Nodal status and prognosis in patients who underwent function-preserving gastrectomy

One hundred and ninety patients underwent function-preserving gastrectomy with limited D0 or D1 lymph node dissection. They were diagnosed as node-negative intraoperatively by sentinel node biopsy, and underwent function-preserving gastrectomy, which consisted of a reduction in the excised area of stomach and omission of lymph node dissection outside the lymphatic basins. Therefore, all these patients underwent prophylactic back-up dissection of the lymphatic basins.

Two of these 190 patients were finally diagnosed with lymph node metastasis. One patient had one metastatic node that was stained blue, and the other patient had three

metastatic nodes, consisting of a non-blue and hot node and two non-blue and cold nodes within the lymphatic basin. These patients were proven to be node-positive by permanent section postoperatively, but failed to be diagnosed intraoperatively by frozen section. These patients were closely observed without further surgical treatment, such as followed gastrectomy or additional lymph node dissection, because they had received limited lymph node dissection of the lymphatic basin. To date, at follow-up periods of 9 years and 2 months in 1 patient and 3 years and 5 months in the other patient, neither has had a recurrence.

Of the 190 patients, 16 patients died of other cancers or other diseases, and the remaining 174 patients, including 2 who had metastasis, are alive without recurrence. The median follow-up period of these 174 patients has been 5.7 years to date.

Relationship between the lymphatic basin and the UML classification

As reported in our previous study,² the gastric lymphatic compartments were divided in the following five directions along the main arteries: left gastric artery area (*l*-GA), right gastric artery area (*r*-GA), right gastroepiploic artery area (*r*-GEA), left gastroepiploic artery area (*l*-GEA), and posterior gastric artery (*p*-GA) (Fig. 2). The relationship between the lymphatic compartments and lymph node stations was as follows: the *l*-GA consisted of stations 1, 7, and the left two-thirds of station 3 (component of station 3 along the left gastric artery); *r*-GA, stations 5, 8a, and the right one-third of station 3 (component of station 3 along the right gastric artery); *r*-GEA, station 4d and station 6; *l*-GEA, station 4sa and station 4sb; *p*-GA, station 11p. The lymphatic basins were found within these lymphatic compartments, and could be grouped in these five directions.

Table 4 presents the relationship between the location of the gastric carcinoma according to the UML classification and the appearance of the lymphatic basin classified by the direction of flow in the lymphatic compartments in our 336 patients. There were no lymphatic basins within the *r*-GA or *r*-GEA for tumors located in the U portion, and similarly, there were no lymphatic basins in the *l*-GEA or *p*-GA for tumors located in the L portion. It was recognized that the *l*-GA was the most important lymphatic compartment regardless of the location of cancer on the long axis. It was also proven that the afferent lymphatics of cancers located in the M portion flowed in various directions, except for *p*-

GA, though the frequency of *l*-GEA showed a low rate, of 5.6%.

Appropriate dividing line between the proximal area and the transitional area

In this series, a lymphatic basin within the *l*-GEA was observed in ten cancers located in the M portion. The locations of the tumors in these ten patients are shown in Fig. 3. All tumors were located in or attached to the greater curvature, and reached the left gastroepiploic artery. In contrast, in the two patients with cancers located in the MU portion, afferent flow to the *r*-GEA was demonstrated. Figure 4 shows the details of these two cancers. Both tumors were large in the long axis and reached the right gastroepiploic artery.

These findings suggested that, from the perspective of physiological lymphatic flow, the appropriate point on the greater curvature for dividing the proximal area from the transitional area corresponded to the watershed between

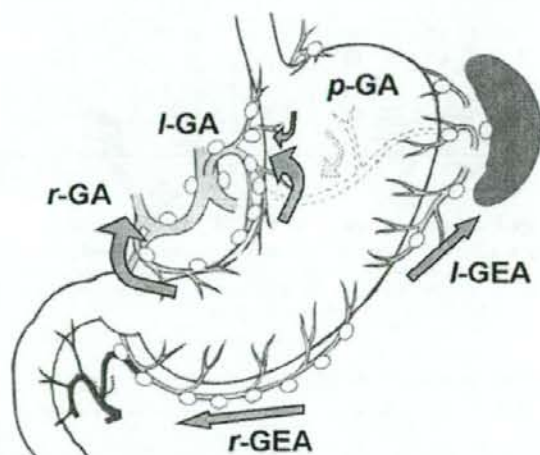


Fig. 2. Gastric lymphatic compartments, divided according to the following five directions along the main arteries. The lymphatic basins were found within these lymphatic compartments. The left gastric artery area (*l*-GA) consisted of lymph node stations 1 and 7, and the left two-thirds of station 3. The right gastric artery area (*r*-GA) consisted of stations 5 and 8a, and the right one-third of station 3. The right gastroepiploic artery area (*r*-GEA) consisted of stations 4d and 6. The left gastroepiploic artery area (*l*-GEA) consisted of stations 4sa and 4sb. The posterior gastric artery (*p*-GA) consisted of station 11p.

Table 4. Relationship between location of the tumor and the stained lymphatic compartments

Tumor location	No. of patients	<i>l</i> -GA	<i>r</i> -GA	<i>r</i> -GEA	<i>l</i> -GEA	<i>p</i> -GA
U	39	37 (94.9 %)	0	0	10 (25.6 %)	9 (23.1 %)
MU	6	5 (83.3 %)	0	2 (33.3 %)	4 (66.7 %)	0
M	178	160 (89.9 %)	34 (19.1 %)	116 (65.2 %)	10 (5.6 %)	0
LM	3	3 (100 %)	2 (66.7 %)	3 (100 %)	0	0
L	110	69 (62.7 %)	57 (51.8 %)	97 (88.2 %)	0	0

Fig. 3. Locations of tumors in the ten patients who had cancer located in the middle (M) portion of the stomach and the lymphatic basin within the *r*-GEA. All tumors reached the left gastroepiploic artery

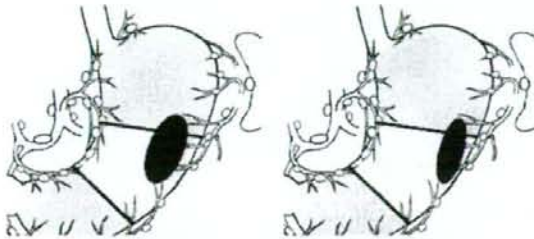
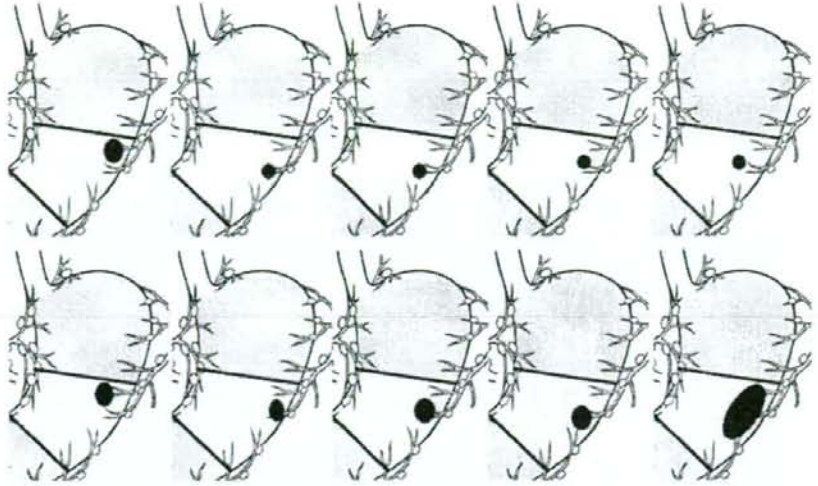


Fig. 4. Locations of the tumors in the two patients who had cancer located in the middle upper (MU) portion of the stomach and the lymphatic basin within the *r*-GEA. Both tumors were large in the long axis and reached the right gastroepiploic artery

the left gastroepiploic artery and the right gastroepiploic artery.

Appropriate dividing line between the transitional area and the distal area

The lymphatic basin within the *r*-GA was common to cancers located in the L portion. The frequency of the *r*-GA in L-portion cancers was 51.8%. However, the frequency of the *r*-GA in cancers located in the M portion was 19.1%, much lower than that for L-portion cancers. Figure 5 shows the relationship between the frequency of the lymphatic basin within the *r*-GA and the distance from the pylorus to the distal margin of the tumor. It was demonstrated that there was no patient with a lymphatic basin in the *r*-GA when the distance from the pylorus was longer than 8 cm, regardless of the cross-sectional circumference.

As the blue dye was injected at the sites marked by metallic clips 1 cm from the edge of the tumor, the appropriate line for dividing the transitional area from the distal area seemed to be an arc at a radius of 8 cm from the pylorus.

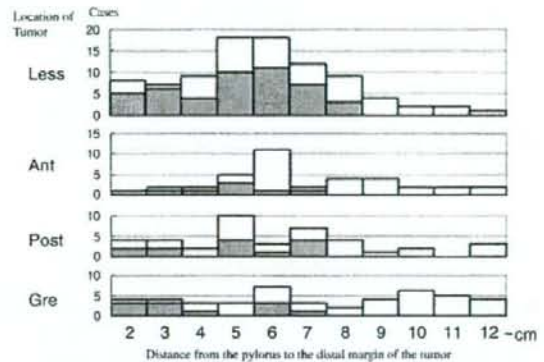


Fig. 5. Relationship between the frequency of the lymphatic basin within the *r*-GA and the distance from the pylorus to the distal margin of the tumor. *Hatched bars* represent patients with the lymphatic basin within the lymphatic compartment of the right gastric artery area. *White bars* represent patients without the lymphatic basin in the lymphatic compartment of the right gastric artery area. *Less*, lesser curvature; *Ant*, anterior wall; *Post*, posterior wall; *Gre*, greater curvature

The PTD classification: a proposal for a new longitudinal classification for the location of gastric cancer based on the physiological lymphatic flow

Based on our findings in this study, we propose a new classification for the location of gastric cancer, based on the physiological lymphatic flow demonstrated by vital dye findings for sentinel node biopsy. We named this new classification the "PTD" classification, based on zones "P", "T", and "D" described below. The PTD classification is a longitudinal classification (in contrast to the UML classification), in which the stomach is divided into three areas according to the afferent lymphatic system. The proximal region is named "zone P", the distal region is named "zone

Table 5. Grouping of regional lymph nodes for dissection according to proposed PTD classification

Grouping of lymph nodes			
	Group 1	Group 2	Group 3
P	<i>l</i> -GA, <i>l</i> -GEA, <i>p</i> -GA	No. 2, No. 8a, No. 9, No. 10, No. 11d, No. 19	<i>r</i> -GA, <i>r</i> -GEA, No. 16a2, b1
T	<i>l</i> -GA, <i>r</i> -GEA	No. 8a, No. 9, No. 11p, No. 14v	<i>r</i> -GA, <i>l</i> -GEA, No. 12a, No. 16a2, b1
D	<i>l</i> -GA, <i>r</i> -GA, <i>r</i> -GEA	No. 9, No. 11p, No. 12a, No. 14v	<i>l</i> -GEA, No. 16a2, b1

The *l*-GA, *r*-GA, *l*-GEA, *r*-GEA, and *p*-GA are shown in Fig. 2

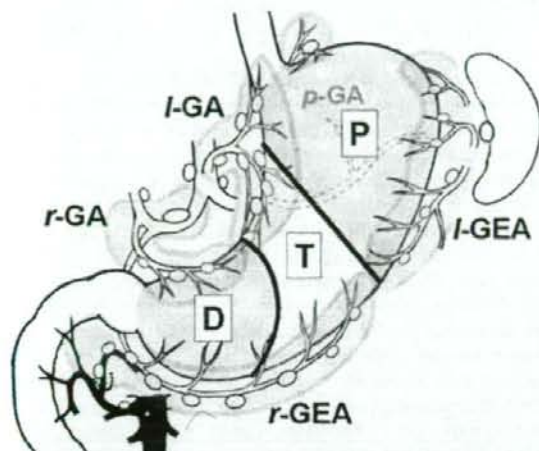


Fig. 6. Proposed PTD classification. The proximal region is named zone P (*P*), the distal region is named zone D (*D*), and the transitional region is named zone T (*T*). The dividing line between zones P and T is the line that links the point of the watershed between the left gastroepiploic artery and right gastroepiploic artery, to the point that is the inflow point of the first descending branch of the left gastric artery; and the dividing line between zones T and D is an arc at a radius of 8 cm from the pylorus

"D", and the transitional region is named "zone T". The dividing line between zones P and T is the line that links the point of the watershed between the left gastroepiploic artery and right gastroepiploic artery, to the point that is the inflow point of the first descending branch of the left gastric artery. The dividing line between zones T and D is an arc at a radius of 8 cm from the pylorus (Fig. 6).

The important lymphatic compartments, in which lymph node metastasis tends to appear first and which should undergo lymph node dissection, are different in each zone. For zone P, the important lymphatic compartments are the *l*-GA, *l*-GEA, and *p*-GA. Similarly, the important lymphatic compartments for zone T are the *l*-GA and *r*-GEA; and for zone D, the *l*-GA, *r*-GEA, and *r*-GA.

At resection of early gastric cancer diagnosed as cN0, the PTD classification would provide a guide for both the extent of lymph node dissection and the procedure for gastric resection. When the tumor is located in zone P, proximal gastrectomy and dissection of the lymphatic compartments of the *l*-GA, *l*-GEA, and *p*-GA is recommended. When the tumor is located in zone T, transverse gastrectomy (segmen-

Table 6. Recommended surgical procedures according to PTD classification

	sT1N0	Greater than sT2 or sN1
P	Proximal gastrectomy D1	Proximal gastrectomy D2
T	Transverse gastrectomy D1	Distal gastrectomy (2/3) D2
D	Distal gastrectomy (1/2) D1	Distal gastrectomy (1/2) D2

tal gastrectomy) and dissection of the lymphatic compartments of the *l*-GA and *r*-GEA is recommended. When the tumor is located in zone D, distal gastrectomy and dissection of the lymphatic compartments of the *l*-GA, *r*-GA, and *r*-GEA is recommended.

Table 5 shows a proposal for the grouping of lymph nodes for dissection, and Table 6 shows a proposal for recommended surgical procedures for resectable gastric cancer according to the PTD classification.

Discussion

The prognosis for survival of a patient with gastric cancer is greatly influenced by the presence and extent of regional lymph node metastasis.^{12,13} Lymph node metastases are often found even in patients with early gastric cancer. Therefore, lymph node dissection is thought to be important because nodal dissection appears to prevent recurrence and to improve cancer-specific survival in patients with early gastric cancer with nodal metastasis.¹² However, lymph node dissection results in wide-area resection of the stomach, because it eliminates some of the main arteries feeding the stomach. Thus, omission of lymph node dissection is necessary to preserve the stomach.

From a prognostic perspective in gastric cancer, the omission of lymph node dissection is problematic. At present, almost all mucosal cancers clinicopathologically suspected to be without metastasis can be resected using endoscopic submucosal dissection,¹⁴ while lymph node dissection is necessary for those patients with a possibility of having lymph node metastasis. Therefore, according to the gastric cancer treatment guidelines in Japan, modified gastrectomy A or modified gastrectomy B is recommended for stage IA or IB gastric cancer.¹⁵ Modified gastrectomy A or B is a less extensive resection than D2 standard gastrectomy; the extent of lymph node dissection includes D1 +

station 7 in modified A, and D1 + stations 7, 8a, and 9 in modified B. However, modified gastrectomy A or B also results in wide-area resection of the stomach because these procedures demand D1 at a minimum. Accordingly, the omission of lymph node dissection below D1 is necessary to preserve some main arteries and more stomach area as a reservoir. To accomplish this omission, reexamination of the D-number for gastric cancer is required.

In the Japanese *Classification of gastric carcinoma*,¹ the lymph node grouping for dissection is too complicated to comprehend. In contrast, the regional lymph nodes of the stomach are strictly classified into stations according to the anatomical structure, and the lymph node station is an excellent classification system for grasping the progression of lymph node metastasis and performing lymph node dissection. The lymph node grouping for dissection is based on the results of studies of lymphatic flow at various tumor sites, together with the observed survival associated with metastasis at each nodal station. The point at issue is that this system is based on studies using the UML classification, which merely divides the stomach into three equal areas, and these are not defined according to anatomical specificity. Based on our experience with IELM, we consider the UML classification to be a rough classification for small gastric cancer.²

Nodal metastasis occurs in a neat and sequential manner early in the development of gastric cancer. In our series, the sensitivity of sentinel node biopsy using IELM was 89.8%, specificity was 100%, and accuracy was 96.6% in the 146 patients who underwent standard gastrectomy with lymph node dissection. In all patients who had pathological metastasis, this could be detected by sentinel node biopsy. The progression pattern of lymph node metastasis was investigated; nodal metastasis occurred in blue or hot nodes first, spread to non-blue and cold nodes within the lymphatic basin next, and rarely extended outside the lymphatic basin. To date, among the 190 patients who were diagnosed as being node-negative intraoperatively on sentinel node biopsy and who underwent surgery with the omission of lymph node dissection outside the lymphatic basin, there has been no recurrence. These results indicate that the sentinel node concept is valid and that IELM accurately predicts nodal status in patients with early gastric cancer. It was interesting to note that the pattern of appearance of lymph node metastasis in the lymphatic basin followed the longitudinal location of the tumor. The lymphatic basin is regarded as the most important lymphatic area in which lymph node metastasis develops first and where lymph node dissection would be needed. Therefore, we propose a new longitudinal classification for the location of gastric cancer, based on the physiological lymphatic flow derived from IELM.

The PTD classification offers an improvement of the longitudinal classification to a more physiological and clinical version. This proposal is based on the experience of IELM, a type of vital dyeing of afferent lymphatics in early gastric cancer. One of the excellent points of the PTD classification is the simplification of the lymph node classification for dissection. Each zone has its own important

lymphatic compartments. The lymphatic compartment is a regulated area of the lymphatic basin; therefore, the important lymphatic compartments tend to develop lymph node metastasis first and should be classified as the group 1 nodal area. Based on our experience, a patient with early gastric cancer diagnosed as having cT1N0 preoperatively would be cured by gastrectomy with dissection of lymph nodes classified in our group 1 lymphatic compartments. The group 2 nodes in our PTD classification are nodes external to the lymphatic compartment and within group 2 of the ordinary classification, and they are nodes that should be dissected in patients with advanced gastric cancer or those with clinically obvious positive nodes.

Another excellent point of the PTD classification is that the classification can be used not only to document location but also as a guide for gastric resection procedures. The UML classification has limited utility for decisions regarding the resection procedure; for example, the appropriate procedures for a patient with early gastric cancer located in the M portion can be as diverse as distal partial gastrectomy, subtotal gastrectomy, pylorus-preserving gastrectomy, and total gastrectomy. In contrast, with the PTD classification, the surgical procedure can be easily decided on according to the location. In early gastric cancer, the recommended procedures are proximal gastrectomy for a patient with tumor located in zone P, transverse gastrectomy (segmental gastrectomy)^{16,17} for a tumor in zone T, and distal gastrectomy for a tumor in zone D. It is a unique point of the PTD classification that transverse gastrectomy is recommended as a regular and safe procedure for cT1N0 cancer located in zone T. Transverse gastrectomy is a type of function-preserving limited surgery that preserves the pylorus, a long antral cuff of more than 3 cm, and the right gastric artery.^{16,17} In a cT1N0 tumor located in zone T, the r-GA lymphatic compartment is outside the lymphatic basin, and so dissection of lymph node station 5 can be omitted and the right gastric artery can be preserved. Transverse gastrectomy has some resemblance to pylorus-preserving gastrectomy.¹⁸ There have been many reports estimating gastric function after pylorus-preserving gastrectomy.¹⁸⁻²³ However, the indications for pylorus-preserving gastrectomy for gastric cancer in these studies were not consistent.¹⁸⁻²⁰ The reason for this discordance seemed to be the necessity of omitting station 5 nodal dissection, and the difficulty in the decision of a lymph node station 5 node-negative case according to the UML classification. In this respect, the PTD classification would provide a new basis for the safe indication of a pylorus-preserving procedure, based on the vital dyeing of afferent lymphatics. Regarding patients with advanced cancer or those who are clinically node-positive, the recommended surgical procedure would change from transverse gastrectomy to distal partial gastrectomy for a tumor located in zone T, because of the need for nodal dissection up to group 2 nodes. However, the area of gastric resection would not change for zone P or zone D cancer. When more than one portion is involved, the area of resection is expanded to cover the merged areas and the extent of nodal dissection is also expanded to the merged group 2 nodes. Therefore, in a patient with advanced cancer

located in zones P and T, or in zones P to D, total gastrectomy is recommended.

A limitation of the PTD classification is the difficulty in determining the tumor location preoperatively. This is a serious issue, because the surgical procedure cannot be established preoperatively unless the location according to the PTD classification is determined. However, it is also difficult to determine the location when using the UML classification. Therefore, the PTD classification is not inferior to the UML classification on this issue. The difficulty in determination occurs for tumors located in the border of each area. Because the line dividing zones T and D is an arc at a radius of 8 cm from the pylorus, measurement of the distance between the pylorus and the anal edge of the tumor is necessary. However, it is not difficult to measure this distance on X-ray examination of the upper gastrointestinal tract. It is also useful that the length of the lesser curvature of the stomach in Japanese patients has been reported to be about 15 cm,²⁷ and the arc dividing zones T and D can be determined as an arc with a radius of half the length of the lesser curvature. Determination of the line dividing zones P and T is more difficult because there is no precise indicator of this line preoperatively. However, the PTD classification is designed for application to surgical treatment; thus, the location of a tumor near the border of zones P and T can be decided intraoperatively, and this issue would not be clinically significant.

Clinically, the PTD classification, as a guide for gastric resection procedures, has the obvious advantage of allowing the preservation of pyloric function for patients with cT1N0 gastric cancer located in the zone T area. Pylorus-preserving procedures are considered to be superior to distal gastrectomy from several points of view: prevention of dumping syndrome, prevention of gallstone formation after gastrectomy, prevention of duodenogastric reflux and duodenoesophageal reflux after gastrectomy, and reduction of reflux gastritis in the remnant stomach.¹⁹⁻²⁶ In our series, 291 patients had gastric cancer located in the M or L portion. Ten of these patients were classified as having cancer located in zone P, and 168 were classified as having cancer located in zone D; thus, the number of patients with cancer located in zone T was 113. Accordingly, almost 40% of patients having cT1N0 gastric cancer located in the M or L portion would reap the benefit of preservation of the pylorus if the PTD classification were to be used as a guide for gastric resection procedures.

It is also an advantage for patients with cT1N0 gastric cancer located in the zone T area that the pylorus can be preserved without diminishing the prognosis. Based on our experience with IELM, afferent lymphatics to the r-GA were common in patients with L-portion cancer and occasionally in those with M-portion cancer. Therefore, according to our estimates, performing a pylorus-preserving procedure would be a risk for 52% of L-portion cancers and 19% of M-portion cancers. In contrast, the estimated risk of nodal metastasis in the r-GA compartment would be negligible in patients with cT1N0 gastric cancer located in zone T. Currently, the diagnosis of nodal status in early gastric cancer has become possible using sentinel node biopsy.

There have been many reports, including ours, in which the sentinel node concept was shown to be valid in patients with early gastric cancer. The clinical application of sentinel node biopsy for employing function-preserving gastrectomy, with the omission of standard lymph node dissection, has been carried out at various specialized centers, including our hospital.²⁻¹⁰ Nevertheless, there are some limitations in the use of sentinel node biopsy, such as the existence of a learning curve, the high cost, the need for radioisotope equipment, the need for additional staff for endoscopic injection and sentinel node identification on the back table, and the extra load on laboratory technicians and pathologists. Therefore, the performance of function-preserving limited gastrectomy under sentinel node navigation would be limited to high-volume centers with well-trained surgeons. In contrast, with the adoption of the PTD classification, the performance of function-preserving limited gastrectomy for patients with cT1N0 cancer located in zone T could be possible at ordinary community hospitals without radioisotope equipment and a pathologist for frozen section diagnosis.

Acknowledgments The authors are most grateful to Dr. Koichi Miwa, the ex-Professor of the Department of Gastroenterologic Surgery, Kanazawa University, for his contribution to this study.

References

1. Japanese Gastric Cancer Association (1998) Japanese classification of gastric carcinoma, 2nd English edn. *Gastric Cancer* 1:10-24
2. Miwa K, Kinami S, Taniguchi K, et al. (2003) Mapping sentinel nodes in patients with early-stage gastric carcinoma. *Br J Surg* 90:178-182
3. Hiratsuka M, Miyashiro I, Ishikawa O, et al. (2001) Application of sentinel node biopsy to gastric cancer surgery. *Surgery* 129: 335-340
4. Kitagawa Y, Fujii H, Mukai M, et al. (2002) Radio-guided sentinel node detection for gastric cancer. *Br J Surg* 89:604-608
5. Ishizaki M, Kurita A, Kubo Y, et al. (2006) Evaluation of sentinel node identification with isosulfan blue in gastric cancer. *Eur J Surg Oncol* 32:191-196
6. Ichikura T, Chochi K, Sugawara H, et al. (2006) Individualized surgery for early gastric cancer guided by sentinel node biopsy. *Surgery* 139:501-507
7. Tonouchi H, Mohri Y, Tanaka K, et al. (2005) Laparoscopic lymphatic mapping and sentinel node biopsies for early-stage gastric cancer: the cause of false negativity. *World J Surg* 29:418-421
8. Kim MC, Kim HH, Jung GJ, et al. (2004) Lymphatic mapping and sentinel node biopsy using 99 mTc tin colloid in gastric cancer. *Ann Surg* 239:383-387
9. Song X, Wang L, Chen W, et al. (2004) Lymphatic mapping and sentinel node biopsy in gastric cancer. *Am J Surg* 187:270-273
10. Gretschesel S, Bembenek A, Ulmer Ch, et al. (2005) Prediction of gastric cancer lymph node status by sentinel lymph node biopsy and the Maruyama computer model. *Eur J Surg Oncol* 31:393-400
11. Nakajima T. (2002) Gastric cancer treatment guidelines in Japan. *Gastric Cancer* 5:1-5
12. Miwa K, Miyazaki I, Sahara H, et al. (1995) Rationale for extensive lymphadenectomy in early gastric carcinoma. *Br J Cancer* 72: 1518-1524
13. Yokota T, Ishiyama S, Saito T, et al. (2004) Lymph node metastasis as a significant prognostic factor in gastric cancer: a multiple logistic regression analysis. *Scand J Gastroenterol* 39:380-384
14. Gotoda T, Yamamoto H, Soetikno RM (2006) Endoscopic submucosal dissection of early gastric cancer. *J Gastroenterol* 41:929-942

15. Nakajima T (2002) Gastric cancer treatment guidelines in Japan. *Gastric Cancer* 5:1-5
16. Ohwada S, Nakamura S, Ogawa T, et al. (1999) Segmental gastrectomy for early cancer in the mid-stomach. *Hepatogastroenterology* 46:1229-1233
17. Furukawa H, Hiratsuka M, Imaoka S, et al. (1999) Phase II study of limited surgery for early gastric cancer: segmental gastric resection. *Ann Surg Oncol* 6:166-170
18. Maki T, Shiratori T, Hatafuku T, et al. (1967) Pylorus-preserving gastrectomy as an improved operation for gastric ulcer. *Surgery* 61:838-845
19. Isozaki H, Okajima K, Momura E, et al. (1996) Postoperative evaluation of pylorus-preserving gastrectomy for early gastric cancer. *Br J Surg* 83:266-269
20. Nakane Y, Michiura T, Inoue K, et al. (2002) Length of the antral segment in pylorus-preserving gastrectomy. *Br J Surg* 89:220-224
21. Nishikawa K, Kawahara H, Yumiba T, et al. (2002) Functional characteristics of the pylorus in patients undergoing pylorus-preserving gastrectomy for early gastric cancer. *Surgery* 131:613-624
22. Urushihara T, Sumimoto K, Shimokado K, et al. (2004) Gastric motility after laparoscopically assisted distal gastrectomy, with or without preservation of the pylorus, for early gastric cancer, as assessed by digital dynamic X-ray imaging. *Surg Endosc* 18: 964-968
23. Michiura T, Nakane Y, Kanbara T, et al. (2006) Assessment of the preserved function of the remnant stomach in pylorus-preserving gastrectomy by gastric emptying scintigraphy. *World J Surg* 30:1277-1283
24. Kodama M, Koyama K (1991) Indications for pylorus preserving gastrectomy for early gastric cancer located in the middle third of the stomach. *World J Surg* 15:628-633
25. Kodera Y, Yamamura Y, Kanemitsu Y, et al. (2001) Lymph node metastasis in cancer of the middle-third stomach: criteria for treatment with a pylorus-preserving gastrectomy. *Surg Today* 31:196-203
26. Morii Y, Arita T, Shimoda K, et al. (2002) Indications for pylorus-preserving gastrectomy for gastric cancer based on lymph node metastasis. *Hepatogastroenterology* 49:1477-1480
27. Matsuura Y (1961) The study of shape of stomach using X-ray examination of the upper gastrointestinal tract (in Japanese). *Kanazawa I-Rikagaku Gousyo* 63:107-155

All Databases PubMed Nucleotide Protein Genome Structure OMIM PMC Jour

Search PubMed

for

Go

Clear

Limits Preview/Index History Clipboard Details

Display AbstractPlus

Show 20

Sort By

Send to

All: 1 Review: 1

 1: J Gastrointest Cancer, 2007;38(2-4):78-82. Epub 2008 Nov 25.**Cyclooxygenase-2 (COX-2) in carcinogenesis and selective COX-2 inhibitors for chemoprevention in gastrointestinal cancers.****Fujimura T, Ohta T, Oyama K, Miyashita T, Miwa K.**

Kanazawa University Hospital, Kanazawa, Japan. tphuji@surg2.m.kanazawa-u.ac.jp

INTRODUCTION: Nonsteroidal anti-inflammatory drugs (NSAIDs) have been reported to have a property to inhibit tumor development in some cancers while it shows various side effects such as gastrointestinal bleeding and renal disorder. Selective cyclooxygenase (COX)-2 inhibitors (coxibs) were originally developed as one of anti-inflammatory drugs to avoid side effect of NSAIDs. Fortunately, the coxibs was also proved to have an inhibiting effect on tumorigenesis by many experimental studies using cell lines and animal models like NSAIDs. **DISCUSSION:** Since a randomized study for polyp chemoprevention by celecoxib in familial adenomatous polyposis (FAP) patients demonstrated a significant reduction in the number of colorectal polyps, the clinical use of celecoxib was approved for FAP patients. Three large trials using celecoxib (the Adenoma Prevention with Celebrex and the Prevention of Spontaneous Adenomatous Polyyps) or rofecoxib (the Adenomatous Polyp Prevention on Vioxx) for the recurrence of colorectal polyps in patients with a history of colorectal adenoma polypectomized confirmed chemopreventive effects on colorectal adenoma but two of three trials alerted us a hazard of cardiovascular (CV) events. Thereafter, some coxibs were withdrawn from the market because they showed to increase risk of serious CV events including heart attacks and strokes. But recent reports concluded that a merit of the reduction in gastrointestinal events by coxibs exceeded a demerit of the increase in serious CV events. In this review, a role of COX-2 in carcinogenesis of gastrointestinal tract and a future of coxibs for chemoprevention are discussed.

PMID: 19031117 [PubMed - indexed for MEDLINE]

Related Articles*Review* Role of cyclooxygenase-2 in carcinogenesis of gastrointestinal cancer: review and report of pers*Review* Use of NSAIDs for chemoprevention of colorectal cancer.*Review* Anti-inflammatory drugs and cancer*Review* Chemoprevention of colorectal cancer: new target needed?*Review* NSAIDs and cancer: a review [Cur

» See

Patient Drug Informatic

Celecoxib (Celebrex®) relieve pain, tenderness caused by osteoarthritis, rheumatoid arthritis, breakdown of the lining of the joint, and arthritis (arthritis caused

Source: AHFS Con

Recent Activity

Cyclooxygenase-2 (COX-2) and selective COX-2 inhibitors for chemoprevention...

fujimura t and miwa k

PTD classification: PTD classification of gastrointestinal cancer on ...

Detection of sentinel lymph node micrometastases in colorectal cancer...

縮小手術(機能温存根治手術)

藤村 隆 木南 伸一 伏田 幸夫 萱原 正都 太田 哲生

消化器外科 2008年4月臨時増刊号 第31巻第5号 通巻第383号

へるす出版

III 胃癌の治療

胃癌に対する手術

縮小手術（機能温存根治手術）

Limited surgery (function-preserving curative gastrectomy) for gastric cancer

藤村 隆
Takashi Fujimura木南 伸一
Shinichi Kinami伏田 幸夫
Sachio Fushida萱原 正都
Masato Kayahara太田 哲生
Tetsuo Ohta

●金沢大学大学院医学系研究科がん局所制御学

key words 機能温存根治手術, センチネルリンパ節理論, リンパ流域

はじめに

早期胃癌においては、外科手術により治療が期待できるようになった現在、術後の quality of life (QOL) をいかに改善できるかが問題となっている。D2を伴う定型手術を受けた患者のうち、60%以上の人が胃切除術後症候群に悩まされるのに対して、分化型の粘膜内癌患者の多くは endoscopic submucosal resection (ESD) により治療されるようになっており、術後の障害はほとんど残らない。

すなわち、この2つの術式の間には術後の QOL の面でかなりの gap があり、この間を埋めるべく、縮小手術の必要性が叫ばれているのである。『胃癌治療ガイドライン』では、縮小手術として、リンパ節郭清に関して D1+a もしくは D1+β などが提案されているが⁶⁾、事実上、郭清の範囲は定型手術 (D2) と大きな差はなく、切除範囲も広範囲胃切除術に準ずるものである。このため D1+a/β が術後 QOL の改善に役立っているかどうかは不明である。

当科ではセンチネルリンパ節 (sentinel node : SN) 理論を応用して、各種の縮小手術を行ってきたので²³⁾、その考え方や方法について概説する。

必要条件

さて合理的な縮小手術が一般診療に受け入れられるためには、以下の3つの条件が必要である。

1. 根治性の確保 (Curability)

早期胃癌は外科手術により治療させるべき疾患であ

るから、局所やリンパ節再発を絶対にきたしてはいけない。その意味では縮小手術というよりはむしろ機能温存根治手術もしくは機能温存治療手術というべきであると、われわれは考えている。

根治性を維持しつつリンパ節郭清を省略するためには、術中にリンパ節転移があるかどうか、また、あるとすればどのリンパ節に転移があるのかを診断する必要がある。ガイドラインにおける D1+a/β は郭清を縮小するための目安で、その根拠は多くのデータから得られた貴重なものではあるが、個々の症例に関して情報を提供するものではないということ認識しておくてはならない。

現在、根治性の確保を可能にすると考えられているのが、乳癌や黒色腫ではすでに臨床応用されている SN 理論である。

2. 普遍性 (Feasibility)

リンパ節郭清の縮小が可能かどうかは、SN 理論が成り立つことが前提となる。これまで国内での単施設から十分有望な成績が報告されているが^{6)~7)}、より確実なエビデンスを得るためには、現在施行されている2つの多施設共同研究の結果を待たなければならない。ただし SN 理論が成立したとしても radioisotope (RI) tracer が必須となった場合には、縮小手術が全国どこでもできる手術とはならないかもしれない。そのような場合、新しい tracer の開発が必要となろう。

一方、胃切除術の範囲に関する縮小手術、すなわち局所切除術や分節切除術などの手術手技自体は、胃癌の手術を多く手がけている施設では問題なく行えると思われる。

図1 Intraoperative endoscopic lymphatic mapping (IELM)

術中胃内視鏡を用いて2% patent blueを、術前に癌が陰性であることを確認して marking されている腫瘍周囲4カ所に、0.2ml ずつ粘膜下注入することにより、リンパ系を描出する

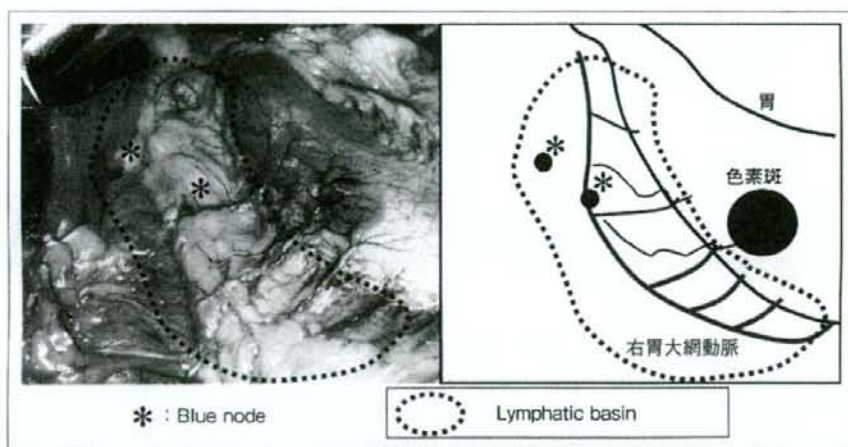
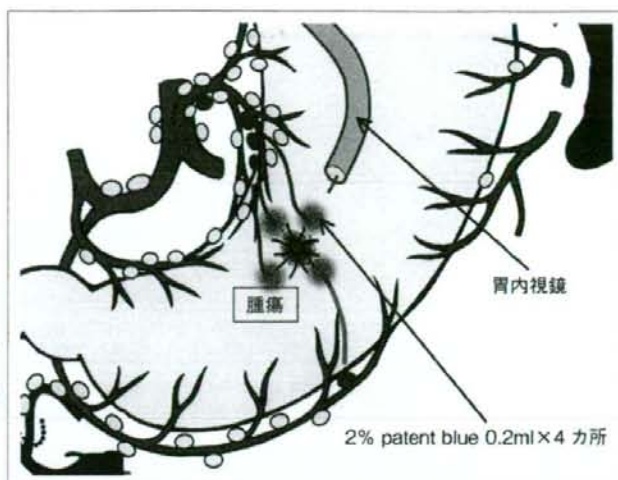


図2 Blue node と lymphatic basin (リンパ流域) —intraoperative endoscopic lymphatic mapping (IELM) における—

色素注入直後に漿膜側に色素斑が出現し、経時的にリンパ管、リンパ節が青く染色される。染色されたリンパ節を blue node (青染リンパ節)、染色されるリンパ節、リンパ管を含む領域を lymphatic basin (リンパ流域) と定義している

3. メリットのあること (Advantage)

縮小手術における最終的な目的は、患者の術後 QOL の改善である。現在までもいくつかの施設から縮小手術の有用性が報告されているが¹⁰⁾、われわれの検討でも機能温存手術を施行した症例のほうが、食事の摂取量や、体重の維持に関して定型手術を行った症例より良好な成績を示している³⁾。とくに、分節切除術では幽門側胃切除術 (Billroth I 法再建) に比較して、残胃内への胆汁の逆流が少なく、内視鏡的胃炎 (粘膜の発赤) が低率であること、ダンピング症状が少ないことなどが判明している¹⁰⁾。

センチネルリンパ節理論と リンパ流域郭清術

乳癌の領域ではすでに SN 理論が応用され、SN に転移がなければ郭清が省略されている。一方、胃癌に関しては、われわれはこれまでの多数例の経験から、「郭清を省略すると転移リンパ節を残存させる可能性が高い、しかしリンパ流域 (lymphatic basin) を郭清すれば根治性は担保される」と考えており、その根拠をここで説明する。

当科では、1993年に intraoperative endoscopic

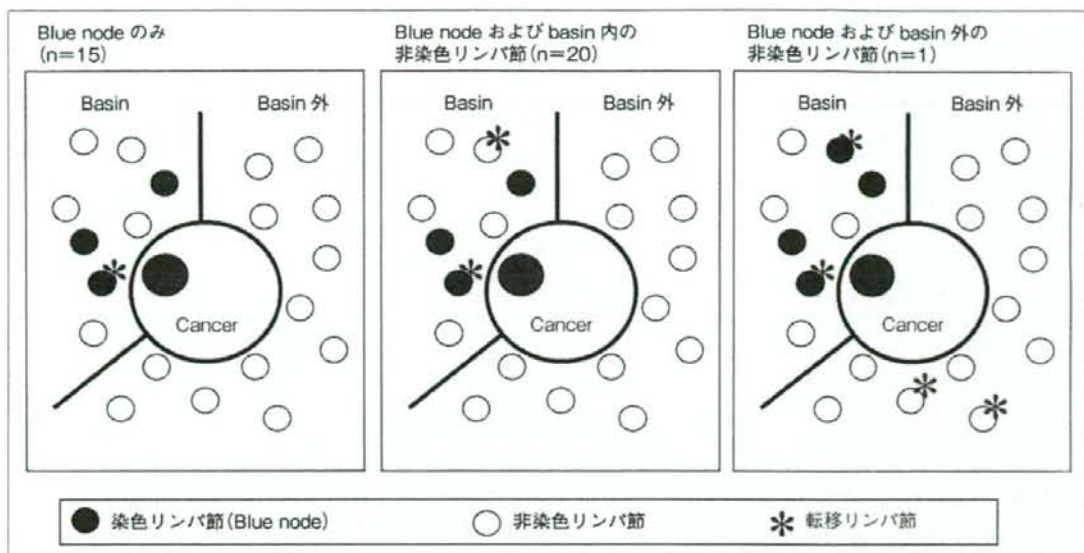


図3 リンパ節転移症例の内訳 (n=36, 肉眼転移を除く)

リンパ節転移はまずSNであるblue nodeに起こり、続いてblue nodeを含むリンパ流域内の他の非染色リンパ節へ広がり、さらに進展するとリンパ流域外の他の非染色リンパ節にまで達する。しかし中央のパネルの症例の場合、術中にblue node そのものあるいは迅速病理でblue nodeにおける転移を見落とした場合、非染色リンパ節における転移が体内に残ってしまうという問題が生じるため、リンパ流域ごと切除する(リンパ流域郭清術=lymphatic basin dissection) ほうが安全である

lymphatic mapping (IELM) と称する色素法によるSNマッピングを開発した¹⁴⁾。IELMは術中内視鏡下に青色色素である2% patent blueを、術前に癌が陰性であることを確認してclippingされている腫瘍周囲4カ所に0.2mlずつ粘膜下注入するものである(図1)。そしてD2の定型手術を行った139例を対象に、IELMにより青く染色される青染リンパ節(blue node)と、郭清後の術後病理検査による全リンパ節における転移診断能を比較した。なお当科ではIELMにより染色されるリンパ節、リンパ管を含む領域をリンパ流域と定義しており、あわせて検討した(図2)。IELMは132例(95%)に成功し、1例あたりのblue node個数の中央値は6個であった。感度88%(36/41)、特異度100%(91/91)、正診率96%(127/132)であった。5例が偽陰性であったが、いずれも肉眼的転移例で術中に容易に判定されるものであり、少なくとも肉眼的リンパ節転移のない症例ではSN理論の成立することが証明された。肉眼的転移例を除く36例の具体的な転移状況を見てみると(図3)、blue nodeのみへの転移が15例、blue nodeを含むリンパ流域内の他の非染色リンパ節への転移が20例と多く認められ、blue nodeとリンパ流域外の他の非染色リンパ節への転移は1例のみであった。最後の1例は

深達度ssでblue nodeに6個、リンパ流域外の他の非染色リンパ節に4個、リンパ節転移を有する進行胃癌であった。

これらのことより、リンパ節転移はまずSNであるblue nodeに起こり、続いてblue nodeを含むリンパ流域内の他の非染色リンパ節へ広がり、さらに進展するとリンパ流域外の他の非染色リンパ節にまで達するものと考えられる。以上から早期胃癌においては、SN理論は成立すると考えられる。しかし、現時点では、blue nodeの見落とし、術中迅速病理の診断率、微小転移の問題などから、blue nodeのみを取り出して術中診断で転移がなければリンパ節郭清を終了するという術式は危険である。なぜなら、前述のごとくblue nodeに転移のあった症例では、半数はblue nodeのみの転移であるが、残り半数はblue node以外にも転移があるため、術中にblue nodeにおける転移を見落とした場合、後者の症例(図3の中央のパネル)ではリンパ流域内の非染色リンパ節における転移が体内に残ってしまうという問題が生じるためである。しかし早期胃癌における転移リンパ節は、われわれの提唱するリンパ流域内に収まっているため、流域ごとに切除する方法(リンパ流域郭清術=lymphatic basin dissection)であれば、これらの問題は解決すると考

表1 Lymphatic basin dissection に基づいた縮小手術 (機能温存根治手術)

占居部位	流域 (basin)		術式
	数	部位	
M, L	1	右胃大網動脈	胃局所切除術
U, M	2	左胃動脈 後胃動脈	噴門側胃切除術
M, L	2	左胃動脈 右胃大網動脈	胃横断切除術
L	2	右胃動脈 右胃大網動脈	小範囲幽門側 胃切除術

えられる。

縮小手術の手順

まずSN マッピングとリンパ流域郭清術を行い、リンパ節郭清の縮小が可能な症例かどうかを判定し、その後温存できる動脈 (リンパ流域) を確認して、機能を維持できるように胃を切除する。

1. リンパ節郭清の縮小

方法は、まず術前日に^{99m}Tc フチン酸、または^{99m}Tc スズコロイドを、放射線管理区域内で内視鏡下にIELMと同様の手技で腫瘍周囲4カ所に粘膜下に注入する。RI tracerを使用するのはRIが長時間にわたり滞留するため、腹腔鏡下手術に応用可能なためである。次に、術当日は術中にIELMの手技に従い、2% patent blue または1% lymphazurin を、それぞれ0.2ml または0.5ml ずつ粘膜下注入する。リンパ流域とblue nodeの判定はIELM施行後15~20分後までに行い、ただちにリンパ流域郭清術を施行する。その後、back tableでblue nodeとガンマプローブを用いてRI陽性のhot nodeを取り出し、これをSNとして術中迅速病理組織検査に提出する。転移が陰性の場合、上述のように染色されるリンパ流域の数と腫瘍の位置に応じて各種の機能温存根治手術を行うが、転移が陽性であった場合には定型手術を行う。

2. 主幹動脈の温存

胃の切除範囲は温存される動脈の数によって決定される。われわれの検討では、胃のリンパ流域は5つ (左・右胃動脈、左・右胃大網動脈、後胃動脈流域) 認められる。術中迅速病理診断によりSNに転移がな

いと診断された場合は、郭清はそれ以上必要ではないと考えている。すなわちリンパ流域郭清術により切除された流域以外のリンパ流域は、その主幹動脈とともに温存できることになる。例えばリンパ流域が右胃大網動脈の1流域のみであれば胃局所切除術が適応となるが、左・右胃動脈、右胃大網動脈の3流域となった場合は、幽門側胃切除術を行わざるを得ない。

3. 胃切除範囲の縮小

ESDと同じように考えると、腫瘍の周囲からある十分な長さのマージンさえ確保できれば、胃の切除範囲は十分であることになる。この考えに従えば、胃切除の際もマージンを確保して全周性に摘出できればよいことになるが、もちろん胃壁内のリンパ流の問題、切除する部位によっては切除が困難であったり、再建後の胃の変形が強く、かえって術後障害が強くなったりする可能性の問題もあり、常にその領域さえ切除すればよいという問題ではない。最低限切除すべき胃範囲を決定し、その部分を含むように切除胃をデザインして残胃をトリミングすることにより、術後機能が維持できるような再建法を工夫するように心がけることが重要である。

主な縮小手術を下記に示すが、より具体的な手技などについては、他の論文を参照していただきたい^{12)~14)}。

1) 胃局所切除術

リンパ流域が1つであれば、胃局所切除術が行える。もっとも典型的な例はM, L (M寄りの) 領域の大彎の早期胃癌で、流域が右胃大網動脈流域の場合である。以前はMの小彎側で、流域が左胃動脈流域の場合も胃局所切除術を施行していたが、胃がV字型に変形してQOLが不良となることが判明したため、現在は

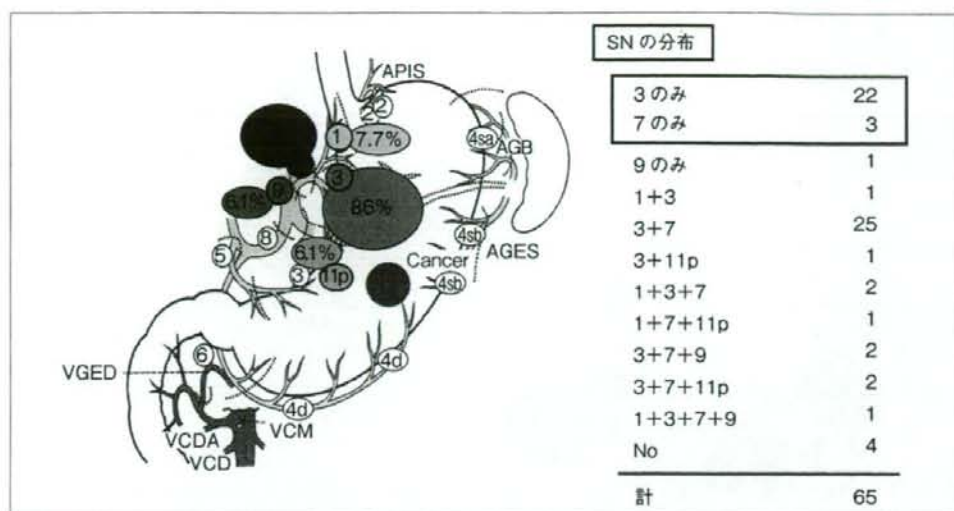


図4 左胃動脈流域におけるSNの分布 (M領域癌, n=65)

3番リンパ節のみならず7番リンパ節も、単独でSNになることがあり、7番リンパ節は「機能的第1群リンパ節」と考えられる

行っていない。

2) 噴門側胃切除術, 胃横断切除術, 小範囲幽門側胃切除術

これらの3つの術式は、その腫瘍のリンパ流域が小彎と大彎の両側にそれぞれ1つずつある場合と考えられ、腫瘍が上部であれば噴門側胃切除術、中部であれば胃横断切除術、下部であれば小範囲幽門側胃切除術になる。具体的な腫瘍の占居部位とリンパ流域に関しては表1にまとめて表示した。

なお術中リンパ節生検で転移が陽性であった場合はもちろんであるが、リンパ流域が3つのときや、大・小彎の同側に2つあるような場合(左右の胃動脈流域、左右の胃大網動脈流域など)は、定型手術(D2)を施行するようにしている。

問題点

患者の術後QOLの改善を目的に行われる縮小手術であるが、考慮しなければいけない問題がいくつかある。

1. 治療度

われわれの提唱する縮小手術において、リンパ節郭清範囲は「胃癌取扱い規約」¹⁹⁾上D0となってしまうことがしばしばである。このため縮小手術は根治度Bになってしまうわけであるが、現在までのわれわれの

成績ではリンパ節転移再発症例はなく、治療切除になっていると思われる。

われわれは多くのSNマッピングを施行してきたが、7番リンパ節や8aリンパ節が単独でSNになることを経験してきた。これはリンパ管がたまたま長く最初に流入するリンパ節がいわゆる2群リンパ節の位置にあったとも考えられ、aberrant drainageのひとつと思われる²⁰⁾。もしこのようなリンパ節に転移が起こった場合、これまでは跳躍転移(skip metastasis)といわれてきたのであるが、SN理論から考えると問題ないことであるかもしれない。われわれは、このようにある領域の胃癌においてSNになりうる一群のリンパ節を「機能的1群リンパ節」と考えており、おおむね、それはリンパ流域に一致するであろうと思われる。

7番リンパ節を例にとりて説明する。図4はM領域胃癌症例における左胃動脈流域のSNの分布を示している。各リンパ節がSNになる確率は3番が86%、7番が55%に対して、1番は7.7%と低率であった。さらに単独でSNになりうるのは、3番(34%)と7番(5%)であり、1番単独例はみられなかった。一方、図5にはM領域胃癌症例における右胃大網動脈流域のSNの分布を示すが、各リンパ節がSNになる確率は4d番が76%、6番が26%であった。単独でSNになりうるのは、4d番(40%)と6番(5%)であった。規約上M領域胃癌では1、3、4d、6番リンパ節が第1群、7番リンパ節が第2群と分類さ

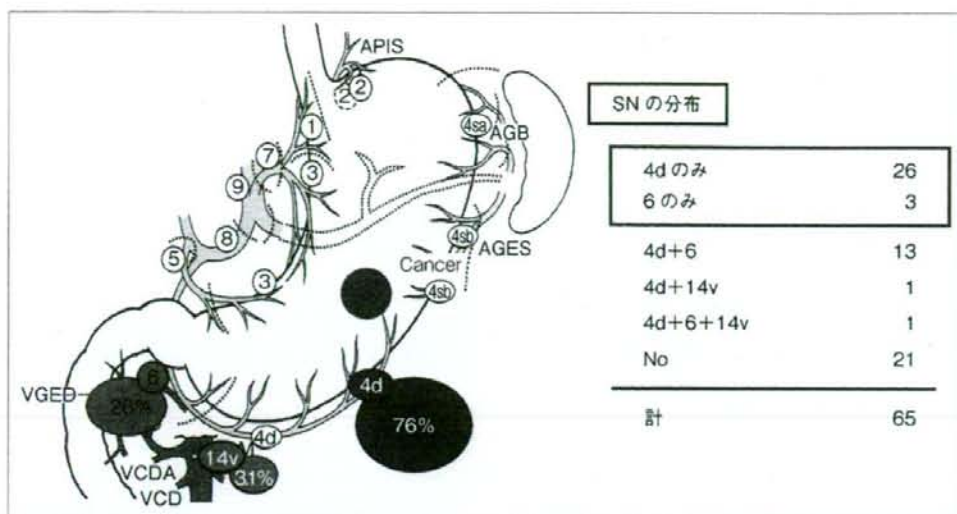
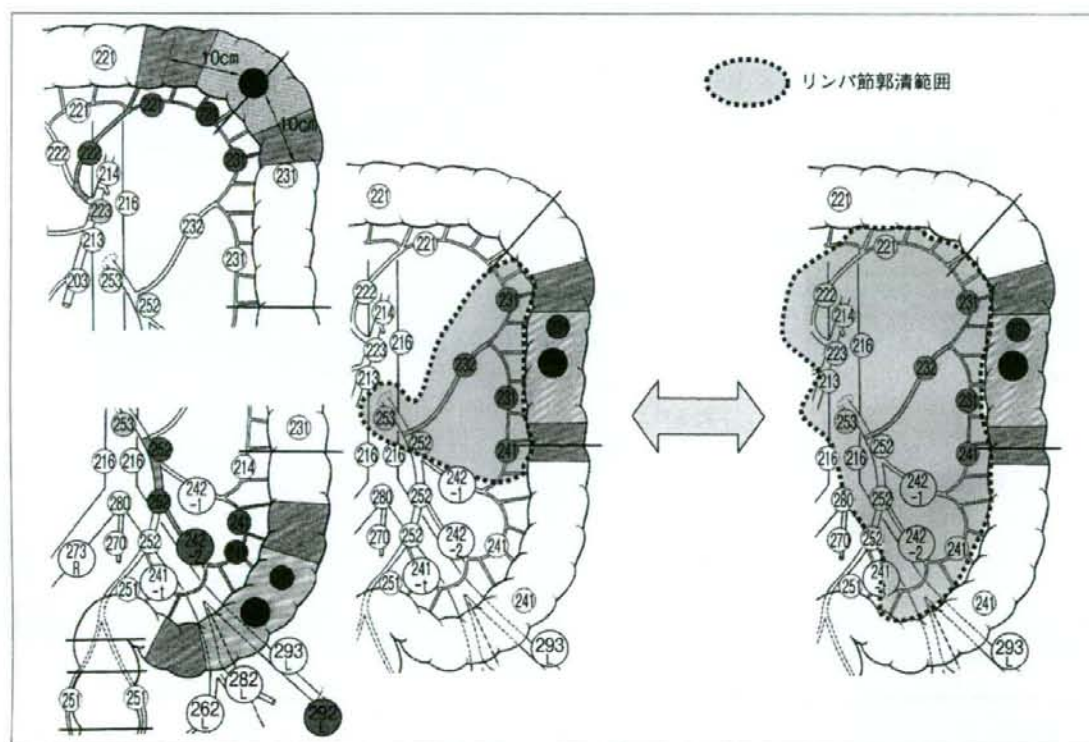


図5 右胃大網動脈流域におけるSNの分布 (M領域癌, n=65)

4d, 6番リンパ節ともに、単独でSNになることがあり、「機能的第1群リンパ節」と考えられるが、右胃大網動脈流域に関しては規約の第1群と合致している



[文献19]より引用]

図6 大腸癌の占居部位と郭清リンパ群

左側のパネルに下行結腸癌に対する通常のD3, 右側のパネルには過大な郭清範囲を示す。早期胃癌に対しては右側のパネルに相当するような郭清が行われている可能性がある

れているが、単独でSNになりうるかどうかという点からみると、7番リンパ節は「機能的1群リンパ節」であると考えられるのである。

<リンパ節群とリンパ節郭清に関する paradigm shift の必要性>

『胃癌取扱い規約』では、胃の近位から第1群、第2群リンパ節群を設定しているが、早期胃癌では機能的1群リンパ節を第1群とするほうがよいと考えられる。そして、ある領域の胃癌に対して機能的1群リンパ節を郭清することにより治療手術が達成されるように規定すれば、真に根治的な縮小手術となると考えられる。これまでも小彎側のリンパ節群分類に関して、動脈流域別にひとつの領域と認識すべきであるという論文が発表されているが²¹⁾、SNマッピングはこの考えに根拠を与えるものと考えられる。

このような考え方は、『大腸癌取扱い規約』¹⁹⁾ではすでに取り入れられている。図6の左側パネルのように下行結腸癌に対しては左結腸動脈に沿った一群のリンパ節を郭清することが基本的な治療手術と定義されている。そのなかでさらに1~3群までの設定はあるものの、ひとつの流域として捉えていることには相違ない。一方、図6の右側パネルに示したような郭清範囲は明らかに過剰なものであるが、横行結腸を胃上部、下行結腸を胃中部、S状結腸を胃下部に置き換えてみるとどうであろうか？ 胃中部の癌に対して1, 3, 5番リンパ節(仮に結腸腸間膜側を小彎とすると)を第1群として郭清することは、まさにこのような過剰郭清を行っていることにならないであろうか？ もちろん、胃は大腸と比較して、長軸が短いこと、血管系が複雑であること、間膜が両側にあることなど、同列には語れないと思われるが、主幹動脈に沿ったリンパ節流域をひとつの群とする概念を取り入れていくことも必要であろう。

2. 異時性胃癌の発生

縮小手術では残存する胃粘膜の面積が大きくなるため、定型手術より異時性胃癌の発生が高くなるのが危惧される。そのため厳密な経過観察が必須であり、早期胃癌の状態で見出しEMRまたはESDで治療させるべく努力が必要である。当科の検討では、機能温存根治手術を施行した160例において、平均5年間の追跡期間の間に5例(2.8%)に異時性胃癌の発生がみられたが、この頻度は報告されている幽門側胃切除術後の頻度と差は認められなかった²⁰⁾。しかし、横断切除術後の胃癌が幽門側の残胃に多いため、初回幽門側切除術を行っていればこれを防止できたという指摘

もあり²¹⁾、今後、長期的に異時性胃癌の発生率をみていくことが重要である。

おわりに

縮小手術を行う際には、早期癌の正しい術前診断、SN生検の手技、術中迅速病理診断など、精度の高い技術が要求される。腹腔鏡下手術と同様に、患者にやさしい(優しい)手術は、外科医にとってはやさしい(易しい)手術ではなく、決して安易な気持ちで取り組んではならないことを、肝に銘ずるべきである。

【文 献】

- 1) 日本胃癌学会編：胃癌治療ガイドライン(医師用) 2004年4月版。金原出版。東京。2004。p.9~11.
- 2) 三輪晃一、木南伸一、寺田逸郎、他：センチネルリンパ節生検による早期胃癌の縮小手術。消化器外科。23：1649~1656。2000.
- 3) 木南伸一、三輪晃一、石井要、他：早期胃癌に対する sentinel node navigation を応用した縮小手術。癌の臨床。48：855~862。2002.
- 4) Kitagawa, Y., Fujii, H., Mukai, M., et al.: The role of sentinel lymph nodes in gastrointestinal cancer. Surg. Clin. North Am. 80: 1799~1809. 2000.
- 5) Hiratsuka, M., Miyashiro, I., Ishikawa, O., et al.: Application of sentinel node biopsy to gastric cancer surgery. Surgery. 129: 335~340. 2001.
- 6) Ichikura, T., Morita, D., Uchida, T., et al.: Sentinel node concept in gastric carcinoma. World J. Surg. 26: 318~322. 2002.
- 7) Miwa, K., Kinami, S., Taniguchi, K., et al.: Mapping sentinel nodes in patients with early-stage gastric carcinoma. Br. J. Surg. 90: 178~182. 2003.
- 8) Isozaki, H., Okajima, K., Nomura, E., et al.: Postoperative evaluation of pylorus-preserving gastrectomy for early gastric cancer. Br. J. Surg. 83: 266~269. 1996.
- 9) Zhang, D., Shimoyama, S., and Kaminishi, M.: Feasibility of pylorus-preserving gastrectomy with scope of lymphadenectomy. Arch. Surg. 133: 993~997. 1998.
- 10) 藤村隆、木南伸一、伏田幸夫、他：Sentinel node navigation を応用した早期胃癌に対する機能温存根治手術。放射線生物研究。41: 221~230. 2006.
- 11) 三輪晃一：胃癌縮小手術における根治性確保の工夫：内視鏡的リンパ系描出法(endoscopic lymphatic mapping: ELM)。医学のあゆみ。170: 940~941. 1994.
- 12) 藤村隆、荻原正都、木南伸一、他：Sentinel node navigation による胃局所切除術(Lesion lifting法)。エンドスコピストとラパロスコピストのための最新消化器内視鏡治療。北島政樹編。先端医療技術研究所。東京。2002。p.308~310.
- 13) 三輪晃一、藤村隆：早期胃癌に対する縮小手術。外科治療。49: 413~419. 2004.
- 14) 三輪晃一、宮下知治、寺田逸郎、他：胃癌リンパ区域郭清術。手術。57: 1633~1637. 2003.
- 15) 日本胃癌学会編：胃癌取扱い規約。第13版。金原出版。