

- [5] Proksch E, Nissen HP, Bremgartner M, et al. Bathing in a magnesium-rich Dead Sea salt solution improves skin barrier function, enhances skin hydration, and reduces inflammation in atopic dry skin. *Int J Dermatol* 2005;44:151-7.

Ko-ichi Kawahara

*Department of Laboratory and Vascular Medicine
Cardiovascular and Respiratory Disorders
Advanced Therapeutics,
Kagoshima University Graduate
School of Medical and Dental Science,
8-35-1 Sakuragaoka, Kagoshima 890-8520,
Japan*

Salunya Tancharoen

*Department of Pharmacology,
Faculty of Dentistry, Mahidol University,
Bangkok, Thailand*

Teruto Hashiguchi

*Department of Laboratory and Vascular Medicine
Cardiovascular and Respiratory Disorders
Advanced Therapeutics,
Kagoshima University Graduate
School of Medical and Dental Science,
8-35-1 Sakuragaoka, Kagoshima 890-8520,
Japan*

Masako Unoshima

*Department of Anesthesiology,
Oita University Faculty of Medicine,
1-1 Hasama-machi,
Oita 879-5593, Japan*

Takashi Ito

*Kiyoshi Kikuchi
Yoko Morimoto
Toshiaki Shimizu
Yoko Oyama*

Kazunori Takenouchi

Shin-ichiro Arimura

Noboru Taniguchi

*Department of Laboratory and Vascular Medicine
Cardiovascular and Respiratory Disorders
Advanced Therapeutics,
Kagoshima University Graduate
School of Medical and Dental Science,
8-35-1 Sakuragaoka,
Kagoshima 890-8520,
Japan*

Masahiro Iwata

*Department of Dermatology,
Kagoshima University Graduate
School of Medical and Dental Science,
8-35-1 Sakuragaoka, Kagoshima 890-8520,
Japan*

Hideo Iwasaka

*Department of Anesthesiology,
Oita University Faculty of Medicine,
1-1 Hasama-machi,
Oita 879-5593,
Japan*

Ikuro Maruyama

*Department of Laboratory and Vascular Medicine
Cardiovascular and Respiratory
Disorders Advanced Therapeutics,
Kagoshima University Graduate
School of Medical and Dental Science,
8-35-1 Sakuragaoka, Kagoshima 890-8520,
Japan*

Tel.: +81 99 275 5437; fax: +81 99 275 2629

E-mail address: rinkin@m3.kufm.kagoshima-u.ac.jp

doi:10.1016/j.mehy.2006.10.025

Attenuation of headache during pregnancy may be caused by increase in thyroid hormone levels

Headache is one of the most common outpatient pain conditions encountered in both the physician office and emergency departments. A wide spectrum of etiological factors has been defined for different types of headache. Etiological factors range from micro insults to brain parenchyma to endocrinological changes [1]. Frequency and

severity of headache varies throughout life. There are hormonal milestones in females' life which affect pattern and quality of headache including menarche, pregnancy and menopause [2]. A considerable body of evidence shows of different kinds of headache during pregnancy. The best established mechanism attributed to this phenom-

Hemostatic Efficacy of a Recombinant Thrombin-Coated Polyglycolic Acid Sheet Coupled With Liquid Fibrinogen, Evaluated in a Canine Model of Pulmonary Arterial Hemorrhage

Yotaro Izumi, MD, Masatoshi Gika, MD, Noriko Shinya, DVM, Sumika Miyabashira, BS, Takayuki Imamura, PhD, Chikateru Nozaki, PhD, Masafumi Kawamura, MD, and Koichi Kobayashi, MD

Background: In thoracic surgery, although infrequent, we encounter unexpected damage to the pulmonary artery (PA). In the present study, we evaluated the hemostatic efficacy of a newly developed fibrin-based sheet material, thrombin sheet, coupled with liquid fibrinogen (TSF), in an experimental model of PA hemorrhage.

Methods: Female beagles ($n = 8$) were used for the study. Left thoracotomy was performed under general anesthesia. PA injury (approximately 4×2 mm) was created, and repaired by TSF (TSF group) or TachoComb (TC group). The animals were allowed to survive, and the repaired site was evaluated 4 weeks after the experiment.

Results: The number of sheet application and compression procedures required for hemostasis was increased in the TC group compared with in the TSF group (TC vs. TSF, 4 ± 1 vs. 1 ± 0.5 , $p = 0.01$, unpaired t test). The time required to achieve hemostasis was increased in the TC group compared with in the TSF group (TC vs. TSF, 7 ± 3 vs. 1 ± 0.5 minutes, $p = 0.01$, unpaired t test). The amount of bleeding during the hemostasis procedure was increased in the TC group compared with in the TSF group (TC vs. TSF, 48 ± 22 vs. 3 ± 3 g, $p = 0.01$, unpaired t test). At 4 weeks, rethoracotomy revealed no apparent indication of delayed bleeding, such as intrathoracic hematoma formation or excessive adhe-

sion formation in the vicinity of PA, in either group. Histologically, the vessel lumen was well sustained in both groups, with no apparent stenosis or thrombus formation.

Conclusion: The hemostatic efficacy of TSF was superior to TC in this particular experiment. Single application of TSF was sufficient to achieve hemostasis in all but one animal. Compression time of approximately 1 minute was also very short albeit that the bleeding was from the PA and not an artery. These results were presumably because the adhesion was stronger, faster, and the sheet was more pliable in TSF compared with TC.

Key Words: Recombinant thrombin sheet, Hemostasis, Pulmonary artery.

J Trauma. 2007;63:783-787.

In thoracic surgery, although infrequent, we encounter unexpected damage to the pulmonary artery (PA) resulting in moderate to massive hemorrhage. In most cases, bleeding can be controlled on the spot by manual compression, but compression needs to be released at some point to repair the damage, either to directly suture the vessel, or to sufficiently isolate the vessel, clamp it, and control the bleeding. Significant blood loss can ensue during this period. It will be

possible to reduce this blood loss if a ready-to-use hemostatic material, capable of swift hemostasis becomes available.

Hemostatic materials exploit various mechanisms such as absorbing and concentrating components of blood, increasing the enzymatic activity of clotting factors, or activating platelets.¹⁻³ Topical hemostatic agents utilizing materials such as cellulose or collagen provide mechanical scaffolds on which thrombus forms, but lack any inherent coagulation potential.^{4,5} In this regard, fibrin-based materials can mimic thrombus formation and currently seem to be most effective.⁶⁻¹¹

We have developed recombinant thrombin,^{12,13} which was lyophilized onto a bioabsorbable synthetic nonwoven polyglycolic acid fabric (Neoveil, Gunze K. K., Kyoto, Japan) to yield a new fibrin-based sheet material, thrombin sheet (TS).¹⁴ TS combined with liquid fibrinogen (TSF), is capable of swift hemostasis even when applied inside a blood pool. Fibrinogen solution is dripped onto the sheet immediately before application. Neoveil is loosely fabricated, and the sheet thickness is adjusted to 0.15 mm. This makes TSF quite supple so that it is able to securely conform to the contour of the applied site.

The hemostatic effect of fibrin-based materials in vascular injuries have been evaluated extensively using arterial injury models.^{1-3,6,8-11} To our knowledge, control of hemorrhage from the PA has not been adequately assessed.

Submitted for publication February 28, 2006.

Accepted for publication June 26, 2006.

Copyright © 2007 by Lippincott Williams & Wilkins

From the Division of General Thoracic Surgery (Y.I., M.K., K.K.), Department of Surgery, School of Medicine Keio University, Tokyo, Japan; Department of Thoracic Surgery (M.G.), Saitama Medical Center, Saitama Medical School, Saitama, Japan; Pathology Department (N.S.), Therapeutic Protein Products Research Department (S.M.), and Research Department 1 (T.I., C.N.), The Chemo-Sero-Therapeutic Research Institute (KAKETSUKEN), Kumamoto, Japan.

Address for reprints: Yotaro Izumi, MD, Division of General Thoracic Surgery, Department of Surgery, School of Medicine Keio University, 35 Shinanomachi, Shinjuku-ku, Tokyo 160-8582, Japan; email: yotaro@sc.keio.ac.jp.

DOI: 10.1097/TA.0b013e318151ffdc

Although blood pressure in the artery is much higher in comparison with that of the PA, adequate attachment of the sheet material may be more difficult to achieve in the PA because the vessel wall is more easily deformed by compression. Therefore, materials that control arterial hemorrhage may not necessarily be effective in PA hemorrhage.

In the present study, we evaluated the hemostatic effect of TSF in an experimentally created PA hemorrhage model. The efficacy of TSF was compared in the same model with that of TachoComb (TC) (ZLB Behring Co., Ltd., Bern, Switzerland), a widely used commercially available fibrin-based sheet product. We also measured *in vitro* fibrin formation in each material as a parameter of hemostatic potential.

MATERIALS AND METHODS

Preparation of Thrombin Sheet

Preparation of TS has been described previously.¹⁴ Briefly, mannitol (Nakarai Kagaku, 213-03, Kyoto, Japan), with a final concentration of 0.5% to 1.5%, and 40 mmol/L of calcium chloride were added to a solution containing 0.5% to 2% of glycerol. Recombinant thrombin^{12,13} was added to make the final concentration 1,500 U/mL. This solution was dripped at a rate of 0.05 mL/cm² and spread evenly using rubber-tipped rods onto a bioabsorptive synthetic nonwoven fabric (3 cm × 3 cm) made of polyglycolic acid, Neoveil (thickness, 0.15 mm). The sheet was frozen at -80°C for 2 hours and dried to fix the recombinant thrombin. The sheet was trimmed to 1.5 cm × 1.5 cm for use in this experiment. The sheet was dipped in 0.2 mL of liquid human fibrinogen (Boehringer, Chemo-sero-therapeutic Research Institute, Kumamoto, Japan). The liquid fibrinogen seeped evenly into the sheet within seconds. The sheet was then immediately applied.

Animal Experiment

Female beagles (Kitayama Labes Co. Ltd., Nagano, Japan) ($n = 8$) were used for the study. Body weight was measured before induction of anesthesia. Anesthesia was induced by subcutaneous injection of atropine sulfate (0.25 mg per animal), followed 10 minutes after by intramuscular injection of xylazine (1 mg/kg) and ketamine (10 mg/kg). The radial vein was cannulated. Anesthesia was maintained by continuous infusion of 0.1% ketamine in 5% glucose at a rate of approximately 1 mL/min. After injection of suxamethonium (10 mg per animal), the animal was intubated and mechanically ventilated with 40% oxygen. Tidal volume was approximately 200 mL, and respiratory rate was 14 breaths per minute. Empirically, mean systemic arterial blood pressure was maintained at approximately 100 mm Hg during this anesthesia protocol.

The animal was placed in a right lateral position, and left fourth intercostal thoracotomy was performed. The interlobar portion of the left PA was used for the experiment. A 2-mm plastic catheter with an 18-gauge needle tip was gently inserted into the PA, and PA pressure was measured until the values stabilized (for approximately 1 minute). Bleeding dur-

ing this procedure was negligible. Next, the vessel wall adjacent to the needle insertion site was held with fine-toothed forceps, and the vessel wall was resected with fine scissors so as to expand the needle hole proximally. Accounting for the thin and soft PA wall, we preferred this procedure to the use of a punch device. In our preliminary experiment, the laceration thus created was approximately 4 mm × 2 mm. The needle catheter was removed, and free bleeding was visually confirmed for approximately 3 seconds, after which it was controlled by manual compression. Blood in the thoracic cavity was thoroughly suctioned. TSF (TSF group, $n = 4$) or TC (TC group, $n = 4$), both 1.5 cm × 1.5 cm in size, was prepared for application. Manual compression was released, and immediately the sheet was applied to cover the laceration. Manual compression was applied over the sheet for 1 minute. If bleeding was not controlled, an additional sheet was applied followed by another minute of manual compression. This was repeated until bleeding was visually controlled. Bleeding during this period was absorbed using gauze, and measured in grams. Hemostasis was confirmed by observation for an additional 10 minutes, and then the chest was closed. Ketoprofen (1 mg/kg) and ampicillin sodium (15 mg/kg) was injected intramuscularly. The animals were allowed to recover and then were returned to their cages. After 4 weeks, the animals underwent rethoracotomy under general anesthesia and the left chest cavity was observed. The interlobar portion of the left PA was carefully inspected for traces of secondary bleeding, for the magnitude of tissue adhesion, and for the presence of residual materials. PA pressure measurement was performed as previously, distal to the site of vessel injury. The animals were killed by pentobarbital overdose, and the left PA was resected together with the left lung. The specimens were fixed in 10% buffered formalin, and embedded in paraffin. Three micrometer paraffin sections were stained with hematoxylin and eosin for histologic examinations.

The School of Medicine Keio University Institutional Animal Care and Use Committee approved all animal studies, which were performed in accordance with the *Guide for the Care and Use of Laboratory Animals* published by the National Academies Press.

Data are shown as mean ± standard deviation. Comparisons were made between groups using unpaired *t* test and within groups using paired *t* test (StatView, SAS Institute Inc., Cary, NC). Significance was assumed at $p < 0.05$.

In Vitro Measurement of Fibrin Formation

The fibrin clots were prepared for *in vitro* analysis as follows. In the TC group, a piece of the sheet (0.5 cm × 0.5 cm) was soaked with 50 μ L of saline containing 10 U/mL of factor XIII, 50 U/mL of recombinant thrombin, and 25 mmol/L of CaCl₂, and then incubated for 5, 10, and 30 minutes at 37°C. The reaction was stopped by adding 50 μ L of stop solution (4 mol/L urea, 5% sodium dodecyl sulfate [SDS], and 10% 2-mercapto ethanol). Fibrin was dissolved overnight.

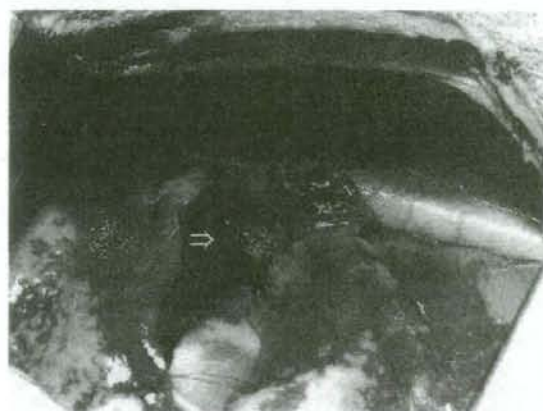

Fig. 1. The appearance of thrombin sheet immediately after application. The pulmonary artery laceration can be seen through the applied sheet (arrow).

In the TSF group, 12.5 μ L of 20 mg/mL fibrinogen containing 25 mmol/L of CaCl_2 was added to TS (size, 0.5 cm \times 0.5 cm; thrombin, 75 U/cm²), and incubated for 5, 10, and 30 minutes at 37°C. The reaction was stopped by adding of 12.5 μ L stop solution as in the treatment for TC.

SDS-polyacrylamide gel electrophoresis was performed according to the method of Laemmli.¹⁵ About 1 μ g of fibrinogen was subjected to SDS-polyacrylamide gel electrophoresis on a 7.5% polyacrylamide gel under reducing conditions. The gel was stained with Coomassie brilliant blue R-250.

RESULTS

All the animals survived. Body weight was comparable between groups before the experiment (TC vs. TSF, 10.0 \pm 1.0 vs. 10.4 \pm 0.2 kg, $p = 0.50$) and at 4 weeks after the experiment (TC vs. TSF, 11.6 \pm 0.9 vs. 11.7 \pm 0.6 kg, $p = 0.1$). Within groups, body weight was increased in both groups at 4 weeks after the experiment (TC group $p = 0.03$, TSF group $p = 0.01$).

Mean PA pressure was comparable between groups before vessel laceration (TC vs. TSF, 28 \pm 5 vs. 27 \pm 9 mm Hg, $p = 0.96$) and at 4 weeks after the experiment (TC vs. TSF, 32 \pm 3 vs. 30 \pm 1 mm Hg, $p = 0.2$). Also, within groups, mean PA pressure was comparable in both groups at 4 weeks after the experiment, compared with values before vessel laceration (TC group $p = 0.59$, TSF group $p = 0.21$).

Hemostasis was effectively achieved in both groups after sheet application. In the TSF group, the laceration could be clearly seen through the sheet (Fig. 1, arrow). The number of sheet application and compression procedures required for hemostasis was increased in the TC group compared with in the TSF group (TC vs. TSF, 4 \pm 1 vs. 1 \pm 0.5, $p = 0.01$). The time required to achieve hemostasis was increased in the TC group compared with in the TSF group (TC vs. TSF, 7 \pm 3 vs. 1 \pm 0.5 minutes, $p = 0.01$). The amount of bleeding during the hemostasis procedure was increased in the TC group compared with in the TSF group (TC vs. TSF, 48 \pm 22 vs. 3 \pm 3 g, $p = 0.01$).

At 4 weeks, rethoracotomy revealed no apparent indication in either group of delayed bleeding, such as intrathoracic hematoma formation or excessive adhesion formation in the vicinity of the PA. Macroscopically, adhesion of the lung to the site of sheet application was more apparent in the TC group compared with the TSF group. Residual material was present in both groups, and more prominent in the TC group. Histologically, the vessel lumen was well sustained in both groups, with no apparent stenosis or thrombus formation. However, thickening of the adventitia and the perivascular sheath seemed to be more prominent in the TC group (Fig. 2).

In vitro fibrin formation was more prominent in the TSF group compared with in the TC group. In the TSF group, γ - γ cross-linking was formed within 10 minutes, and α - α polymer was observed. On the other hand, we identified only a trace amount of γ - γ cross-linking in TC group (Fig. 3).

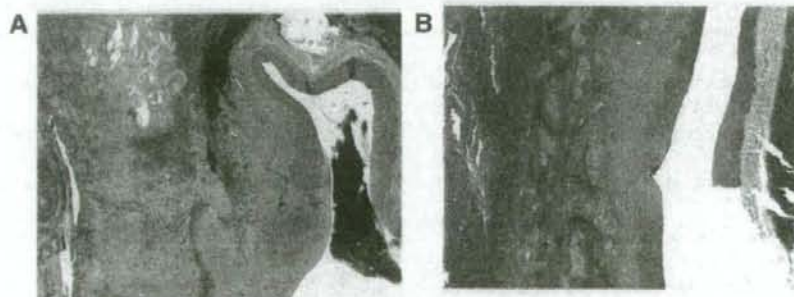


Fig. 2. Histologically, the lumen of the repaired vessel was well sustained in both TacoComb (A), and thrombin sheet (B) groups. However, thickening of the adventitia, and the perivascular sheath seemed more prominent in the TacoComb group (A), compared with the thrombin sheet (B) group (Hematoxylin and eosin stain; original magnification, $\times 2$).

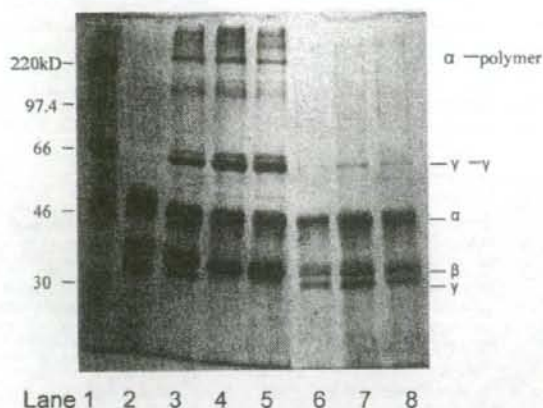


Fig. 3. SDS-PAGE of *in vitro* formed fibrin in thrombin sheet plus liquid fibrinogen (TSF group), and TacoComb (TC group). Lane 1, molecular weight marker; lane 2, fibrinogen; lane 3, TSF group reaction for 5 minutes; lane 4, TSF group reaction for 10 minutes; lane 5, TSF group reaction for 30 minutes; lane 6, TC group reaction for 5 minutes; lane 7, TC group reaction for 10 minutes; lane 8, TC group reaction for 30 minutes. *In vitro* fibrin formation was more prominent in the TSF group compared with in the TC group. In the TSF group, γ - γ cross-linking was formed within 10 minutes, and α - α polymer was observed. On the other hand, we identified only a trace amount of γ - γ cross linking in TC group.

DISCUSSION

Fibrin-based sealants have been commercially available in Europe and Japan for many years. Most formulations come as solutions of dissolved thrombin and fibrinogen, which are mixed on application. This form of liquid application is obviously not well suited for hemostasis in vessel injuries where there is significant outflow of blood. Solid material is more suitable because it can withstand the initial outflow of blood, and can be held with pressure after application. To this end, dry fibrin-based hemostatic materials are being developed extensively for potential use, particularly in trauma.^{8,9,11} These materials should optimally contain both components, thrombin and fibrinogen, lyophilized onto a sheet material ready for immediate use. Dry materials are also easier to store, particularly for use in combat settings. TC is one such material commercially available in Europe and Japan.¹⁶ Similar dry-sheet type fibrin-based sealants have been extensively evaluated in a variety of hemorrhage models. The results are promising.

Compared with dry materials, TSF is semidry, and may not be ideal for use in trauma settings because liquid fibrinogen needs to be separately prepared. But our attempt to include dry fibrinogen into a sheet material considerably increased the rigidity of the sheet, as is the case with TC. To this end, the TSF is quite supple and conforms considerably better to the contour of the applied site in comparison with how well TC conforms. We considered that this may be

advantageous for bleeding during surgery, particularly from the PA, which is distributed three dimensionally in the thoracic cavity with branching from short segments and is surrounded by lung tissue, which inflates and deflates during ventilation.

In the present study, we investigated the efficacy of fibrin-based sheet type materials in a PA injury model. Hemostasis in vessel injury has been evaluated quite extensively in swine aortic models.^{2,8-11} Considering the size of the animals used, approximately 10 kg dogs versus approximately 40 kg pigs, we consider the laceration size in the present study (4 mm \times 2 mm) to be sufficiently large, relative to the laceration size in the widely reported swine model of aortic bleeding (4 mm \times 4 mm). In our preliminary experiment, PA injury could not be controlled by manual compression alone.

Both TSF and TC were capable of adequately controlling PA hemorrhage in this study. Because PA pressure is significantly lower compared with systemic arterial pressure, reduction in blood flow caused by stenosis may more readily ensue compared with the response of arteries of similar caliber. Based on the PA pressure measurements and histologic observations, vessel stenosis or intraluminal thrombosis was not apparent with the use of either material in this study 4 weeks after application, despite the relatively large laceration size. Histologically, thickening of the adventitia and the perivascular sheath was suspected in the TC group, which may in part be because of the increased number of sheet applications.

Overall, the efficacy of TSF was superior to that of TC in this particular experiment. A single application of TSF was sufficient to achieve hemostasis in all but one animal in which the sheet was misplaced, and the vessel laceration was only partially covered on the first application. Compression time of approximately 1 minute was also very short albeit that the bleeding was from the PA and not an artery. These results were observed presumably because the adhesion was stronger, faster, and the sheet was more pliable in TSF compared with in TC.

Fibrinogen is a multidomain protein composed of three polypeptide chains termed A α , B β , and γ . Thrombin binds to fibrinogen and cleaves fibrinopeptide A and fibrinopeptide B, and assembles to form fibrin. In the presence of factor XIII and Ca²⁺, fibrin undergoes intermolecular covalent cross-linking, which was not as prominent in the TC group compared with in the TSF group. The stronger and faster adhesion may have been at least in part a result of the facilitated formation of fibrin in TSF as shown *in vitro*, although *in vivo* relevance may be less because tissue-derived coagulation factors exist. TSF also allowed for visualization of the laceration through the applied sheet, which was not possible with TC. This enables suturing of the laceration through the TSF for a more definitive hemostasis (data not shown). This property can be considered comparable with what is reported for the American Red Cross fibrin dressing.^{8,9} Although we do

not have any experience with this material because of lack of access, the reports indicate that the American Red Cross dressing also achieves superior hemostasis compared with that of TC. Adhesion of TC to the surgical glove during manual compression was another problem. TC had to be gently scraped off the glove with forceps to leave the sheet in place, which was not the case with TSF. Furthermore, after 4 weeks, TSF induced less adhesion compared with TC, suggesting better biocompatibility, although this difference may just be because of the number of applications required. It is true that both materials sufficiently controlled bleeding in this experiment. However, we think that TSF would be much less stressful to use in a setting of unexpected PA bleeding, considering the multiple applications required for TC, as well as the additional blood loss that occurred during this period.

Despite its efficacy, there are certain constraints associated with fibrin-based materials such as availability and cost. It is also true that fibrin-based materials carry a risk of pathogen transmission, although today this is considered to be minimal as a result of improved screening and purification techniques. To alleviate some of these problems, we used recombinant thrombin for TS and development of recombinant fibrinogen is in progress. Ongoing preliminary studies in rabbit aortic injury models also seem to be promising. Studies are necessary to further clarify the hemostatic efficacy of this material in other organ trauma models and in coagulopathic animals.

ACKNOWLEDGMENTS

We thank Dr. Yuji Nishiwaki, Department of Preventive Medicine and Public Health, for his helpful comments on statistical analysis.

REFERENCES

- Rothwell SW, Fudge JM, Chen WK, Reid TJ, Krishnamurti C. Addition of a propyl gallate-based procoagulant to a fibrin bandage improves hemostatic performance in a swine arterial bleeding model. *Thromb Res*. 2002;108:335-340.
- Vournakis JN, Demcheva M, Whitson AB, Finkielstein S, Connolly RJ. The RDH bandage: hemostasis and survival in a lethal aortotomy hemorrhage model. *J Surg Res*. 2003;113:1-5.
- Connolly RJ. Application of the poly-N-acetyl glucosamine-derived rapid deployment hemostat trauma dressing in severe/lethal Swine hemorrhage trauma models. *J Trauma*. 2004;57:S26-S28.
- Masova L, Rysava J, Krizova P, et al. Hemostatic effect of oxidized cellulose on blood platelets. *Sb Lek*. 2003;104:231-236.
- Sirlak M, Eryilmaz S, Yazicioglu L, et al. Comparative study of microfibrillar collagen hemostat (Colgel) and oxidized cellulose (Surgicel) in high transfusion-risk cardiac surgery. *J Thorac Cardiovasc Surg*. 2003;126:666-670.
- Jackson MR, Friedman SA, Carter AJ, et al. Hemostatic efficacy of a fibrin sealant-based topical agent in a femoral artery injury model: a randomized, blinded, placebo-controlled study. *J Vasc Surg*. 1997; 26:274-280.
- Jackson MR. New and potential uses of fibrin sealants as an adjunct to surgical hemostasis. *Am J Surg*. 2001;182:365-395.
- Sondeen JL, Pusateri AE, Coppes VG, Gaddy CE, Holcomb JB. Comparison of 10 different hemostatic dressings in an aortic injury. *J Trauma*. 2003;54:280-285.
- Pusateri AE, Modrow HE, Harris RA, et al. Advanced hemostatic dressing development program: animal model selection criteria and results of a study of nine hemostatic dressings in a model of severe large venous hemorrhage and hepatic injury in Swine. *J Trauma*. 2003;55:518-526.
- Rothwell SW, Reid TJ, Dorsey J, et al. A salmon thrombin-fibrin bandage controls arterial bleeding in a swine aortotomy model. *J Trauma*. 2005;59:143-149.
- Kheirabadi BS, Acheson EM, Deguzman R, et al. Hemostatic efficacy of two advanced dressings in an aortic hemorrhage model in Swine. *J Trauma*. 2005;59:25-35.
- Soejima K, Mimura N, Yonemura H, Nakatake H, Imamura T, Nozaki C. An efficient refolding method for the preparation of recombinant human prothrombin-2 and characterization of the recombinant-derived alpha-thrombin. *J Biochem (Tokyo)*. 2001; 130:269-277.
- Yonemura H, Imamura T, Soejima K, et al. Preparation of recombinant alpha-thrombin: high-level expression of recombinant human prothrombin-2 and its activation by recombinant ecarin. *J Biochem (Tokyo)*. 2004;135:577-582.
- Uchida T, Shinya N, Kaetsu H, Imamura T, Nozaki C. Thrombin-carrying bioabsorbable synthetic nonwoven fabric. WO 2004/043503.
- Laemmli UK. Cleavage of structural proteins during the assembly of the head of bacteriophage T4. *Nature*. 1970;227:680-685.
- Agus GB, Bono AV, Mira E, et al. Hemostatic efficacy and safety of TachoComb in surgery. Ready to use and rapid hemostatic agent. *Int Surg*. 1996;81:316-319.

EDITORIAL COMMENT

The authors have demonstrated that a new fibrin-based sheet material that is combined with liquid fibrinogen immediately before use (TSF) provides superior hemostasis when compared with a commercially available fibrin-based sheet material, TachoComb (TC), in a canine model of hemorrhage from an acute pulmonary artery injury. They reference a similar study showing hemostatic superiority of an American Red Cross dry fibrin-based sheet dressing for obtaining hemostasis from acute injury. They, also, reference studies showing excellent hemostasis for systemic arterial hemorrhage, which, of course, occurs at a much higher pressure than that seen from pulmonary artery hemorrhage. Although the authors point out that there are subtle differences in the physics of the injured low-pressure pulmonary artery compared with the high-pressure aortic perforation, the enhanced efficacy of the TSF in this lower arterial pressure system is predictable. Furthermore, the injury described, herein, might be encountered by a thoracic surgeon doing extirpative surgery for intrathoracic tumors but would be rarely encountered in the injured patient who, typically, would have associated lung injury. Thus, the application of this technique to the injured patient is limited.

This reviewer eagerly awaits subsequent reports defining the benefits of this product in the hands of thoracic surgeons.

Charles E. Lucas, MD
Wayne State University
Detroit, MI

Cross-linked poly (gamma-glutamic acid) attenuates peritoneal adhesion in a rat model

Yotaro Izumi, MD, PhD,^a Michiko Yamamoto, BS,^b Masafumi Kawamura, MD, PhD,^a Takeshi Adachi, MD, PhD,^b and Koichi Kobayashi, MD, PhD,^a Tokyo, Japan

Background. Poly (gamma-glutamic acid) (PGA) is a naturally occurring biodegradable polymer produced by *Bacillus subtilis*. PGA is crosslinked by gamma-irradiation to yield crosslinked PGA (XL). XL absorbs large amounts of fluid and forms a biodegradable viscous hydrogel. In the present study, we evaluated the anti-adhesive effect of XL in a rat abdominal wall defect and cecal abrasion model.

Methods. Abdominal wall resection and cecal abrasion were carried out in rats (abrasion-no-treatment group, n = 12). In the treatment groups, the following materials were applied: PGA (n = 12), XL (n = 16), hyaluronic acid (HA) (n = 12), Seprafilm (n = 12), and Intereed (n = 10). A week later, adhesion formation was evaluated.

Results. Firm adhesions were seen in the abrasion-no-treatment group. XL reduced adhesion formation significantly compared with abrasion-no-treatment, HA, Seprafilm, and Intereed groups. Although not statistically significant, the magnitude of adhesion formation was decreased in the XL group in comparison to the PGA group.

Conclusions. We suggest that the anti-adhesive effect of XL was superior to other materials in this rat model. XL application may have attenuated tissue adhesion by forming a viscous hydrogel over the injured surfaces. (*Surgery* 2007;141:678-81.)

From the Department of Surgery, Division of General Thoracic Surgery,^a and Department of Biochemistry and Integrative Medical Biology,^b School of Medicine, Keio University, Tokyo, Japan

THE CONSEQUENCES OF ADHESIONS after abdominal operation include small-bowel obstruction, infertility, chronic abdominal pain, and difficulty of a second operation. As longevity is increased, more patients are likely to undergo multiple operative procedures during their lifetime. With the advent of minimally invasive video-assisted operation, the frequency and magnitude of postoperative adhesion formation has decreased dramatically in all fields of operation. Adhesion formation, however, occurs to some extent even in video-assisted operation, and there are still many instances where open operation is required. The search for an effective anti-adhesive agent has been ongoing for

decades. Although some agents have shown promise in preclinical and clinical studies, their efficacy currently is by no means satisfactory.

Poly (gamma-glutamic acid) (PGA) is a naturally occurring, biodegradable polymer produced by a strain of *Bacillus subtilis*.¹ PGA can be crosslinked by gamma-irradiation to yield crosslinked PGA (XL). In the presence of fluid, XL forms a biodegradable viscous hydrogel capable of holding water approximately 1,400 times its dry volume.² There are many ways to crosslink polymers such as PGA to create hydrogels with high water absorption. Among these, irradiation is most convenient, because it uses no chemical agents that require subsequent removal, and it often expedites the need for additional sterilization. Research into the application of XL for cosmetics, purification of sewage, drug delivery systems, and reforestation is in progress currently. Based on its ability to absorb fluid and form a viscous hydrogel, we hypothesized that XL may be effective as an anti-adhesive agent. In the present study, we evaluated the anti-adhesive effect of XL in a rat abdominal wall defect and cecal abrasion model.

Accepted for publication December 14, 2006.

Reprint requests: Yotaro Izumi, Department of Surgery, Division of General Thoracic Surgery, School of Medicine Keio University, 35 Shinanomachi, Shinjuku-ku, Tokyo 160-8582, Japan. E-mail: yotaro@sc.itc.keio.ac.jp.

0039-6060/\$ - see front matter

© 2007 Mosby, Inc. All rights reserved.

doi:10.1016/j.surg.2006.12.010

MATERIALS AND METHODS

Animal experiment. Male Donryu rats, 5 to 7 weeks old, weighing 150 to 200 g (Saitama-jikkenn, Saitama, Japan) were used for this study. The animals were housed 3 per cage in a temperature-controlled, 12-hour light/dark-cycled room with free access to food and water. The rats were anesthetized with an intramuscular injection of a cocktail of 90 mg ketamine hydrochloride (Parke-Davis, Morris Plains, NJ) and 9 mg xylazine (Fermentia, Kansas City, MO) per kg body weight. Operative procedures were carried out in a semi-sterile environment under a heating lamp. Abdominal wall resection and cecal abrasion was carried out as reported previously.³ In brief, the ventral hair was clipped with an electric shaver, and the abdominal skin was painted with 70% alcohol. A 5-cm midline abdominal incision was made. In all the rats used, the cecum was located to the left of midline. The left abdominal wall covering the cecum was retracted. A 1 × 2 cm segment of parietal peritoneum directly anterior to the cecum was excised sharply from the abdominal wall including a layer of underlying muscle. The defect was then abraded by rubbing with a dry gauze. The cecum was also abraded by rubbing with dry gauze so that a homogenous surface of petechial hemorrhage was created over a 1 × 2 cm surface. Both the abdominal wall defect and the abraded cecum were dried in hot air with a hair dryer for 20 seconds, and then exposed to room air for 10 minutes. The rest of the abdominal contents were protected from drying by placement of moistened gauze. The abraded areas were then placed in contact, and the midline incision was closed (abrasion-no-treatment group, n = 12). The animals were allowed to recover from anesthesia, and were returned to their cages.

In the treatment groups, the following materials were placed between the abraded areas at closure. PGA (BioPGA, Meiji Seika Kaisha Ltd, Tokyo, Japan), (PGA group, n = 12), XL (BioPGA-XL, Meiji Seika Kaisha Ltd) (XL group, n = 16), hyaluronic acid (HA group, n = 12) (molecular weight 2×10^5 ; Meiji Seika Kaisha Ltd), Seprafilm (Seprafilm group, n = 12) (Genzyme Corp, Cambridge, MA), and Interceed (Interceed group, n = 10) (Ethicon Inc, Somerville, NJ). BioPGA and BioPGA-XL are powders. In the PGA and XL groups, BioPGA or BioPGA-XL was sprinkled to cover the abraded area. In the HA group, HA was applied as a 0.4% solution in phosphate buffered saline as reported previously.¹ Two milliliters of the solution was applied over the abraded area and allowed to spread in the abdominal cavity. Se-

prafilm and Interceed are sheets. In the Seprafilm and Interceed groups, the sheets were trimmed and applied so that the entire abraded areas were covered completely. One surgeon (Y.I.) carried out all the operations but was blinded to the randomization while carrying out the abrasions.

Seven days later, the rats were anesthetized, and a relaparotomy was carried out through a right paramedian incision to avoid damaging the site of adhesions. Adhesions were scored by an adhesion severity scoring system reported previously³:

- 0 = no adhesions;
- 1 = loose filmy adhesions that can be separated by blunt dissection;
- 2 = adhesions requiring less than 50% of sharp dissection for separation;
- 3 = adhesions requiring greater than 50% of sharp dissection for separation;
- 4 = serosal injury;
- 5 = full-thickness injury.

Scoring was done by M.K. who was blinded to the group assignment. Scores were averaged within groups.

Body weight of the animals were measured before operation and 7 days after before scoring the adhesion. For comparison, body weight also was measured in animals receiving no intervention (control group, n = 6), and in animals receiving anesthesia and laparotomy without abrasion (laparotomy-only group, n = 6).

All animal studies were approved by the School of Medicine Keio University Institutional Animal Care and Use Committee and were carried out in accordance with the "Guide for the Care and Use of Laboratory Animals" published by the National Institute of Health.

Data are presented as mean \pm standard deviation. Adhesion scores were compared between groups using Kruskal-Wallis Dunn's test (StatMate III, ATMS, Ltd, Tokyo, Japan). Changes in body weight were compared between groups using ANOVA Bonferroni's test (StatView, SAS Institute, Cary, NC). Significance was assumed at *P* less than .05.

RESULTS

Animal experiment. The distribution of adhesion scores is shown in the Table. With the exception of 1 animal, adhesions were absent in the XL group. The average adhesion score was less in XL (0.1 ± 0.3) compared with the other groups of abrasion-no-treatment (3.4 ± 1.1), HA (3.0 ± 0.9), Seprafilm (1.8 ± 0.6), or Interceed (2.4 ± 0.8). The average adhesion score did not differ between

Table. Distribution of adhesion scores in each group are shown

Group	Abrasion- adhesion score	Abrasion- no- treatment	PGA†	XL*	HA	Septrafilm	Interceed
0	0	9	15	0	0	0	0
1	1	5	1	0	3	1	1
2	0	2	0	5	8	5	5
3	6	0	0	3	1	3	3
4	3	0	0	4	0	1	1
5	2	0	0	0	0	0	0

HA, hyaluronic acid; PGA, poly (gamma-glutamic acid); XL, cross-linked poly (gamma-glutamic acid).

*Differs from all other groups except PGA ($P < .05$).

†Differs from abrasion-no-treatment, HA, and Interceed ($P < .05$).

the XL and PGA groups (0.6 ± 0.7). The average adhesion score was less in PGA group compared with abrasion-no-treatment, HA, or Interceed groups, but not in comparison to the Septrafilm group. There were no differences between the abrasion-no-treatment, HA, Septrafilm, or Interceed groups.

No apparent changes in behavior were seen in any of the animals. The percent changes in body weight in the abrasion-no-treatment, PGA, XL, HA, Septrafilm, and Interceed groups were 93 ± 3 , 104 ± 7 , 105 ± 6 , 93 ± 4 , 97 ± 6 , and 97 ± 7 , respectively. Body weight remained greater in the Septrafilm, Interceed, PGA, and XL group compared with abrasion-no-treatment, and HA groups, but only PGA, and XL groups reached statistical significance. In the control and laparotomy-only groups, the percent increase in body weight during 7 days were 138 ± 3 and 119 ± 3 , respectively. Increases in weight were greater in the control group compared with the laparotomy-only group and in the laparotomy-only group compared with any of the animals that underwent abrasion ($P < .05$ each).

DISCUSSION

Mechanical separation of injured surfaces is a strategy for preventing the formation of tissue adhesion. Ideally, the material should be easily applicable, biodegradable without systemic effects, and can be applied repetitively if multiple operations are required. Materials of this kind come in various forms including liquid, powder, and sheet preparations. We evaluated the formation of adhesions in this rat model 7 days after operation based on a number of studies that indicate that adhesions become established within 7 days of tissue injury³ and because in a rat model, adhesions presenting at 1

week were persistent at 6 months.⁶ The extent of tissue injury in this experiment was probably greater than what we encounter commonly in clinical practice, but adhesions of this magnitude may be present in patients who have undergone multiple operations. The increase in body weight during the 7-day observation period was suppressed in these groups receiving abrasion compared with only-laparotomy. This suppression in weight gain may have been attenuated by the application of the anti-adhesive materials of PGA and XL. The results also showed that weight suppression was not attributable to any of the materials applied.

In the present study, the efficacy of HA was not clear, consistent with previous reports indicating its efficacy only when applied before abrasion is created.⁴ Lubricating agents such as HA have shown some effect when used before injury, but this is not always possible in clinical practice. The sheet materials of Septrafilm and Interceed are available commercially. Although the average adhesion scores did not differ from the abrasion-no-treatment group, their efficacy in this study was comparable to previous preclinical studies using these materials in various laparotomy models, notwithstanding that the models differ slightly from study to study.^{5,7} Both these agents decreased the severity of adhesion formation, but sharp dissection was required to some extent in most animals. Although our study groups were relatively small, the anti-adhesive effect of XL seems to be superior to other materials in this particular model. Although the difference in the average adhesion score between XL and PGA did not differ, adhesions were absent in the XL group with the exception of 1 animal; thus, we believe that this material deserves further investigation. The efficacy of anti-adhesive agents is reported to be related, at least in part, to the agents' viscosity, its ability to coat the wounded surface, and the residence time at the site of injury.⁸ We know that XL forms a viscous hydrogel, and this hydrogel may have coated effectively the wounded surface for a sufficient period of time. Further studies are necessary to elucidate the exact mechanisms involved.

One may question the dose-equivalency between the different forms of the materials used in this study. Although it is not possible to compare explicitly liquid, powder, and sheet, in the present study, materials other than PGA and XL were used according to previous reports. As for PGA and XL, we used the minimum amount required to cover sufficiently the abraded area. Further dose-efficacy studies along with studies on potential side effects are necessary to determine the most appropriate

dose. Each material has advantages and drawbacks. Liquid materials such as HA disperse in the abdominal cavity. Some investigators claim this property to be beneficial, because it interferes with all potential adhesion formation. Prevention of adhesions remote from the site of application may not, however, always be advantageous. Adhesions may represent the process of healing and thereby function to prevent or ameliorate postoperative bleeding or dehiscence of gastrointestinal anastomoses. The use of drainage tubes after operation may evacuate extravasated secretions or exudate in the abdominal cavity, and at the same time, the anti-adhesive material may interfere with this drainage. To this end, sheet materials, such as Seprafilm and Interceed, provide localized anti-adhesive effect, but materials in the forms of liquid or powder may be more easily applicable from the ports in video-assisted operation. Because XL forms a hydrogel by absorbing surrounding fluid, it eventually disperses in the abdominal cavity with time. This property may be overcome by embedding the powder in a sheet material to provide better localization. It may also be possible to incorporate factors that regulate adhesion formation within the XL hydrogel. Further studies are necessary to evaluate the anti-adhesive effect of XL, including studies in relaparotomy models, as well as other models of adhesion. Regarding its safety, studies in experimental models including intraperitoneal gastrointestinal anastomoses are necessary because this

material may interfere with wound healing of anastomoses. We assume that the XL in the abdominal cavity is degraded by hydrolysis and absorbed, but long-term observations are necessary to further define its metabolism.

We thank Dr. Yuji Nishiwaki, Department of Preventive Medicine and Public Health, for his comments on the statistical analyses.

REFERENCES

1. Shih IL, Van YT. The production of poly-(gamma-glutamic acid) from microorganisms and its various applications. *Bioresour Technol* 2001;79:207-25.
2. Choi HJ, Kunioka M. Preparation conditions and swelling equilibria of hydrogel prepared by gamma-irradiation from microbial poly (gamma-glutamic acid). *Radiat Phys Chem* 1995;46:175-9.
3. Harris ES, Morgan RF, Rodeheaver GT. Analysis of the kinetics of peritoneal adhesion formation in the rat and evaluation of potential anti-adhesive agents. *Surgery* 1995;117:663-9.
4. Yaacobi Y, Israel AA, Goldberg EP. HA Prevention of postoperative abdominal adhesions by tissue precoating with polymer solutions. *J Surg Res* 1993;55:422-6.
5. Oncel M, Remzi FH, Senagore AJ, Connor JT, Fazio VW. Comparison of a novel liquid (Adcon-P) and a sodium hyaluronate and carboxymethylcellulose membrane (Seprafilm) in postsurgical adhesion formation in a murine model. *Dis Colon Rectum* 2003;46:187-91.
6. Ryan GB, Grobety J, Majno G. Postoperative peritoneal adhesions. A study of the mechanisms. *Am J Pathol* 1971; 65:117-48.
7. Ryan CK, Sax HC. Evaluation of a carboxymethylcellulose sponge for prevention of postoperative adhesions. *Am J Surg* 1995;169:154-9.

ヘモグロビン小胞体 (HbV)-リコンビナントアルブミン分散溶液による 40% 交換輸血：ラット脾臓内 HbV 代謝と造血に関する 2 週間の観察[†]

酒井 宏水¹⁾ 堀之内宏久²⁾ 山本 学²⁾ 池田 栄二³⁾ 武岡 真司⁴⁾
高折 益彦⁵⁾ 土田 英俊¹⁾ 小林 紘一²⁾

(背景) 輸血代替として開発されたヘモグロビン小胞体 (HbV, 粒径 $251 \pm 81 \text{nm}$) について, 動物投与試験によりその酸素運搬機能が明らかにされてきた。しかし投与後の中長期的な回復過程, 特に細網内皮系における HbV の分解と造血については十分な検討が為されていなかった。(方法) Wistar 系ラット (♂, 60 匹) を用い, HbV を 5g/dL 濃度のリコンビナントアルブミン溶液 (rHSA) に分散させた溶液 (HbV/rHSA), ラット保存赤血球を rHSA に分散させた溶液 (sRBC/rHSA), 或は rHSA 溶液単独で, 循環血液量の 40% を急速交換した。その後最長 14 日間の血液学的, 血液生化学的解析, および組織病理学的検討を実施した。(結果) HbV/rHSA 群と rHSA 群では, 血液交換後に低下したヘマトクリット値 (Hct, 約 26%) が, 7 日後には交換前の値 (43%) にまで回復した。血中エリスロポエチン濃度は, 全群で上昇した。特に rHSA 群で 1 日後に最も高い値を示し ($321 \pm 123 \text{IU/L}$), 貧血状態を反映したと考えられた (HbV/rHSA, 153 ± 22 ; sRBC/rHSA, 63 ± 7 ; baseline, 21 ± 3)。また, 同時に全群で脾臓肥大を認めた (HbV/rHSA > rHSA > sRBC/rHSA)。組織病理学的観察から, 脾臓に捕捉された HbV は 14 日以内に完全に消失した。しかし, ヘモジデリン沈着が HbV/rHSA 群および sRBC/rHSA 群に認められた。また, rHSA 群と HbV/rHSA 群の赤脾臓に多量の赤芽球が存在した。(結論) 40% 交換輸血において, 脆弱な赤血球が細網内皮系で捕捉分解される生理的機序と同様の経路を経て, HbV が捕捉代謝される過程が予想された。また, 造血機能の亢進により Hct が 7 日以内に完全に支障無く回復することを確認した。

キーワード: 人工血液, 人工酸素運搬体, 人工赤血球, リボソーム, 代用血漿剤

[†]本論文内容は, Transfusion 誌編集長および Blackwell Publishing 社の許可のもと, Transfusion 第 46 巻 第 3 号 339 頁-347 頁, 2006 年に最初に掲載された論文に基づき作製したものである (This article is based on a study first reported in the paper: Sakai H, Horinouchi H, Yamamoto M, Ikeda E, Takeoka S, Takaori M, Tsuchida E, Kobayashi K: Acute 40 percent exchange-transfusion with hemoglobin-vesicles (HbV) suspended in recombinant human serum albumin solution: degradation of HbV and erythropoiesis in a rat spleen for 2 weeks. Transfusion. 46 (3): 339-347, 2006)

第 53 回日本輸血学会総会推薦論文

1. 緒言

ヘモグロビン (Hb) を利用した人工酸素運搬体 (Hb-based O_2 carriers, HBOCs) の研究が世界的規模で進展し, 臨床試験の段階にある製剤も幾つか知られている^{1,2)}。HBOC の利点は, 血液型が無いこと, 病原体を完全に排除できること, また, 赤血球に比較して長期間の保存が可能なことである³⁾。血中滞留時間が赤血球に比較して 2~3 日と短いものの⁴⁾, 様々な短時間の用途が期

待されている。例えば, 1) 緊急時の出血性ショックの蘇生液として, 輸血までの繋ぎとしての投与⁵⁾, 2) 術前の血液希釈, 術中の出血に対する投与により, 輸血の回避, 或は輸血を遅らせる手段⁶⁾, 3) 心臓手術の際に使用する体外循環回路の補充液としての利用, 4) 酸素治療剤として, 虚血性疾患など局所的低酸素状態の改善薬としての利用, などがある^{7,8)}。

筆者らが開発したヘモグロビン小胞体 (HbV) は,

- 1) 早稲田大学理工学研究所
- 2) 慶應義塾大学医学部外科
- 3) 慶應義塾大学医学部病理学
- 4) 早稲田大学理工学術院
- 5) 東宝塚さとう病院

[受付日: 2006 年 10 月 5 日, 受理日: 2006 年 12 月 12 日]

期限切れ赤血球から精製した高純度高濃度ヒト Hb 溶液を脂質膜で被覆した微粒子構造をしている^{10,11}。赤血球と類似の細胞構造により、本来毒性を有する分子状 Hb と血管内皮細胞との直接的接触の回避が可能となる^{12,13}。血中に投与された HbV は、酸素運搬機能を終えた後、最終的に細網内皮系 (RES, Reticuloendothelial system) マクロファージに捕捉、分解されることが負荷投与試験から明らかになっている¹⁴⁻¹⁷。これまでに、HbV をヒト血漿由来のアルブミン或はリコンビナントアルブミン溶液 (rHSA) に分散させ、循環血液量の 80~90% を交換する極度の血液希釈試験、50% 脱血による出血性ショックモデルに対する蘇生試験等で、急性期において赤血球と同等の酸素運搬機能が実証されてきた¹⁸⁻²⁰。しかし、投与後数時間の観察に留まっておらず、中長期的な観察は充分になされていなかった。

そこで本研究では、HbV を rHSA 溶液に分散させた溶液を用い、臨床的に想定される 40% の血液交換をラットモデルを用いて行い、その後 2 週間に亘る観察を行った。血液生化学検査、血液学的検査、組織病理学的検査を行い、特に RES における HbV の代謝と Hct の回復過程について注目した。単回負荷投与、或は反復負荷投与の際には、肝臓よりも脾臓の肥大が顕著であり^{16,17}、更に、老化赤血球は脾臓にて捕捉代謝されることが知られているので²¹、本研究では、輸血モデルとして保存赤血球を投与した場合も実施し、脾臓への影響を比較検討した。

2. 材料・方法

2-1. rHSA に分散させた HbV の調製

HbV は無菌的条件下で、既報に従って調製した^{20,21}。精製ヒト Hb 溶液は、日本赤十字社から提供を受けた期限切れヒト赤血球より調製した。HbV は 38g/dL の Hb 溶液を内包している。アロステリック因子として pyridoxal 5-phosphate (PLP) を含有する (Sigma-Aldrich Co., St. Louis, MO, PLP : Hb = 2.5 : 1 by mol)。HbV の脂質膜には、1,2-dipalmitoyl-sn-glycero-3-phosphatidylcholine, cholesterol, 1,5-O-dihexadecyl-N-succinyl-L-glutamate (日本精化、大阪)、および 1,2-distearoyl-sn-glycero-3-phosphatidylethanolamine-N-PEG₂₀₀₀ (日本油脂、東京) が、5/5/1/0.033 の割合で存在している。エンドキシン含量は、リムルス法の変法により 0.1EU/mL 以下であることを確認した²²。物理化学的パラメータとして、酸素親和度 (P_{50}) が 27Torr、粒径 251 ± 81 nm、metHb 含量は 3% 以下であった。HbV 分散液 ([Hb] = 10g/dL) 8.6mL を rHSA 溶液 (25g/dL) 1.4 mL と混合し、HbV が分散している外液の rHSA 濃度を 5g/dL に調節した。従って、得られた HbV/rHSA の Hb 濃度は $8.6g/dL = 10g/dL \times 8.6 / (8.6 + 1.4)$ にな

る。このとき懸濁液浸透圧は 20Torr、粘度 2.9cP になる。

2-2. rHSA に分散させたラット保存血の調製

エーテル麻酔下、Wistar 系ラットの下大静脈から急速脱血した。ラット血液 10mL に対し、血液保存液 (CPDA-1, 川澄化学社製) を 1mL 加え、密封して 4°C にて 1 週間冷蔵保存した。報告によれば、1 週間保存したラット赤血球の脆弱性は、ヒト赤血球を同条件で 4 週間保存したものと同等になる²³。保存後、遠心分離 (4,000 g, 10min) して血清と白血球を除去し、再度生理食塩水を等量加えて遠心分離する操作を二回繰り返した。次いで 5g/dL の rHSA を添加して再分散させ、再度遠心分離して上澄みを除去し、rHSA を添加して Hb 濃度を 8.6g/dL に調節した (sRBC/rHSA)。

2-3. 血液交換試験と 2 週間の観察

Wistar 系ラット 65 匹を用いた (♂, $223 \pm 20g$)。ネンブタール (Abbot Laboratories, North Chicago, IL) を腹腔内投与し (1mL/kg) 麻酔状態とし、頸動脈にポリエチレン製カテーテル (SP31) を挿入した。1mL/30 sec の脱血と同量の試料溶液投与を繰り返して 40% の血液を交換した。試料溶液は、HbV/rHSA (HbV 群, $n=20$)、sRBC/rHSA (sRBC 群, $n=20$)、および rHSA 単独の投与 ($n=20$) である。ベースラインの値を知るため、5 匹のラットを使用した。

循環血液量は 56mL/kg 体重と推定し²⁴、これを維持しながら血液を交換すると仮定し、実験に必要な HbV 分散液の量を計算した。1.0mL の脱血と試料等投与を繰り返したと仮定すると、40% の血液交換は次式で示される。

$$40\% = 100 \times \{1 - [(0.056 \times \text{体重} - 1.0) / (0.056 \times \text{体重})]\} \quad (1)$$

総投与量は、 $n \times 1.0$ (mL) と計算できる²⁵。体重 220 g のラットの場合、必要量は 6.0mL になる。

血液交換終了後、カテーテルを外し、右頸動脈を結紮、切開部を縫合した。ラットはその後、ケージに入れ最長 14 日間生存させた。投与後 1, 3, 7, 14 日目に各群から 5 匹を選択し、1.5% セボフルレン吸入麻酔下、尾静脈より 24G-留置針 (ニプロ社製) を使用して採血 (150 μ L) し、ヘマトクリットと血球数測定を行った (Model KX-21, シスメックス、神戸)。開腹して下大静脈から採血し、血液生化学検査の検体とした。その後直ちに臓器を摘出し、10% ホルマリン中性リン酸溶液に浸漬固定し、パラフィン包埋した。4 μ m 厚の切片について、ヘマトキシリン-エオジン (H/E) 染色、ベルリンブルー染色、および、ギムザ染色を実施した。

脱血液 (約 6mL) を遠心分離 (5,000g, 10分) し、血漿を得た。HbV が血漿中に残存している場合 (1, 3 日後) には、更に超速心分離 (50,000g, 20分) によりこれを沈降分離し、透明な血漿層を測定検体とし、血

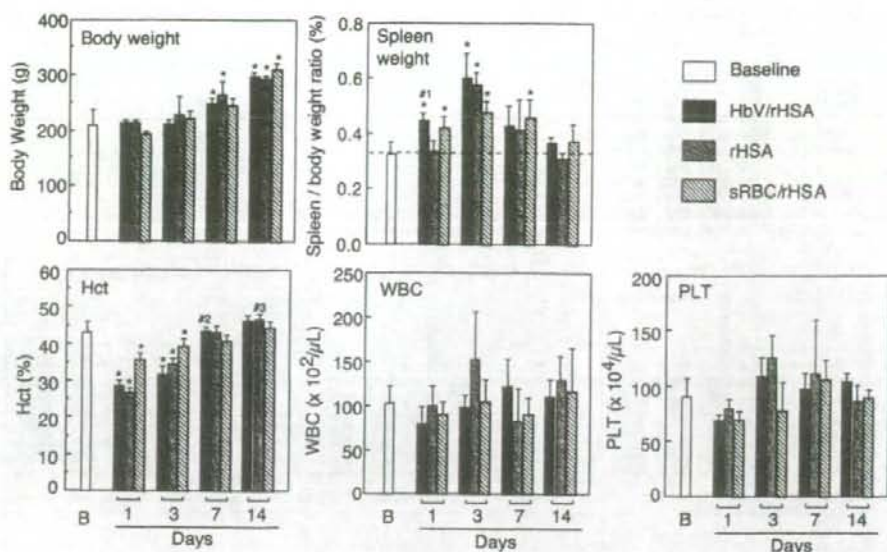


図1 40%血液交換後の体重、脾臓重量比、および血球数の変化。* $p < 0.01$ vs baseline; # $p < 0.01$ vs. rHSA 群; # $p = 0.0288$ vs. sRBC/rHSA; # $p = 0.0353$ vs. sRBC/rHSA. B: baseline. (From: Sakai et al. Transfusion 2006; 46: 339-347, Blackwell Publishing, Oxford, UK)

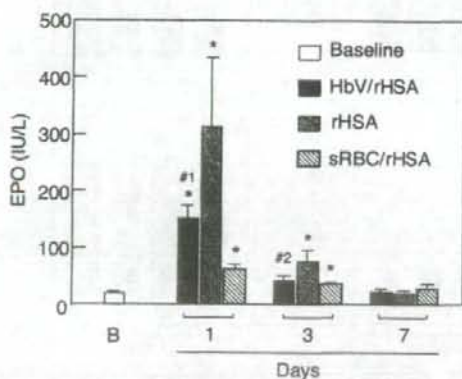


図2 40%血液交換後の血中エリスロポエチンの濃度変化。* $p < 0.01$ vs baseline; # $p = 0.0222$ vs. rHSA; # $p = 0.0195$ vs. rHSA. B: baseline. (From: Sakai et al. Transfusion 2006; 46: 339-347, Blackwell Publishing, Oxford, UK)

液生化学検査におけるHbVの干渉作用を排除した²⁾。得られた透明な血漿にはHbが含まれず、HbVの溶血が無いことを示した。血漿検体は検査まで -80°C にて凍結保存した。測定項目は、肝臓、腎臓機能等を反映する通常の検査項目のほか、エリスロポエチン(EPO)、およびHbVの分解排泄を反映すると考えられる脂質成分と、ビリルビン、遊離鉄等とした(BML社)。ラッ

トのエPOは、ヒトのエPOとの相溶性が高いので、抗ヒトEPO抗体での検出が可能であった²⁾。

動物実験は慶應義塾大学医学部動物実験委員会の承認を得て実施した。また、Guide for the Care and Use of Laboratory Animalの指針に従った²⁾。

2-4. 統計処理

結果は全て平均±標準偏差(SD)として記した。コントロール群と処置群の間の有意差検定には、Fisher's protected least significance difference testおよびone way ANOVA法を用いた。 p 値が0.01以下のときに有意な差と判定した。

3. 結果

3-1. 体重、脾臓重量、血液学的検査の結果

全群が40%交換輸血に耐え、犠牲死させるまで生存した。これは、5g/dLのrHSA溶液の使用により、膠質浸透圧と循環血液量を一定に保ち乍ら血液希釈を行ったことが理由として先ず考えられる。体重(約223g)は14日後には300g程度にまで成長した(図1)。立毛などの異常な症状は認められなかった。

体重に対する脾臓重量の変化では、HbV/rHSA群で特に、1、3日後に有意に増大していたが、14日後には正常値に復した。rHSA群では1日後には変化は無いが、3日後に急激に増大し、その後低下して14日後には正常値に復した。sRBC群はHbV群よりは程度は低いものの1日後から7日後まで脾臓肥大が見られた。

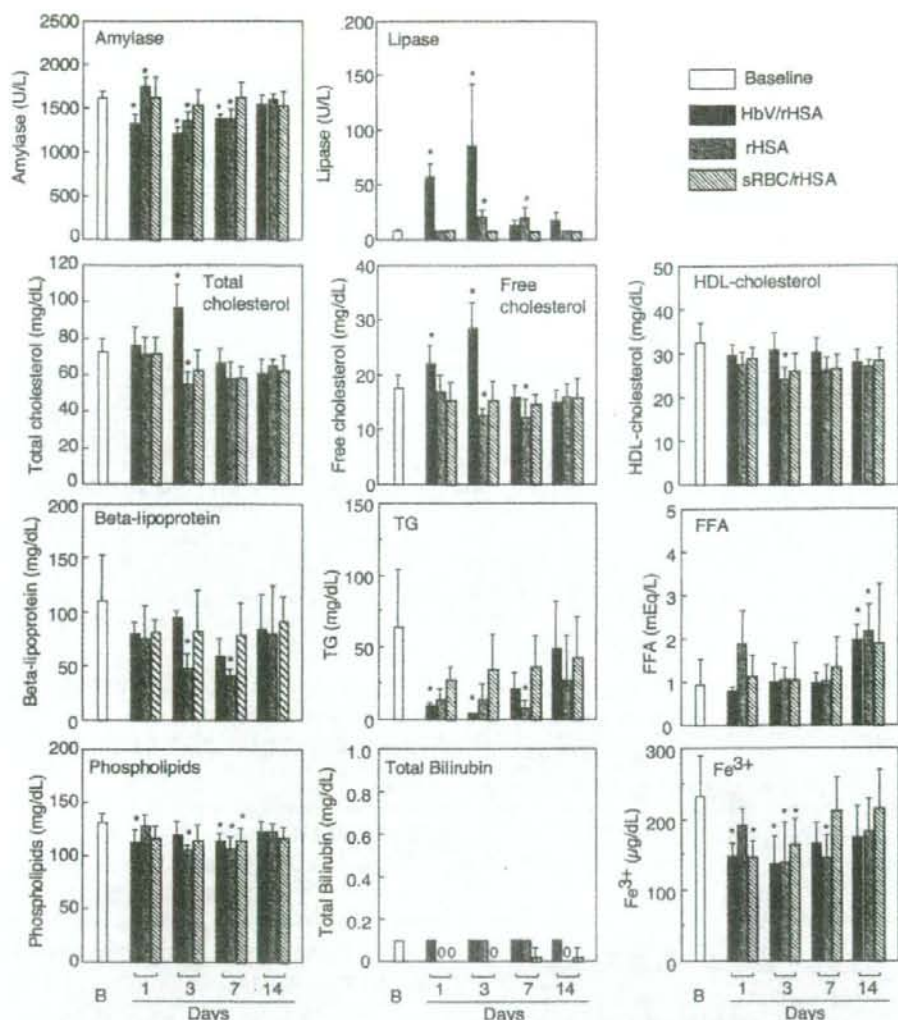


図3 40%血液交換後の血液生化学検査の結果。* $p < 0.01$ vs. baseline. Triglyceride, TG; free fatty acid, FFA; baseline, B. (From: Sakai et al. Transfusion 2006; 46: 339-347. Blackwell Publishing, Oxford, UK)

Hct値は、血液交換前は43%であったが、HbV/rHSA群およびrHSA群は、血液交換後Hct値が26%に低下した。7日後には交換前の値(43%)に復した。更に14日後には46%になり、交換前の値を超えた。sRBC/rHSA群では、投与後の値は高いが、7、14日後では他の二群に比較して低めの値を示した。平均赤血球ヘモグロビン量(MCH)、平均赤血球容積(MCV)、平均赤血球ヘモグロビン濃度(MCHC)に異常を認めなかった。但し、HbV/rHSA群では、1、3日後に血液中にHbVが残存しているため、測定不能であった。sRBC/rHSA群では、1日後のMCHおよびMCHCで低下傾向がみ

られた。Hct値とは対照的に、血小板数および白血球数は、安定した値を推移した。HbV由来の血漿中Hb濃度は、血液交換直後は4.4g/dLと想定され、その後、1、3、7日後に 1.8 ± 0.1 、 1.1 ± 0.1 、 0 g/dLに低下した。

3-2. 血液生化学検査

血中EPO値は、貧血、低酸素状態、ストレス等を反映する項目であり、血液交換前の 21 ± 3 IU/Lが、1日後にrHSA群が 321 ± 123 IU/Lを示し、これはHbV/rHSA群(153 ± 22)、sRBC/rHSA群(63 ± 7)よりも高値であった(図2)。しかし3日目には低下傾向にあり、7日後には処置前の値に復した。

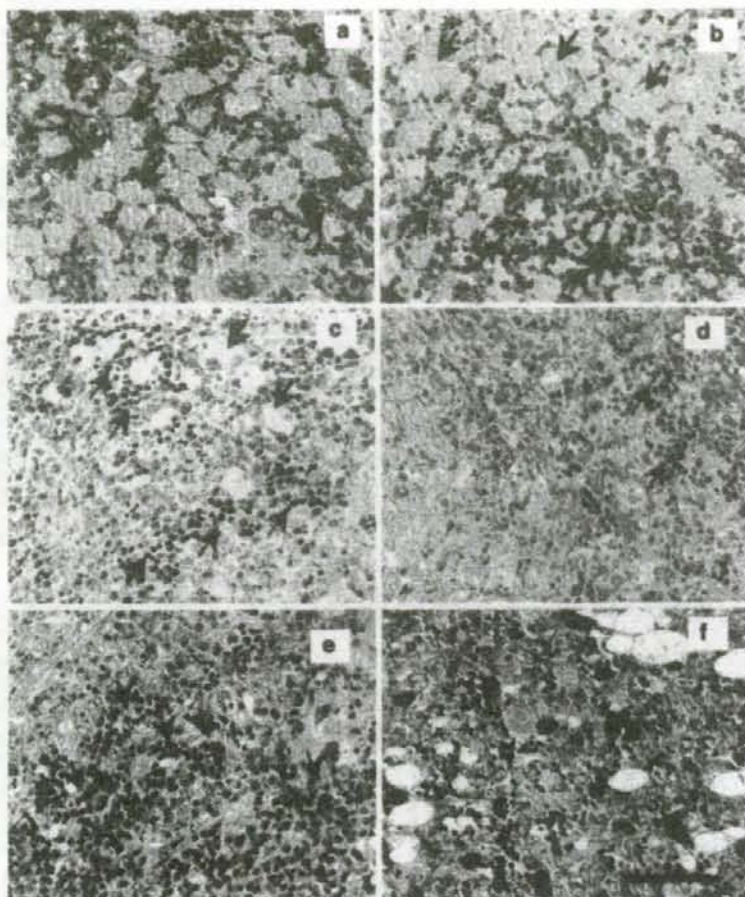


図4 HbV/rHSA 群およびrHSA 群の組織切片のギムザ染色像。(a),(b),(c)は、HbV/rHSA 群の1,3,7日後の脾臓。捕捉されたHbVは薄青色の領域(黒矢印)、赤芽球果は濃青色の細胞として確認される(赤矢印)。HbVは7日後には可成り減少する。(d) HbV/rHSA 群の14日後の脾臓。HbVは完全に消失した。(e) rHSA 群の3日目の脾臓。赤芽球果が多く認められる。(f) HbV/rHSA 群の3日目の骨髄にも濃青色の赤芽球が存在する。紫のスポットが点状する細胞は好塩基球と考えられる。スケールバーは50 μ m。(From: Sakai et al. Transfusion 2006; 46: 339-347, Blackwell Publishing, Oxford, UK)

その他、AST 値が1日目若干の上昇傾向を示したが(HbV/rHSA, 70 ± 5 U/L; rHSA, 69 ± 12 ; sRBC/rHSA, 72 ± 9 ; 正常値, 60 ± 7)、3日後には正常値に復した。ALT 値は特に変化は無かった。ALP および γ -GTP には多少の変動があった。CPK は安定していた。全群について、クレアチニン、尿酸は低値傾向を示した。アミラーゼに低下傾向が見られたが(図3)、HbV/rHSA 群のみ、リパーゼの上昇を認めたが、7日後には正常値に復した。脂質成分濃度については、HbV/rHSA 群で血中の総コレステロール、遊離コレステロールの亢進が3日後に見られたが、7日後には正常値に復した。 β -リポ蛋白、高密度リポ蛋白コレステロールは、血液交

換後に特にrHSA 群で低下傾向があった。トリグリセリドも全群で低下傾向にあり、特にHbV/rHSA 群で1, 3日後に顕著であった。これは、血漿を超遠心分離した際に分離されたことも一因と考えられた。リン脂質は全群で僅かに低下傾向にあった。遊離脂肪酸は14日後に増加傾向にあった。ビリルビン濃度(<0.1 mg/dL)は常に低値を推移した。遊離鉄濃度は低下傾向にあったが、14日後には血液交換前の値に復した。

3-3. 組織病理学的検討

全群において肺、心臓、腎臓等に著変を認めなかった。HbV/rHSA 群では1,3日後に肝臓のクッパー細胞、骨髄のマクロファージに捕捉されたHbVが観察された

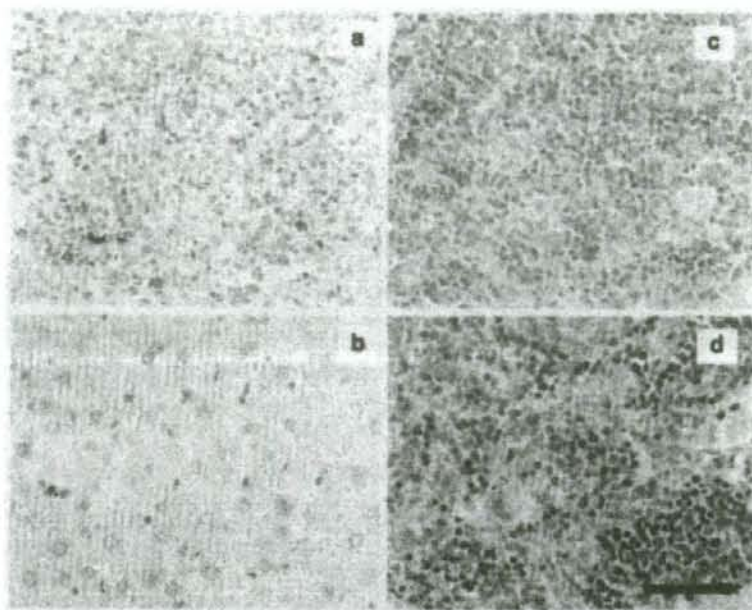


図5 HbV/rHSA 群およびsRBC/rHSA 群の14日後の組織切片のベルリンブルー染色像。HbV/rHSA 群の (a) 脾臓、(b) 肝臓、および (c) 骨髄、脾臓と肝臓にヘモジデリンが存在した。(d) sRBC/rHSA 群の脾臓にもヘモジデリンが検出された。スケールバーは50 μ m。(From: Sakai et al, Transfusion 2006; 46: 339-347, Blackwell Publishing, Oxford, UK)

が次第に減少し、14日後には消失した。HbV/rHSA 群では3日後に血中リパーゼの上昇が認められたが、脾臓に著変は認められなかった。HbV/rHSA 群の脾臓のギムザ染色では、1,3日後に赤脾髄に捕捉されたHbVが多く認められた。しかし7日後には減少し、14日後には消失していた(図4)。実験期間を通して脾索に赤芽球および前赤芽球の果(集合)が多く存在し、特に3,7日後で顕著であった。果の形成から、活発な髄外造血が伺えた。rHSA 群でも3日目に赤芽球果を多く認めた。骨髄での造血もHbV/rHSA 群で確認された。ベルリンブルー染色により、HbV/rHSA 群で7日後に脾臓にヘモジデリンが僅かに観測され、14日後に更に顕著になった(図5)。僅かに肝臓のクッパー細胞にも認められたが、骨髄には無かった。sRBC/rHSA 群では、14日後に脾臓にヘモジデリン沈着が観測された。

4. 考 察

本研究における重要な点は、HbV/rHSA 溶液により40%血液交換されて低下したHct値が、7日後には完全に回復したこと、また、14日までにRESに捕捉されたHbVがほぼ消失したことである。HbV 群の脾臓肥大は、赤脾髄へのHbVの捕捉と、EPO分泌に反応して強い造血作用により赤芽球果が脾索に多く存在する事に起因すると考えられた。しかし脾臓重量は14日後には

完全に回復していた。

これまでの放射化ラベルしたHbVの体内動態の研究から、HbVは最終的にRESに移行することが解っている^{11,16}。脾臓肥大の一因は、図4から解るように、HbVが赤脾髄に捕捉されることであるが、14日後には消失する。投与3日後までの血中コレステロールの緩やかな上昇、またHbVが血中では分解しない事実から、HbVがRESのマクロファージの食胞で捕捉分解されてからコレステロールが血中に遊離したものと考えられた^{11,12}。既報のHbV負荷投与試験の結果では、高密度リポ蛋白コレステロール、 β リポ蛋白、リン脂質の増大が、過剰量として血中に確認された^{12,17}。しかし、今回の40%交換輸血試験では、それらの上昇が見られず、むしろ低下する傾向もあった。従って大量の血液がHbV/rHSAで置換された場合には、HbVの脂質成分が体内で有効利用され、造血や成長に使用された可能性がある。

HbVが大量に投与され、その分解過程でヘム鉄やポルフィリンの分解物であるビリルビンが大量に遊離することを懸念したが、血中濃度の上昇は14日間全く見られなかった。Hbから放出されたヘムは、肝臓クッパー細胞や、脾臓マクロファージの誘導型ヘムオキシゲナーゼ-1の酵素分解を受け、ビリルビンに変化する^{18,19}。今回の実験から、HbVの大量投与に際してもビリルビンは通常の経路によって分解され、胆汁となって排泄さ

れること、また胆汁管排泄機能に影響が無いことが考えられた。ベルリンブルー染色では、14日後の肝臓と脾臓にヘモジデリン沈着が認められた。通常、ヘム由来の鉄はフェリチンとして蓄えられるが²⁰、鉄含量が多くなるとヘモジデリンになる。フェリチンもヘモジデリンも鉄イオンを遊離し、過酸化水素とのフェントン反応によりOHラジカルを産生し、これが脂質過酸化を助長する懸念がある²¹。しかし化学的には、不溶化沈着したヘモジデリンの方がフェリチンよりも不活性であるとの見方もある²²。一般的に輸血を頻回受ける患者では、保存赤血球の血中半減期が短いためRESに捕捉され、ヘモジデリンが多く認められる。本研究では、sRBC群でも緩慢ではあるが脾臓肥大とヘモジデリン沈着が認められた。保存血では老化赤血球のように赤血球の変形能が低下し脆弱となり、血中滞留時間が短くなり脾臓で捕捉、分解されることも原因の一つと考えられる²³。これらのことから、HbV由来のヘムの分解および鉄の貯蔵は、生理的許容範囲内であり、脆弱な保存赤血球の場合と同様の良く知られた生理的経路により行われていることが予想できた²⁴。

興味深い事に、脾臓肥大はHbV/rHSA群およびsRBC/rHSA群だけでなく、rHSA群で3日目に顕著であった。文献によると、ラットは低酸素状態に曝されると、髄外造血が脾臓で顕著になる^{25,26}。我々の実験では、rHSA群で特に3日目に大量の赤芽球様の存在を見出している。¹²⁵I-rHSAの体内動態に関する文献から^{27,28}、rHSAが異種蛋白質として脾臓に特異的に捕捉される可能性は低く、脾臓肥大との関係も無いと考えられる。従ってrHSA群の脾臓肥大は、EPO分泌によって髄外造血が活性化された為と考えられた。

腎臓から分泌されるEPOは、貧血の状態を強く反映する²⁹。rHSA群で投与1日後に最も高いEPO値を示し、酸素運搬量の低下により貧血状態が最も強かったことが伺える。次いでHbV/rHSA群が高値を示した。これはHbVの血中半減期が短い事と、酸素運搬機能の無いmetHbの含量が増大することに起因している³⁰。また、sRBC/rHSA群でも血液交換後にHctが低下しているため、EPO値の緩慢な上昇が確認された。従って、HbV/rHSA群およびsRBC/rHSA群の脾臓肥大のもう一つの要因として、造血過程における赤芽球様の存在があり、これがHctを1週間で回復させた原動力であると考えられる。興味深い事に、rHSA群、HbV/rHSA群の14日後のHct値は46%となり、sRBC群の値(43%)を上回っていた。これはEPO分泌量がrHSA群、HbV群がsRBC群よりも高く、造血が亢進されたため overshootingしたのかもしれない。MCH、MCV、MCHCが正常であったことも、造血作用に異常が無いことを支持している。

血液生化学検査では、HbVが大量に肝臓クッパー細胞に移行するにも関わらず、特に肝機能に影響が無いことを示唆した。HbVの投与によってリパーゼの上昇が既報の負荷投与試験も含め常に認められている。これは、HbVの成分である脂質によって、リパーゼの分泌が亢進したのかもしれない^{31,32}。

結論として、臨床でのHbVの使用を想定したラットへの投与試験(40%血液交換)に際し、ラットは全例が生存し、血液希釈により低下したHctは7日以内に回復した。一過性の脾臓肥大とヘモジデリン沈着が確認されたが、余剰な鉄イオンの遊離は認められなかった。HbVは脆弱な保存赤血球の場合と同様の生理的経路により、細網内皮系で捕捉代謝され、構成成分が支障無く排泄或は再利用される過程が予想された。まだ不明の点もあるが、HbVを輸血代替として使用する場合の安全性についての知見を得ることができた。

謝辞：試料調製を担当した宗慶太郎助教授、政田洋平氏(早稲田大学)、組織病理学的検討に際し染色を担当した阿部仁氏(慶應義塾大学医学部病理学教室)、また有益なご助言を頂きました末松誠教授(慶應義塾大学医学部医化学)、ならびに村田清教授(慶應義塾大学医学部臨床検査医学)に感謝申し上げます。リコンビナントアルブミンはニプロ社より提供を受けた。本研究の一部は、厚生労働科学研究費補助金(医薬品・臨床機器等レギュラトリーサイエンス総合研究事業)、日本学術振興会 科学研究費補助金(B16300162)、日本人工臓器学会JSAO-Grantにより推進された。また、(株)オキシジェニクスからの支援を受けた。記して謝意を表する。

文 献

- 1) Chang TMS: Hemoglobin based red blood cells substitutes. *Artif Organs*, 28: 789-794, 2004.
- 2) Buehler PW, Alayash AI: Toxicities of hemoglobin solutions: in search of in-vitro and in-vivo model systems. *Transfusion*, 44: 1516-1530, 2004.
- 3) Sakai H, Tomiyama K, Sou K, et al: Polyethyleneglycol-conjugation and deoxygenation enable long-term preservation of hemoglobin-vesicles as oxygen carriers in a liquid state. *Bioconjugate Chem*, 11: 425-432, 2000.
- 4) Lee R, Neya K, Svizzero TA, et al: Limitations of the efficacy of hemoglobin-based oxygen-carrying solutions. *J Appl Physiol*, 79: 236-242, 1995.
- 5) Johnson JL, Moore EE, Offner PJ, et al: Resuscitation with a blood substitute abrogates pathologic postinjury neutrophil cytotoxic function. *J Trauma*, 50: 449-456, 2001.
- 6) Standl T, Burmeister MA, Horn EP, et al: Bovine

- haemoglobin-based oxygen carrier for patients undergoing haemodilution before liver section. *Brit J Anesth*, 80: 189–194, 1998.
- 7) York GB, DiGeronimo RJ, Wilson BJ, et al: Extracorporeal membrane oxygenation in piglets using a polymerized bovine hemoglobin-based oxygen-carrying solution (HBOC-201). *J Pediatr Surg*, 37: 1387–1392, 2002.
 - 8) Contaldo C, Plock J, Sakai H, et al: Hemodilution with polymerized and encapsulated hemoglobins improves oxidative energy metabolism in collateralized hamster flap tissue. *Crit Care Med*, 33: 806–812, 2005.
 - 9) Nozue M, Lee I, Manning JM, et al: Oxygenation in tumors by modified hemoglobins. *J Surg Oncol*, 62: 109–114, 1996.
 - 10) Djordjevic L, Mayoral J, Miller IF, et al: Cardiorespiratory effects of exchanging transfusions with synthetic erythrocytes in rats. *Crit Care Med*, 15: 318–323, 1987.
 - 11) Awasthi VD, Garcia D, Klipper R, et al: Neutral and anionic liposome-encapsulated hemoglobin: effect of postinserted poly (ethylene glycol)-distearylphosphatidylethanolamine on distribution and circulation kinetics. *J Pharmacol Exp Ther*, 309: 241–248, 2004.
 - 12) D'Agostino F, Alayash AI: Redox cycling of diaspirin cross-linked hemoglobin induces G2/M arrest and apoptosis in cultured endothelial cells. *Blood*, 98: 3315–3323, 2001.
 - 13) Sakai H, Hara H, Yuasa M, et al: Molecular dimensions of Hb-based O₂ carriers determine constriction of resistance arteries and hypertension in conscious hamster model. *Am J Physiol Heart Circ Physiol*, 279: H908–H915, 2000.
 - 14) Sakai H, Horinouchi H, Tomiyama K, et al: Hemoglobin-vesicles as oxygen carriers: influence on phagocytic activity and histopathological changes in metabolism. *Am J Pathol*, 159: 1079–1088, 2001.
 - 15) Sakai H, Masada Y, Horinouchi H, et al: Physiologic capacity of reticuloendothelial system for degradation of hemoglobin-vesicles (artificial oxygen carriers) after massive intravenous doses by daily repeated infusions for 14 days. *J Pharmacol Exp Ther*, 311: 874–884, 2004.
 - 16) Sou K, Klipper R, Gains B, et al: WT. Circulation kinetics and organ distribution of Hb-vesicles developed as a red blood cell substitute. *J Pharmacol Exp Ther*, 312: 702–709, 2005.
 - 17) Sakai H, Horinouchi H, Masada Y, et al: Metabolism of hemoglobin-vesicles (artificial oxygen carriers) and their influence on organ functions in a rat model. *Biomaterials*, 25: 4317–4325, 2004.
 - 18) Cabrales P, Sakai H, Tsai AG, et al: Oxygen transport by low and normal oxygen affinity hemoglobin vesicles in extreme hemodilution. *Am J Physiol Heart Circ Physiol*, 288: H1885–H1892, 2005.
 - 19) Yoshizu A, Izumi Y, Park S, et al: Hemorrhagic shock resuscitation with an artificial oxygen carrier, hemoglobin vesicle, maintains intestinal perfusion and suppresses the increase in plasma tumor necrosis factor- α . *ASAIO J*, 50: 458–463, 2004.
 - 20) Sakai H, Takeoka S, Park SL, et al: Surface-modification of hemoglobin vesicles with polyethyleneglycol and effects on aggregation, viscosity, and blood flow during 90%-exchange transfusion in anesthetized rats. *Bioconjugate Chem*, 8: 15–22, 1997.
 - 21) Sakai H, Masada Y, Horinouchi H, et al: Hemoglobin-vesicles suspended in recombinant human serum albumin for resuscitation from hemorrhagic shock in anesthetized rats. *Crit Care Med*, 32: 539–545, 2004.
 - 22) Landaw SA: Factors that accelerate or retard red blood cell senescence. *Blood Cells*, 14: 47–69, 1988.
 - 23) Sou K, Endo T, Naito Y, et al: Efficient up-scale production of hemoglobin-vesicles (HbV) using the freeze-thawing and rapid extrusion. *Biotechnol Progr*, 19: 1547–1552, 2003.
 - 24) Sakai H, Yuasa M, Onuma H, et al: Synthesis and physicochemical characterization of a series of hemoglobin-based oxygen carriers: objective comparison between cellular and acellular types. *Bioconjugate Chem*, 11: 56–64, 2000.
 - 25) Sakai H, Hisamoto S, Fukutomi I, et al: Detection of Lipopolysaccharide in hemoglobin-vesicles by Limulus amoebocyte lysate test with kinetic-turbidimetric gel clotting analysis and pretreatment with a surfactant. *J Pharm Sci*, 93: 310–321, 2004.
 - 26) d'Almeida MS, Jagger J, Duggan M, et al: A comparison of biochemical and functional alterations of rat and human erythrocytes stored in CPDA-1 for 29 days: implications for animal models of transfusion. *Transfus Med*, 10: 291–303, 2000.
 - 27) Izumi Y, Sakai H, Hamada K, et al: Physiologic responses to exchange transfusion with hemoglobin vesicles as an artificial oxygen carrier in anesthetized rats: changes in mean arterial pressure and renal cortical tissue oxygen tension. *Crit Care Med*, 24: 1869–1873, 1996.
 - 28) Sakai H, Tsai AG, Kerger H, et al: Subcutaneous microvascular responses to hemodilution with a red cell substitute consisting of polyethyleneglycol-modified vesicles encapsulating hemoglobin. *J Biomed Mater Res*,

- 40: 66—78, 1998.
- 29) Sakai H, Tomiyama K, Masada Y, et al: Pretreatment of serum containing Hb-vesicles (oxygen carriers) to avoid interference in clinical laboratory tests. *Clin Chem Lab Med*. 41: 222—231, 2003.
- 30) Wen D, Boissel JP, Tracy TE, et al: Erythropoietin structure-function relationships: high degree of sequence homology among mammals. *Blood*. 82: 1507—1516, 1993.
- 31) Braggins PE, Trakshel GM, Kutty RK, et al: Characterization of two heme oxygenase isoforms in rat spleen: comparison with the hematin-induced and constitutive isoforms of the liver. *Biochem Biophys Res Commun*. 141: 528—533, 1986.
- 32) Finch CA, Huebers H: Perspectives in iron metabolism. *New Engl J Med*, 306: 1520—1528, 1982.
- 33) Grady JK, Chen Y, Chasteen ND, et al: Hydroxyl radical production during oxidative deposition of iron in ferritin. *J Biol Chem*, 264: 20224—20229, 1989.
- 34) O'Connell MJ, Ward RJ, Baum H, et al: Iron release from haemosiderin and ferritin by therapeutic and physiological chelators. *Biochem J*, 260: 903—907, 1989.
- 35) Bennett GD, Kay MM: Homeostatic removal of senescent murine erythrocytes by splenic macrophages. *Exp Hematol*. 9: 297—307, 1981.
- 36) Ou LC, Kim D, Layton WM Jr, et al: Splenic erythropoiesis in polycythemic response of the rat to high-altitude exposure. *J Appl Physiol*. 48: 857—861, 1980.
- 37) Stutte HJ, Sakuma T, Falk S, et al: Splenic erythropoiesis in rats under hypoxic and post-hypoxic conditions. *Virchows Arch A Pathol Anat Histopathol*. 409: 251—261, 1986.
- 38) Okano K, Sogame Y, Ohkubo M, et al: Metabolic fate of recombinant human serum albumin (rHSA) (2). *Jpn Pharmacol Ther (Yakuri tou Chiryou)*. 25 (Suppl): 2007—2018, 1987.
- 39) Baynes JW, Thorpe S: Identification of the sites of albumin catabolism in the rat. *Arch Biochem Biophys*. 206: 372—379, 1981.
- 40) Eckardt KU, Koury ST, Tan CC, et al: Distribution of erythropoietin producing cells in rat kidneys during hypoxic hypoxia. *Kidney Int*. 43: 815—823, 1993.
- 41) Hughes GS Jr, DeSmith VL, Locker PK, et al: Phlebotomy of 500 or 750 milliliters of whole blood followed by isovolemic hemodilution or autologous transfusion yields similar hemodynamic, hematologic, and biochemical effects. *J Lab Clin Med*. 123: 290—298, 1994.
- 42) Teramura Y, Kanazawa H, Sakai H, et al: Prolonged oxygen-carrying ability of hemoglobin vesicles by coencapsulation of catalase in vivo. *Bioconjugate Chem*. 14: 1171—1176, 2003.
- 43) Stuecklin-Utsch A, Hasan C, Bode U, et al: Pancreatic toxicity after liposomal amphotericin B. *Mycoses*. 45: 170—173, 2002.

ACUTE 40 PERCENT EXCHANGE-TRANSFUSION WITH HEMOGLOBIN-VESICLES (HBV) SUSPENDED IN RECOMBINANT HUMAN SERUM ALBUMIN SOLUTION: DEGRADATION OF HBV AND ERYTHROPOIESIS IN A RAT SPLEEN FOR 2 WEEKS

Hiromi Sakai¹⁾, Hirohisa Horinouchi²⁾, Manabu Yamamoto³⁾, Eiji Ikeda³⁾, Shinji Takeoka⁴⁾, Masuhiko Takaori⁵⁾, Eishun Tsuchida¹⁾ and Koichi Kobayashi²⁾

¹⁾Advanced Research Institute for Science and Engineering, Waseda University

²⁾Department of Surgery, School of Medicine, Keio University

³⁾Department of Pathology, School of Medicine, Keio University

⁴⁾Faculty of Science and Engineering, Waseda University

⁵⁾East Takarazuka Sato Hospital

Keywords:

Artificial Blood, Artificial Oxygen Carriers, Artificial Red Cells, Liposome, Plasma Substitutes

©2007 The Japan Society of Transfusion Medicine and Cell Therapy

Journal Web Site: <http://yuketsu.gr.jp>

マイクロサンプリング法

渡辺真純¹；小林紘一¹；石坂彰敏²

索引用語 — 気管支鏡, マイクロサンプリング法, 気道上皮被覆液

(気管支鏡, 2007;29:309-313)

Bronchoscopic Microsampling Method

Masazumi Watanabe¹; Koichi Kobayashi¹; Akitoshi Ishizaka²

KEY WORDS — Bronchoscopy, Microsampling method, Epithelial lining fluid

(JJSRE, 2007;29:309-313)

はじめに

従来より肺内の生化学情報や細胞成分を分析する方法として気管支肺胞洗浄 (BAL: Bronchoalveolar lavage) などが用いられている。しかしながら BAL により血液ガスの悪化や原疾患の増悪などが生じることがあり、反復して施行することは通常困難であった。また、限局性疾患における BAL の有効性は疑問視されている。近年 BAL 以外の方法として呼気凝縮液 (EBC: Exhaled breath condensate) 分析なども行われる。気管支鏡を用いないため低侵襲で有意義な方法であるが、測定可能な項目が限定されることや部位別の採取ができないことなどから、現状で主な適応は炎症性気道疾患などに限られている。

一方、これらの問題点を解決するべく BAL よりも低い侵襲で気道上皮被覆液 (ELF: Epithelial lining fluid) を採取することができる気管支鏡下マイクロサンプリング (BMS: Bronchoscopic microsampling) 法が考案され、各種肺疾患の診断、病態解析などに利用されている^{1,2}。また最近では、ELF 中の薬剤濃度測定³、細菌の検出⁴、プロテオーム解析⁵にも応用されている。BAL との比較で採取される検体量は少ないが、侵襲が低いことからマイクロサンプリング法と命名された。

マイクロサンプリング法とは

マイクロサンプリング法は気管支肺胞領域の ELF を採取し、生化学情報などを得る方法として開発された。現在は医療用具として認可を受けたマイクロサンプリングプローブTM (BC-401C および BC-402C, オリンパス社製) のうち細径である BC-401C を主に使用している。このプローブはポリエチレン製の外筒と、吸水性の高いポリエステル製ファイバーストックを先端に装着した内筒よりなる。そのスペックを表 1 に示す。先端部の外観を図 1 に示す。2.0 mm の気管支鏡チャンネルから挿入し先端ロッド部に ELF を吸収し採取する。BC-401C では 10~20 μ l 程度の ELF が採取される。

表 1. マイクロサンプリングプローブの仕様

		BC-401C	BC-402C
内視鏡挿入部	最大外径	1.8 mm	2.5 mm
	有効長	1050 mm	
吸収部	外径	1.1 mm	1.9 mm
	長さ	30 mm	20 mm
使用可能な内視鏡	有効長	600 mm 以下の BF	
	チャンネル径	2 mm 以上	2.6 mm 以上

慶應義塾大学医学部 ¹呼吸器外科, ²呼吸器内科。
著者連絡先: 渡辺真純, 慶應義塾大学医学部呼吸器外科, 〒160-8582 東京都新宿区信濃町 35。

¹Department of General Thoracic Surgery, ²Department of Internal Medicine, School of Medicine, Keio University, Japan.

Correspondence: Masazumi Watanabe, Department of General

Thoracic Surgery, School of Medicine, Keio University, 35 Shinanomachi, Shinjuku, Tokyo 160-8582, Japan.

© 2007 The Japan Society for Respiratory Endoscopy
第 19 回気管支鏡セミナーで「マイクロサンプリング法」として講演されたものである。