

表 1 拘禁反応 19 症例の特徴

発症	入所	刑期	主な罪名	IQ	学歴	家庭環境	依存性 薬物	精神科 通院歴	症状	タイプ	転帰	併記病名
1	23歳	初犯	36カ月	傷害致死	83	大退	祖父を殺害	-	うつ病	妄想	不変	幻覚妄想状態
2	23歳	初犯	78カ月	強盗, 強姦	68	中卒	両親離婚	+	なし	朦朧	軽快	幻覚妄想状態, 解離性障害
3	27歳	2回	24カ月	強制わいせつ	78	中卒	両親離婚	-	なし	原始	寛解	統合失調症の疑い
4	27歳	2回	22カ月	窃盗	37	中卒	特になし	-	なし	神経症	寛解	精神遅滞
5	28歳	初犯	48カ月	強盗	80	中卒	特になし	-	うつ病	原始	軽快	躁うつ病の疑い
6	29歳	2回	36カ月	強盗	75	中卒	両親離婚	-	強迫神経症	変調	不変	なし
7	29歳	2回	14カ月	窃盗	60	高退	両親離婚	+	なし	神経症	軽快	てんかん疑い, 覚醒剤後遺症疑い
8	30歳	初犯	10カ月	器物破損	70	高退	姉が前科あり	-	なし	妄想	不変	発達障害の疑い
9	31歳	2回	24カ月	傷害	46	中卒	両親離婚	+	不眠, 不安	神経症	不変	精神遅滞
10	31歳	初犯	10カ月	詐欺, 窃盗	45	中卒	特になし	-	てんかん	朦朧	不変	精神遅滞, てんかん
11	33歳	初犯	96カ月	放火未遂, 詐欺	92	大退	特になし	-	なし	妄想	軽快	なし
12	35歳	3回	108カ月	強制わいせつ致傷	64	中卒	特になし	-	なし	妄想	軽快	妄想性障害疑い
13	37歳	6回	24カ月	常習累犯窃盗	53	中卒	元暴走族員	+	なし	妄想	不変	精神遅滞
14	37歳	2回	14カ月	窃盗	78	中卒	父自殺, 遺伝要因	+	なし	神経症	寛解	うつ状態
15	40歳	5回	22カ月	覚醒剤取締り法違反	99	高退	特になし	+	薬物依存症	神経症	寛解	覚醒剤後遺症疑い
16	42歳	7回	24カ月	常習累犯窃盗	70	中卒	父がアル中	-	なし	妄想	不変	精神遅滞
17	42歳	4回	72カ月	殺人未遂	37	中卒	特になし	+	なし	神経症	軽快	精神遅滞
18	51歳	初犯	66カ月	強盗, 強姦未遂	59	大卒	特になし	-	うつ状態	朦朧	不変	うつ状態
19	55歳	13回	14カ月	詐欺	45	中卒	両親と生き別れ	+	なし	妄想	軽快	統合失調症疑い

b) 拘禁神経症 (n=6)

体に限局した痛みや違和感、疲労感、倦怠感などの不定愁訴の多いタイプ。最も頻繁に認められる。

c) 反応性朦朧状態 (n=3)

Ganser症候群と拘禁性ヒステリーが代表的であり、何らかの意味で意図的な傾向が前面に表出するタイプ。原始反応と詐病の中間状態と考えられている。

d) 原始反応 (n=2)

憤怒発作や極度の混乱など感情の爆発や昏迷を呈するタイプ。発作的に自傷行為を行うこともある。

e) 反応性気分変調 (n=1)

反応性うつ状態、躁状態を含む。うつ状態では、意気消沈し、面会を避け、緘黙を呈することもある。死刑囚では、反応性躁状態がみられ、笑いながら泣いたりすることもある。

【治療効果】治療効果は、軽快・不変の2カテゴリーとした。

【IQと学歴】IQは、35～50を精神遅滞、50～70を軽度遅滞、70～80を境界域、80以上を正常の4カテゴリーとした。学歴は、中卒・高校中退・高卒・大学以上(大学退学、卒業)の4カテゴリーとした。

【発症年齢】発症年齢は、20代・30代・40代以上の3カテゴリーとした。

【精神科通院歴・依存性薬物使用・両親問題】精神科通院歴は、通院・未通院を2カテゴリーとした。依存性薬物使用は、使用・未使用の2カテゴリーとした。両親問題は、あり(両親離婚、父親自殺、両親と生き別れ)・なしの2カテゴリーとした。

【懲役刑期・入所回数】懲役刑期は、1年未満・1～2年・2～3年・3年以上の4カテゴリーとした。また、入所回数は、初犯・2回・3回以上の3カテゴリーとした。

4 結果

1. オブジェクトスコアによる2つの次元へのカテゴリー負荷

各カテゴリーが2つの次元に分類された等質性

表2 10項目をカテゴリー変数とした等質性分析の結果

カテゴリー変数	カテゴリー	人数	オブジェクトスコア	
			次元1	次元2
タイプ	妄想	7	-0.473	0.673
	朦朧	3	-1.033	-0.037
	原始反応	2	0.94	-1.695
	神経症	6	1.054	0.165
	気分変調	1	-0.103	-2.2
治療効果	軽快	11	0.443	0.008
	不変	8	-0.61	-0.011
IQ	正常	4	-0.712	0.114
	境界	5	0.229	-0.612
	軽度遅滞	5	-0.081	0.238
	精神遅滞	5	0.422	0.464
最終学歴	中卒	13	0.259	-0.12
	高退	3	0.454	0.416
	高卒	0	0	0
	大学以上	3	-1.578	0.102
発症年齢	20代	7	0.115	-0.987
	30代	7	-0.185	0.309
	40代以上	5	0.098	0.948
精神科通院歴	通院	7	-0.549	-0.422
	未通院	12	0.32	0.246
依存性薬物	使用	8	0.766	0.392
	未使用	11	-0.557	-0.285
両親問題	あり	7	0.544	-1.037
	なし	12	-0.317	0.605
懲役刑期	1年未満	2	-1.091	0.353
	1～2年	5	1.113	0.349
	2～3年	4	0.4	-0.72
	3年以上	8	-0.623	0.27
入所回数	初犯	7	-1.082	-0.169
	2回	6	0.915	-0.866
	3回以上	6	0.348	1.063

分析の結果を表2に示した。すべての項目は次元1と次元2の2つの軸において、正または負のカテゴリー負荷を示している。表2においてそれぞれの軸に対して大きく負荷している主な項目を表3に示した。そして次元1をX軸、次元2をY軸とし、平面状にオブジェクトスコアをプロットし散布図を作成した(図1)。視覚的に近接あるいは対立している項目に注目した。

次元1(散布図上X軸)は、「拘禁神経症」が正、「反

表3 2つのオブジェクトスコアに対する各項目のカテゴリー-負荷

次元1	
正に負荷	神経症(1.054), 治療効果軽快(0.443), 精神遅滞(0.422), 中卒(0.259), 高校中退(0.454) 精神科通院歴なし(0.32), 依存性薬物使用あり(0.766), 両親問題あり(0.544)
負に負荷	朦朧(-1.033), 治療効果不変(-0.610), IQ正常(-0.712), 大学以上(-1.578) 精神科通院歴あり(-0.548), 依存性薬物使用なし(-0.557), 両親問題なし(-0.317)
次元2	
正に負荷	妄想(0.673), 30代発症(0.309), 40代以上発症(0.948), 両親問題なし(0.605), 入所3回以上(1.063)
負に負荷	原始反応(-1.695), 気分変調(-2.200), 20代発症(-0.987), 両親問題あり(-1.037), 初犯(-0.169), 入所2回(-0.866)

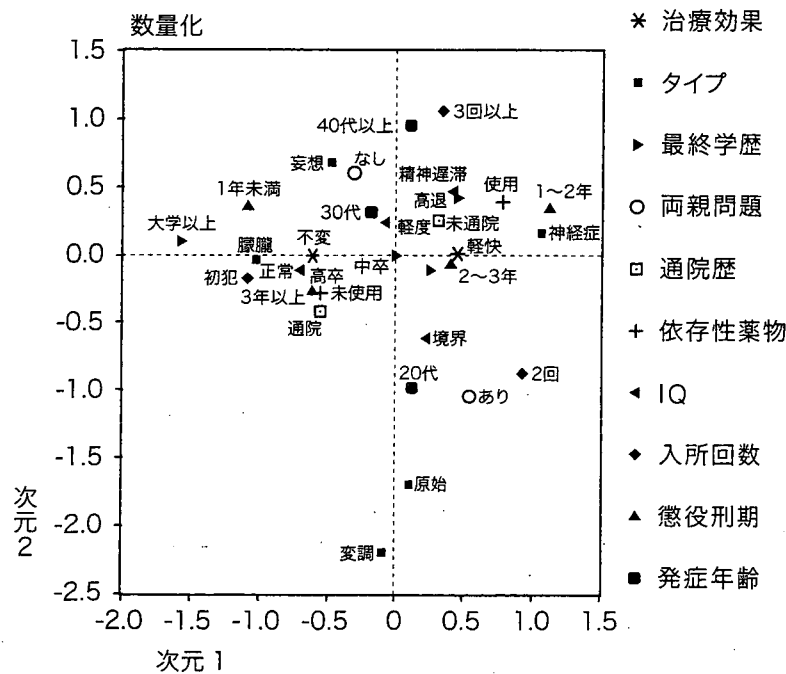


図1 等質性分析の散布図

応性朦朧状態」が負のカテゴリー-負荷を示した。また、治療効果では、「軽快」が正、「不変」が負のカテゴリー-負荷を示した。IQと学歴のカテゴリー項目では、「精神遅滞」、「中学卒業」、「高校中退」が正、「IQ正常」、「大学以上」が負のカテゴリー-負荷を示した。さらに、精神科通院歴・依存性薬物使用歴・両親問題のカテゴリー項目では、「精神科通院なし」、「依存性薬物使用歴あり」、「両親問題あり」が正、「精神科通院歴あり」、「依存性薬物使用歴なし」、「両親問題なし」が負のカテゴリー-負荷を示した。

一方、次元2(散布図上Y軸)は、「反応性妄想

状態」が正、「原始反応」と「反応性気分変調」が負のカテゴリー-負荷を示した。また、発症年齢のカテゴリー項目では、「30代」、「40代以上」が正、「20代」が負のカテゴリー-負荷を示した。そして、両親問題のカテゴリー項目では、「両親問題なし」が正、「両親問題あり」が負のカテゴリー-負荷を示した。さらに、入所回数では、「3回以上」が正、「初犯」、「2回」が負のカテゴリー-負荷を示した。

2. カテゴリー-負荷による2つの次元の解釈

上述の結果から、次元1は、拘禁反応のタイプにおける拘禁神経症と反応性朦朧状態の対立を示す軸と解釈した。さらに、治療効果、IQ、精神

科通院歴、依存性薬物の使用歴、両親問題における対立軸をなすと解釈できた。

一方、次元2は、拘禁反応のタイプでは反応性妄想状態と原始反応・反応性気分変調の対立軸と解釈できた。また発症年齢、両親問題、入所回数との関係を表す軸であると解釈できた。

3. カテゴリー数量化した10項目の類似度の検討

オブジェクトスコアの散布図(図1)に示したとおり、「反応性妄想状態」のカテゴリーは「40代以上発症」、「両親問題なし」のカテゴリーに近接した。

「拘禁神経症」のカテゴリーは、「治療効果あり」、「依存性薬物使用歴あり」、「懲役刑期1~2年」のカテゴリーに近接した。また、同じ第1象限には、「精神遅滞」、「高校退学」、「精神科通院歴なし」が位置した。

「反応性朦朧状態」は、「治療効果なし」、「IQ正常」、「学歴が大学以上」、「初犯」のカテゴリーに近接した。

「原始反応」と「反応性気分変調」のカテゴリーは、それぞれ近接し、さらに、「20代発症」、「両親問題あり」のカテゴリーにも近接した。

5 考察

1. 拘禁反応の診断について

拘禁反応はICD-10に則って診断すれば、F43重度ストレス反応および適応障害、F44解離性(転換性)障害、F45身体表現性障害、F23急性一過性精神病性障害などが候補にあげられる¹⁾。しかし、実際には、疾病利得の問題が関係し、常に虚偽性障害や詐病の鑑別が必要となる。この病状に対する修飾は拘禁着色と呼ばれ¹⁷⁾、病状を複雑にしている。また、拘禁反応として移送されてくる症例の中には、人格障害者や薬物中毒後遺症例が含まれていることがある。物質関連疾患は、しかるべき診断を受け、当施設に移送されることは少ないが、本研究の対象19例の中に、依存性薬物の使用者が8例含まれていた。また刑事施設内ではよくみられる“処遇困難者”がこの“拘禁反応”という病名がつけられ移送となる場合もあり注意が必

要である。本邦で歴史の古い北九州医療刑務所では、刑務作業や集団処遇に適応せず処遇困難となり移送されてくるケースも多いため、気分変調症や神経症圏内の症例では、躁うつ病以外は拘禁反応という診断はなさずに、入所した場合にも早期に還送している¹⁰⁾。

2. 拘禁神経症と反応性朦朧状態の対立関係について

拘禁神経症は小木の報告のとおり拘置所では一番頻繁にみられるタイプである。今回の結果で拘禁神経症は治療効果軽快と近接しており、たとえ既決後に症状が持続していても寛解を得ることが可能であると考えられた。またこの群は一般的に自然軽快や初期治療で改善されるとされる拘禁反応群と同じ疾患群であると推察された。拘禁神経症のカテゴリーは、依存性薬物使用ありのカテゴリーにも近接しており、当所においても薬剤中毒後遺症例を含んでいる可能性が示唆された。また精神遅滞と同じ第1象限に位置しており、施設の規律や医療の説明に理解を示さず、身体的な不定愁訴として表現する群も含んでいると推察された。

それに対し、反応性朦朧状態は、治療効果が得られにくい結果であった。この群はIQ正常で最終学歴も大学以上と高く、初犯のカテゴリーと近接していることから、犯罪傾向が進んでない群であった。しかし同じ第3象限に、精神科通院歴ありのカテゴリーが位置しており、背景に何らかの精神疾患を伴い、症状が遷延化する可能性が考えられた。この結果は、反応性朦朧状態の代表であるGanser症候群ないしGanser状態^{3,5,13-15,20,23)}では、症状が軽快したとする報告^{13-15,20,21,23)}と矛盾する結果であった。しかし一部には症状が遷延化するという報告もあり^{1,13)}、中田¹⁴⁾は、未決拘禁者では、拘禁が続く限り、Ganser症候群が長期にわたることもあるとしている。

3. 反応性妄想状態と原始反応・反応性気分変調の対立関係について

今回の対象では、反応性妄想状態は19例中7例(36.8%)にみられ最多であった。村田ら^{11,12)}は、既決囚の拘禁反応では、反応性妄想状態が6割を占めたと報告し、福島⁴⁾の受刑者の中に慢性の幻

覚妄想状態が多く認められたという報告とも一致した。本研究の結果では、反応性妄想状態のカテゴリーは、40代以上発症、両親問題なしのカテゴリーに近接した。発育、生育歴に環境的要因は少なく、情動面では十分成熟していると考えられる年齢であることから、反応性妄想状態を呈した群は、高齢発症で、心因的要因の少ない群と解釈でき、いわゆる“拘禁精神病”といわれている群と推察された²²⁾。

それに対し、原始反応や気分変調のカテゴリーは、20代発症、両親問題ありのカテゴリーに近接していた。この群は若年発症で環境的にも恵まれず、情動的に不安定となりやすい要素が含まれ、心因的要因が多い群と解釈できた。稲村⁶⁾は、拘禁性心因反応と診断された症例の1/6以上に、拘禁中の自殺企図を認めたと報告しており、原始反応を呈する症例の中では、発作的な自傷行為を行うことがあり注意が必要であると考えられた。

4. 反応性朦朧状態と反応性妄想状態の関係について

小木は¹⁷⁾、反応性朦朧状態の後に、妄想が出現することが多いことから、反応性朦朧状態が妄想成立の土壌の役割を担う可能性を示した。このことは、Ganser症候群の一部は遷延化することや、長期にわたる妄想状態は軽快しない例も多いという朴ら²⁾の報告と一致している。今回の結果でも、反応性朦朧状態と反応性妄想状態のカテゴリーは、小木の分類による他のカテゴリーと比べ、比較的接近し、次元1では負の領域に位置した。すなわち、反応性朦朧状態と反応性妄想状態は、ともに、知的な要因や心因的要因に関係せず、背景に何らかの精神疾患がある可能性が示唆される疾患群であり、病態として連続している可能性が考えられた。また治療効果が得られにくい傾向を示しており、拘禁のまま治療を行うのであれば、密な精神的または身体的なケアが必要であると考えられた。

6 結語

1) 拘禁神経症は、既決後に症状が持続していても治療効果が得られる傾向がみられた。

2) 反応性妄想状態は、高齢発症で心因的要因が少ない群と考えられるのに対し、原始反応・反応性気分変調は、若年発症で心因的要因が多い群と考えられた。

3) 反応性朦朧状態と反応性妄想状態は、疾患群として連続している可能性が示唆された。

本研究の19例という対象数は、多変量解析を用いて議論するにはあまりに少ない。しかし、既決後も症状が持続する拘禁反応は非常に特殊な症例であり、わずか19症例であっても、多変量解析することに意味があると考え、今回報告した。本研究は、あくまでpilot的な研究であり、今後、少しでも対象数を増やし、再度報告したいと考えている。

文献

- 1) 阿部恵一郎：拘禁反応。松下正明，山内俊雄，山上 皓ほか編：司法精神医学 2，刑事事件と精神鑑定。中山書店，東京，pp240-248，2006
- 2) 朴 光則，山上 皓：拘禁反応。松下正明，浅井昌弘，牛島定信ほか編：臨床精神医学講座，第19巻，司法精神医学・精神鑑定。中山書店，東京，pp361-369，1998
- 3) Dwyer J, Reid S : Ganser's syndrome. Lancet 364 : 471-473, 2004
- 4) 福島 章：拘禁反応。懸田克躬，大熊輝雄，鳥菌安雄ほか編：現代精神医学大系 6B。中山書店，東京，pp115-141，1978
- 5) Ganser S : Ueber einen eigenartigen hysterischen Dammerzustand. Arch Psychiat 30 : 633-640, 1898 (中田 修訳：古典紹介。精神医学16 : 603-609, 1974)
- 6) 稲村 博：犯罪性精神障害者の自殺。臨床精神医学 3 : 1185-1195, 1974
- 7) 石村貞夫。SPSSによるカテゴリカルデータ分析の手順。東京図書，東京，pp140-155，2001
- 8) 十河真人，北川香子，中角久典：拘禁の及ぼす睡眠，体重，排便，月経などへの影響。矯正医学 38 : 1-10 (16-25)，1989
- 9) 加賀乙彦：拘禁状況の心理。矯正医学 41 : 29-39 (40-50)，1993
- 10) 古賀幸博：司法精神医学研究，精神鑑定と矯正医療。林 幸司，古賀幸博，松野敏行編：新興医学出版社，東京，2001
- 11) 村田 浩，糸井孝吉：既決時の拘禁反応の特徴

- について. 矯正医学 37: 28-39, 1988
- 12) 村田 浩, 糸井孝吉: 既決時の拘禁反応の発病機序について. 矯正医学 38: 1-9, 1989
- 13) 中田 修: 「Vorbeireden」の精神病理について. 精神医学 5: 789-794, 1963
- 14) 中田 修: Ganser 症候群. 臨床精神医学 14: 561-564, 1985
- 15) 中谷陽二: Ganser 症候群—文献例と自験例から一. 精神科治療学 12: 391-400, 1997
- 16) 野村俊明, 奥村雄介, 吉永千恵子ほか: 矯正施設における精神医療の実際. こころの臨床 a・la・carte 24: 279-293, 2005
- 17) 小木貞孝: 拘禁状況の精神病理. 井村恒郎, 懸田克躬, 島崎敏樹ほか編: 異常心理学講座第V巻, みすず書房, 東京, pp279-347, 1965
- 18) 小木貞孝: 拘禁状況の精神病理, 死刑囚と無期囚の心理. 金剛出版, 東京, 1974
- 19) 大田中庸: 拘禁の心理. 犬塚石夫, 松本良枝, 進藤 眸ほか編: 矯正心理学上巻理論編, 東京法令出版, 東京, pp191-235, 2004
- 20) 小田 晋, 森田展彰, 薩美由貴ほか: Ganser 症候群および偽痴呆. 臨床精神医学 23 (増刊号): 191-198, 1994
- 21) 大谷正敏: 拘禁反応. 矯正医学 9: 1-8, 1960
- 22) 柴田洋子, 寺前雅人, 多田かすみ: 拘禁性妄想反応の一例—妄想の分析と反応の位置づけ—. Act Crim Japon 57: 17-26, 1991
- 23) 山上 皓: ガンザー症候群. 精神科治療学 10(臨): 164-165, 1995

* * *

学会告知板

日本精神障害者リハビリテーション学会 第15回名古屋大会

開催日: 2007年11月21日(水)・22日(木) <23日(金) サテライト企画>

会場: 名古屋市公会堂(名古屋市昭和区鶴舞)

日本福祉大学名古屋キャンパス(名古屋市中区千代田)

大会テーマ: Cross Borders! かきねをこえて 踏み出そうもう一歩

参加登録: 事前登録を9月上旬より開始いたします。詳細は、追ってHP上 (<http://www.japr.jp/2007/jpr-top.html>) でお知らせいたします。

参加費 事前参加登録: 会員 8,000円 非会員 9,000円 学生 3,000円

当日参加登録: 会員 9,000円 非会員 10,000円 学生 3,000円

懇親会参加: 会員・非会員 5,000円 学生 2,000円

申込先・問い合わせ先:

日本精神障害者リハビリテーション学会・第15回名古屋大会運営事務局

(株) コンベンションリンクージ内

〒460-0008 名古屋市中区栄3-32-20 朝日生命ビル

TEL: 052-262-5070 FAX: 052-262-5084 E-mail: japr2007@secretariat.ne.jp

大会HP: <http://www.japr.jp/2007/jpr-top.html>



Interfrontal commissural abnormality in schizophrenia: Tractography-assisted callosal parcellation

Jun Miyata^{a,*}, Kazuyuki Hirao^a, Chihiro Namiki^{a,b}, Hidenao Fukuyama^b,
Tsutomu Okada^c, Yukio Miki^c, Takuji Hayashi^a, Toshiya Murai^a

^a Department of Neuropsychiatry, Graduate School of Medicine, Kyoto University, Shogoin-Kawaharacho 54, Kyoto 606-8507, Japan

^b Human Brain Research Center, Graduate School of Medicine, Kyoto University, Shogoin-Kawaharacho 54, Kyoto 606-8507, Japan

^c Department of Diagnostic Imaging and Nuclear Medicine, Graduate School of Medicine,
Kyoto University, Shogoin-Kawaharacho 54, Kyoto 606-8507, Japan

Received 20 March 2007; received in revised form 23 June 2007; accepted 17 July 2007

Available online 19 September 2007

Abstract

Previous studies have indicated abnormal fiber connectivity of the corpus callosum (CC) in schizophrenia. This study investigated whether the interfrontal commissural region of the CC is decreased in schizophrenia, by partitioning the CC using a functio-anatomically relevant internal landmark derived from tractographic analysis of diffusion tensor imaging (DTI). T1 weighted and DTI images were acquired by 3T-MRI. Using tractography, the interfrontal commissural region (anterior part) was partitioned from the rest of the CC in 40 schizophrenia patients and 36 healthy controls. Schizophrenia patients showed smaller anterior/total CC length and area rates. These results suggested interfrontal hypoconnectivity in schizophrenia.

© 2007 Elsevier B.V. All rights reserved.

Keywords: Schizophrenia; White matter; Diffusion tensor imaging; Tractography

1. Introduction

The corpus callosum (CC), the largest interhemispheric commissural pathway, is a region of much interest in schizophrenia. The first MRI study (Nasrallah et al., 1986) suggested increased CC size in schizophrenia; however, a following meta-analysis (Woodruff et al., 1995) suggested a slightly decreased CC size in schizophrenia. As homologous cortical areas between the two hemispheres topographically map to specific regions of the CC (de Lacoste et al., 1985; Pandya and Seltzer, 1986), it is important to investigate CC subregional abnormality in schizophrenia. Among the

subregions, the interprefrontal area has a strong possibility of hypoconnectivity; the decreased number of mediodorsal thalamic neurons in schizophrenia (Pakkenberg, 1990; Popken et al., 2000) would lead to decreased thalamo-cortical input to the prefrontal cortex, which would possibly lead to abortive development of cortical differentiation and interprefrontal connections (Innocenti et al., 2003). However, the CC lacks distinct functio-anatomically relevant landmarks for parcellation, therefore previous studies (Goghari et al., 2005; Keshavan et al., 2002) could only parcellate the CC proportionally (Witelson, 1989).

Diffusion tensor imaging (DTI) tractography reconstructs white matter fiber trajectories using directional information in DTI data (Mori et al., 1999; Mori and van Zijl, 2002). In a recent tractography study, the boundary

* Corresponding author. Tel.: +81 75 751 3386; fax: +81 75 751 3246.
E-mail address: miyata10@kuhp.kyoto-u.ac.jp (J. Miyata).

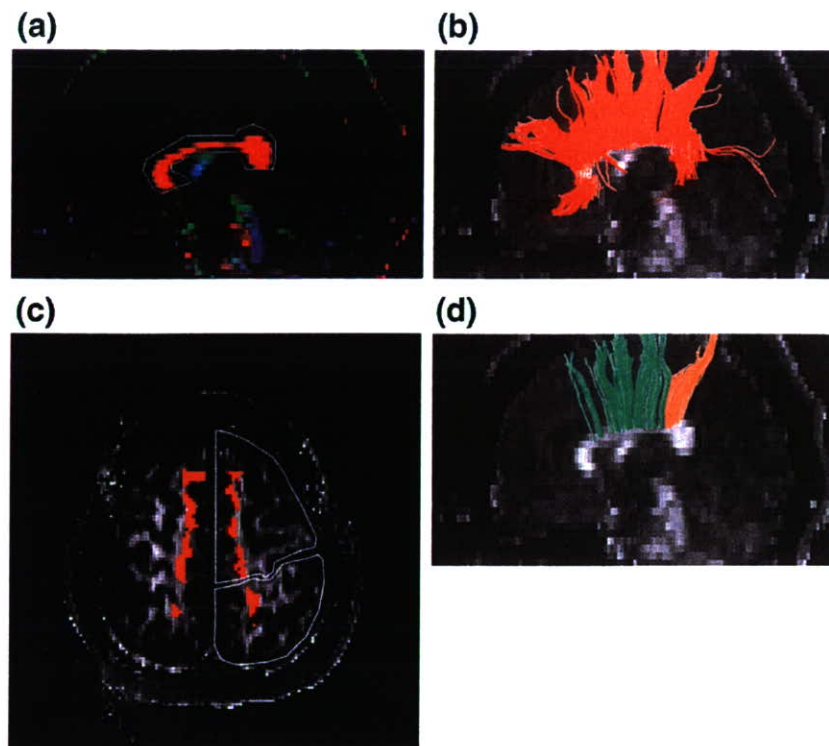


Fig. 1. 1st and 2nd ROI were placed on the DTI images. (a) The 1st ROI was placed contouring the CC in the mid sagittal plane, on a color coded map. Fiber orientations were assigned specific colors as follows; red represents the right-to-left orientation; green, the anterior-to-posterior orientation and blue the superior-to-inferior orientation (Pajevic and Pierpaoli, 1999). (b) Reconstructed fibers by 1st ROI are displayed on an FA map. (c) The 2nd ROI was placed on the frontal and parietal lobes in the axial slice. Red regions indicate the axial section of fibers reconstructed using the 1st ROI. (d) Reconstructed fibers penetrating both the 1st and 2nd ROIs are displayed. Green: interfrontal fibers. Orange: interparietal fibers.

between interfrontal and interparietal commissural fibers was clearly identifiable on a midsagittal image of the CC in healthy subjects (Huang et al., 2005). In the present study, in which we utilized their procedures, we divided the CC into anterior and posterior parts with this interfrontal/interparietal fiber boundary. We then tested the hypothesis that there is a specific reduction of the anterior parts of the CC in schizophrenia. We also investigated the possible underlying pathology of the subregional CC volume reduction by measuring the DTI-derived indices of fractional anisotropy (FA) and mean diffusivity (MD); FA represents white matter fiber coherence and MD is the index of the degree of water diffusion. Finally, we investigated the possible association of these regional CC abnormalities and clinical symptoms.

2. Materials and methods

2.1. Subjects

Forty-five schizophrenia patients (mean age=37.11 years; 23 males and 22 females; 42 outpatients and 3 inpatients), diagnosed by the patient edition of the Structured Clinical Interview for DSM-IV Axis I

Disorders (SCID) (First et al., 1996), were studied. None of the patients had comorbid psychiatric disorders. Anti-psychotic medication was prescribed to all patients. The Positive and Negative Syndrome Scale (PANSS; Kay et al., 1986) was used to assess clinical symptoms. Thirty seven healthy controls were recruited, with age, sex, handedness and education levels matched with the patient group. These controls had no history of psychiatric illness as determined by using the non-patient edition of the SCID (First et al., 1998). They also had no history of psychiatric disorders among first-degree relatives. Exclusion criteria for all individuals included a history of head trauma, neurological illness, serious medical or surgical illness and substance abuse. Three patients and one control subject were left handed. The relevant ethic committees approved these studies and all subjects provided written informed consent.

2.2. MRI acquisition

The DTI data were acquired using single-shot spin-echo echo-planar sequences and structural MRI data were acquired using three dimensional magnetization prepared rapid gradient echo (3D-MPRAGE) sequences, on a 3.0-T MRI unit (Trio; Siemens, Erlangen, Germany) with a

40 mT/m gradient. Parameters for the DTI were as follows; TE 79 ms, TR 5200 ms, 128×128 matrix, FOV 220×220 mm, 40 continuous axial slices of 3.0 mm thickness, 12 non-colinear axis motion probing gradient, $b=700$ s/mm². To enhance the signal-to-noise (S/N) ratio, imaging was repeated four times. Parameters for the 3D-MPRAGE imaging were as follows; TE 4.38 ms, TR 2000 ms, inversion time 990 ms, 256×256 matrix, FOV 240×240 mm, 208 axial slices of 1.0 mm thickness. 3D-MPRAGE images were also repeated 3 times and averaged images were created using statistical parametric mapping 2 (SPM2) (<http://www.fil.ion.ucl.ac.uk/spm>). Axial slices were adjusted to be parallel to the anterior commissure–posterior commissure (AC–PC) line in each subject.

2.3. Tensor calculation and fiber tracking

2.3.1. Tensor calculation

DtiStudio, version 2.4, (H. Jiang, S. Mori, Department of Radiology, Johns Hopkins University, Baltimore, Md) was used for tensor calculations and tractography (Jiang et al., 2006; Mori and van Zijl, 2002). All source images from the DTI datasets were visually inspected and images with apparent artifacts caused by bulk motion were removed from subsequent tensor calculations. We averaged four sets of source images, and mean and standard deviation (S.D.) images were created for each subject. If a subject made a bulk motion during data acquisition, the resulting S.D. images would show strong signal intensity, and so low quality images were clearly distinguishable.

In our dataset, there was low eddy current-related geometric distortion between images obtained in each motion-probing gradient direction (Bastin and Armitage, 2000; Naganawa et al., 2004), so post-processing distortion correction was not applied. After calculating the diffusion tensor, three eigenvalues and three eigenvectors were obtained (Basser et al., 1994, 2000); the eigenvector associated with the largest eigenvalue was assumed to represent the intravoxel fiber orientation. Then the directional color-coded maps (Figs. 1(a) and 2(a)), FA maps (Fig. 1(b), (c), and (d)), and MD maps were synthesized.

2.3.2. Fiber tractography

Fiber tractography was performed on the basis of the fiber assignments derived by means of the continuous tracking method (Mori and van Zijl, 2002; Wakana et al., 2004). Tracking from all voxels within the brain was performed and tracking results that penetrated the two regions of interest (ROIs) were assigned to specific tracts. The termination criteria for fibertracking were an FA < 0.2 or a turning angle of two consecutive vectors > 50°.

2.3.3. ROI selection and CC partition

On the DTI images, the 1st ROI was placed in the midsagittal plane, contouring the CC (Fig. 1(a)). The 2nd ROI was placed on the frontal and parietal lobes in an axial slice (Fig. 1(c)). Fig. 1(b) and (d) displays reconstructed fibers. The interfrontal/interparietal fiber boundary was determined in the midsagittal section,

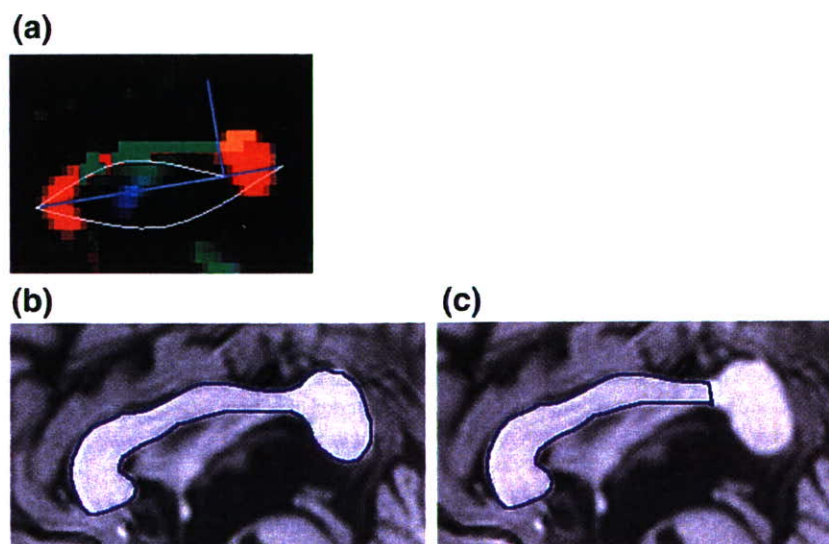


Fig. 2. (a) The interfrontal/interparietal fiber boundary was determined perpendicular to the maximal length line of the CC (light blue lines) and the anterior part length/maximal length rate (Length Rate) was calculated. Green and orange regions indicate the midsagittal section of frontal and parietal fibers respectively. Total area (b) and anterior part area (c) of the CC were measured on midsagittal sections of 3D-MPRAGE images.

Table 1
Demographic data of subjects used for the Length Rate and Area Rate analyses

	Schizophrenia (n=40)		Control (n=36)		Statistics <i>p</i>
	Mean	S.D.	Mean	S.D.	
Age (years)	37.40	9.56	36.42	7.86	N.S.
Sex (male/female)	20/20		18/18		N.S.
Handedness (rt/lt)	38/2		35/1		N.S.
Education (years)	14.05	2.30	14.36	2.74	N.S.
Age of onset (years)	25.20	6.43	–	–	–
Duration of illness (years)	12.45	9.31	–	–	–
Duration after first medication (years)	10.53	8.74	–	–	–
Medication (mg/day, HPD equivalent) ^a	11.48	7.14	–	–	–
PANSS total score	68.43	19.65	–	–	–
Positive scale	15.70	6.18	–	–	–
Negative scale	18.20	6.95	–	–	–
General psychopathology scale	34.53	10.40	–	–	–

^a Haloperidol equivalents were calculated according to Inagaki (2004).

partitioning the CC into anterior and posterior parts (Fig. 2(a)), and the rate of anterior part length/maximal length (Length Rate) was calculated. Additionally, the rate of anterior part area/total area (Area Rate) was calculated at the midsagittal plane of 3D-MPRAGE images (Fig. 2(b) and (c)). Mean FA and MD values of the anterior and posterior areas were measured by applying the same ROIs as used in Area Rate analysis. Image coregistration and mean FA and MD calculations were done by Pmod 2.75 (PMOD Technologies Ltd. Zurich, Switzerland). To test the inter-rater reliability of CC measurements, a second independent rater assessed 8 randomly selected subjects.

2.4. Statistical analyses

As an initial exploration of the data revealed that both Length and Area Rate were not normally distributed, non-parametric tests (Mann–Whitney, Spearman's correlation coefficient) were used for group comparisons and correlation analysis. Otherwise parametric tests were applied. Both FA and MD comparisons were done through diagnosis (schizophrenia and healthy control) by subregion (anterior and posterior parts) repeated measures analysis of variance (ANOVA). The 2-tailed statistical significance level was set at $p < 0.05$.

3. Results

3.1. Demographic data

The interfrontal/interparietal boundary was successfully determined in 40 (89%) of the patients and 36 (97%) of the controls. The characteristics of these participants are shown in Table 1. No significant group

difference was found in regards to age, sex, handedness or education. Significant group differences in the numbers who were excluded from further analysis were not found. In the comparison of demographic data and PANSS scores between included patients and excluded patients, there were no significant difference except for education (included patients=14.05, excluded patients=11.40, in average. $t=2.51$, $p=0.016$).

3.2. Image data analysis

Table 2 shows a summary of CC measurements. Cronbach α coefficients for the test of inter-rater reliability were 0.92 for Length Rate and 0.95 for Area Rate. No significant difference between the two groups was found in total CC area. Length Rate and Area Rate were significantly smaller in the schizophrenia group ($z = -2.46$ and -2.09 , $p=0.013$ and 0.036 , respectively). As

Table 2
Summary of CC measurements

	Schizophrenia (n=40)		Control (n=36)	
	Mean	S.D.	Mean	S.D.
Total area (mm ²)	639.35	96.80	650.99	70.55
Frontal area (mm ²)	427.52	63.64	447.45	55.66
Posterior area (mm ²)	211.83	43.74	203.54	28.04
Length Rate	0.758	0.041	0.782	0.038
Area Rate	0.670	0.038	0.687	0.032
Frontal area FA ^a	0.544	0.045	0.550	0.036
Posterior area FA ^a	0.614	0.059	0.640	0.043
Frontal area MD (mm ² /s)	0.830	0.065	0.829	0.060
Posterior area MD (mm ² /s)	0.776	0.078	0.763	0.076

Abbreviations: FA = fractional anisotropy, MD = mean diffusivity.

^a Dimensionless units.

sex difference is a major issue in studies of the CC (Panizzon et al., 2003), we divided both groups by gender and performed a 2 (diagnosis) × 2 (sex) ANOVA in a supplementary analysis. Neither a significant main effect of gender nor a significant gender by diagnosis interaction was found. Neither Length Rate nor Area Rate showed a significant correlation with age and education in either group. These CC measures did not show any significant correlation with age of onset, duration of illness, duration after first medication, haloperidol equivalent medication or any PANSS indices (total scores, positive scale, negative scale, and general psychopathology scale) in patients.

For FA and MD, Cronbach α coefficients for the test of inter-rater reliability were as follows: 0.85/0.86 for anterior/posterior area FA and 0.94/0.89 for anterior/posterior area MD. The ANOVAs both revealed significant main effects of subregion ($F=187.787$, $p<0.0005$ and $F=47.449$, $p<0.0005$, respectively), however did not show significant main effect of diagnosis or diagnosis by subregion interaction. The main effects of subregions indicated that the anterior part has lower FA and higher MD relative to the posterior part.

4. Discussion

Our study, using a tractography-derived CC internal boundary between interfrontal and interparietal commissural fibers, is the first to demonstrate a reduction of the CC size specific to the interfrontal commissural component in schizophrenia. The method reflects, and is robust to, the anatomical variety of the fiber boundary found between subjects. It also has an advantage over conventionally applied proportional parcellation. Inter-hemispheric connectivity disturbances have been suggested to play a major role in schizophrenia (Bullmore et al., 1998; Crow, 1998; Friston, 1998; Hoffman and McGlashan, 1998). Among the subregions of the CC, the interprefrontal area has been suspected to have a high possibility of hypoconnectivity (Innocenti et al., 2003). Our results support this hypothesis.

The issue of gender difference has been a major concern in morphological studies of the CC, and some suggest a global gender effect over the whole CC area (Highley et al., 1999; Panizzon et al., 2003). Our data of Area or Length Rate did not suggest sexual dimorphism; a factor such as gender might affect the entire CC rather than its specific subregion.

The neuropathological changes of the CC that underlie such interfrontal hypoconnectivity have been poorly investigated; however, decreased axonal density (number of fibers per area), as shown in a recent post-

mortem study, is a possible candidate (Highley et al., 1999). Other candidates include the reduction of axonal diameter or myelin density, and a decreased number or size of non-axonal components such as glial cell bodies (Innocenti et al., 2003). These factors can all affect FA or MD values. Since we did not find group-by-subregion interaction in either FA or MD, our results might support a different possibility from the above-mentioned ones, i.e., it is suspected that the entire number of interfrontal commissural fibers are reduced without massive changes of the microstructure of axonal fibers or their surrounding non-axonal structures.

Caution needs to be taken when interpreting the results since our study has several methodological limitations; the CC subdivisions derived from our partitioning are rather large and consist of fibers from a still wider range of cortical areas. This might mask the underlying abnormalities of more circumscribed subregions. This might also be the reason that no significant associations were demonstrated between Area/Length Rates and clinical symptoms. Tibbo et al. (1998) reported associations between negative symptoms and a smaller CC, while Goghari et al. (2005), found no association between subregional CC volumes and any PANSS scores. It might be necessary to apply a more detailed psychopathological measure to more fully address this issue. Another possible explanation for our negative correlations of symptomatology with CC measures is that the interfrontal hypoconnectivity shown in our study is more associated with vulnerability to illness rather than any current symptom severity. Family studies or high risk studies may help clarify this issue.

Although we attempted to further subdivide the CC, referring to a recent healthy subject study (Hofer and Frahm, 2006), the frontoparietal boundary was found to be the only landmark that could be reliably determined in the majority of our subjects. Detailed parcellation of the CC possibly using a more advanced method such as probabilistic multi-fiber tractography (Behrens et al., 2007) might enable us to detect any correlations existing between CC subregional abnormalities and psychopathology.

Role of the funding source

This research was supported by the Uehara Memorial Foundation and the Meiji Yasuda Mental Health Foundation. They had no further role in study design; in the collection, analysis and interpretation of data; in the writing of the report; and in the decision to submit the paper for publication.

Contributors

JM and TM designed the study and wrote the protocol, under the supervision of TH. JM managed the literature searches and analyses. JM, KH, and CN undertook the statistical analyses. TO supervised the MRI

data acquisition and processing. JM wrote the first draft of the manuscript. All authors contributed to and have approved the final manuscript.

Conflict of interest

All authors declare that they have no conflicts of interest.

Acknowledgements

The authors wish to extend their gratitude to Dr. Hao Huang and Dr. Susumu Mori (Johns Hopkins University School of Medicine, Department of Radiology, Division of MRI Research) for helpful technical advice regarding MRI data processing, Saori Fujie and Miho Yoshizumi for their assistance in statistical analysis, the staff of Kyoto Prefectural Rakunan Hospital for their cooperation with patient recruitment, and, most of all, the patients and volunteers for participating in the study.

References

- Basser, P.J., Mattiello, J., LeBihan, D., 1994. MR diffusion tensor spectroscopy and imaging. *Biophys. J.* 66, 259–267.
- Basser, P.J., Pajevic, S., Pierpaoli, C., Duda, J., Aldroubi, A., 2000. In vivo fiber tractography using DT-MRI data. *Magn. Reson. Med.* 44, 625–632.
- Bastin, M.E., Armitage, P.A., 2000. On the use of water phantom images to calibrate and correct eddy current induced artefacts in MR diffusion tensor imaging. *Magn. Reson. Imaging* 18, 681–687.
- Behrens, T.E., Berg, H.J., Jbabdi, S., Rushworth, M.F., Woolrich, M.W., 2007. Probabilistic diffusion tractography with multiple fibre orientations: what can we gain? *NeuroImage* 34, 144–155.
- Bullmore, E.T., Woodruff, P.W., Wright, I.C., Rabe-Hesketh, S., Howard, R.J., Shuriquie, N., Murray, R.M., 1998. Does dysplasia cause anatomical dysconnectivity in schizophrenia? *Schizophr. Res.* 30, 127–135.
- Crow, T.J., 1998. Schizophrenia as a transcallosal misconnection syndrome. *Schizophr. Res.* 30, 111–114.
- de Lacoste, M.C., Kirkpatrick, J.B., Ross, E.D., 1985. Topography of the human corpus callosum. *J. Neuropathol. Exp. Neurol.* 44, 578–591.
- First, M., Spitzer, R., Gibbon, M., Williams, J., 1996. Structured Clinical Interview for DSM-IV Axis I Disorders (SCID-I). American Psychiatric Publishing, Washington, D.C.
- First, M., Spitzer, R., Gibbon, M., Williams, J., 1998. Structured Clinical Interview for DSM-IV Axis I Disorders — Non Patient Edition (With Psychotic Screen). American Psychiatric Publishing, Washington, D.C.
- Friston, K.J., 1998. The disconnection hypothesis. *Schizophr. Res.* 30, 115–125.
- Goghari, V.M., Lang, D.J., Flynn, S.W., Mackay, A.L., Honer, W.G., 2005. Smaller corpus callosum subregions containing motor fibers in schizophrenia. *Schizophr. Res.* 73, 59–68.
- Highley, J.R., Esiri, M.M., McDonald, B., Cortina-Borja, M., Herron, B.M., Crow, T.J., 1999. The size and fibre composition of the corpus callosum with respect to gender and schizophrenia: a post-mortem study. *Brain* 122, 99–110.
- Hofer, S., Frahm, J., 2006. Topography of the human corpus callosum revisited-comprehensive fiber tractography using diffusion tensor magnetic resonance imaging. *NeuroImage* 32, 989–994.
- Hoffman, R.E., McGlashan, T.H., 1998. Reduced corticocortical connectivity can induce speech perception pathology and hallucinated ‘voices’. *Schizophr. Res.* 30, 137–141.
- Huang, H., Zhang, J., Jiang, H., Wakana, S., Poetscher, L., Miller, M.I., van Zijl, P.C., Hillis, A.E., Wytik, R., Mori, S., 2005. DTI tractography based parcellation of white matter: application to the mid-sagittal morphology of corpus callosum. *NeuroImage* 26, 195–205.
- Inagaki, A., 2004. Translation Table of Psychotropic Drugs. Keio University, Tokyo.
- Innocenti, G.M., Ansermet, F., Parnas, J., 2003. Schizophrenia, neurodevelopment and corpus callosum. *Mol. Psychiatry* 8, 261–274.
- Jiang, H., van Zijl, P.C., Kim, J., Pearlson, G.D., Mori, S., 2006. DtiStudio: resource program for diffusion tensor computation and fiber bundle tracking. *Comput. Methods Programs Biomed.* 81, 106–116.
- Kay, S.R., Opler, L.A., Fiszbein, A., 1986. The Positive and Negative Syndrome Scale (PANSS). Multi-Health Systems Inc, North Tonawanda, NY.
- Keshavan, M.S., Diwadkar, V.A., Harenski, K., Rosenberg, D.R., Sweeney, J.A., Pettegrew, J.W., 2002. Abnormalities of the corpus callosum in first episode, treatment naive schizophrenia. *J. Neurol. Neurosurg. Psychiatry* 72, 757–760.
- Mori, S., van Zijl, P.C., 2002. Fiber tracking: principles and strategies—a technical review. *NMR Biomed.* 15, 468–480.
- Mori, S., Crain, B.J., Chacko, V.P., van Zijl, P.C., 1999. Three-dimensional tracking of axonal projections in the brain by magnetic resonance imaging. *Ann. Neurol.* 45, 265–269.
- Naganawa, S., Koshikawa, T., Kawai, H., Fukatsu, H., Ishigaki, T., Maruyama, K., Takizawa, O., 2004. Optimization of diffusion-tensor MR imaging data acquisition parameters for brain fiber tracking using parallel imaging at 3 T. *Eur. Radiol.* 14, 234–238.
- Nasrallah, H.A., Andreasen, N.C., Coffman, J.A., Olson, S.C., Dunn, V.D., Ehrhardt, J.C., Chapman, S.M., 1986. A controlled magnetic resonance imaging study of corpus callosum thickness in schizophrenia. *Biol. Psychiatry* 21, 274–282.
- Pajevic, S., Pierpaoli, C., 1999. Color schemes to represent the orientation of anisotropic tissues from diffusion tensor data: application to white matter fiber tract mapping in the human brain. *Magn. Reson. Med.* 42, 526–540.
- Pakkenberg, B., 1990. Pronounced reduction of total neuron number in mediodorsal thalamic nucleus and nucleus accumbens in schizophrenics. *Arch. Gen. Psychiatry* 47, 1023–1028.
- Pandya, D.N., Seltzer, B., 1986. The topography of commissural fibers. In: Lepore, F., Ptioto, M., Jasper, H.H. (Eds.), *Two hemispheres, one brain. Functions of the corpus callosum*. Alan R. Liss Inc., New York, pp. 47–73.
- Panizzon, M.S., Hoff, A.L., Nordahl, T.E., Kremen, W.S., Reisman, B., Wieneke, M., Harris, D., Goodman, C., Espinoza, S., Liu, W., Lim, K., 2003. Sex differences in the corpus callosum of patients with schizophrenia. *Schizophr. Res.* 62, 115–122.
- Popken, G.J., Bunney Jr., W.E., Potkin, S.G., Jones, E.G., 2000. Subnucleus-specific loss of neurons in medial thalamus of schizophrenics. *Proc. Natl. Acad. Sci. U. S. A.* 97, 9276–9280.
- Tibbo, P., Nopoulos, P., Amdt, S., Andreasen, N.C., 1998. Corpus callosum shape and size in male patient with schizophrenia. *Biol. Psychiatry* 44, 405–412.
- Wakana, S., Jiang, H., Nagae-Poetscher, L.M., van Zijl, P.C., Mori, S., 2004. Fiber tract-based atlas of human white matter anatomy. *Radiology* 230, 77–87.
- Witelson, S.F., 1989. Hand and sex differences in the isthmus and genu of the human corpus callosum. A postmortem morphological study. *Brain* 112, 799–835.
- Woodruff, P.W., McManus, I.C., David, A.S., 1995. Meta-analysis of corpus callosum size in schizophrenia. *J. Neurol. Neurosurg. Psychiatry* 58, 457–461.

Teruyasu Saze · Kazuyuki Hirao · Chihiro Namiki · Hidenao Fukuyama · Takuji Hayashi · Toshiya Murai
Insular volume reduction in schizophrenia

Received: 8 January 2007 / Accepted: 8 June 2007 / Published online: 27 September 2007

Abstract Structural and functional abnormalities of the insular cortex have been reported in patients with schizophrenia. Most studies have shown that the insular volumes in schizophrenia patients are smaller than those of healthy people. As the insular cortex is functionally divided into anterior and posterior subdivisions, recent research is focused on uncovering a specific subdivisional abnormality of the insula in patients with schizophrenia. A recent ROI-based volumetric MRI study demonstrated specific left anterior insular volume reduction in chronic schizophrenia patients (Makris N, Goldstein J, Kennedy D, Hodge S, Caviness V, Faraone S, Tsuang M, Seidman L (2006) Decreased volume of left and total anterior insular lobule in schizophrenia. *Schizophr Res* 83:155–171). On the other hand, our VBM-based volumetric study revealed a reduction in right posterior insular volume (Yamada M, Hirao K, Namiki C, Hanakawa T, Fukuyama H, Hayashi T, Murai T (2007) Social cognition and frontal lobe pathology in schizophrenia: a voxel-based morphometric study. *NeuroImage* 35:292–298). In order to address these controversial results, ROI-based subdivisional volumetry was performed using the MRI images from the same population we analyzed in our previous VBM-study. The sample group comprised 20 schizophrenia patients and 20 matched healthy controls. Patients with schizophrenia showed a global reduction in

insular gray matter volumes relative to healthy comparison subjects. In a simple comparison of the volumes of each subdivision between the groups, a statistically significant volume reduction in patients with schizophrenia was demonstrated only in the right posterior insula. This study suggests that insular abnormalities in schizophrenia would include anterior as well as posterior parts. Each subdivisional abnormality may impact on different aspects of the pathophysiology and psychopathology of schizophrenia; these relationships should be the focus of future research.

Key words schizophrenia · insular · volumetry · self-awareness

Introduction

It has been postulated that dysfunction of the limbic system would be linked to difficulties in distinguishing between internal and external perceptions and regulating behaviors, ultimately allowing the emergence of the psychotic symptoms of schizophrenia; however, the underlying pathology remains to be elucidated [2, 9, 27]. The insular cortex is part of the limbic region, playing a key role in integrating perceptual experiences and affects to produce balanced behavior [1, 16].

There is converging evidence of a functional-anatomical abnormality of the insula in patients with schizophrenia. Functional neuroimaging studies suggest that insular hypometabolism [6] or decreased cerebral blood flow [4] might be involved in the pathophysiology of schizophrenia. Volumetric magnetic resonance imaging (MRI) studies of the insular cortex have almost unanimously indicated that there are morphological abnormalities of the insular gray matter in patients with schizophrenia [7, 10, 14, 18–21, 24, 25, 27].

T. Saze, MD (✉) · K. Hirao, MD · C. Namiki, MD
 T. Hayashi, MD, PhD · T. Murai, MD, PhD
 Department of Neuropsychiatry
 Graduate School of Medicine
 Kyoto University
 Kyoto 606-8507, Japan
 Tel.: +81-75-7513382
 Fax: +81-75-7513246
 E-Mail: sazeteru@kuhp.kyoto-u.ac.jp

C. Namiki, MD · H. Fukuyama, MD, PhD
 Human Brain Research Center
 Graduate School of Medicine
 Kyoto University
 Kyoto 606-8507, Japan

However, what remains unsolved is whether the insular abnormality in schizophrenia is specific to a certain subdivision (or lateralized), or if it is bilateral and global. Regarding the laterality issue, the literature is inconsistent: some studies report bilateral insular volume reductions [10, 14, 20, 25], whereas others report left-sided volume reductions [19, 21, 24]. Right-sided insular volume reduction has also been reported in female subjects [7].

In addition to the laterality issue, what is important is the intrahemispheric functional-anatomical subdivision of the insular cortex. The insular cortex is anatomically divided into two major subdivisions (anterior and posterior lobules) by the central sulcus of the insula [22, 23]. Morphological separation between these two parts reflects, to some extent, the characteristics of the cytoarchitectonic composition and their different neural connections. The anterior insula represents the agranular and adjacent dysgranular insula, and is connected to the piriform, orbitofrontal, temporopolar and parahippocampal regions. Together with the above-mentioned areas, the anterior insula plays a role in the control of emotions and autonomic regulation. By contrast, the posterior insular lobule consists of the granular and adjacent regions, and is more closely connected to the somatosensory, auditory, and motor areas [17]. The posterior insula mainly connects with the primary and secondary somatosensory cortices (SI, SII), the superior and inferior parietal lobules, the orbitofrontal, prefrontal and premotor cortices, the auditory cortex (AI, AII), the superior and inferior temporal cortices, the basal ganglia and the thalamus [1, 17].

Makris et al. [15] recently measured the volumes of the insular subregions (left/right \times anterior/posterior) using the central sulcus of the insula as a landmark for subdivisions, and investigated the volumetric alteration of the insula in patients with schizophrenia based on a volumetric MRI study. The authors reported that there was a significant reduction in insular cortical volume throughout the anterior insular lobules, and particularly in the left anterior lobule, in chronic schizophrenia patients compared with normal controls.

However, there are technical problems in previous volumetric MRI studies. Since the insula is a relatively small structure, it is difficult to clearly delineate it in images of low spatial resolution, especially when subdivisional volumetry is intended. Most studies have utilized lower magnetic field MR images (from 1.0 to 1.5 T) and obtained slices thicker than 1 mm (~1.5–3 mm). Such low quality protocols might lead to insufficient measurement of insular volumes.

Previously, our voxel-based morphometry (VBM) study revealed that there is a volume reduction in the right posterior insular lobules of patients with schizophrenia [26], in contrast to the results of Makris et al. [15]. Thus, to address these controversial

results, a region-of-interest (ROI)-based subdivisional volumetry study was performed using the MRI images from the same population we analyzed in our previous VBM-study [26]. The analyzed structural MRI images were obtained using a 3.0 T MRI scanner with slices of an acceptable thickness (1 mm) to investigate changes in the volumes of the subdivisions of the insular cortex.

Methods

Participants

The participants are identical to those of our previous study [26]. The schizophrenia group comprised 20 patients (10 men and 10 women), referred to the Department of Psychiatry, Kyoto University Hospital. Exclusion criteria included a history of seizure disorder, head trauma resulting in a loss of consciousness, neurological illness or substance abuse. Based on the Structural Clinical Interview for DSM-IV (SCID), all patients met DSM-IV criteria for schizophrenia and clinical symptoms were rated according to the Positive and Negative Syndrome Scale (PANSS; [13]). All patients were being treated with antipsychotic medications and were physically healthy at the time of scanning. Haloperidol equivalents, which were calculated according to Inagaki et al. [11], were administered at 11.9 ± 8.9 mg/day. Among the 20 patients, 18 were being treated with atypical antipsychotic medications (12 with 6.63 ± 3.45 mg/day of risperidone, 5 with 10.00 ± 6.12 mg/day of olanzapine, 3 with 391.7 ± 278.8 mg/day of quetiapine, and 2 with 18.00 ± 6.00 mg/day of perospirone); 11 were being treated with a single atypical antipsychotic medication, three were being treated with multiple atypical antipsychotics, and four were being treated with atypical antipsychotics in combination with typical (haloperidol or chlorpromazine) antipsychotics. Two patients were being treated with multiple typical antipsychotics. Some patients ($n = 8$) were also receiving adjunctive anticholinergic treatment. The comparison group comprised 20 healthy individuals (10 men and 10 women) who were matched with the schizophrenia group with regard to age and education level. These subjects were also evaluated on the basis of SCID. They had no current or past history of psychiatric or neurologic diseases. In addition, they had no first degree relatives who had current or past psychotic episodes.

Table 1 indicates the demographic characteristics of the two groups. The estimated verbal and performance IQs were obtained from vocabulary and block design subtests, respectively, using the Wechsler Adult Intelligence Scale-Revised (WAIS-R) by transforming the scores corrected for age into T scores.

After a complete description of the study to the participants, they gave written informed consent to a protocol approved by the Committee on Medical Ethics of Kyoto University.

MRI acquisition and pre-processing

MR images were obtained at Kyoto University Hospital on a 3-T whole-body scanner equipped with an 8-channel phased array coil (Trio, Siemens, Erlangen, Germany). The scanning parameters of the three-dimensional magnetization-prepared rapid gradient-echo (3D-MPRAGE) sequences were as follows: TE = 4.38 ms; TR = 2000 ms; TI = 990 ms; FOV = 240; slice plane = axial; slice thickness = 1 mm; resolution = $0.94 \times 0.94 \times 1.0$; and slice number = 208. In order to increase the signal/noise ratio, we scanned all participants three times and obtained average images from the three scans using statistical parametric mapping 2 (SPM2) software (The Wellcome Department of Imaging Neuroscience, London, U.K.) running in Matlab 6.5 (The Math Works, Natic, MA, U.S.).

Table 1 Demographic, clinical, and neuropsychological characteristics of the subjects

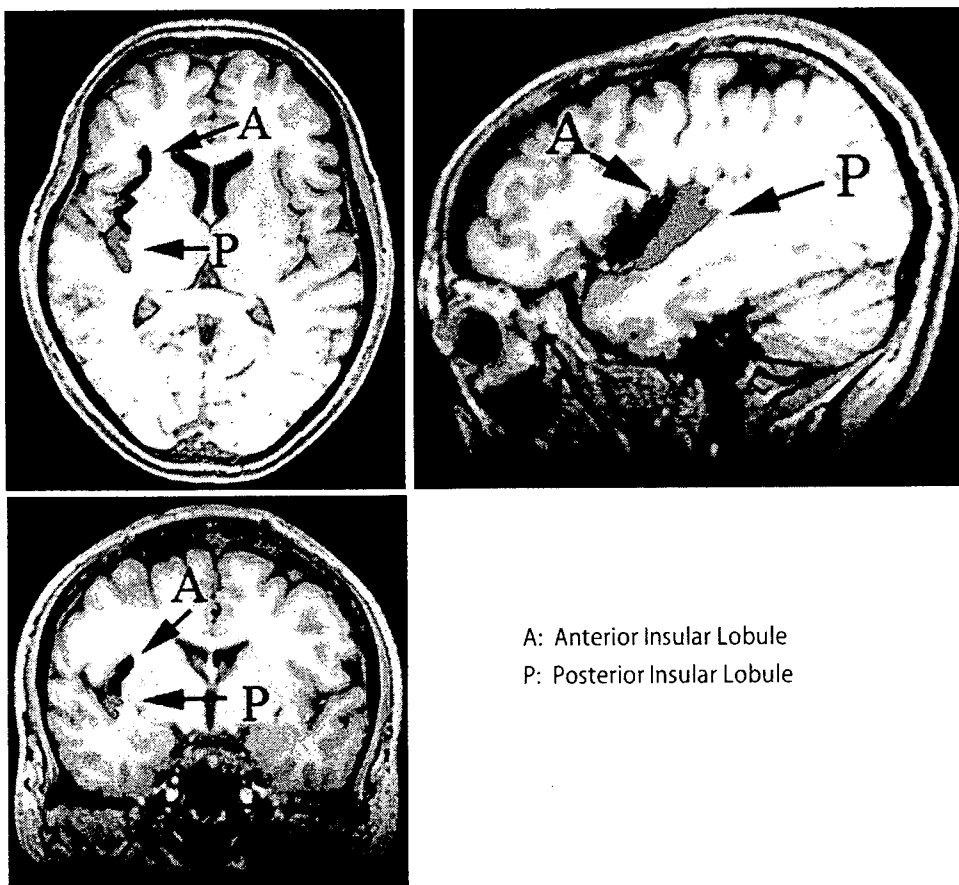
	Schizophrenia (<i>n</i> = 20)		Healthy (<i>n</i> = 20)		Statistics	
	Mean	S.D.	Mean	S.D.	<i>t</i> (df = 38)	<i>p</i>
Age (years)	38.8	7.2	39.1	7.1	0.13	<i>p</i> > 0.05
Sex (male/female)	10/10		10/10		–	–
Handedness (right/left)	19/1		19/1		–	–
Education years	13.5	2.0	14.4	1.9	0.15	<i>p</i> > 0.05
Age at onset (years)	27.4	6.4	–	–	–	–
Duration of illness (years)	11.6	8.7	–	–	–	–
Drug (mg/day, haloperidol equivalent)	11.9	8.9	–	–	–	–
PANSS Total	64.5	19.8	–	–	–	–
PANSS Positive	16.4	6.7	–	–	–	–
PANSS Negative	15.7	6.5	–	–	–	–
PANSS General	32.4	10.1	–	–	–	–
VIQ	97.8	16.0	107.5	14.8	2.00	<i>p</i> > 0.05
PIQ	97.8	14.9	107.0	12.7	2.11	<i>p</i> = 0.04

ROI definition

The boundaries of the insular cortex were manually determined using MRICro (Chris Rorden, University of Nottingham, Great Britain) on consecutive coronal slices. The most rostral coronal plane containing the insular cortex and the coronal plane containing the fusion of the superior and inferior circular insular sulci were chosen as anterior and posterior boundaries, respectively. On each coronal slice, the insular cortex was bounded superiorly by the superior circular insular sulcus, and inferiorly by the inferior circular insular sulcus or the orbitoinsular sulcus, following the procedure of Crespo-Facorro et al. [3]. In addition, following the procedure applied by Makris et al. [15], the central sulcus of the insula was considered as the

landmark dividing the insular cortex into anterior and posterior parts; thus, this sulcus constitutes the inferior border of the anterior insular lobule and the superior border of the posterior insular lobule (Fig. 1). The volume of each lobule was calculated by multiplying the number of voxels assigned to that structure by the single-voxel volume $0.94 \times 0.94 \times 1.0 \text{ mm}^3$. All measurements were carried out by the first author (TS) who was blind to subjects' identity, demographic data, diagnosis, and psychopathology.

To determine the reliability of the insular measurements, 10 subjects were randomly selected. Segmentation and parcellation was independently carried out by the first author and another researcher who was experienced at volumetric analysis. Both raters were blinded to participant details, including the study group and

Figure 1 The anterior and posterior insular lobules

the results of neuropsychological tests, during the measurement. For the insula subregion, intrarater reliability ranged from 0.96 to 0.97; interrater reliability ranged from 0.90 to 0.92 using Cronbach's alpha coefficient.

Intracranial volume (ICV) measurement

Estimates of the global gray and white matter volumes and cerebrospinal fluid (CSF) volume were obtained after the automatic brain segmentation procedure had been carried out by SPM2 in our previous study [26]. Total ICV was the sum of the volumes of gray and white matters and CSF.

Statistical analysis

In group comparisons of the insular subdivisional gray matter volumes, the relative volume ($[\text{absolute ROI volume/ICV}] \times 100$) was analyzed by repeated measures analysis of variance (ANOVA) with group (schizophrenia, control) as a between-subject factor, and hemisphere (left, right) and subregion (anterior, posterior) as within-subject variables. As mentioned in the introduction, each insular subdivision differs in its anatomical features, connectivity and functional roles. Thus, we were also interested in determining if the volumes of each insular subdivision differ significantly between the groups, especially for those of the left anterior and right posterior subdivisions, the volumes of which have been reported to be reduced in schizophrenia patients [15, 26]. Hence, separate group comparisons for each of the four subregional volumes were performed without correction for multiple comparisons of the four subregions.

Finally, in order to investigate the relationship between the gray matter volumes of the patients' insular subregions and their PANSS scores, parametric statistics were used if an initial exploration of the data set indicated a normal distribution; otherwise nonparametric statistics were applied.

For all of the resulting statistics, the significance threshold was set at $p < 0.05$. All of the above statistical analyses were performed using SPSS v.12.0.

Results

Demographic and clinical characteristics of patients and controls

Demographic and clinical data are summarized in Table 1. Two-tailed t -tests were applied to compare the differences in demographic and clinical variables between groups. The groups did not differ significantly in age, sex, handedness, education or estimated VIQ. The estimated PIQs of the schizophrenia subjects were significantly worse than those of healthy controls [controls = 107.0 (12.7); patients = 97.8 (14.9); $t = 2.11$; $df = 38$; $p = 0.04$].

Volume change

The ANOVA revealed a significant main effect of group ($F = 4.280$, $df = 38$, $p = 0.045$), subregion ($F = 677.4$, $df = 38$, $p < 0.001$) and a hemisphere-by-subregion interaction ($F = 8.825$, $df = 38$, $p = 0.005$), but no significant main effect of hemisphere ($F = 0.019$, $df = 38$, $p = 0.890$) and no significant group-by-hemisphere ($F = 0.086$, $df = 38$, $p = 0.771$), group-by-subregion ($F = 0.041$, $df = 38$, $p = 0.840$),

Table 2 Insular volumes in subjects with schizophrenia and healthy controls

	Schizophrenia ($n = 20$)		Healthy ($n = 20$)		Statistics	
	Mean	S.D.	Mean	S.D.	t ($df = 38$)	p
Intracranial volume (ml)	1564.1	212.8	1617.3	172.3	0.87	0.39
Insular cortex volume						
Right anterior						
Absolute (ml)	3.5	0.59	3.5	0.35		
Relative (%)	0.23	0.029	0.22	0.027	-1.00	0.33
Right posterior						
Absolute (ml)	1.9	0.40	1.8	0.30		
Relative (%)	0.13	0.021	0.11	0.015	-2.20	0.032
Left anterior						
Absolute (ml)	3.7	0.59	3.6	0.47		
Relative (%)	0.24	0.029	0.22	0.026	-1.50	0.13
Left posterior						
Absolute (ml)	1.8	0.33	1.7	0.19		
Relative (%)	0.11	0.017	0.11	0.015	-1.20	0.24

or group-by-hemisphere-by-subregion ($F = 1.027$, $df = 38$, $p = 0.317$) interactions. This result suggests that patients with schizophrenia have a global (that is, non-specific to subregion or hemisphere) reduction in the volume of insular gray matter relative to healthy subjects. When subregional relative volumes were compared between groups separately, a significant difference was demonstrated only in the right posterior lobule ($F = 4.960$, $df = 38$, $p = 0.032$), but not in the other three subregions (Table 2 and Fig. 2).

Correlations between volumes and clinical measures

Age, age when first medicated, duration of medication treatment, or current dose of antipsychotic medication, were not correlated with any of the investigated relative volumes. No significant correlation was demonstrated between any of the investigated relative volumes and any of the three PANSS subscores (positive, negative and general scores).

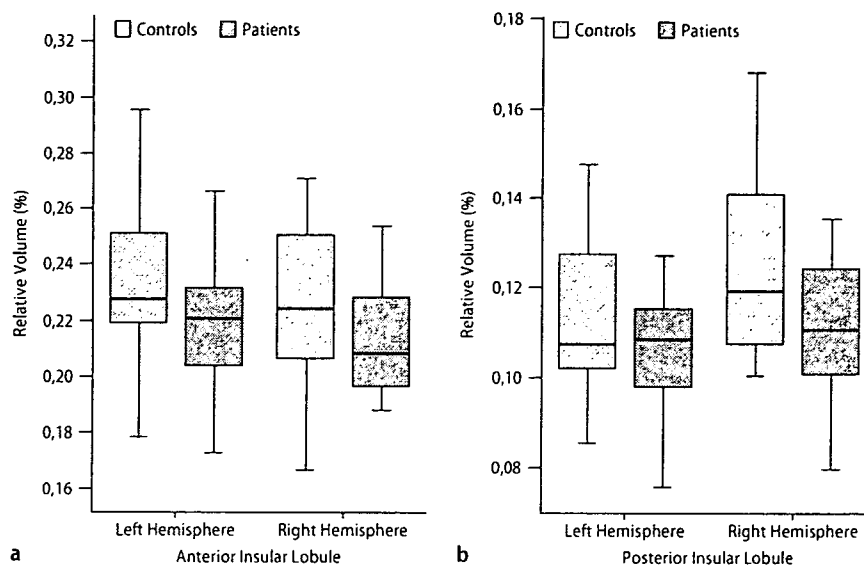
Discussion

Three main findings emerge from this study: (1) schizophrenia patients show a global reduction in insular volumes; (2) among insular subregions, the right posterior insula was the only subregion in which patients showed a significant volume reduction; (3) in the patient group, none of the subregional insular volumes were associated with psychopathological measures.

Insular volume reduction in schizophrenia

Although, most previous studies have shown volume reduction in the insular gray matter in patients with schizophrenia, little is known regarding the subdivi-

Figure 2 Box-plots of the relative volumes (%) of the insular lobules in the anterior (a) and posterior (b) zones of patients with chronic schizophrenia ($n = 20$) and healthy control subjects ($n = 20$). Means are indicated by horizontal lines. Each box encompasses 50% of the distribution of volumes



sional specificity of this volume reduction, as summarized in the Introduction. Our results, using high spatial resolution images, suggest that the insular abnormality is not subregion specific, but global, affecting the structure bilaterally as well as in both anterior and posterior subregions. Thus, the inconsistencies of the previous literature might be due to differences in patient characteristics as well as substantial measurement error variations associated with lower resolution images.

Specifically, in contrast to the recent study by Makris et al. [15], which is, other than our studies, the only study to investigate the insular subregional volumes in schizophrenia by dividing the insula into anterior and posterior sections, we did not demonstrate a specific volume reduction in the left anterior insula. This discordance might originate from differences in the characteristics of the patients investigated; for example, the illness durations in the patients in Makris' study (22.5 ± 10.9 years) were twice as long as those in ours (11.6 ± 8.7 years). However, the difference in methodological protocols would also be important. We traced an average of 50 coronal slices per subject when measuring the insular cortex; among these, 30 covered the posterior insular cortex. We believe that this method, using 1 mm-thick slices, can provide a more exact measure of the subregional volumes than that of Makris et al. [15], using 3 mm-thick coronal slices.

Although we did not demonstrate a statistically significant group difference in left anterior insular volumes, our assertion is not that the left anterior insula is not involved in the pathophysiology of schizophrenia, but that the left anterior insula is not specifically involved. Anterior and posterior subdivisions of the insula are involved in different neural circuitries, and bear a differential impact on our cognition and behavior. We suspect that the functions of both subdivisions would be compromised in schizophrenia. Pathology of the

anterior insula, together with other limbic and paralimbic structures, mainly affects emotional processes modulating our behaviors. Pathology of the posterior subdivision would have a different impact.

Regarding the effect of medication on regional volumes, we found no significant correlation between antipsychotic doses and subdivisional insular volumes. Dazzan et al. [5] reported that typical but not atypical antipsychotics are likely to induce regional cortical volume reductions, including a volume reduction in the insula, among first episode schizophrenia patients. The lack of an association of medication with insular volumes in our current study might be due to the fact that most of the patients were being treated with atypical antipsychotics.

• The volume change in the right posterior lobule

The main result of our analysis should be interpreted as a global reduction in the volume of the insula. However, in a separate group comparison for each subdivision, the only subregion in which a significant difference in volumes was found was the right posterior insula, although this difference was marginal without correction for multiple comparisons. Comparing the methodological advantages and disadvantages of VBM and manual ROI analysis, Kubicki et al. [14] recommended the initial use of VBM in an exploratory manner and subsequent confirmatory analyses by application of manual ROI tracing. Such an approach has been demonstrated to be successful in our analysis regarding the insular cortical volumes of schizophrenia: an initial whole-brain VBM analysis revealed a reduced volume region in the right posterior part of the insula [26], and this preliminary result was further confirmed by the present analysis using manual ROI tracing.

Although not fully elucidated, recent neuroimaging studies provide a clue to the possible functional sig-

nificance of this particular subregion of the human insula. Based on a lesion study analyzing an unselected sample of stroke patients with right brain damage, Karnath et al. [12] reported that right posterior insula lesions are specifically associated with "anosognosia" for hemiplegia/hemiparesis. On the other hand, in an activation study by Farrer et al. [8] using positron emission tomography (PET), healthy subjects were requested to indicate whether movements they saw on a computer screen corresponded to their executed movements, or were controlled by another person. The experiment showed decreased activity in the right posterior insula with a decreasing feeling of controlling the movement; that is, when subjects experienced a mismatch between what they did and what they saw. By contrast, this activity was increased when the afferent input matched their own actions. A possible interpretation of these findings is that the right posterior insula plays an important role in integrating signals related to self-awareness and establishing a boundary between self and others.

Although speculative, considering the functional significance of this region, some of the core characteristics of the psychopathology of schizophrenia could be explained by a dysfunctional right posterior insula: lack of insight could be explained straightforwardly as compromised self-awareness, while multimodal hallucinations could also be interpreted as a consequence of misintegration of sensory inputs into self-awareness.

Unfortunately, we did not find any correlation between psychopathological measures and the volume of any of the insular subregions, including the right posterior insula. The small sample size or non-uniformity of the subjects investigated (including both first episode subjects and more chronic subjects) might have affected our results of non-association between psychopathology and insular volumes. However, previous studies are also controversial regarding the association of psychopathology and insular volume reduction. If the above-mentioned role of the right posterior insula and its possible impact on psychopathology are true, such a putative association could be demonstrated using specifically-designed cognitive tasks or psychopathological measures to capture aspects of self-awareness in schizophrenia; this is the goal of our future studies.

Acknowledgments This work was supported by the Uehara Memorial Foundation, the Kobayashi Magobe Memorial Medical Foundation, and the Research Group for Schizophrenia, Japan.

References

- Augustine JR (1996) Circuitry and functional aspects of the insular lobe in primates including humans. *Brain Res Rev* 22:229-244
- Brebion G, Smith MJ, Amador X, Malaspina D, Gorman JM (1998) Word recognition, discrimination accuracy, and decision bias in schizophrenia Association with positive symptomatology and depressive symptomatology. *J Nerv Ment Dis* 186:604-609
- Crespo-Facorro B, Kim JJ, Andreasen NC, O'leary DS, Bockholt J, Magnotta V (2000) Insular cortex abnormalities in schizophrenia: a structural magnetic resonance imaging study of first-episode patients. *Schizophr Res* 46:35-43
- Curtis VA, Bullmore ET, Brammer MJ, Wright IC, Williams SC, Morris RG, Sharma TS, Murray RM, McGuire PK (1998) Attenuated frontal activation during verbal fluency tasks in patients with schizophrenia. *Am J Psychiatry* 155:1056-1063
- Dazzan P, Morgan KD, Orr K, Hutchinson G, Chitnis X, Suckling J, Fearon P, McGuire PK, Mallett RM, Jones PB, Leff J, Murray RM (2005) Different effects of typical and atypical antipsychotics on grey matter in first episode psychosis: the AESOP study. *Neuropsychopharmacology* 30:765-774
- Desco M, Gispert J, Reig S, Sanz J, Pascual J, Sarramea F, Benito C, Santos A, Palomo T, Molina V (2003) Cerebral metabolic patterns in chronic and recent-onset schizophrenia. *Psychiatry Res Neuroimaging* 122:125-135
- Duggal HS, Muddasani S, Keshavan MS (2005) Insular volumes in first-episode schizophrenia: gender effect. *Schizophr Res* 73:113-120
- Farrer C, Franck N, Georgieff N, Frith CD, Decety J, Jeannerod M (2003) Modulating the experience of agency: a positron emission tomography study. *NeuroImage* 18:324-333
- Frith C, Dolan RJ (1997) Brain mechanisms associated with top-down processes in perception. *Philos Trans R Soc Lond B Biol Sci* 352:1221-1230
- Hulshoff Pol HE, Schnack HG, Mandl RCW, Haren NEM, Konig H, Collins L, Evans AC, Kahn RS (2001) Focal gray matter density changes in schizophrenia. *Arch Gen Psychiatry* 58:1118-1125
- Inagaki A (2004) Translation table of psychotropic drugs. Keio University, Tokyo
- Karnath HO, Baier B, Nagele T (2005) Awareness of the functioning of one's own limbs mediated by the insular cortex? *J Neurosci* 25:7134-7138
- Kay SR, Fiszbein A, Opler LA (1987) The Positive and Negative Syndrome Scale (PANSS) for schizophrenia. *Schizophr Bull* 13:261-276
- Kubicki M, Shenton ME, Salisbury DF, Hirayasu Y, Kasai K, Kikinis R, Jolesz FA, McCarley RW (2002) Voxel-based morphometric analysis of gray matter in first episode schizophrenia. *NeuroImage* 17:1711-1719
- Makris N, Goldstein J, Kennedy D, Hodge S, Caviness V, Faraone S, Tsuang M, Seidman L (2006) Decreased volume of left and total anterior insular lobule in schizophrenia. *Schizophr Res* 83:155-171
- Mesulam MM, Mufson EJ (1982) Insula of the old world monkey: III. Efferent cortical output and comments on function. *J Comp Neurol* 212:38-52
- Mesulam MM, Mufson EJ (1985) The insula of Reil in man and monkey: Architectonics connectivity and function. In: Peters A, Jones EG (eds) *Cerebral cortex*, vol 4. Association and auditory cortices. Plenum Press, New York, pp 179-226
- Okugawa G, Tamagaki C, Agartz I (2007) Frontal and temporal volume size of grey and white matter in patients with schizophrenia: an MRI parcellation study. *Eur Arch Psychiatry Clin Neurosci* 257:304-307
- Paillere-Martinot M, Caclin A, Artiges E, Poline JB, Joliot M, Mallet L, Recasens C, Attar-Levy D, Martinot JL (2001) Cerebral gray and white matter reductions and clinical correlates in patients with early onset schizophrenia. *Schizophr Res* 50:19-26
- Shapleske J, Rossell SL, Chitnis XA, Suckling J, Simmons A, Bullmore ET, Woodruff PWR, David AS (2002) A computational morphometric MRI study of schizophrenia: effect of hallucinations. *Cereb Cortex* 12:1331-1341

21. Sigmundsson T, Suckling J, Maier M, Williams SCR, Bullmore ET, Greenwood KE, Fukuda R, Ron MA, Toone BK (2001) Structural abnormalities in frontal, temporal, and limbic regions and interconnecting white matter tracts in schizophrenic patients with prominent negative symptoms. *Am J Psychiatry* 158:234-243
22. Ture U, Yasargil DC, Al-Mefty O, Yasargil MG (1999) Topographic anatomy of the insular region. *J Neurosurg* 90:720-733
23. Varnavas GG, Grand W (1999) The insular cortex: morphological and vascular anatomic characteristics. *Neurosurgery* 44:127-136 (discussion 136-138)
24. Wilke M, Kaufman C, Grabner A, Putz B, Wetter TC, Auer DP (2001) Gray matter-changes and correlates of disease severity in schizophrenia: a statistical parametric mapping study. *NeuroImage* 13:814-824
25. Wright IC, Ellison ZR, Sharma T, Friston KJ, Murray RM, McGuire PK (1999) Mapping of grey matter changes in schizophrenia. *Schizophr Res* 35:1-14
26. Yamada M, Hirao K, Namiki C, Hanakawa T, Fukuyama H, Hayashi T, Murai T (2007) Social cognition and frontal lobe pathology in schizophrenia: A voxel-based morphometric study. *NeuroImage* 35:292-298
27. Yamasaki S, Yamasue H, Abe O, Yamada H, Iwanami A, Hirayasu Y, Nakamura M, Furukawa SI, Rogers MA, Tanno Y, Aoki S, Kato N, Kasai K (2007) Reduced planum temporale volume and delusional behaviour in patients with schizophrenia. *Eur Arch Psychiatry Clin Neurosci* (in press)

Impaired facial emotion recognition and reduced amygdalar volume in schizophrenia

Chihiro Namiki^{a,b,*}, Kazuyuki Hirao^b, Makiko Yamada^b, Takashi Hanakawa^a,
Hidenao Fukuyama^a, Takuji Hayashi^b, Toshiya Murai^b

^aHuman Brain Research Center, Kyoto University Graduate School of Medicine, Kyoto 606-8507, Japan

^bDepartment of Neuropsychiatry, Kyoto University Graduate School of Medicine, Kyoto 606-8507, Japan

Received 28 July 2006; received in revised form 8 February 2007; accepted 14 March 2007

Abstract

Structural abnormalities of the amygdala and impaired facial emotion recognition have been reported in schizophrenia. Most studies demonstrated reduced amygdalar volumes in schizophrenia patients, and difficulty in recognizing negative facial emotions has also been reported. However, findings on the deficit in facial emotion recognition have been inconsistent, and the relationships between this impairment and amygdalar volume reduction remain unclear. In this study, we investigated these relationships by performing volumetric analysis of the amygdala and evaluation of facial emotion recognition performance in the same subjects with schizophrenia. The sample group comprised 20 schizophrenia patients and 20 matched healthy controls. We measured the volumes of the amygdalae with high-resolution magnetic resonance imaging (MRI) at 3.0 Tesla. Additionally, we included a task that evaluated the subjects' ability to recognize the intensity of basic facial emotions. We found that impaired facial emotion recognition in schizophrenia patients is emotion-specific (sadness, surprise, disgust, and anger). Moreover, the volume of each amygdala on either side of the brain was reduced. Finally, we found a correlation between left amygdalar volume and the recognition of sadness in facial expressions. This study demonstrated that amygdala dysfunction may contribute to impaired facial emotion recognition in schizophrenia.

© 2007 Elsevier Ireland Ltd. All rights reserved.

Keywords: Schizophrenia; Amygdalar volume reduction; Facial emotional perception; Sadness facial perception disturbance

1. Introduction

1.1. Facial emotion recognition studies in schizophrenia

Disturbance of emotion is one of the important features of schizophrenia patients (Bleuler, 1950). Information about the impairment in their perception of emotions expressed by others has accumulated over the past few decades (Edwards et al., 2002), and recently more attention has been paid to facial emotion

* Corresponding author. Department of Neuropsychiatry, Kyoto University Graduate School of Medicine, 54 Kawahara-cho, Shogoin, Sakyo-ku, Kyoto 606-8507, Japan. Tel.: +81 75 751 36031; fax: +81 75 751 3246.

E-mail addresses: cnamiki@kuhp.kyoto-u.ac.jp (C. Namiki), kazhirao@kuhp.kyoto-u.ac.jp (K. Hirao), yamada@kuhp.kyoto-u.ac.jp (M. Yamada), hanakawa@ncnp.go.jp (T. Hanakawa), fukuyama@kuhp.kyoto-u.ac.jp (H. Fukuyama), takuhaya@kuhp.kyoto-u.ac.jp (T. Hayashi), murai@kuhp.kyoto-u.ac.jp (T. Murai).