

A CASE OF GYNECOMASTIA ASSOCIATED WITH EFAVIRENZ

KENJI UNO, MITSURU KONISHI, EIICHIRO YOSHIMOTO,
KEI KASAHARA, KEI MORI,

KOICHI MAEDA* and KEIICHI MIKASA

*Center for Infectious Diseases, *Department of General Medicine, Nara Medical University*

Received June 13, 2007

Abstract : We herein report on an HIV-infected patient with gynecomastia caused by efavirenz (EFV). A 57-year-old man was diagnosed with HIV-1 infection in 1994. He started therapy with zidovudine / lamivudine, didanosine, and EFV in December 2002. He felt painful breast hypertrophy after 5 months. There were firm, tender, unattached masses under the bilateral nipples, and ultrasonography showed benign enlargement of the breast without adipomastia. The blood levels of thyroid hormones, testosterone, estradiol, prolactin, and cortisol were normal. Therefore, we diagnosed him as having EFV-induced gynecomastia because of medication history and examinations. Although EFV was not stopped, his gynecomastia gradually improved.

Key words : human immunodeficiency virus infection, gynecomastia, efavirenz, adverse effect

INTRODUCTION

The prognosis of human immunodeficiency virus (HIV) infection has dramatically improved in the era of highly active antiretroviral therapy (HAART). However, HAART has been associated with the development of numerous acute and long-term adverse effects. Some morphologic changes are often observed as adverse effects of HAART¹⁾. There have been recent reports describing gynecomastia in HIV-infected men treated with HAART²⁻⁵⁾. We describe herein an HIV-infected man with gynecomastia that developed after receiving efavirenz (EFV).

CASE REPORT

A 57-year-old homosexual man was diagnosed with HIV-1 infection at a public health office in December 1994. He commenced the antiretroviral therapy in October 1995, but often needed to change the regimen of antiretroviral therapy because of insufficient effects or adverse reactions. He received zidovudine (AZT) between October 1995 and July 1996, AZT and didanosine (ddI) between July 1996 and July 1997, AZT and lamivudine (3TC) between July 1997 and October 1997, AZT, 3TC and nelfinavir (NFV) between October 1997 and April 1998, stavudine (d4T), ddI and NFV between April 1998 and December 1998, d4T, ddI and indinavir (IDV) between December 1998 and August 2001, and d4T, ddI, IDV and ritonavir (RTV) between August 2001 and December 2002. He started the therapy with AZT/3TC, ddI and EFV in December 2002. EFV was the only agent administered for the first time. He had not received any other medications. His CD4 positive cell count was kept over 500/ μ l, and his




Fig. 1. Gynecomastia in this patient. The firm, tender, unattached masses were observed under his bilateral nipples

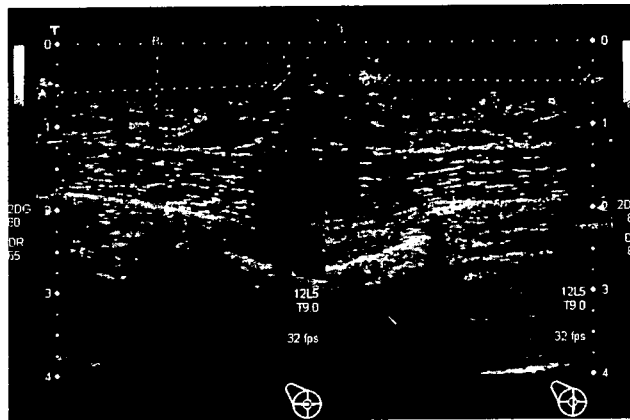


Fig. 2. Ultrasonography of the bilateral breasts showed ill-defined, heterogenous, echo-poor areas of nodularity deep to the nipple

plasma viral load was the limit of detection (<50 copies/ml). He felt painful breast hypertrophy at the end of May 2003. His height was 150.0 cm, and his weight was 47.6 kg. His blood pressure was 118/70 mmHg. There were firm, tender, unattached masses under the bilateral nipples (Fig. 1). His testicles were normal, and he showed no manifestations of lipodystrophy syndrome. Laboratory data showed a red blood cell count of $340 \times 10^4/\mu\text{l}$, serum aspartate aminotransferase of 36 IU/l, lactate dehydrogenase of 232 IU/l, γ -glutamyl transferase of 129 IU/l, creatinine of 1.2 mg/dl, triglycerides of 151 mg/dl, and total cholesterol of 268 mg/dl. The CD4 positive cell count was $591/\mu\text{l}$, and the HIV-RNA load remained undetectable. The blood levels of thyroid hormones, testosterone, estradiol,

Table 1. Table 1. Laboratory data

【Peripheral blood】	【Blood chemistry】	CD4 ⁺ 591 /μl
RBC 340 × 10 ⁴ /μl	AST 36 IU/l	CD8 ⁺ 929 /μl
Hb 13.8 g/dl	ALT 36 IU/l	【Virology】
Ht 39.0	LDH 232 IU/l	HBsAg -
WBC 5400 /μl	γ-GTP 129 IU/l	HCVAb -
meta 1 %	UA 6.1 mg/dl	HIV-RNA <50 copies/ml
st 1 %	BUN 20 mg/dl	【Endocrine】
seg 60 %	Cre 1.2 mg/dl	TSH 1.97 μU/ml
ba 1 %	TG 151 mg/dl	T3 1.03 ng/ml
lym 31 %	T.cho 268 mg/dl	T4 6.4 μg/dl
mo 6 %	Glu 99 mg/dl	Cortisol 11.5 μg/dl
Plt 24.6 × 10 ⁴ /μl	【Serology/immunology】	PRL 8.6 ng/ml
	CRP 0.1 mg/dl	Estoradiol 36.5 pg/ml
		Teststerone 5.9 ng/ml

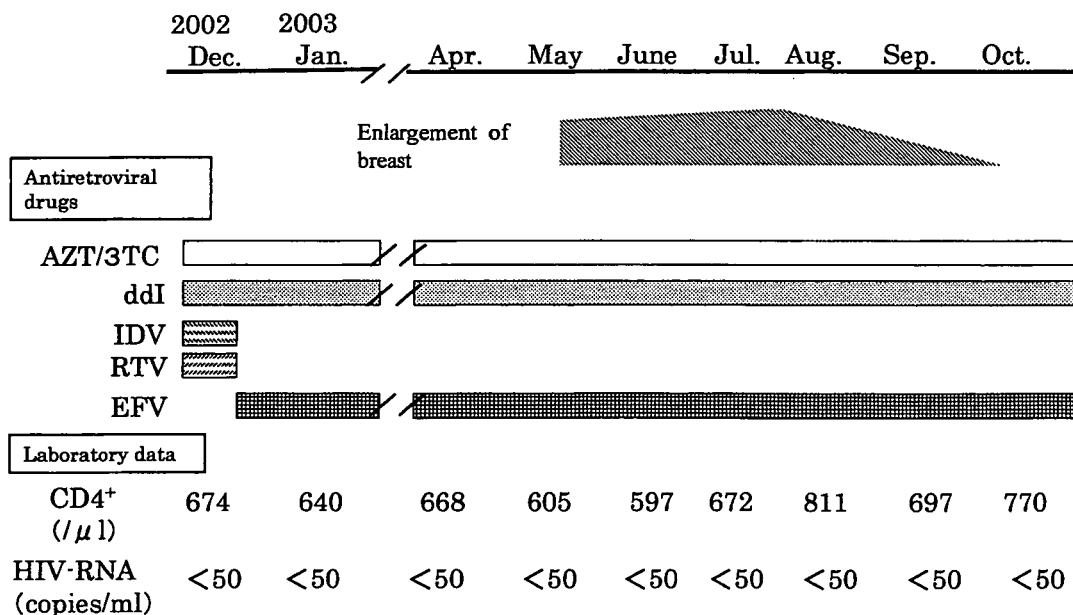


Fig. 3. Clinical course of this patient. AZT/3TC : zidovudine/lamivudine, ddI: didanosine, IDV: indinavir, RTV: ritonavir, EFV: efavirenz, CD4+: CD4 positive cell count.

prolactin and cortisol were normal (Table 1). Ultrasonography showed benign enlargement of the breast without adipomastia (Fig. 2).

We suspected gynecomastia associated with EFV because of the medication history and the results of examinations. We did not change the regimen of HAART because HAART was effective and his gynecomastia was mild. However, the size of his breasts regressed and they became no longer tender or painful after 5 months (Fig. 3).

DISCUSSION

Gynecomastia is defined as the development of prominent breast tissue in male. True gynecomastia is a condition in which there is an enlargement of the male breast due to an increase in the ductal tissue and periductal stroma⁶. On the other hand, lipomastia (pseudogynecomastia) is characterized by increased amounts of adipose tissue. Gynecomastia is recognized in 36–65% of normal men⁷. It is a normal physiologic finding in 3 groups of males : newborns in whom it is transient due to exposure to maternal estrogens, adolescents who experience a transient gynecomastia in association with puberty, and elders in whom the androgenic activity decreases with aging. Gynecomastia has several etiologies, such as liver disease, hyperthyroidism, neoplasms of the testicles, pituitary tumors, adrenal tumors, and the use of drugs. Drugs can cause gynecomastia in several ways : acting as direct estrogen receptor agonists, increasing the estrogenic activity, enhancing the testicular estrogen secretion, interfering with the production of testosterone, or blocking the binding of testosterone to its receptor⁸.

Our patient was not receiving other medications that could have caused gynecomastia, and this disorder appeared a few months after he began the HAART regimen including EFV that was the only agent received for the first time. He had no evidence of lipodystrophy syndrome. There were no biological or hormonal abnormalities that could explain gynecomastia in this case. These findings suggest that EFV can produce gynecomastia without lipodystrophy syndrome.

Gynecomastia has rarely been reported in HIV-infected men. However, gynecomastia has been increasingly reported in HIV-infected men taking several antiretroviral drugs since the introduction of HAART. At first, nucleoside reverse transcriptase inhibitors or protease inhibitors probably played a causal role²⁻⁵. Recently, there have been some reports on gynecomastia in HIV-infected men that was associated with EFV belonging to non-nucleoside reverse transcriptase inhibitors⁹⁻¹¹. Therefore, we have to consider that gynecomastia may occur in HIV-infected men treated with several different classes of antiretroviral drugs.

The mechanisms underlying the development of EFV-associated gynecomastia remain unclear. Different hypotheses explaining this pathogenesis have been described in several reports. Qazi *et al* suggested that gynecomastia might represent a manifestation of immune restoration disease, because gynecomastia developed only in HIV-infected men who had excellent response to HAART¹². The improvement of the helper T-cell cytokines response may influence the growth of breast tissue after commencement of an effective HAART. Besides, cytochrome P-450 inhibition induced by antiretroviral agents can elevate the

estrogen-androgen ratio. EFV was found to increase by 37% in the area under the curve (AUC) of coadministered ethynil estradiol, due to inhibition of cytochrome P-450¹³⁾. Furthermore, EFV may have estradiol-like effects in the human body, triggering the growth of breast tissue. Sinicco et al found that blood samples from HIV-infected patients receiving EFV had unusually high levels of the female estradiol as measured by enzyme-linked immunosorbent assay (ELISA) method. Thus, EFV may bind to parts of the ELISA test that normally detect estradiol¹⁴⁾.

In conclusion, we report herein a case of gynecomastia associated with EFV. Our experience could explain the possible occurrence of gynecomastia in HIV-infected men receiving various antiretroviral drugs. Therefore, we should pay attention to gynecomastia in the long-term follow-up of HIV-infected men treated with HAART.

REFERENCES

- 1) Carr, A., Samaras, K., Burton, S., et al. : A syndrome of peripheral lipodystrophy, hyperlipidemia and insulin resistance in patients receiving HIV protease inhibitors. *AIDS* 12 : 51-58, 1998.
- 2) Melbourne, K.M., Brown, S.L. and Silverblatt, F.J. : Gynecomastia with stavudine treatment in an HIV-positive patient. *Ann. Pharmacother.* 32 : 1108, 1998.
- 3) Toma, E. and Therrien, R. : Gynecomastia during indinavir antiretroviral therapy in HIV. *AIDS* 12 : 681-682, 1998.
- 4) Donovan, B., Bodsworth, N.J., Mulhall, B.P. and Allen, D. : Gynecomastia associated with saquinavir therapy. *Int. J. STD AIDS* 10 : 49-50, 1999.
- 5) Mastroianni, A. and Cancellieri, C. : Gynecomastia associated with HAART. *AIDS Reader* 10 : 115-118, 2000.
- 6) Braunstein, G.D. : Gynecomastia. *N. Engl. J. Med.* 328 : 490-495, 1993.
- 7) Nuttall, F.Q. : Gynecomastia as a physical finding in normal men. *J. Clin. Endocrinol. Metab.* 48 : 338-340, 1979.
- 8) Thompson, D.F and Carter, J.R. : Drug-induced gynecomastia. *Pharmacother.* 13 : 37-45, 1993.
- 9) Patrick, M., Jean-François, V., Rodolphe, T., et al. : Efavirenz-associated breast hypertrophy in HIV-infected patients. *AIDS* 15 : 126-129, 2001.
- 10) Caso, J.A.A., Prieto, J.M., Casas, E. and Sanz, J. : Gynecomastia without lipodystrophy syndrome in HIV-infected men treated with efavirenz. *AIDS* 15 : 1447-1448, 2001.
- 11) Rahim, S., Ortiz, O., Maslow, M. and Holzman, R. : A case-control study of gynecomastia in HIV-1-infected patients receiving HAART. *AIDS Reader* 14 : 23-40, 2004.
- 12) Qazi, N.A., Morlese, J.F., King, D.M., Ahmad, R.S., Gazzard, B.G. and Nelson, M.R. : True gynaecomastia, another manifestation of immune reconstitution disease? *Int. J. STD AIDS* 13 : 59-60, 2002.
- 13) Jover, F., Cuadrado, J.M., Roig, P., Rodriguez, M., Andreu, L. and Merino, J. : Efavirenz-associated gynecomastia : Report of five cases and review of the literature. *Breast J.* 10 : 244-246, 2004.
- 14) Sinicco, A., Raiteri, R., Rossati, A., Savarino, A., Di Perri, G. : Efavirenz interference in estradiol ELISA assay. *Clin. Chem.* 46 : 734-735, 2000.

Resistant recurrent aphthous stomatitis in an AIDS patient ～ Efficacy and problems of long-term corticosteroid therapy ～

YOSHINARI MORIMOTO^{1,2}, MITSURU KONISHI³, YUICHIRO IMAI²,
KOUTARO INAGAKE², SATORU FUKUTSUJI² and TADAAKI KIRITA²

Abstract : Recurrent aphthous stomatitis (RAS) in HIV patients is treated by local application of corticosteroid or oral administration of 40 ~ 60 mg/day of prednisone or prednisolone for less than 14 days, as recommended by treatment guidelines. However, when the immune system does not improve, large aphthous stomatitis keeps recurring over a short period of time. We treated an AIDS patient with resistant RAS using long-term prednisolone therapy.

The patient presented with hemophilia B complicated by AIDS. Aphthous stomatitis lesions were 10 ~ 15 mm in diameter. Aphthous stomatitis was unresponsive to corticosteroid ointment, but responded to oral administration of prednisolone 40 mg/day for 4 ~ 7 days. However, when the immune system became severely compromised, aphthous stomatitis kept recurring over a short period of time.

As a result, 5 mg of prednisolone was administered every other day, and this was successful in suppressing recurrence without adverse effects.

Long-term prednisolone therapy was useful in treating RAS when the immune system was severely compromised. In such treatment, close communication and teamwork is required between the physician and dentist to prevent adverse effects.

Key words : human immunodeficiency virus (HIV), acquired immunodeficiency syndrome (AIDS), aphthous stomatitis, corticosteroid, immunosuppression

Introduction

Recurrent aphthous stomatitis (RAS) is a condition often seen in dentistry, and 10 ~ 15% of RAS cases are major aphthae¹⁾. In HIV patients, frequency of aphthous stomatitis is about 1.1 ~ 3.1%²⁻⁴⁾, and when the level of CD4+ lymphocytes drops to < 100/mm³, large lesions of aphthous stomatitis with a diameter ≥ 6 mm typically appear^{3,5,6)}, often causing eating disturbances and weight loss. While corticosteroid ointments and oral medications have been used to treat such lesions^{2,4,5)}, quality of life can be reduced if aphthous stomatitis recurs frequently over a short period of time. We describe herein a case of RAS in a patient

with AIDS that was successfully treated using long-term prednisolone therapy.

Case Report

On February 23, 2001, a 28-year-old male presented to our hospital with eating disturbance due to pain as the chief complaint. The patient displayed hemophilia B (severe type) and HIV infection. Leukocyte count was 4000/mm³, CD4+ lymphocyte count was 21/mm³, and HIV-RNA level was 9000 copies/mL. Stavudine (d4T), lamivudine (3TC) and saquinavir were being administered as highly active antiretroviral therapy (HAART) (Fig. 1). However, this patient was allergic to numerous drugs, and as HAART was discontinued

¹ Department of Dental Anesthesiology, Graduate School of Dentistry, Osaka University (Chief: Prof. HITOSHI NIWA)

² Department of Oral and Maxillofacial Surgery, Nara Medical University (Chief: Prof. TADAAKI KIRITA)

³ Center for Infectious Diseases, Nara Medical University (Chief: Prof. KEIICHI MIKASA)

¹ 大阪大学大学院歯学研究科統合機能口腔科学専攻高次脳口腔機能学講座 (主任: 丹羽 均教授)

² 奈良県立医科大学口腔外科学講座 (主任: 桐田忠昭教授)

³ 奈良県立医科大学感染症センター (主任: 三笠桂一教授)

[2006年9月8日受付]

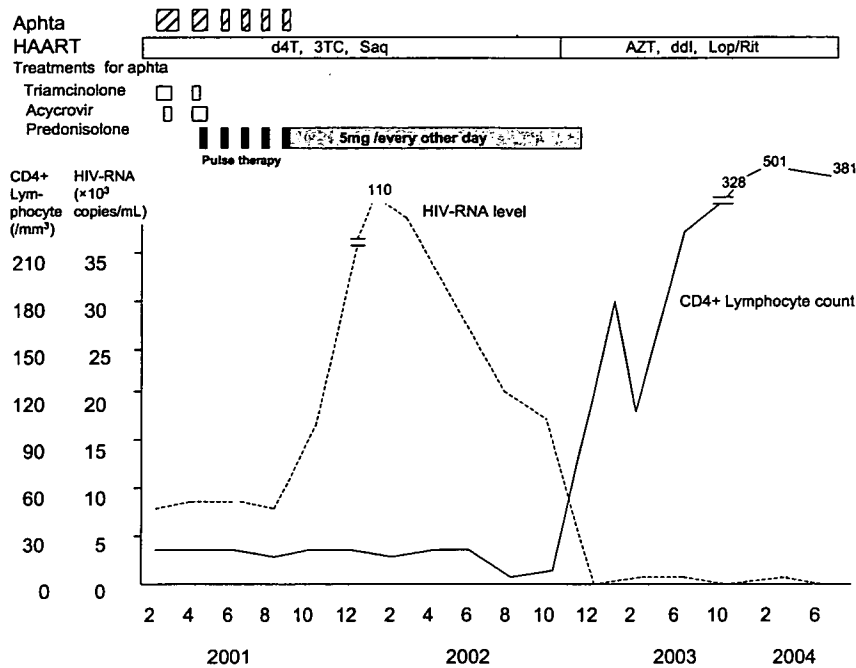


Fig. 1 Treatment courses

d4T: stavudine, 3TC: lamivudine, Saq: saquinavir, AZT: zidovudine, ddI: didanosine, Lop/Rit: lopinavir/ritonavir

on occasion, multidrug-resistant viruses were present. Hence, even when the drug regimen was altered, the patient was not responsive to HAART, and CD4+ lymphocyte count was $< 50/\text{mm}^3$ and HIV-RNA level was above the level of detection for more than 4 years. On presentation, a lesion of aphthous stomatitis with a diameter of 5 mm was seen at the gingivobuccal fold for the left maxillary incisor and canine. Triamcinolone acetonide ointment was used for more than 2 weeks, but aphthous stomatitis did not resolve. A physician suspected herpes simplex virus (HSV) infection, so 1000 mg/day of acyclovir was orally administered for 7 days, but no changes were seen. Given the effects of HAART agents and sulfa drugs, no drugs were administered for 1 month, but again no changes were seen.

On April 16, 2001, the patient displayed 5 aphthous lesions: a 15-mm lesion on the left side of the upper lip, and 5- to 8-mm lesions on the sublingual surface (Fig. 2). The physician administered 1000 mg/day of acyclovir intravenously for 7 days and orally for 14 days, and triamcinolone acetonide ointment was used for more than 2 weeks, but again no changes were seen.

The patient tested negative to cytomegalovirus (CMV) antigen in blood. Oral prednisolone 40 mg/day was subsequently administered for 7 days, and aphthous lesions disappeared. Prednisolone dose was reduced over time and eventually discontinued.

On June 15, 1 month after the end of prednisolone therapy, the patient visited our department with recurrence of 10-mm aphthous lesions on the left upper lip and right sublingual surface (Fig. 3). Lesions disappeared with oral administration of prednisolone 40 mg/day for 4 days. However, the patient repeatedly visited our hospital on July 5, August 8 and September 3 due to recurrence of aphthous stomatitis. Each time, 40 mg/day of prednisolone was administered for 4 days to clear aphthous stomatitis. The immune system of the patient was further compromised, and in September 2001, CD4+ lymphocyte count was $4/\text{mm}^3$ and HIV-RNA level was 20,000 copies/mL.

As resistance to HAART medication and marked depression of the immune system were responsible for the RAS, improvement of the immune system over such a short period was considered unlikely. 5 mg/day

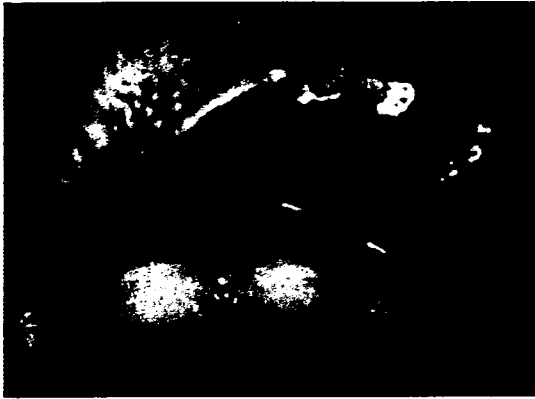

Fig. 2 A 15-mm aphthous lesion on the left side of the upper lip.

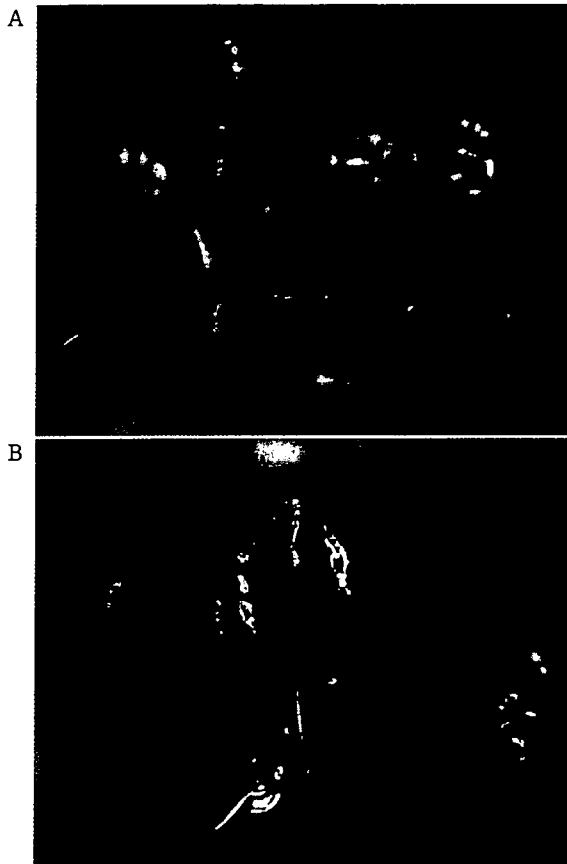


Fig. 3 Aphthous lesions (10-mm diameter) on the left upper lip (A) and right sublingual surface (B).

of prednisolone was administered every other day from October 2001 in consultation with the physician. Aphthous stomatitis subsequently resolved. During this procedure, the physician monitored the patient to maintain immune status and avoid the development of corticosteroid-associated adverse effects. Physical conditions and hematological tests were checked at least every 2 weeks. The dentist investigated intraoral condition, to avoid exacerbation of candidiasis or other HIV-associated lesions at the same time. Fortunately, no symptoms of immunosuppression were identified.

In October 2002, zidovudine (AZT), didanosine (ddI) and lopinavir/ritonavir were administered as HAART, and the patient displayed marked improvements in immune status. In November, CD4+ lymphocyte count was 54/mm³ and HIV-RNA level was < 400 copies/mL, and in December, CD4+ lymphocyte count improved to 180/mm³. As the immune system improved and aphthous stomatitis did not recur, prednisolone therapy was discontinued in February 2003. In June 2004, CD4+ lymphocyte count was 381/mm³ and HIV-RNA level was < 50 copies/mL. As of the time of writing, the patient has not displayed any recurrence of aphthous stomatitis.

Discussion

RAS in HIV patients is diagnosed based mainly on clinical symptoms, and HSV infection, CMV infection, deep mycotic infection, lymphoma and pharmacological agents must be excluded as causes^{7,8}. In the present patient, clinical findings suggested large aphthous stomatitis (diameter, > 6 mm) that persisted for months. The patient did not respond to acyclovir at all, so HSV infection was unlikely. The patient also did not test positive to CMV antigen and had no lymphoma. Furthermore, when use of all drugs was discontinued for 1 month, no changes were seen, thus excluding the possible effects of pharmacotherapy. As a result, RAS was diagnosed. However, since the patient had hemophilia B, no biopsy was conducted. Close collaboration among physicians and dentists is thus necessary for the diagnosis of oral lesions in patients with AIDS.

According to the treatment guidelines for RAS in HIV patients, local application of corticosteroid is selected at the early period and early period of recur-

rence as a first-line therapy, because high-potency topical corticosteroids are the most efficacious and safest option^{8,9}. However, if topical therapy fails to manage the acute ulcer, more aggressive treatment modality is recommended^{8,9}. Friedman et al. reported that weekly intralesional injections of 0.5 ~ 1.0 mL of triamcinolone 40 mg/mL were efficacious in HIV-infected patients with major RAS ulcers persisting > 2 weeks¹⁰. However, this method was not adopted in this patient, because he was a hemophiliac and invasive procedures may have led to disastrous hemorrhage.

Oral administration of 40 ~ 80 mg/day of prednisone or prednisolone for 3 ~ 7 days represents another effective method. A very low prevalence of adverse effects is seen in patients with very low CD4+ counts (< 50/mm³)¹¹. However, Lozada et al. have reported that systemic prednisone administration for > 2 weeks significantly increases the onset of complications¹². The treatment guidelines for RAS in HIV patients thus suggest oral administration of 40 ~ 60 mg/day of prednisone for < 14 days⁹. However, no reports have provided information on long-term control.

In the present patient, once the immune system was depressed, corticosteroid ointment became ineffective, and prednisolone 40 mg/day was administered orally for 4 ~ 7 days. Marked improvements in aphthous stomatitis were seen. However, as the patient was resistant to HAART medication and the immune system did not improve, large aphthous stomatitis kept recurring over a short period of time and caused eating disturbances and weight loss. In the treatment guidelines, use of thalidomide^{8,9,13} and combination immunosuppressant and topical steroid therapy¹⁴ have been recommended for RAS, but these drugs are not approved for this lesion in Japan. As a result, long-term corticosteroid therapy was considered.

Long-term corticosteroid therapy has been reported for the treatment of recurrent idiopathic esophageal ulcer (IEU) in patients with HIV infection^{15,16}, organ transplant¹⁷ or diseases such as Crohn's disease¹⁸ or Behcet's disease¹⁹. Kotler et al. have reported a comparison of 3 regimens: oral prednisone 40 mg/day for ≥ 1 month; intravenous hydrocortisone 100-250 mg every 6 h for ≤ 7 days; and intralesion injection of dexamethasone 80-160 mg for management of IEU in HIV-

infected patients¹⁵. A 40% rate of complications such as CMV-associated gastritis, esophagitis and ulcer-associated infection, Pneumocystis pneumonia and tuberculosis was identified¹⁵. Wilcox et al. reported use of prednisone 40 mg/day for 4 weeks for management of IEU in HIV-infected patients, and a 25% complication rate was suggested with CMV infections, Candida esophagitis, herpes zoster, Pneumocystis pneumonia, progression of Kaposi's sarcoma and diabetes mellitus¹⁶. Furthermore, systemic corticosteroid administration can cause complications such as cushingoid faces or thrush²⁰. If long-term systemic corticosteroid therapy is indicated, more adverse effects and immunosuppression can thus be observed compared to short-term therapy^{11,12}. The lowest possible therapeutic dosage and shortest duration should be employed with close medical supervision.

As for the dose of corticosteroid therapy, Kotler et al. and Wilcox et al. administered 40 mg/day of prednisone for ≥ 1 month^{15,16}, but this dose is too high for long-term administration. Use of prednisolone 15 mg/day for 3 months has been reported for the treatment of IEU in Crohn's disease¹⁸, while 10 mg/day of prednisolone was administered for 5 months in the treatment of IEU in a renal transplant patient¹⁷, and 5 mg/day of prednisolone has been administered for IEU in Behcet's disease¹⁹.

Since this patient responded well to short-term prednisolone therapy, a minimal dose (5 mg/day) was administered every other day, and this therapy was consequently continued for 17 months until the immune system of the patient improved under a new HAART regimen.

In patients with a severely compromised immune system, long-term corticosteroid therapy can further suppress the immune system and cause other lesions. Close communication and teamwork is thus required between the physician and dentist to prevent adverse effects^{8,20}. In this patient, the physician checked the immune status and other HIV- or corticosteroid-associated physical complications through examination and hematological tests at least every 2 weeks. The dentist also investigated intraoral condition to avoid exacerbation of oral candidiasis or other HIV-associated lesions at the same time. The plan was

made that if either the physician or dentist noticed an abnormal condition, a meeting would be held to determine whether to continue or discontinue therapy. Fortunately, symptoms of further immunosuppression and other abnormal conditions were not identified in this patient.

In this patients, long-term prednisolone therapy was useful in treating RAS when the immune system was severely compromised.

References

- 1) Scully, C., et al: The diagnosis and management of recurrent aphthous stomatitis. *J Am Dent Assoc* 2003 134 : 200 ~ 207.
- 2) Phelan, J. A., et al: Major aphthous-like ulcers in patients with AIDS. *Oral Surg Oral Med Oral Pathol* 1991 71 : 68 ~ 72.
- 3) Muzyka, B. C., et al: Major aphthous ulcers in patients with HIV disease. *Oral Surg Oral Med Oral Pathol* 1994 77 : 116 ~ 120.
- 4) Patton, L. L., et al: Changing prevalence of oral manifestations of human immunodeficiency virus in the era of protease inhibitor therapy. *Oral Surg Oral Med Oral Pathol* 2000 : 89 : 299 ~ 304.
- 5) MacPhail, L. A., et al: Recurrent aphthous ulcers in association with HIV infection. *Oral Surg Oral Med Oral Pathol* 1992 73 : 283 ~ 288.
- 6) Glick, M., et al: Oral manifestations associated with HIV-related disease as markers for immune suppression and AIDS. *Oral Surg Oral Med Oral Pathol* 1994 77 : 344 ~ 349.
- 7) Casiglia, J. M.: Recurrent aphthous stomatitis- Etiology, diagnosis and treatment. *Gen Dent* 2002 50 : 157 ~ 166.
- 8) Kerr, A. R., et al: Management strategies for HIV-associated aphthous stomatitis. *Am J Clin Dermatol* 2003 4 : 669 ~ 680.
- 9) American Academy of Oral Medicine: Clinician's guide to treatment of HIV-infected patients. 3rd ed. 2001.
- 10) Friedman, M., et al: Treatment of aphthous ulcers in AIDS patients. *Laryngoscope* 1994 104 : 566 ~ 570.
- 11) Silverman, S. J.: Prednisone management of HIV-associated recurrent oral aphthous ulceration. *J Acquir Immun Defic Syndr* 1992 5 : 952 ~ 953.
- 12) Lozada F., et al: Adverse side effects associated with prednisone in the treatment of patients with oral inflammatory ulcerative diseases. *J Am Dent Assoc* 1984 109 : 269 ~ 270.
- 13) Shetty K.: Thalidomide in the management of recurrent aphthous ulcerations in patients who are HIV-positive: A review and case reports. *Spec Care Dentist* 2005 25 : 236 ~ 241.
- 14) Brown, R. S., et al: Combination immunosuppressant and topical steroid therapy for treatment of recurrent major aphthae. *Oral Surg Oral Med Oral Pathol* 1990 69 : 42 ~ 44.
- 15) Kotler, D. P., et al: Chronic idiopathic esophageal ulceration in the acquired immunodeficiency syndrome characterization and treatment with corticosteroid. *J Clin Gastroenterol* 1992 15 : 284 ~ 290.
- 16) Wilcox C. M., et al: Comparison of two corticosteroid regimens for the treatment of HIV-associated idiopathic esophageal ulcer. *Am J Gastroenterol* 1994 89 : 2163 ~ 2167.
- 17) Farrell, J. J., et al: Idiopathic giant esophageal ulcers in a renal transplant patient responsive to steroid therapy. *Transplant* 2000 70 : 230 ~ 232.
- 18) Ohta, M., et al: Crohn's disease of the esophagus- Report of a case. *Surg Today* 2000 30 : 262 ~ 267.
- 19) Yasuo, M., et al: Successful treatment with corticosteroid in a case of Behcet's syndrome with multiple esophageal ulcers. *Intern Med* 2003 42 : 696 ~ 699.
- 20) Barrons, R. W.: Treatment strategies for recurrent aphthous ulcers. *Am J Health Syst Pharm* 2001 58 : 41 ~ 53.

症 例

間質性肺炎発症から後天性免疫不全症候群と判明した2症例

¹⁾ 近畿大学医学部奈良病院呼吸器アレルギー内科, ²⁾ 奈良県立医科大学附属病院感染症センター

澤口博千代¹⁾ 中島 宏和¹⁾ 中島 重徳¹⁾ 古西 満²⁾

(平成18年4月11日受付)

(平成18年8月3日受理)

Key words: acquired immunodeficiency syndrome, interstitial pneumonia

序 文

今回私たちは、発熱と呼吸困難を契機に医療機関を受診し、胸部画像上主にび慢性間質性陰影を認め、後天性免疫不全症候群(AIDS)と診断された2症例を経験したので報告する。

症 例

症例1: 35歳男性, 3年前から無職それまでの職歴不詳, 男性同性間性行為歴あり

主訴: 呼吸困難, 発熱

現病歴: 東京で働いていたが, 3年前体調を崩したとして退職, 奈良県の実家にもどり, 以降はひきこもっていた。平成16年5月末頃から呼吸困難と胸痛を自覚, 6月15日, 近医受診, 胸部レントゲン像上肺炎像を認め当科へ紹介され入院となった。

既往歴: 23歳B型肝炎, 家族歴: 特記すべきことなし,

入院時身体所見: 身長170cm, 体重60kg, 体温37.5℃, 脈拍103/分, 血圧122/60mmHg, SpO₂(酸素10L/minマスク投与)94%, 顔面手掌足底に紅潮と落屑, 心音異常なし, 肺野両側呼吸音減弱,

検査所見: 入院時の末梢血所見は, 好中球優位の正常範囲の白血球数と炎症反応性蛋白の中等度上昇, 著明なLDH値の上昇が認められた。又, 著明な低酸素血症を認めた(Table 1)。胸部CTでは, 下肺野優位の全体的な間質性陰影に加え, 一部air bronchogramも認める実質性陰影の部分も認められた。(Fig. 1)

入院後経過: 入院時検査で梅毒定性検査陽性の結果があり, 顔面その他の紅潮性落屑は2期梅毒の梅毒性乾癬と診断された。血中IgE値, β-D-galcan値, KL-6値が高かったため, 過敏性肺臓炎, 特発性間質性肺炎, 真菌性間質性肺炎, ニューモシステイス肺炎などが疑

われたが, 未治療の梅毒感染があるため, Human immunodeficiency virus (HIV) 感染も疑われスクリーニング検査したところ陽性となりWestern blot法での確認検査で抗HIV-1抗体陽性だった。喀痰細胞診では, 多数の真菌の発芽胞子が混在し, *Pneumocystis jirovecii* だけの同定は困難であった。抗HIV-1抗体陽性判明後, 6月25日奈良県内のAIDS拠点病院である奈良県立医科大学附属病院へ転院, 治療されたがサイトメガロウイルス感染症によると考えられる副腎不全から全身状態が悪化し, 7月6日死亡した。剖検病理所見で, 肺に関しては, ニューモシステイス肺炎が確認された(Fig. 2)¹⁾²⁾。また, これらの結果からAIDSと診断された。

症例2: 28歳男性, 会社員, 複数異性間性行為歴あり

主訴: 発熱, 呼吸困難, 乾性咳嗽

現病歴: 生来健康と自覚していた。平成15年9月12日頃から38℃の発熱を認め, 近医で抗生剤を処方されるも効果なく, 9月24日胸部CT上びまん性間質性陰影を認め, 当科を紹介された。

既往歴: 特記すべきことなし, 家族歴: 特記すべきことなし,

喫煙歴: 10本/日×8年

現症: 身長178cm, 体重60kg, 体温37.0℃, 脈拍69/分, 血圧108/52mmHg, SpO₂(room air)95%, 咽頭発赤あり, 扁桃腫大なし, 心音異常なし, 肺野背部中下肺野呼吸音やや粗

検査所見: 入院時の検査所見では, 白血球数正常範囲, 炎症反応性蛋白の軽度上昇, LDH値の軽度上昇, IgE値上昇を認めた(Table 2)胸部CT上は両側下肺野中心に軽度のスリガラス様陰影を認めた。(Fig. 3)

入院後経過: まず, マイコプラズマ肺炎, クラミジア肺炎, 過敏性肺臓炎, 特発性間質性肺炎, 膠原病肺,

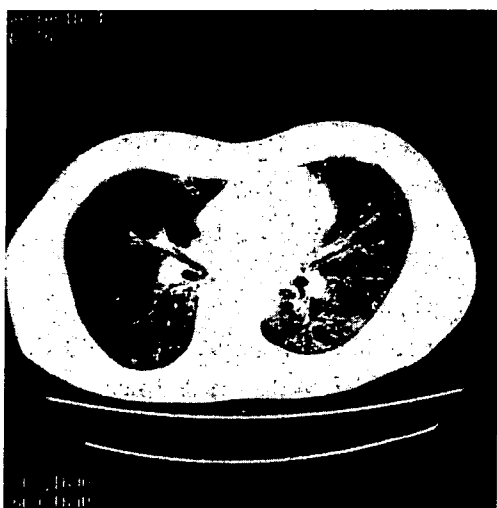
別刷請求先: (〒630-0293) 奈良県生駒市乙田町1248番の1
近畿大学医学部奈良病院呼吸器アレルギー内科
澤口博千代

平成19年1月20日

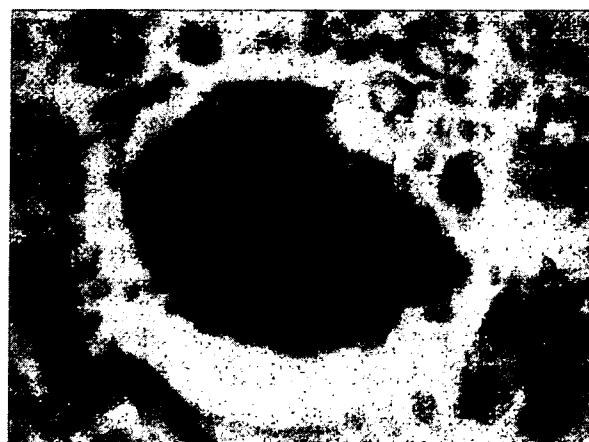
Table 1 Laboratory findings for case 1

Hematology		Blood chemistry	
WBC	7,260 / μ L	Alb	2.6 g/dL
Neutro	85 %	GOT	44 IU/L
Lymph	8.0 %	GPT	10 IU/L
(CD4 positive lymphocytes)	10.8 / μ L)	LDH	1,115 IU/L
Mono	7.0 %	BUN	6.9 mg/dL
Serology		Crn	0.5 mg/dL
CRP	7.39 mg/dL	Na	115 mEq/L
IgG	1,649 mg/dL	K	3.3 mEq/L
IgA	639 mg/dL	ABG (O ₂ 10L/minmask)	
IgE	2,156 U/mL	PH	7.478
IgD	< 1.0 mg/dL	PaO ₂	62.1 torr
CEA	13.3 ng/mL	PaCO ₂	31.4 torr
CYFRA	6.8 ng/mL	HCO ₃ ⁻	23.0 mmol/L
IAP	1,550 μ g/mL	A.B.E.	0.5 mmol/L
Soluble IL-2 receptor	1,142 U/mL	EIA method	
β -D-glucan	271.7 ng/mL	Anti-HIV antibody	positive
KL-6	2,880 U/mL	Western blotting	
STS	256	Anti-HIV-1antibody	positive
TPHA	40,960	Anti-HIV-2antibody	negative
FTA-IgM	$\times 20$ positive	Sputum Culture	
Rheumatoid factor	negative	Candida albicans	several colonies
Antinuclear antibody	< 40		
Antibodies to candida	negative		
Antibodies to mycoplasma	< 40		
Antibodies to chlamydia pneumoniae			
IgG	1.6		
IgM	1.4		
Perinuclear ANCA	< 1.3		

Fig. 1 Chest CT for case 1 on admission showing diffuse, and thick ground glass appearance.



薬剤性間質性肺炎, 真菌性間質性肺炎, などを疑ったが, 過敏性肺臓炎であれば入院による抗原回避での改善があるべきところ, 改善なく, 否定的と思われた。膠原病肺は, 抗核抗体やリウマチ因子が陰性かつ臨床

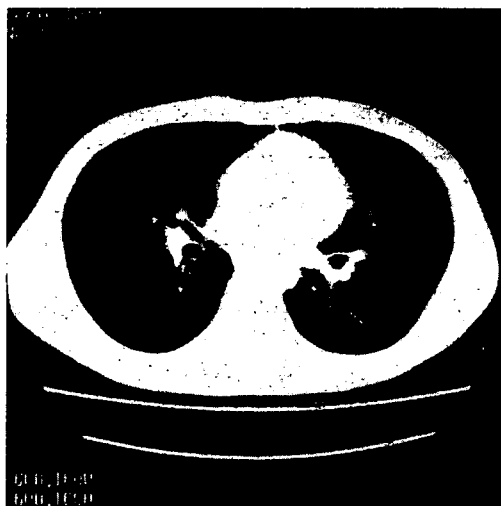
Fig. 2 Grocott staining of lung specimen by autopsy showing cystic forms of *Pneumocystis jirovecii*.

上も膠原病を疑う身体症状がなく可能性は低いと思われた。また, マイコプラズマ肺炎及びクラミジア肺炎であれば, 一般的に効果があるとされるマクロライド系抗生剤投与をおこなったが効果なく, β -D-glucan 値の高値 (=348.9ng/mL) が判明し, 真菌性肺炎あるいはニューモシテイス肺炎の可能性が考えられた^{1)~5)}。免疫状態が正常かどうか検査する必要性もあ

Table 2 Laboratory findings for case 2

Hematology		Antibodies to chlamydia pneumoniae	
WBC	4,700 / μ L	IgG	index 0.4
Neutro	67.6 %	IgA	index 2.7
Lymph	21.2 %	Perinuclear ANCA	< 1.3
(CD4positive lymphocytes	34 / μ L)	Blood chemistry	
Mono	9.7 %	Alb	3.5 g/dL
Eosino.	1.5 %	GOT	26 IU/L
Serology		GPT	9 IU/L
CRP	2.98 mg/dL	LDH	410 IU/L
IgG	1,499 mg/dL	BUN	10.6 mg/dL
IgA	1,093 mg/dL	CRN	0.9 mg/dL
IgE	1,242 U/mL	Na	139 meq/L
IgD	< 1.0 mg/dL	K	4.2 meq/L
Rheumatoid factor	negative	EIA	
Antinuclear antibody	< 40	Anti-HIV antibody	positive
β -D-glucan	348.9 ng/mL	Western blot ting	
KL-6	525 U/mL	Anti-HIV-1 antibody	positive
Antibodies to Canadida	negative	Anti-HIV-2 antibody	negative
Antibodies to cytomegalovirus			
IgG	0.1 mg/dL		
IgM	0.27 mg/dL		
Antibodies to mycoplasma			
September 24	< 40		
October 10	< 40		

Fig. 3 Chest CT for case 2 on admission showing ground glass-appearance.



ると判断し、CD3、CD4 陽性リンパ球数を検査したところ、CD4 陽性リンパ球数 34/ μ L という結果となった。同意を得て抗 HIV 抗体スクリーニング検査を行い、陽性となり western blot 法による確認検査で抗 HIV-1 抗体陽性と判明した。ST 合剤の投与を開始し、10 月 17 日県内の AIDS 拠点病院である奈良県立医科大学附属病院へ転院、当初 ST 合剤が継続され、10 月 23 日の胸部 CT でのスリガラス状陰影の消失、低酸素血症の改善が認められた。気管支肺胞洗浄などに

よるニューモシステイス肺炎の確定診断は、臨床症状改善のためなされなかったが、HIV 感染者で CD4 陽性リンパ球数 34/ μ L と著明に減少していた事、胸部 CT 画像所見、発熱、呼吸困難、低酸素血症、乾性咳嗽などの臨床症状、 β -D-glucan 値 348.9ng/mL と著明な上昇、ST 合剤が効果的であった事などから、AIDS に伴うニューモシステイス肺炎と臨床的に診断した。

考 察

AIDS は、HIV 感染後数年から十数年の潜伏期間を経て CD4 陽性 T リンパ球の減少と機能低下により免疫不全が惹起されて生じる。発症の指標となる疾患には、成人の呼吸器では、ニューモシステイス肺炎、肺カンジタ症、サイトメガロウイルス性肺炎、単純ヘルペス性肺炎または気管支炎、活動性肺結核などが指定され、CD4 陽性 T リンパ球が 200/ μ L 未満で発症しやすくなると言われている。これらの疾患のうち肺結核以外は、画像上主に間質性肺炎像を呈するため⁶⁾、過敏性肺臓炎、特発性間質性肺炎、薬剤性間質性肺炎、膠原病肺、前述以外の病原微生物による間質性肺炎との鑑別が必要となる。とくに症例 2 のように発症まで HIV 無症候性キャリアである可能性について全く自覚がない場合、感染症として、マイコプラズマ肺炎や、クラミジア肺炎を疑いがちである。AIDS におけるニューモシステイス肺炎は、他の原因による免疫不全状態からの発症の場合と比較すると、より発症経過が緩慢で、発熱、低酸素血症も軽いといわれ¹²⁾、このこ

とも鑑別診断を困難にする一因ではないかと思われる。マイコプラズマ肺炎の迅速診断には、DNAプローブ法やPCR法によって直接病原体の抗原を検出する方法やIgM抗体迅速検出が可能であるが、実施できる場合は限られ、クラミジア肺炎についても一般的には、迅速診断はできないのが現状である。その為、empiricに抗生剤を投与してその効果も診断の補助材料とする事が多い。マクロライド系抗生剤の投与効果が認められない場合、症例2のように血清中 β -D-galcan値測定が、鑑別診断に寄与する場合がある。Yasuokaらによって報告されたように血清中 β -D-galcan値高値は、ニューモシステイス肺炎を疑う支持材料となり得る⁴³⁾。ニューモシステイス肺炎の確定診断には、誘発喀痰や気管支肺胞洗浄液中の*Pneumocystis jirovecii*の検出やPCRによる検査が有用で、AIDSでは、他の免疫不全状態からの発症に比べ、誘発喀痰による検出率が高く50%から90%といわれ、又、気管支肺胞洗浄液では更に高率に検出できるとされる⁴²⁾。症例2では、自然喀出の痰がなかったのだが、誘発喀痰検査を試みるべきだったと反省される。厚生労働省の統計では平成17年度の全国AIDS発症者数は365人で前年度の386人よりわずかに減少を示したが、平成14年度から平成16年度までは毎年前年度を上回る発症者数となっている⁷⁾。抗HIV薬の開発により、キャリアからの発症は、高率に予防できるようになった。従って、十分な知識と抵抗感なく検査を受けられる環境があれば、発症率の低下が期待でき、診断にいたるまで、医療機関で鑑別診断のために多くの検査を受け、診断まで長期間を要する事もなくなるだろうと思われる。今後、AIDSは更に身近な感染症となっていく可能性が高いと懸念され、医療従事者は、AIDSも鑑別診断

の念頭におくべきであり、呼吸器科的には、間質性肺炎診療時には、簡便に測定できる β -D-galcan値が、重要な意味を持つと考えられた。さらに、啓蒙活動も積極的に行うべきであると思われた。

文 献

- 1) Charles FTJ, Andrew HL : Pneumocystis pneumonia. N Engl J Med 2004 ; 350 (24) : 2487—98.
- 2) Joseph AK, John WH, Abe MM, Diane S, Henry WM, James S, et al. : Pneumocystis carinii Pneumonia : a comparison between patient with the acquired immunodeficiency syndrome and patients with other. Annals of Intern Med 1984 ; 100 : 663—71.
- 3) 村上 亨, 鈴木道明, 岡田聖子, 鈴木純子, 長岡鉄太郎, 坂本匡一, 他 : 血中KL-6, β -D-galcanの経時的变化を観察した後天性免疫不全症候群に伴うカリニ肺炎の1例. 日呼吸会誌 2000 ; 38 : 632—5.
- 4) Okamoto K, Yamamoto T, Nonaka D, Shin H, Okada K, Hyashi J, et al. : Plasma (1→3)- β -D-galcan measurement and polymerase chain reaction on sputum as practical parameters in Pneumocystis carinii pneumonia. Intern Med 1998 ; 37 : 618—21.
- 5) Yasuoka A, Tachikawa N, Shimada K, Shimada K, Kimura S, Oka S : (1→3)- β -D-galcan as a quantitative serological marker for Pneumocystis carinii pneumonia. Clin Diagn Lab Immunol 1996 ; 3 : 197—9.
- 6) 鈴木謙三, 鎌田憲子, 阿部克巳, 横山佳明, 牛見尚史, 寺田一志, 他 : AIDSにおけるカリニ肺炎の画像の多様性. 臨床放射線 1999 ; 44 : 59—66.
- 7) 国立感染症研究所 : 感染症発生動向調査. 感染症情報センターホームページ 2006.

Two Cases of AIDS Diagnosed by Onset of Interstitial Pneumonia

Hirochiyo SAWAGUCHI¹⁾, Hirokazu NAKAJIMA¹⁾, Sigenori NAKAJIMA¹⁾ & Mitsuru KONISHI²⁾¹⁾Department of Respiratory and Allergy medicine, Kinki University of Medicine Nara Hospital,²⁾Center for Infectious disease, Nara Medical University

Case 1: A 35-year-old man admitted for fever and respiratory failure during several weeks was found in chest computed tomography (CT) to have interstitial pneumonia, and the plasma β -D-glucan level indicated *Pneumocystis jirovecii* pneumonia. Psoriasis from second-stage syphilis raised the suspicion of HIV infection. Serum anti-HIV-1 antibody proved positive and CD4-positive lymphocytes in peripheral blood were 18/ μ L. The man died despite treatment. Autopsy confirmed *P. jirovecii* pneumonia.

Case 2: A 28-year-old man seen for a fever and respiratory failure was found in chest CT to have mild interstitial pneumonia. We checked for hypersensitivity pneumonitis, *Mycoplasma pneumoniae* pneumonia, etc. The plasma β -D-glucan level indicated possible *P. jirovecii* pneumonia and immunodeficiency. Serum anti-HIV-1 antibody proved positive and CD4-positive lymphocytes in peripheral blood were 34/ μ L. The man was treated successfully, using trimethoprim with sulfamethoxazole for his interstitial pneumonia. His clinical symptoms were compatible with *P. jirovecii* pneumonia.

P. jirovecii pneumonia with AIDS may present with more subacute or subtle symptoms than other immunosuppressive diseases, making it difficult to diagnose. Medical professionals should thus make it a point to familiarize themselves with AIDS prevention.

(J.J.A. Inf. D. 81 : 67~71, 2007)

研究成果の刊行に関する一覧表

平成 19 年度 信州大学医学部附属病院 内視鏡診療部 山崎喜隆

雑誌

発表者氏名	論文タイトル名	発表誌名	巻号	ページ	出版年
Mari Sasabayashi, Md; Yoshitaka Yamazaki, Md, PhD; Kenji Tsushima, MD, PhD Orié Hatayama, MD; and Tadashi Okabe, MD	Usefulness of Bronchoscopic Microsampling To Detect the Pathogenic Bacteria of Respiratory Infection	CHEST	131	474-479	2007
Sumiko Yoshikawa, MD, Kenji Tsushima, MD,PhD, Masanori Yasuo, MD, PhD, Keisaku Fujimoto, MD, PhD, Keishi kubo, MD, PhD, Toshiko Kumagai, PhD, and Yoshitaka Yamazaki, MD,phD	Hypersensitivity Pneumonitis Caused by Penicillium citrinum, not Enoki spores	AMERICAN JOURNAL OF INDUSTRIAL MEDICINE	50	1010-1017	2007

Usefulness of Bronchoscopic Microsampling To Detect the Pathogenic Bacteria of Respiratory Infection*

Mari Sasabayashi, MD; Yoshitaka Yamazaki, MD, PhD;
Kenji Tsushima, MD, PhD; Orié Hatayama, MD; and Tadashi Okabe, MD

Background: Bronchoscopic microsampling (BMS) is a method in which a device consisting of a wire with a polyester probe at the tip is used to collect bronchial epithelial lining fluid with bronchoscopy. In this study, we bacteriologically investigated sample collection using BMS to incorporate BMS into diagnosis of respiratory infection.

Methods: Strains of *Streptococcus pneumoniae*, *Haemophilus influenzae*, *Pseudomonas aeruginosa*, and *Mycobacterium avium* complex (MAC), were used for experiments. In the standard sampling procedure using BMS, the probe coming out of the sheath was immersed in approximately 6×10^6 cfu/mL bacterial suspension for 30 s and cut into a tube containing 1 mL of normal saline solution. The tube was stirred for 1 min using a vortex. The sampling rate was calculated by the following equation: (actual amount of bacteria collected by BMS [colony forming units per milliliter])/(bacterial amount in suspension for sampling [colony forming units per milliliter]) \times 100 (percentage).

Results: The sampling rate of *S pneumoniae*, *H influenzae*, and MAC showed no significant difference among three bacteria, but the sampling rate of *P aeruginosa* was higher. The shortened time of sampling, stirring, and the reduced bacterial amount in the suspension (1/100) did not significantly affect the rates of standard procedure. In contrast, in comparison with a protected specimen brush (PSB), the recoveries of *S pneumoniae*, *H influenzae*, and MAC using PSB were significantly lower than those by BMS, but the recovery of *P aeruginosa* was not significantly different.

Conclusion: This *in vitro* study might suggested the usefulness of BMS as a new diagnostic technique capable of quantitative and stable sampling. (CHEST 2007; 131:474–479)

Key words: BAL; bronchial epithelial lining fluid; bronchoscopic microsampling; protected specimen brush

Abbreviations: BMS = bronchoscopic microsampling; ELF = epithelial lining fluid; MAC = *Mycobacterium avium* complex; PSB = protected specimen brush; VAP = ventilator-associated pneumonia

Bacteriologic tests such as sputum culture and smear are important particularly for the diagnosis of bacterial pneumonia among respiratory infections. In contrast, for patients with specific patho-

logic conditions, such as severe pneumonia and ventilator-associated pneumonia (VAP), bronchoscopic detection of the pathogen is recommended.^{1–5} BAL used for this test is prepared by infusing 50 to

*From the Departments of Pulmonary and Infectious Diseases (Drs. Sasabayashi, Tsushima, and Hatayama), Endoscopy (Dr. Yamazaki), and Laboratory Medicine (Dr. Okabe), Shinshu University School of Medicine, Matsumoto, Japan.

Dr. Yamazaki was partially supported by a research grant-in-aid from the Japanese Foundation for Research and Promotion of Endoscopy (2006). The other authors have no conflicts of interest to disclose.

Manuscript received April 18, 2006; revision accepted August 31, 2006.

Reproduction of this article is prohibited without written permission from the American College of Chest Physicians (www.chestjournal.org/misc/reprints.shtml).

Correspondence to: Yoshitaka Yamazaki, MD, PhD, Department of Endoscopy, Shinshu University School of Medicine, Asahi, Matsumoto, 390-8621, Japan.

DOI: 10.1378/chest.06-0989

150 mL of normal saline solution through a bronchoscope, and collecting the saline solution with bacteria. Bacteria are collected by lavage of the bronchus over the alveolar area, but lavage is frequently contaminated with oral indigenous bacteria. In the diagnosis of VAP, diagnostic criteria based on bacterial amounts are employed to exclude oral and skin indigenous bacteria. Bacteria present at concentrations of $\geq 1 \times 10^3$ cfu/mL in a protected specimen brush (PSB) sample and/or $\geq 1 \times 10^4$ cfu/mL in BAL are considered to be pathogenic. The level in BAL required for diagnosis is one-order higher, suggesting that PSB is more useful.^{2,6}

There have been some reports⁴⁻⁷ on the usefulness of PSB for the diagnosis of VAP. Characteristics of PSB are as follows: (1) the sampling brush is covered by a sheath, and (2) the tip of the sheath is plugged, which reduces contamination by indigenous bacteria even though the brush is inserted through the channel for forceps of a bronchoscope. Bronchoscopic microsampling (BMS) is covered by a sheath but not plugged.

Since PSB is capable of sampling pus components from lesions by inserting the brush with bronchoscopic guidance, it may increase the amount of sampled bacteria in clinical cases.⁷ Wimberly et al⁷ described that the weight determinations of PBS before and after based on quantitative cultures indicated that the brush accumulates approximately 0.001 mL (1 μ L) of sample. It is possible that the brush may accumulate different quantities of purulent secretions. However, even a 10-fold variation in specimen size would give a difference of only one log unit with quantitative bacterial counts.

BMS is a new procedure for bronchoscopic diagnosis, capable of collecting local bronchial epithelial lining fluid (ELF).⁸⁻¹⁰ A polyethylene-absorbable probe 30 mm in length and 1.1 mm in diameter is attached to a wire tip, and the wire is stored in a plastic guide sheath (Fig 1). BMS is performed while observing the bronchial lumen using a bronchofiberscope; when the target site is reached, the probe is pushed out of the sheath tip and absorbs bronchial epithelial fluid present in the bronchial lumen. Ishizaka et al⁸⁻¹⁰ analyzed various cytokines in patients with ARDS using this method, and found that BMS was as useful as BAL for effective and less-invasive sampling of bronchial ELF.

In this study, we bacteriologically investigated the possibility of applying BMS for respiratory infections, paying attention to two advantages of BMS: (1) effective adsorption of bronchial ELF, and (2) less invasiveness for patients. We performed a basic bacteriologic study of microsampling of typical etiologic bacteria of community-acquired pneumonia: *Streptococcus pneumoniae*; *Haemophilus influenzae*




FIGURE 1. A polyethylene-absorbable microsampling probe (30 mm in length and 1.1 mm in diameter) is attached to a wire tip (top, a). The PSB is a brush covered with a sheath (bottom, b).

*zae*¹¹⁻¹³, *Pseudomonas aeruginosa*, frequently detected in hospital-acquired pneumonia¹⁴⁻¹⁶, and *Mycobacterium avium* complex (MAC), which has recently been increasingly detected in middle-aged women.^{17,18}

MATERIALS AND METHODS

Bacterial Strains and Culture

The bacterial strains used were *S pneumoniae* (IID553 [NYS-DHDP-2]), *H influenzae* (ATCC9833), *P aeruginosa* (ATCC27107), and MAC 104 strain (provided by Dr. L.E. Bernudez, Oregon State University). Cryopreserved (-78°C) bacteria were thawed, and *S pneumoniae* and *P aeruginosa* were cultured on a blood agar plate (Becton Dickinson; Franklin Lakes, NJ), *H influenzae* was cultured on a chocolate agar plate (Becton Dickinson), and MAC was cultured on Middlebrook 7H11 medium (Becton Dickinson) at 37°C in 5% CO_2 . *S pneumoniae* and *P aeruginosa* were subcultured overnight and used. MAC was subcultured for 10 days and used.

Preparation of Bacterial Suspension

S pneumoniae, *H influenzae*, *P aeruginosa*, and MAC were collected using a cotton swab and suspended in a plastic tube containing 3 mL of normal saline solution. The turbidity was adjusted using saline solution and an McF assay meter (bio-Merieux; Marcy l'Etoile, France), and the concentration of bacterial suspensions for sampling was adjusted to approximately 6×10^6 cfu/mL. The suspension (2 mL) was added to a 3-mL plastic tube, and 100 μ L was collected using a pipette and combined with 900 μ L of saline solution for 1/10 dilution, and 100 μ L of each dilution was inoculated and homogeneously spread using a Conradi stick on an agar plate. We particularly paid attention to the two points listed below: (1) the probe was completely immersed in bacterial suspension, and (2) all procedures were performed on a clean bench to exclude contamination.

Standard Procedure

A probe (polyethylene, 30 mm in length, 1.1 mm in diameter) attached to the tip of a microsampling device (BC-401C; Olym-

pus; Tokyo, Japan) was pushed 5 cm out of the sheath. The probe was placed in the bacterial suspension, pulled out after 30 s, and stored back in the sheath. The probe was then pushed out of the sheath, and the sponge region was cut with ethanol-disinfected scissors. The probe was placed in 1 mL of saline solution in an Eppendorf tube. The tube was immediately stirred for 1 min using a vortex. Serial dilutions were prepared and inoculated on agar plates, and colonies were counted. The bacterial sampling rate was calculated using the following equation: BMS sampling rate = actually sampled bacterial amount (colony forming units per milliliter)/bacterial amount in suspension for sampling (colony forming units per milliliter) × 100 (percentage).

Revision of the Study Parameters

Sampling and Stirring Times: Shortening of the treatment time in the standard BMS method was investigated. The duration of immersing a probe into bacterial suspension for sampling (approximately 6×10^6 cfu/mL) was shortened to 5 s (30 s in the standard method). Next, the stirring time of the probe after sampling bacteria using a vortex was shortened to 10 s (1 min in the standard method).

Sampling Amount of Bacteria: To investigate whether BMS is capable of stably collecting bacteria when the sampling amount is changed, the bacterial suspension for sampling was diluted to 1/100. This solution was also subjected to colony counting. The sampling time was 30 s, and stirring, preparation of serial dilutions, and colony counting were performed by the standard procedure.

Time of Standing (Storage): Since samples collected by BMS may not be processed immediately after sampling in clinical application, the stability of bacteria sampled by BMS within the storage time was investigated. After sampling by the standard procedure, the probe was kept in an Eppendorf tube at room temperature for 3 h, followed by stirring, preparation of serial dilutions, and colony counting by the standard procedure.

Surfactant: It is important to investigate any possible inconsistency in the bacterial amount due to bacterial adhesion to the sampling device, which reduces the apparent bacterial number. Physiologic saline solution containing 0.1% surfactant (Tween80; Sigma; St. Louis, MO) was prepared to inhibit bacterial adhesion to probes and tubes. Tween solution (1 mL) was added to the Eppendorf tube prepared by the standard procedure and stirred for 1 min using a vortex, followed by preparation of serial dilutions with Tween solution and colony counting.

Current Test Using a PSB

The PSB is a device with a brush covered with a sheath and distal occlusion composed of polyethylene glycol. In the present study, we used a sheath brush (disposable cytology brush, BC-202D-2010; Olympus) immersed in a bacterial suspension for sampling (6×10^6 cfu/mL) for 30 s and stored in the sheath. The brush was then pushed out of the sheath, cut with ethanol-disinfected scissors, and placed in an Eppendorf tube containing 1 mL of saline solution. After stirring, the preparation was serially diluted, and colonies were counted by the standard procedure.

Statistical Analysis

All experiments were repeated three times, and the means ± SD were calculated. For between-group comparison, the Mann-Whitney *U* test was used; $p < 0.05$ was regarded as significant.

RESULTS

Investigation of the Standard Procedure

The bacterial amount in the suspension for sampling was $5.90 \pm 2.42 \times 10^5$ cfu/mL in *S pneumoniae* suspension, $6.87 \pm 4.04 \times 10^6$ cfu/mL in *H influenzae* suspension, $7.83 \pm 1.80 \times 10^6$ cfu/mL in *P aeruginosa* suspension, and $3.47 \pm 1.97 \times 10^6$ cfu/mL in MAC suspension. The bacterial amounts collected on the BMS probe were $9.10 \pm 4.19 \times 10^4$, $9.17 \pm 4.91 \times 10^4$, $23.7 \pm 8.62 \times 10^4$, and $4.27 \pm 3.57 \times 10^4$ cfu/mL, respectively. The sampling rates were $1.41 \pm 0.02\%$, $1.40 \pm 0.17\%$, $3.29 \pm 1.64\%$, and $1.22 \pm 0.53\%$, respectively, showing no significant difference among the *S pneumoniae*, *H influenzae*, and MAC sampling rates, but the *P aeruginosa* sampling rate was significantly higher than the other three species ($p < 0.05$) [Table 1]. Colonies formed on agar medium were carefully observed, but no contaminating environmental bacteria or fungi were noted.

BMS Under Various Conditions

Sampling Time: Sampling for 5 s was investigated in comparison with the sampling time (30 s) in the standard procedure. The *S pneumoniae*, *H influenzae*, *P aeruginosa*, and MAC sampling rates were $1.46 \pm 0.22\%$, $1.65 \pm 0.34\%$, $3.32 \pm 0.90\%$, and $1.32 \pm 0.35\%$, respectively, showing that the *P aeruginosa* sampling rate was significantly higher than the others ($p < 0.05$), but no significant difference was noted in the sampling rate between the 5-s and standard sampling times.

Changes in the Bacterial Amount in Suspension for Sampling: The investigation was performed using 1/100-diluted bacterial suspensions for sampling. The amounts of *S pneumoniae*, *H influenzae*, *P aeruginosa*, and MAC in the dilutions were $5.57 \pm 3.41 \times 10^4$, $1.97 \pm 0.42 \times 10^4$, $4.17 \pm 1.31 \times 10^4$, and $1.67 \pm 0.60 \times 10^4$ cfu/mL, respectively. The amounts of bacteria collected on the probe were $12.9 \pm 8.15 \times 10^2$, $7.37 \pm 3.07 \times 10^2$, $5.83 \pm 0.80 \times 10^2$, and $1.23 \pm 0.97 \times 10^2$ cfu/mL, respectively. The sampling rates were $2.40 \pm 1.23\%$, $3.88 \pm 1.80\%$, $1.86 \pm 0.58\%$, and $0.66 \pm 0.32\%$, respectively, showing no significant difference among the four species (Table 2).

Standing for 3 h After Sampling: The *S pneumoniae*, *H influenzae*, *P aeruginosa*, and MAC sampling rates were $1.55 \pm 0.40\%$, $1.63 \pm 1.00\%$, $3.46 \pm 1.03\%$, and $1.46 \pm 0.92\%$, respectively, showing that the *P aeruginosa* sampling rate was

Table 1—Sampling Rate Comparing Standard and Revised BMS Procedures*

Variables	Bacterial Amount		
	Actual Sample, ×10 ⁴ cfu/mL	Suspension, ×10 ⁶ cfu/mL	Sampling Rate, %
Standard sampling			
<i>S pneumoniae</i>	5.90 ± 2.42	9.10 ± 4.19	1.41 ± 0.22†
<i>H influenzae</i>	6.87 ± 4.04	9.17 ± 4.91	1.40 ± 0.17†
<i>P aeruginosa</i>	7.83 ± 1.80	23.7 ± 8.62	3.29 ± 1.64
MAC	3.47 ± 1.97	4.27 ± 3.57	1.22 ± 0.53†
Shorten sampling time for 5 s			
<i>S pneumoniae</i>	4.40 ± 3.00	26.9 ± 35.0	1.46 ± 0.22†
<i>H influenzae</i>	3.40 ± 2.86	5.40 ± 3.96	1.65 ± 0.34†
<i>P aeruginosa</i>	6.30 ± 0.70	16.2 ± 12.7	3.32 ± 0.90
MAC	3.37 ± 3.67	1.40 ± 0.44	1.32 ± 0.35†
Treatment with 0.1% Tween HBSS			
<i>S pneumoniae</i>	4.37 ± 1.93	3.73 ± 1.93	1.94 ± 0.65†
<i>H influenzae</i>	3.73 ± 1.93	6.87 ± 4.45	1.79 ± 0.35†
<i>P aeruginosa</i>	7.63 ± 1.46	25.0 ± 13.7	4.64 ± 0.93
MAC	3.47 ± 1.97	5.77 ± 1.97	1.97 ± 0.82†
Keep for 3 h in room condition after sampling			
<i>S pneumoniae</i>	9.57 ± 2.96	14.0 ± 2.00	1.55 ± 0.40†
<i>H influenzae</i>	4.13 ± 0.51	7.03 ± 5.19	1.63 ± 1.00
<i>P aeruginosa</i>	8.67 ± 1.27	30.3 ± 11.9	3.46 ± 1.03
MAC	1.70 ± 0.17	14.4 ± 22.2	1.46 ± 0.92†
Shorten vortex time for 10 s			
<i>S pneumoniae</i>	6.83 ± 1.68	9.37 ± 3.15	1.47 ± 0.15†
<i>H influenzae</i>	3.10 ± 0.90	9.20 ± 7.00	2.70 ± 1.60†
<i>P aeruginosa</i>	7.70 ± 1.57	24.0 ± 13.1	3.37 ± 2.25
MAC	1.37 ± 0.21	1.57 ± 0.91	1.37 ± 0.72

*Data are presented as mean ± SD. HBSS = Hank's buffered salt solution.

†p < 0.05; the sampling rate of *P aeruginosa* was significantly higher than those of *S pneumoniae*, *H influenzae*, or MAC in each group.
‡p < 0.05; the sampling rates of each bacteria were higher than those in the standard sampling.

significantly higher among the four species, but no significant differences from the those obtained by the standard procedure were noted.

Surfactant (0.1% Tween Solution): The *S pneumoniae*, *H influenzae*, *P aeruginosa*, and MAC sampling rates were 1.94 ± 0.65%, 1.79 ± 0.35%, 4.64 ± 0.93%, and 1.97 ± 0.82%, respectively, showing that the *P aeruginosa* sampling rate was significantly higher among the four species (p < 0.05), but no significant differences from the those obtained by the standard procedure were noted.

Table 2—Sampling Rate of Thinner Bacterial Solution Using BMS*

Variables	Bacterial Amount		
	Actual Sample, ×10 ⁴ cfu/mL	Suspension, ×10 ⁶ cfu/mL	Sampling Rate, %
Decreased sampling bacteria (1:100)			
<i>S pneumoniae</i>	5.57 ± 3.41	12.9 ± 8.15	2.40 ± 1.23
<i>H influenzae</i>	1.97 ± 0.42	7.37 ± 3.07	3.88 ± 1.80
<i>P aeruginosa</i>	4.17 ± 1.31	5.83 ± 0.80	1.86 ± 0.58
MAC	1.67 ± 0.60	1.23 ± 0.97	0.66 ± 0.32†

*Data are presented as mean ± SD.

†p < 0.05; the sampling rate of MAC was significantly lower than those of other bacteria.

Stirring Time Using a Vortex: The stirring time was shortened to 10 from 60 s in the standard procedure. The *S pneumoniae*, *H influenzae*, *P aeruginosa*, and MAC sampling rates were 1.47 ± 0.15%, 2.70 ± 1.60%, 3.37 ± 2.25%, and 1.37 ± 0.72%, respectively, showing no significant difference from those obtained by the standard procedure.

Comparison With PSB: When PBS was used for sampling, the *S pneumoniae*, *H influenzae*, *P aeruginosa*, and MAC sampling rates were 0.09 ± 0.02%, 0.42 ± 0.33%, 2.85 ± 0.48%, and 0.04 ± 0.02%, respectively, showing that the *S pneumoniae*, *H influenzae*, and MAC sampling rates obtained by the standard BMS procedure were significantly higher (p < 0.05), but the *P aeruginosa* sampling rate was not significantly different between sampling using BMS and PSB (Table 3).

DISCUSSION

This *in vitro* bacteriologic study was performed to introduce BMS as a diagnostic aid for infectious

Table 3—Sampling Rate of PSB Procedure*

Variables	Bacterial Amount		
	Actual Sample, ×10 ⁴ cfu/mL	Suspension, ×10 ⁶ cfu/mL	Sampling Rate, %
PSB			
<i>S pneumoniae</i>	7.80 ± 1.05	0.69 ± 0.16	0.09 ± 0.02††
<i>H influenzae</i>	4.33 ± 0.58	1.70 ± 1.26	0.42 ± 0.33††
<i>P aeruginosa</i>	8.10 ± 1.37	22.7 ± 1.15	2.85 ± 0.48
MAC	5.4 ± 6.59	0.22 ± 0.24	0.04 ± 0.02††§

*Data are presented as mean ± SD.

†p < 0.05; the sampling rate of *P aeruginosa* was significantly higher than that of *S pneumoniae*, *H influenzae*, or MAC in each group.

††p < 0.05; the sampling rate of each bacteria was higher than that in the standard sampling.

§p < 0.05; the sampling rate of MAC was significantly lower than that of *S pneumoniae* and *H influenzae*.