

References

1. Lin HY, Wu KY. Tentative surgical repair of leaking filtering bleb with amniotic membrane transplantation—a case report. *Kaohsiung J Med Sci* 2001;17:495-498.
2. Kee C, Hwang JM. Amniotic membrane graft for late-onset glaucoma filtering leaks. *Am J Ophthalmol* 2002;133:834-835.
3. Tseng SC, Prabhasawat P, Barton K, Gray T, Meller D. Amniotic membrane transplantation with or without limbal allografts for corneal surface reconstruction in patients with limbal stem cell deficiency. *Arch Ophthalmol* 1998;116:431-441.
4. Heiligenhaus A, Bauer D, Meller D, Steuhl KP, Tseng SC. Improvement of HSV-1 necrotizing keratitis with amniotic membrane transplantation. *Invest Ophthalmol Vis Sci* 2001;42:1969-1974.

The Effect of Once-daily Levobunolol on Intraocular Pressure in Normal-tension Glaucoma

Levobunolol hydrochloride is a nonselective β_1 - and β_2 -adrenoceptor antagonist. A once-daily instillation of levobunolol 0.5% eyedrops was reported to reduce intraocular pressure (IOP) significantly in patients with primary open-angle glaucoma (POAG) or ocular hypertension.¹⁻³ In a recent population-based glaucoma prevalence survey, normal-tension glaucoma (NTG) has been found to be one of the most dominant types of glaucoma in Japan.⁴ Therefore, having detailed information about the regimen for NTG treatment is very important. There are no reports about the effects of levobunolol eyedrops on IOP in patients with NTG. We report the effectiveness on IOP and the safety of once-daily levobunolol eyedrops in patients with NTG.

Case Reports

In our study at the Inouye Eye Hospital, we enrolled 33 consecutive NTG patients (12 men and 21 women, 33 eyes), with IOP 15-20 mmHg without glaucoma treatment. Patient age was 50.4 ± 12.8 years (mean \pm SD, range 25-82 years). Patient refractive errors were -3.6 ± 3.6 D (range -10.5 to +3.0 D). Mean deviation by Humphrey visual field examination was -5.7 ± 4.9 dB (range -14.2 to -0.4 dB).

Patients were instructed to instill one drop of levobunolol 0.5% into each affected eye in the morning. If the patient used levobunolol in both eyes, we selected the right eye for inclusion in this study. IOP was measured every month for 6 months at almost the same time in each patient with a Goldmann applanation tonometer. Fourteen patients were measured in the morning and 19 in the afternoon. The IOP just before and just after levobunolol treatment and the percentage of IOP reduction were recorded. Adverse reactions were monitored by routine slit-lamp biomi-

Table 1. The percentage of eyes in which intraocular pressure was reduced by more than 20% and 30% in 3 and 6 months

Reduced rate	3 months (%)		6 months (%)	
	Achieved	Not achieved	Achieved	Not achieved
20%	37.0	63.0	40.0	60.0
30%	25.9	74.1	25.0	75.0

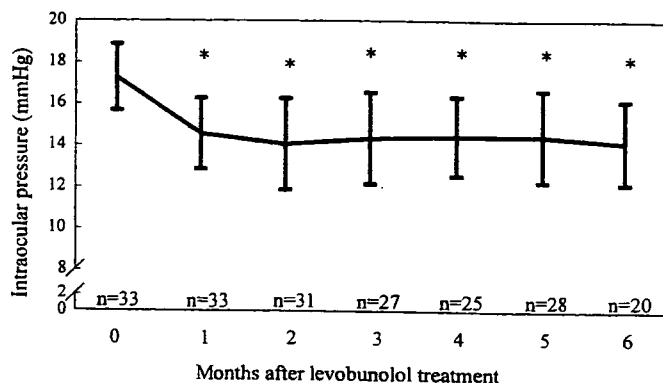


Figure 1. Before (month 0) and after levobunolol treatment mean intraocular pressure values (*significant value at $P < 0.0001$, analysis of variance and paired t test).

croscopy and by questioning patients about their ocular and systemic conditions. All patients gave their informed consent to participate in the study. Changes in the IOP were evaluated using analysis of variance (ANOVA) and the paired t test.

The mean IOP was 17.2 ± 1.6 mmHg before treatment (Fig. 1). After treatment, IOP was 14.5 ± 1.7 mmHg at 1 month, 14.0 ± 2.2 mmHg at 2 months, 14.3 ± 2.2 mmHg at 3 months, 14.4 ± 1.9 mmHg at 4 months, 14.4 ± 2.2 mmHg at 5 months, and 14.1 ± 2.0 mmHg at 6 months. These data were significantly lower than those before treatment ($P < 0.0001$). The percentage of eyes with IOP reduction of more than 20% and 30% is shown in Table 1.

Superficial punctate keratitis (two eyes) and hyperemia (one eye) were observed in the patients in this study. Three patients were withdrawn for insufficient IOP reduction.

Comments

In patients with POAG or ocular hypertension, the IOP reduction after levobunolol treatment has been reported as 4.5-7.0 mmHg.¹⁻³ This is a higher reduction than reported in this study. This difference could be due to the difference in glaucoma type or to the baseline IOP. In the patients with NTG in this study, the reduction values (2.7-3.2 mmHg) and rates (15.5%-18.4%) of IOP after levobunolol treatment were higher than those (0.8-0.9 mmHg and 5.4%-6.1%,

respectively) reported after carteolol treatment.⁵ The percentage of eyes with IOP reduction of more than 20% and 30% in this study was also higher than in this previous report.⁵

Ocular adverse reactions were seen in three patients (9.1%), which is more frequent than reported in a previous study (3.0%).² There was only one patient (3.0%) unable to continue levobunolol treatment owing to ocular adverse reactions. Since neither heart rate nor systemic blood pressure was monitored in this study, we cannot report on the effects of levobunolol on heart rate or systemic blood pressure. However, it is certain that significant systemic adverse reactions were not induced by levobunolol treatment.

Levobunolol was effective in reducing IOP and could be safely used in patients with NTG for at least 6 months.

Key Words: adverse reaction, intraocular pressure, levobunolol, normal-tension glaucoma

Kenji Inoue^{1,2}, Tsukasa Ezure¹, Masato Wakakura¹, Jiro Inoue¹, and Goji Tomita²

¹Inouye Eye Hospital, Tokyo, Japan; ²Department of Ophthalmology, University of Tokyo Graduate School of Medicine, Tokyo, Japan

Received: December 26, 2003 / Accepted: March 11, 2004

Correspondence to: Kenji Inoue, Inouye Eye Hospital, 4-3 Kanda-Surugadai, Chiyoda-ku, Tokyo 101-0062, Japan
e-mail: inoue-k@fd5.so-net.ne.jp

DOI 10.1007/s10384-004-0139-y

References

1. Wandel T, Charap AD, Lewis RA, et al. Glaucoma treatment with once-daily levobunolol. *Am J Ophthalmol* 1986;101:298-304.
2. Kitazawa Y, Azuma I, Shirato S, et al. Late phase II clinical study of AG-901 ophthalmic solution in primary open-angle glaucoma or ocular hypertension: dose-determining study. *Atarashii Ganka (J Eye)* 1999;16:1169-1177.
3. Rakofsky SI, Melamed S, Cohen JS, et al. A comparison of the ocular hypotensive efficacy of once-daily and twice-daily levobunolol treatment. *Ophthalmology* 1989;96:8-11.
4. Iwase A. Prevalence of normal-tension glaucoma: the Tajimi study. *Atarashii Ganka (J Eye)* 2003;20:1343-1349.
5. Maeda H, Tanaka Y, Yamamoto M, Mizokami K. Effect of topical carteolol on visual function in normal-tension glaucoma. *Nippon Ganka Gakkai Zasshi (J Jpn Ophthalmol Soc)* 1997;101:227-231.

Visual Field Defects Associated with Sick Sinus Syndrome

Several studies suggest that optic nerve head ischemia is a risk factor for normal-tension glaucoma,¹⁻³ although the pathogenesis of normal-tension glaucoma remains unknown. In patients with normal-tension glaucoma, inappropriate vasoconstriction or increased vascular resistance

at the optic disk causes tissue death at the optic head.¹⁻³ In addition, systemic hypotension as a risk factor for glaucoma has been reported.^{4,5} Glaucoma patients having visual field deterioration show significantly lower nocturnal blood pressure than patients having stable visual fields. In the present report, we describe a case of normal-tension glaucoma with low blood pressure and bradycardia caused by sick sinus syndrome. Automated threshold perimetry has been carried out for 11 years after implantation of an electric cardiac pacemaker.

Case Report

A 49-year-old woman presented with visual disturbance in both eyes in August 1992. She claimed that the visual disturbance was not acute, and that it progressed chronically. The patient had a long history of sudden syncopal attacks before the visual symptom, and exhibited typical advanced glaucomatous changes of bilateral optic disks (Fig. 1). Automated static threshold perimetry (Humphrey 30-Humphrey Zeiss, Dublin, CA, USA) revealed advanced glaucomatous defects corresponding to the glaucomatous changes seen in the optic disks (Fig. 2A). The mean deviation was -20.52 dB in the right eye and -20.51 dB in the left eye in September 1992. The diurnal variation in her intraocular pressure was maintained bilaterally between 12 and 14 mmHg. Her heart rate was always less than 40 beats/min. The systolic and diastolic blood pressures were 70 and 40 mmHg, respectively. Magnetic resonance imaging of the brain revealed several small infarctions in the white matter of the cerebrum, indicating hypoxia of the brain. Electrocardiography exhibited frequent cardiac arrest lasting 2 to 3 s; therefore, sick sinus syndrome was diagnosed in this patient. An electric cardiac pacemaker was implanted in September 1992. Thereafter, the patient's heart rate was maintained at about 70 beats/min. Her systolic and diastolic blood pressure increased to 120 and 70 mmHg, respectively. The patient has been followed up for 11 years without medication for glaucoma. The diurnal variation of her intraocular pressure has remained between 12 and 14 mmHg. Visual field defects in both eyes have not progressed even without intraocular pressure control for the 11 years since the implantation of the pacemaker (Fig. 2B). The mean deviation was -20.77 dB in the right eye and -22.72 dB in the left eye in May 2003.

Comments

Visual field defects in this case did not result from ocular hypertension, because the visual field defects have not progressed even without intraocular pressure control for 11 years. The visual symptoms did not have acute onset, and progressed chronically. Therefore, it is not probable that the glaucomatous changes of visual field defect and optic disks in this case resulted from anterior ischemic optic neuropathy. These findings suggest that ophthalmic changes

Galina Dimitrova
Goji Tomita
Satoshi Kato

Correlation between capillary blood flow of retina estimated by SLDF and circulatory parameters of retrobulbar blood vessels estimated by CDI in diabetic patients

Received: 25 January 2004
Revised: 6 August 2004
Accepted: 7 October 2004
Published online: 19 January 2005
© Springer-Verlag 2005

Abstract *Background:* The aim of this study was to investigate the correlation between the recordings of scanning laser Doppler flowmetry (SLDF) of the retina and the recordings of color Doppler imaging (CDI) of the retrobulbar circulatory parameters in diabetic patients without diabetic retinopathy. *Methods:* Twenty-three diabetic patients without diabetic retinopathy were evaluated using SLDF for the apparent retinal circulation and using CDI for the apparent retrobulbar circulation in the central retinal artery, the central retinal vein and the short posterior ciliary artery. The circulatory parameters estimated in the retinal tissue using SLDF were velocity, volume and flow. The Circulatory parameters that were recorded using the CDI method were peak systolic velocity (PSV), end-diastolic velocity (EDV), mean velocity (MV), pulsatility (PI) and resistivity index (RI). We obtained the correlation coefficients between parameters of SLDF and CDI. Multiple regression analysis was performed with “flow” parameter of SLDF recordings as a dependent variable and all estimated CDI parameters as independent variables. Multiple linear regression was also performed, including the “flow” parameter of SLDF recordings as a dependent variable and PI of the CDI parameters of all the

measured blood vessels as independent variables. *Results:* The “velocity” parameter of SLDF was significantly correlated with the PI in the central retinal artery ($P=0.02$), PI and RI in the central retinal vein ($P=0.01$; $P=0.01$) and the PSV, MV, PI and RI in the short posterior ciliary artery, as recorded by CDI ($P=0.003$; $P=0.02$; $P=0.002$; $P=0.01$). The “volume” parameter of SLDF was significantly correlated with the PI and RI in the central retinal vein ($P=0.03$; $P=0.03$) and the PSV in the short posterior ciliary artery ($P=0.03$), as recorded by CDI. The “flow” parameter of SLDF was significantly correlated with the PI and RI in the central retinal vein ($P=0.01$; $P=0.01$) and the PSV, MV, PI and RI in the short posterior ciliary artery ($P=0.003$; $P=0.03$; $P=0.002$; $P=0.01$) as measured by CDI. The multiple regression analysis was statistically non-significant ($P=0.86$). The multiple linear regression analysis indicated that from among the PI of the evaluated blood vessels, the PI of the short posterior ciliary artery was the most significant predictor of the “flow” parameter of SLDF ($P=0.01$). *Conclusion:* This study suggests a positive correlation between the recordings of SLDF of the retinal tissue and the retrobulbar circulatory parameters of the CDI in diabetic patients without diabetic retinopathy.

G. Dimitrova
Clinic for Eye Diseases,
Clinical Center,
Skopje, Macedonia

G. Tomita · S. Kato
Department of Ophthalmology,
Tokyo University Hospital,
Tokyo, Japan

G. Dimitrova (✉)
Vodnjanska 17,
1000 Skopje, Macedonia
e-mail: galina@sonet.com.mk
Tel.: +389-2-3161714
Fax: +389-2-3161714

Introduction

The circulation in the diabetic eye has been investigated using various methods [8, 12, 15, 18, 30]. However, reports sometimes gave contradictory results, probably because of the difference in the characteristics of the blood flow at the various points of measurement, as well as the difference of the methods that were used.

Scanning laser Doppler flowmetry (SLDF) is among the most recent methods for evaluation of blood flow in the retinal tissue [19]. It has been used in many conditions of ophthalmic pathology, including diabetic retinopathy (DR) [2, 20, 25]. On the other hand, color Doppler imaging (CDI) technique is a method that evaluates blood flow velocity based on ultrasound Doppler shift, which has been widely used in various medical fields [7].

To our knowledge, no studies have reported the correlation between SLDF parameters and CDI in diabetic subjects. We believe that it is of interest to investigate such a correlation between the parameters of the two methods that will facilitate the interpretation of further studies on ocular circulation in diabetes. Hence, as the first step, we performed this study to investigate the correlation between the retrobulbar blood circulation parameters estimated by CDI and the apparent retinal tissue blood flow parameters recorded by SLDF in diabetic patients without diabetic retinopathy.

Materials and methods

Patient selection

The study was performed in accordance with the standards of the ethics committee of the University of Tokyo School of Medicine. All subjects were informed about the nature of the study and gave consent to be included. The research followed the tenets of the Declaration of Helsinki.

Twenty-three diabetic subjects without diabetic retinopathy were included in this study (Table 1). The subject group included 18 men and five women. The subjects were randomly chosen from among patients who came at the diabetic retinopathy outpatient clinic at the Department of Ophthalmology, the University Hospital of University of Tokyo School of Medicine. Patients with other eye conditions that could affect the blood flow, such as high

Table 1 Clinical characteristics of the patients. *Mean BP* mean blood pressure, *IOP* intraocular pressure, *HgA_{1c}* glycosylated hemoglobin, *SD* standard deviation

	Age	Mean BP (mmHg)	Visual acuity	IOP (mmHg)	HgA _{1c} (mmol/l)	Blood sugar
Mean	59.70	99.18	1.26	15.61	7.16	158.00
SD	8.00	12.21	0.28	2.87	1.34	46.93

degree myopia, maculopathy of any origin, glaucoma, and those with a history of laser treatment or intraocular surgery, were excluded. Patients with cataract were also excluded from the study because of poor visibility of the fundus during recording of SLDF.

Patients underwent assessment of best-corrected visual acuity after standardized refraction. Intraocular pressure (IOP) was measured by Goldman tonometry. Only one (right) eye was included in the study, for both CDI and SLDF recordings. Brachial artery systolic (BP_s) and diastolic (BP_d) blood pressures were determined by an automatic device for measurement of blood pressure in the brachial artery. Mean brachial artery pressure (BP_m) was calculated as follows:

$$BP_m = BP_d + 1/3(BP_s - BP_d). \quad (1)$$

Scanning laser Doppler flowmetry

Scanning laser Doppler flowmetry for evaluating the apparent retinal tissue blood flow was performed using a Heidelberg Retina Flowmeter (Heidelberg Engineering, Germany). The instrumentation has been described elsewhere [19]. In brief, SLDF estimates the Doppler frequency shift in each retinal point with a size of 10×10 μm in a retinal area with a size of 2.7×0.7 mm within 2 s. One observer (GD) did all the recordings. The observer was blinded for the results of CDI when performing the SLDF recordings. The patients were examined in a sitting position.

Retinal blood flow parameters (velocity, volume, flow) were evaluated from four sample areas [superior (*s*), temporal (*t*), inferior (*i*) and nasal (*n*)] from the optic disc. Each sample area measured 10×10 pixels and was 100 pixels away from the optic disc. Mean retinal blood flow values (mv) were then calculated by the following equation:

$$mv = (s + t + i + n)/4. \quad (2)$$

Color Doppler imaging

The CDI recordings were taken using a Powervision SSA-380A (Toshiba, Japan) using a 7-MHz transducer. One investigator (G.D.) performed all the CDI recordings. The method of examination has been described in a previous study [3]. The patients were examined in a sitting posture, which was identical to the posture that patients assumed during the recordings of SLDF. This allowed fewer circulatory alterations as a result of differences in posture. The retrobulbar blood vessels that were examined were: central retinal artery and vein and the short posterior ciliary arteries. We attempted to maintain the Doppler angle as parallel as possible to the measured blood vessels in order to obtain accurate data of the blood velocity. The hemodynamic

parameters that were estimated in the aforementioned blood vessels were: peak systolic blood velocity (PSV), time average mean velocity (MV), end-diastolic velocity (EDV), pulsatility index (PI) and resistivity index (RI).

PI and RI were calculated as follows:

$$PI = (PSV - EDV)/MV, \quad (3)$$

$$RI = (PSV - EDV)/PSV. \quad (4)$$

CDI and SLDF recordings were performed on each patient consecutively.

Statistical analysis

A statistical analysis for the correlation between the blood flow parameters recorded by the two methods was done using Fisher's r (Stat View® Microsoft). Furthermore, we did a multiple regression analysis in which the "flow" parameter of SLDF was a dependent variable, and all the examined retrobulbar blood flow variables (evaluated by CDI) were independent variables (Stat View® Microsoft). We also did a multiple linear regression analysis to determine the relation of the PI indices of all the three examined retrobulbar blood vessels (central retinal artery, central retinal vein and posterior ciliary artery) to the "flow" parameter of SLDF (Excel® Microsoft).

Correlation between systemic blood pressure and CDI and SLDF parameters was also calculated using Fisher's r (Stat View® Microsoft). P Values <0.05 were regarded as having a statistical significance.

Results

Patients' systemic characteristics are presented in Table 1.

The "velocity" parameter of SLDF was significantly correlated with the PI in the central retinal artery, PI and RI in the central retinal vein and the PSV, MV, PI and RI in the short posterior ciliary artery, as measured by CDI (Tables 2, 3, 4).

The "volume" parameter of SLDF was significantly correlated with the PI and RI in the central retinal vein and the PSV in the posterior short ciliary artery as estimated by CDI (Tables 3, 4).

The "flow" parameter of SLDF showed significant correlations with the PI and RI in the central retinal vein and the PSV, MV, PI and RI in the short posterior ciliary artery, as estimated by CDI (Tables 3, 4).

The multiple regression analysis ($R=0.75$, $R^2=0.56$) was statistically non-significant ($P=0.86$) (Table 5). Stepwise elimination led to an optimum model that included only PI of the posterior ciliary artery ($R=0.60$, $R^2=0.36$, $P=0.003$).

Table 2 Coefficient of correlation (r) between central retinal artery circulatory parameters and retinal tissue blood flow parameters. *CRA* central retinal artery, *PSV* peak systolic velocity, *EDV* end diastolic velocity, *MV* time averaged mean velocity, *PI* pulsatility index, *RI* resistivity index

	CRA- PSV	CRA- EDV	CRA- MV	CRA- PI	CRA- RI
Blood velocity	0.33	-0.38	0.09	0.48	0.37
<i>P</i> -value	0.14	0.87	0.69	0.02*	0.09
Blood volume	0.24	-0.01	0.08	0.34	0.26
<i>P</i> -value	0.28	0.97	0.71	0.12	0.25
Blood flow	0.24	-0.01	0.08	0.34	0.26
<i>P</i> -value	0.28	0.97	0.71	0.12	0.25

*Statistically significant difference

Table 3 Coefficient of correlation (r) between central retinal vein circulatory parameters and retinal tissue blood flow parameters. *CRV* central retinal vein, *PSV* peak systolic velocity, *EDV* end diastolic velocity, *MV* time averaged mean velocity, *PI* pulsatility index, *RI* resistivity index

	CRV-PSV	CRV-EDV	CRV-MV	CRV-PI	CRV-RI
Blood velocity	0.37	-0.02	0.23	0.54	0.55
<i>P</i> -value	0.10	0.94	0.31	0.01*	0.01*
Blood volume	0.35	0.02	0.23	0.46	0.47
<i>P</i> -value	0.11	0.92	0.30	0.03*	0.03*
Blood flow	0.38	-0.00	0.24	0.55	0.56
<i>P</i> -value	0.08	0.99	0.28	0.01*	0.01*

*Statistically significant difference

Table 4 Coefficient of correlation (r) between short posterior ciliary artery circulatory parameters and retinal tissue blood flow parameters. *SPCA* short posterior ciliary artery, *PSV* peak systolic velocity, *EDV* end diastolic velocity, *MV* time averaged mean velocity, *PI* pulsatility index, *RI* resistivity index

	SPCA- PSV	SPCA- EDV	SPCA- MV	SPCA- PI	SPCA- RI
Blood velocity	0.60	0.33	0.48	0.61	0.55
<i>P</i> -value	0.003*	0.14	0.02*	0.002*	0.01*
Blood volume	0.45	0.40	0.41	0.29	0.25
<i>P</i> -value	0.03*	0.07	0.06	0.16	0.26
Blood flow	0.60	0.33	0.47	0.60	0.54
<i>P</i> -value	0.003*	0.13	0.03*	0.002*	0.01*

*Statistically significant difference

Table 5 Results of multiple regression analysis in which retinal tissue blood flow (estimated by SLDF) is the dependent variable and the retrobulbar blood flow parameters (estimated by CDI) are independent variables ($R=0.75$, $R^2=0.56$, $P=0.86$). *CRA* central retinal artery, *CRV* central retinal vein, *SPCA* short posterior ciliary artery, *PSV* peak systolic velocity, *EDV* end diastolic velocity, *MV* time averaged mean velocity, *P* pulsatility index, *R* resistivity index, *SLDF* scanning laser Doppler flowmetry, *CDI* color Doppler imaging

Independent variable	Coefficient	<i>p</i> Value
CRA PSV	0.12	0.99
CRA EDV	11.30	0.47
CRA MV	-6.44	0.50
CRA PI	-3.35	0.92
CRA RI	68.71	0.55
CRV PSV	40.08	0.16
CRV EDV	-5.25	0.74
CRV MV	-42.48	0.16
CRV PI	-427.40	0.14
CRV RI	479.65	0.14
SPCA PSV	-4.41	0.66
SPCA EDV	-3.87	0.69
SPCA MV	10.39	0.49
SPCA PI	48.66	0.49
SPCA RI	-114.72	0.36

The multiple linear regression analysis ($R=0.58$, $R^2=0.34$) was statistically significant ($P=0.046$). It indicated that among the PI of all the examined blood vessels, the PI of the posterior ciliary artery was a statistically significant predictor of the "flow" parameter of SLDF ($P=0.01$), the PI of the central retinal vein had a statistical tendency to predict the "flow" parameter of SLDF ($P=0.052$), and the PI of the central retinal artery was non-significant as a predictor of the "flow" parameter of SLDF ($P=0.93$) (Table 6).

We found no statistically significant correlation between the systemic blood pressure and the local perfusion parameters ($P>0.05$).

Table 6 Results of multiple linear regression in which retinal tissue blood flow (measured by SLDF) is the dependent variable, and PI of central retinal artery, central retinal vein and short posterior ciliary artery (measured by CDI) are independent variables ($R=0.58$, $R^2=0.34$, $P=0.046$). *CRA* central retinal artery, *CRV* central retinal vein, *SPCA* short posterior ciliary artery, *PI* pulsatility index, *SLDF* scanning laser Doppler flowmetry, *CDI* color Doppler imaging

Independent variables	Coefficient	<i>p</i> Value
CRA PI	9.92	0.93
CRV PI	397.35	0.05 [#]
SPCA PI	318.62	0.01 [*]

[#]Statistical tendency

^{*}Statistically significant

Discussion

This study investigates the correlation between two methods that estimate the ocular circulation in two different segments of the eye. SLDF attempts to evaluate the blood flow in the capillaries of the retinal tissue, while CDI attempts to evaluate circulatory parameters of the retrobulbar blood vessels. However, because both of the methods are estimative, the correlation between the two methods could be influenced not only by the circulatory characteristics in the measured areas, but also by other known and unknown factors.

The results of this study indicate a significant positive correlation between the recordings of SLDF and CDI in diabetic patients without ophthalmic pathology. However, contrary to what may be expected, the parameters of SLDF had a stronger correlation to the parameters of short posterior ciliary artery than to the central retinal artery and vein (Tables 2, 3, 4). Similar results were also reported by Bohdanecka et al. in patients with glaucoma [1].

As far as we understand, the possible reasons for this outcome could be the following.

1. Because the short posterior ciliary arteries and the central retinal artery are similar in caliber, we may also expect similarity in their circulatory parameters. If reproducibility of recordings of the short posterior ciliary artery is higher than those of the central retinal artery, then we may also expect a stronger correlation.

However, because the reproducibility between these blood vessels has not been reported to be significantly different, this possibility does not seem to be valid [22].

2. SLDF recordings are believed to be confocal. However, some investigators have suggested an influence of the choroidal circulation on measurements of laser Doppler flowmetry [24]. The depth of the retinal tissue that is being scanned by SLDF is reported to be 400 μm [32]. The thickness of the retina in the area where we did the recordings (peripapillary region) is approximately 500 μm [27]. The movement of the retina resulting from the fundus pulsation in diabetic patients without diabetic retinopathy has been reported to average 3.29 (± 0.98) μm [26]. Therefore, it is unlikely that the choroid is directly involved in the scanning area because of the movement forward towards the camera. However, there may be an indirect effect of the choroidal circulation through its involvement in the supply of oxygen in the outer layers, which in turn may affect the circulation in the inner layers of the retina [17].

3. The blood circulation in the choroid, which has a blood supply from the short posterior ciliary arteries, is considered responsible for the ocular pulsatility. Ocular pulsatility was reported to induce a significant effect to the SLDF recordings [28]. The reason for this effect was suggested to be either the pulsatile flow within the retinal capillaries, or the "to and fro" movement of the retina with respect to the flowmeter [28]. The latter possibility sug-

gests that the movements of the retina, which are a result of the choroidal pulsation, defocus the area of the retina that is being scanned. This defocusing may have induced an effect on SLDF recordings that could have influenced the correlation.

Furthermore, from among all the CDI parameters, the PI had the highest (and positive) correlation with the SLDF parameters (Tables 2, 3, 4), and the multiple regression and linear analyses indicated that the PI of short posterior ciliary arteries was the strongest predictor of the "flow" parameter of SLDF (Tables 5, 6). The results of RI were also positively and significantly correlated to the SLDF recordings, although they had no significant impact in the multiple regression analysis (Tables 2, 3, 4, 5, 6). The PI, which is considered to be an index of pulsatility, together with RI, as an index of blood vessel resistivity, have been reported to increase in patients with blood vessel alterations (diabetes, atherosclerosis, hypertension, aging, etc.) [3, 4, 6, 10]. Therefore, it may be unlikely to expect a positive correlation of these indices with the SLDF measurements.

In this case, again, we may suspect interference from the ocular pulsatility. As an indicator of the pulsatile component of the blood circulation, the PI in the short posterior ciliary arteries should be related to the choroidal (ocular) pulsatility. Therefore, because of its close relation to the ocular pulsatility, the PI could be positively correlated to the SLDF recordings.

Boghdanecka et al. found a non-significant, but negative correlation between RI in retrobulbar vessels and SLDF recordings in glaucoma patients [2]. The pathology of the subjects (glaucoma), the method of measurement (supine position of CDI recordings), or some other cause may be the reason for the difference with the present study concerning the RI outcome.

As presented in Eqs 3 and 4, the PI and RI are indices that are indirectly estimated from the velocity parameters. In healthy, young patients, PI and RI may increase because of an increase of peak systolic velocity. On the other hand, in older patients, suffering from blood vessel alterations, PI and RI may increase because of a decrease of end-diastolic velocity. This has been observed in a number of studies that investigated retrobulbar circulation [3, 4, 6, 10]. However, some authors question the use of RI as an indicator of vascular resistance in the central retinal artery [23]. Therefore, these indices should be interpreted with caution and not without the velocity parameters data.

Central retinal vein pulsation has been detected by ophthalmoscopy, as well as by Doppler sonography methods [11, 13]. The reasons for the pulsation are considered to be the variation in IOP, as well as the pressure changes to the central retinal vein as it leaves from the intrabulbar to the extrabulbar portion [13, 21]. PI and RI are indices that are most often used when recording arterial circulation. However, they have also been used in describing blood flow in

the central retinal vein, where they indicate the vessel's pulsatility and the resistance to venous outflow [3, 5, 31].

The PI and RI in the central retinal vein were significantly correlated with the retinal blood flow, velocity and volume (Table 3). The linear regression analysis, including the PI of all the measured retrobulbar blood vessels as independent variables and the "flow" parameter of SLDF as the dependent parameter, indicated that PI in the central retinal vein had a statistical tendency to influence the "flow" parameter, while PI in the central retinal artery had no statistical influence (Table 6). These results suggest that the pulsatile component of the blood flow in the central retinal vein has a stronger impact on the recordings of SLDF than the pulsatile component of the central retinal artery. It is also interesting that the "volume" parameter of SLDF was more significantly related to the circulatory parameters in the central retinal vein than in the other evaluated blood vessels (Tables 2, 3, 4). This may suggest a stronger relation of the blood volume in the retinal tissue with the outflow capacity of the central retinal vein.

We found no significant correlation between the ocular circulatory parameters and the systemic arterial blood pressure. Retrobulbar blood flow parameters were also reported to be not significantly correlated with the systemic blood pressure [9]. However, in another study, blood velocity in the ophthalmic artery, as recorded by pulsed Doppler ultrasonography, was significantly correlated to arterial blood pressure [16]. The retinal tissue blood flow is autoregulated and therefore not expected to be correlated with the systemic arterial blood pressure.

As shortcomings of our study, although we attempted to fix the ultrasound gate parallel to the blood vessel, there is still the possibility that the Doppler angle influenced our results concerning blood velocity recorded by CDI. Furthermore, SLDF results are also prone to be influenced by factors such as fundus brightness, poor fixation, optic media opacities, etc. [14, 29]. SLDF values are presented in arbitrary units, which also has to be taken into consideration.

In conclusion, this study found significant correlation between retinal tissue blood flow estimated by SLDF and retrobulbar circulation estimated by CDI in diabetic patients without diabetic retinopathy. From among the retrobulbar blood vessels that were evaluated, the circulatory parameters of the short posterior ciliary artery had the highest coefficients of correlation to the SLDF parameters. The PI of the short posterior ciliary artery was the most significant predictor for the "flow" parameter of SLDF. In order to confirm our current findings, the technical relationship of methodologies of SLDF and CDI will need further investigation.

Acknowledgments This study was sponsored by the Japanese Ministry for Science and Education.

References

1. Bohdanecka Z, Orgul S, Meyer AB, Prunte C, Flammer J (1999) Relationship between blood flow velocities in retrobulbar vessels and laser Doppler flowmetry at the optic disk in glaucoma patients. *Ophthalmologica* 213(3):145–149
2. Cuyppers MHM, Kasanardjo JS, Polak BCP (2000) Retinal blood flow changes in diabetic retinopathy measured with the Heidelberg scanning laser Doppler flowmeter. *Graefes Arch Clin Exp Ophthalmol* 238:935–941
3. Dimitrova G, Kato S, Tamaki Y et al. (2001) Choroidal circulation in diabetic patients. *Eye* 15:602–607
4. Dimitrova G, Tamaki Y, Kato S (2002) Retrobulbar circulation in patients with age-related maculopathy. *Eye* 16:580–586
5. Dimitrova G, Kato S, Yamashita H, et al (2003) Relation between retrobulbar circulation and progression of diabetic retinopathy. *Br J Ophthalmol* 87:622–625
6. Friedman E, Krupsky S, Lane AM et al. (1995) Ocular blood flow velocity in age-related macular degeneration. *Ophthalmology* 102:640–646
7. Goebel W, Lieb WE, Ho A (1995) Color Doppler imaging: a new technique to assess orbital blood flow in patients with diabetic retinopathy. *Invest Ophthalmol Vis Sci* 36:860–870
8. Grunwald JE, Brucker AJ, Braunstein SN et al. (1994) Strict metabolic control and retinal blood flow in diabetes mellitus. *Br J Ophthalmol* 78:598–604
9. Guthoff RF, Berger RW, Winkler P, Helmke K, Chumbley LC (1991) Doppler ultrasonography of the ophthalmic and central retinal vessels. *Arch Ophthalmol* 109:532–536
10. Harris A, Harris M, Biller J et al. (2000) Aging affects the retrobulbar circulation differently in women and men. *Arch Ophthalmol* 118:1076–1080
11. Hedges TR, Baron EM, Hedges TR, Sinclair SH (1994) The retinal venous pulse—its relation to optic disc characteristics and choroidal pulse. *Ophthalmology* 101:542–547
12. Hellstedt, R Kaaja, K Teramo, H Immonen (1996) Macular blood flow during pregnancy in patients with early DR measured by blue-light entoptic simulation. *Graefes Arch Clin Exp Ophthalmol* 234:659–663
13. Levine DN (1998) Spontaneous pulsation of the retinal veins. *Microvasc Res* 56:154–165
14. Kagemann L, Harris A, Chung HS, Evans D, Buck S, Martin B (1998) Heidelberg retinal flowmetry: factors affecting blood flow measurement. *Br J Ophthalmol* 82:131–136
15. Kawagishi T, Nishizawa Y, Emoto M (1995) Impaired retinal artery blood flow in IDDM patients before clinical manifestation of diabetic retinopathy. *Diabetes Care* 18:1544–1549
16. Keiser HJ, Schotzau A, Flammer J (1996) Blood flow velocities in the extraocular vessels in normal volunteers. *Am J Ophthalmol* 122:364–370
17. Kiss B, Polska E, Dorner G et al. (2002) Retinal blood flow during hyperoxia revisited: concerted results using different measurement techniques. *Microvasc Res* 64:75–85
18. Kohner EM (1993) The retinal blood flow in diabetes. *Diabetes Metab (Paris)* 19:401–404
19. Michaelson G, Langhans MJ, Groh MJM (1995) Clinical investigation of the combination of a scanning laser ophthalmoscope and laser Doppler flowmeter. *Ger J Ophthalmol* 4:342–349
20. Michaelson G, Langhans MJ, Groh MJM (1996) Perfusion of the juxtapapillary retina and the neuroretinal rim area in primary open angle glaucoma. *J Glaucoma* 5(2):91–98
21. Michaelson G, Harazny J (1997) Relationship between ocular pulse pressures and retinal vessel velocities. *Ophthalmology* 104:664–671
22. Niwa Y, Yamamoto T, Kawakami H, Kitazawa Y (1998) Reproducibility of color Doppler imaging for orbital arteries in Japanese patients with normal-tension glaucoma. *Jpn J Ophthalmol* 42:389–392
23. Polska E, Kircher K, Ehrlich P, Vecsei PV, Schmetterer L (2001) RI in central retinal artery as assessed by CDI does not correspond to retinal vascular resistance. *Am J Physiol Heart Circ Physiol* 280:H1442–H1447
24. Polska E, Luksch A, Ehrlich P, Sieder A, Schmetterer L (2002) Measurements in the peripheral retina using LDF and laser interferometry are mainly influenced by the choroidal circulation. *Curr Eye Res* 24(4):318–323
25. Remsch H, Spraul CW, Lang GK, Lang GE (2000) Changes of retinal capillary blood flow in age-related maculopathy. *Graefes Arch Clin Exp Ophthalmol* 238:960–964
26. Schmetterer L, Salomon A, Rheinberger A, Unfried C, Lexer F, Wolzt M (1996) Fundus pulsation measurements in diabetic retinopathy. *Graefes Arch Clin Exp Ophthalmol* 235:283–287
27. Snell RS, Lemp MA (1998) *Clinical anatomy of the eye*, 2nd edn. Blackwell, Malden, USA
28. Sullivan P, Cioffi GA, Wang L et al. (1999) The influence of ocular pulsatility on scanning laser Doppler flowmetry. *Am J Ophthalmol* 128:81–87
29. Tsang AC, Harris A, Kagemann L et al. (1999) Brightness alters HRF measurements in an in vitro model. *Invest Ophthalmol Vis Sci* 40:795–799
30. Wolf S, Arend O, Toonen H, Bertram B, Jung F, Reim M (1991) Retinal capillary blood flow measurement with a scanning laser ophthalmoscope. *Ophthalmology* 98:996–1000
31. Williamson TH, Baxter GM (1994) Central retinal vein occlusion, an investigation by color Doppler imaging. *Ophthalmology* 101:1362–1372
32. Zinser G (1999) Scanning laser Doppler flowmetry—principle and technique. In: Pillunat LE, Harris A, Anderson DR, Greve EL (eds) *Current concepts on ocular blood flow in glaucoma*. Kugler Publications, The Hague, Netherlands, pp 197–204

Prevalence of Appositional Angle Closure Determined by Ultrasonic Biomicroscopy in Eyes with Shallow Anterior Chambers

Shiho Kunimatsu, MD,¹ Atsuo Tomidokoro, MD,¹ Kouichi Mishima, MD,¹ Hiroyo Takamoto, MD,¹ Goji Tomita, MD,¹ Aiko Iwase, MD,² Makoto Araie, MD¹

Purpose: To determine the prevalence of appositional angle closure in eyes with a shallow peripheral anterior chamber but no peripheral anterior synechia (PAS) in Japanese patients.

Design: Cross-sectional study.

Participants: Eighty eyes of 80 consecutive patients with a shallow peripheral anterior chamber, determined using the method of van Herick, and no PAS.

Methods: The anterior chamber angle was classified according to Shaffer's grading with noncompression gonioscopy superiorly, inferiorly, temporally, and nasally. The absence of PAS was confirmed by compression gonioscopy if necessary. The presence of appositional angle closure and the trabecular-iris angle (T-I angle) was determined with ultrasound biomicroscopy in each quadrant under light and dark conditions. Factors related to appositional angle closure were studied using logistic analysis, and the covariates included gender, age, refraction, gonioscopic grading, and the quadrant of the angle measured.

Main Outcome Measures: Gonioscopic grading of the angle width, the T-I angle, and the prevalence of appositional closure.

Results: The gonioscopic grading ($P < 0.001$ in light and dark) and the T-I angle ($P < 0.001$ in light and dark) varied significantly among the 4 quadrants. Narrower angle gradings were observed more frequently superiorly. The T-I angle was narrower superiorly (in light) and inferiorly (in dark) ($P < 0.001$ and $P = 0.040$, respectively). The T-I angle was significantly narrower in dark than in light ($P < 0.001$). The sites with the narrower gonioscopic gradings tended to have a smaller T-I angle ($P < 0.001$ and $P = 0.006$ in light and dark, respectively). Appositional angle closure was found in at least 1 quadrant in 46 (57.5%) of 80 eyes in light and in 68 eyes (85%) in dark. Logistic analysis showed that gonioscopic grading and the quadrant were significantly related to the presence of appositional angle closure in light and dark ($P < 0.003$ for both comparisons).

Conclusions: Appositional angle closure was frequently observed in eyes with a shallow peripheral anterior chamber, especially under dark conditions in Japanese patients. The angle width, evaluated with conventional gonioscopic grading, and the quadrant of the angle were significantly related to the presence of appositional angle closure. *Ophthalmology* 2005;112:407-412 © 2005 by the American Academy of Ophthalmology.

Appositional angle closure is reversible nonpermanent angle closure that is thought potentially to increase the risk of developing peripheral anterior synechia (PAS).¹ During gonioscopy, the configuration of appositional closure often can be affected by inadvertent pressure on the anterior chamber. The usefulness of provocation tests, including

prone position testing,²⁻⁴ dark room testing,⁴⁻⁶ and mydriatic testing,⁴ is unclear.

Ultrasound biomicroscopy (UBM), using a high-frequency transducer, permits noninvasive examination of the anterior segment anatomy at high resolution (40 μm).⁷ The efficacy of UBM has been demonstrated in relation to the mechanism of angle closure in eyes with primary angle glaucoma,⁸⁻¹⁰ the relation between intraocular pressure (IOP) and angle width,¹¹ the improved accuracy for diagnosing plateau iris syndrome,¹¹ and the morphologic changes after laser iridotomy.¹² Moreover, UBM has advantages when evaluating the physiologic configuration of the iris, ciliary body, and angle, in that no inadvertent pressure is exerted on the anterior chamber under controlled light conditions.

Asian patients have eyes with a shallow anterior chamber, and the prevalence of angle-closure glaucoma (ACG) is higher than in non-Asian patients.¹³⁻¹⁶ Thus, it is imperative to identify patients, before PAS develops, at risk of devel-

Originally received: June 3, 2004.

Accepted: October 6, 2004.

Manuscript no. 240426.

¹ Department of Ophthalmology, University of Tokyo, Graduate School of Medicine, Tokyo, Japan.

² Department of Ophthalmology, Tajimi Municipal Hospital, Gifu, Japan.

Presented in part as a poster at: American Academy of Ophthalmology annual meeting, October, 2002; Orlando, Florida.

The authors have no proprietary interest in any aspect of this article.

Correspondence to Atsuo Tomidokoro, MD, Department of Ophthalmology, University of Tokyo, Graduate School of Medicine, 7-3-1 Hongo, Bunkyo-ku, Tokyo, 113-8655, Japan. E-mail: tomidokoro-tyk@umin.ac.jp.




Figure 1. An ultrasound biomicroscopy image of the superior angle of the eye of a 70-year-old woman, in which the gonioscopic angular width was classified as grade 1. The trabecular-iris angle (T-I angle) was measured with the apex in the iris recess and the arms of the angle passing through a point on the trabecular meshwork 500 μm from the scleral spur and the point on the iris perpendicularly opposite. The T-I angle is 8° in light, and appositional angle closure does not occur. In dark, the T-I angle is 0°, and appositional angle closure is identified.

oping ACG. For this purpose, observing appositional angle closure using UBM may play a key role in the management of eyes with a shallow peripheral anterior chamber. However, there have been no UBM studies on the presence of appositional closure in eyes with a shallow anterior chamber and no PAS. The aims of the present cross-sectional study were to determine the frequency of appositional angle closure in eyes with narrow angles without PAS and to evaluate the relation between the frequency of appositional angle closure and the grade of the angle width evaluated using conventional gonioscopy in Japanese patients.

Materials and Methods

Consecutive patients with a peripheral anterior chamber depth equal to or shallower than a quarter of the peripheral corneal thickness according to the method of van Herick¹⁷ underwent gonioscopic assessment between August 2000 and December 2001 at the outpatient clinic of the Department of Ophthalmology,

Graduate School of Medicine, University of Tokyo, Tokyo, Japan. This is a referral-based general eye clinic to which most new patients are sent from other physicians because of not only glaucoma or suspected glaucoma but also other ocular diseases. The anterior chamber angle was assessed, and the width was graded according to the grading system of Shaffer¹⁸ in 4 quadrants (superior, inferior, temporal, and nasal) by an experienced examiner (MA) using a Goldmann-type 2-mirror indirect gonioscope (Haag-Streit Inc., Koeniz, Switzerland). Inadvertent compression of the angle was avoided. Based on this grading system, an anterior chamber angle was classified using the angle width: the widest open angle was graded as 4, and an apparently closed angle without compression was grade slit (or grade 0).^{18,19} The absence of PAS was confirmed using a compression technique with a Zeiss-type 4-mirror gonioscope (Haag-Streit) when necessary. After excluding eyes with a history of laser or incisional glaucoma surgeries, acute ACG, or other eye diseases, 80 consecutive patients who had a shallow peripheral anterior chamber and no PAS bilaterally underwent UBM after we obtained informed consent. Because all of the measurements were obtained by methods that were routinely used with patients with a shallow anterior chamber and this study protocol did not include surgical or medical interventions, approval of the institutional review board or ethics committee was not needed when this study was carried out. This protocol was performed in accordance with the tenets of the Declaration of Helsinki.

At the same time on a different day, profile images of the limbal area in the superior (12 o'clock), inferior (6 o'clock), temporal (3 or 6 o'clock), and nasal (6 or 3 o'clock) quadrants were assessed with the patient in a supine position by an experienced examiner (SK) using UBM (UBM model 840, Humphrey Research Division, Carl Zeiss Inc., Thornwood, NY). The UBM system was equipped with a 50-MHz transducer (gain, 80 decibels; time of gain compensation, 5 decibels per millimeter; delay, 2.56 mm), and its spatial resolution was approximately 40 μm . After topical anesthesia was applied, an eyecup containing hydroxyethyl cellulose and physiologic saline was mounted on the globe, and UBM assessments in the 4 quadrants were carried out in room light (approximately 240 lux, measured with an ANA-F12 luminance meter [Shimazu-rika Instruments, Tokyo, Japan]) in both eyes. The assessments were repeated in the same manner 5 minutes after the

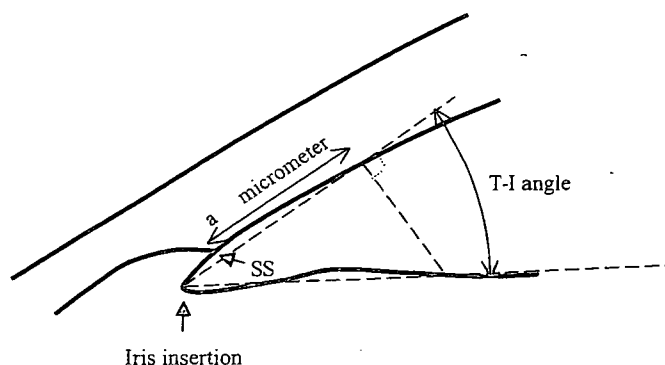


Figure 2. Determination of the trabecula-iris angle (T-I angle). The T-I angle is measured with the apex in the iris insertion and the arms of the angle passing through a point on the trabecular meshwork 500 μm from the scleral spur (SS) and the point on the iris perpendicularly opposite.¹¹

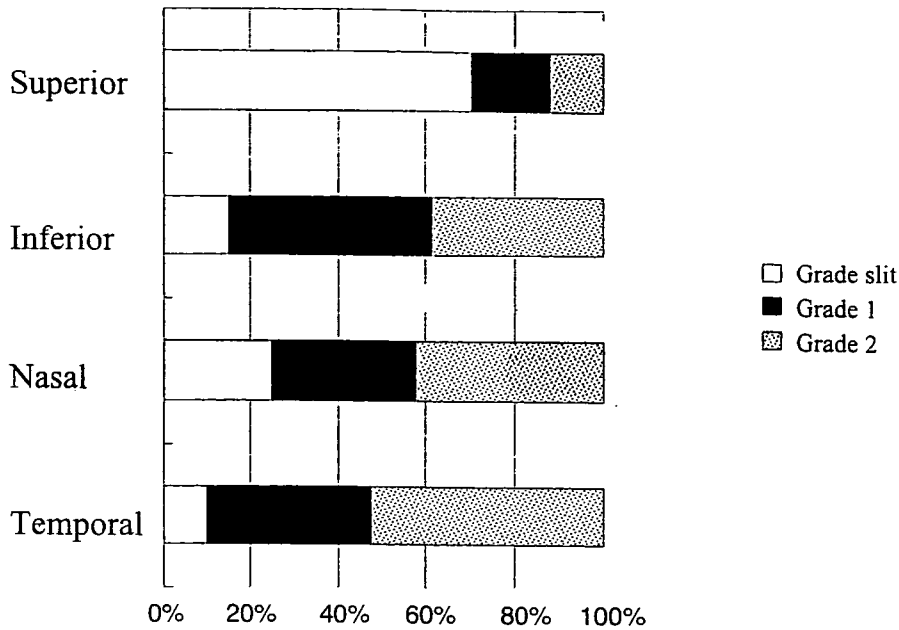


Figure 3. The prevalence of the gonioscopic angle gradings according to Schaffer's classification¹⁸ superiorly, inferiorly, nasally, and temporally in 80 eyes with a shallow peripheral anterior chamber without peripheral anterior synechia.

room was darkened to approximately 0.1 lux. Ultrasound biomicroscopy assessment was done first in the right eye, and all measurements were carried out in 1 day.

When the trabecular meshwork and iris were located appositionally on the UBM image, it was estimated that the site of the angle had appositional angle closure (Fig 1). On each UBM image in which appositional angle closure was not present, the trabecular-iris angle (T-I angle) was determined according to the method of Pavlin et al¹¹ and Marchini et al²⁰; the T-I angle was measured with the apex in the iris recess and the arms of the angle passing through a point on the trabecular meshwork 500 μm from the scleral spur and the point on the iris perpendicularly opposite (Fig 2). The examiner (AT) of the UBM images was masked to the results of gonioscopic classification.

Factors related to the presence of appositional angle closure in light or dark were studied using logistic analysis with gender, age, refraction, gonioscopic grading, and the quadrant where the angle was located (superior, inferior, temporal, or nasal) as covariates using the following formula:

$$\text{logit}(P_{\text{app}}) = \beta_0 + \beta_1(\text{sex}) + \beta_2(\text{age}) + \beta_3(\text{refraction}) + \beta_4(\text{gonioscopic grade}) + \beta_5(\text{quadrant}),$$

where P_{app} is the probability that the site has appositional angle closure. In the analysis, categorized covariates, such as gonioscopic grade and quadrant, were automatically coded by statistical software.²¹ The data obtained from the right eyes were used for statistical analyses.

Results

Eighty right eyes of 80 patients (63 women, 17 men) aged 69.4 ± 7.0 years (mean \pm standard deviation) (range, 51–89) were included in this study. The mean spherical error was $+0.7 \pm 2.8$ diopters (range, -4.0 to +3.75), and the mean IOP was 14.6 ± 2.7 mmHg (range, 8–21).

The prevalence of the gonioscopic angle gradings varied significantly among the 4 quadrants ($P < 0.001$, chi-square test) (Fig 3). No site was classified as grade 3 or 4. Narrower angle gradings were observed more frequently superiorly relative to the other quadrants.

The T-I angle averaged in all 4 quadrants was significantly greater in light than in dark ($P < 0.001$, paired t test) and significantly differed among the 4 quadrants ($P < 0.001$ in both light and

Table 1. Trabecula-Iris (T-I) Angle in the Superior, Inferior, Temporal, and Nasal Quadrants (in Degrees)

	Superior	Inferior	Temporal	Nasal	All Quadrants
Light	6.9 ± 4.2	9.3 ± 5.7	11.2 ± 5.6	10.6 ± 5.6	9.7 ± 5.6
Dark	7.2 ± 3.7	6.8 ± 3.9	10.3 ± 6.4	8.9 ± 6.1	8.9 ± 6.8
<i>P</i> value	0.42	0.002	0.09	0.015	<0.001

Values are means \pm standard deviations. *P* indicates the comparison between light and dark (paired t test). The T-I angle significantly differs among the 4 quadrants in light or dark ($P < 0.001$, analysis of variance). Post hoc Tukey tests revealed that the T-I angle is significantly smaller superiorly than temporally or nasally in light ($P < 0.001$) and that the T-I angle is smaller inferiorly than temporally in dark ($P = 0.040$).

Table 2. Trabecular-Iris (T-I) Angle in Sites with Gonioscopic Angles Graded Slit, 1, and 2 (in Degrees)

	Slit	Grade 1	Grade 2
Light	7.3±3.9	8.9±5.0	11.3±5.8
Dark	6.0±4.0	7.9±4.7	9.6±5.0
P value	0.05	0.007	<0.001

Values are means ± standard deviations. P indicates a comparison between light and dark (paired t test). The T-I angle significantly differs among these gradings in light or dark ($P < 0.001$ or $P = 0.006$, respectively; analysis of variance). Post hoc Tukey tests revealed that the T-I angle is significantly greater in grade 2 than in grade slit or grade 1 in light ($P < 0.001$ or $P = 0.005$) and that in grade 2 the T-I angle is greater than in grade slit in dark ($P = 0.007$).

dark) (Table 1). The T-I angle differed significantly among the sites graded as slit, 1, and 2 ($P < 0.001$ and $P = 0.006$ in light and dark, respectively) (Table 2).

Appositional angle closure was found in at least 1 quadrant in 46 eyes (57.5%) of 80 eyes in light and 68 eyes (85%) in dark (Table 3). The frequency varied significantly among the 4 quadrants ($P < 0.001$ in light and dark, chi-square test). In light, the frequency was significantly higher superiorly ($P < 0.001$) and inferiorly ($P = 0.001$) than temporally. In dark, the frequency was significantly higher superiorly ($P < 0.001$) and inferiorly ($P < 0.001$) than temporally. In each of the 4 quadrants, the frequency of appositional angle closure in light was significantly lower than that in dark ($P < 0.005$).

The frequency of appositional angle closure significantly differed among the sites with different gonioscopic gradings in light and dark ($P < 0.001$) (Table 4) and was significantly higher in dark than in light ($P < 0.01$) for each gonioscopic grading.

The results of logistic analysis are shown in Tables 5 and 6. Gonioscopic grading and quadrant (superior, inferior, temporal, or nasal) were variates that were significantly correlated with the presence of appositional closure in light or dark ($P < 0.003$ for both), whereas gender, age, and refraction were not ($P > 0.08$). Using these regression models for light and dark conditions, the squared correlation coefficients (Nagelkerke R^2) were 0.23 and 0.33, respectively.

Discussion

Ultrasound biomicroscopy has several advantages for evaluating the configuration of the anterior portion of the globe. A profile image of the iridocorneal angle can be obtained, and further quantitative analyses of it can be carried out. The physiologic configuration of the pupil and iris can be seen without illumination. Moreover, UBM allows obser-

vation of the back of the iris or ciliary body. Several studies of the movement of the iris and ciliary body under light or dark conditions indicated that appositional or nonsynechial angle closure was often observed in eyes with shallow anterior chambers with or without PAS.^{6,22} Sakuma et al reported appositional angle closure in 90% of 30 eyes with a narrow angle with PAS and in 81.3% of 16 eyes without PAS.²²

Because patients were included in this study based on the method of van Herick,¹⁷ which can be used easily and widely in clinics, the current results would be applicable to a wide area of clinical settings. Moreover, from a clinical standpoint, because the indication for prophylactic laser iridotomy can be determined easily in eyes with PAS, information about appositional angle closure is more important in eyes without PAS than in those with it. Once PAS has developed, the movement of the iris root adjacent to the PAS must be somewhat altered from the normal physiologic state. Therefore, we studied the presence of appositional angle closure using UBM in eyes in which no PAS was observed with conventional gonioscopy.

In the current study, we found appositional angle closure in at least 1 quadrant in 46 (57.5%) of 80 Japanese eyes with a narrow angle with no PAS under normal room light and in 68 eyes (85%) in the dark. Taken with the results of Sakuma et al,²² the present results reemphasize that in Japanese patients almost 9 of 10 eyes with a shallow peripheral anterior chamber with no PAS have appositional closure. In the United States, Ishikawa et al⁶ studied 178 eyes with clinically narrow angles (i.e., a Shaffer grade of 1 or 2) and found no eye with appositional angle closure in light and 99 eyes (55.6%) with appositional angle closure during the dark provocation test. Those previous studies and the present results suggest differences in the prevalence of appositional angle closure in eyes with a narrow angle between Caucasian and Japanese patients. This difference may be related to racial differences in the configuration of the anterior chamber, as reported by Oh et al.²³ Those investigators studied 291 normal subjects including African Americans, Caucasians, and Asians and found significantly more anterior iris insertion in Asians, whereas the angle width evaluated with gonioscopy did not differ significantly.

The T-I angle, which was determined according to the method of Pavlin et al¹¹ and Marchini et al,²⁰ was an average $9.7 \pm 5.6^\circ$ and $8.9 \pm 5.8^\circ$ in light and dark, respectively, in the present study. The T-I angle in light in our study ($9.7 \pm 5.6^\circ$) is smaller than previous results determined

Table 3. Prevalence of Appositional Angle Closure Superiorly, Inferiorly, Temporally, and Nasally (Total N = 80 Eyes)

	Superior		Inferior		Temporal		Nasal	
	Light	Dark	Light	Dark	Light	Dark	Light	Dark
Appositional closure (+)	32 (40%)	63 (79%)	23 (29%)	51 (64%)	7 (9%)	21 (26%)	11 (14%)	26 (33%)

In light and dark, the prevalence of appositional angle closure differs significantly among the 4 quadrants ($P < 0.0001$; chi-square test). The prevalence of appositional angle closure in light is significantly smaller than that in dark in each quadrant ($P < 0.005$).

Table 4. Prevalence of Appositional Angle Closure in Sites with Gonioscopic Gradings of Slit, 1, and 2 in Light or Dark

	Slit (88 Sites)		Grade 1 (118 Sites)		Grade 2 (114 Sites)	
	Light	Dark	Light	Dark	Light	Dark
Appositional closure (+)	34 (39%)	69 (78%)	26 (22%)	61 (52%)	13 (11%)	31 (27%)

In light and dark, the prevalence of appositional angle closure differs significantly among the sites with grades of slit, 1, and 2 ($P < 0.0001$; chi-square test). The prevalence of appositional angle closure in light is significantly smaller than that in dark regarding the sites with gonioscopic classifications of grades slit, 1, and 2 ($P < 0.0001$, $P < 0.0001$, and $P = 0.0025$, respectively).

using the same method in 54 Caucasian patients with primary angle glaucoma.²⁰ Those authors reported that the T-I angle averaged $11.7 \pm 8.8^\circ$, $19.9 \pm 9.8^\circ$, and $31.3 \pm 9.2^\circ$ in patients with acute, intermittent, and chronic ACG, respectively, in constant ambient light conditions (illumination, 190 lux). Because there has been no report on the T-I angle in Japanese patients with primary angle closure, the reasons for this discrepancy may be difficult to determine. Racial differences at the site of iris insertion²³ may be at least partly responsible.

The anterior chamber angle was reported to be narrower in the superior quadrant than elsewhere, based on several gonioscopic studies.²⁴⁻²⁷ To our knowledge, however, there has been no report published on the differences in the configuration of the anterior chamber angle evaluated with UBM among different quadrants, with the exception that Woo et al²⁸ reported that iris curvature (defined as the maximum distance from the line between the iris root and the iris tip) was almost equal among the superior, inferior, temporal, and nasal quadrants. In the current study, narrower angles were more frequently found superiorly by gonioscopy than in the other quadrants (Fig 3), which agreed with previous reports on Western patients.²⁴⁻²⁷ Moreover, the present study was the first to document differences in anterior chamber angles and differences in the prevalence of appositional angle closure among the quadrants in Japanese patients. The T-I angle was narrower superiorly than in the other quadrants in light (Table 1), which agreed with the current gonioscopic results. In dark, the T-I angle in a superior quadrant was equal to that inferiorly and narrower than that temporally or nasally, which was not previously documented, probably because the angle cannot be observed during gonioscopic studies under dark conditions. The results obtained under dark

conditions should be emphasized more than those under light conditions because acute attacks of ACG develop more frequently under dark conditions. Table 2 shows that narrower gonioscopically graded angles tended to have a narrower T-I angle, which also correlated well between the gonioscopic gradings and the T-I angle.

The prevalence of appositional angle closure was greater superiorly and inferiorly than temporally and nasally (Table 3) and significantly correlated with the gonioscopic gradings (Table 4). Although the quadrants and gonioscopic gradings correlated with each other, the results of logistic analysis indicated that these 2 factors, in part, were related individually to the presence of appositional angle closure (Tables 5, 6). In these analyses, the correlation coefficients were not as large ($R^2 = 0.23$ or $R^2 = 0.33$), suggesting that there are other important factors related to the development of appositional angle closure in eyes without PAS. The position of the iris insertion; the thickness of the ciliary body, iris, and lens; and the dynamic movement of the iris root may be associated with the development of appositional angle closure.

The process of PAS development in eyes with a narrow angle is still unclear. Using gonioscopy, Bhargava et al¹ investigated the topologic distributions of appositional closure and PAS, which were differentiated by the reaction to pilocarpine, in 20 patients with early chronic ACG. The investigators found that areas of closure occur most commonly in the superior angle and that pilocarpine-induced resolution of iridotrabecular contact occurs most often inferiorly. They concluded that angle closure develops insidiously from the superior quadrant downward, initially by reversible iridotrabecular contact and later by permanent goniosynechia. The current results—that the anterior chamber angle is narrower superiorly or inferiorly than

Table 5. Results of Logistic Analysis of Factors Correlated with the Presence of Appositional Angle Closure in Light

	Odds Ratio (95% Confidence Interval)	P Value
Gender	0.77 (0.38-1.57)	0.47
Age	1.01 (0.97-1.04)	0.68
Refraction	1.03 (0.83-1.26)	0.82
Gonioscopic grading	0.45 (0.26-0.76)	0.003
Quadrant*	0.64 (0.49-0.85)	0.002

*Quadrant where the angle is located. Using this model, $R^2 = 0.23$.

Table 6. Results of Logistic Analysis of Factors Correlated with the Presence of Appositional Angle Closure in Dark

	Odds Ratio (95% Confidence Interval)	P Value
Gender	1.82 (0.93-3.55)	0.08
Age	1.01 (0.98-1.04)	0.53
Refraction	0.95 (0.79-1.14)	0.59
Gonioscopic grading	0.35 (0.23-0.54)	<0.001
Quadrant*	0.48 (0.37-0.61)	<0.001

*Quadrant where the angle is located. Using this model, $R^2 = 0.33$.

elsewhere and that appositional angle closure is most frequently observed superiorly—are consistent with the results of Bhargava et al.¹ It must be noted, however, that there are unidentified factors other than appositional angle closure in the pathogenesis of PAS and acute angle closure.

Kessler²⁹ and Gorin³⁰ forwarded the hypothesis that angle closure extends from posterior (the scleral spur) to anterior (Schwalbe's line), especially when angle closure develops acutely. Conversely, Sakuma et al divided appositional closure into the S type, in which appositional closure starts in the vicinity of Schwalbe's line, and the B type, in which it starts at the bottom of the angle, and suggested that two thirds of appositional closures start as the S type.²² From the results of the current study, the design of which was cross-sectional, it is difficult to speculate how PAS progresses. The relationship between configuration of the angle, iris, and ciliary body and the development of PAS and acute angle closure awaits further investigation using longitudinal analysis.

In Japanese patients, as our results suggested, appositional angle closure is probably not a rare finding, especially under dark conditions in eyes with a shallow peripheral anterior chamber, and gonioscopic grading and the quadrant where the angle is located are related significantly to the presence of appositional angle closure. Although the role and significance of appositional angle closure in a clinical setting are not yet explained fully, accumulating knowledge on appositional angle closure and a shallow T-I angle should provide a better understanding of the development of PAS and acute or chronic ACG.

References

- Bhargava SK, Leighton DA, Phillips CI. Early angle-closure glaucoma. Distribution of iridotrabecular contact and response to pilocarpine. *Arch Ophthalmol* 1973;89:369–72.
- Hyams SW, Friedman Z, Neumann E. Elevated intraocular pressure in the prone position. A new provocative test for angle-closure glaucoma. *Am J Ophthalmol* 1968;66:661–72.
- Harris LS, Galin MA. Prone provocative testing for narrow angle glaucoma. *Arch Ophthalmol* 1972;87:493–6.
- Hitchings RA, Powell DJ. Pilocarpine and narrow-angle glaucoma. *Trans Ophthalmol Soc U K* 1981;101:214–7.
- Pavlin CJ, Harasiewicz K, Foster FS. An ultrasound biomicroscopic dark-room provocative test. *Ophthalmic Surg* 1995;26:253–5.
- Ishikawa H, Esaki K, Liebmann JM, et al. Ultrasound biomicroscopy dark room provocative testing: a quantitative method for estimating anterior chamber angle width. *Jpn J Ophthalmol* 1999;43:526–34.
- Pavlin CJ, Sherar MD, Foster FS. Subsurface ultrasound microscopic imaging of the intact eye. *Ophthalmology* 1990;97:244–50.
- Pavlin CJ, Harasiewicz K, Sherar MD, Foster FS. Clinical use of ultrasound biomicroscopy. *Ophthalmology* 1991;98:287–95.
- Ritch R, Liebmann JM. Role of ultrasound biomicroscopy in the differentiation of block glaucomas. *Curr Opin Ophthalmol* 1998;9:39–45.
- Wilensky JT, Kaufman PL, Frohlichstein D, et al. Follow-up of angle-closure glaucoma suspects. *Am J Ophthalmol* 1993;115:338–46.
- Pavlin CJ, Harasiewicz K, Foster FS. Ultrasound biomicroscopy of anterior segment structures in normal and glaucomatous eyes. *Am J Ophthalmol* 1992;113:381–9.
- Gazzard G, Friedman DS, Devereux JG, et al. A prospective ultrasound biomicroscopy evaluation of changes in anterior segment morphology after laser iridotomy in Asian eyes. *Ophthalmology* 2003;110:630–8.
- Bourne RR, Sukdom P, Foster PJ, et al. Prevalence of glaucoma in Thailand: a population based survey in Rom Klao District, Bangkok. *Br J Ophthalmol* 2003;87:1069–14.
- Foster PJ, Baasanhu J, Alsbirk PH, et al. Glaucoma in Mongolia. A population-based survey in Hövsgöl province, northern Mongolia. *Arch Ophthalmol* 1996;114:1235–41.
- Seah SK, Foster PJ, Chew PT, et al. Incidence of acute primary angle-closure glaucoma in Singapore. An island-wide survey. *Arch Ophthalmol* 1997;115:1436–40.
- Foster PJ, Oen FT, Machin D, et al. The prevalence of glaucoma in Chinese residents of Singapore: a cross-sectional population survey of the Tanjong Pagar district. *Arch Ophthalmol* 2000;118:1105–11.
- Foster PJ, Devereux JG, Alsbirk PH, et al. Detection of gonioscopically occludable angles and primary angle closure glaucoma by estimation of limbal chamber depth in Asians: modified grading scheme. *Br J Ophthalmol* 2000;84:186–92.
- Shaffer RN. Primary glaucomas. Gonioscopy, ophthalmoscopy and perimetry. *Trans Am Acad Ophthalmol Otolaryngol* 1960;64:112–27.
- Stamper RL, Lieberman MF, Drake MV. *Becker-Shaffer's Diagnosis and Therapy of the Glaucomas*. 7th ed. St. Louis: Mosby; 1999:101–13.
- Marchini G, Pagliaruso A, Toscano A, et al. Ultrasound biomicroscopic and conventional ultrasonographic study of ocular dimensions in primary angle-closure glaucoma. *Ophthalmology* 1998;105:2091–8.
- SPSS [computer program]. Version 11.0.1J. Tokyo: SPSS Japan Inc.
- Sakuma T, Sawada A, Yamamoto T, Kitazawa Y. Appositional angle closure in eyes with narrow angles: an ultrasound biomicroscopic study. *J Glaucoma* 1997;6:165–9.
- Oh YG, Minelli S, Spaeth GL, Steinman WC. The anterior chamber angle is different in different racial groups: a gonioscopic study. *Eye* 1994;8:104–8.
- Barkan O. Etiology of narrow-angle glaucoma; report of a case of glaucoma secondary to anterior displacement of the lens iris diaphragm. *Am J Ophthalmol* 1953;36:901–6.
- Barkan O. Narrow-angle glaucoma; effect of miosis on the narrow-angle mechanism and intraocular pressure. *Am J Ophthalmol* 1953;36:1387–8.
- Phillips CI. Sectoral distribution of goniosynechiae. *Br J Ophthalmol* 1956;40:129–35.
- Phillips CI. Closed-angle glaucoma; significance of sectoral variations in angle depth. *Br J Ophthalmol* 1956;40:136–43.
- Woo EK, Pavlin CJ, Slomovic A, et al. Ultrasound biomicroscopic quantitative analysis of light-dark changes associated with pupillary block. *Am J Ophthalmol* 1999;127:43–7.
- Kessler J. A discussion of the mechanisms in chronic angle-closure glaucoma. *Am J Ophthalmol* 1958;46:888–90.
- Gorin G. Shortening of the angle of the anterior chamber in angle-closure glaucoma. *Am J Ophthalmol* 1960;49:141–6.

CLINICAL INVESTIGATION

Efficacy and Complications After Trabeculectomy with Mitomycin C in Normal-Tension Glaucoma

Boonphen Jongsareejit¹, Atsuo Tomidokoro¹, Tatsuya Mimura¹, Goji Tomita¹, Shiroaki Shirato², and Makoto Araie¹

¹Department of Ophthalmology, University of Tokyo School of Medicine, Tokyo, Japan;

²Department of Ophthalmology, Tokyo Medical University Hachioji Medical Center, Tokyo, Japan

Abstract

Purpose: To evaluate the efficacy of and complications after trabeculectomy using mitomycin C (MMC) in Japanese normal-tension glaucoma (NTG) patients by a retrospective analysis based on the Kaplan-Meier life table method.

Methods: Clinical records of 39 NTG patients who underwent trabeculectomy with 0.04% MMC and had postoperative follow-up periods of 3 years or more (50.5 ± 8.4 months, mean \pm SD) were reviewed. Postoperative intraocular pressure (IOP) at every 1 or 2 months, complications, visual acuity, and visual field at every 6 months were recorded.

Results: IOP significantly decreased from 15.9 ± 1.9 preoperatively to 8–11 mmHg throughout the postoperative follow-up period ($P < 0.0001$). The life table analysis, in which failure of IOP control was defined as an IOP above a level either 30% or 20% lower than the preoperative IOP at three consecutive visits, showed a cumulative survival rate of $39.4 \pm 7.8\%$ (mean \pm SEM) or $41.3 \pm 8.9\%$, respectively, at 4 years after surgery. Mean deviation of the visual field results did not significantly change ($P > 0.5$). The cumulative survival rate from postoperative late-onset hypotony was $74.7 \pm 6.3\%$ at 4 years after surgery. Postoperative complications observed were shallow anterior chamber (six eyes), choroidal detachment (nine eyes), hypotonous maculopathy (seven eyes), bleb leak (one eye), cataract development (three eyes), and blebitis (two eyes). No eyes developed endophthalmitis.

Conclusions: In NTG patients, trabeculectomy with MMC showed significant efficacy in reducing IOP up to 4 years after surgery. Since risks of postoperative complications are unavoidable, indications for surgery should be carefully considered, and careful follow-up is necessary to avoid severe postoperative complications. **Jpn J Ophthalmol** 2005;49:223-227 © Japanese Ophthalmological Society 2005

Key Words: complications, intraocular pressure, Kaplan-Meier life table method, mitomycin C, normal-tension glaucoma, trabeculectomy

Introduction

Normal-tension glaucoma (NTG), also referred to as low-tension glaucoma, has been defined as open-angle glaucoma developing in an eye with normal intraocular pressure (IOP) but having some level of glaucomatous optic nerve damage with the corresponding visual field defects. In

various countries, the prevalence of NTG has been reported as one-third to two-thirds of open-angle glaucoma patients.¹⁻⁴ In an epidemiological report from Japan, the prevalence of NTG reached 2.04% of the 40-and-older population, which was 57.3% of all glaucoma patients in the study.⁴

Although NTG should be a multifactorial disease, high IOP is still the only identified risk factor, not only for high-tension glaucoma but also for NTG. Several studies have suggested that lowering the IOP has the beneficial effect of halting or slowing the progression of NTG.⁵⁻¹⁰ For example, a randomized controlled trial showed that a 30% or larger reduction of IOP from the preoperative value had

Received: April 1, 2004 / Accepted: October 15, 2004

Correspondence and reprint requests to: Atsuo Tomidokoro, Department of Ophthalmology, University of Tokyo School of Medicine, 7-3-1 Hongo, Bunkyo-ku, Tokyo 113-8655, Japan
e-mail: tomidokoro-ky@umin.ac.jp

a significantly beneficial effect of preserving visual fields in NTG patients.⁸ Moreover, maintaining a lower IOP without remarkable fluctuation through a long period is crucial in the treatment of open-angle glaucoma.¹¹

The introduction of the intraoperative use of mitomycin C (MMC) has improved the success rate of trabeculectomy for primary open-angle glaucoma patients.^{12–15} However, there has been no study on IOP control and complications after trabeculectomy with MMC in NTG patients, except for a few studies with small numbers of subjects (25 or fewer).^{6,16,17} Moreover, since the postoperative target IOP is definitely lower in NTG patients compared with primary open-angle glaucoma patients, the NTG patients often face a greater risk of ocular hypotony and its associated complications, such as hypotonous maculopathy, choroidal detachment, and cataract development.^{16,17} These complications occur not only in the early postoperative period but also during the long-term follow-up after surgery. Therefore, the outcome of trabeculectomy should be evaluated based on long-term observations also for postoperative complications.

The purpose of this study was to evaluate long-term results of postoperative IOP control and complications after trabeculectomy with MMC in a relatively greater number of NTG patients whose postoperative follow-up periods were 3 or more years by using a life table analysis.

Patients and Methods

Clinical records were reviewed of 39 consecutive NTG patients who underwent initial trabeculectomy (i.e., who had no history of previous glaucoma surgery except laser procedures) using intraoperative MMC at the Department of Ophthalmology, University of Tokyo Graduate School of Medicine, and on whom postoperative follow-up was successfully carried out for 3 or more years. The postoperative follow-up period averaged 50.5 ± 8.4 (mean \pm SD) months. Patients who underwent a combined procedure of trabeculectomy and other ocular surgeries such as cataract surgery were not included.

The diagnosis of NTG was made according to evidence of typical glaucomatous optic disc cupping and visual field damage in eyes with normal IOP, open angles, and the absence of any contributing ocular or specific systemic disorders. IOP was measured by multiple observers using a Goldmann applanation tonometer, and normal IOP was defined as IOP that never exceeded 21 mmHg during the follow-up period, including 24-h fluctuation, which was assessed at 2- or 3-h intervals during an overnight stay in the hospital. Table 1 describes the characteristics of the patients, all of whom were Japanese. In general, the indication for trabeculectomy was progression of visual field damage when the maximum tolerable medication had already been prescribed or when there was risk of visual field loss threatening fixation, and surgery was performed only with the patient's informed consent. If both eyes of a patient underwent trabeculectomy during the above-

Table 1. Patient demographics at the time of surgery

Number of eyes	39
Age ^a (years)	55.2 \pm 9.4
Male/Female	19/20
Preop IOP ^a (mmHg)	15.9 \pm 1.9
Mean deviation ^a (dB)	-17.9 \pm 6.8

IOP, intraocular pressure.

^amean \pm SD.

mentioned period, data obtained for the eye that underwent surgery first was used.

Trabeculectomy was performed as follows. After local anesthesia, a limbal-based conjunctival flap and a scleral flap one-half the thickness of the sclera were produced at the superior temporal quadrant. The shape of the scleral flap was triangular, and its size was approximately 3.5 mm \times 3.5 mm. It was hinged at the corneal limbus. Small pieces of surgical sponges soaked in 0.04% MMC were placed under the conjunctival flap for 3 min. After the sponges were removed, the area was irrigated with a balanced salt solution. At the edge of the corneoscleral bed, a block of clear corneal and trabecular meshwork tissue was removed and peripheral iridectomy was performed. The scleral flap was sutured with three to five monofilament 10-0 nylon sutures, adjusted so that a little leakage around the scleral flap margin could be observed without shallowing of the anterior chamber. The conjunctiva and Tenon's capsule were closed using a 10-0 nylon running suture. The anterior chamber and filtering bleb were reformed with balanced salt solution to verify that the conjunctival wound was watertight.

The postoperative follow-up schedule involved daily eye examinations during the first 7 to 14 days of hospitalization, once a week for the first month in the outpatient clinic, and once a month thereafter. The follow-up studies involved IOP measurements with Goldmann applanation tonometer, precise slit-lamp biomicroscopy, and funduscopy. To keep appropriate IOP control, topical glaucoma therapy and/or laser suture lysis, or a needling procedure for bleb revision were also carried out when necessary. Visual acuity was measured every 4 months postoperatively. Visual fields were evaluated with the central 30-2 program of the Humphrey visual field analyzer (Humphrey, San Leandro, CA, USA) within 1 month preoperatively and then every 6 months postoperatively. The development of postoperative complications, such as hypotony, hypotonous maculopathy, blebitis, and endophthalmitis, was also carefully checked for at every visit.

To evaluate IOP control and the incidence of hypotonic complications during the postoperative follow-up period, the Kaplan-Meier life table method was used. Two different definitions of the endpoint (i.e., failure) of IOP control were separately applied: (1) when IOPs exceeding a level 30% lower than the preoperative IOP were obtained at three consecutive visits; and (2) when IOPs exceeding a level 20% lower than the preoperative IOP were obtained at three consecutive visits. Since glaucoma topical medications, laser

suture lysis, or the needling procedure were optionally carried out according to the doctor's decision during the postoperative follow-up period, the execution of those procedures was not taken into account when the failure of IOP control was decided. The incidence of postoperative late-onset hypotony was also evaluated using the same life table method, in which the endpoint was defined as when an IOP lower than 5 mmHg was obtained at three consecutive visits, except during the first postoperative month or when a treatment such as surgical bleb repair or autologous blood injection into the bleb had been performed to treat hypotony.

Results

Mean IOP decreased from 15.9 ± 1.9 mmHg preoperatively to 11.1 ± 1.3 mmHg 1 week after surgery ($P < 0.0001$, paired *t* test), and the significant reduction continued throughout the follow-up period up to 4 years postoperatively ($P < 0.0001$) (Fig. 1). Prior to surgery, the number of topical antiglaucomatous eye drops used averaged 1.0 ± 0.9 (range, 0-3), and oral acetazolamide 500 mg/day was prescribed for two patients. At the latest examination after surgery, the number of topical eye drops was reduced to 0.2 ± 0.5 (range, 0-2), and oral acetazolamide was not used by any patient. Laser suture lysis and the needling procedure were performed in 22 and 5 eyes, respectively, in the follow-up period. Figure 2 shows the cumulative survival rates determined by the Kaplan-Meier life table method, in which the endpoint (i.e., failure) of IOP control was defined as when an IOP more than 30% lower than the preoperative IOP was obtained at three consecutive visits. The cumulative survival rates at 1, 2, 3, and 4 years postoperatively were 58.7 ± 7.1 (mean \pm SEM), 39.4 ± 7.8 , 39.4 ± 7.8 , and $39.4 \pm 7.8\%$, respectively. When the endpoint of IOP control was defined as an IOP exceeding a level 20% lower than the preopera-

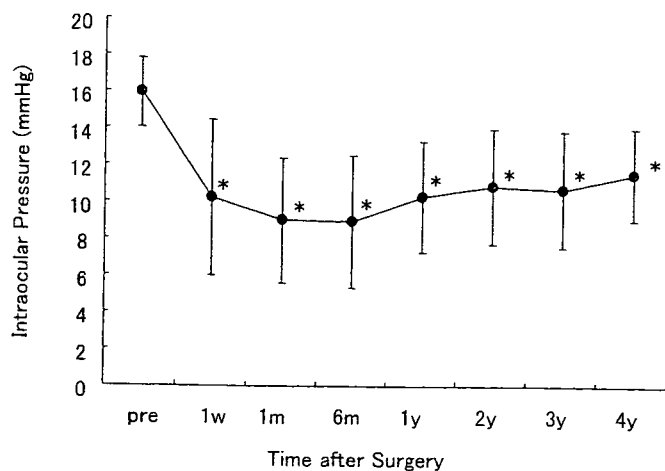


Figure 1. Averages of intraocular pressures (IOPs) before and after trabeculectomy with mitomycin C. Error bars show SD. *significantly smaller than the preoperative value (paired *t* test, $P < 0.0001$).

tive IOP was obtained at 3 consecutive visits, the cumulative survival rate increased to $41.3 \pm 8.9\%$ at 4 years postoperatively (Fig. 3).

There was no significant difference in mean deviation of the visual field results between the preoperative value (-17.9 ± 6.8 dB) and the last obtained value (-17.4 ± 6.9 dB) ($P > 0.5$, Fig. 4).

Figure 5 shows the cumulative survival rate from postoperative late-onset hypotony, to which the above-mentioned endpoint was applied. The cumulative survival rate from hypotony was approximately $74.7 \pm 6.3\%$ at 4 years after surgery. All postoperative complications found

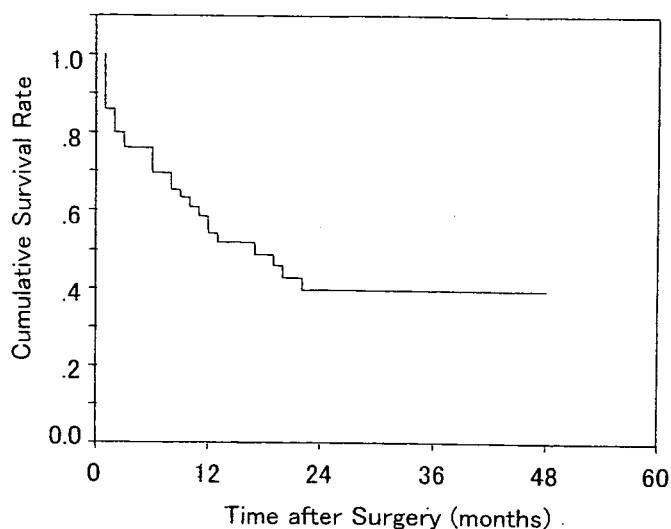


Figure 2. Cumulative survival rate determined with the Kaplan-Meier life table method, in which the endpoint (i.e., failure) of IOP control was defined as when IOPs exceeding a level 30% lower than the preoperative IOP were obtained at three consecutive visits.

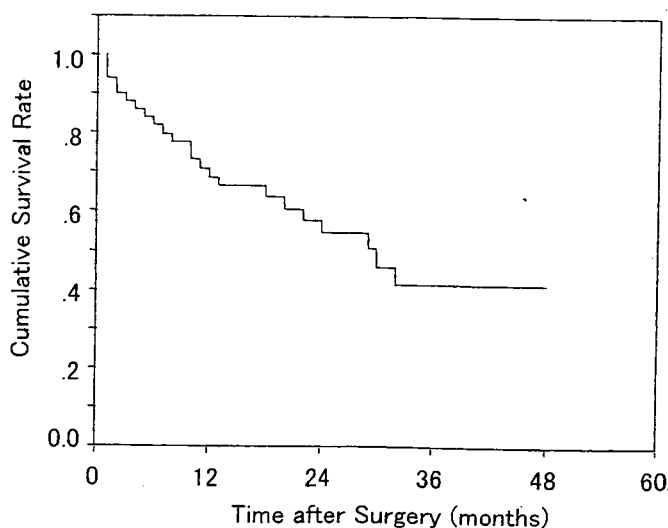


Figure 3. Cumulative survival rate determined with the Kaplan-Meier life table method, in which the endpoint (i.e., failure) of IOP control was defined as when IOPs exceeding a level 20% lower than the preoperative IOP were obtained at three consecutive visits.

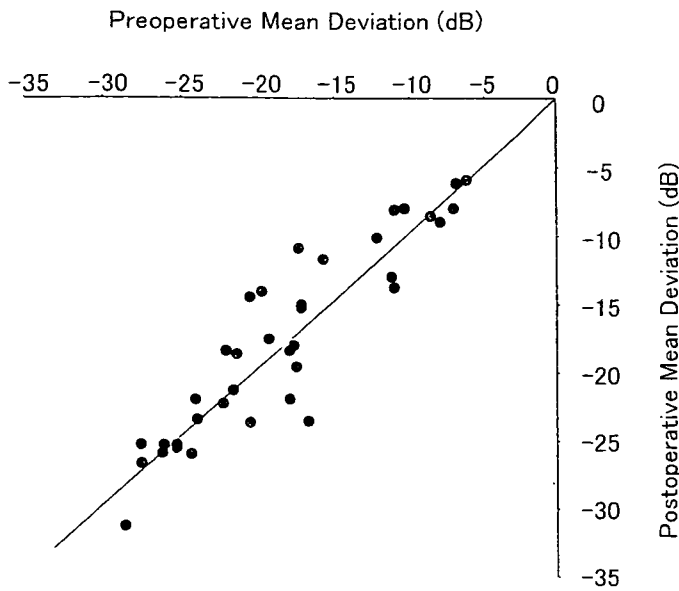


Figure 4. Changes in mean deviation of the visual field results obtained preoperatively and at the last postoperative visit.

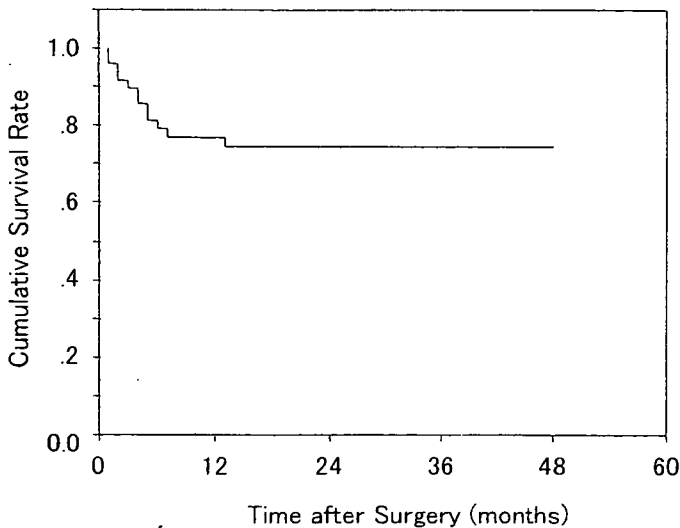


Figure 5. Cumulative survival rate from late-onset hypotony determined with the Kaplan-Meier life table method, in which the endpoint was defined as when IOPs lower than 5 mmHg were obtained at three consecutive visits or when the treatments were started to treat hypotony.

during the follow-up period are listed in Table 2. The two most common late-onset complications were those relating to the hypotonic conditions: choroidal detachment in nine eyes (23.6%) and maculopathy in seven (18.4%). In three eyes, cataract development was seen, but it was not necessary to perform cataract surgery. There were two infection cases; both were local blebitis and were successfully cured with local or systemic antibiotics. No eye developed endophthalmitis. Visual acuity was maintained in all eyes

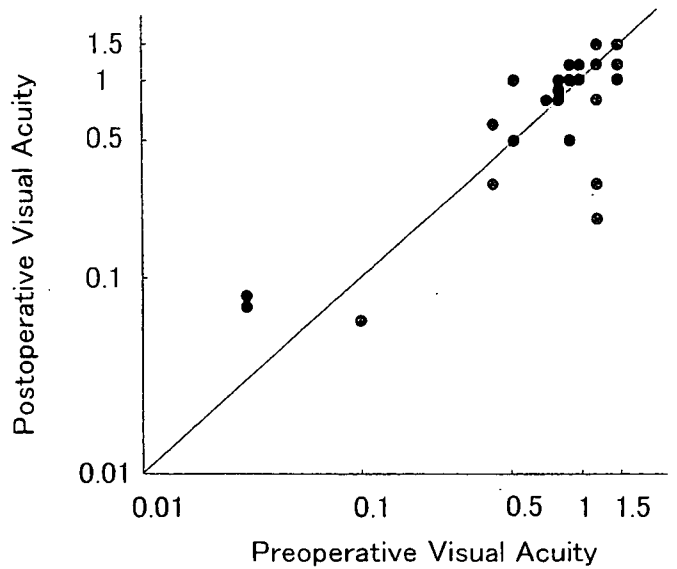


Figure 6. Changes in visual acuity decided preoperatively and at the last postoperative visit.

Table 2. Postoperative complications

	Number of eyes
Early complications	
Shallow anterior chamber	6
Choroidal detachment	9
Late complications	
Maculopathy	7
Bleb leak	1
Cataract	3
Infection (blebitis)	2

except the three in which cataract development was seen (Fig. 6).

Discussion

Mean IOP in 39 NTG patients decreased from approximately 15.9 ± 1.9 mmHg preoperatively to 11.1 ± 1.3 mmHg after trabeculectomy with MMC, and the significant IOP reduction continued up to 4 years (Fig. 1). However, when the outcome was analyzed using the life table method, only about 40% of the patients maintained successful IOP control 4 years after surgery (Figs. 2 and 3). In those life table analyses, the endpoint (i.e., failure) of IOP control was defined as when IOPs exceeding a level 30% or 20% lower than the preoperative IOP were obtained at three consecutive visits. We adopted those endpoints of IOP control in accordance with the results of a previous randomized control study in which an IOP reduction of 30% or 20% had a significantly favorable effect on the retardation of visual field defects in NTG patients.⁸

Hagiwara et al.¹⁶ reported that IOP decreased from 14.8 ± 1.8 mmHg preoperatively to 9.6 ± 3.9 mmHg at one time

point between 2 and 7 years after trabeculectomy with MMC in 21 Japanese NTG patients. The current results shown by the 39 NTG patients included in this study are similar, and provide further information about the cumulative "survival" rate of IOP control after surgery, which should be considered as important as mean IOP change. On the other hand, the postoperative IOP control in the current study seems to be worse relative to the results of previous studies in Western countries. Membrey et al.¹⁷ reported that the cumulative survival rate, regarded as a 25% IOP reduction at 2 years after trabeculectomy with 0.01% MMC, which was a lower concentration than used in the current study (0.04%), in 25 NTG patients was approximately 65%. Although differences in the postoperative follow-up periods and in the preoperative IOP levels should be taken into account, discrepancies in fibrotic reactions after trabeculectomy between Japanese and peoples of Western countries should account for the differences in IOP "survival" rates after trabeculectomy with MMC.

In the current study, we found several cases with late-onset postoperative complications, including hypotonous maculopathy (7/39 eyes, 18%), bleb leak (1/39 eyes, 3%), cataract (3 eyes, 8%), and blebitis (2 eyes, 5%), while no eyes developed cataract requiring surgery or endophthalmitis (Table 2). The life table analysis was used only to assess the incidence of hypotonous maculopathy. Since complications other than hypotonous maculopathy occurred in only a few patients, the life table method was not used for them. According to the life table analysis of the current results, the cumulative survival rate from postoperative hypotony was calculated as 75% at the 4-year follow-up (Fig. 5). Compared with the results reported by Membrey et al.,¹⁷ the incidence of late hypotony (12% in their report) and that of hypotonous maculopathy (28%) are similar in our patients, while those of bleb leak (12%), cataract (surgery needed in 12%), and endophthalmitis (8%) are apparently different. These data suggest that aqueous leakage from thin-walled blebs may be associated with the development of more severe cataract and endophthalmitis.

Trabeculectomy using MMC has been a standard surgical procedure to reduce IOP in open-angle glaucoma patients. However, in patients who show a lower preoperative IOP, the amount of surgical IOP reduction should be smaller and the risk of postoperative complications should be greater or similar. If these points are taken into consideration, neither a case that does not show apparent progression in visual field damage, nor one in which baseline IOP is quite low has a good indication for surgery.

It is essential to have reliable information about the probability of maintaining successful IOP control after surgery and avoiding the risks of postoperative complications. Since this study was done in a retrospective manner, there might have been unexpected, uncontrolled, or con-

flicting factors. Prospective trials including strictly scheduled follow-up are necessary to provide definitive evidence of the efficacy and risks of trabeculectomy with MMC in NTG patients. Until this evidence becomes available, the results of this study should be helpful when therapeutic options are chosen for NTG patients.

References

1. Hollands FC, Graham PA. Intra-ocular pressure, glaucoma, and glaucoma suspects in a defined population. *Br J Ophthalmol* 1966; 50:570-586.
2. Bengtsson B. The prevalence of glaucoma. *Br J Ophthalmol* 1981; 65:46-49.
3. Klein BE, Klein R, Sponsel WE, et al. Prevalence of glaucoma. The Beaver Dam Eye Study. *Ophthalmology* 1992;99:1499-1504.
4. Shiose Y, Kitazawa Y, Tsukahara S, et al. Epidemiology of glaucoma in Japan—a nationwide glaucoma survey. *Jpn J Ophthalmol* 1991; 35:133-155.
5. Abedin S, Simmons RJ, Grant WM. Progressive low-tension glaucoma: treatment to stop glaucomatous cupping and field loss when these progress despite normal intraocular pressure. *Ophthalmology* 1982;89:1-6.
6. Hitchings RA, Wu J, Poinosawmy D, et al. Surgery for normal tension glaucoma. *Br J Ophthalmol* 1995;79:402-406.
7. Koseki N, Araie M, Shirato S, et al. Effect of trabeculectomy on visual field performance in central 30 degrees field in progressive normal-tension glaucoma. *Ophthalmology* 1997;104:197-201.
8. Collaborative Normal-Tension Glaucoma Study Group. Comparison of glaucomatous progression between untreated patients with normal-tension glaucoma and patients with therapeutically reduced intraocular pressures. *Am J Ophthalmol* 1998;126:487-497.
9. Daugeliene L, Yamamoto T, Kitazawa Y. Effect of trabeculectomy on visual field in progressive normal-tension glaucoma. *Jpn J Ophthalmol* 1998;42:286-292.
10. Shigeeda T, Tomidokoro A, Araie M, et al. Long-term follow-up of visual field progression after trabeculectomy in progressive normal-tension glaucoma. *Ophthalmology* 2002;109:766-770.
11. The AGIS Investigators. The Advanced Glaucoma Intervention Study (AGIS). 7. The relationship between control of intraocular pressure and visual field deterioration. *Am J Ophthalmol* 2000;130: 429-440.
12. Shields MB, Scroggs MW, Sloop CM, et al. Clinical and histopathologic observations concerning hypotony after trabeculectomy with adjunctive mitomycin C. *Am J Ophthalmol* 1993;116:673-683.
13. Greenfield DS, Parrish RK II. Bleb rupture following filtering surgery with mitomycin-C: clinicopathologic correlations. *Ophthalmic Surg Lasers* 1996;27:876-877.
14. Belyea DA, Dan JA, Stamper RL, et al. Late onset of sequential multifocal bleb leaks after glaucoma filtration surgery with 5-fluorouracil and mitomycin C. *Am J Ophthalmol* 1997;124:40-45.
15. Sihota R, Dada T, Gupta SD, et al. Conjunctival dysfunction and mitomycin C-induced hypotony. *J Glaucoma* 2000;9:392-397.
16. Hagiwara Y, Yamamoto T, Kitazawa Y. The effect of mitomycin C trabeculectomy on the progression of visual field defect in normal-tension glaucoma. *Graefes Arch Clin Exp Ophthalmol* 2000;38: 232-236.
17. Membrey WL, Poinosawmy DP, Bunce C, et al. Glaucoma surgery with or without adjunctive antiproliferatives in normal tension glaucoma. 1. Intraocular pressure control and complications. *Br J Ophthalmol* 2000;84:586-590.

Frequency Doubling Technology and Scanning Laser Tomography in Eyes With Generalized Enlargement of Optic Disc Cupping

Shiho Kunimatsu, MD,* Goji Tomita, MD,* Makoto Araie, MD,* Makoto Aihara,*
Yasuyuki Suzuki, MD,† Aiko Iwase, MD,‡ Nobuyuki Koseki, MD,§ Shun Matsumoto, MD,¶
Yoshio Yamazaki, MD,|| and Keiji Yoshikawa, MD#

Purpose: To characterize functional and structural changes in eyes with generalized enlargement of optic disc cupping (vertical cup/disc ratio ≥ 0.8), normal intraocular pressure, normal standard achromatic automated perimetry (SAP) results, and no other ophthalmoscopic findings suggesting glaucoma (large C/D eyes) using frequency doubling technology (FDT) and the Heidelberg Retina Tomograph (HRT).

Methods: This comparative observational case series included 30 large C/D eyes (30 subjects), 17 eyes (17 patients) with early-stage normal tension glaucoma with generalized enlargement of optic disc cupping (NTG eyes), and 25 eyes from 25 normal subjects (normal eyes). Results with Humphrey 30-2, FDT N-30 threshold programs, and HRT were compared among these groups. Large C/D eyes were subdivided into FDT-normal and -abnormal eyes according to the predetermined criteria and HRT parameters were compared among them.

Results: No significant difference was seen in HRT parameters between the large C/D and NTG eyes. In the large C/D eyes, FDT mean deviation was lower than in the normal eyes and higher than in the NTG eyes, whereas FDT pattern standard deviation was smaller than in the NTG eyes ($P = 0.02-0.03$). Among HRT parameters, only cup shape measure (CSM) showed significant negative correlation with FDT mean deviation in the large C/D eyes. Between FDT-normal and -abnormal subgroups, only CSM showed significant difference ($P < 0.01$).

Conclusion: Frequency doubling technology showed abnormalities in large C/D eyes. Only CSM showed significant correlation with FDT result and difference between those with normal and abnormal

FDT results. In management of large C/D eyes, FDT and CSM will be useful to detect functional and structural change.

Key Words: cup shape measure, frequency doubling technology, the Heidelberg Retina Tomograph, large C/D eyes, large cup/disc ratio, normal-tension glaucoma, scanning laser tomography, standard achromatic automated perimetry

(*J Glaucoma* 2005;14:280-287)

INTRODUCTION

Early structural abnormalities of the optic nerve head and nerve fiber changes usually precede clinically detectable visual field loss measured by standard achromatic automated perimetry (SAP).¹⁻⁷ Therefore, careful detection of structural changes in the optic nerve head is important for early diagnosis of glaucoma. In clinical practice, we sometimes encounter an eye with generalized enlargement of optic disc cupping (cup/disc ratio ≥ 0.8) but no other findings suggestive of glaucoma, such as a nerve fiber layer bundle defect or localized rim thinning, and with both normal intraocular pressure (IOP) and SAP results. However, there are no definitive methods to determine whether such a disc represents a variant of a normal disc or very early-stage normal tension glaucoma (NTG).

There are several psychophysical tests that might detect visual field abnormalities in patients with glaucoma years earlier than SAP, short-wavelength automated perimetry (SWAP),^{8,9} high pass resolution perimetry,¹⁰ motion perimetry,¹¹ or frequency doubling technology (FDT).¹²⁻¹⁴ According to one report,¹⁴ FDT distinguishes patients with glaucoma from normal subjects more often than SWAP or motion perimetry. Compared with SAP, the test-retest variability of FDT is lower with a shorter test time.¹⁵

Laser scanning tomography provides three-dimensional, highly reproducible measurements of the optic nerve head.^{16,17} Several studies indicate that topographic optic disc parameters obtained using this technique can distinguish glaucomatous discs from normal discs with relatively high sensitivity and specificity.¹⁸⁻²⁰

In the present study, we sought both to evaluate whether there were abnormalities in FDT perimetry in eyes with generalized enlargement of optic disc cupping with a vertical

Received for publication July 19, 2004; accepted January 18, 2005.

From *Department of Ophthalmology, University of Tokyo Graduate School of Medicine, Tokyo, Japan; †Department of Ophthalmology, Teikyo University of Medicine, Ichihara Hospital, Ichihara, Japan; ‡Department of Ophthalmology, Tajimi Municipal Hospital, Gifu, Japan; §Koseki Eye Clinic, Saitama, Japan; ¶Department of Ophthalmology, Tokyo Post and Telecommunication Hospital, Tokyo, Japan; ||Department of Ophthalmology, Nihon University, School of Medicine, Tokyo, Japan; #Yoshikawa Eye Clinic, Tokyo, Japan.

Reprints: Shiho Kunimatsu, Department of Ophthalmology, The University of Tokyo Graduate School of Medicine, 7-3-1 Hongo, Bunkyo-ku, Tokyo, 113-8655, Japan (e-mail: shihok-tyk@umin.ac.jp).

Copyright © 2005 by Lippincott Williams & Wilkins