The Breast (2005) 14, 322–324

ELSEVIER

THE
BREAST

www.elsevier.com/locate/breast

CASE REPORT

Intracystic papillary carcinoma of the breast in a male patient diagnosed by core needle biopsy: a case report

Takayuki Kinoshita[a,*], Takashi Fukutomi[a], Eriko Iwamoto[a], Miyuki Takasugi[a], Sadako Akashi-Tanaka[a], Tadashi Hasegawa[b]

[a]*Surgical Oncology Division, National Cancer Center Hospital, 5-1-1 Tsukiji, Chuo-ku, Tokyo 104-0045, Japan*
[b]*Pathology Division, National Cancer Center Research Institute, Japan*

Received 17 August 2004; received in revised form 29 November 2004; accepted 15 December 2004

KEYWORDS
Intracystic papillary carcinoma;
Male breast carcinoma;
Core needle biopsy

Summary We report a case of intracystic papillary carcinoma (IPC) of the breast in a 71-year-old man in whom diagnosis was made by core needle biopsy. He came to our hospital complaining of a left subareolar mass. Imaging diagnosis was a cyst with an intracystic component. Since aspiration biopsy cytology was interpreted as a borderline lesion, the decision was made to proceed with core needle biopsy.

Pathological examination of the specimen revealed the intracystic component to be non-invasive papillary carcinoma. So the patient underwent simple mastectomy without axillary node biopsy. From the final pathological result, no invasion was identified.
© 2005 Elsevier Ltd. All rights reserved.

Introduction

Male breast cancer is an uncommon disease with an incidence of approximately 1% of all breast cancers.[1] Intracystic papillary carcinoma (IPC) forms a small subgroup of breast carcinomas with a favorable prognosis.[2,3] Core needle biopsy has been increasingly utilized as initial approach for the diagnosis of mammographic abnormalities and palpable breast lesions. In this report, we describe a case of mammary IPC diagnosed in a 71-year-old man by core needle biopsy. We discuss the clinicopathological features of cystic breast cancer in the male and review the literature and the present case.

Case report

A 71-year-old man, complaining of a round mass in his subareolar region with bloody nipple discharge,

*Corresponding author. Tel.: +81 3 3542 2511; fax: +80 3 3542 3815.
E-mail address: takinosh@ncc.go.jp (T. Kinoshita).

0960-9776/$ - see front matter © 2005 Elsevier Ltd. All rights reserved.
doi:10.1016/j.breast.2004.12.003

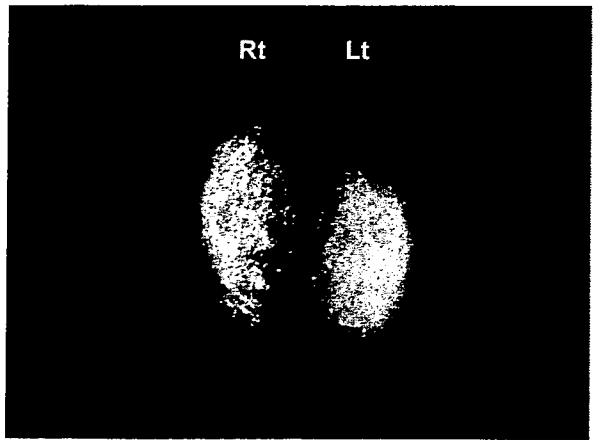

Figure 1 Mammogram revealed a 6 cm lobulated mass in his left breast and subareolar gynecomastia in his right breast.

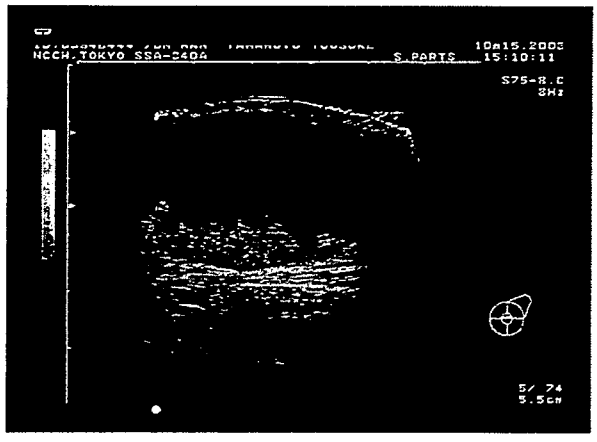

Figure 2 Ultrasound studies showed a cystic lesion with an intracystic component.

visited the National Cancer Center Hospital in October 2003. He had a past history of lung cancer and gastric cancer. There was no reported history of breast trauma. He had gynecomastia in his right breast. The tumor was $6 \times 5\,cm^2$ in size with a smooth surface and clear margin. No overlying skin retraction and no palpable axillary lymph nodes were noted.

Mammogram revealed a 6 cm lobulated mass in his left breast and subareolar gynecomastia in his right breast (Fig. 1). Ultrasound studies showed a cystic lesion with an intracystic component (Fig. 2).

We diagnosed intracystic papilloma or carcinoma from the radiological appearance of the intracystic lesion. So, the decision was made to proceed with core needle biopsy. Three passes with 16-gauge biopsy gun were performed. The diagnosis of non-invasive papillary carcinoma was made on core needle biopsy (Fig. 3). Finally, we diagnosed the

Figure 3 Core needle biopsy demonstrates a solid epithelial proliferation composed of papillary structures with fibrovascular cores lined by a uniform population of neoplastic cuboidal cells. No invasion was identified.

tumor as intracystic carcinoma from these combined informations. The patient underwent simple mastectomy without axillary lymph node biopsy. Because the role of adjuvant therapy is not clearly defined for this type of tumor, no other treatment was performed.

Pathologic findings

The specimen consisted of a simple mastectomy with an overlying ellipse skin with nipple. A $4.1 \times 2.0\,cm^2$ well-circumscribed, partially hemorrhagic cystic mass was identified under the areola. At lower-power magnification, the cyst wall was lined by multilayered flat epithelial cells, and papillary epithelial lesions with a fibrous stalk present in the wall (Fig. 4A).

At higher magnification, this solid papillary proliferation is composed of neoplastic cells with mild nuclear atypia and a high mitotic index (Fig. 4B). Since no evidence of stromal invasion was found, the lesion was diagnosed as IPC, high grade.

The immunohistological examination for cancer cells revealed positive for estrogen and progesterone receptor, and negative for HER-2 and p53 protein.

Discussion

IPC of the breast in the male is a very rare disease and it also shows a good prognosis. IPC represents a small subgroup of breast cancers and accounts 0.5–2% of breast cancer in women.[2] Some studies have suggested that they form a higher percentage in men, with an incidence range of 5–7.5%.[4,5] Furthermore, increased risk in men with gynecomastia has been reported.[6] Pacelli,[7] in a recent review of the literature, reported that nine

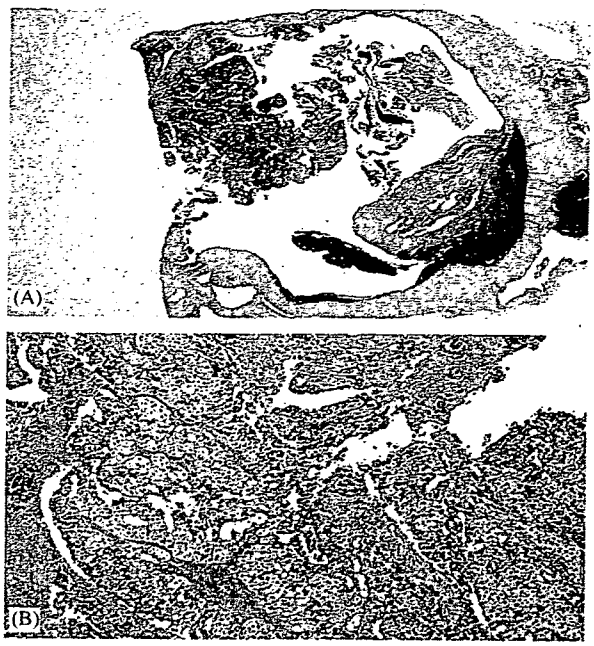

Figure 4 (A) Microscopic feature of the cystic lesion. The cyst wall was lined by multilayered flat epithelial cells, and a papillary epithelial lesion with a fibrous stalk is present in the wall. (B) At higher magnification, this solid papillary proliferation is composed of neoplastic cells with mild nuclear atypia and a high mitotic index. Since no evidence of stromal invasion was found, the lesion was diagnosed as IPC, high grade.

patients underwent fine-needle aspiration, but only four cases were positive for malignant cells. In the remaining patients, fine-needle biopsy gave either negative (two cases), or borderline results (three cases). Imoto,[8] in a review of Japanese literature, also stated that the difficulty in obtaining a definite diagnosis of malignancy by fine-needle aspirate can attributed to the cystic and hemorrhagic nature of these lesions. Only one case was reported that was diagnosed by core needle biopsy.[7] Fine-needle aspiration cytology in male breast lesions is a useful technique and has been shown to be highly sensitive and specific with good cytohistologic correlation.[9,10] However, many institutions have chosen core needle biopsy as alternative to fine-needle aspiration cytology due to the level complexity involved in the interpretation of breast cytology.[11] In our case, core needle biopsy was very useful in decision of operating procedure because of a favorable prognosis of this tumor.

The majority of the reports confirm excellent prognosis associated with pure IPC. The low frequency of axillary node metastases with pure IPC does not justify axillary lymph node dissection.[12] The role of sentinel node biopsy has not been evaluated in this disease, but sentinel node biopsy may be an excellent alternative to full axillary dissection in patients with IPC and associated invasive carcinoma. Lumpectomy is an option for pure IPC. However, the role of radiotherapy in these patients remains undefined. The majority of patients with IPC will have associated DCIS or invasive cancer, or both, and should be treated on the basis of this associated pathology.

Our case report demonstrates that the ICP can be accurately diagnosed by core needle biopsy and the radiological feature of the tumor in a male patient. Because of a favorable prognosis of this tumor, histologic finding is very important in decision of operating procedure.

References

1. Haagensen CD. *Disease of the breast*. Philadelphia: WB Saunders; 1986.
2. Czernobilsky B. Intracystic carcinoma of female breast. *Surg Gynecol Obstet* 1967;**124**:93–8.
3. Carter D, Orr SL, Merino M. Intracystic papillary carcinoma of the breast after mastectomy, radiotherapy or excision biopsy alone. *Cancer* 1983;**52**:14–9.
4. Heller KS, Rosen PP, Schottenfeld D, Ashikari R, Kenne DW. Male breast cancer: clinicopathologic study of 97 cases. *Ann Surg* 1978;**188**:60–5.
5. Wolff M, Renis MS. *Breast cancer in males: clinicopathologic study of 40 patients*. New York: Masson Publishing; 1981.
6. Liechty RD, Davis J, Gleysteen J. Cancer of the male breast: forty cases. *Cancer* 1967;**20**:1617–24.
7. Pacceli A, Bock BJ, Jensen EA, et al. Intracystic papillary carcinoma of male breast in a male patient diagnosed by ultrasound-guided core biopsy. *Breast J* 2002;**8**:387–90.
8. Imoto S, Hasebe T. Intracystic papillary carcinoma of the breast in male: case report and review of the Japanese literature. *Jpn J Clin Oncol* 1998;**28**:517–20.
9. Joshi A, Kapila K, Verma K. Fine needle aspiration cytology in the management of male breast masses. Nineteen years experience. *Acta Cytol* 1999;**43**:334–8.
10. Dei Tos AP, Della Giustina D, Bittesini L. Aspiration biopsy cytology of malignant papillary breast neoplasms. *Diagn Cytopathol* 1992;**8**:580–4.
11. Masood S. Fine-needle aspiration biopsy of nonpalpable breast lesions. Challenges and promises. *Cancer Cytolpathol* 1998;**84**:197–9.
12. Carmen CS, Lavinia PM, Kelly KH, et al. Treatment and outcome with intracystic papillary carcinoma of the breast. *Am J Surg* 2002;**184**:364–8.

Available online at www.sciencedirect.com
SCIENCE DIRECT

Breast Cancer
Vol. 12 No. 2 April 2005

Panel Discussion

Analysis of Ipsilateral Breast Tumor Recurrences after Breast-conserving Treatment Based on The Classification of True Recurrences and New Primary Tumors

Yoshifumi Komoike[*1], Futoshi Akiyama[*2], Yuichi Iino[*3], Tadashi Ikeda[*4], Sadako Tanaka-Akashi[*5], Shozo Ohsumi[*6], Mikihiro Kusama[*7], Muneaki Sano[*8], Eisei Shin[*9], Kimito Suemasu[*10], Hiroshi Sonoo[*11], Tetsuya Taguchi[*12], Tunehiro Nishi[*13], Reiki Nishimura[*14], Shunsuke Haga[*15], Keiichi Mise[*16], Takayuki Kinoshita[*17], Shigeru Murakami[*18], Masataka Yoshimoto[*19], Hideaki Tsukuma[*20], and Hideo Inaji[*1]

*[*1]Department of Surgery, Osaka Medical Center for Cancer and Cardiovascular Diseases, [*2]Department of Breast Pathology, Cancer Institute Hospital, [*3]Department of Emergency and Critical Care Medicine, Gunma University Faculty Medicine, [*4]Department of Surgery, Keio University School of Medicine, [*5]Division of Breast Surgery, National Cancer Center Hospital, [*6]Department of Surgery, National Shikoku Cancer Center, [*7]Department of Second Surgery, Tokyo Medical Colledge, [*8]Department of Surgery, Niigata Cancer Center Hospital, [*9]Department of Surgery, National Osaka Hospital, [*10]Department of Surgery, Saitama Cancer Center, [*11]Department of Breast and Thyroid Surgery, Kawasaki Medical School, [*12]Department of Surgical Oncology, Osaka University Graduate School of Medicine, [*13]Department of Surgery, Mitsui Memorial Hospital, [*14]Department of Surgery, Kumamoto City Hospital, [*15]Department of Surgery, Tokyo Women's Medical University Daini Hospital, [*16]Kodama Clinic, [*17]Department of Surgery, National Tokyo Medical Center Hospital, [*18]Department of Breast Oncology, National Kyushu Cancer Center, [*19]Department of Breast Surgery, Cancer Institute Hospital, [*20]Department of Cancer Control and Statics, Osaka Medical Center for Cancer and Cardiovascular Diseases, Japan.*

Background: Ipsilateral breast tumor recurrences (IBTR) after breast-conserving treatment include two different entities: true recurrence (TR) thought to occur when residual cancer cells grow gradually to detectable size and new primary (NP) thought to be de novo cancer independently arising in the preserved breast. The patients with ipsilateral breast tumor recurrence (IBTR) are potentially at high risk for subsequent distant metastasis, but many studies do not distinguish between these types of recurrence. The aim of this study is to clarify the biological difference between TR and NP, and to show the clinical significance of classifying IBTR into these two types of recurrence.

Patients and Method: A total of 172 patients with IBTR after breast-conserving therapy from the cohort of a long-term large scale study (Research of cancer treatment from the Ministry of Health, Labor and Welfare of Japan (no.13-9)) were analyzed. We classified IBTRs as TR or NP based on tumor location and pathological findings. The characteristics of the primary tumors of TR and NP were compared. Survival rates and risk factors of each type of IBTR were examined by the Kaplan-Meier method. The results of salvage surgery were also analyzed.

Results: Of the 172 patients, 135 patients were classified as TR and 26 as NP. Eleven cases could not be categorized. The primary tumor of TR was characterized by a high rate of lymph node metastasis (37.8%) and short disease-free interval (mean DFI; 46.6 months) while that of NP showed a rather low lymph node positivity (8.7%) and longer DFI (62.1 months). The risk factors for TR were young age, positive surgical margin, omission of irradiation and positive lymph node metastasis. Those for NP were young age, omission of irradiation and contralateral breast cancer after the primary operation. The 5-year survival rates after IBTR were 71.0% in TR and 94.7% in NP ($p=0.022$). Salvage operation was performed in 136 IBTRs. Eighty-one patients underwent salvage mastectomy and 55 patients underwent repeat lumpectomy. Five-year survival rates after salvage operation were 75.7% for mastectomy and 84.2% for lumpectomy (N.S.). Twenty percent of patients who underwent repeat lumpectomy developed secondary local relapse within 5 years after salvage treatment. The risk factors for secondary local relapse were analyzed. Limited to cases of IBTR which received radiation therapy after the primary operation, NP was the only factor influencing secondary local relapse by univariate analysis.

Conclusions: TR and NP show clinically quite different features; time to occurrence, characteristics of the original tumor, prognosis and risk factor profile for IBTR were all different. Classifying IBTR as TR or NP can provide clinically significant data for the management of IBTR.

Breast Cancer 12:104-111, 2005.

Key words: Breast cancer, Breast-conserving treatment, Ipsilateral breast tumor recurrence, True recurrence, New primary

A number of prospective and retrospective studies have shown that breast-conserving therapy is standard of care for Stages I and II breast cancer. Twenty-year follow-up data from the NSABP B-06 and Milan trials showed equal survival between mastectomy and conservative surgery. Those same results also showed ipsilateral breast tumor recurrence (IBTR) over 10 years after primary operation even though the rate was under 1% per year[1, 2]. The increasing number of women opting for breast conservation means that IBTR is becoming a significant clinical issue[3-5].

The IBTR rate is about 5% to 10% at 5 years and 10% to 15% at 10 years[3, 5]. There is an increasing risk of relapse in the first few years after primary operation which levels off after approximately 5 years[6]. The average interval to IBTR ranges 34 to 60 months[5]. Most studies have found that omission of postoperative irradiation, resection margin status, young age, an extensive intraductal component (EIC) and lymphatic vessel invasion correlate with a higher risk of IBTR[3, 5, 7, 8]. The overall survival after IBTR averages about 74% at 5 years and 65% at 10 years and the disease-free survival averages 60% at 5 years and 57% at 10 years[5]. These survival rates are better than those of patients with chest wall recurrence after mastectomy[7]. It is, however, often reported that IBTR is actually one of the strongest prognostic variables available to predict distant metastases or death from breast cancer[9, 10]. Most studies have reported that the relative risk of distant metastases with IBTR ranges from three- to five- fold[5]. The interval between initial treatment and local relapse, nodal status at the time of initial treatment and initial tumor size were reported to correlate with subsequent distant metastasis[3, 5-7, 11]. Whether IBTR is a determinant or indicator of distant metastases is now unclear. Currently, the standard treatment of IBTR is salvage mastectomy, which has provided locoregional control in 90% of patients[3, 7, 12]. The use of repeat lumpectomy as an alternative to mastectomy, chemotherapy, endocrine therapy and additional partial irradiation remain controversial[5, 13-15]. The optimal systemic therapy after IBTR is also unknown[4]. Thus the issues arising from IBTR such as biological behavior and treatment options are expected to be clear[4, 5, 16].

One of the concerns regarding IBTR is whether it is a recurrent tumor or a second primary tumor. It recently became clear that a significant portion of patients with IBTR actually have new primary tumors[17, 18]. In considering IBTR, it is worth to note that IBTR may represent two distinct entities. Veronesi *et al.* related in their report that true recurrences (TR) were cases consistent with the regrowth of malignant cells not removed by surgery or not killed by radiotherapy. Alternatively, new primary tumors were *de novo* cases of malignancies arising from mammary epithelial cells of residual breast tissue[10]. Some studies suggested that NP recurrence had a longer mean time to IBTR, was more frequent with young patients, more likely to occur in a different quadrant from the initial tumor and were associated with improved survival[6, 17, 19]. The complicated behavior of IBTR may be related to the fact that the patient population represents these two distinct entities. The location of the first and secondary tumor, as Recht *et al.* and most other investigators reported, was used in classifying TR/NP[19]. Histological subtypes and time to relapse were also used[6, 20]. The presence of carcinoma *in situ*, a different histologic type, or better differentiation of the second cancer may help in identifying independent tumors[21]. Recently, some molecular techniques such as DNA finger printing, loss of heterozygosity (LOH) pattern or allelic imbalances profile have been used to distinguish NP from TR[22], but the classification rules are not standardized yet.

We collected information on Japanese women who had received breast-conserving treatment with the support of the Ministry of Health, Labor and Welfare of Japan. The long-term follow-up results will be described elsewhere. In the current study, we tentatively classified IBTR as TR or NP, and the characteristics, prognosis and risk factors were compared. Also the results of salvage surgical treatment were discussed.

Reprint requests to Yoshifumi Komoike, Department of Surgery, Osaka Medical Center for Cancer and Cardiovascular Diseases, 1-3-3 Nakamichi, Higashinari-ku, Osaka 537-8511, Japan.
E-mail: komoike-yo@mc.pref.osaka.jp

Patient and Method

Patients and Clinical Data

A total of 172 patients with IBTR after breast-conserving therapy from the cohort of a long-term, large scale study (Research of cancer treatment from the Ministry of Health, Labor and Welfare of Japan (no.13-9)) were included in this study. This large scale study consisted of 1901 patients with unilateral breast cancer smaller than 3 cm in diameter who underwent BCT at 18 major institutes from 1986 to 1993. Patients who had received primary systemic therapy, and those with a past history of breast cancer were excluded. Post-operative irradiation and adjuvant therapy were not exclusion criteria. The surgical procedure was wide excision or quadrantectomy plus axillary lymph node dissection. The clinical data of the patients were collected from each institute by sending questionnaire forms. Factors requested included age at primary operation, menopausal status, initial tumor size by palpation, histological type, pathological lymph node status, histological margin status, lymphovascular invasion, nuclear grade, presence of extensive intraductal component (EIC), estrogen receptor (ER) status, progesterone receptor (PgR) status, adjuvant endocrine therapy, adjuvant chemotherapy and post-operative irradiation. The judgment of histological margin status varied among institutions. Close margins (< 5 mm from the cut edge of the specimen) were usually regarded as "positive margins". Serial sections of resected specimens were meticulously examined at all institutions. Measurement methods and cutoff levels of the hormone receptors were not standardized, and varied among institutions. Among 1901 patients, 182 had IBTR. One hundred seventy-two had IBTR as the first recurrence site and 10 had IBTR after distant metastasis. In this study, the 172 cases with IBTRs as a first event were examined.

Classification Criteria of TR/NP

Classification of TR/NP was based on the location of the primary and secondary tumor, initial surgical margin and other pathologic features. Ambiguous cases were principally classified as TR. Finally the judgment of TR/NP depended on each institution's decision. For example, if the recurrent tumor was located at the primary tumor bed, close to the cut edge or resection scar, it was judged as TR (such was most frequent with TR). Positive margins, especially cases with tumors located narrowly apart, supported TR. If the resection margin at the primary operation was negative and the locations were remote, it was judged as NP (this scenario was most frequent for NP recurrences). Even though the margin status was positive or close, if the locations were far enough apart, it was judged NP. Conversely, when the location was close to the primary tumor bed, if the margin status was completely negative and IBTR was morphologically quite different from the primary tumor, such cases were classified as NP. Thus the judgment was mainly based on location but all cases were carefully and individually determined.

Statistical Analysis

Local free, disease free, distant disease free, and overall survival rates were calculated using the Kaplan-Meier method. The statistical differences of local, distant, disease free rates and overall survival were proved using a log-rank test for univariate analysis. Multivariate analyses for local free, and distant disease free rates were performed using the Cox proportional hazards model. All statistical analyses were performed with JMP software Version 5.1 (SAS Institute, Cary, NC).

Results

The characteristics of 172 patients with IBTR were as follows. Mean age was 50.0 years and mean tumor size was 1.7 cm. Forty-two cases had positive lymph node status and 54 cases had positive surgical margins. Fifty-seven patients developed subsequent distant metastasis after IBTR. Among 172 IBTRs, 135 cases were judged TR, 26 were judged NP and 11 cases were difficult to classify.

The annual incidence of TR/NP is shown in Fig 1. The mean disease free interval (DFI) to TR was 47 months and DFI to NP was 62 months. The DFI of NP was statistically longer than that of TR ($p = 0.025$). The peak annual incidence of TR was at 3 to 4 years after the primary operation. Then the incidence gradually decreased. On the contrary, the incidence of NP did not change so much. As a result, the proportion of NP was low close to the time of primary operation but became relatively high as time progressed. The clinicopathologic features of the primary tumors devel-

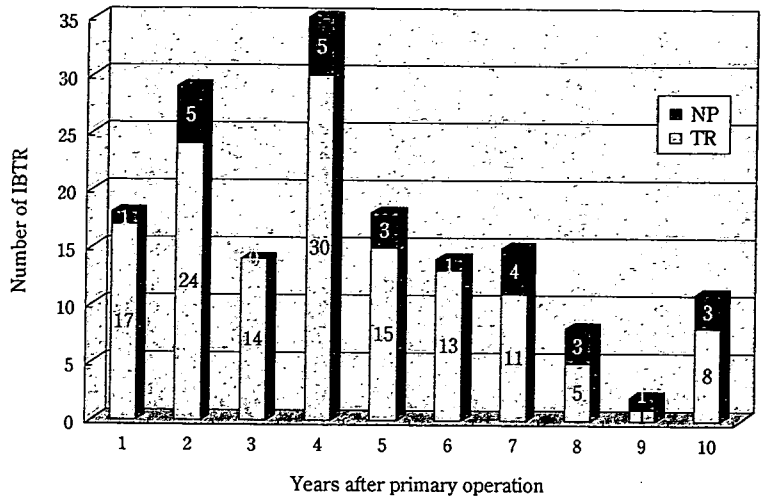

Fig 1. Annual incidence of ipsilateral breast tumor recurrence (IBTR) according to recurrence type.

oping TR/NP are compared in Table 1. The patients with NP were characterized by a low rate of positive lymph nodes of the primary tumor and longer DFI. There were not significant differences between the two groups with regard to age, primary tumor size, lymphovascular invasion and estrogen receptor status.

Risk factors of TR/NP are shown in Tables 2 and 3. Multivariate analysis showed that young age, positive lymph node metastasis, positive surgical margin and omission of postoperative irradiation were significant risk factors for TR (Table 2). Young age, contralateral breast cancer after primary operation and omission of post-operative irradiation were significant risk factors for NP (Table 3).

Fig 2 showed overall survival curves of TR/NP after primary operation by the Kaplan-Meier method. The 10-year overall survival rates were

Table 1. Comparison of Clinicopathological Characteristics between TR and NP

	TR	NP	*p*-value
Age	44.8	47.1	N.S.
Size (cm)	1.7	1.8	N.S.
LN (+/−)	37/98	2/23	*0.031
ly (+/−)	44/53	5/13	N.S.
ER (+/−)	47/44	9/4	N.S.
DFI (months)	46.6	62.1	**0.025

*chi-square test
**t-test

Table 2. Risk Factor for True Recurrence (TR) Detected by Uni- and Multivariate Analysis

Variable	risk/reference	univariate	multivariate		
		p-value	R.R.	*p*-value	95%C.I.
Age	≦35/>35	<0.0001	5.932	<0.0001	3.031-10.867
Size	>1 cm/≦1 cm	0.048	1.657	0.281	0.627-3.646
LN meta	positive/negative	0.028	2.064	0.009	1.205-3.457
Margin	positive/negative	<0.0001	2.921	<0.0001	1.562-5.341
EIC	positive/negative	0.0304	1.422	0.217	0.807-2.433
ER	negative/positive	0.0352	1.626	0.058	0.983-2.675
RT	(−)/(+)	<0.0001	3.491	<0.0001	2.024-6.033

R.R.; relative risk, EIC; extensive intraductal component, ER; estrogen receptor, RT; radiation therapy
Log-rank test was used for univariate analysis and Cox proportional hazard model was used for multivariate analysis.

Table 3. Risk Factor for New Primary (NP) Detected by Uni- and Multivariate Analysis

Variable	risk/reference	univariate	multivariate		
		p-value	R.R.	*p*-value	95%C.I.
Age	younger/older	0.017	1.046	<0.045	1.0028-1.1271
Ly	negative/positive	0.048	1.116	0.842	0.6556-7.3288
CBC	yes/no	0.004	4.950	0.036	1.8639-19.731
Endocrine therapy	(−)/(+)	0.0047	2.196	0.174	0.8163-21.881
Chemotherapy	(−)/(+)	0.0016	2.000	0.270	0.4921-17.374
Radiation	(−)/(+)	0.0002	3.090	0.023	1.3940-8.4595

CBC; contralateral breast cancer
Log-rank test was used for univariate analysis and Cox proportional hazard model was used for multivariate analysis.

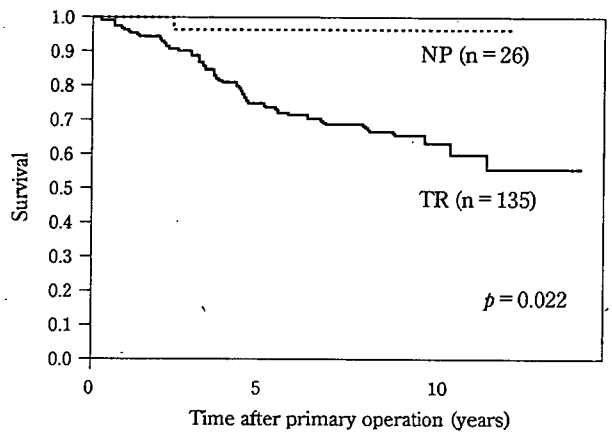

Fig 2. Survival rates of patients with true recurrence (TR) and new primary (NP) after primary operation.

71.2% in TR and 92.3% in NP, respectively. Patients with NP had significantly better survival rates than those with TR ($p = 0.02$).

Of 172 patients with local recurrence, 136 patients underwent salvage surgery. Fifty-five patients underwent repeat lumpectomy and 81 patients underwent salvage mastectomy. The 5-year distant disease-free survival rate was 74.6% in the mastectomy group and 75.0% in the lumpectomy group. There was no significant difference between the two groups. As for local relapse-free survival, however, the 5-year local relapse-free survival was 93.1% in the mastectomy group and 80.0% in the lumpectomy group. The difference was not great statistically, but the local recurrence rate was slightly higher in the lumpectomy group. Finally, the risk factors for secondary local relapse were examined by univariate analysis limited to the patients who underwent breast-conserving surgery and post-operative irradiation as the primary therapy (Table 4). NP was the only considerable risk factor for secondary local relapse.

Table 4. Risk Factors for Secondary Local Relapse after Repeat Lumpectomy (Univariate Analysis)

Variable	risk/reference	*p*-value
Age	younger/older	0.335
menopause	pre-/post-	0.810
location	elsewhere/near	0.726
type of recurrence	NP/TR	0.003
size	>1 cm/≦1 cm	0.405
LN	positive/negative	0.506
margin	positive/negative	0.861
ly	positive/negative	0.233
v	positive/negative	0.256
grade	3/1, 2	N.E.
EIC	positive/negative	0.073
ER	positive/negative	0.131
PgR	positive/negative	0.772
Endocrine therapy	(−)/(+)	0.058
chemotherapy	(−)/(+)	0.227
CBC	(−)/(+)	0.778
DFI	(−)/(+)	0.156

CBC; contralateral breast cancer
N.E.; not evaluated

Discussion

As breast-conserving therapy becomes common treatment for early stage breast cancer, a growing number of women will develop IBTR. Many studies have showed the clinical significance of IBTR as predictor of subsequent distant metastasis[3, 5, 7]. In evaluating IBTR, however, we must consider that IBTR represent two distinct

entities, TR and NP. The prognosis of TR and NP appears to differ. It has also been shown that the clinicopathological characteristics of these two entities are different[6, 17, 19, 20]. These studies suggest that the treatment may change depending on whether IBTR is TR or NP. Our aim was to ascertain the differences between TR and NP and to show the clinical significance of classifying IBTR into two types of recurrence.

According to our classification criteria mentioned already, 135 patients were classified as TR and 26 were classified as NP. The proportion of NP was low when compared with other reports[6, 8, 18-20], especially the results based on molecular technique[22, 23]. As for the clinical outcome after IBTR, NP showed higher overall, cause-specific and distant disease-free survival rates than TR. Five year actual survival rates after IBTR were 71.0% for TR and 94.7% for NP. There was a significant difference between the two groups ($p = 0.022$). This result is consistent with previous studies. Smith *et al.* showed the overall survival following IBTR was 55% at 10 years in TR patients and 75% in NP patients[17]. Huang *et al.* also reported very similar results, 46% in TR and 77% in NP[20]. However, there exist some conflicting data. Fowble *et al.* did not find a significant difference in prognosis between TR, marginal miss recurrence and elsewhere recurrence at 5-year after IBTR[24]. Krauss *et al.* also did not find a difference between the prognosis of TR and NP[25]. Differences of classifying criteria might explain this controversy.

There was a difference in the risk factor profile for IBTR between TR and NP groups. Young age and omission of postoperative irradiation were the risk factors in common. In addition to these risk factors, occurrence of contralateral breast cancer after first breast cancer was a risk factor for NP. As for TR recurrence, positive surgical margin and positive lymph node status were additional risk factors. These results suggest that therapeutic or host factors are related to NP through a certain likely individual pathways of tumorigenesis, and on the other hand, characteristics of tumor aggressiveness such as positive lymph node status might relate to TR.

Thus, many studies including the current study have found that TR and NP show quite different behavior. This distinction between two types of IBTR may have important implications in clinical management. Patients with NP are thought to have favorable long-term survival. It is therefore reasonable that therapeutic decisions regarding systemic therapy are similar to those used for patients with an equivalent stage of initial breast cancer. On the contrary, patients with TR have a poorer outcome and more intensive chemotherapy might have to be applied.

The problem of this work involved some vagueness about the classification of TR/NP. The decision rules are, in fact, different among the studies. In the current study, the location of the primary and "recurrent" tumor and pathological findings such as surgical margin or certain histological types were mainly taken into account. Location was a significant basis of judgment. Many studies were based on difference in location when judging TR/NP. Recht classified IBTR as true recurrence, marginal miss and elsewhere recurrence according to the relation of the recurrent site and the radiation field[19]. Kurtz *et al.* defined "new tumors" as occurring elsewhere in the breast and reported their favorable behavior. Fowble *et al.* also distinguished IBTR mainly by the location of the primary and secondary cancers though the results of the prognosis differed[24]. In addition to location, Huang *et al.* considered histological subtype to distinguish TR/NP[20]. They designated a tumor as TR if it was located within 3 cm of the primary tumor bed and if the histologic subtype was consistent with the primary tumor (i.e., infiltrating ductal, lobular, medullary, tubular carcinoma). Other pathological findings suggesting independent tumors are the presence of carcinoma *in situ*, better differentiation (infiltrating to non-infiltrating changes, high grade to low grade atypical changes) of the second tumor[21, 23]. Molecular methods were used for classifying IBTRs in some reports. Haffty *et al.* classified tumors according to location and DNA flow cytometry. They related that converting from an aneuploid to a diploid genotype meant NP recurrence[23]. More recently, DNA finger printing detected by allelic imbalances or loss of heterozygosity was adopted in analyzing IBTR. Schlechter *et al.* showed that their new evaluation method could predict the patient's outcome more precisely than conventional methods[22]. The number in their series was very small but in the near future, more studies will likely be able to identify the clonality of IBTR and the primary tumor.

Salvage mastectomy is currently the standard surgical treatment for IBTR[5, 15], but several studies have shown that the results of repeat lumpectomy

were equal to those of mastectomy from the point of overall and distant disease-free survival. In our series, the 5-year overall survival rates after IBTR were 75.7% in the mastectomy group and 84.2% in the lumpectomy group. The rates of subsequent distant metastasis were 25.4% and 25.0%, respectively. There was no significant difference between the two treatment groups with regard to survival and distant metastasis. Whether repeat lumpectomy can be applied safely for patients with IBTR was also examined. Salvadori *et al.* showed excellent results of repeat lumpectomy with 85% OS and 81% local control rate at 5 years. However, generally the rate of secondary local relapse was rather higher than expected. Kurtz *et al.* reported 35% of their cases developed secondary local relapse[6, 13]. The current study showed, though not statistically significant, that the patients undergoing repeat lumpectomy tended to develop secondary local failure compared to the patients undergoing salvage mastectomy. We examined the risk factors of secondary local relapse, limited to the patients who underwent postoperative irradiation after the primary operation. Among 26 patients, the type of recurrence (NP recurrence) was the only risk factor by univariate analysis. Safe selection criteria for repeat lumpectomy are now unknown. Young age at first diagnosis and a family history of breast cancer were reported to be considerable risks of secondary local failure[26]. Young women are thought to be at risk of a second breast cancer. A family history of breast cancer indicates some genetic prediction, and NP also suggests individual differences. The number of repeat lumpectomies was rather small and the follow up was not long enough to draw definitive conclusions. Further studies are needed to determine the indications for repeat lumpectomy.

In conclusion, TR and NP show clinically quite different features. This suggests that classifying IBTR into TR or NP may provide clinically significant data for the management of IBTR both systemically and locally. Establishment of more exact classifying criteria is expected.

Acknowledgement

This work was supported by a Grant-in Aid for research of cancer treatment from the Ministry of Health, Labor and welfare of Japan (No. 13-9).

References

1) Fisher B, Anderson S, Bryant J, Margolese RG, Deutsch M, Fisher ER, *et al*: Twenty-year follow-up of a randomized trial comparing total mastectomy, lumpectpmy, and lumpectomy plus irradiation for the treatment of invasive breast cancer. *N Engl J Med* 347:1233-1241, 2002.
2) Veronesi U, Cascinelli N, Mariani L, Greco M, Saccozzi R, Luini A, *et al*: Twenty-year follow-up of a randomized study comparing breast-conserving surgery with radical mastectomy for early breast cancer. *N Engl J Med* 347:1227-1232, 2002.
3) Fowble B: Ipsilateral breast tumor recurrence following breast-conserving surgery for early-stage invasive cancer. *Acta Oncol* 38 Suppl 13:9-17, 1999.
4) Mamounas E: Ipsilateral breast tumor recurrence after lumpectomy: Is it time to take the bull by the horns? *J Clin Oncol* 19:3798-3800, 2001.
5) Lannin DR, Haffty BG: End results of salvage therapy after failure of breast-conservation surgery. *Oncology* 18:272-279, 2004.
6) Kurtz JM, Spitalier JM, Amalric R, Brandone H, Ayme Y, Jacquemier J, *et al*: The prognostic significance of late local recurrence after breast-conserving therapy. *Int J Radiat Oncol Biol Phys* 18:87-93, 1990.
7) Freedman GM, Fawble B: Local recurrence after mastectomy or breast-conserving surgery and radiation. *Oncology* 14:1561-1581, 2000.
8) Touboul E, Buffat L, Belkacemi Y, Lefranc JP, Uzan S, Lhuillier P, *et al*: Local recurrences and distant metastases after breast-conserving surgery and radiation therapy for early breast cancer. *Int J Radiat Oncol Biol Phys* 46:683-684, 2000.
9) Fisher B, Anderson S, Fisher ER, Redmond C, Wickerham DL, Wolmark N, *et al*: Significance of ipsilateral breast tumor recurrence after lumpectomy. *Lancet* 338:327-331, 1995.
10) Veronesi U, Marubini E, Del Vecchio M, Manzari A, Andreola S, Greco M, Luini A, *et al*: Local recurrences and distant metastases after conservative breast cancer treatments: partly independent events. *J Natl Cancer Inst* 87:19-27, 1995.
11) Schmoor C, Sauerbrei W, Bastert G, Schmoor M: Role of isolated locoregional recirrence of breast cancer: Results of four prostictive studies. *J Clin Oncol* 18:1696-1708, 2000.
12) Bethke KP: Breast Conservation: predictors and treatment of local recurrence. *Semin Surg Oncol* 12:332-338, 1996.
13) Kurtz JM, Jacquemier J, Amalric R, Brandone H, Ayme Y, Hans D, *et al*: Is breast conservation after local recurrence feasible? *Eur J Cancer* 27:240-244, 1991.
14) Salvadori B, Marubini E, Miceri R, Cont AR, Cusumano F, Andreola S, *et al*: Reoperation for locally recurrent breast cancer in patients previously treated with conservsative surgery. *Br J Surg* 86:84-87, 1999.
15) Clemons M, Hamilton T, Mansi J, Lockwood G, Goss P: Management of recurrent locoregional breast cancer: oncologist survey. *Breast* 12:328-337, 2003.
16) Della Rovere GQ, Benson RJ: Ipsilateral breast tumor recurrence of breast cancer: determinant or indicator of poor prognosis. *Lancet Oncol* 3:183-187, 2002.

17) Smith TE, Lee D, Turner BC, Carter D, Haffty BG: True recurrence vs. new primary ipsilateral breast tumor relapse: an analysis of clinical and pathologic differences and their implications in natural history, prognoses, and therapeutic management. *Int J Radiat Oncol Biol Phys* 48:1281-1289, 2000.
18) Santiago RJ, Wu L, Harris E, Fox K, Schultz D, Glick J, *et al*: Fifteen-year results of breast-conserving surgery and definitive irradiation for Stage I and II breast carcinoma: the University of Pennsylvania experience. *Int J Radiat Oncol Biol Phys* 58:233-240, 2004.
19) Recht A, Silen W, Schnitt SJ, Connolly JL, Gelman RS, Rose MA, *et al*: Time-course of local recurrence following conservative surgery and radiotherapy for early stage breast cancer. *Int J Radiat Oncol Biol Phys* 15:255-261, 1988.
20) Huang E, Buchholz TA, Meric F, Krishnamurthy S, Mirza NQ, Ames FC, *et al*: Classifying local disease recurrences after breast conservation therapy based on location and histology: new primary tumors have more favorable outcomes than true local disease recurrences. *Cancer* 95:2059-2067, 2002.
21) Chaudary MA, Millis RR, Hoskins EO, Haldor M, Bulbrook RD, Cuzick J: Bilateral primary breast cancer: A prospective study of disease incidence. *Br J Surg* 71:711-714, 1984.
22) Schlechter BI, Yang Q, Larson PS, Golubeva A, Blanchard RA, de La Morenas A, *et al*: Quantitative DNA fingerprinting may distinguish new primary breast cancer from disease recurrence. *J Clin Oncol* 22:1830-1838, 2004.
23) Haffty BG, Carter D, Flynn SD, Fischer DB, Brash DE, Simons J, *et al*: Local recurrence versus new primary: Clinical analysis of 82 breast relapses and potential applications for genetic fingerprinting. *Int J Radiot Oncol Biol Phys* 27:575-583, 1993.
24) Fowble B, Solin L, Schultz D, Rubenstein J, Goodman RL: Breast recurrence following conservative surgery and radiation. Patterns of failure, prognosis, and pathologic findings from mastectomy specimens with implications for treatment. *Int J Radiat Oncol Biol Phys* 19:833-842, 1990.
25) Krauss DJ, Kestin LL, Mitchell C, Martinez AA, Vicini FA: Changes in temporal patterns of local failure after breast-conserving therapy and their prognostic implications. *Int J Radiat Oncol Biol Phys* 60:731-740, 2004.
26) Komoike Y, Motomura K, Inaji H, Kasugai T, Koyama H: Repeat lumpectomy for patients with ipsilateral breast tumor recurrence after breast-conserving surgery. Preliminary results. *Oncology* 64:1-6, 2003.

Breast Cancer
Vol. 12 No. 1 January 2005

Review Article

General Aspects and Specific Issues of Informed Consent on Breast Cancer Treatments

Miyuki Takasugi*[1], Eriko Iwamoto*[1], Sadako Akashi-Tanaka*[1], Takayuki Kinoshita*[1], Takashi Fukutomi*[1], and Kohichi Kubouchi*[2]

*Departments of *[1]Surgical Oncology Divisions, National Cancer Center Hospital, *[2]Yokohama Breast and Stomach Hospital, Japan.*

Informed consent (IC) is the process by which a patient can make choices about his/her health care; therefore it is considered to be a voluntary authorization given by the patient to the physician. To ensure the patient's right to self-determination, what can the physicians do?

When treating breast cancer, there are several specific issues that must be clarified by the IC. We have selected and evaluated the basic elements of IC and mentioned the basic concepts of IC in details.

First of all, complete information must be disclosed to the patient (physician's responsibility for medical accountability). The information to be disclosed is summarized in the following three elements: 1) The nature of the treatment/procedure, 2) The relevant risks/benefits, and 3) Reasonable alternatives to the proposed intervention (alternative treatments/procedures). However, the physician is not obliged to persuade the patient to accept the proposed intervention. IC information should be documented in detail on the patient's chart without delay. These issues include IC regarding surgical procedures (mastectomy or breast conservation treatment), IC regarding clinical studies (description of randomized controlled trials), IC regarding genetic diagnosis (ethical issues), and the like.

IC means informed decision-making, close relationships between physicians and patients are needed.

Breast Cancer 12:39-44, 2005.

Key words: Breast cancer, Informed consent

Informed consent (IC) is the process by which the patient can make choices about his/her health care and is regarded as a voluntary authorization given by the patient to the physician. In other words, IC is permission given by the patient to the physician to initiate a certain treatment or testing[1,2], especially in such cases involving invasive procedures. More specifically, the most important goal of IC is to ensure the patient has the right of self-determination, making free decisions regarding himself/herself; in that the physician is to take full responsibility for disclosing complete information (physician's responsibility for medical accountability) about the proposed intervention. Therefore, Informed consent (IC) should be interpreted as "The responsibility for medical accountability and consent". Basically, the patient has a legal right to receive complete and accurate information about himself/herself, and under any circumstance, the patient has the right to make decisions and to design his/her own life. In this sense, the physician should inform the patient prior to contact with his/her family members.

However, terms such as informed consent and the patient's right to self-determination did not originate from healthy patient-physician relationships, but instead, these terms emerged from the legal process of determining compensation in medical malpractice lawsuits. For example, the term "informed consent" was first used in 1957 in an Appeals Court decision in California (Salgo suit). Since then, this term has been widely used in North America, and was then imported to Japan. Therefore, "informed consent" is strictly a legal term.

To evaluate the basic concepts of IC, we selected and discussed the following aspects of IC, when

Reprint requests to Takashi Fukutomi, Surgical Oncology Divisions, National Cancer Center Hospital, 5-1-1, Chuo-ku, Tokyo, 104-0045, Japan.

Received February 13, 2004; accepted August 3, 2004

we manage breast cancer patients;

1) What is the physician's responsibility for "medical accountability

2) What are the elements of IC?

3) Basic checklist and concepts for IC.

4) Specific issues regarding surgery, clinical trials, genetic tests and sentinel lymph node biopsy.

What is the Physician's Responsibility for "Medical Accountability"?

In general, medical accountability involves the following two elements[1]:

1. Accountability as a precondition to obtaining consent from a patient on the proposed intervention (in cases when highly invasive treatments/testing such as surgery or anti-cancer drug treatment are planned).

2. Accountability as a protection of the physician's legal rights in regard to the outcomes of the existing condition (to recommend transfer to another hospital to receive a thorough examination or new treatment), and accountability in regard to complications/risks after discharge.

What are the Elements of IC?

Informed consent is to include the following three elements[1,2,3]:

1) The Nature of the Treatment/Procedure

In general, treatments/procedures disclosed by IC are considered to be invasive interventions to a certain extent. For example, No IC is required for routine biochemical lab tests except for some unique tests such as the HIV test. On the contrary, IC is prerequisite for surgical cases, imaging contrast tests, administration of toxic agents, etc.

2) The Relevant Risks and Benefits

The patient is to receive complete information about the relevant risks and benefits (complications, toxicity, etc.) of the proposed intervention. In many cases, information about the risks associated with a proposed intervention is not sufficiently disclosed to the patient; this may become the cause of legal action. In reference to judicial precedents, the physician is obliged to actively disclose information regarding relevant risks to the patient.

3) The Reasonable Alternatives to the Proposed Intervention

The physician is obliged to inform the patient about the nature of alternative treatments (other treatment(s) if the patient decides not to accept the proposed intervention) which are considered to be reasonable and comparable to the proposed intervention. Citing precedents, any consent for surgery obtained without informing the patient about alternative treatment(s) have been ruled legally ineffectual. For example, consent for mastectomy obtained without informing the patient about breast conservation treatment is legally invalid.

Basic Checklists and Concept for IC

1) Basic Checklist for IC[1,2,3]

1. Right to refuse medical treatment (World Medical Association Declaration of Lisbon on the Patient's Rights, 1981)

It is accepted as a foregone conclusion that the patient has the right to refuse medical treatment. The patient's right to self-determination is particularly ensured by this declaration.

2. Negation of duty to persuasion (Tokyo district court decision, 1988)

The physician does not have to insist that the patient receives what is believed to be the best treatment if this is against the will of the patient. The physician does not have to persuade the patient to choose the proposed intervention.

3. Physicians working at university hospitals and large-scale general hospitals (general hospitals, hospital centers) are burdened with greater responsibilities for precautions and accountability in comparison with physicians at medium- to small-scale hospitals and practitioners. (Sendai District Court, 1977, Yokohama District Court, 1979).

4. IC information should be documented in detail on the patient's chart without delay. At the time of consultation with the patient, in addition to oral presentation, the accountable physician should take special care to keep good records on the consultation card and information sheet. Both the physician and patient are to sign for the record.

2) The Authors' Basic Concept for IC

Most breast cancer is found as an indolent tumor of about 3 cm in diameter in active and otherwise healthy women between the ages of 40 and 50. Surgical treatments such as mastectomy must be chosen for medical reasons; however, these treatments are tremendous psychological and cosmetic burdens for such patients. Therefore, to treat patients with breast cancer, it is extremely important to directly disclose the diagnosis to the patient, and to demonstrate evidence that explains

why a particular treatment is recommended. In cases where the patient is indicated for breast conservation therapy, it is necessary to address the possibility of local recurrence and post-operative radiation therapy. In order to achieve successful treatment, it is critical that the patient has a good understanding of the disease[4]. In such cases, we conduct the consultation with the patient in compliance with the "Study on the preparation of guidelines for breast cancer treatment based on scientific evidence" issued on April 2003 (the Ministry of Health, Labour, and Welfare) to the maximum possible extent[5].

In particular, the "Guidelines for breast cancer treatment, the Ministry of Health, Labour, and Welfare" clearly state that there is no difference in survival rates between local breast conservation treatment and mastectomy in patients who have stage I to II invasive breast cancer (Grade A). This information should be clearly explained to the patient. Furthermore, these guidelines also state that tumor shrinking can be achieved using preoperative chemotherapy for patients at early stages of operable cancer; this treatment increases the success rate of breast conservation treatment (Grade B). Therefore, except in cases where the patient is diagnosed with broad calcification or local progressive breast cancer, all operable patients should be informed of the option of breast conservation treatment. The guidelines issued by public institutions are prepared based on current medical technology as of the time of issue; therefore, in a legal setting, these guidelines tend to be referenced as the average medical options at that time period. The lack of information given to patients regarding alternative treatments which are regarded as standard medical options available at the time, and biased information affecting the patient's decision making are considered ascribable for many legal disputes. In most legal cases, the verdicts have gone against medical care providers, and the defendants have been charged with small amounts of compensation (based on real content, the verdicts have gone in favor of the defendants). The law demands that the physician may not influence the patient's judgment by manipulating the information process.

However, chemotherapy for cancer recurrence involves high toxicity and causes symptoms such as vomiting, epilation, and myelopathy, and becomes a cause of sociophysical burden to the patient. Therefore, unless the patient has a good understanding and acceptance of the stage of disease, it is difficult to continue such treatment. In particular, as the aforementioned guidelines recommend the use of anthracycline as a post-operative treatment (Grade A), the toxicity of the proposed intervention should be sufficiently described. Moreover, instances of serious toxicity have been reported; these were caused by the combined use of the prescribed chemotherapeutic agents with other drugs. Therefore, it is critical that the patient receives accurate information regarding the indications and toxicity of the anticancer drugs.

In any case, breast cancer has a better prognosis and even relapsed and metastatic cancers can be well controlled with the current medical technology. Accordingly, the physician can openly discuss the facts of the disease with the patient in a straightforward manner. In particular, in the current information age, the level of patient knowledge about the disease and awareness of patient's rights have become extremely high. Consequently, the questions and requests from the patient for self-determination are becoming more accurate and technical.

In any event, the consultation should be planned at least 3 or 4 days to one week before the proposed surgery date to allow the patient to have enough time to get a second opinion and to investigate alternative treatments. The physician should respect the patient's right to self-determination and make every endeavor to obtain IC based on the patient's own decision, not a decision entrusted to the physician. The use of the information sheet and clinical path helps the patient understand the context of the discussion. In our hospital, we provide the information sheet and the clinical path for patients prior to hospitalization.

When dealing with breast cancer, there are a wide range of opinions from each patient and physician regarding the concept of disease, assessment of the treatment options, and opinions about quality of life (QOL). The patient's understanding of the reasons for the proposed intervention is a key factor in successful treatment, and allows the patient to have a positive acceptance of and active involvement in the treatment. Therefore, the physician should present actual data as much as possible and try to describe the data in a manner that the patient can comprehend, so that the patient can make decisions based on her own beliefs and preferences. In the following section, the impor-

tant points for each item are described.

Specific Issues

1) How should the Surgical Procedures for Breast Cancer be Described to the Patient?

During consultation with breast cancer patients, we use the following two guidelines: "Guidelines for breast conservation treatment" issued by the Japanese Breast Cancer Society (1995)[6], and "Guidelines for breast cancer treatment" issued by the Ministry of Health, Labour, and Welfare (2003). Breast conservation treatment is indicated for patients with tumors smaller than 3 cm in diameter, which are not diagnosed as multiple tumor types, and without extensive calcification shown in mammography. For patients with tumors larger than 3 cm in diameter, we recommend preoperative chemotherapy. Mastectomy sounds like a difficult procedure for the patient to accept; however, considering the fact that breast cancer tends to show intraductal spread and multicentricity, and cosmetic results, we always emphasize that mastectomy is the most reliable treatment. Even so, the patient should be informed of the following facts: (1) realistically, stage I and II breast cancers can be adequately treated with breast conservation treatment, which involves the local dissection of the lesion to spare the breast, (2) in breast conservation treatment, a 5 to 10% rate of local recurrence is expected, (3) to reduce the incidence of recurrence, postoperative radiation is mandatory, and (4) even in cases where the cancer recurred, most of the tumors were resectable. We use illustrations to describe these points and repeat the important elements for better understanding. Most importantly, we give our best effort to clearly address the fact that local recurrence and the occurrence of a contralateral primary cancer are two different events and have totally different probabilities. Finally, we emphasize that the final decision should be made by the patient.

2) How should Participation in Clinical Studies be Described to the Patient?

The basic rule in obtaining IC for participation in a clinical study is to place the highest priority on the patient's decision. Furthermore, in clinical studies of novel drugs, it is the physician's responsibility to clearly state that the drug proposed for treatment is in the experimental stage and to disclose the relevant (or irrelevant) effects and toxicity. The ministerial ordinance states the following: Informed consent requires the subject to receive all relevant information regarding the proposed clinical trial for voluntary participation, to fully understand the consequences, to agree to participate by self-determination, and to give written consent to confirm that the required processes have been undertaken. The ministerial ordinance also recommends the use of the information sheet and consent form[7].

It is important that the patient is fully informed about the characteristics of each type of clinical trial: phase I trials aim to assess toxicity, phase II trials aim to assess efficacy, and phase III trials are comparison studies with conventional standard therapeutic methods. In general, patients tend to overestimate efficacy and toxicity; therefore, physicians should make an effort to be objective and unbiased during the consultation. In cases of randomized controlled trials, patients are to be fully informed that the trial will allocate patients randomly for treatment in a manner similar to drawing a lottery and that the physicians and patients are not involved in the allocation. However, we also ensure that the patients understand that the randomization of treatment is clearly different from the lottery, as intervention will be at least one of the standard treatments at the time; therefore, there is no "winning" or "losing", and the final assessment will not be known until 5 to 10 years after the actual participation in the trial. In fact, it is very difficult to give a proper presentation of a clinical trial, and particularly a randomized controlled trial, in a manner that results in complete understanding by the patient. However, the patient needs to understand that modern medicine cannot rely upon the physician's empiricism for better treatments, and instead, stringent comparison of treatments in randomized controlled trials is the condition necessary to maximize effective medical advances.

As described above, the disclosure documents for each protocol are provided to the patient in an on-site consultation at our hospital. The patient receives the complete information and signs the consent form if she decides to participate in the trial. The disclosure of information is as follows:

1. Background
2. What is the anti-cancer drug? Is it effective?
3. What is the clinical trial? What is a randomized controlled trial?

The essence of the disclosure is summarized as follows:

"If you agree to participate in this randomized

controlled trial, you are asked to receive one of several treatments. However, we, the physicians, cannot decide which treatment you are to be assigned. As this is a clinical study that aims at the development of further effective treatments, every decision in regard to the trial is to be ensured complete fairness; therefore the executive office, independent from the personal points of view, discretion, and requests of the concerned parties (physicians and patients), is responsible for allocation. You may feel that it is unfair that the patients who will receive the treatment are not able to choose the treatment method; however, many current standard methods have been accessed and evaluated through similar randomized controlled trials."

4. Specific description of the treatment.

5. The patient has a right to self-determination of participation in the clinical trial; therefore the patient has the right to refuse participation.

6. The privacy of the participant is protected.

7. The participant can withdraw his or her consent at any time.

8. This clinical study has been reviewed and approved by an institutional review board in order to ensure that it is medically valid and that the rights and safety of the patients are protected.

It may sound unreasonable to emphasize the utility of a standardized clinical trial while the tailor-made approach to cancer treatment has become a focus of attention; however, no advancement in cancer treatment can be achieved without randomized controlled trials.

3) How should Genetic Diagnosis of Genetic and Familial Breast Cancer be Described to the Patient?

Should a physician recommend the genetic diagnosis of breast cancer, with particular emphasis on the BRCA1/BRCA2 genes, to breast cancer patients with higher incidence of familial breast cancer? The aforementioned guidelines issued by the Ministry of Health, Labour, and Welfare stipulate the following: Recommendations that women with higher incidence of familial breast cancer undergo genetic diagnosis increase the probability of finding the women at high risk for the development of breast cancer; however, as treatments and preventive methods have not been established at present, there is no reason to recommend genetic diagnosis (Grade C). However, it is clear that mutations in the BRCA1/BRCA2 genes increase the occurrence of breast cancer; therefore, the cumulative risk (penetrance) of breast cancer is significantly higher in women who carry BRCA1 or BRCA2 mutations (carrier). Nevertheless, this finding has not been confirmed in the Japanese population (Grade B). This ordinance is interpreted as indicating that the penetrance of mutations in these genes has not yet been determined, and that countermeasures (preventative mastectomy, preventative ovariotomy, genetic counseling) in the case of positive genetic diagnosis have not been established in Japan; therefore, genetic diagnosis cannot be recommended at the present time. Although such diagnosis and preventative countermeasures have been practiced in many cases in western countries, we should not yet adopt these procedures "as-is".

Therefore, genetic diagnosis should be utilized based upon the current medical situation in Japan. In our hospital, we are sure to inform the patient that the genetic diagnosis of breast cancer is still in an experimental stage (that is, the clinical utility has not been fully established), the privacy of the patient is completely protected, and even if testing yields a positive result, specific intervention has not yet been established.

4) How should Sentinel Lymph Node Biopsy be Described to the Patient?

When we discuss this particular intervention with the patient, we follow the guidelines issued by the Ministry of Health, Labour, and Welfare; that is, when it is asked whether it is appropriate to replace the radical dissection of axillary lymph nodes with sentinel lymph node biopsy in breast cancer patients who do not have lymph node metastasis clinically (NO), the guidelines indicate that there is insufficient data to prove sentinel lymph node biopsy as a standard method, suggesting no reason to use it as an alternative to the radical dissection of axillary lymph nodes. (Grade C) Therefore, regardless of the method, sentinel lymph node biopsy is not currently considered to be a standard alternative method to radical dissection of axillary lymph nodes. Preferably, further experiments will be added to the works by Veronesi *et al.*[8]. When we perform this procedure, the patient is fully informed that sentinel lymph node biopsy is an experimental procedure and is not an alternative procedure for the radical dissection of axillary lymph nodes. In addition, we suggest using the protocol approved by the institutional Review Board to provide both the disclosure document and consent form. In the case of back-up radical dis-

section, it can be incorporated into the standard preoperative IC.

In this paper, general aspects and specific issues of IC on breast cancer treatments have been discussed with emphasis on several specific issues. To fully comply with the demands for IC, physicians are expected to have an accurate understanding of the current medical standards and excellent skills to communicate with the patients.

References

1) Hanayana T: Medical Accidents and Juridical Criteria (First edition), Hanrei Times Co., Ltd. Tokyo, pp91-166, 2003 (in Japanese).
2) Kanakawa T: Practical Medical Jurisprudence (First Edition), Kanehara & Co., Ltd., Tokyo, pp105-116, 2002 (in Japanese).
3) Kuroyanagi T: Malpractice and Judicial Precedents (First Edition), Hanrei Times, Tokyo, pp1-176, 2003 (in Japanese).
4) Fukutomi T., Informed Consent: Manual of the Latest Breast Cancer Diagnosis and Treatment (Second edition), Medical View, Tokyo, pp122-128, 2001.
5) Takashima S: Study on the preparation of guidelines for breast cancer treatment based on scientific evidence, Ministry of Health, Labour, and Welfare, Tokyo, pp1-260, 2003.
6) Japanese Breast Cancer Society, Academic Committee: Guidelines for breast conservation treatment, Japanese Breast Cancer Society, Tokyo, pp4-22, 1999.
7) NSAS GCP (GPMSP) Data, Report, Central Pharmaceutical Affairs Council, Ministry of Health, Labour, and Welfare: Pharmaceutical Affairs Bureau, Ministry of Health and Welfare, Tokyo, p.5, 1998.
8) Veronesi U, Paganelli G, Viale G, Luini A, Zurrida S, Galimberti V, *et al*: A randomized comparison of sentinel-node biopsy with routine axillary dissection in breast cancer. *N Engl J Med* 349:546-553, 2003.

ORIGINAL ARTICLE

Diagnosis of Complete Response to Neoadjuvant Chemotherapy Using Diagnostic Imaging in Primary Breast Cancer Patients

Takashi Kanazawa, MD,* Sadako Akashi-Tanaka, MD,* Eriko Iwamoto, MD,* Miyuki Takasugi, MD,* Tadahiko Shien, MD,* Takayuki Kinoshita, MD,* Kunihisa Miyakawa, MD,† Chikako Shimizu, MD,‡ Masashi Ando, MD,‡ Noriyuki Katsumata, MD,‡ Yasuhiro Fujiwara, MD,‡ and Takashi Fukutomi, MD*

**Division of Surgical Oncology, †Department of Diagnostic Radiology, and ‡Division of Breast and Medical Oncology, National Cancer Center Hospital, Tokyo, Japan*

■ **Abstract:** Advances in the therapeutic agents used for neoadjuvant chemotherapy (NAC) have recently achieved higher response rates and induced a greater number of pathologic complete responses (pCR) than ever before. The aim of this study is the diagnosis of pCR after NAC by diagnostic imaging of clinical complete response (cCR) patients. This study included 35 breast cancer patients who demonstrated cCR after receiving NAC with a combination of anthracycline and taxane from May 1998 to August 2003. Surgical treatment included breast-conserving therapy followed by radiotherapy or mastectomy. The identity of post-NAC lesions as either a complete response (CR) or partial response (PR) were made by mammography, ultrasonography, and contrast-enhanced computed tomography (CT). Among the 35 patients, 11 achieved pCR, including the disappearance of both invasive and intraductal components. Of the patients achieving pCR, eight were defined as CR and three were determined to be PR by CT. There was a significant relationship between the pCR and the determination of CR by CT. The determination of CR by ultrasonography was indicative of the disappearance of pathologic invasive components. While mammography appeared to reflect the observed histologic results, we did not observe any statistical differences. A subset of cases exhibited discrepancies between the imaging and pathologic results, likely due to the replacement of destroyed tumor cells by fibrosis and granulomatous tissue. The evaluation of CR by CT was significantly indicative of pCR. The positive predictive value, however, was not large enough to avoid surgical treatment. Further studies will be needed to establish a diagnosis of pCR. ■

Key Words: breast cancer, complete response, computed tomography, diagnostic images, neoadjuvant chemotherapy

With advances in the therapeutic agents and combinations used for neoadjuvant chemotherapy (NAC), we have recently achieved higher response rates and greater numbers of pathologic complete responses (pCR). Until now, the highest rate of pCR reported was 66% (1). The accurate evaluation of the existence of residual disease after NAC would facilitate more effective strategies for local treatment after NAC.

We previously reported the efficacy of contrast-enhanced computed tomography (CT) as a method to determine the extent of residual breast cancer following NAC (2). Multiple reports have also demonstrated the accuracy of magnetic resonance imaging (MRI) in the detection of residual breast cancer after NAC (3,4). However, these studies utilized only a small number of pCR cases and did not describe the specific findings of the pCR images. To our knowledge, only a few reports detailing the diagnostic findings for patients with clinical complete responses (cCR) have been published (5,6); these suggest the accuracy of breast CT or MRI for precise evaluation of pCR. This study sought to diagnose pCR precisely after NAC by diagnostic imaging of cCR patients.

MATERIALS AND METHODS

Patients

A total of 202 women with pathologically confirmed breast carcinomas measuring more than 3 cm in diameter were eligible for NAC at the National Cancer Center Hospital (NCCH), Tokyo, Japan, from May 1998 to August 2003. This study examined 35 patients who obtained cCR

Address correspondence and reprint requests to: Sadako Akashi-Tanaka, MD, Breast Surgery Division, National Cancer Center Hospital, 5-1-1 Tsukiji, Chuo-ku, Tokyo 104-0045, Japan, or e-mail: sakashi@gan2.ncc.go.jp.

© 2005 Blackwell Publishing, Inc., 1075-122X/05
The Breast Journal, Volume 11 Number 5, 2005 311–316

Table 1. Chemotherapy Regimen

Regimen	Treatment period	Number of patients
ADM (50 mg/m^2), DTX (60 mg/m^2) × 4	98.5–2001.8	26
ADM (60 mg/m^2), CPA (600 mg/m^2) × 4 PTX (80 mg/m^2) × 12 weeks[a]	2002.3–2005	4
5FU (500 mg/m^2), EPI (100 mg/m^2), CPA (500 mg/m^2) × 4, PTX (80 mg/m^2) × 12 weeks[a]	2002.10–2003.8	5

ADM, adriamycin; CPA, cyclophosphamide; DTX, docetaxel; EPI, epirubicin; 5FU, 5-fluorouracil; PTX, paclitaxel.
[a]Trastuzumab was added when the tumor showed overexpression of HER-2.

after NAC followed by local treatment. Inflammatory breast carcinomas were excluded from this study. All patients gave informed consent for study participation as approved by the institutional review board of NCCH. Of the 167 non-cCR patients, pCR was achieved in 7 cases. These cases were not examined in this study. Responses were assessed before and after NAC by clinical measurement by palpation of the primary tumor. The response was determined according to the criteria of the International Union Against Cancer (7). cCR was defined as total resolution of the breast mass by physical examination without considering the result of diagnostic imaging.

Treatment

The presence of a breast carcinoma was confirmed pathologically by core needle biopsy (CNB). The NAC regimen employed a combination of anthracycline and taxane (Table 1). Patients underwent surgical treatment, including modified radical mastectomy or breast-conserving therapy (BCT) approximately 4 weeks after the last NAC cycle. BCT was followed by radiotherapy to achieve a total dose of 50 Gy. When margin was involved by cancer cells, we added a radiation boost to the tumor bed.

Imaging Examinations

Mammography, ultrasonography, and CT were examined before and after NAC, as reported previously (8). CT scans were performed using a helical CT scanner (X-vigor, Toshiba Medical Systems, Tokyo, Japan) before 2002 and a multislice helical CT scanner (Aquilion 4, Toshiba Medical Systems) at a current of 200 mA after 2002. Patients underwent a single spiral acquisition during inspiratory apnea for 30 seconds in the supine position. An enhanced CT scan was performed for the whole breast using a slice thickness of 1 mm with 100 ml of nonionic contrast material injected into the patient at a rate of 3 ml/second. After 40 seconds of bolus (2) administration of contrast material, we began early phase scanning. The late-phase scan was performed 3 minutes after administration. Using a Mammomat 3000 (Siemens, Malvern, PA), craniocaudal and mediolateral mammography views were obtained without magnification. Breast ultrasound images were obtained using a SSA340A (Toshiba Medical Systems). We measured the diameter of tumor in the transverse plane with all modalities.

The responses to NAC in the obtained images were classified as complete response (CR) and partial response (PR) (Fig. 1). By mammography, we defined CR as the absence of a mass and spiculation, while PR was when an obvious mass was observed. In the absence of tumor shadows, microcalcifications were classified as PR (Iwamoto E, et al., personal communication). Three cases could not

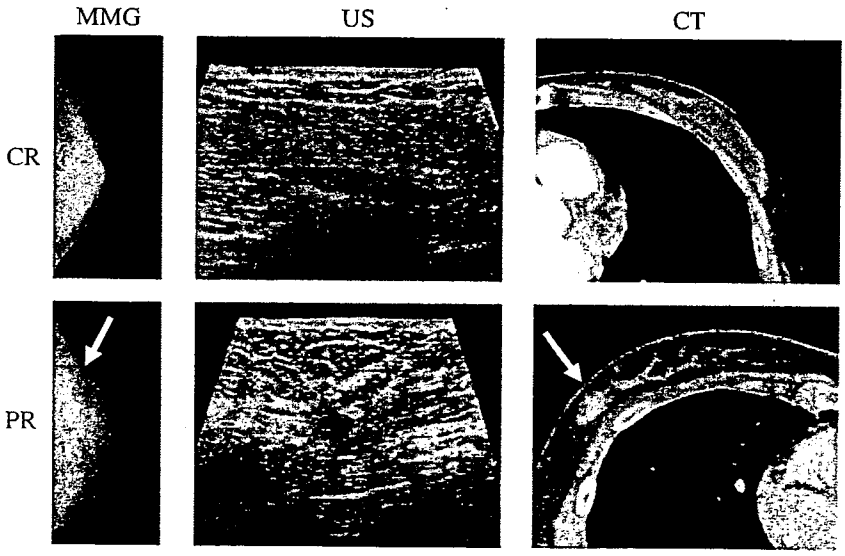

Figure 1. Typical CR and PR determined by each imaging modality.

be evaluated because of the density of the breast. By ultrasonography, a diagnosis of CR was made when the ultrasound findings were normal and PR when images exhibited low echoic lesions with lower echoes than fat tissue or obvious masses. By CT, we defined CR as the complete absence of marks or small and faint enhanced lesions, which were diagnosed as mastopathy when the original tumor location was unknown. CT findings were classified as PR when the images exhibited a highly enhanced mass, regardless of size, or a well-recognized mass, regardless of the enhancement. We classified the tumors into localized and diffuse types by diagnostic imaging, as reported previously (8).

Images were evaluated independently by at least two doctors. Cases without coincident interpretation were mutually agreed upon following discussion.

Histopathologic Examinations

After sectioning in 7–10 mm slices along the transverse axis, all specimens were analyzed by breast pathologists. The response to NAC was classified as either pCR or pathologic partial response (pPR). When neither invasive nor intraductal cancer cells could be observed pathologically, samples were classified as pCR. When residual invasive or noninvasive components were observed, specimens were classified as pPR.

Statistical Analysis

The chi-square test was used for the comparison of CR and PR classifications. Differences of $p < 0.05$ were considered to be significant. Fisher's exact test was used for the comparison when zero was included.

RESULTS

The characteristics of the 35 CR patients are detailed in Table 2. The mean age of the patients obtaining cCR was 48.3 years (range 26–67 years). BCT was performed in 25 cases (71%). Eleven cases (31%) achieved pCR. Twenty-four cases (69%) demonstrated pPR. The determination of histologic type after surgical treatment (pCR cases were diagnosed before NAC by CNB) revealed that 28 cases were diagnosed as invasive ductal carcinoma and 7 were determined to be intraductal carcinoma. Of the seven intraductal carcinomas, six were diagnosed as invasive ductal carcinoma in CNB before NAC. The invasive components were likely diminished by NAC administration.

Tumor sizes were measured before and after NAC on each image (Table 3). The mean tumor size before treatment ranged from 3 cm to 4 cm, diminishing in size to 1–2 cm following NAC. We did not observe a significant difference between the pathologic responses and the sizes obtained at each examination. The mean pathologic sizes were 2.2 cm in pPR patients and 0 cm in pCR patients.

The responses to NAC were evaluated by each imaging method (Table 4). By CT, eight cases were defined as CR and three were determined to be PR in the pCR group. We observed a significant correlation between pCR and the determination of CR by CT ($p < 0.05$). The positive predictive value of CT diagnosis of pCR was 53%. Responses evaluated by ultrasonography, however, did not reflect the pathologic results. In the pPR group, the invasive tumor components disappeared in two of three patients with CR determined by ultrasonography. In these patients, residual intraductal carcinomas were revealed pathologically. The diagnosis of CR by ultrasonography predicted the absence of residual invasive components ($p = 0.1$). Both

Table 2. Patient's Characteristics

Age (years)	48.3 (26–67)
Menopausal status	
Premenopausal	17 (49%)
Postmenopausal	18 (51%)
Tumor size (before NAC)	4.7 cm (3.2–6.5 cm)
TNM category	
T2	29 (83%)
T3	4 (12%)
T4	2 (6%)
Stage before NAC	
IIA	18 (51%)
IIB	13 (37%)
IIIA	2 (6%)
IIIB	2 (6%)
Local treatment	
Mastectomy	10 (29%)
BCT	25 (71%)
Pathologic response to NAC	
Pathologic PR	24 (69%)
Pathologic CR	11 (31%)

Table 3. Mean Tumor Size (cm) before and after NAC and Pathologic Response

	Pathologic PR	Pathologic CR
Mammogram		
Before NAC	3.7	3.6
After NAC	1.5	1.5
Ultrasound		
Before NAC	3.8	3.5
After NAC	1.0	1.2
CT		
Before NAC	4.5	4.2
After NAC	1.4	1.6
Pathology	2.2	0

After NAC, all 35 cases were confirmed total resolution of the breast mass by physical examination and defined as cCR.