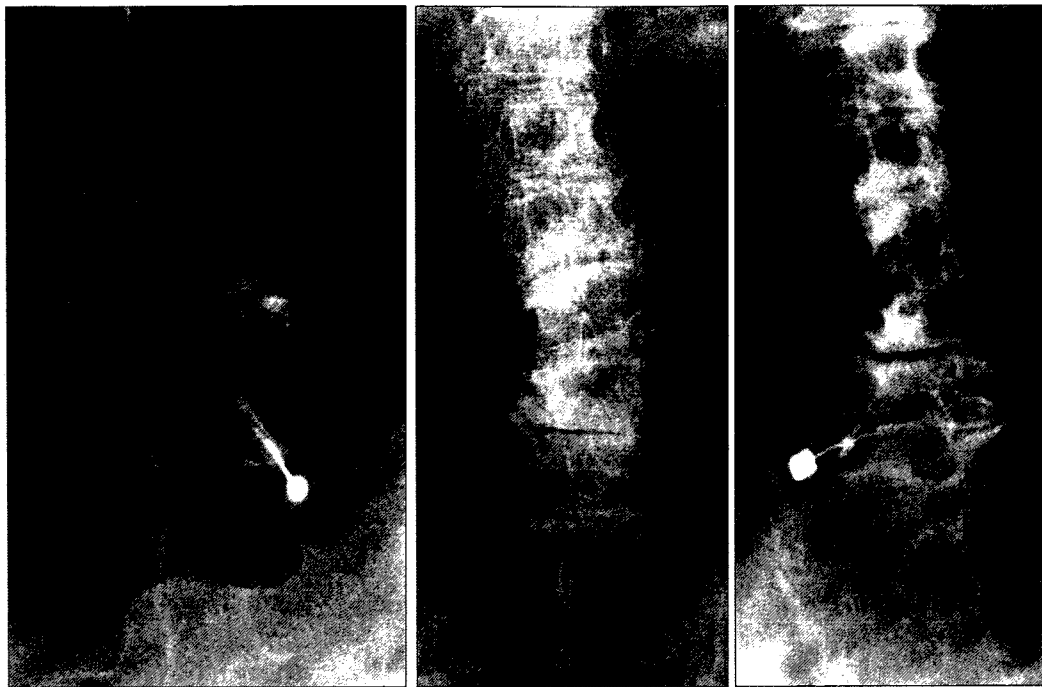

a. S1 神経根ブロックはガントリーを傾けて前後の仙骨孔が1つの孔に見えるようにすると容易に施行できる（左側の仙骨孔のみえ方に注目）。

b. 下肢痛をきたして来院した高度の変性側弯症例。このような症例では最初から斜位での刺入を試みるとよい。この症例では神経根ブロックで疼痛が消失し手術を回避できた。

図6. 神経根ブロックの実際

によって、神経根走行のイメージが大きく変化することに注意する（図5, 6）。刺入点が決まれば皮膚を消毒し覆布をかける。局麻薬は刺入点の皮下に十分効かせるのみでよい。まずはカテラン針の先を横突起まですすめて数回横突起にあて、深さを確認するとともにカテラン針の先を若干なまらせておく。神経根は横突起よりも浅い位置には存在しないので、患者が痛みを訴えてもそれは真の放散痛ではない。いったん横突起まですすめてから少し針を引き抜き、今度は神経根に向かって直線的にゆっくりと針をすすめていく。神経根は横突起に接するように走行するのではなく、椎間孔の出口においては横突起より1.5 mmほど尾側を走行する²⁾。神経根は椎間孔を出たのち椎体に沿って腹側、尾側へと走行していくので、外側に向かえばそれだけ腹側、尾側で神経根に到達することを念頭におかなければいけない。針先が神経根に触れば患者は強い疼痛を訴える。当該神経根に応じた放散痛が得られたところで、必要であれば造影剤（イオトロラン 1 ml 以下）にて神経根を造影したあとに薬液の注入を行う。薬液注入開始時は強い放散痛があるが、局麻薬の効果によりただちに下肢への放散痛は消失する。施行後は下肢伸展挙上テスト、筋力検査などを行い、確実に効果が得られたかどうかを確認する。

患者には神経根ブロック施行前に一時的な筋力低下がみられること、局麻薬の効果が消失して歩行が安定するまで30分～1時間程度坐って休む必要があることを十分に説明しておく。次回外来時に効果の程度、持続期間などを必ず聴取し、その後の治療方針の決定に役立てる。同一神経根への注入は神経根の線維化の危険性を考えて3回程度にとどめておくほうがよく、それ以上のブロックが必要である場合には、手術的治療など次のフェーズの治療法を考えるべきである。

ま と め

高齢化に伴って、今後ますます神経根性疼痛を訴える患者が増加するものと思われる。的確な診断のもと、本稿で紹介したブロック療法を活用し、日常の外来診療に役立てていただきたい。

文 献

- 1) 菊地臣一：腰痛，医学書院，東京，2003
- 2) Ebraheim NA, Xu R, Darwich M et al : Anatomic relations between the lumbar pedicle and the adjacent neural structures. Spine 22 : 2338-2341, 1997

Prostaglandin E₂ EP4 agonist (ONO-4819) accelerates BMP-induced osteoblastic differentiation

Keisuke Nakagawa*, Yuuki Imai, Yoichi Ohta, Kunio Takaoka

Department of Orthopaedic Surgery, Osaka City University Graduate School of Medicine, Asahimachi 1-4-3, Abenoku, Osaka 545-8585, Japan

Received 12 May 2006; revised 3 June 2007; accepted 20 June 2007

Available online 29 June 2007

Abstract

Bone morphogenetic proteins (BMPs) were originally isolated based on their ability to induce ectopic cartilage and bone formation. The agents to promote the local bone formation with BMP would be beneficial to promote bone repair and to shorten the treatment period. For this purpose, we have examined ONO-4819, which is a prostaglandin (PG) E₂ EP4 receptor selective agonist (EP4A), as a positive modulators for the efficacy of BMPs. In our previous study, the systemic and local (with biodegradable synthetic polymers) administration of EP4A led to a significant augmentation of ossicle mass. But the mechanisms how EP4A accelerates the BMP-mediated bone formation are still unknown. In this study, we have examined how EP4A facilitates the BMP signaling using *in vitro* system with pluripotent stromal cell line, ST2. The mRNA expressions of Osterix and ALP (a marker enzyme of osteoblastic differentiation) and enzymatic activity of ALP in the ST2 cells were elevated significantly by BMP treatment. This elevation was further elevated by addition of the EP4A. The accelerated BMP action by the EP4A was abolished by pre-treatment with PKA inhibitor.

This study suggests that ONO-4819 accelerates BMP-induced osteoblastic differentiation of ST2 cells by stimulating the commitment for osteoblastic lineage. Thus PKA signaling pathway would be the main intracellular signaling pathway of the EP4 for the anabolic effect of bone and mineral metabolisms.

© 2007 Elsevier Inc. All rights reserved.

Keywords: Bone morphogenetic protein; Osteoprogenitor cells; Cyclic adenosine monophosphate; EP4 agonist

Introduction

Enhanced local new bone (callus) formation is an essential biological reaction during the repair of fractured or damaged bone. Agents that promote local bone formation would accelerate bone repair and shorten the treatment period. Prostaglandin E₂ (PGE₂) has been shown to promote bone formation both in *in vivo* [1] and *in vitro* [2] experimental systems. PGE₂ action is mediated through 4 types of prostaglandin E₂ receptors (EP1, EP2, EP3 and EP4) [3]. The osteogenic action of PGE₂ is mediated exclusively through EP4 in osteoblasts, based on the experimental evidence that PGE₂-mediated bone formation was abolished in EP4 knock-out mice but not in the EP1-, EP2- and EP3-knock-out mice [4]. The involvement of the EP4 receptor in the osteogenic action of

PGE₂ was also shown through enhanced new bone formation following continuous exposure of osteoblasts to a selective EP4 agonist [5]. In our previous studies, we noted that elevation of intracellular cAMP by phosphodiesterase inhibitors (pentoxifylline and rolipram) and a permeable analogue of cAMP (dibutyl cAMP) enhanced BMP action and caused an increase in alkaline phosphatase activity of osteoblastic cells [6]. Additionally, in an experimental bone induction model, addition of the EP4 agonist to ectopic implants containing rhBMP-2 caused an increase in induced bone mass in a dose-dependent manner in mice [7]. In reviewing these data, it was hypothesized that elevated levels of cAMP might enhance BMP signaling at the transcriptional level. EP4 bound to ligand (PGE₂) mediated activation of adenylate cyclase by the α subunit of Gs protein (G α) and subsequent activation of cyclic AMP-dependent protein kinase A (PKA) would phosphorylate the cAMP-responsive element binding protein (CREB) and thereby regulate the transcriptional function of CRE. However, it is not yet known to what extent the PKA

* Corresponding author. Fax: +81 6 6646 6260.

E-mail address: k-nakagawa@msic.med.osaka-cu.ac.jp (K. Nakagawa).

signaling pathway interacts with BMP-mediated signaling to regulate osteoblastic differentiation.

The present paper describes the results of studies aimed at to elucidate 'cross-talk' between the EP4-mediated and BMP-mediated intracellular signaling pathways to provide further insights into how PGE₂ promotes bone formation.

Materials and methods

Cell cultures

Murine bone marrow-derived stromal cells (ST2) and pluripotent mesenchymal cells (C2C12, C3H10T1/2) were obtained from the RIKEN Cell Bank (Tsukuba, Japan). Primary calvarial osteoblasts and myoblasts were obtained from an 18-day pc.fetus of ICR strain mice by enzymatic digestion. Cells obtained from these sources were seeded at a cell density of 3×10^5 cells per 100-mm plastic dish and cultured in α -minimal essential medium (α -MEM; Sigma, St. Louis, MO, USA) containing 10% (vol./vol.) or 2.5%, heat-inactivated fetal bovine serum (FBS; Gibco, Grand Island, NY, USA) at 37 °C in 5% CO₂ humidified air. Upon approaching confluency, the cells were harvested for use in specific experiments.

Reagents

Recombinant BMP-2 of human type (rhBMP-2) was produced by Wyeth Pharmaceutical Co. (Cambridge, MA) and donated to us through Astellas Pharmaceutical Co. (Tokyo, Japan). The rhBMP-2 was supplied in a buffer solution (5 mmol/l glutamic acid, 2.5% glycine, 0.5% sucrose, and 0.01% Tween-80) at a concentration of 3.52 μ g/ μ l after filter sterilization. Prostaglandin E₂ was purchased from Sigma Chemical Co. (St. Louis, MO, USA). A synthetic selective EP4 receptor agonist (EP4A) ONO-4819, EP4 receptor antagonist ONO-3208, and an EP2 receptor agonist (EP2A) ONO-1259 were provided by Ono Pharmaceutical Co. (Osaka, Japan). The kinase inhibitors used were myristoylated PKI (Biomol Research Laboratories Inc.) for PKA, Gö-6976 (Calbiochem Co.) for PKC, SB203580 (Sigma Chemical Co.) for MAPK and LY294002 (Cayman Chemical Co.) for PI3K.

MTT assay

Cell viability was evaluated with an assay kit using MTT (3-[4,5-dimethylthiazol-2-yl]-2,5-diphenyl tetrazolium bromide) according to the manufacturer's instructions (Promega, Madison, WI, USA). The original form of this assay was described by Mossman [7]. MTT solutions were added to the cells in each well of a 96-well tissue culture plate and incubated for 4 h at 37 °C. After incubation, the Solubilization/Stop solution were added to each well and then mixed thoroughly. The absorbance of each mixture was measured on a microplate reader at a wavelength of 570 nm.

Routine cell counting was also performed under a microscope with use of a hemocytometer. Cells were seeded in 6-well plates and incubation was begun. At sequential time points, the cells were detached from plate by trypsin and stained by trypan blue to exclude dead cells before cell counting.

Assay of cAMP production

To confirm the action of the EP4A in elevating the intracellular cAMP level via EP4 receptor, the cAMP levels in ST2 cells stimulated with the EP4A alone or concurrently with rhBMP-2 (100 ng/ml) were measured and compared with control ST2 cells without treatment. After 20 min of pretreatment with 0.5 mM IBMX, cells were treated with rhBMP-2 and EP4A for 10 min. The medium was then removed and the level of cAMP determined using a cAMP enzyme immunoassay system (GE Healthcare).

Real-time reverse transcription polymerase chain reaction (RT-PCR)

The effects of EP4A on BMP-2-induced Osterix (OSX) and ALP (alkaline phosphatase) expressions were investigated quantitatively by real-time reverse

transcriptase polymerase chain reaction (RT-PCR). When cultures maintained in 12-well plates ($n=3$ per group) became confluent, growth medium containing 2.5% FBS, rhBMP-2 and EP4A was added to the cultures. Total RNA was prepared from ST2 cells treated with each chemical for each time period (0, 3, 6, and 12 h, 1, 2, and 3 days) at 37 °C using NucleoSpin RNA II (Macherey-Nagel, Duren, Germany) according to the manufacturer's instructions. After cleaning of the isolated RNA using the RNeasy kit (Qiagen, Hilden, Germany), 5 μ g of total RNA was reverse-transcribed into first-strand cDNA with an oligo-dT primer using Superscript II reverse transcriptase (Invitrogen, CA, USA). Real-time RT-PCR was performed using the vendor's protocols (Applied Biosystems, Foster City, CA, USA). Quantitative PCR analysis was performed using an iCycler apparatus (Bio-Rad laboratories, Hercules, CA, USA) and the iCycler Optical System Interface software (version 3.0; Bio-Rad). TaqMan fluorogenic probes for OSX, ALP and β -actin, an internal control, were purchased from Applied Biosystems (Foster City, CA, USA). Real-time RT-PCR was performed using Absolute QPCR low rox Mixs (Applied Biosystems, Foster City, CA, USA). Experimental samples were matched to a standard curve generated by amplifying serially diluted products using the same PCR protocol. To correct variability in RNA recovery and efficiency of reverse transcription, β -actin cDNA was amplified and quantified in each cDNA preparation. Normalization and calculation steps were performed as described by Pfaffl [8]. For the *in vitro* study, experiments were performed on three separate test occasions with an n of 3 for each test occasion.

Assay for alkaline phosphatase (ALP) activity

Alkaline phosphatase (ALP) levels in cells were assayed to evaluate osteoblastic differentiation levels under the influence of exogenous BMP and/or EP4A. Cells were seeded at a density of 1×10^4 cells/well in 48-well plates ($n=6$ per group). First, cells were treated with medium in the presence of 50 ng/ml of rhBMP-2 and various concentrations of EP4A (10^{-9} M to 10^{-5} M).

Following a review of the data from these experiments, a concentration of 10^{-7} M EP4A was used for the following series of studies. Cells were treated with medium in the presence or absence of 50 ng/ml of rhBMP-2 and/or 10^{-7} M of EP4A for 2 days with ST2 cells. The cells were washed twice with normal saline, solubilized with 0.2% Triton X in saline, frozen and then thawed. The cells were subsequently, sonicated in cold water and supernatants were measured for ALP activity as described previously [9] using *p*-nitrophenylphosphate as the substrate. One unit of activity is defined as 1 nmol *p*-nitrophenol liberation/30 min. Activity was normalized by protein content assayed with the Bio-Rad kit (BioRad) according to Lowry's method and expressed as a percentage of the control value in the absence of rhBMP-2 or EP4A. Independent experiments were performed in triplicate.

The effects of EP4A on rhBMP-2-induced ALP levels in primary osteoblasts and C2C12 cells were also investigated by treating those cells with 50 ng/ml of rhBMP-2 with or without concurrent treatment with EP4A for 6 days. After those treatments, the ALP levels in the different treatment groups were determined as described above. The respective mean level was determined from values in triplicate samples.

Effects of protein kinase inhibitors on the ALP activity

In order to identify the intracellular pathway of the EP4A-induced signaling on BMP action, specific inhibitors to PKA, protein kinase C (PKC), mitogen-activated protein kinase (MAPK) or phosphatidylinositol 3-kinase (PI3K) was used. ST2 cells were pre-treated with medium containing respective inhibitor for 15 min followed by rhBMP-2 (50 ng/ml) and EP4A (10^{-7} M) and incubated for a further 2 days. The effects of the inhibitors were estimated by measuring ALP levels as described above. The respective mean level was determined from values in triplicate sample.

Statistical analysis

Data were expressed as mean \pm SD for each group and analyzed by one-way analysis of variance (ANOVA) followed by Fisher's protected least significant difference (PLSD). Values of $p < 0.05$ were considered to be significant.

Results

Cell viability

Cell viability as measured by MTT assay (Fig. 1) and cell counting (data not shown) showed no significant effect of BMP and EP4A treatment on the growth of cells examined until 7 days.

Elevation of intracellular cAMP levels by EP4A

In ST2 cells, cAMP levels increased significantly in 10 min of EP4A treatment (Fig. 2). No change in the intracellular cAMP level was recorded following treatment with rhBMP-2 alone and no additive cAMP elevation was noted by concurrent treatment with EP4A and rhBMP-2.

Effect of EP4A on osteoblastic differentiation induced by rhBMP-2

Fig. 3 indicates the effects of EP4A on the induction of ALP (early differentiation marker of osteoblasts) activity by rhBMP-2 in primary osteoblasts (Fig. 3a), C2C12 cells (Fig. 3b), ST2 cells (Fig. 3c), C3H10T1/2 cells and primary myoblasts cells (data not shown). All of these cells consistently responded to the rhBMP-2 and ALP levels were elevated. The addition of EP4A significantly and consistently enhanced the rhBMP-2-induced ALP activity. In ST2 cells, similar results were obtained when PGE₂ (10 nM) was added in place of EP4A (data not shown). In a further experiment, the enhancement of the rhBMP-2-induced ALP activity was abolished by the addition of an EP4 antagonist (Fig. 3c). The additional enhancement of BMP-induced ALP activity by EP4A was reproduced by the addition of dibutyllyl cAMP [6].

Changes of rhBMP-2-induced Osterix and ALP expressions by the addition of the EP4 agonist

From the real-time RT-PCR analysis, Osterix and ALP mRNA expression were increased by rhBMP-2 treatment and further enhanced by EP4A addition (Fig. 4). These results

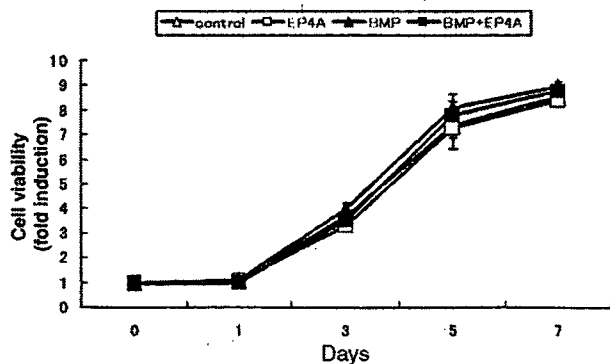


Fig. 1. Cell viability as measured by MTT assay. BMP and EP4A treatment showed no significant effect on the growth of cells examined until 7 days. Bars and lines represent mean±SD for 4 wells.

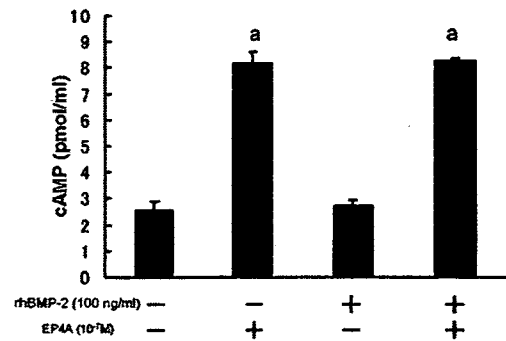


Fig. 2. Effects of EP4A on intracellular cAMP production in 10 min. ST2 cells were pre-incubated in α -MEM, then incubated with 50 ng/ml of rhBMP-2 and/or 10⁻⁷ M of EP4A. Intracellular cAMP levels of the cells treated with EP4A were significantly elevated. Bars and lines represent mean±SD for 4 wells. ^a*p*<0.01 to the group treated without EP4A and rhBMP-2.

indicated that the EP4A potentially enhanced the rhBMP-2 action at a mRNA level in early phase.

Intracellular signaling pathway involved in the EP4A action on BMP signaling

In order to investigate intracellular signaling pathway involved in the mechanism to enhance BMP signaling by EP4A, the effects of kinase inhibitors were examined. As shown in Fig. 5, the inhibitors against PKC (Gö-6976) (Fig. 5a), MAPK (SB203580) (Fig. 5b) and PI3K (LY294002) (Fig. 5c) did not inhibit the EP4A-induced additional elevation of rhBMP-2-induced ALP activity. Only a PKA inhibitor (myristoylated PKI) (Fig. 5d) abolished the EP4A action completely. We concluded that the action of the EP4A was mediated via the PKA signaling pathway.

Discussion

A few studies have revealed close relationships of PGE₂ and PGE₂-producing enzymes such as COX-2 or PGE synthase with biological action of BMP. One study [10] indicated that COX-2 expression might be increased by BMP-2 stimulation to osteogenic cells via core-binding factor activity 1 (Cbf1/Runx2) binding to its consensus sequence in the COX-2 promoter region, and that BMP-induced osteoblastic differentiation was dramatically reduced in COX-2 knock-out mice. Another study [11] revealed suppression of expression of BMP-2 by COX-2 inhibitor, in human mesenchymal stem cells, suggesting the possible involvement of PGE₂ in regulation of BMP-2 expression. In addition to these findings, the present study indicated that exogenously administered EP4 agonist (an analogue of PGE₂) enhanced the biological effects of BMP-2. The previous and present experimental findings suggest the presence of co-operative or auto-regulatory mechanisms between BMP-2 and PGE₂ signaling systems in maintaining or promoting osteoblastic differentiation of cells with osteogenic potential.

The enhancement of BMP action by an EP4A might also be driven by the increased intracellular accumulation of cAMP

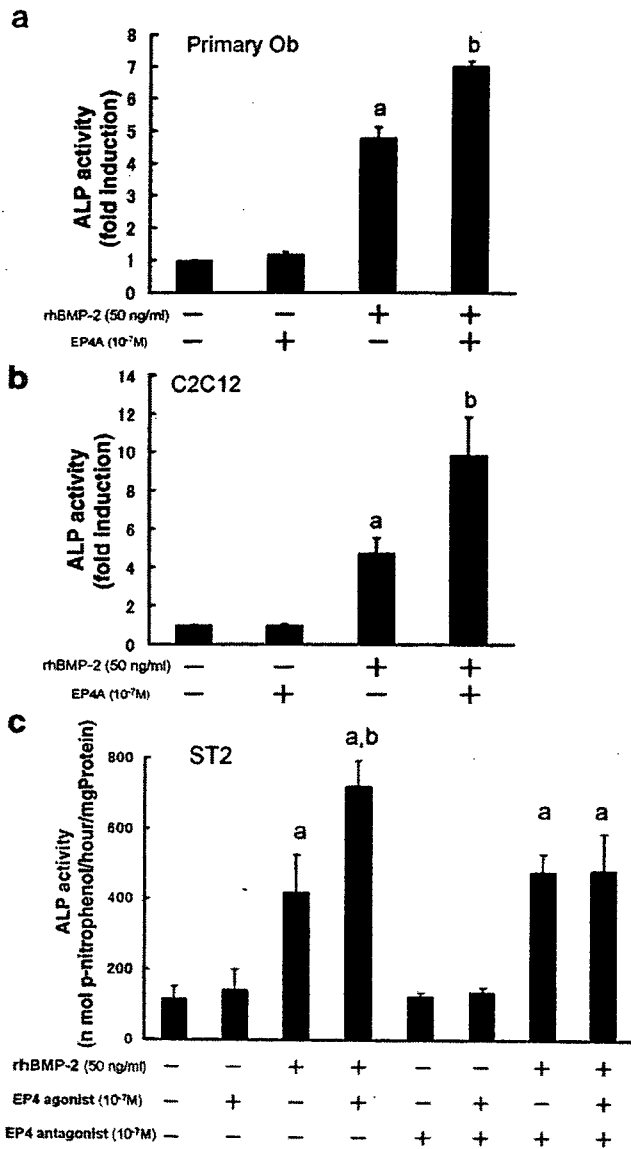


Fig. 3. Effects of EP4A on osteoblastic differentiation induced by rhBMP-2. Alkaline phosphatase (ALP) activities were assayed to evaluate the effects of BMP, EP4 agonist and EP4 antagonist on osteoblastic differentiation. The results of ALP activities of primary osteoblasts (a), C2C12 cells (b) and ST2 cells (c) treated with or without 50 ng/ml of BMP-2 and/or 10⁻⁷ M of EP4A are shown. ALP activities of all cells treated with both of BMP-2 and EP4A were increased when compared to that of all cells treated with BMP-2 only. The effects of EP4A were abolished by the addition of the EP4 antagonist (c). Bars and lines represent mean \pm SD for 4 wells. ^a*p* < 0.05 to the group treated without EP4A and rhBMP-2, ^b*p* < 0.05 to the group treated with rhBMP-2 alone.

based on data from previous *in vivo* [12] and *in vitro* [13] studies. Relationship between intracellular cAMP concentration and intracellular BMP signaling has not been clarified. EP4A alone could not elicit ALP induction, but it enhanced BMP-induced ALP induction as shown in Fig. 3. The rhBMP-2-dependent action of EP4A was also noted in BMP-induced Osterix and ALP expression (Fig. 4). One of the possible intracellular events subsequent to cAMP accumulation would be the activation of cAMP-dependent kinase PKA, since the effect of EP4A was abolished by a PKA-specific inhibitor (myristoylated PKI) (Fig. 5d). Activated PKA phosphorylates

cAMP responsive element binding protein (CREB) to regulate CRE-dependent gene expression [14]. A similar effect of EP4A was observed during the formation of ectopic new bone mass in the muscles following the implantation of rhBMP-2 containing collagen pellets [12,15,16]. These compounds also enhanced BMP-induced ALP expression *in vitro* [6,13].

It was reported that systemic administration of an EP4 agonist (ONO-4819) enhanced new bone formation and prevented bone loss by unloading or ovariectomy in mice [17,18], and an EP4 antagonist suppressed bone formation induced by PGE₂ [19]. Following the reports, we previously reported that systemic [20] and local (with biodegradable synthetic polymers) [7] administration of the EP4A led to the significant augmentation of size and bone mineral density of ectopic ossicles induced by rhBMP-2. At that time, it was equivocal whether EP4A stimulated the BMP signaling or the growth of osteoblastic cells induced by BMP. The results from the present study would indicate that EP4A enhanced BMP signaling at mRNA level to promote the osteoblastic differentiation process.

Effects of protein kinase inhibitors of PKA, protein kinase C (PKC), mitogen-activated protein kinase (MAPK) and phosphatidylinositol 3-kinase (PI3K), showed that the anabolic

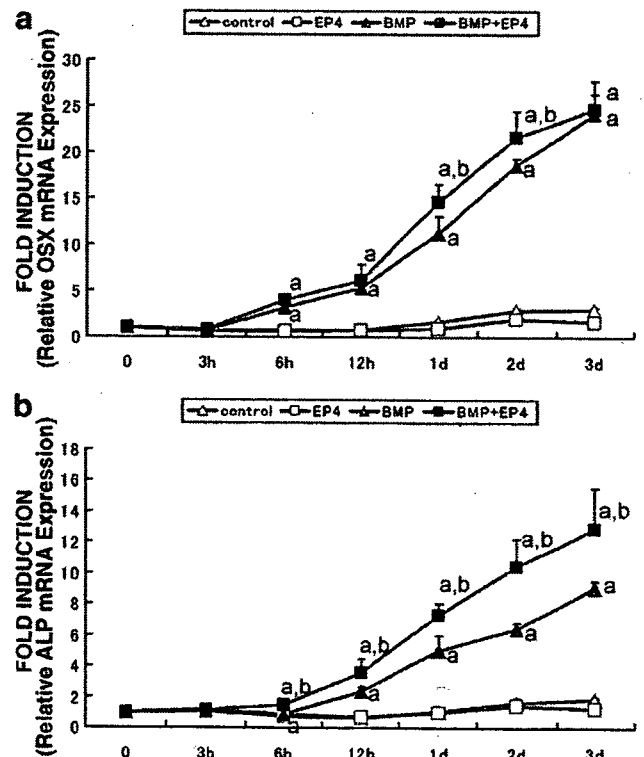


Fig. 4. Relative expression of mRNA for Osterix (a) and ALP (b). Total RNA was prepared from ST2 cells treated with or without BMP and EP4A for each time period (0, 3, 6, and 12 h, 1, 2 and 3 days) on the 12-well plate. Relative mRNA expression was normalized using amplified B-actin expression values. The mRNA expression of Osterix and ALP was increased by rhBMP-2 treatment and further enhanced by EP4A addition. In day 3, Osterix mRNA expression levels were equal in BMP group and BMP/EP4A group. Bars and lines represent mean \pm SD for 4 wells. ^a*p* < 0.05 to the group treated without EP4A and rhBMP-2, ^b*p* < 0.05 to the group treated with rhBMP-2 alone.

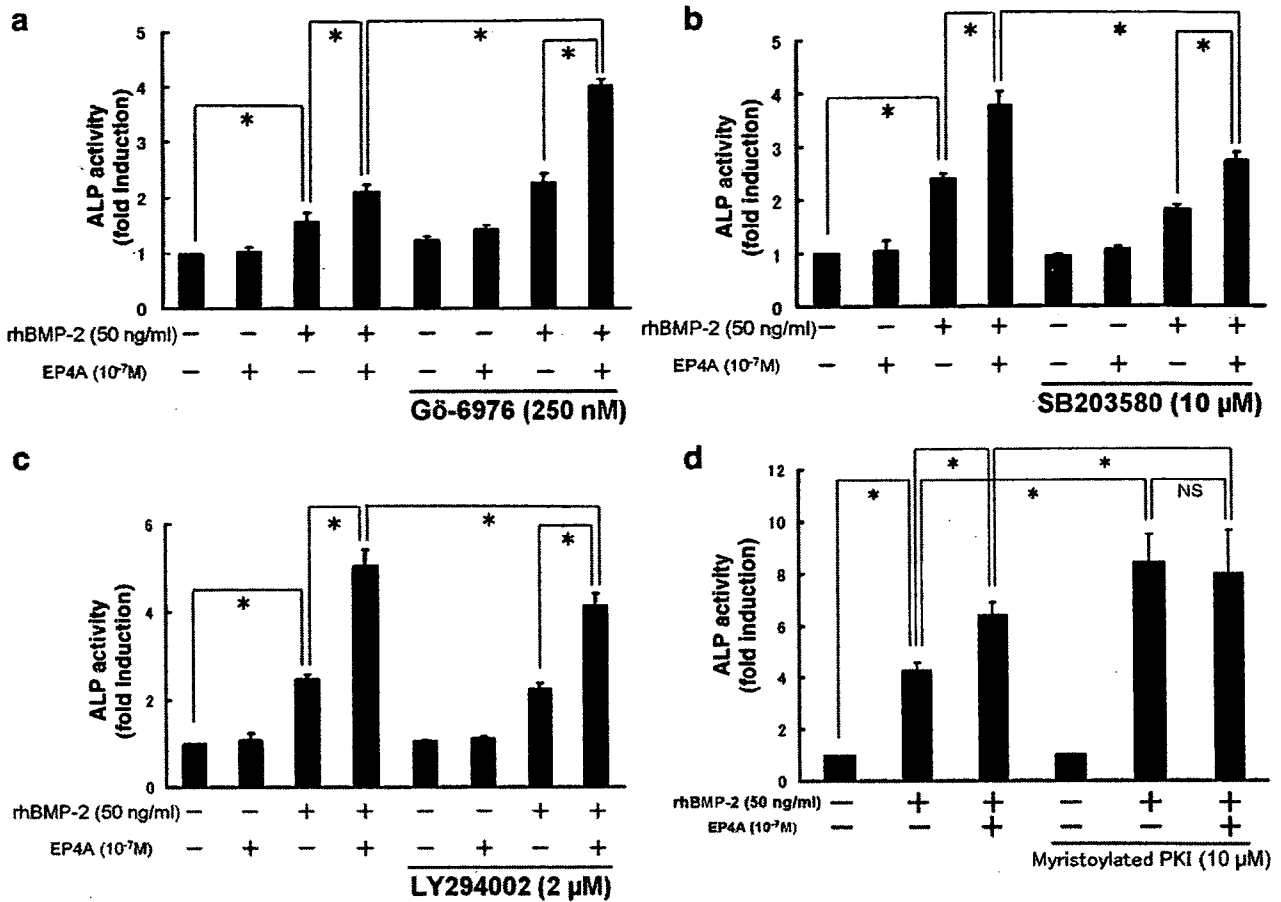


Fig. 5. Effects of protein kinase inhibitors on BMP induced osteoblastic differentiation enhanced with the EP4A. Alkaline phosphatase (ALP) was used as a marker to evaluate the effects of BMP-2, EP4A and respective protein kinase inhibitors on osteoblastic differentiation. Cells were pre-treated with medium containing one of the inhibitors for 15 min before treatment. 250 nM Gö-6976 for PKC inhibitor (a), 10 µM SB203580 for MAPK inhibitor (b), 2 µM LY294002 for PI3K inhibitor (c) and 10 µM myristoylated PKI for PKA inhibitor (d) were used to inhibit respective protein kinases. The value of control group was indicated as 1. Enhancement of BMP induced osteoblastic differentiation by EP4A was abolished by the PKA inhibitor. Bars and lines represent mean \pm SD for 4 wells. ^a $p < 0.05$ to the group treated without EP4A and rhBMP-2, ^b $p < 0.05$ to the group treated with rhBMP-2 only, ^c $p < 0.05$ to the group treated with EP4A and rhBMP-2, ^d $p < 0.05$.

effect of EP4A might be mediated via the PKA signaling pathway. However, it appeared curious that pretreatment by myristoylated PKI alone increased responsiveness to BMP. Although the reason of the increased responsiveness to BMP by inhibition of PKA could not be identified in this study, but one possible explanation might be the presence of unknown suppressive regulatory mechanism to BMP action involving PKA. Considering other protein kinases, MAPK and PI3K inhibitors blocked the effect of EP4A only partially. PKC inhibitor, on the other hand, enhanced the effects of BMP and EP4A. The mechanism by which PKC inhibitor enhances the effects of BMP and EP4A was not clarified. One possibility is that PKC kinase is involved in dephosphorylation of ATP to ADP, and that PKC inhibitor preserves ATP, which would be metabolized to cAMP by adenylyl cyclase. This is only a hypothesis and further study is needed to clearly determine the mechanism.

Currently, certain BMP molecules (BMP-2, BMP-7) with a dimeric molecular structure are produced commercially in CHO cells by DNA recombination technology with low efficiency [21]. In considering the clinical use of BMP to

promote the regenerative repair of fractures or bone defects, several problems need to be addressed. A major challenge is the high cost of the BMP due to the low responsiveness of humans to this protein. The result is a requirement for high doses of BMP and consequent high cost for production of this protein in CHO cells. In this context, any method that enhances the efficacy of BMPs and reduces the cost of BMP-retained implants warrants further exploration. From a clinical perspective, the EP4A used in this study (ONO-4819) could be a promising agent for bone formation because it consistently enhanced BMP activity and induced more bone when compared to BMP alone [7].

Acknowledgments

This work was supported in part by a Grant-in-Aid from the Ministry of Education, Culture, Sports, Science and Technology of Japan (Project Grant No. 30112048, 17591588, 17591589, 17659477, 18390421, 18591640). The authors thank the members of Central Laboratory of Osaka City University Graduate School of Medicine for cooperation in this study.

References

- [1] Weinreb M, Suponitzky I, Keila S. Systemic administration of an anabolic dose of PGE₂ in young rats increases the osteogenic capacity of bone marrow. *Bone* 1997;20:521–6.
- [2] Keila S, Kelner A, Weinreb M. Systemic prostaglandin E₂ increases cancellous bone formation and mass in aging rats and stimulates their bone marrow osteogenic capacity in vivo and in vitro. *J Endocrinol* 2001;168:131–9.
- [3] Suda M, Tanaka K, Natsui K, Usui T, Tanaka I, Fukushima M, et al. Prostaglandin E receptor subtypes in mouse osteoblastic cell line. *Endocrinology* 1996;137:1698–705.
- [4] Yoshida K, Oida H, Kobayashi T, Maruyama T, Tanaka M, Katayama T, et al. Stimulation of bone formation and prevention of bone loss by prostaglandin E EP4 receptor activation. *Proc Natl Acad Sci U S A* 2002;99:4580–5.
- [5] Machwate M, Harada S, Leu CT, Seedor G, Labelle M, Gallant M, et al. Prostaglandin receptor EP(4) mediates the bone anabolic effects of PGE (2). *Mol Pharmacol* 2001;60:36–41.
- [6] Sugama R, Koike T, Imai Y, Nomura-Furuwatari C, Takaoka K. Bone morphogenetic protein activities are enhanced by 3',5'-cyclic adenosine monophosphate through suppression of Smad6 expression in osteoprogenitor cells. *Bone* 2006;38:206–14.
- [7] Toyoda H, Terai H, Sasaoka R, Oda K, Takaoka K. Augmentation of bone morphogenetic protein-induced bone mass by local delivery of a prostaglandin E EP4 receptor agonist. *Bone* 2005;37:555–62.
- [8] Pfaffl MW. A new mathematical model for relative quantification in real-time RT-PCR. *Nucleic Acids Res* 2001;29:e45.
- [9] Imai Y, Terai H, Nomura-Furuwatari C, Mizuno S, Matsumoto K, Nakamura T, et al. Hepatocyte growth factor contributes to fracture repair by upregulating the expression of BMP receptors. *J Bone Miner Res* 2005;20:1723–30.
- [10] Chikazu D, Li X, Kawaguchi H, Sakuma Y, Voznesensky OS, Adams DJ, et al. Bone morphogenetic protein 2 induced cyclo-oxygenase 2 in osteoblasts via a Cbfa1 binding site: role in effects of bone morphogenetic protein 2 in vitro and in vivo. *J Bone Miner Res* 2002;17:1430–40.
- [11] Arikawa T, Omura K, Morita I. Regulation of bone morphogenetic protein-2 expression by endogenous prostaglandin E₂ in human mesenchymal stem cells. *J Cell Physiol* 2004;200:400–6.
- [12] Horiuchi H, Saito N, Kinoshita T, Wakabayashi S, Yotsumoto N, Takaoka K. Effect of phosphodiesterase inhibitor-4, rolipram, on new bone formations by recombinant human bone morphogenetic protein-2. *Bone* 2002;30:589–93.
- [13] Tsutsumimoto T, Wakabayashi S, Kinoshita T, Horiuchi H, Takaoka K. A phosphodiesterase inhibitor, pentoxifylline, enhances the bone morphogenetic protein-4 (BMP-4)-dependent differentiation of osteoprogenitor cells. *Bone* 2002;31:396–401.
- [14] Shaywitz AJ, Greenberg ME. CREB: a stimulus-induced transcription factor activated by a diverse array of extracellular signals. *Annu Rev Biochem* 1999;68:821–61.
- [15] Horiuchi H, Saito N, Kinoshita T, Wakabayashi S, Tsutsumimoto T, Takaoka K. Enhancement of bone morphogenetic protein-2-induced new bone formation in mice by the phosphodiesterase inhibitor pentoxifylline. *Bone* 2001;28:290–4.
- [16] Horiuchi H, Saito N, Kinoshita T, Wakabayashi S, Tsutsumimoto T, Otsuru S, et al. Enhancement of recombinant human bone morphogenetic protein-2 (rhBMP-2)-induced new bone formation by concurrent treatment with parathyroid hormone and a phosphodiesterase inhibitor, pentoxifylline. *J Bone Miner Metab* 2004;22:329–34.
- [17] Hayashi K, Fotovati A, Ali SA, Oda K, Oida H, Naito M. Prostaglandin EP4 receptor agonist augments fixation of hydroxyapatite-coated implants in a rat model of osteoporosis. *J Bone Jt Surg Br* 2005;87:1150–6.
- [18] Tanaka M, Sakai A, Uchida S, Tanaka S, Nagashima M, Katayama T, et al. Prostaglandin E₂ receptor (EP4) selective agonist (ONO-4819.CD) accelerates bone repair of femoral cortex after drill-hole injury associated with local upregulation of bone turnover in mature rats. *Bone* 2004;34:940–8.
- [19] Shamir D, Keila S, Weinreb M. A selective EP4 receptor antagonist abrogates the stimulation of osteoblast recruitment from bone marrow stromal cells by prostaglandin E₂ in vivo and in vitro. *Bone* 2004;34:157–62.
- [20] Sasaoka R, Terai H, Toyoda H, Imai Y, Sugama R, Takaoka K. A prostanoid receptor EP4 agonist enhances ectopic bone formation induced by recombinant human bone morphogenetic protein-2. *Biochem Biophys Res Commun* 2004;318:704–9.
- [21] Sampath TK, Maliakal JC, Hauschka PV, Jones WK, Sasak H, Tucker RF, et al. Recombinant human osteogenic protein-1 (hOP-1) induces new bone formation in vivo with a specific activity comparable with natural bovine osteogenic protein and stimulates osteoblast proliferation and differentiation in vitro. *J Biol Chem* 1992;267:20352–62.

Repair of Bone Defects in Revision Hip Arthroplasty by Implantation of a New Bone-Inducing Material Comprised of Recombinant Human BMP-2, Beta-TCP Powder, and a Biodegradable Polymer: An Experimental Study in Dogs

Masatoshi Hoshino, Takashi Namikawa, Minori Kato, Hidetomi Terai, Susumu Taguchi, Kunio Takaoka

Department of Orthopedic Surgery, Osaka City University Graduate School of Medicine,
1-4-3 Asahi-Machi Abeno-Ku Osaka, 545-8585 Japan

Received 30 October 2006; accepted 19 March 2007

Published online 27 April 2007 in Wiley InterScience (www.interscience.wiley.com). DOI 10.1002/jor.20424

ABSTRACT: A recombinant BMP-2-retaining putty-form implant in combination with a hip prosthesis was used to reconstruct a canine hip joint with defects similar to those encountered in revision total hip arthroplasty (THA). The bone defects were made by resecting the medial half of the proximal femur and the superior acetabular bone with inner iliac wall perforation in 10 dogs. In five dogs, hip prostheses were implanted with the putty material consisting of a synthetic polymer (poly D,L-lactic acid-polyethylene glycol block copolymer), β -tricalcium phosphate powder, and recombinant human BMP-2 in each defect (BMP/Polymer/TCP group). In the remaining five dogs, the same material without rhBMP-2 (control group) was implanted. In the BMP/Polymer/TCP group, new radiopaque shadows began to appear 4 weeks after surgery at the defects around the hip prostheses on both the femoral and acetabular sides. At 12 weeks, the defects were completely filled with new bone in contact with the prosthesis. On histology, the rhBMP-2/Polymer/ β -TCP composite putty implants had been completely resorbed and replaced by new bone. Repair of the bone defects was not seen in the control group. The ability of this material to restore bone effectively eliminates the dependency on bone grafts of autogeneic or allogeneic origin for revision hip arthroplasty and thus opens up a potential new treatment approach in hip cases requiring this type of surgery. © 2007 Orthopaedic Research Society. Published by Wiley Periodicals, Inc. *J Orthop Res* 25:1042–1051, 2007

Keywords: bone defects; BMP/Polymer/TCP group; dogs

INTRODUCTION

Currently, total hip arthroplasty (THA) is a standard treatment of hip disorders associated with significant disability. Globally, large numbers of patients have undergone THA, and satisfactory long-term clinical outcomes have been reported without complications in the early post-operative phase.^{1–6} Satisfactory hip function is maintained as long as the prosthesis remains firmly fixed to the host bone. However, over time, layers of fibrous tissue are generated at the interface between the host bone and prosthesis (with cementless fixation) or cement mantle (with cement fixation). This is likely due to migration of polyethylene wear particles into the interface, resulting in chronic inflammation, bone resorption, and loosening of the prosthesis and leading to

hip and thigh pain and increasing dysfunction of the joint.^{7–9}

Fibrous tissue growth routinely associates with periprosthetic osteolysis, and bone defects of varying size are encountered at revision surgery. This causes difficulty in securing fixation of a new prosthesis; the extent of the problem depends on the severity of the bone defects. When the defects are limited in size, specific modifications of the revision prosthesis (e.g., large-sized cementless metal acetabular sockets and long calcar replacement femoral stems) can solve the problem.^{10–13} However, when the defects are large, augmentation with or without allo- or autogeneic bone graft or bone graft substitutes such as hydroxyapatite and tricalcium phosphate are needed to repair the defects. In these situations, fixation of the revision prosthesis is much more difficult.^{14–17} Options for treatment include use of impaction morselized allograft and cement fixation of the prosthesis or the use of bulky allografts to fill the bone defect. Unfortunately, the latter approach comes with the risk of infection, limited sources of graft material, and limited osteogenic potential.^{14,18,19}

Correspondence to: M. Hoshino (Telephone: +81-6-6645-3851; Fax: +81-6-6646-6260; E-mail: hirotoy@msic.med.osaka-cu.ac.jp)

© 2007 Orthopaedic Research Society. Published by Wiley Periodicals, Inc.

Revision surgery would be greatly enhanced if new methods were available to enhance bone regeneration and ultimately repair the defect without the use of bone grafts. One approach would be to utilize bone-inducing proteins (BMPs) in combination with an appropriate delivery system. Human BMP-2 and BMP-7 have osteoinductive capacities and are currently produced commercially by DNA recombination techniques (rhBMP-2, rhBMP-7).²⁰⁻²³ The rhBMPs are used for spinal fusion, repair of nonunion fractures, and treatment of open tibial fractures using animal-derived collagen as a carrier material.²⁴⁻²⁷

To investigate the use of rhBMP to regenerate lost bone in hip revision surgery, we obtained a hip prosthesis for beagles and specially formulated BMP-retaining putty-form biodegradable materials to fill bone defects created in both the femur and acetabulum. The bone regeneration process was monitored by serial radiographs and computed tomography. The quality of the new bone was investigated using undecalcified histological sections.

MATERIALS AND METHODS

RhBMP-2 was produced by Wyeth (Cambridge, MA) and donated to us through Astellas Pharma Inc. (Tokyo, Japan), supplied in a buffered solution (5 mmol/L glutamic acid, 2.5% glycine, 0.5% sucrose, and 0.01% Tween-80) at a concentration of 3.52 µg/µL after filter sterilization. Poly-D, L-lactic acid-polyethylene glycol block copolymer (PLA-PEG) (MW; 9100, PLA/PEG molar ratio; LA/EO = 60/40), was synthesized and provided to us by Taki Chemical Co., Ltd. (Kakogawa, Japan). Details of the physicochemical characteristics of this biodegradable polymer were reported previously.²⁸⁻³⁰ Beta-TCP powder (particle size <100 µm in diameter) was provided to us by Olympus Biomaterial Corp. (Tokyo, Japan).

To prepare an implant for one dog, 400 mg of β-TCP powder, 400 mg of PLA-PEG, and 200 µg of rhBMP-2 were stirred with a metal rod at 50°C for several minutes. The resultant dough was stored at -30°C until implantation. Control implants consisting of 400 mg of β-TCP powder and 400 mg of PLA-PEG but without rhBMP-2 were prepared in the same manner.

The acetabular and femoral prostheses were fabricated by Zimmer Japan Co., Ltd. (Tokyo, Japan). The titanium femoral stem was 65 mm long and 5 mm wide, with a varus inclination of 10°. Pure titanium fiber coarse metal mesh was diffusion-bonded to the proximal medial 25 mm of the stem. The ultrahigh molecular weight polyethylene head was 10 mm in diameter. The acetabular component had an outer diameter of 20 mm and a hemispherical shell covered with coarse pure titanium fiber mesh. Three small flanges with three screw holes at

the periphery provided fixation to the anterior and posterior parts of the acetabular rim. The porous surfaces were covered manually with rhBMP-2/Polymer/β-TCP or Polymer/β-TCP composite or control at the time of surgery (Fig. 1a).

Ten Beagle dogs (male, 8 months old, weight, 9-11 kg) were purchased from Oriental Yeast Co., Ltd. (Tokyo, Japan) and fed in separate cages with free access to food and water. This animal study was approved by the Animal Care and Oversight Committee of Osaka City University Medical School. The animals were randomly divided into two groups (BMP/Polymer/TCP and Polymer/TCP group), five animals in each group.

Each animal was anesthetized by an intramuscular injection of ketamine (10 mg/kg) and xylazine (1.2 mg/kg) and maintained under anesthesia by an intravenous injection of pentobarbital (25 mg/kg). The right hip was exposed through an anterolateral approach by standard sterile techniques. After an anterior capsulotomy and section of the ligamentum teres, the hip was dislocated, and the femoral head and medial half of the proximal femoral (2.5 cm in length) were resected with an oscillating saw to create a bone defect. The acetabular floor cartilage and bone were then removed with a reamer (2-cm diam) up to the inner wall of the iliac bone, and the central part of the exposed inner wall was perforated (8-mm diam) with a high-speed air drill. In addition, a superior portion of the iliac bone including the superior acetabular rim (15 mm wide, 15 mm long, and 10 mm deep) was removed with a high-speed air drill. Figure 1b shows canine femoral and acetabular specimens with simulated bone defects. The acetabular component was then implanted with one-quarter of the rhBMP-2/Polymer/β-TCP or Polymer/β-TCP composite (control) and fixed to the remaining acetabular rim with titanium screws through the holes in the component flanges. The defect between the acetabular component and iliac bone was packed with one-quarter of the putty implant mass. The distal part of the stem was fixed with cement (Surgical Simplex P, London, England) into the femoral canal. The surface of the femoral component exposed to the proximal medial part was covered with the remaining putty material. After these procedures, the hip was reduced and the wound was closed. Care was taken so that the bone-defect sites were covered and in contact with muscles to keep the putty implant in place. Intra- and postoperative health of the animals was monitored carefully, and prophylactic antibiotics (10 mg/body weight) were administered once a day for 3 days after surgery.

Plain radiographs and CT scans were taken immediately after surgery and serially at 4-week intervals thereafter to monitor new bone formation at the defects. Twelve weeks after surgery, all animals were euthanized by overdose anesthesia, and the pelvis and femurs containing the hip prosthesis were harvested. All dissected samples were examined by plain radiographs and CT scans and then fixed in 70% ethanol for histological examination. CT data of harvested acetabulum and femora were obtained with a helical CT

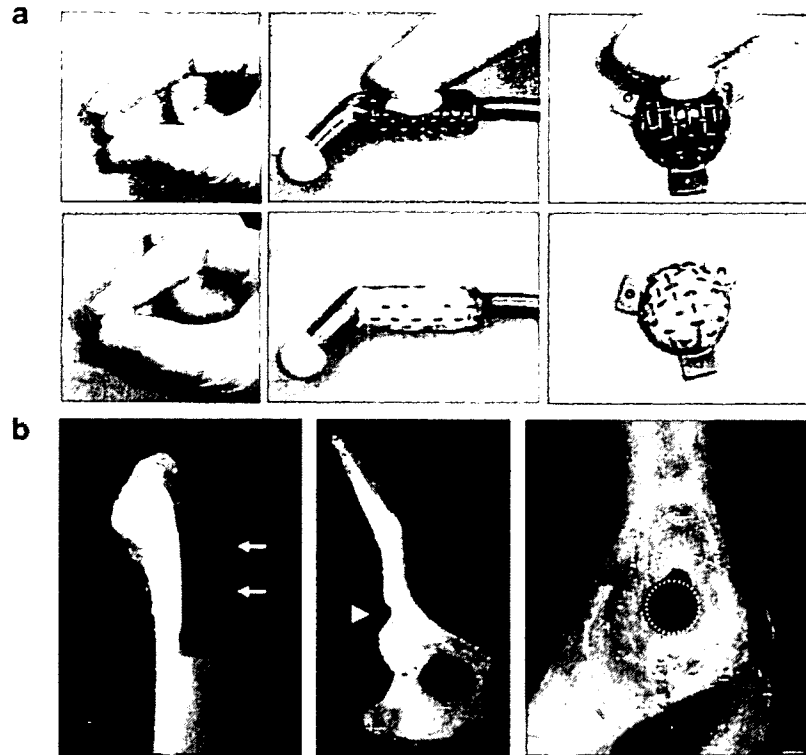


Figure 1. (a) Gross appearance of a new bone-inducing putty material comprised of β -TCP powder, PLA-PEG polymer, and rhBMP-2. (Left) The putty material can be molded at surgery. (Middle and right) The material was pushed manually into the mesh on the hip prosthesis. (b) Gross appearance of canine femoral and acetabular specimens with simulated bone defects. (Left) The defect in proximal femur was made by resecting the femoral head and medial half of the proximal femur (2.5 cm in length) (arrows). (Middle and right) Acetabular defects were created by resecting the superior acetabular bone (15 mm in width, 5 mm in length, and 10 mm in depth) and by perforating the medial wall of the acetabulum (8 mm in diameter) (arrow head and areas surrounded by dot lines).

(GE Yokogawa, Tokyo, Japan) with 1-mm slice thickness and were reconstructed to 3D images and frontal slice images with reconstruction soft-ware (Aze, Tokyo, Japan).

Soft tissues were removed and the samples soaked in Villanueva mineralized bone stain for 7 days, dehydrated in ascending grades of ethanol, defatted in an acetone/methylmethacrylate monomer (mixture rate: 1:2), and embedded in methylmethacrylate (Wako Chemicals, Kanagawa, Japan) without decalcification. Serial sections 200 μ m thick were cut with a precision bone saw in a vertical direction for the central part of the acetabulum and a transverse direction at the femoral defect for the proximal femur. Sections were mounted on plastic slides and ground to 50 μ m using a precision lapping machine (Maruto, Tokyo, Japan).

Quantification of new bone formation at the defects was made from reslice images obtained with the 3D CT images in a center plane at the acetabular defect and perpendicular to the femoral axis at the middle of the femoral defects. The mid reslice images and two 2-mm

additional slices were measured at the defects in each dog. The new bone area including intertrabecular spaces was measured using Scion Image soft ware (Scion Corp., Frederick, MA). The average value of three new bone areas was expressed as new bone area (mm^2).

Mann-Whitney's *U*-test was used to determine significant differences with at $p < 0.05$.

RESULTS

All surgeries were completed successfully, and animals survived without any complications. The animals presented mild lameness immediately after surgery but recovered normal ambulation within 2–3 weeks.

Figure 2a shows time sequence changes in acetabular bone defects in experimental and control groups of dogs on reconstructed frontal CT slices. In the BMP/Polymer/TCP group animal, radiopaque shadows were noted in the superior and

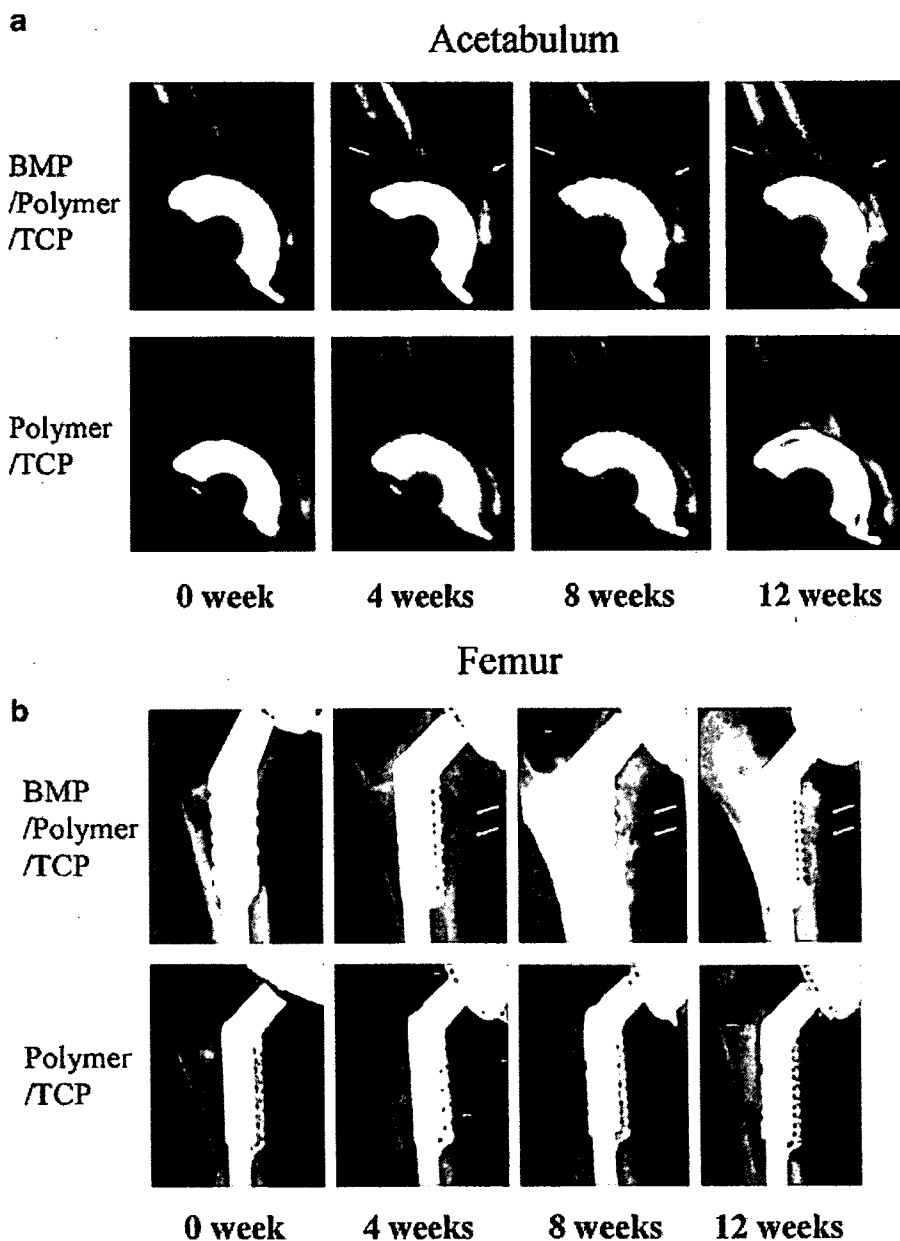


Figure 2. (a) Representative sequential reconstructed CT images of acetabular bone and (b) plain serial radiographs of the femoral bone defect are shown. The defects in the above column were implanted with the rhBMP-2/Polymer/ β -TCP composite; the control defects shown in the lower column were implanted with Polymer/ β -TCP composite. Arrows indicate new bone formed at the superior and medial wall defects of the acetabulum and along the prosthesis at the femoral defects at 4, 8, and 12 weeks after implantation in the BMP/Polymer/TCP group. No bone formation was noted on the control defects where Polymer/ β -TCP composite was implanted.

medial acetabular wall defects at 4 weeks. At 8 weeks, the radiopaque mass in the defect became larger and more evident, and at 12 weeks the defects appeared fully repaired with evidence of

remodeling and cortical bone formation. No loosening of the acetabular component was noted. Radiopaque shadows were not seen throughout the 12 week period in the control group.

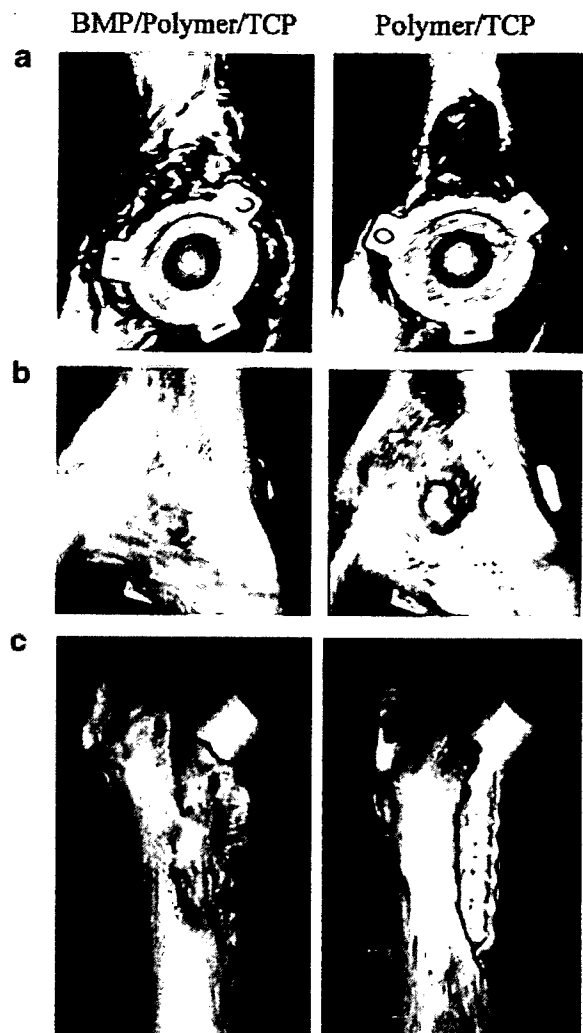


Figure 3. Representative 3D images of acetabular and femoral bones implanted with rhBMP-2/Polymer/ β -TCP composite or Polymer/ β -TCP composite and harvested 12 weeks after surgery. Bone defects in (a) the superior and (b) the medial acetabular wall and in (c) the proximal medial portion of femur were repaired by implanting the rhBMP-2 retaining putty.

On serial plain radiographs of the femoral defect, a pattern of repair similar to that seen in the acetabular defects was observed. At 4 weeks, speckles of radiopaque shadows were noted at the defects in parallel to the femoral implant in the BMP/Polymer/TCP group (Fig. 2b). At 8 weeks, a more dense radiopaque mass was seen around the implants at the defect. Twelve weeks after implantation, all implants in the BMP/Polymer/TCP group showed new bone formation at the defects. In the control group, no evidence of radiopaque deposits was seen, although a small amount of new

bone was seen at distal cut ends of the defects. No further evidence of repair was noted throughout the 12 week period.

Repair of the bone defects was also confirmed in the samples from the BMP/Polymer/TCP group animal on the 3D CT images of the acetabulum and femur samples retrieved at 12 weeks (Fig. 3). In the control group, the defect of femoral implant remained unrepaired with no evidence of new bone formation.

Figure 4 shows representative undecalcified sections of the acetabulum and femur from an experimental BMP/Polymer/TCP group animal and a control group animal. In the BMP/Polymer/TCP group, the periacetabular bone defect and perforated hole at the medial iliac wall was occupied by a significant amount of new woven bone with fibrous tissue in the marrow space (Fig. 4c). Additionally, the new bone ingrowth onto the surface of the acetabular component was noted. In the control section, the defect as well as the perforated medial wall showed no signs of repair or ingrowth of bone onto the acetabular component, with no apparent loosening of the acetabular socket. The putty implant mass was not recognized on the section at 12 weeks after surgery. Inflammatory and foreign body reactions were not elicited by the implanted material at 12 weeks after surgery. The femoral bone defect was also repaired by a significant amount of new bone in the BMP/Polymer/TCP group. Ingrowth of the new bone on the femoral component surface was noted. In the control section, the defect was left unrepaired with no ingrowth of bone onto the femoral component. In BMP-treated defects, new bone formation was also observed within the titanium mesh of both acetabular and femoral components in contact with the titanium surface (Fig. 5). In the control group, fibrous tissue was observed predominantly at the defect site.

The BMP/Polymer/TCP group showed a time-dependent increase in new bone both in the acetabular and femoral defects, but the Polymer/TCP group showed only small areas of new bone formation through the experimental period (Fig. 6). The new bone area of the BMP/Polymer/TCP group at 4, 8, and 12 weeks was significantly higher than that of the Polymer/TCP group in both the acetabulum and femur.

DISCUSSION

Our experimental results indicate that bone defects in revision hip surgery can be repaired with the use of BMP in combination with a

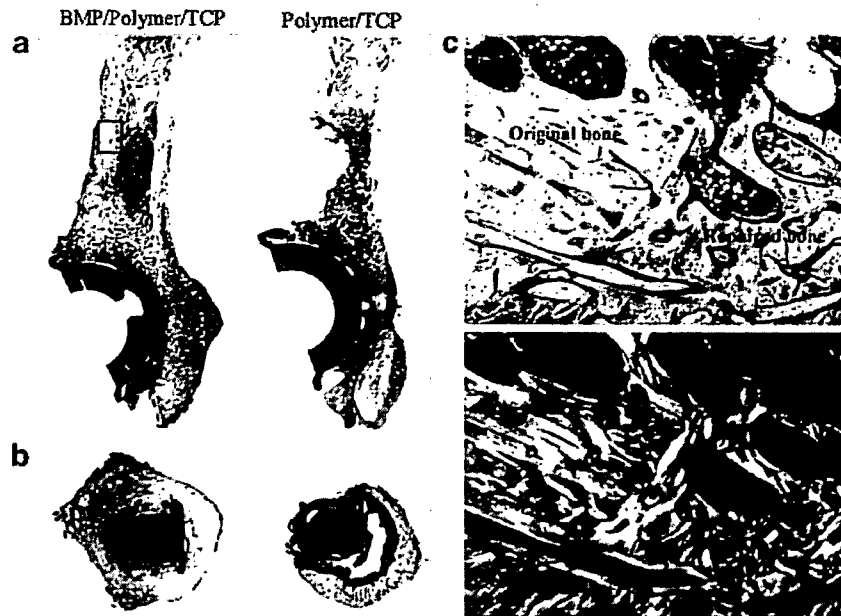


Figure 4. (a,b) Representative undecalcified sections (Villaneuva bone stain, $\times 2$) of acetabular (a) and femoral (b) bone harvested 12 weeks after implantation. Sections on the left are from a dog implanted with rhBMP-2/Polymer/ β -TCP composite and the right from control dogs implanted with the Polymer/ β -TCP composite. In the BMP/Polymer/TCP dog, the defects showed complete repair. (c) Undecalcified histology at the junction area of the original bone and newly formed bone indicated by a rectangle in (a) (Villaneuva bone stain, $\times 50$). The lower section shows the same microscopic field as that seen in the upper right panel, but under polarized light, indicating the woven structure of the newly formed bone.

delivery system. The defects generated in the acetabulum and proximal femurs would likely be classified as moderately severe (type III in AAOS classification for acetabular bone defects, and type I for proximal femoral defects), and clinically would require bone grafting and/or implantation of bone-graft substitutes with a significantly long postoperative period to restore hip function.^{31,32} The key points to draw from our study are that: large bone defects were regenerated by implanting the rhBMP-2 retaining paste implant without bone grafting; new bone grew to restore bone loss and fix the acetabular and femoral components firmly to the host bone; and the paste implant filling the original defects was completely resorbed and replaced by newly formed bone within 12 weeks. These results were achieved with an optimized dose of rhBMP and an appropriate delivery system developed in a series of studies previously undertaken in our laboratory.^{33,34}

Generally, to use rhBMP effectively for bone repair, a local delivery system is essential to elicit bone formation and define the shape of the resultant bone mass. Currently, animal-derived

collagen is used as a carrier material for spinal fusion and for treating nonunions.²⁴⁻²⁷ However, the drawbacks with collagen include lack of mechanical strength and lack of plasticity for fabrication purposes. Consequently, it is difficult to control the BMP-induced bone mass and shape, which depend on the size and shape of the carrier material. In contrast, the paste implant used in this study offers advantages over collagen in terms of mechanical characteristics that enable mass retention and plasticity. Also, the lack of potential immunoreaction and no risk for disease transmission provide safety benefits.³⁵⁻³⁷

To use this method clinically, the optimal dose of rhBMP required in humans must be defined. High doses of the rhBMP-2 are required to elicit new bone formation in highly evolved species including primates and humans. Milligram quantities are needed to generate a few cubic centimeters of new bone.³⁸ Consequently, cost becomes a barrier to broader clinical use. In our study, the dose (100 μ g per defect) was much lower compared to that used in previous dog models with acetabular or femoral periprosthetic bone defects in revision THA.³⁹⁻⁴²

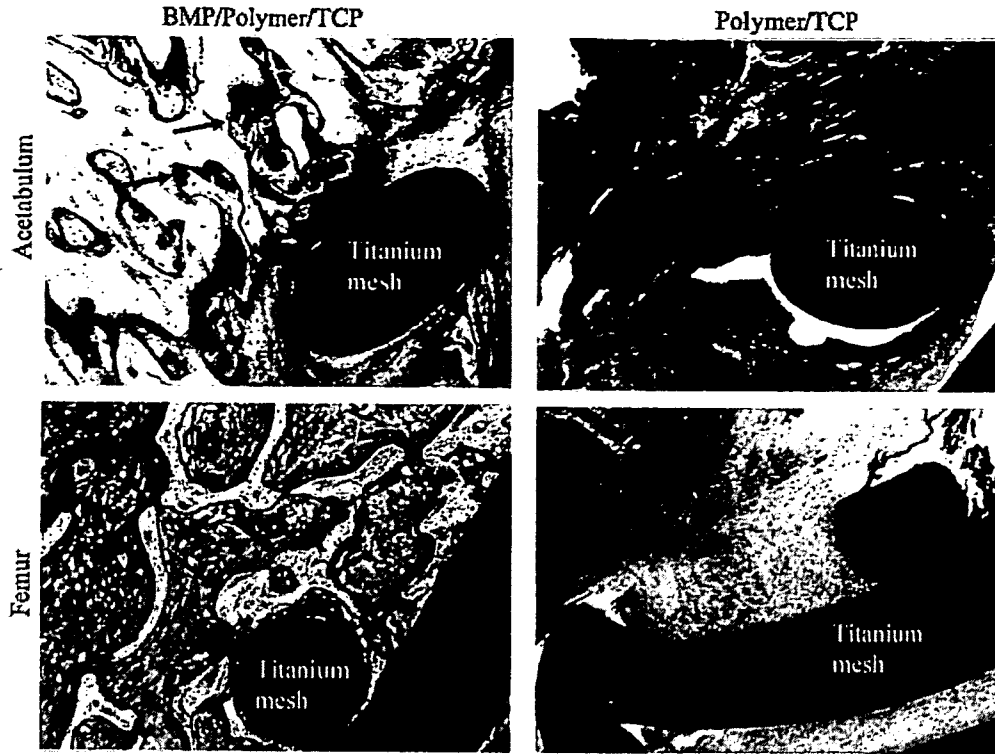


Figure 5. Undecalcified histological view at the interface between the acetabular prosthesis surface (top row) or femoral stem (lower row) and contacting tissues. In the BMP/Polymer/TCP group (left), abundant bone (arrows, stained pink) surrounds or directly contacts the prosthesis, but no bony tissue is seen in the control group (right) (Villaneuva bone stain, $\times 50$).

Based on typical acetabular diameters in dog (2 cm) and humans (5 cm), the defects in humans are effectively 16 times larger than those in the dogs, so the required dose would be 1.6 mg. If the

responsiveness to rhBMP-2 in humans is assumed to be half that in dogs, 12–13 g of the paste containing 3 to 4 mg of rhBMP-2 would be needed to repair similar types of periprosthetic defects. These

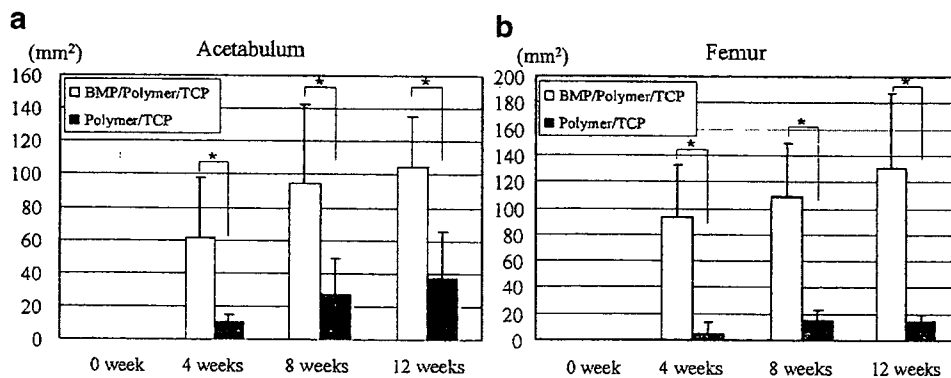


Figure 6. New bone areas (a) at the mid-coronal plane of the acetabular defects and (b) on mid-cross CT slice images of the femoral defects in the BMP/Polymer/TCP and Polymer/TCP groups at 0, 4, 8, and 12 weeks after surgery. The new bone area of the BMP/Polymer/TCP group was significantly greater than that of the Polymer/TCP group in both the acetabulum and femur at 4, 8, and 12 weeks (open columns: Significant difference, $p < 0.05$).

figures are speculative; clinical trials would be required to determine optimal dose and the safety of the rhBMP-2 used on this scale.

Addition of β -TCP to the rhBMP-2 delivery system might help repair bone defects. In a previous study, we used a sticky synthetic polymer in combination with a femoral prosthesis and rhBMP-2 to repair a proximal femoral defect.³⁹ In that case, mixing the rhBMP with the polymer and the combination with the prosthesis was difficult because of the highly sticky nature of the polymer. To address this limitation, biodegradable β -TCP powder was added to create putty that was easy to handle and shape. The addition of the powder reduced the effective dose of rhBMP-2 to one-fifth the amount required in the previous study to rebuild the same size femoral defect. We concluded that this delivery system was better optimized compared with the system used in our previous study.

Solid fixation of the revised prosthesis is an important factor for successful revision surgery with reduced bone stock. In our model, the acetabular socket was fixed with small screws to the anterior and posterior columns. This type of fixation may be less than required, but no displacement of the sockets was noted. This was probably due to limited or no weight-bearing pressure on the operated hip joints in the dogs for the first 2–3 week after surgery. More efforts to achieve solid fixation or limited weight bearing until a significant amount of new bone is established may be necessary as part of the clinical use of this method.

A few clinical and experimental studies have investigated the efficacy of rhBMP in revision hip surgery. Karrholm et al.⁴³ reported no significant clinical efficacy of rhBMP-7 (OP-1) in an impaction allograft application. In their study, OP-1 was added to morselized allograft (3.5 mg/allogeneic femoral head) as part of the impaction technique for treatment of the acetabular and femoral sides. No beneficial effects on bone formation or improved fixation were noted over 5 years. Although they did not define the reason for the lack of efficacy of OP-1, the morselized allograft might not have been an appropriate carrier material to deliver OP-1 or the dose of OP-1 may have been too low to elicit new bone formation in humans. McGee also investigated OP-1 in an impaction allograft to fix the femoral prosthesis in a sheep model.⁴⁴ Their results suggested increased allograft resorption and compromised prosthesis fixation by OP-1 addition, probably through increased remodeling activity. In another study, Barrack et al.⁴⁵ reported

enhanced bone formation and partial bone ingrowth onto the porous surface of the socket by implanting an OP-1 device (rhBMP-7/Type 1 bovine collagen) in a small defect (8 mm in diameter and 5 mm in depth) in a dog model. To enhance bone ingrowth into the porous surface of an acetabular socket, Bragdon et al.⁴⁰ placed a rhBMP-2/calcium phosphate composite in the gap between the socket and the reamed acetabulum. They reported enhanced bone growth within the gap and intensified biological fixation of the socket. The results from all these studies suggest that allograft material has limited efficacy as a carrier. Alternative systems involving calcium phosphate or biodegradable polymers such as utilized in our study may be more effective.

There were some limitations in this study. The 8-month-old dogs were skeletally immature. In addition, this revision model does not include a biological response to loosening. Despite these limitations, the present study successfully achieved repair with use of a novel delivery system and an efficacious dose of rhBMP-2 determined from extensive studies conducted in our laboratory. Our findings suggest that the use of these osteoinductive, biodegradable, and absorbable implants would provide positive benefits over existing treatment procedures in revision hip surgery, specifically avoidance of bone grafts and potentially shorter recovery periods. Further studies to evaluate safety and efficacy in humans will be essential before this system can be adopted for use in the clinic.

ACKNOWLEDGMENTS

We thank Genetic Institute, Astellas Pharma Inc., Taki Chemical Co., Ltd., Olympus Biomaterial Co., Ltd., and Zimmer Japan Co., Ltd. for kindly providing the chemicals and other materials. This work was supported in part by a Grant-in-Aid from the Ministry of Education, Culture, Sports, Science and Technology of Japan (Project Grant No.30112048), Takeda Science Foundation, and the Hip Joint Foundation of Japan.

REFERENCES

1. McDonald DJ, Fitzgerald RH Jr, Ilstrup DM. 1989. Two-stage reconstruction of a total hip arthroplasty because of infection. *J Bone Joint Surg Am* 71-A:828–834.
2. Tsukayama DT, Estrada R, Gustilo RB. 1996. Infection after total hip arthroplasty. A study of the treatment of one hundred and six infections. *J Bone Joint Surg Am* 78-A:512–523.

3. Woo RY, Morrey BF. 1982. Dislocations after total hip arthroplasty. *J Bone Joint Surg Am* 64-A:1295-1306.
4. Dorr LD, Wolf AW, Chandler R, et al. 1983. Classification and treatment of dislocations of total hip arthroplasty. *Clin Orthop Relat Res* 173:151-158.
5. Warwick D, Williams MH, Bannister GC. 1995. Death and thromboembolic disease after total hip replacement. A series of 1162 cases with no routine chemical prophylaxis. *J Bone Joint Surg Br* 77-B:6-10.
6. Geerts WH, Heit JA, Clagett GP, et al. 2001. Prevention of venous thromboembolism. *Chest* 119 (Suppl):132S-175S.
7. Amstutz HC, Campbell P, Kossovsky N, et al. 1992. Mechanism and clinical significance of wear debris-induced osteolysis. *Clin Orthop Relat Res* 276:7-18.
8. Schmalzried TP, Guttman D, Grecula M, et al. 1994. The relationship between the design, position, and articular wear of acetabular components inserted without cement and the development of pelvic osteolysis. *J Bone Joint Surg Am* 76-A:677-688.
9. Zicat B, Engh CA, Gokcen E. 1995. Patterns of osteolysis around total hip components inserted with and without cement. *J Bone Joint Surg Am* 77-A:432-439.
10. Whaley AL, Berry DJ, Harmsen WS. 2001. Extra-large uncemented hemispherical acetabular components for revision total hip arthroplasty. *J Bone Joint Surg Am* 83-A:1352-1357.
11. Berry DJ, Sutherland CJ, Trousdale RT, et al. 2000. Bilobed oblong porous coated acetabular components in revision total hip arthroplasty. *Clin Orthop Relat Res* 371:154-160.
12. Chen WM, Engh CA Jr, Hopper RH Jr, et al. 2000. Acetabular revision with use of a bilobed component inserted without cement in patients who have acetabular bone-stock deficiency. *J Bone Joint Surg Am* 82-A:197-206.
13. Head WC, Malinin TI, Emerson RH Jr, et al. 2000. Restoration of bone stock in revision surgery of the femur. *Int Orthop* 24:9-14.
14. Kerboul M, Hamadouche M, Kerboul L. 2000. The Kerboul acetabular reinforcement device in major acetabular reconstructions. *Clin Orthop Relat Res* 378:155-168.
15. Hamadouche M, Blanchat C, Meunier A, et al. 2002. Histological findings in a proximal femoral structural allograft ten years following revision total hip arthroplasty: a case report. *J Bone Joint Surg Am* 84-A:269-273.
16. Wolfgang GL. 1990. Femoral head autografting with total hip arthroplasty for lateral acetabular dysplasia. A 12-year experience. *Clin Orthop Relat Res* 255:173-185.
17. Oonishi H, Iwaki Y, Kin N, et al. 1997. Hydroxyapatite in revision of total hip replacements with massive acetabular defects: 4- to 10-year clinical results. *J Bone Joint Surg Br* 79-B:87-92.
18. Buck BE, Malinin TI. 1994. Human bone and tissue allografts. Preparation and safety. *Clin Orthop Relat Res* 303:8-17.
19. Buck BE, Resnick L, Shah SM, et al. 1990. Human immunodeficiency virus cultured from bone. Implications for transplantation. *Clin Orthop Relat Res* 251:249-253.
20. Wozney JM, Rosen V, Celeste AJ, et al. 1988. Novel regulators of bone formation: molecular clones and activities. *Science* 242:1528-1534.
21. Wang EA, Rosen V, D'Alessandro JS, et al. 1990. Recombinant human bone morphogenetic protein induces bone formation. *Proc Natl Acad Sci USA* 87:2220-2224.
22. Takaoka K, Yoshikawa H, Hashimoto J, et al. 1993. Purification and characterization of a bone-inducing protein from a murine osteosarcoma (Dunn type). *Clin Orthop* 292:329-336.
23. Takaoka K, Yoshikawa H, Hashimoto J, et al. 1993. Gene cloning and expression of a bone morphogenetic protein derived from a murine osteosarcoma. *Clin Orthop* 294:344-352.
24. Boden SD, Kang J, Sandhu H, et al. 2002. Use of recombinant human bone morphogenetic protein-2 to achieve posterolateral lumbar spine fusion in humans: a prospective, randomized clinical pilot trial: 2002 Volvo Award in clinical studies. *Spine* 27:2662-2673.
25. Burkus JK, Transfeldt EE, Kitchel SH, et al. 2002. Clinical and radiographic outcomes of anterior lumbar interbody fusion using recombinant human bone morphogenetic protein-2. *Spine* 27:2396-2408.
26. Friedlaender GE, Perry CR, Cole JD, et al. 2001. Osteogenic protein-1 (bone morphogenetic protein-7) in the treatment of tibial nonunions. *J Bone Joint Surg Am* 83-A (Suppl 1):S151-S158.
27. Govender S, Csimma C, Genant HK, et al. 2002. Recombinant human bone morphogenetic protein-2 for treatment of open tibial fractures: a prospective, controlled, randomized study of four hundred and fifty patients. *J Bone Joint Surg Am* 84-A:2123-2134.
28. Miyamoto S, Takaoka K, Okada T, et al. 1993. Polylactic acid-polyethylene glycol block copolymer. A new biodegradable synthetic carrier for bone morphogenetic protein. *Clin Orthop* 294:333-343.
29. Saito N, Okada T, Toba S, et al. 1999. New synthetic absorbable polymers as BMP carriers: plastic properties of poly-D,L-lactic acid-polyethylene glycol block copolymers. *J Biomed Mater Res* 47:104-110.
30. Saito N, Okada T, Horiuchi H, et al. 2001. Biodegradable poly-D,L-lactic acid-polyethylene glycol block copolymers as a BMP delivery system for inducing bone. *J Bone Joint Surg Am* 83-A (Suppl 1):S92-S98.
31. D'Antonio JA, Capello WN, Borden LS, et al. 1989. Classification and management of acetabular abnormalities in total hip arthroplasty. *Clin Orthop Relat Res* 243:126-137.
32. D'Antonio J, McCarthy JC, Bargar WL, et al. 1993. Classification of femoral abnormalities in total hip arthroplasty. *Clin Orthop Relat Res* 296:133-139.
33. Namikawa T, Terai H, Suzuki E, et al. 2005. Experimental spinal fusion with recombinant human bone morphogenetic protein-2 delivered by a synthetic polymer and beta-tricalcium phosphate in a rabbit model. *Spine* 30:1717-1722.
34. Kato M, Namikawa T, Terai H, et al. 2006. Ectopic bone formation in mice associated with a lactic acid/dioxanone/ethylene glycol copolymer-tricalcium phosphate composite with added recombinant human bone morphogenetic protein-2. *Biomaterials* 27:3927-3933.
35. Bach FH, Fishman JA, Daniels N, et al. 1998. Uncertainty in xenotransplantation: individual benefit versus collective risk. *Nat Med* 4:141-144.
36. Butler D. 1998. Last chance to stop and think on risks of xenotransplants. *Nature* 391:320-324.
37. DeLustro F, Dasch J, Keefe J, et al. 1990. Immune responses to allogeneic and xenogeneic implants of

- collagen and collagen derivatives. *Clin Orthop Relat Res* 260:263–279.
38. Valentin-Opran A, Wozney J, Csimma C, et al. 2002. Clinical evaluation of recombinant human bone morphogenetic protein-2. *Clin Orthop Relat Res* 395:110–120.
 39. Murakami N, Saito N, Takahashi J, et al. 2003. Repair of a proximal femoral bone defect in dogs using a porous surfaced prosthesis in combination with recombinant BMP-2 and a synthetic polymer carrier. *Biomaterials* 24:2153–2159.
 40. Bragdon CR, Doherty AM, Rubash HE, et al. 2003. The efficacy of BMP-2 to induce bone ingrowth in a total hip replacement model. *Clin Orthop Relat Res* 417:50–61.
 41. Sumner DR, Turner TM, Urban RM, et al. 2004. Locally delivered rhBMP-2 enhances bone ingrowth and gap healing in a canine model. *J Orthop Res* 22:58–65.
 42. Sumner DR, Turner TM, Urban RM, et al. 2006. Additive enhancement of implant fixation following combined treatment with rhTGF-beta2 and rhBMP-2 in a canine model. *J. Bone Joint Surg Am* 88-A:806–817.
 43. Karrholm J, Hourigan P, Timperley J, et al. 2006. Mixing bone graft with OP-1 does not improve cup or stem fixation in revision surgery of the hip: 5-year follow-up of 10 acetabular and 11 femoral study cases and 40 control cases. *Acta Orthop* 77:39–48.
 44. McGee MA, Findlay DM, Howie DW, et al. 2004. The use of OP-1 in femoral impaction grafting in a sheep model. *J Orthop Res* 22:1008–1015.
 45. Barrack RL, Cook SD, Patron LP, et al. 2003. Induction of bone ingrowth from acetabular defects to a porous surface with OP-1. *Clin Orthop Relat Res* 417:41–49.

Estrogen Prevents Bone Loss via Estrogen Receptor α and Induction of Fas Ligand in Osteoclasts

Takashi Nakamura,^{1,2,9} Yuuki Imai,^{1,3,9} Takahiro Matsumoto,^{1,2} Shingo Sato,⁴ Kazusane Takeuchi,¹ Katsuhide Igarashi,⁵ Yoshifumi Harada,⁶ Yoshiaki Azuma,⁶ Andree Krust,⁷ Yoko Yamamoto,¹ Hiroshi Nishina,⁴ Shu Takeda,⁴ Hiroshi Takayanagi,⁴ Daniel Metzger,⁷ Jun Kanno,⁵ Kunio Takaoka,³ T. John Martin,⁸ Pierre Chambon,⁷ and Shigeaki Kato^{1,2,*}

¹Institute of Molecular and Cellular Biosciences, University of Tokyo, Yayoi 1-1-1, Bunkyo-ku, Tokyo 113-0032, Japan

²Exploratory Research for Advanced Technology, Japan Science and Technology Agency, Honcho 4-1-8, Kawaguchi, Saitama 332-0012, Japan

³Department of Orthopaedic Surgery, Osaka City University Graduate School of Medicine, Asahimachi 1-4-3, Abeno-ku, Osaka, 545-8585, Japan

⁴Tokyo Medical and Dental University, Yushima 1-5-45, Bunkyo-ku, Tokyo 113-8510, Japan

⁵Division of Cellular and Molecular Toxicology, National Institute of Health Sciences, 1-18-1 Kamiyoga, Setagaya-ku, Tokyo 158-8501, Japan

⁶Teijin Institute for Biomedical Research, Asahigaoka 4-3-2, Hino, Tokyo 191-8512, Japan

⁷Institut de Génétique et de Biologie Moléculaire et Cellulaire, Département de Physiologie Génétique / Inserm, U-596 / CNRS, UMR7104 / Université Louis Pasteur, Illkirch, Strasbourg, F-67400 France

⁸St. Vincent's Institute of Medical Research, 9 Princes Street, Fitzroy VIC 3065, Australia

⁹These authors contributed equally to this work.

*Correspondence: uskato@mail.ecc.u-tokyo.ac.jp

DOI 10.1016/j.cell.2007.07.025

SUMMARY

Estrogen prevents osteoporotic bone loss by attenuating bone resorption; however, the molecular basis for this is unknown. Here, we report a critical role for the osteoclastic estrogen receptor α (ER α) in mediating estrogen-dependent bone maintenance in female mice. We selectively ablated ER α in differentiated osteoclasts (ER $\alpha^{\Delta Oc/\Delta Oc}$) and found that ER $\alpha^{\Delta Oc/\Delta Oc}$ females, but not males, exhibited trabecular bone loss, similar to the osteoporotic bone phenotype in postmenopausal women. Further, we show that estrogen induced apoptosis and upregulation of Fas ligand (FasL) expression in osteoclasts of the trabecular bones of WT but not ER $\alpha^{\Delta Oc/\Delta Oc}$ mice. The expression of ER α was also required for the induction of apoptosis by tamoxifen and estrogen in cultured osteoclasts. Our results support a model in which estrogen regulates the life span of mature osteoclasts via the induction of the Fas/FasL system, thereby providing an explanation for the osteoprotective function of estrogen as well as SERMs.

INTRODUCTION

Bone remodeling is a dynamic metabolic process. The destruction or "resorption" of pre-existing bone by mature osteoclasts is followed by the formation of new bone by osteoblasts. Osteoblasts are derived from pleiotropic mesenchymal stem cells in the bone marrow. Mature osteoclasts are multinuclear, macrophage-like cells, derived from hematopoietic stem cells also in the bone marrow. Bone resorption and deposition are tightly coupled, and their balance defines both bone mass as well as quality. The regulation of bone remodeling is complex. A number of systemic hormones and transcription factors directly regulate the proliferation and differentiation of osteoblasts and osteoclasts (Karsenty, 2006; Karsenty and Wagner, 2002; Rodan and Martin, 2000; Teitelbaum and Ross, 2003). Additionally, the indirect cellular communication among groups of bone cells is also physiologically critical for bone growth and remodeling (Martin and Sims, 2005; Mundy and Elefteriou, 2006). The molecular and genetic mechanisms governing bone cell fate have been intensively studied; however, how the life span of bone cells is determined on a molecular level remains elusive.

Estrogen is a key hormone in bone remodeling in several species. The osteoprotective action of estrogen is demonstrable in rodents and is clinically important in humans, particularly older women (Chien and Karsenty, 2005;

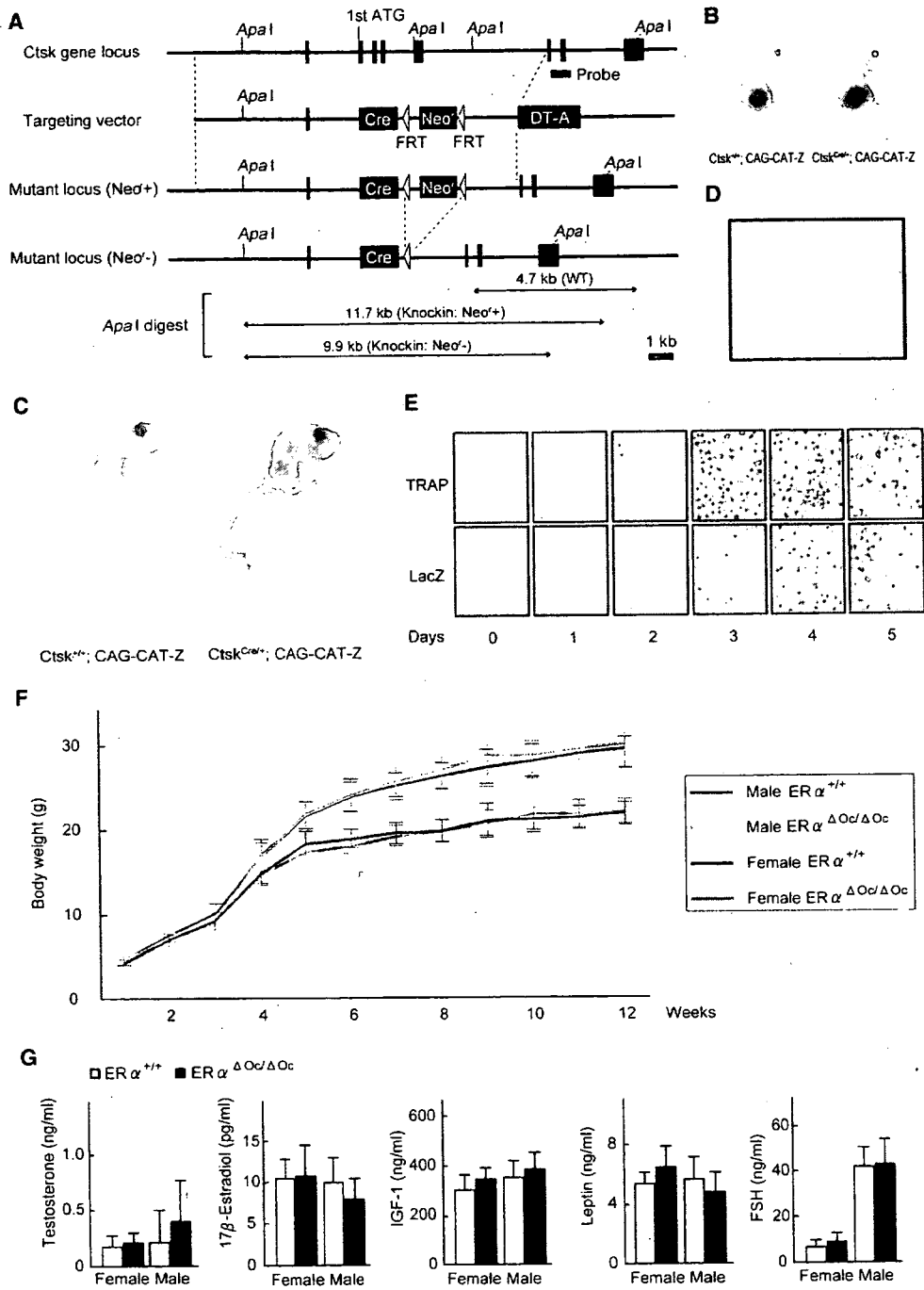


Figure 1. Generation of Knockin Mice Selectively Expressing Cre in Mature Osteoclasts

(A) Illustration of the targeting strategy for insertion of the Cre gene into the mouse *Cathepsin K* (*Ctsk*) gene. A targeting vector was generated to contain the Cre cDNA at the endogenous ATG start site, followed by a FRT (Flp-recombinase target)-flanked Neo^c cassette. The DT-A (diphtheria toxin-A) gene was also inserted to avoid random integrations.

(B and C) *Ctsk*-Cre mice were then crossed with CAG-CAT-Z mice. β -galactosidase activity derived from the activated LacZ reporter gene was monitored to test if expressed Cre excised the loxP sites in mature osteoclasts. LacZ expression patterns reflected the localization patterns of mature osteoclasts in the developing bone at 16.5 days post coitum embryos and in the skeletal tissues of 7-day-old pups.

(D) The LacZ expression induced by Cre-mediated excision was also seen in osteoclasts attached to trabecular bone in the lumbar vertebrae of 12-week-old mice.

(E) LacZ expression was induced during osteoclastogenesis. Osteoclast-like cells that differentiated from bone-marrow macrophages following culture in the presence of M-CSF and RANKL were stained with TRAP (tartrate-resistant acid phosphatase), a mature osteoclast marker.

Delmas, 2002; Raisz, 2005; Rodan and Martin, 2000). Estrogen deficiency in postmenopausal women frequently leads to osteoporosis, the most common skeletal disorder. Similarly, ovariectomy clearly produces an osteoporotic bone phenotype in mice. Osteoporotic bone loss is the result of high bone turnover in which bone resorption outpaces bone deposition (Rodan and Martin, 2000; Teitelbaum, 2007). This imbalance in bone turnover that is induced by estrogen deficiency in women and female rodents can be ameliorated with bio-available estrogens including selective estrogen receptor modulators (SERMs) (Riggs and Hartmann, 2003).

Estrogen and SERMs primarily act by regulating gene transcription via estrogen receptors ($ER\alpha$, $ER\beta$) (Couse and Korach, 1999; Shang and Brown, 2002). ERs belong to the nuclear receptor gene superfamily and act as ligand-inducible transcriptional factors (Mangelsdorf et al., 1995). ER dimers directly or indirectly associate with specific DNA elements in the target gene promoter (Shang and Brown, 2002) and control transcription through reorganizing chromatin structure and histone modifications (Belandia and Parker, 2003). Genetic mouse models (KO mice) lacking $ER\alpha$ ($ER\alpha^{-/-}$) and $ER\beta$ ($ER\beta^{-/-}$) provide insights into ER function (Mueller and Korach, 2001; Windahl et al., 2002). In mice, though $ER\alpha$ appears to be the major receptor in most estrogen target tissues including bone (Sims et al., 2003), neither clear bone loss nor high bone turnover is detectable in $ER\alpha$ single or $ER\alpha/ER\beta$ double-KO females (Syed and Khosla, 2005; Windahl et al., 2002). This unexpected maintenance of bone mass in female mutants is presumed to be due to unphysiologically elevated levels of other osteoprotective hormones, like androgens. Systemic defects in the hypothalamus caused by ER inactivation appear to impair the negative feedback system of hormone production (Syed and Khosla, 2005). This leads to an excess in estrogen precursors, notably androgens. In fact, the anabolic effects of androgens mediated by the androgen receptor (AR) are evident in female mice (Kawano et al., 2003; Sims et al., 2003). In males, estrogen is also osteoprotective, as is evident by the development of osteopenia in male patients genetically deficient in $ER\alpha$ (Smith et al., 1994) or aromatase activity (Simpson and Davis, 2001). Thus, irrespective of the accumulating clinical and basic research data on the osteoprotective actions of estrogen and SERMs, the molecular basis of this osteoprotection in females remains elusive.

To study the molecular interactions behind the antibone resorptive actions of estrogen in women and female animals, we genetically ablated $ER\alpha$ in mature osteoclasts ($ER\alpha^{4Oc/4Oc}$). Selective ablation of $ER\alpha$ in differentiated osteoclasts ($ER\alpha^{4Oc/4Oc}$) was accomplished by crossing a *Cathepsin K-Cre* knockin mouse with a floxed $ER\alpha$ mouse. This resulted in clear trabecular bone loss and

high bone turnover associated with increased osteoclast numbers in females but not in males. In the female mutants, further bone loss following ovariectomy was not significant and recovery by estrogen was ineffective in the trabecular areas of long bones and lumbar vertebral bodies. Upregulated expression of *Fas ligand* (*FasL*) gene, and increased apoptosis in differentiated osteoclasts by estrogen was found in the intact bone of wild-type females but undetectable in $ER\alpha^{4Oc/4Oc}$ females. Induction of *FasL* and apoptosis by estrogen as well as a SERM also required $ER\alpha$ in cultured osteoclasts. Thus, we propose that the osteoprotective actions of estrogen and SERMs are mediated at least in part through osteoclastic $ER\alpha$ in trabecular bone, and the life span of mature osteoclasts is regulated through the activation of the *FasL* signaling.

RESULTS

Generation of Osteoclast-Specific $ER\alpha$ Gene Disruption by Knocked-In *Cre* in the *Cathepsin K* Gene

To specifically disrupt $ER\alpha$ gene in mature osteoclasts, we knocked in *Cre* into the gene locus of *Cathepsin K* ($Ctsk^{Cre/+}$) (Figures 1A, S1A, and S1B), a gene known to be expressed in differentiated osteoclastic cells arising from hematopoietic stem cells. This gene is functionally indispensable for mature osteoclasts (Saftig et al., 1998). Only one copy appears enough to support normal bone formation and bone turnover, since heterozygous mutant mice of *Cathepsin K* ($Ctsk^{+/-}$) have no obvious bone phenotype (Gowen et al., 1999; Li et al., 2006; Saftig et al., 1998). Clear, bone-specific expression of the *Cre* transcript in the adult $Ctsk^{Cre/+}$ mice was observed in the tested tissues (Figure S1C). To confirm *Cre* protein expression, the $Ctsk^{Cre/+}$ mice were crossed with tester mice (CAG-CAT-Z). These mice were genetically engineered to express β -galactosidase by excision of the transcribed stop sequence in front of the β -galactosidase gene (*LacZ*) in cells expressing *Cre* (Sakai and Miyazaki, 1997). β -galactosidase expression visualized by *LacZ* staining was observed in the bones of 16.5 dpc embryos and 7-day-old pups of $Ctsk^{Cre/+}$; CAG-CAT-Z mice. Expression patterns were consistent with the appearance and skeletal localization of functionally mature osteoclasts (Figures 1B and 1C). Histochemical staining of *LacZ* in the lumbar vertebrae of 12-week-old mice was localized in multinuclear osteoclasts (Figure 1D) but not seen in osteoblasts and osteocytes (Figure S1D) and the hypothalamus (Figure S1E). Since *Cathepsin K* gene expression is evident in differentiated osteoclasts (Saftig et al., 1998), we used an in vitro culture cell system to test whether *Cre* expression was driven by the endogenous promoter that is induced at the time of osteoclast differentiation. Osteoclast-precursor cells derived from bone marrow

(F) The growth curve of $ER\alpha^{4Oc/4Oc}$ mice was indistinguishable from that of the control mice. Data are represented as mean \pm SEM.

(G) Serum hormone levels were normal in 12-week-old $ER\alpha^{4Oc/4Oc}$ (filled column) versus $ER\alpha^{+/+}$ (open column) mice ($n = 10$ –11 animals per genotype). Data are represented as mean \pm SEM.