

16. Ogino H, Ueda Y, Sugita T, et al. Monitoring of regional cerebral oxygenation by near-infrared spectroscopy during continuous retrograde cerebral perfusion for aortic arch surgery. *Euro J Cardiothorac Surg* 1998;14:415-8.
17. Reich DL, Uysal S, Griep RB, et al. Neuropsychologic outcome after deep hypothermic circulatory arrest in adults. *J Thorac Cardiovasc Surg* 1999;177:156-63.
18. Ergin MA, Uysal S, Griep RB, et al. Temporary neurological dysfunction after deep hypothermic circulatory arrest: a clinical marker of long-term functional deficit. *Ann Thorac Surg* 1999;67:1887-90.
19. Westaby S, Katsumata T. Proximal aortic perfusion for complex arch and descending aortic disease. *J Thorac Cardiovasc Surg* 1998;115:162-7.
20. Jacobs MJ, deMol BA, Veldman DJ. Aortic arch and proximal supraaortic arterial repair under continuous antegrade cerebral perfusion and moderate hypothermia. *Cardiovasc Surg* 2001;9:396-402.
21. Di Eusanio M, Schepens MA, Kazui T, et al. Brain protection using antegrade selective cerebral perfusion: a multicenter study. *Ann Thorac Surg* 2003;76:1181-9.
22. Spielvogel D, Halstead JC, Griep RB, et al. Aortic arch replacement using a trifurcated graft: simple, versatile, and safe. *Ann Thorac Surg* 2005;80:90-5.
23. Kouchoukos NT, Masetti P. Total aortic arch replacement with a branched graft and limited circulatory arrest of the brain. *J Thorac Cardiovasc Surg* 2005;129:1207-8.

# Aortic Arch Replacement Using Selective Cerebral Perfusion

Teruhisa Kazui, MD, PhD, Katsushi Yamashita, MD, PhD, Naoki Washiyama, MD, PhD, Hitoshi Terada, MD, PhD, Abul Hasan Muhammad Bashar, MBBS, PhD, Kazuchika Suzuki, MD, PhD, and Takayasu Suzuki, MD

First Department of Surgery, Hamamatsu University School of Medicine, Hamamatsu, Japan

**Background.** The present study was conducted to report our clinical experience with aortic arch replacement using selective cerebral perfusion (SCP) and determine the independent predictors of in-hospital mortality and neurologic outcome.

**Methods.** We studied 472 consecutive patients who underwent aortic arch replacement using SCP between January 1986 and February 2006. All operations were performed with the aid of hypothermic extracorporeal circulation, SCP, and in most cases, systemic circulatory arrest for open distal anastomosis. The etiology of aortic diseases included acute aortic dissection in 126 patients (27%), chronic aortic dissection in 102 (21%), and degenerative aneurysm in 245 (52%). Total arch replacement was performed in 420 patients (89%). Mean SCP time was  $88 \pm 32$  minutes.

**Results.** The overall in-hospital mortality was 9.3%, but it dropped significantly to 4.1% in the most recent 266

patients. Independent predictors of in-hospital mortality were early series, renal/mesenteric ischemia, pump time, increasing age, chronic renal dysfunction, history of cerebrovascular accident (CVA), and previous ascending or arch operation. Overall postoperative temporary and permanent neurologic dysfunction were 4.7% and 3.2%, respectively. A history of CVA was the only predictor of temporary neurologic dysfunction, whereas CVA and pump time were independent predictors of permanent neurologic dysfunction. SCP time had no significant correlation with in-hospital mortality and neurologic outcome.

**Conclusions.** SCP facilitates complicated aortic arch replacement, resulting in a reduction of mortality and morbidity for arch aneurysms or dissections.

(Ann Thorac Surg 2007;83:S796-8)

© 2007 by The Society of Thoracic Surgeons

It is essential to select optimal strategies for cerebral protection and surgical technique of arch repair to improve the surgical outcome of arch aneurysms or dissections. Antegrade selective cerebral perfusion (SCP) has been the cerebral protection method of choice at our institution if the required cerebral protection time will exceed 30 minutes [1-4].

The aim of the present study was to report the clinical experience with SCP during aortic arch replacement and to determine the independent predictors of in-hospital mortality and neurologic outcome.

## Material and Methods

This was a retrospective study in which individual patient data were not revealed. For this type of study, individual patient consent and institutional approval are waived.

Between January 1986 and February 2006, 589 patients were operated on for arch aneurysm or dissection using hypothermic cardiopulmonary bypass (CPB), and deep

hypothermic circulatory arrest (DHCA), with or without retrograde cerebral perfusion (RCP) or antegrade SCP. Included in this study are 472 patients (79%) who received the operation with the aid of SCP. Their mean age was  $64 \pm 13$  years (range, 18 to 92 years), and 65% were men. A total of 126 patients (27%) were treated for acute dissection, 102 (21%) for chronic dissection, and 245 (52%) for degenerative and atherosclerotic aneurysm. Emergent operations were performed on 138 patients (29%) within 24 hours of admission for rupture of their aneurysm or acute dissection.

Preoperative complications included shock in 40 patients (8.5%), chronic obstructive pulmonary disease in 44 (9.3%), a history of cerebrovascular accident in 70 (14.8%), coronary artery disease in 68 (14.4%), and chronic renal dysfunction in 49 (10.4%), with 12 (2.5%) requiring hemodialysis. Aortic dissection-related complications included cardiac tamponade in 52 (11.0%), myocardial ischemia in 10 (2.1%), cerebral ischemia in 13 (2.8%), renal/mesenteric ischemia in 12 (2.5%), and leg ischemia in 17 (3.6%). Eighty patients (17%) had undergone previous cardiovascular procedures.

In all elective cases, preoperative cerebral four-vessel (bilateral internal carotid and vertebral artery) angiography, cerebral computed tomographic scanning, or magnetic resonance imaging were performed to rule out

Presented at Aortic Surgery Symposium X, New York, NY, April 27-28, 2006.

Address correspondence to Dr Kazui, First Department of Surgery, Hamamatsu University School of Medicine, 1-20-1 Handayama, Hamamatsu 431-3192, Japan; e-mail: tkazui@hama-med.ac.jp.

© 2007 by The Society of Thoracic Surgeons  
Published by Elsevier Inc

0003-4975/07/\$32.00  
doi:10.1016/j.athoracsur.2006.10.082

cerebrovascular disease and to select the site of cerebral perfusion.

Operations were performed through a median sternotomy in 446 patients (94%) and through median sternotomy with opening of the left pleura in 13 (3%). A left anterior thoracotomy was used in 13 (3%) for an extended descending aortic replacement. The site of arterial cannulation for CPB in most of the recent cases was the ascending aorta, and the right axillary artery was used when necessary.

The details of hypothermic CPB and antegrade SCP have been described previously [1, 3]. Briefly, systemic circulation is arrested when the patient is cooled by extracorporeal circulation to a rectal temperature of 25°C (usually dropping later to 22°C). Both innominate and left common carotid arteries are cannulated and are perfused at a rate of 10 mL/(kg · min) by a single pump. The left subclavian artery is kept cross-clamped during SCP, except in cases where an additional left subclavian artery perfusion is performed: (1) occlusion of the right vertebral artery, (2) lack of efficient intracranial arterial communication, or (3) dominant left vertebral artery. The right radial arterial pressure and bilateral catheter tip pressure are adjusted to about 40 mm Hg to regulate perfusion pressure. During CPB, arterial blood pH is managed according to the  $\alpha$ -stat strategy.

More recently, unilateral cerebral perfusion through the right axillary artery instead of bilateral cerebral perfusion has been used in selected patients undergoing hemiarch replacement for acute type-A aortic dissection. CPB is instituted through the right axillary artery. After cooling to a rectal temperature of 20°C, both innominate and left common carotid arteries are cross-clamped at their origins, and systemic circulatory arrest is induced.

Table 1. Surgical Technique

Technique/Procedure	No. (%)
<b>Surgical technique</b>	
Patch aortoplasty	3 (1)
AAR + HAR	49 (10)
AAR + TAR	225 (48)
AAR + TAR + DAR	168 (35)
TAR	19 (4)
TAR + DAR	8 (2)
Total TAR	420 (89)
<b>Concomitant procedures</b>	
Composite graft replacement (redo)	55 (8)
CABG	64
AVR	18
AV resuspension	27
MVR/MAP	5
AAA repair	3
Miscellaneous	9

AAA = abdominal aortic aneurysm; AAR = ascending aortic replacement; AV = aortic valve; AVR = aortic valve replacement; CABG = coronary artery bypass grafting; DAR = descending aortic replacement; HAR = hemiarch replacement; MVR/MAP = mitral valve replacement/mitral annuloplasty; Redo = redo composite graft replacement; TAR = total arch replacement.

Table 2. Independent Predictors for In-Hospital Mortality and Neurologic Outcome

Independent Variables	OR (95% CI)	p Value
<b>In-hospital mortality</b>		
Early series	7.122 (2.83, 17.9)	<0.0001
Renal/mesenteric ischemia	35.68 (16.56, 194.2)	<0.0001
Pump time	1.010 (1.005, 1.015)	0.0002
Increasing age	1.075 (1.029, 1.122)	0.0012
Chronic renal dysfunction	3.413 (1.33, 8.75)	0.0107
History of CVA	2.896 (1.20, 7.00)	0.0182
Previous ascending/arch operation	3.934 (1.19, 13.0)	0.0250
<b>Temporary neurologic dysfunction</b>		
History of CVA	3.42 (1.36, 8.64)	0.0092
<b>Permanent neurologic dysfunction</b>		
History of CVA	12.32 (3.92, 38.8)	<0.0001
Pump time	1.009 (1.004, 1.015)	0.0017

CI = confidence interval; CVA = cerebrovascular accident; OR = odds ratio.

Then, unilateral cerebral perfusion through the right axillary artery is maintained at a flow rate of 5 to 10 mL/(kg · min). The number of arch vessels used for SCP in our series was a single vessel in 24 patients (5%), two vessels in 438 (93%), and three vessels in 10 (2%).

Real-time intraoperative monitoring of SCP includes perfusion pressure and flow rates, two-channel serial electroencephalography, and two-channel near-infrared spectroscopy. If available, internal jugular venous oxygen saturation and transcranial Doppler sonography are also used.

Open distal anastomosis has been used in 98% of patients since March 1987. Operative techniques used in this series are listed in Table 1. Patch angioplasty of the aortic arch was used in the initial 3 patients (1%), and graft replacement was performed in the remaining 469 (99%). Ascending aortic replacement (AAR) and hemiarch replacement (HAR) were performed in 49 patients (10%); AAR and total arch replacement (TAR) in 225 patients (48%); AAR, TAR, and descending aortic replacement (DAR) in 168 (35%); isolated TAR in 19 patients (4%), and TAR and DAR in 8 patients (2%). Overall, TAR was performed in 420 patients (89%). TAR with a concomitant elephant trunk technique was performed in 63 patients (13%).

The en bloc repair or island technique for TAR was used in the initial 21 patients (5%), and the remaining 399 patients (95%) underwent the separated graft technique in which an aortic arch branched graft was used. A total of 166 patients (35%) had 181 concomitant procedures, which are summarized in Table 1.

## Results

The overall in-hospital mortality was 9.3% (44/472). In-hospital mortality was 16.0% in the early series (1986 to

1996) of 206 patients and 4.1% ( $n = 11$ ) in the 266 patients in the late series (1997 to 2006;  $p < 0.001$ ), even with the inclusion of emergent cases. Table 2 summarizes the independent predictors of in-hospital death as estimated by multivariable step-wise logistic regression analysis. It revealed that early series, renal/mesenteric ischemia owing to acute dissection, pump time, increasing age, chronic renal dysfunction, history of CVA, and previous ascending/arch operation were significant independent predictors of in-hospital mortality.

The overall postoperative temporary and permanent neurologic dysfunction rates were 4.7% and 3.2% in the early series and 4.9% and 3.8%, respectively, in the late series (NS). Multivariable analysis indicated that a history of CVA was the only independent predictor of temporary neurologic dysfunction, and CVA and pump time were independent predictors of permanent neurologic dysfunction (Table 2).

Mean SCP time was  $88.2 \pm 32.2$  minutes. There was no significant correlation between SCP time and in-hospital mortality or neurologic outcome.

### Comment

Cerebral protection methods currently used are DHCA with or without RCP, and antegrade SCP. Several experimental and clinical studies indicate that antegrade SCP presents several advantages compared with DHCA with or without RCP. Antegrade SCP can extend the safe duration of circulatory arrest up to 90 minutes [5], allowing meticulous aortic arch repair and facilitating the complex and time-consuming TAR. SCP obviates the need for deep hypothermia, thus reducing pump time and the risk of hypothermia-related complications such as pulmonary insufficiency and coagulopathy. SCP is more effective in supplying oxygenated blood to the brain, thus ensuring a more physiologic brain energy metabolism. SCP is therefore considered to be the most reliable method of preventing ischemic injury to the brain.

A suggested major drawback of SCP is the risk of cerebral embolism or malperfusion while cannulating the arch vessels. But complications related to arch vessel cannulation can be completely avoided by transecting each arch vessel 1 cm distal to its origin, where it is free from atheroma or dissection, and by cannulating it through the arteriotomy under direct vision.

In our series, the sites of arch vessel cannulation for SCP were the innominate or right axillary artery and the left common carotid artery. In principle, however, selec-

tion of cannulation sites is determined by the pathophysiology of the intracerebral and extracerebral arterial system as well as the expected duration of cerebral protection, which is related to the underlying disease and the extent of aortic replacement. Using this integrated cerebral protection method of SCP with systemic circulatory arrest, we were able to perform TAR in a more aggressive manner to include even the acute aortic dissection cases and to extend aortic replacement down to the mid-descending aorta through a median sternotomy alone.

We prefer the separated graft TAR technique to the en bloc technique because it presents several advantages:

1. in aged patients, atherosclerotic lesions near the origin of the arch vessels can be completely resected;
2. in patients with acute dissection, graft anastomoses can be performed at the intact distal sites of the arch vessel where dissection has not extended;
3. the pathologic portion of the aortic arch can be completely resected in Marfan patients; and
4. bleeding from the site of the arch vessel anastomoses can be controlled easily.

The average SCP time was 88 minutes in the present series, and it had no significant correlation with in-hospital mortality or neurologic outcome.

In summary, with the refined use of antegrade SCP and the separated graft technique, we could substantially reduce in-hospital mortality and neurologic complications in recent patients with arch aneurysm or dissection.

### References

1. Kazui T, Washiyama N, Bashar AHM, et al. Total arch replacement using aortic arch branched grafts with the aid of antegrade selective cerebral perfusion. *Ann Thorac Surg* 2000;70:3-9.
2. Kazui T, Washiyama N, Bashar AHM, et al. Extended total arch replacement for acute type A aortic dissection: experience with seventy patients. *J Thorac Cardiovasc Surg* 2000;119:558-65.
3. Kazui T, Washiyama N, Bashar AHM, Terada H, Yamashita K, Takinami M. Improved results of atherosclerotic arch aneurysm operations with a refined technique. *J Thorac Cardiovasc Surg* 2001;121:491-9.
4. Kazui T, Yamashita K, Washiyama N, et al. Usefulness of antegrade selective cerebral perfusion during aortic arch operations. *Ann Thorac Surg* 2002;74:S1806-9.
5. Sakurada T, Kazui T, Tanaka H, Komatsu S. Comparative experimental study of cerebral protection during aortic arch reconstruction. *Ann Thorac Surg* 1996;61:1348-54.

# Effect of prophylactically administered edaravone during antegrade cerebral perfusion in a canine model of old cerebral infarction

Takayasu Suzuki, MD,<sup>a</sup> Teruhisa Kazui, MD, PhD,<sup>a</sup> Seiji Yamamoto, MD, PhD,<sup>b</sup> Naoki Washiyama, MD, PhD,<sup>a</sup> Kazuhiro Ohkura, MD, PhD,<sup>a</sup> Kentaro Ohishi, PhD,<sup>b</sup> Abul Hasan Muhammad Bashar, MBBS, PhD,<sup>a</sup> Katsushi Yamashita, MD, PhD,<sup>a</sup> Hitoshi Terada, MD, PhD,<sup>a</sup> Kazuchika Suzuki, MD, PhD,<sup>a</sup> Satoshi Akuzawa, MD,<sup>a</sup> and Michio Fujie, MS<sup>c</sup>

**Objective:** Reactive free radical species are thought to be involved in postoperative neurologic dysfunction after antegrade selective cerebral perfusion in brains with old infarction. We assessed the brain protective effect of prophylactically administered edaravone, a free radical scavenger, for antegrade selective cerebral perfusion in brains with or without old infarction in a canine model.

**Methods:** A canine model of old cerebral infarction was created by injecting cylindrical silicone embolus into the middle cerebral artery. Animals showing obvious neurologic deficits and surviving 4 weeks or longer were included in the model. Deep hypothermia with antegrade selective cerebral perfusion was performed in both intact (non-edaravone, group A; edaravone-treated, group B) and infarcted animals (non-edaravone, group C; edaravone-treated, group D). Serum concentrations of malondialdehyde, hexanoyl-lysine, glutamate, and venous-arterial lactate difference were measured, and central conduction time and amplitude of somatosensory evoked potentials were assessed during the operation.

**Results:** Compared with the intact groups, serum concentrations of malondialdehyde and hexanoyl-lysine in group C significantly increased at the end of antegrade selective cerebral perfusion, whereas that of glutamate did so in the rewarming phase. Increases in all these biochemical parameters were suppressed in group D. In group C, the venous-arterial lactate difference was significantly greater in the rewarming phase at 28°C compared with intact groups. A significant prolongation of postoperative central conduction time and decrease in neuronal activity were detected in group C, both of which recovered in group D.

**Conclusion:** Prophylactic administration of edaravone exerted a significant protective effect against postoperative neurologic dysfunction after antegrade selective cerebral perfusion in a canine model with old cerebral infarction.

From the First Department of Surgery,<sup>a</sup> Photon Medical Research Center,<sup>b</sup> and Research Equipment Center,<sup>c</sup> Hamamatsu University School of Medicine, Hamamatsu, Japan.

Received for publication Aug 10, 2006; revisions received Oct 9, 2006; accepted for publication Oct 30, 2006.

Address for reprints: Takayasu Suzuki, MD, The First Department of Surgery, Hamamatsu University School of Medicine, 1-20-1 Handayama, Hamamatsu, 431-3192, Japan (E-mail: tac.sz@hama-med.ac.jp).

J Thorac Cardiovasc Surg 2007;133:710-6  
0022-5223/\$32.00

Copyright © 2007 by The American Association for Thoracic Surgery

doi:10.1016/j.jtcvs.2006.10.032

Postoperative neurologic dysfunction is one of the most serious complications after aortic arch operation. The incidence of this complication has decreased in recent times because of improvements in operative techniques and cerebral protection methods.<sup>1</sup> Antegrade selective cerebral perfusion (ASCP) has been found to be the safest method of brain protection during aortic arch surgery with respect to energy metabolism and time limitation.<sup>2,3</sup> Clinical practice has indicated that ASCP can reduce cerebral injury during aortic arch operation more effectively compared with other methods for cerebral protection, including deep hypothermic circulatory arrest with or without retrograde cerebral perfusion.<sup>4</sup> Although our total arch replacement assisted with ASCP has resulted in a lower rate of mortality and morbidity,<sup>5</sup> a multivariable analysis of 220 patients revealed that a history of

**Abbreviations and Acronyms**

ASCP	= antegrade selective cerebral perfusion
CCT	= central conduction time
CPB	= cardiopulmonary bypass
HEL	= hexanoyl-lysine
MDA	= malondialdehyde
VALD	= venous-arterial lactate difference

cerebral infarction should be regarded as an independent predictor of postoperative neurologic dysfunction.<sup>6</sup>

Our previous canine studies showed that ASCP in animals with old cerebral infarction induced ischemic neurologic damage and that it increased the production of free radicals, suggesting oxidative damage in the peri-infarct region of the brain.<sup>7,8</sup> Many previous reports described accelerated production of free radicals in acute cerebral infarction resulting in neurologic damage, and free radical scavenger has already been found to be effective in attenuating such neurologic damage in clinical situations.<sup>9,10</sup> Similarly, a recent experimental study from our laboratory documented that edaravone (Mitsubishi Pharma Co, Tokyo, Japan), a commercially available free radical scavenger, was effective in attenuating acute ischemic neurologic damage in the rabbit spinal cord.<sup>11</sup> However, the exact relationship between free radicals and old cerebral infarction is unknown. A pharmacologic agent with a similar protective effect on brains with old cerebral infarct can be of great clinical relevance during an aortic arch operation with ASCP. Therefore, in the present study, we assessed the neuroprotective effect of prophylactically administered edaravone for ASCP in brains with or without old cerebral infarction in a canine model.

**Materials and Methods**

The study was approved by the Animal Care and Use Committee of Hamamatsu University School of Medicine. All animals received human care in compliance with the "Guide for the Care and Use of Laboratory Animals," published by the National Institutes of Health (NIH publication 85-23, revised 1985), and the "Guidelines for Animal Experimentation," formulated by Hamamatsu University School of Medicine (published 1987, revised 1991).

**Cerebral Infarct Model**

Our technique of creating a cerebral infarct model has been described.<sup>7</sup> In short, the left common carotid artery with its bifurcation was surgically exposed, and a cylindrical silicone embolus was injected into the left internal carotid artery. Nonvisualization of the left middle cerebral artery in the subsequent angiogram suggested that the embolus was located in the proximal left middle cerebral artery. Twelve hours later, the dogs were evaluated with a neurologic scoring system consisting of 5 grades (score 0: no neurologic deficit; score 1: walks with limp or circles to the side of lesion; score 2: walks poorly and stands but cannot support the body with

a left limb held off the ground; score 3: cannot stand without support; and score 4: dead).<sup>12</sup> Only the dogs with neurologic scores of 2 and 3, and surviving 4 weeks or longer were included in the cerebral infarct model.

**Animal Preparation**

After general anesthesia with an intravenous injection of pentobarbital sodium (30 mg/kg), mechanical ventilation was started. A 19-gauge detaining needle was inserted into the right brachial artery for blood sampling and blood pressure monitoring. A 4F catheter was placed into the right maxillary vein for sampling of venous blood for blood gas analysis and lactate measurement. An additional dose of pentobarbital sodium (15 mg/kg) was given before the beginning of rewarming.

**Cardiopulmonary Bypass**

After median sternotomy and full heparinization (300 U/kg), cardiopulmonary bypass (CPB) was instituted by inserting the arterial cannula into the ascending aorta, and the venous cannulae into the superior and inferior vena cavae. The perfusion system, consisting of a roller pump and membrane oxygenator (Senkoika Corp, Tokyo, Japan), was primed with lactated Ringer solution. A second dose of heparin (150 U/kg) was added before the beginning of rewarming. Alpha-stat strategy was used for blood pH management.

**Measurement of Somatosensory Evoked Potentials**

Single-channel recordings were obtained on a Nicolet Compact Four/CA 2000 (Nicolet JAPAN Corp, Tokyo, Japan). Three needle electrodes were positioned: the first over the head approximately 2 cm dorsal to the coronal suture, the second in the upper right-hand side of the sternum, and the third (the reference electrode) on the right shoulder. The median nerve of the right forelimb was exposed and stimulated with a bipolar stimulator. The pulse duration used was 100 msec, and the strength of the stimulating current was 2 to 5 mA with a frequency of 5.1 Hz. A total of 300 responses were obtained and averaged with automatic artifact rejection by setting the filter between approximately 5 and 1000 Hz. The central conduction time (CCT), indicating the transmission time of neuronal activity in the brain, was measured as an interpeak latency of N2 (the second negative wave) and N4 (the fourth negative wave). The amplitude ratio between N4 and N1 (the first negative wave), an indicator of neuronal activity in the sensory cortex, was calculated. The preoperative and postoperative values were compared.

**Experimental Protocol**

Twenty-four female mongrel dogs were divided into the following 4 groups: group A, intact, non-edaravone group (n = 6); group B, intact, edaravone-treated group (n = 6); group C, infarct, non-edaravone group (n = 6); and group D, infarct, edaravone-treated group (n = 6). Animals of all 4 groups underwent deep hypothermia with ASCP. CPB flow was maintained at approximately 50 to 80 mL/kg/min in accordance with the amount of venous return. After the animals were cooled to a rectal temperature of 20°C, ASCP was initiated at a flow rate of 10 mL/kg/min by clamping the proximal ascending aorta, the left subclavian artery, and the descending aorta. The lower half of the body was not perfused

during ASCP. After 120 minutes of ASCP, CPB was returned to its original flow rate. Then, rewarming to a rectal temperature of 36°C was performed. Differences between the rectal and arterial temperatures were always kept within 5°C in both cooling and rewarming phases.

### Drug Delivery Protocol

In the edaravone-treated groups, first, edaravone 1.5 mg/kg in 100 mL normal saline solution was dripped into the extracorporeal circuit just before the beginning of cooling. Because it takes approximately 30 minutes to obtain a steady plasma level of edaravone after its intravenous injection, we made sure that the first dose of edaravone was completed 30 minutes before the initiation of ASCP.<sup>13</sup> To ensure a stable plasma level of the drug until the end of the experiment, a second dose of edaravone (1.5 mg/kg) was added to the circuit in the same method 30 minutes after the first. For the non-edaravone group, only 100 mL of normal saline solution without edaravone was administered into the circuit at the same time points.

### Protocol for Blood Biochemistry

Blood samples were obtained on the following 8 occasions: (1) before the operation; (2) 5 minutes after the initiation of CPB; (3) on reaching a rectal temperature of 28°C in the cooling phase; (4) on reaching a rectal temperature of 20°C in the cooling phase; (5) 60 minutes after the initiation of ASCP; (6) at the end of ASCP; (7) on reaching a rectal temperature of 28°C in the rewarming phase; and (8) on reaching a rectal temperature of 36°C in the rewarming phase. Sampled blood was centrifuged, and protein was extracted from the serum. Malondialdehyde (MDA), a marker of free radical production and lipid peroxidation of membrane polyunsaturated fatty acid, was measured by means of thiobarbituric acid fluorescence (FP-777; Nihon Bunko, Tokyo, Japan).<sup>14,15</sup> Hexanoyl-lysine (HEL) formed by the reaction between linoleic acid hydroperoxide and lysine is another biomarker of oxidative stress, which was measured by the enzyme-linked immunosorbent assay method using the HEL adduct enzyme-linked immunosorbent assay kit (Japan Institute for the Control of Aging, Shizuoka, Japan).<sup>16,17</sup> Serum glutamate, a biomarker of neural cell damage, was measured on a column packed with reverse-phase support with a special device (PICO-TAG; Waters Corp, Milford, Mass). Blood lactate was measured using a blood gas analyzer (Stat Profile Ultra M; Nova Biomedical Corp, Tokyo, Japan), and the venous-arterial lactate difference (VALD) was calculated.

### Statistical Analysis

All values are expressed as means  $\pm$  standard error. One-way analysis of variance was used for comparison among the groups. When the 1-way analysis of variance showed a significant difference ( $P < .05$ ), we compared the 2 groups by using the Tukey honestly significant difference test.

### Results

Important preoperative and intraoperative data are shown in Table 1. There were no significant differences in the preoperative physiologic variables and the intraoperative data among the groups.

### Blood Biochemistry

The preoperative biochemical parameters did not show any significant differences among the groups. Serum concentration of MDA in group C was significantly higher than that in the intact groups (groups A and B) at the end of ASCP ( $P = .012$ ). In addition, the level was significantly higher in comparison with that in groups A and B, as well as that in group D in the rewarming phase ( $P = .047$  at 28°C;  $P = .003$  at 36°C) (Figure 1). In group C, the serum concentration of HEL became significantly higher compared with that in groups A and B, and group D at the end of ASCP, with the differences continuing to widen until the end of the experiment ( $P = .005$  at the end of ASCP;  $P = .0013$  at 28°C;  $P = .0001$  at 36°C) (Figure 2). Serum concentrations of glutamate in group C were significantly higher in comparison with groups A and B, and group D during the rewarming phase ( $P = .001$  at 28°C,  $P = .0006$  at 36°C) (Figure 3). In group C, VALD was significantly greater than that in the intact groups at 28°C in the rewarming phase ( $P = .0082$ ), although the difference was not significant when compared with group D (Figure 4). However, the 2 intact groups did not differ significantly with regard to the above parameters. Likewise, values in group D were not significantly different when compared with those in the intact groups.

### Somatosensory Evoked Potentials

The preoperative CCT and N4/N1 amplitude ratio did not show any difference among the groups. In group C, the postoperative CCT was significantly prolonged compared with that in the intact groups (A and B) and group D (group A, 109%  $\pm$  3.6%; group B, 98.7%  $\pm$  4.1%; group C, 195.6%  $\pm$  25.7%; group D, 142.3%  $\pm$  5.4%;  $P = .0002$ ) (Figure 5). Moreover, in group C, the postoperative N4/N1 amplitude ratio decreased significantly compared with that in the intact groups and group D (group A, 90.2%  $\pm$  7.1%; group B, 101%  $\pm$  7.1%; group C, 30.8%  $\pm$  8.1%; group D, 60.9%  $\pm$  5.3%;  $P < .0001$ ). No significant differences were noted between the 2 intact groups with regard to the postoperative CCT and N4/N1 amplitude ratio. Values in group D were also not significantly different compared with those in the intact groups.

### Discussion

In brains with old infarction, ischemia can occur in the peri-infarct area, where the baseline blood flow is low. Such regions are known as chronic penumbra, which are nourished by collateral blood flow.<sup>18</sup> In the present study, we maintained a cerebral perfusion flow of 10 mL/kg per minute (perfusion pressure 40–50 mm Hg) during ASCP, which is consistent with our clinical practice. This perfusion flow is adequate for normal brains because they have a wider safety margin for cerebral ischemia.<sup>19</sup> However, the

TABLE 1. Preoperative and intraoperative data

	Intact group		Infarct group		P value*
	Group A (non-edaravone)	Group B (edaravone-treated)	Group C (non-edaravone)	Group D (edaravone-treated)	
Age (mo)	13.3 ± 0.7	13.7 ± 1.0	15.2 ± 0.6	15.8 ± 0.5	.06
Body weight (kg)	13.8 ± 0.7	13.1 ± 0.9	13.9 ± 0.8	13.6 ± 1.7	.90
Duration after CI (mo)	—	—	3.5 ± 0.4	4.0 ± 0.3	.26
Preoperative Ht (%)	35.5 ± 1.3	33.8 ± 1.2	36.5 ± 1.9	34.3 ± 1.3	.57
MAP (mm Hg)					
Preoperative	135.3 ± 9.3	127.5 ± 3.8	134.3 ± 3.6	129.5 ± 8.5	.82
On CPB	76.2 ± 4.7	74.5 ± 3.3	77.2 ± 4.2	75.8 ± 2.4	.97
Cooling 28°C	66.5 ± 3.9	65.2 ± 3.4	66.8 ± 4.3	62.3 ± 4.5	.86
Cooling 20°C	59.5 ± 2.7	56.5 ± 2.9	60.2 ± 2.8	59.7 ± 4.0	.84
ASCP 60 min	43.5 ± 2.3	42.3 ± 2.0	43.0 ± 4.6	44.2 ± 3.3	.98
End of ASCP	49.0 ± 5.1	46.0 ± 3.4	45.8 ± 3.8	43.2 ± 2.8	.77
Rewarming 28°C	75.3 ± 6.0	74.8 ± 5.2	75.0 ± 6.7	69.5 ± 3.2	.85
Rewarming 36°C	78.2 ± 3.8	73.3 ± 2.6	74.8 ± 5.7	72.2 ± 4.6	.78
Pao <sub>2</sub> (mm Hg)					
Preoperative	106.5 ± 7.5	104.1 ± 7.2	115.8 ± 36.2	103.5 ± 11.8	.84
On CPB	272.3 ± 72.4	161.9 ± 20.8	214.6 ± 50.4	248.3 ± 66.2	.55
Cooling 28°C	347.4 ± 64.1	396.9 ± 53.8	469.1 ± 61.4	467.0 ± 49.6	.39
Cooling 20°C	735.2 ± 31.2	655.6 ± 21.0	562.9 ± 77.5	679.7 ± 66.7	.19
ASCP 60 min	683.1 ± 61.9	754.7 ± 60.1	792.2 ± 32.8	797.1 ± 25.4	.33
End of ASCP	729.7 ± 32.7	766.7 ± 7.6	688.0 ± 28.7	718.3 ± 40.5	.34
Rewarming 28°C	446.8 ± 41.1	454.8 ± 72.1	498.6 ± 23.4	466.5 ± 21.5	.85
Rewarming 36°C	200.1 ± 53.2	151.3 ± 22.4	203.8 ± 73.9	145.4 ± 28.7	.75
Paco <sub>2</sub> (mm Hg)					
Preoperative	29.2 ± 3.6	33.1 ± 6.5	26.8 ± 4.9	36.0 ± 8.2	.72
On CPB	30.5 ± 2.7	32.4 ± 1.4	35.8 ± 1.3	29.4 ± 1.4	.10
Cooling 28°C	37.2 ± 5.2	41.5 ± 1.5	37.3 ± 1.4	36.4 ± 1.7	.61
Cooling 20°C	35.7 ± 5.3	41.5 ± 2.0	36.5 ± 0.9	36.7 ± 1.6	.46
ASCP 60 min	26.5 ± 2.1	30.9 ± 2.0	34.0 ± 0.8	31.3 ± 2.9	.13
End of ASCP	27.1 ± 1.5	31.9 ± 0.6	32.0 ± 1.5	29.1 ± 2.5	.14
Rewarming 28°C	31.2 ± 3.9	28.1 ± 0.7	28.8 ± 2.9	27.0 ± 0.7	.67
Rewarming 36°C	30.8 ± 4.2	30.5 ± 0.4	29.0 ± 2.4	27.8 ± 2.2	.85
Arterial pH					
Preoperative	7.44 ± 0.02	7.43 ± 0.03	7.46 ± 0.02	7.42 ± 0.01	.48
On CPB	7.38 ± 0.03	7.37 ± 0.02	7.39 ± 0.03	7.37 ± 0.02	.87
Cooling 28°C	7.35 ± 0.03	7.36 ± 0.03	7.34 ± 0.04	7.34 ± 0.02	.95
Cooling 20°C	7.37 ± 0.03	7.37 ± 0.01	7.35 ± 0.04	7.34 ± 0.01	.91
ASCP 60 min	7.37 ± 0.02	7.36 ± 0.02	7.35 ± 0.03	7.35 ± 0.02	.90
End of ASCP	7.36 ± 0.02	7.37 ± 0.01	7.36 ± 0.03	7.37 ± 0.02	.98
Rewarming 28°C	7.36 ± 0.02	7.34 ± 0.01	7.34 ± 0.03	7.36 ± 0.02	.95
Rewarming 36°C	7.37 ± 0.02	7.33 ± 0.02	7.35 ± 0.02	7.36 ± 0.03	.88
Time required (min)					
Cooling	58.2 ± 3.5	54.8 ± 3.8	56.7 ± 2.1	58.6 ± 4.0	.86
Rewarming	75.6 ± 5.3	72.8 ± 3.2	72.7 ± 3.8	75.7 ± 5.7	.94

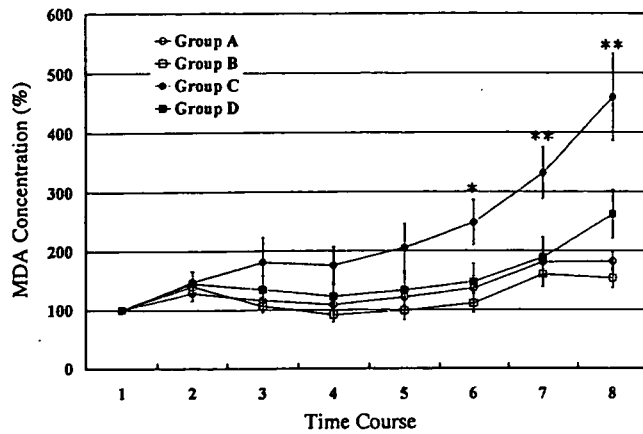
CI, Cerebral infarction; Ht, hematocrit; MAP, mean artery pressure; CPB, cardiopulmonary bypass; ASCP, antegrade selective cerebral perfusion. \*One-way analysis of variance.

flow may not be adequate for the chronic penumbra region. Ning and colleagues<sup>20</sup> reported an accelerated free radical production in the peri-infarct region after transient focal ischemia in mice brain. Thus, it seems that brain ischemia and the consequent free radical production in the chronic

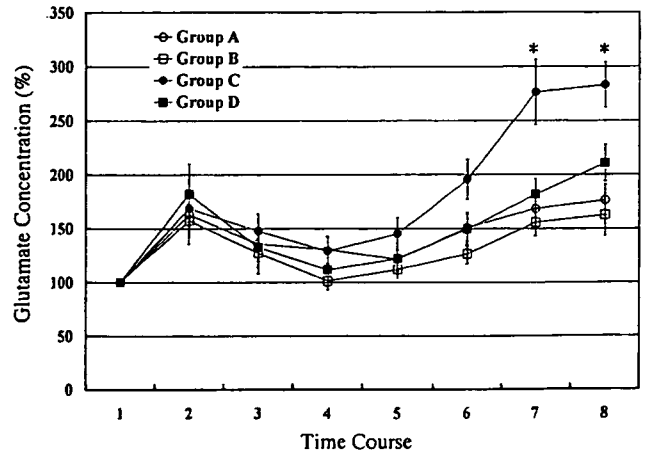
penumbra region cause neurologic dysfunction after ASCP for brain with old infarction.

It is thought that hypothermic ASCP itself can also give rise to cerebral ischemia, particularly in a setting of old cerebral infarction. The cold perfusion of ASCP may cause





**Figure 1.** Changes in serum MDA concentration. Values at different time points are expressed as percentages of the preoperative value (see text). In group C, values significantly increased at time points 6 to 8 (\*group C vs groups A and B,  $P < .05$ ; \*\*group C vs groups A, B, and D,  $P < .05$ ). MDA, Malondialdehyde.

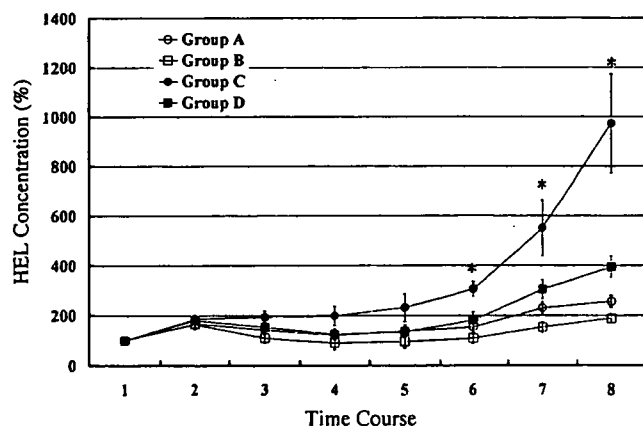


**Figure 3.** Changes in serum glutamate concentration. Values at different time points are expressed as percentages of the preoperative value (see text). In group C, values significantly increased compared with that in all other groups during the rewarming phase (\*group C vs groups A, B, and D,  $P < .001$ ).

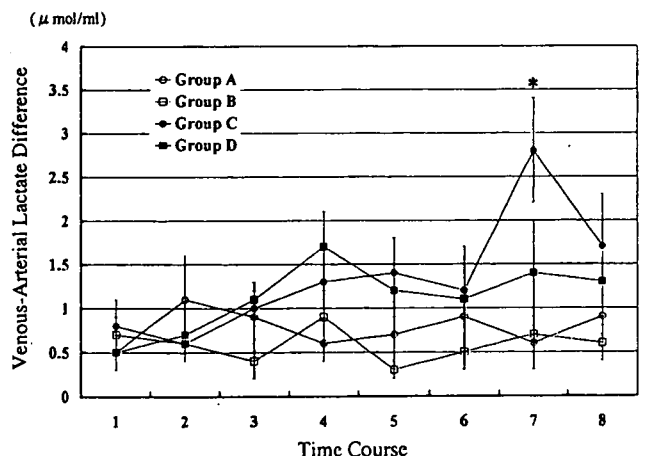
the loss of cerebral autoregulation,<sup>21</sup> which may result in cerebral vasoconstriction. This, in turn, may lead to a global reduction in cerebral blood flow. Moreover, phenomena such as low flow-induced astrocyte edema<sup>22</sup> and cerebral vasospasm may also contribute to a further reduction in cerebral blood flow, particularly at the penumbral region.

Brain ischemia initiates a complex cascade of metabolic events, several of which involve the generation of nitrogen and oxygen free radicals. These free radicals and related reactive chemical species mediate much of the damage that occurs after transient brain ischemia and in the penumbral region of infarcts caused by permanent ischemia.<sup>23</sup> Free

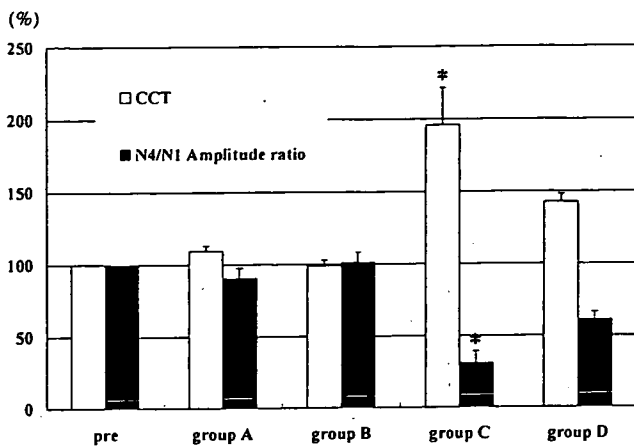
radical species lead to oxidation of lipids, protein, and nucleic acid, which might alter cellular function in a critical way, resulting in neurologic injury and subsequent neurologic dysfunction.<sup>24,25</sup> Aldehydes, such as MDA and 4-hydroxy-2-nonenal, have been well-known products of lipid peroxidation.<sup>14,26</sup> HEL is a novel lipid hydroperoxide-modified lysine residue formed in the earlier stage of lipid peroxidation by oxidative modification of linoleic acid or arachidonic acid.<sup>16,17</sup> To our knowledge, it has not been previously used as a marker of free radical production in a cerebral infarction model. Be-



**Figure 2.** Changes in serum HEL concentration. Values at different time points are expressed as percentages of the preoperative value (see text). In group C, values significantly increased compared with that in all other groups at points 6 to 8 (\*group C vs groups A, B, and D,  $P < .001$ ). HEL, Hexanoyl-lysine.



**Figure 4.** Level of VALD. Values are shown at different time points (see text). In group C, VALD was significantly greater than that in the intact groups at 28°C in the rewarming phase (\*group C vs groups A and B,  $P < .001$ ). VALD, Venous-arterial lactate difference.



**Figure 5.** Changes in CCT and N4/N1 amplitude ratio. Values are expressed as percentages of the preoperative values (see text). In group C, postoperative CCT was significantly prolonged compared with that in all other groups. The postoperative N4/N1 amplitude ratio in group C decreased significantly compared with that in all other groups (\*group C vs groups A, B, and D,  $P < .0001$ ). CCT, Central conduction time.

cause brain is a fat-rich tissue, we believe that HEL can be a reliable biochemical marker of free radical production induced by ischemic brain injury.

In the present study, the animals in group C (the cerebral infarct group) showed a remarkable increase in serum HEL and MDA at the end of ASCP. These findings suggested that ASCP induced ischemia in brains with old cerebral infarction, which resulted in accelerated free radical production. Moreover, in group C, we observed a prolongation of CCT and a decrease in the N4/N1 amplitude ratio, whereas none of these changes were seen in the intact animals. Previous studies demonstrated that impaired somatosensory evoked potential was associated with cerebral injury in permanent ischemic models.<sup>27,28</sup> Our findings were consistent with the above findings in the sense that we also found brains with old infarction showing functional impairment with acceleration of free radical production caused by ischemia during ASCP, whereas the intact brain showed no such evidence of ischemic damage.

The animals in group D (the edaravone-treated infarct group) showed a reduction in the level of serum MDA and HEL concentrations compared with those in the non-edaravone-treated infarct animals. A decrease in postoperative CCT prolongation and the recovery of postoperative N4/N1 amplitude ratio were also noted in group D, suggesting that free radical scavenging was effective in reducing neurologic dysfunction after ASCP in brains with old infarction. Although the cerebral protective effect of edaravone in acute cerebral ischemia is well described,<sup>9,10,22</sup> to our knowledge, this is the first report

demonstrating the neuroprotective effect of edaravone during CPB for permanent cerebral infarction.

In our study, increasing free radical production was found from the point of ASCP termination until the end of the experiment in group C. Serum glutamate also showed a parallel increase during the rewarming phase in this group. In the rewarming phase, VALD also became greater in group C, perhaps indicating an acceleration of anaerobic glycolysis in the brain tissue.<sup>29</sup> These findings may be explained by neural cell damage being worsened by accelerated free radical production and increased cellular metabolism. It is important to note that the serum concentration of glutamate decreased in the edaravone-treated infarct group (group D) in this study. This suggests that edaravone attenuated ischemic and free radical-mediated neural cell damage and by doing so, reduced neurologic dysfunction that was documented by the results of somatosensory evoked potential examination in group D. From the above results, it is evident that in brains with old infarction, free radical scavenging provides an effective way to attenuate functional and metabolic damage to neural cells within the chronic penumbra region in the rewarming phase after ASCP.

However, the present study has a number of important limitations. Although it can be assumed from the biochemical assessment performed in the present study that brain ischemia causes free radical production in the chronic penumbra region, the actual regional cerebral blood flow during ASCP was not measured. Thus, the relationship between ischemia and free radical-mediated neurologic injury is not directly evident. Transcranial Doppler sonography or near-infrared spectroscopy may be used to measure regional cerebral blood flow.<sup>30</sup> Moreover, we could not perform brain histopathology to document ischemia-induced tissue damage in a graded manner.

## Conclusions

We examined the influences of prophylactic administration of edaravone, a free radical scavenger, on brains with or without old cerebral infarction in dogs undergoing ASCP. Cerebral ischemia occurred during experimental ASCP resulting in postoperative neurologic dysfunction, which was attenuated by prophylactic administration of edaravone. It is therefore expected that prophylactic administration of edaravone could be useful for brain protection in ASCP for high-risk patients with a history of cerebral infarction.

## References

- Di Eusanio M, Schepens MAAM, Morshuis WJ, Di Bartolomeo R, Pierangeli A, Dossche KM. Antegrade selective cerebral perfusion during operations on the thoracic aorta: factors influencing survival and neurologic outcome in 413 patients. *J Thorac Cardiovasc Surg.* 2002;124:1080-6.
- Swain JA, McDonald TJ, Griffith PK, Balaban RS, Clark RE, Ceckler T. Low-flow hypothermic CPB protects the brain. *J Thorac Cardiovasc Surg.* 1991;102:76-84.

3. Sukurada T, Kazui T, Tanaka H, Komatsu S. Comparative experimental study of cerebral protection during aortic arch reconstruction. *Ann Thorac Surg.* 1996;61:1348-54.
4. Hagl C, Ergin MA, Galla JD, Lansman SL, McCullough JN, Spielvogel D, et al. Neurologic outcome after ascending aorta-aortic arch operations: effect of brain protection technique in high risk patients. *J Thorac Cardiovasc Surg.* 2001;121:1107-21.
5. Kazui T, Washiyama N, Muhammad BAH, Terada H, Yamashita K, Takinami M. Improved results of atherosclerotic arch aneurysm operations with a refined technique. *J Thorac Cardiovasc Surg.* 2001;121:491-9.
6. Kazui T, Washiyama N, Bashar ABH, Terada H, Yamashita K, Takinami M, et al. Total arch replacement using aortic arch branched grafts with the aid of antegrade selective cerebral perfusion. *Ann Thorac Surg.* 2000;70:3-9.
7. Washiyama N, Kazui T, Takinami M, Yamashita K, Fujita S, Terada H, et al. Experimental study on the effect of antegrade cerebral perfusion on brains with old cerebral infarction. *J Thorac Cardiovasc Surg.* 2001;122:734-40.
8. Ohkura K, Kazui T, Yamamoto S, Yamashita K, Tarada H, Washiyama N, et al. Comparison of pH management during antegrade selective cerebral perfusion in canine models with old cerebral infarction. *J Thorac Cardiovasc Surg.* 2004;128:378-85.
9. Mizuno A, Umemura K, Nakashima M. Inhibitory effects of MCI-186, free radical scavenger, on cerebral ischemia following rat middle cerebral artery occlusion. *Gen Pharmacol.* 1998;30:575-8.
10. Edaravone Acute Infarction Study Group. Effect of a novel free radical scavenger, edaravone (MCI-186), on acute brain infarction. Randomized, placebo-controlled, double-blind study at multicenters. *Cerebrovasc Dis.* 2003;15:222-9.
11. Kazuchika S, Kazui T, Terada H, Umemura K, Ikeda Y, Bashar ABH, et al. Experimental study on the protective effects of edaravone against ischemic spinal cord injury. *J Thorac Cardiovasc Surg.* 2005;130:1586-92.
12. Smith AL, Hoff JT, Nielsen SL, Larson CP. Barbiturate protection in acute focal cerebral ischemia. *Stroke.* 1974;5:1-7.
13. Takamatsu Y, Watanabe T. Studies on the concentrations of 3-methyl-1-phenyl-2-pyrazolin-5-one (MCI-186) in dog plasma and cerebral spinal fluid. *Jpn Pharmacol Ther.* 1997;25(suppl):S1785-91.
14. Lantos J, Temes G, Roth R, Morvay G. Alterations in malondialdehyde concentration of jugular vein blood following transient brain ischemia: the effect of lactic acidosis. *Acta Physiol Hung.* 1994;82:229-36.
15. Ohkawa H, Ohnishi N, Yagi K. Assay for lipid peroxides in animal tissues by thiobarbituric reaction. *Anal Biochem.* 1979;95:351-8.
16. Kato Y, Mori Y, Makino Y, Morimatsu Y, Hiroi S, Ishikawa T, et al. Formation of Nε-(hexanonyl)lysine in protein exposed to lipid hydroperoxide. *J Biol Chem.* 1999;274:20406-14.
17. Kato Y, Osawa T. Detection of lipid hydroperoxide-derived modification with polyclonal antibodies. *Methods Mol Biol.* 2002;186:37-44.
18. Paulson OB. Regional cerebral blood flow in apoplexy due to occlusion of the middle cerebral artery. *Neurology.* 1970;20:63-77.
19. Tanaka H, Kazui T, Sato H, Inoue N, Yamada O, Komatsu S. Experimental study on the optimum flow rate and pressure for selective cerebral perfusion. *Ann Thorac Surg.* 1995;59:651-7.
20. Zhang N, Komine-Kobayashi M, Tanaka R, Liu M, Mizuno Y, Urabe T. Edaravone reduces early accumulation of oxidative products and sequential inflammatory responses after transient focal ischemia in mice brain. *Stroke.* 2005;36:2220-5.
21. Watanabe T, Oshikiri N, Inui K, Kuraoka S, Minowa T, Hosaka J, et al. Optimal blood flow for cooled brain at 20°C. *Ann Thorac Surg.* 1999;68:864-9.
22. Swanson RA, Ying W, Kauppinen TM. Astrocyte influence on ischemic neuronal death. *Curr Mol Med.* 2004;4:193-205.
23. Love S. Oxidative stress in brain ischemia. *Brain Pathol.* 1999;9:119-31.
24. Lewen A, Matz P, Cfan PH. Free radical pathways in CNS injury. *J Neurotrauma.* 2000;17:871-90.
25. Floyd RA, Carney JM. Free radical damage to protein and DNA: mechanism involved and relevant observations on brain undergoing oxidative stress. *Ann Neurol.* 1992;32(suppl):S22-7.
26. Toshino H, Hattori N, Urabe T, Uchida K, Tanaka M, Mizuno Y. Postischemic accumulation of lipid peroxidation products in the rat brain: immunohistochemical detection of 4-hydroxy-2-nonenal modified proteins. *Brain Res.* 1997;767:81-6.
27. Meyer KL, Dempsey RJ, Roy MW, Donaldson DL. Somatosensory evoked potentials as a measure of experimental cerebral ischemia. *J Neurosurg.* 1985;62:269-75.
28. Skeigh JW, Havill JH, Frith R, Kersel D, Marsh N, Ulyatt D. Somatosensory evoked potentials in severe traumatic brain injury: a blinded study. *J Neurosurg.* 1999;91:577-80.
29. Michenfelder JD, Middle JH. The relationship among canine brain temperature, metabolism, and function during hypothermia. *Anesthesiology.* 1991;75:130-6.
30. Yamashita K, Kazui T, Tarada H, Washiyama N, Suzuki K, Bashar AH. Cerebral oxygenation monitoring for total arch replacement using selective cerebral perfusion. *Ann Thorac Surg.* 2001;72:503-8.

# Total Aortic Arch Replacement in Patients With Arch Vessel Anomalies

Kazuchika Suzuki, MD, PhD, Teruhisa Kazui, MD, PhD,  
Abul Hasan Muhammad Bashar, MBBS, PhD, Katsushi Yamashita, MD, PhD,  
Hitoshi Terada, MD, PhD, Naoki Washiyama, MD, PhD, and Takayasu Suzuki, MD

First Department of Surgery, Hamamatsu University School of Medicine, Hamamatsu, Japan

**Background.** The presence of anomalous arch vessels has considerable impact on aortic arch reconstruction techniques and cerebral protection methods when the separated graft technique is adopted to perform total arch replacement. We analyzed our experience of total arch replacement in patients with arch vessel anomalies.

**Methods.** Among the 220 patients undergoing total arch replacement at our institution, 21 patients (9.5%) had various arch vessel anomalies. Common brachiocephalic trunk was found in 8 patients (3.6%); an isolated left vertebral artery in 9 (4.1%); aberrant right subclavian artery in 3 (1.4%); and coexistent common brachiocephalic trunk and isolated left vertebral artery in 1 (0.5%). In 4 of the 9 patients with isolated left vertebral artery, preoperative diagnosis was possible with magnetic resonance angiography or three-dimensional computed tomography. In cases with common brachiocephalic trunk, total arch replacement could be performed with the usual techniques after separating the innominate and left com-

mon carotid arteries from each other. The isolated left vertebral artery was anastomosed to the left subclavian artery graft in 7 patients and to the native left subclavian artery in 2. In the aberrant right subclavian artery variety, a distal aortic anastomosis was performed distal to the orifice of this anomalous artery. The aberrant vessel was reconstructed on the right side of the trachea and esophagus.

**Results.** There was no early or in-hospital mortality. No neurologic complication attributable to the arch vessel anomalies was found.

**Conclusions.** A precise preoperative diagnosis is very important for the selection of an appropriate surgical strategy in patients with arch vessel anomalies. Magnetic resonance angiography and three-dimensional computed tomography may be useful diagnostic tools in these patients.

(Ann Thorac Surg 2006;81:2079–83)

© 2006 by The Society of Thoracic Surgeons

According to available data, the incidence of various types of arch vessel anomalies is about 17% among the general population in Japan [1]. Among the American population, the incidence is reported to be as high as 34% [2]. Although it is rare for the anomalous arch vessels to cause symptoms that are severe enough to necessitate surgical intervention, their presence influences the total arch replacement (TAR) operations to a significant extent. This is particularly true when the TAR is carried out using the separated graft technique, which otherwise offers a number of advantages over the en-bloc repair technique. With the separated graft technique, the arch vessel anastomoses can be performed at a site that is free from atherosclerotic plaques or dissection. Control of bleeding from the arch vessel anastomotic sites is also easier with the former technique. Although the difference between the two techniques is not always significant in terms of major outcome variables [3], we prefer the separated graft technique popularized by Kazui and colleagues [4] for its above-mentioned advantages. The usefulness of this technique is getting increasing recog-

nition as evident from the growing number of centers that now use the technique for TAR [5, 6]. With this technique, however, the presence of anomalous arch vessels often requires changes in the arch reconstruction technique as well as the cerebral protection methods. Although reports of TAR in patients having arch vessel anomalies are increasing [7–12], there is no literature summarizing the various aspects of TAR in such patients. In this study, we analyzed our experience with TAR in this specific group of patients to assess the difficulties encountered during surgery.

## Patients and Methods

The study was approved by the institutional review board of the Hamamatsu University School of Medicine. Informed written consent was also obtained from each individual patient. Between March 1997 and November 2005, 220 patients underwent TAR for atherosclerotic aneurysm or aortic dissection at our institution. Of them, a total of 21 patients (9.5%) had various arch vessel anomalies in the presence of a normal left aortic arch. A classification of the arch vessel anomalies is shown in Figure 1. Routine preoperative investigations in non-emergent cases included enhanced computed tomo-

Accepted for publication Dec 20, 2005.

Address correspondence to Dr K. Suzuki, The First Department of Surgery, Hamamatsu University School of Medicine, 1-20-1 Handayama, Hamamatsu, 431-3192, Japan; e-mail: kazuchi@fj9.so-net.ne.jp.

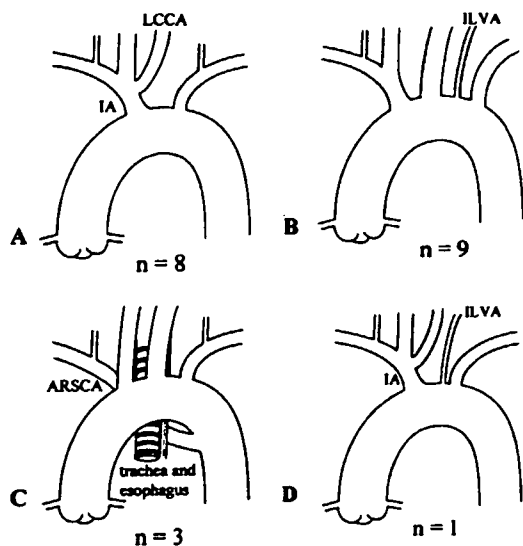


Fig 1. (A) Common brachiocephalic trunk (CBT); left common carotid artery (LCCA) and innominate artery (IA) originate from the common trunk. (B) Isolated left vertebral artery (ILVA); a left vertebral artery arising directly from the aortic arch. (C) Aberrant right subclavian artery (ARSCA); a right subclavian artery arising from the proximal descending aorta as the fourth aortic arch branch and passing behind the esophagus and trachea. (D) Coexistent common brachiocephalic trunk and isolated left vertebral artery.

graphic scan and digital subtraction angiography, whereas magnetic resonance angiography and three-dimensional computed tomographic scan were used only in the recent cases. Common brachiocephalic trunk (CBT), in which the left common carotid artery and the innominate artery originate from a common trunk (Fig 1A) was found in 8 patients (3.6%). Isolated left vertebral artery (ILVA), which is defined as a left vertebral artery taking off directly from the aortic arch (Figs 1B, 2), was present in 9 patients (4.1%). Although preoperative digital subtraction angiography was routinely performed, it could not give the conclusive diagnosis of the ILVA in any of the patients. In 4 of the 9 patients, the anomaly was diagnosed preoperatively: 3 with the help of magnetic resonance angiography and 1 with three-dimensional computed tomographic scan. Aberrant right subclavian artery (ARSCA), which is a right subclavian artery arising from the proximal descending aorta as the fourth aortic arch branch and passing behind the esophagus and trachea (Fig 1C), was found in 3 patients (1.4%). The remaining 1 patient (0.5%) who had both CBT and ILVA (Fig 1D) was included in the ILVA group. The patient characteristics in the three groups are shown in Table 1. There were no symptoms attributable to the arch vessel anomalies except in 1 patient with ARSCA, who complained of dysphagia.

All patients underwent TAR under moderately hypothermic circulatory arrest and with the aid of antegrade selective cerebral perfusion (SCP). The details of our cerebral protection and arch reconstruction techniques have been described elsewhere [13]. In brief, after median sternotomy, cardiopulmonary bypass was estab-

lished with the arterial inflow through the ascending aorta or right axillary artery and venous drainage from the right atrium. Systemic cooling was then started. When the rectal temperature reached 25°C, circulatory arrest was induced, and SCP was started through the innominate and the left common carotid arteries after cannulating the vessels with balloon-tipped catheters. The flow rate for SCP was 10 mL · kg<sup>-1</sup> · min<sup>-1</sup>. Then the distal aortic anastomosis was performed with a four-branched aortic arch graft (Hemashield, Meadox Medical, Oakland, NJ). After the completion of this anastomosis, the circulation was restarted with perfusion through the side branch of the graft. The reconstruction of left subclavian artery was performed next, and systemic rewarming was started. Then anastomoses of the proximal aorta, innominate artery, and left common carotid artery were performed in that order to complete the arch reconstruction. Electroencephalography is used as the intraoperative neurologic monitor on most occasions. Transcranial Doppler sonography, jugular venous oxygen saturation, and multichannel near-infrared spectroscopy are used to monitor the cerebral blood flow during antegrade SCP. The specific cerebral protection and arch reconstruction techniques required for each individual type of arch vessel anomaly are described below.

#### Common Brachiocephalic Trunk

First the innominate and the left common carotid arteries were separated from each other and were cannulated separately with balloon-tipped catheters for SCP. This ensured a cerebral protection and arch vessel reconstruction procedure that were, basically, similar to the TAR



Fig 2. Preoperative magnetic resonance angiogram showing the dominant isolated left vertebral artery (arrow).

Table 1. Patient Characteristics

Characteristic	CBT (n 8)		ILVA (n 10)		ARSCA (n 3)	
Age (y)	70.6	4.1	70.2	12.0	73.9	2.2
Male/female	4/3		3/7		1/2	
Cause						
Aortic aneurysm	7		8		1	
Chronic dissection	0		2		1	
ARSCA aneurysm	0		0		1	
Preoperative diagnosis	8 (100%)		4 (40%)		3 (100%)	

ARSCA aberrant right subclavian artery; CBT common brachiocephalic trunk; ILVA isolated left vertebral artery.

procedure without arch vessel anomaly. Therefore, this type of anomalous arch vessels did not pose any significant surgical challenge during TAR.

*Isolated Left Vertebral Artery*

In the cases in which this particular anomaly was discovered intraoperatively, the vessel was simply clamped until the reconstruction of the ILVA was completed. Selective cerebral perfusion with two-vessel perfusion through the innominate artery and left common carotid artery was first used. Then the ILVA reconstruction was performed, after which rewarming was started. In the two cases in which the existence of the ILVA was diagnosed preoperatively with magnetic resonance angiography, direct cannulation and perfusion of the ILVA with an 8F balloon-tipped catheter was undertaken. The ILVA was the dominant arch vessel in these patients and was wide enough for the insertion of the catheter (Fig 2). However, cannulation of the ILVA was not undertaken in the other 2 patients who also had preoperative diagnosis of this vessel because the ILVA in those patients was not the dominant arch vessel. The techniques of ILVA reconstruction are shown in Figure 3. In 7 patients (70%), a side-hole was made on the left subclavian artery graft, and the ILVA was anastomosed to that hole. In 2 patients (20%), a side-hole was made on the native left subclavian artery, to which the ILVA was anastomosed (Fig 3B). In 1 patient (10%), the ILVA was reconstructed with an en-bloc technique (Fig 3C).

*Aberrant Right Subclavian Artery*

Selective cerebral perfusion was established with three-vessel perfusion through the right common carotid artery, left common carotid artery, and left subclavian artery. The ARSCA, which originated as the fourth arch branch, was simply clamped. After the proximal descending aorta was circumferentially resected distal to the ARSCA orifice, a distal aortic anastomosis with a four-branched aortic arch graft was performed. The anastomoses of left subclavian artery and proximal aorta were performed next. The right subclavian artery was then exposed and resected on the right side of the trachea and esophagus, after which the right subclavian artery was anastomosed in an end-to-end fashion with another piece of 8-mm graft (Hemashield, Meadox Medical, Oakland, NJ). After completing this anastomosis, right subclavian artery perfusion was started through the graft. After reconstruction of the right common carotid artery and left common carotid artery was completed, the 8-mm graft of the right subclavian artery was anastomosed to the aortic graft as its most proximal branch (Fig 4).

**Results**

There were no early or in-hospital deaths in the 21 patients with arch vessel anomalies who underwent TAR. There were no permanent or temporary neurologic complications attributable to the arch vessel anomalies. The extracorporeal circulation data of the 19 patients are as

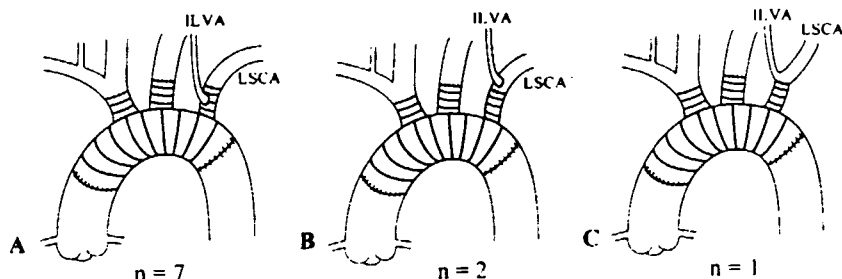


Fig 3. (A) The isolated left vertebral artery (ILVA) is anastomosed to the side-hole of the left subclavian artery (LSCA) graft. (B) The isolated left vertebral artery is anastomosed to the native left subclavian artery. (C) The isolated left vertebral artery and left subclavian artery are reconstructed with en-bloc technique.

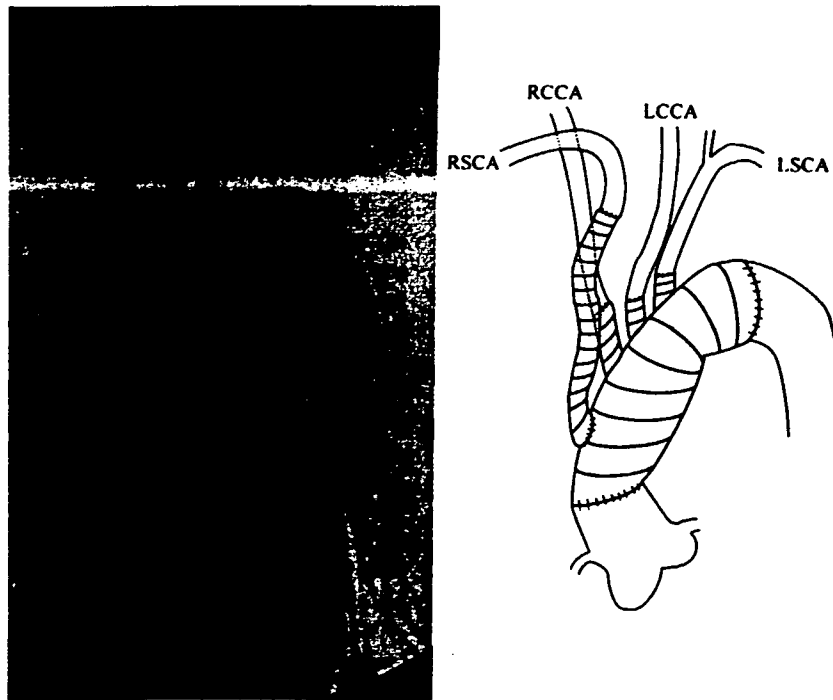


Fig 4. (Left) Digital subtraction angiogram with schematic after total arch replacement in a patient with aberrant right subclavian artery (ARSCA). (Right) The right subclavian artery (RSCA) was reconstructed on the right side of the trachea and esophagus. (LCCA left common carotid artery; LSCA left subclavian artery; RCCA right common carotid artery.)

follows: the mean total pump time was 208.3 ± 97.8 minutes; the mean SCP time, 95.6 ± 20.3 minutes; and the circulatory arrest time, 41.9 ± 15.4 minutes. The data were not significantly different from those of the patients having TAR without arch vessel anomalies.

#### Comment

Adachi [1] classified the branching pattern of the aortic arch into seven groups (groups A through G) on the basis of his experience with the dissection of 516 Japanese cadavers. The arch vessel anomalies most frequently encountered were CBT (type B), ILVA (type C), and ARSCA (type G). According to his report, the frequency was 10.9% for CBT, 4.3% for ILVA, and 0.2% for ARSCA [1]. Williams and Edmonds [2] reported their findings about arch vessel anomalies after dissecting 407 human cadavers: 191 American whites and 216 blacks. According to their report, the frequencies of arch vessel anomalies in white and black populations were 17.8% and 37.8% for CBT, 2.6% and 2.0% for ILVA, and 1.0% and 0% for ARSCA, respectively. The above data suggest that the incidence of the CBT variety of arch vessel anomaly might be higher among the black population. Obviously, the finding needs to be validated against larger data sets. Unfortunately, there has been a relative paucity of data in this area of research.

In dealing with the CBT variety, we separated the innominate artery and the left common carotid artery from the common trunk to ensure a more precise arch vessel cannulation for antegrade SCP during arch repair.

We were concerned that the insertion of a single cannula in the common trunk might sometimes result in accidental slippage of the cannula into any one of the branches, resulting in inadequate perfusion in the other. Another reason behind the separation of the two vessels was that we wanted to perform the anastomosis at a site that was free from atherosclerotic changes. The short common trunk as well as the bifurcation often has such atherosclerotic changes. Separation of the two vessels was easily accomplished, and, thereafter, no special device or strategy was necessary for cerebral protection and arch reconstruction. Among all types of arch vessel anomalies, the ILVA is the most difficult to diagnose preoperatively. Therefore, they are most often discovered intraoperatively. In the present study, only 4 of the 9 patients (40%) with ILVA could be diagnosed preoperatively. The ILVA is usually a small vessel and is often obscured by other larger arch branches, making its preoperative detection considerably more difficult. Of the 4 patients in whom a preoperative diagnosis was possible, 3 had their diagnosis made with the help of magnetic resonance angiography and 1 with three-dimensional computed tomographic scan. In our experience, magnetic resonance angiography and three-dimensional computed tomographic scan were very useful in the diagnosis of ILVA and in interpreting the dominance of vertebral arteries. However, as ILVA is usually revealed intraoperatively, it is necessary to take special precaution while the arch branches are dissected and exposed. It is difficult to insert the perfusion catheter into the ILVA because of its small diameter. Therefore, in most cases, the vessel has to be

simply clamped. However, this entails the risk of neurologic deficit owing to poor perfusion to the brainstem or cerebellum if the arterial communication at the circle of Willis is inadequate. Thus, it is important that the systemic temperature is sufficiently lowered. When the ILVA was discovered intraoperatively, we reasoned that the ILVA should be reconstructed rather than sacrificed because the dominance of the vertebral artery was unknown. The reconstructive procedures of the ILVA are shown in Figure 3. Although anastomosis with the native left subclavian artery as depicted in Figure 3B is the most advantageous from the viewpoint of long-term patency, this requires wide exposure of the left subclavian artery and anastomosis at a very deep position. When the origin of the ILVA is close to the left subclavian artery, the en-bloc technique as shown in Figure 3C is easy and useful. However, severe atherosclerotic changes are usually present at this site, and the ILVA or the left subclavian artery is often involved in aneurysmal dilatation of the aorta. As a result, the en-bloc technique, despite its advantages, cannot be used in most patients with ILVA, even when the latter originates near the left subclavian artery. The technique of left subclavian artery anastomosis shown in Figure 3A may, therefore, be the easiest and most useful.

It is not difficult to diagnose ARSCA preoperatively. With our cerebral protection method, the bilateral common carotid arteries and left vertebral artery were perfused under hypothermia. Although this proved sufficient in avoiding neurologic complications, additional ARSCA perfusion might be needed if the right vertebral artery is found to be dominant on preoperative magnetic resonance angiography. Even when the aneurysmal change does not extend to the orifice of the ARSCA, or the ARSCA itself does not expand to form an aneurysm, distal aortic anastomosis should be performed distal to the ARSCA orifice, and the right subclavian artery should be reconstructed distal to its intersection with the trachea and esophagus. This will circumvent the possibility of aneurysmal dilatation of the orifice of this vessel as well as the vessel itself in the future and prevent tracheoesophageal compression symptoms. In fact, the patients with ARSCA in our series did have aneurysmal dilatation of the ARSCA orifice with degenerative changes in the artery itself. Others have also reported similar findings [5, 6].

In conclusion, surgical treatment of anomalous arch vessels can be accomplished with a satisfactory outcome

if a precise preoperative diagnosis can be established. Magnetic resonance angiography and three-dimensional computed tomographic scan may be useful tools for diagnosing arch vessel anomalies, particularly the ILVA variety. When TAR is performed in patients with arch vessel anomalies, it is important to select the most appropriate method for cerebral protection and arch vessel reconstruction. As the ILVA is often revealed intraoperatively, careful manipulation of the arch branches and adequate systemic cooling during SCP are very important for avoiding neurologic complications.

## References

1. Adachi B. *Das Arteriensystem der Japaner*. Verlag der Kaiserl Jap Univ, Kyoto, 1928;1:29-31.
2. Williams GD, Edmonds HW. Variations in the arrangement of the branches arising from the aortic arch in American whites and Negroes. *Anat Rec* 1935;62:139-46.
3. Eusanio MD, Schepens MA, Morshuis WJ, et al. Separate grafts or en bloc anastomosis for arch vessels reimplantation to the aortic arch. *Ann Thorac Surg* 2004;77:2021-8.
4. Kazui T, Washiyama N, Bashar AHM, et al. Total arch replacement using aortic arch branched grafts with the aid of antegrade selective cerebral perfusion. *Ann Thorac Surg* 2000;70:3-9.
5. Ueda T, Shimizu H, Hashizume K, et al. Mortality and morbidity after total arch replacement using a branched arch graft with selective antegrade cerebral perfusion. *Ann Thorac Surg* 2003;76:1951-6.
6. Kouchoukos NI, Masetti P. Total aortic arch replacement with a branched graft and limited circulatory arrest of the brain. *J Thorac Cardiovasc Surg* 2004;128:233-7.
7. Suzuki K, Kazui T, Bashar AHM, Yamashita K, Terada H, Washiyama N. Total aortic arch replacement for thoracic aneurysm involving an isolated left vertebral artery. *Jpn J Thorac Cardiovasc Surg* 2002;50:381-2.
8. Bednarkiewicz M, Bruschiweiller I, Christenson JT. Undiagnosed aberrant right subclavian artery: pitfall in aortic arch surgery. *Cardiovasc Surg* 2003;11:61-3.
9. Kokotsakis JN, Lazopoulos GL, Lioulias AG, Kaskarelis JS, Romana CN, Lolas CT. Surgical treatment for aneurysm at the origin of an aberrant right subclavian artery. *Ann Vasc Surg* 2003;17:315-9.
10. Myers JL, Gomes MN. Management of aberrant subclavian artery aneurysms. *J Cardiovasc Surg* 2004;41:607-12.
11. Naito Y, Nakajima M, Inoue H, Mizutani E, Tsuchiya K. Successful treatment of a mycotic aortic aneurysm associated with an isolated left vertebral artery. *J Thorac Cardiovasc Surg* 2003;126:883-5.
12. Mogi K, Okimoto M, Okada Y. Emergent ascending and arch replacement for acute type A aortic dissection with anomalies of the aortic arch. *Kyobu Geka* 2003;56:817-21.
13. Kazui T, Yamashita K, Washiyama N, et al. Usefulness of antegrade selective cerebral perfusion during aortic arch operations. *Ann Thorac Surg* 2002;74(Suppl):S1806-9.



## Successful repair of ascending aortic pseudoaneurysm using autograft patch from fascia lata and saphenous vein

Katsushi Yamashita, MD, PhD  
Teruhisa Kazui, MD, PhD · Kazuya Suzuki, MD, PhD  
Hitoshi Terada, MD, PhD  
Naoki Washiyama, MD, PhD  
Abul Hasan Muhammad Bashar, MBBS, PhD

Received: 20 June 2007 / Accepted: 14 August 2007  
© The Japanese Association for Thoracic Surgery 2007

**Abstract** An 80-year-old man developed a pseudoaneurysm in the ascending aorta due to mediastinitis following cardiac surgery. We successfully repaired the pseudoaneurysm with an autograft patch harvested from fascia lata and the saphenous vein. The repair, which was carried out in two layers, can be expected to be durable.

**Key words** Pseudoaortic aneurysm · Fascia lata · Mediastinitis

### Introduction

Infectious aortic pseudoaneurysm is an intractable disease. Artificial material used for the repair is poorly tolerated in this situation. Although homograft repair can be a good option,<sup>1</sup> its use is limited. We performed a successful double-layer repair of an ascending aortic pseudoaneurysm using an autograft patch harvested from fascia lata and saphenous vein.

### Case

The patient was an 80-year-old man who had undergone mitral valve repair and coronary artery bypass grafting

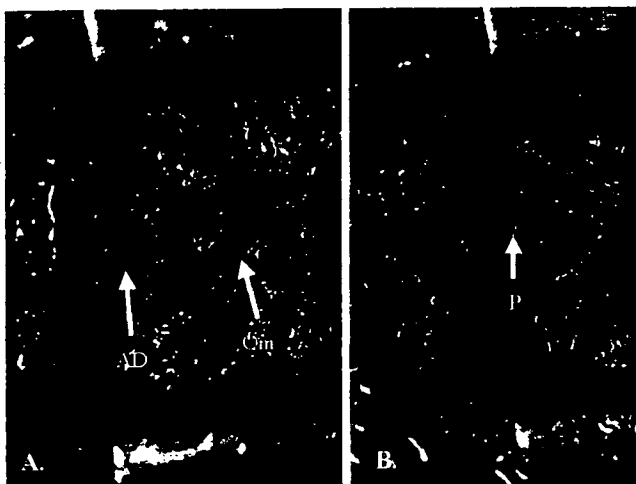
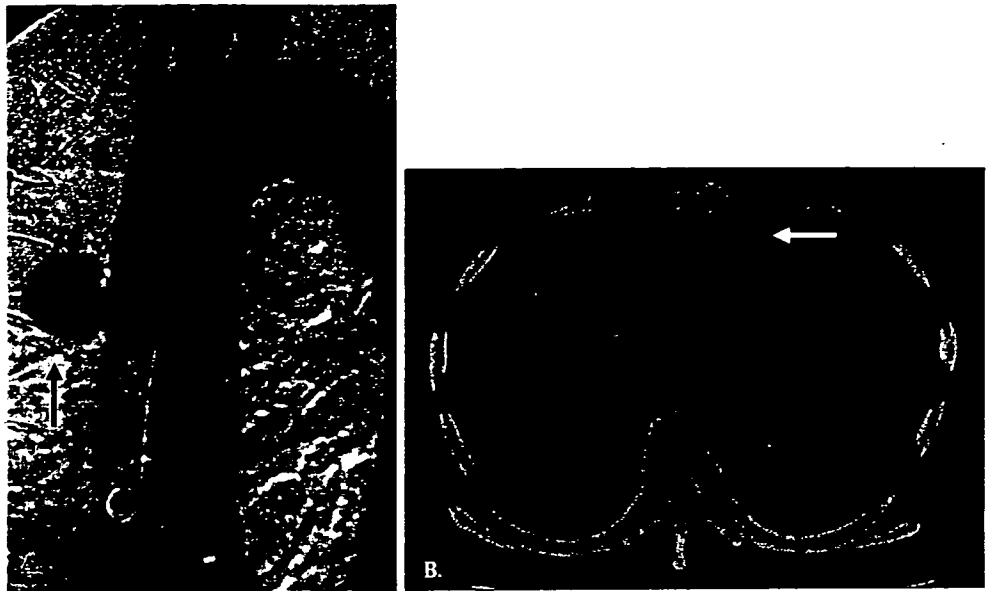
using a saphenous vein graft. Mitral valve replacement using a bioprosthesis was required for progressive hemolytic anemia 3 weeks later. The latter surgery was complicated by mediastinitis caused by methicillin-resistant *Staphylococcus aureus*. Because of major bleeding from the saphenous vein graft, emergent re-sternotomy was done, and ligation of the saphenous vein, débridement, irrigation, and omentopexy were performed. Despite the prolonged use of injectable antibiotics, an aortic pseudoaneurysm in the ascending aorta was detected 2 months later (Fig. 1A). The pseudoaneurysm was located at the arterial cannulation site. We planned pseudoaneurysm repair with an autograft patch under deep hypothermic circulatory arrest.

After establishing extracorporeal circulation using femoral artery and venous cannulations, cooling was started. Cardiac massage was done to prevent possible distension of the left ventricle under ventricular fibrillation. The fascia lata and saphenous vein were harvested from the left thigh. The autograft patch was constructed by affixing the two materials with each other and was then sized and arranged in two layers in such a way that the saphenous vein formed the inner layer and the fascia lata the outer layer. When the rectal temperature dropped to 20°C, sternotomy with omental dissection was performed. After circulatory arrest, the pseudoaneurysm was opened (Fig. 2A). Due to the use of deep hypothermic circulatory arrest technique, extensive dissection was not required. The aortic defect was repaired using an autograft patch measuring 2 cm in width (Fig. 2B). Circulatory arrest time was 15 min.

The mediastinal infection was controlled, and no recurrence of the pseudoaneurysm was detected 5 years after the operation.

K. Yamashita (✉) · T. Kazui · K. Suzuki · H. Terada ·  
N. Washiyama · A.H.M. Bashar  
First Department of Surgery, Hamamatsu University School  
of Medicine, 1-20-1 Handayama, Higashi-ku, Hamamatsu  
431-3192, Japan  
Tel. +81-53-435-2276; Fax +81-53-435-2272  
e-mail: dbi6011@hama-med.ac.jp

**Fig. 1** **A** Preoperative aortogram. *Arrow* indicates a pseudoaneurysm in the ascending aorta. **B** Preoperative computed tomogram. *Arrow* indicates a pseudoaneurysm in the ascending aorta



**Fig. 2** Operative findings. **A** Pseudoaneurysm is opened, and aortic edge is trimmed under deep hypothermic circulatory arrest. **B** *AD*, aortic defect; *Om*, dissected omentum. **B** Patch repair with autograft is performed. *P*, autograft patch

## Discussion

There have been several reports of ascending aortic pseudoaneurysm following cardiac operations.<sup>2</sup> Among them, pseudoaneurysms after mediastinitis are particularly intractable. Yamazaki et al. reported two cases of successful repair of pseudoaneurysm in the ascending aorta using a fascia lata patch.<sup>3</sup> They used double-folded fascia lata, which was found to be durable. We also successfully repaired a pseudoaneurysm in the ascending aorta with autograft patches consisting of fascia lata and saphenous vein in layers. The durability of both patches

was satisfactory. Papadimitriou et al. documented 2-year durability of the fascia lata patch used to replace a short segment of the ascending aorta in a canine study.<sup>4</sup> Wylie et al. described experimental and clinical use of fascia lata for major artery repair.<sup>5</sup> We thought that the layer of saphenous vein might be useful with regard to aortic wall strength and antithrombosis. Therefore, we arranged a two-layered autograft patch by putting fascia lata over a sutured venous patch.

Fascia lata is usually used in general thoracic surgery for filling defects in the chest wall,<sup>6</sup> diaphragm,<sup>7</sup> and pericardium.<sup>8</sup> We have previously examined in an experimental model the tensile strength of fascia lata used for diaphragm reconstruction.<sup>9</sup> Based on the results of that experimental study, we thought that suture line strength of fascia lata should be adequate even when it is used for aortic reconstruction.

A double-layer autograft patch consisting of fascia lata and saphenous vein may be an effective material for reconstruction of an infective aortic pseudoaneurysm.

## References

1. Katsumata T, Westaby S. Homograft aortic replacement for infected mediastinal false aneurysm. *Ann Thorac Surg* 1997; 64:1464–6.
2. Vrochides D, Feng WC, Singh AK. Mycotic ascending aortic pseudoaneurysm secondary to *Pseudomonas* mediastinitis at the aortic cannulation site. *Texas Heart Inst J* 2003;30(4):322–4.
3. Yamazaki I, Ichikawa Y, Ishii M, Hamada T, Kajiwara H. Using fascia lata to treat infective aortic false aneurysm. *Ann Thorac Surg* 2005;79:1425–7.

4. Papadimitriou J, Tsiftsis D, Papadimitriou K, Kourias E, Tountas C. Long-term results from use of fascia lata as arterial graft. *Am J Surg* 1976;132(1):15–8.
5. Wylie EJ, Kerr E, Davies O. Experimental and clinical experiences with the use of fascia lata applied as a graft about major arteries after thrombo-endarterectomy and aneurysmorrhaphy. *Surg Gynecol Obstet* 1951;93(3):257–72.
6. Asai K, Suzuki K, Shimota H, Ito Y, Asano K, Kazui T. Full-thickness chest wall reconstruction using autologous tissue grafts after resection of recurrent desmoid tumor. *Jpn J Thorac Cardiovasc Surg* 2004;52(6):296–9.
7. Kageyama Y, Suzuki K, Matsushita K, Takahashi T, Kazui T. Diaphragm reconstruction with autologous fascia lata: report of a case. *Surg Today* 1999;29(12):1285–6.
8. Kageyama Y, Suzuki K, Matsushita K, Nogimura H, Kazui T. Pericardial closure using fascia lata in patients undergoing pneumonectomy with pericardiectomy. *Ann Thorac Surg* 1998;66(2):586–7.
9. Suzuki K, Takahashi T, Itou Y, Asai K, Shimota H, Kazui T. Reconstruction of diaphragm using autologous fascia lata: an experimental study in dogs. *Ann Thorac Surg* 2002;74(1):209–12.

## What Expectations are Realistic in the Surgical Outcome of Acute Type-A Aortic Dissection?

Teruhisa Kazui, MD.

Director, Japanese Association for Thoracic Surgery, Hamamatsu University School of Medicine

Acute type-A aortic dissection is a life-threatening condition in which emergency surgical intervention is almost always required to prevent sudden death from aortic rupture or vital-organ malperfusion. In-hospital mortality following this complex surgery is reported to be 15–30%, although a few centers have reported less than 10%. Improved surgical outcome is said to be closely related to the surgeon's experience, diagnostic advances such as the use of transesophageal echocardiography and computed tomography (CT) resulting in earlier surgical referral, and appropriate surgical techniques. Surgical techniques include the use of graft exclusion, open distal anastomosis, biological glue such as gelatin resorcin formaldehyde (GRF) and Bioglue, collagen-impregnated Dacron grafts, improved cerebral protection such as deep hypothermic circulatory arrest with or without retrograde cerebral perfusion and antegrade selective cerebral perfusion, antegrade systemic perfusion after the distal graft anastomosis, and axillary or subclavian artery cannulation to avoid malperfusion of the vital organs. Better perioperative and anesthetic care has also significantly improved surgical outcome.

However, recent reports on surgical outcome following acute type-A aortic dissection repair are not particularly encouraging. Data from the International Registry of Acute Aortic Dissection Investigators provides a good example. Compiled from 526 patients at 18 referral centers world-wide and published in 2005, the report shows an in-hospital mortality of 25.1%<sup>1</sup>—a figure that appears unchanged in 3 decades. Are we missing something here? Why have these major centers been unable to reduce in-hospital mortality for this particular condition to an acceptable level despite continuous effort? Can these centers somehow have not

benefited from advances over the years? This becomes a reasonable question when we look at the Annual Report of the Japanese Association for Thoracic Surgery for 2003. In a cohort of 2,247 patients operated on for acute type-A aortic dissection at 385 institutions across Japan, in-hospital mortality was 14.5%.<sup>2</sup> What is responsible for this gap? Are Japanese surgeons somehow practicing superior surgical techniques or are centers participating in the International Registry operating under somewhat different circumstances? What, then, are the realistic expectations for in-hospital mortality following surgery for acute type-A aortic dissection?

Established determinants of in-hospital mortality following this surgical intervention include preoperative conditions such as shock, organ malperfusion (coronary, cerebral, abdominal visceral), comorbidities such as renal dysfunction and chronic obstructive pulmonary disease (COPD), and surgical techniques including cerebral protection. The type and location of the institution is also considered important in determining outcome. A primary care center with an active emergency department must deal with all sorts of cases. A tertiary referral center, however, may never see the moribund patients who die before reaching the hospital—a type of “natural selection.” Such natural selection has almost no positive influence on the surgical outcome at tertiary centers, however. Last but not least is the case volume of a given institution or surgeon. Even the busiest of centers usually conduct fewer than 15 cases involving acute type-A dissection a year, although their routine open-heart cases such as coronary artery bypass grafting (CABG) and valve replacement procedures may exceed 1,000 a year. If 5 staff surgeons work at such centers and cases are evenly distributed among them, this becomes a mere 2–3 cases of acute type-A dissection per surgeon per year, which is simply not enough for surgeons to improve their skill and expertise.

Indeed, the surgeon's experience greatly affects in-hospital mortality following acute type-A aortic dissection surgery. Westaby et al. reported 6% in-hospital mortality in his single-surgeon experience with this

From First Department of Surgery, Hamamatsu University School of Medicine, Hamamatsu, Shizuoka, Japan.

Address for reprints: Teruhisa Kazui, MD, First Department of Surgery, Hamamatsu University School of Medicine, 1-20-1 Handayama, Hamamatsu, Shizuoka 431-3192, Japan.