

distal arch, potential sources of embolus. Therefore, total arch replacement with a quadrifurcated graft may decrease the risk of embolization from arch vessels. Second, when the distal arch aneurysm is of saccular type, patch closure might be considered. However, because of the high incidence of pseudoaneurysm or residual aneurysm after patch repair for saccular aneurysm of the aortic arch, graft replacement of the aorta is generally recommended [15]. The third advantage is that concomitant surgery such as coronary artery bypass grafting and valve surgery are possible using the usual approaches. Twenty-two patients (18.5%) required concomitant coronary artery bypass grafting in this series, and all coronary targets were easily accessible. Most cardiovascular surgeons are familiar with the midsternotomy approach and can deal with unexpected situations during operation.

Hagl and colleagues [16] noted the superiority of the midsternal approach compared with left thoracotomy. They reported that the more respiratory disturbances resulted from approaching the aorta through a left thoracotomy than through midsternotomy. Although their report was limited to octogenarians and our series featured a slightly younger population, it may well be that elderly patients have increased risk of respiratory complications after operations performed through a left thoracotomy.

In conclusion, advanced brain protection and meticulous procedures can reduce the rate of stroke after total arch replacement for distal arch aneurysm. The operative approach we have described for distal arch aneurysm exhibits a low mortality rate and a low risk of perioperative stroke. Other cardiac operations routinely can be performed concomitantly with it in standard fashion. Distal arch aneurysm that does not involve a large segment of the descending thoracic aorta can thus be repaired with a low mortality rate and few cerebral complications through a midsternotomy.

## References

1. Kay GL, Cooley DA, Livesay JJ, Reardon MJ, Duncan JM. Surgical repair of aneurysms involving the distal aortic arch. *J Thorac Cardiovasc Surg* 1986;91:397-404.
2. Goldstein LJ, Davies RR, Rizzo JA, et al. Stroke in surgery of the thoracic aorta: incidence, impact, etiology, and prevention. *J Thorac Cardiovasc Surg* 2001;122:935-45.
3. Ando M, Adachi S, Nakaya M, Kawashima Y. Surgical results in atherosclerotic distal aortic arch aneurysm Nippon Kyobu Geka Gakkai Zasshi 1993;41:2034-9.
4. Hayashi J, Eguchi S, Yasuda K, et al. Operation for nondissecting aneurysm in the descending thoracic aorta. *Ann Thorac Surg* 1997;63:93-7.
5. Verdant A, Cossette R, Page A, Baillet R, Dontigny L, Page P. Aneurysms of the descending thoracic aorta: three hundred sixty-six consecutive cases resected without paraplegia. *J Vasc Surg* 1995;21:385-91.
6. Galloway AC, Schwartz DS, Culliford AT, et al. Selective approach to descending thoracic aortic aneurysm repair: a ten-year experience. *Ann Thorac Surg* 1996;62:1152-7.
7. Okita Y, Minatoya K, Tagusari O, Ando M, Nagatsuka K, Kitamura S. Prospective comparative study of brain protection in total aortic arch replacement: deep hypothermic circulatory arrest with retrograde cerebral perfusion or selective antegrade cerebral perfusion. *Ann Thorac Surg* 2001;72:72-9.
8. Kazui T, Yamashita K, Washiyama N, et al. Usefulness of antegrade selective cerebral perfusion during aortic arch operations. *Ann Thorac Surg* 2002;74(Suppl):1806-9.
9. Numata S, Ogino H, Sasaki H, et al. Total arch replacement using antegrade selective cerebral perfusion with right axillary artery perfusion. *Eur J Cardiothorac Surg* 2003;23:771-5.
10. Niinami H, Aomi S, Chikazawa G, Tomioka H, Koyanagi H. Progress in the treatment of aneurysms of the distal aortic arch: approach through median sternotomy. *J Cardiovasc Surg (Torino)*. 2003;44:243-8.
11. Tominaga R, Kurisu K, Ochiai Y, et al. Total aortic arch replacement through the L-incision approach. *Ann Thorac Surg* 2003;75:121-5.
12. Ohata T, Sakakibara T, Takano H, Ishizaka T. Total arch replacement for thoracic aortic aneurysm via median sternotomy with or without left anterolateral thoracotomy. *Ann Thorac Surg* 2003;75:1792-6.
13. Sasaguri S, Yamamoto S, Fukuda T, Hosoda Y. Anteroaxillary thoracotomy facilitates the use of retrograde cerebral perfusion in distal aortic arch reconstruction. *Ann Thorac Surg* 1996;62:1861-2.
14. Sueda T, Orihashi K, Okada K, Sugawara Y, Imai K, Kochi K. Fate of aneurysms of the distal arch and proximal descending thoracic aorta after transaortic endovascular stent-grafting. *Ann Thorac Surg* 2003;76:84-9.
15. Okita Y, Takamoto S, Ando M, et al. Long-term results of patch repair for saccular aneurysms of the transverse aortic arch. *Eur J Cardiothorac Surg* 1997;11:953-6.
16. Hagl C, Galla JD, Spielvogel D, et al. Is aortic surgery using hypothermic circulatory arrest in octogenarians justifiable? *Eur J Cardiothorac Surg* 2001;19:417-23.

## DISCUSSION

**DR SARA SHUMWAY** (Minneapolis, MN): I have just two quick questions. What do you consider a large area of involvement in the area of the subclavian artery, and also, how did you decide to cool to just 20° to 25°C for your circulatory arrest?

**DR MINATOYA:** You mean, not only distal arch but also including the transverse arch?

**DR SHUMWAY:** How do you decide whether it is a large area that is involving the descending thoracic?

**DR MINATOYA:** The point is a distal anastomosis; if the diseased area is included in the transverse arch, it does not

matter. We can perform the operation in the same fashion. But the point of this presentation is we believe that kind of aneurysm could not be performed safely through a left thoracotomy.

As to the second question, the temperature was mainly about 20 degrees in this series, but actually we raised that to 25 to 28 degrees these days, and so far our result is not so different.

**DR JOHN FEHRENBACHER** (Indianapolis, IN): These are very impressive results. Would you describe in detail your technique for antegrade cerebral protection? Specifically, did you directly cannulate the arch vessels or did you rely on axillary cannulation?

**DR MINATOYA:** In most cases, as I mentioned in the presentation, we are using the right axillary cannulation, and as an aortic return we are using basically femoral cannulation or ascending cannulation, and we start axillary perfusion first, before ascending or femoral perfusion. After establishment of circulatory arrest, we put the cannulation on the second arch branch and third arch branch from inside. But at the time, we check the back flow from the arch branches.

**DR D. CRAIG MILLER (Stanford, CA):** I have faced this dilemma many times where you look at these distal arch or proximal descending aneurysms and wonder if it would be safer for the patient (mostly in terms of cerebral protection) and easier on you as well as the patient to go in from the front or the side using a thoracotomy; the correct answer is not obvious in all circumstances.

I rise to bring up something I have been teasing Dr Teruhisa Kazui about for a couple of years. I'm sure you know Dr Kazui over in Hamamatsu, who has shown us that he can even do total arch replacement for those with acute type A dissections with surprisingly good results in Japanese patients. My word of caution is that I do not believe this applies to large 90 to 100 kg lumberjacks from North America or Europe. Many of the patients we operate on in California tend to be larger and have much deeper chests; one has to be very careful here in deciding which approach is best. In a thin Asian person, you can probably get down the descending thoracic aorta as far as the left main stem bronchus without too much trouble using a sternotomy, but I don't think this is true for large Western subjects.

Therefore, I am interested in the size and weight of your patients. What was the average (and range) of weight and body surface area of the patients you presented today? You may be a lot luckier than we are here in North America by operating on smaller Japanese people.

**DR MINATOYA:** I am sorry, I don't have precise data of the size and weight, but you are actually right. I am actually one of the biggest Japanese, and North American guys are much bigger than me, but the point of Dr Kazui's method is the standardization and the simplification. We actually do a lot of total arch replacement for these kind of patients and also total transverse aortic arch aneurysm patients, of course, for acute dissection patients. But we select every time this type of operation. So all staff, including residents, know how to do this operation. That is the point, I guess, of our good results.

**DR JOSEPH BAVARIA (Philadelphia, PA):** I rise to congratulate you on an incredible series. Isolated distal aortic arch aneurysms are usually very atherosclerotic, and Stanley Crawford taught us a few years back that these had very high morbidity and mortality rates. However, my observation is, for most of the CT scans that you showed in the presentation, our group would place endovascular thoracic aortic stent grafts in many of these

distal aortic arch aneurysms. Your slides (CT scans) show normal middescending aortic diameters and enough of a distal arch neck proximally so that a thoracic aortic stent graft could be placed proximally, with or without a left subclavian artery transposition. So my first question is: Did you place any thoracic aortic stent grafts for these types of distal arch aneurysms? And if not, why not?

And my second comment is, I would like to propose, as we begin to write the history of thoracic aortic stent grafting for distal arch aneurysms, that this paper represent the benchmark in the stent graft community for open distal arch aneurysm repair. The stent graft operation will need to beat this number. These are very, very good results. Thank you very much.

**DR MINATOYA:** Thank you very much. Actually we don't do a lot of stent grafting in our institute. Stent grafting might be a good choice for this type of aneurysm, but I have no idea at this moment.

**DR KIYOFUMI MORISHITA (Sapporo, Japan):** You reported a high incidence of stroke using circulatory arrest through a left thoracotomy, and I performed this procedure with 0% stroke, though the number is 20 or so. And it seems to me that circulatory arrest reduced the incidence of stroke whatever approach, mid, right, or left thoracotomy. Why did you perform circulatory arrest through a left thoracotomy with a high incidence of stroke?

**DR MINATOYA:** Those data included older data, so these days we don't do circulatory arrest so frequently through a left thoracotomy. When we face the distal arch aneurysm extended to descending aorta, we do a two-stage operation. I mean, firstly, we do a total arch replacement with the elephant trunk, and secondly, we do a descending replacement with femoral-femoral perfusion. So we don't have to do circulatory arrest through a left thoracotomy.

**DR REX STANBRIDGE (London, UK):** You have a great experience with these two incision exposures, but I wonder why you do not consider using a transverse clamshell incision across the chest this way [illustrating a line drawn transversely across the lower border of the rib cage up toward both axillae], which gives extremely good exposure of the heart, the ascending aorta, the arch, the subclavian, the descending aorta right back down to the diaphragm and would eliminate some of the restrictions of the use of your procedure?

**DR MINATOYA:** I know there are lots of alternative incisions like you mentioned, maybe we have to try to do it. At this moment, we just need a midsternal incision, and we can see almost the distal arch perfectly, and if we need more, maybe we do, additional T incision. But we would like to try your incision too. Thank you very much.

# Integrated Total Arch Replacement Using Selective Cerebral Perfusion: A 6-Year Experience

Hiroaki Sasaki, MD, Hitoshi Ogino, MD, Hitoshi Matsuda, MD, Kenji Minatoya, MD, Motomi Ando, MD, and Soichiro Kitamura, MD

Department of Cardiovascular Surgery, National Cardiovascular Center, Osaka, and Department of Thoracic Surgery, Fujita Health University, Aichi, Japan

**Background.** The purpose of this study was to evaluate the recent outcome of integrated total arch replacement using antegrade selective cerebral perfusion with right axillary artery perfusion.

**Methods.** Between 2000 and 2005, 305 patients underwent elective total arch replacement for arch or distal arch aneurysm using a Dacron (DuPont, Wilmington, DE) quadrifurcated prosthesis through a median sternotomy. There were 34 dissecting and 271 nondissecting aneurysms. Brain protection was standardized using antegrade selective cerebral perfusion with right axillary artery cannulation at 20° to 28°C. Risk factors for early mortality and neurologic complications were investigated using multivariate logistic regression analyses.

**Results.** The durations of hypothermic circulatory arrest, myocardial ischemia, selective cerebral perfusion, cardiopulmonary bypass, and surgery were  $60.9 \pm 16.8$ ,

$125.2 \pm 39.3$ ,  $150.1 \pm 39.0$ ,  $229.8 \pm 91.4$ , and  $466.4 \pm 175.8$  minutes, respectively. Seven patients died, for a 2.3% early mortality. Permanent neurologic dysfunction developed in 5 patients (1.6%), and temporary neurologic dysfunction in 20 (6.6%). The mid-term survival rate was  $94.6\% \pm 1.5\%$  at 3 years. On multivariate analyses, prolonged surgery was a risk factor for early mortality. Preoperative cerebral hypoperfusion was a significant determinant for temporary neurologic dysfunction and male gender for permanent neurologic dysfunction.

**Conclusions.** Integrated total arch replacement using antegrade selective cerebral perfusion with right axillary artery cannulation yields a favorable outcome with low mortality and cerebral morbidity rates.

(Ann Thorac Surg 2007;83:S805–10)

© 2007 by The Society of Thoracic Surgeons

Total arch replacement (TAR) for arch-to-distal arch aneurysms still has surgically challenging aspects and features high mortality and morbidity [1, 2]. In particular, postoperative neurologic complications resulting in mortality or other morbidities remain prevalent, although great progress in brain protection has recently been achieved [1–7]. We have changed our technique of brain protection from retrograde cerebral perfusion (RCP) [5, 6, 8] with profound hypothermia to antegrade selective cerebral perfusion (SCP) [2–4] combined with right axillary artery cannulation [9]. In the present study, the recent outcome of integrated TAR using SCP with right axillary artery cannulation is reviewed, and relevant risk factors for early mortality and cerebral morbidity are examined.

## Patients and Methods

### Patients

A retrospective review was performed of 305 patients (238 men) undergoing elective TAR for arch or distal arch aneurysm between 2000 and 2005 in the National Cardio-

vascular Center, Osaka, Japan. Median patient age was 73 years (range, 52 to 87 years). There were 34 dissecting and 271 nondissecting aneurysms. The cause of the aneurysm was atherosclerotic in 289 patients, non-Marfan degenerative in 10 patients, Marfan in 2 patients, and aortic (including Behçet disease) in 4 patients. Ten patients requiring reoperative surgery were included. Also included were 18 patients with extensive thoracic aortic aneurysm involving the arch; for them, two-stage surgery was performed with stage I TAR, followed by stage II descending aortic replacement in 12 patients and endoluminal stent grafting in 6 older patients with respiratory dysfunction. Institutional approval for this study was obtained, and each patient in the study gave informed consent to serve as a subject.

### Surgical Techniques and Brain Protection

All aneurysms were approached through a median sternotomy and replaced using a quadrifurcated Dacron (DuPont, Wilmington, DE) prosthesis with open distal anastomosis.

1. Cardiopulmonary bypass (CPB) establishment with right axillary artery perfusion. In the last decade, we have refined surgical techniques, including strategies of CPB, brain protection, and lowest core temperature (Fig 1). Since 2000, right axillary artery perfusion has been routinely used in conjunction

Presented at Aortic Surgery Symposium X, New York, NY, April 27–28, 2006.

Address correspondence to Dr Sasaki, Department of Cardiovascular Surgery, National Cardiovascular Center, 5-7-1 Fujishirodai, Suita, Osaka 565-8565, Japan; e-mail: hmsasaki@hsp.ncvc.go.jp.

© 2007 by The Society of Thoracic Surgeons  
Published by Elsevier Inc

0003-4975/07/\$32.00  
doi:10.1016/j.athoracsur.2006.10.094

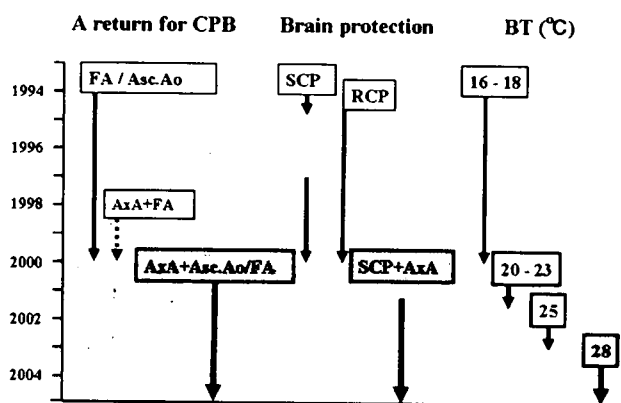


Fig 1. Refinement of cardiopulmonary bypass (CPB), brain protection, and body (core) temperature (BT). (FA = femoral artery; Asc.Ao = ascending aorta; AxA = axillary artery; SCP = antegrade selective cerebral perfusion; RCP = retrograde cerebral perfusion.)

with femoral artery or ascending aorta cannulation for CPB to prevent cerebral emboli caused by retrograde femoral artery perfusion and for quick and easy conversion to SCP (Fig 2) [9].

The right axillary artery is exposed through a 5-cm to 7-cm incision in the right armpit. After full heparinization, a 10F to 16F straight thin-walled cannula is inserted into the right axillary artery. Empirically, 12F cannulae produce up to 1500 mL/min flow for CPB. Right axillary artery perfusion is initiated to prevent cerebral emboli before femoral artery perfusion. Bicaval venous drainage with left ventricular venting is routine.

- Brain protection using SCP with right axillary artery perfusion. Before 2000, RCP with deep hypothermia at 16° to 18°C was predominantly used for brain protection (Fig 1) [5, 6]. Since the beginning of 2000, we have routinely used the current method of SCP combined with right axillary artery perfusion [9]. After induction of hypothermic circulatory arrest (HCA), SCP through right axillary artery perfusion is commenced by clamping the brachiocephalic (innominate) artery. The transverse arch is opened, and a 12F SCP balloon-tipped cannula is inserted from within the aorta into the left common carotid artery.

Between 2000 and 2002, SCP was instituted by right axillary artery and left common carotid artery perfusion, with the left subclavian artery clamped, at 20° to 23°C. During SCP, the bilateral superficial temporal artery pressures or the pressures of the balloon tips were monitored and maintained in the range of 30 to 50 mm Hg. Subsequently, SCP flows were about 10 mL/(kg · min), generated by a single roller pump separate from the systemic circulation (Fig 2). In 2003, left subclavian artery perfusion using another balloon-tip cannula was added, and the lowest core temperature was gradually increased to 25° or 28°C. SCP flow is also increased to maintain perfusion pressure between 50 and 70 mm

Hg (800 to 1200 mL/min). Cardiac arrest is induced by antegrade and retrograde cardioplegia.

- Stepwise distal anastomosis (Fig 3). Through the aneurysm, the proximal descending aorta distal to the aneurysm is transected completely to prevent phrenic and vagal nerve injury. Open distal anastomosis is performed during HCA of the lower half of the body. Before 2000, a quadrifurcated arch graft was directly anastomosed to the descending aorta with 3-0 or 4-0 polypropylene continuous suture. Since 2000, stepwise distal anastomosis has been used for an easy and secure anastomosis [10, 11] with routine right axillary artery perfusion.

In this original technique, an invaginated tube graft (7-cm to 12-cm long) composed of the main arch graft is initially inserted into the descending aorta. We have recently refined our stepwise technique to reinforce the anastomosis and prevent bleeding (Fig 3). In making the stepwise graft, 2 to 3 cm of the proximal end is left without invagination to reinforce the anastomosis from the inside, using a sandwich technique with a Teflon (DuPont, Wilmington, DE) felt strip. We call this the mini-elephant trunk technique. The proximal end of the graft is anastomosed to the descending aorta using an over-and-over running suture, with outside reinforcement with a strip of Teflon felt. After the anastomosis, the distal end of the inserted graft is extracted proximally. Debris is flushed from the descending aorta by femoral artery perfusion. The main arch graft is connected to this short interposed graft end using a 3-0 polypropylene running suture.

Systemic circulation is resumed using a branch of the arch graft. The left subclavian artery is initially reconstructed using a branch graft, and the patient is slowly rewarmed to 30°C. The proximal aortic anastomosis follows, above the sinotubular junction, using 4-0 polypropylene running suture. Coronary circulation is initiated by unclamping the aorta. The other two arch vessels are finally reconstructed with branch grafts.

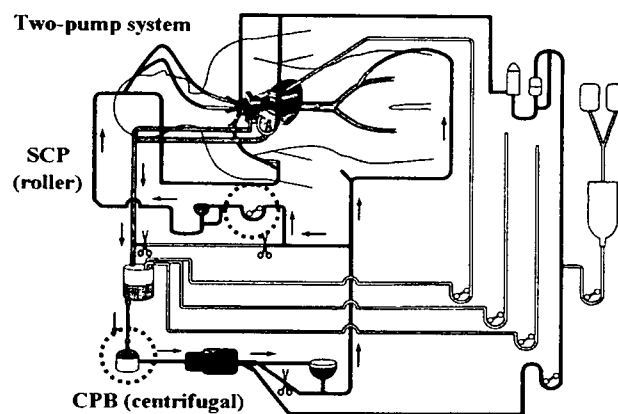


Fig 2. A two-pump system for cardiopulmonary bypass (CPB) and antegrade selective cerebral perfusion (SCP).

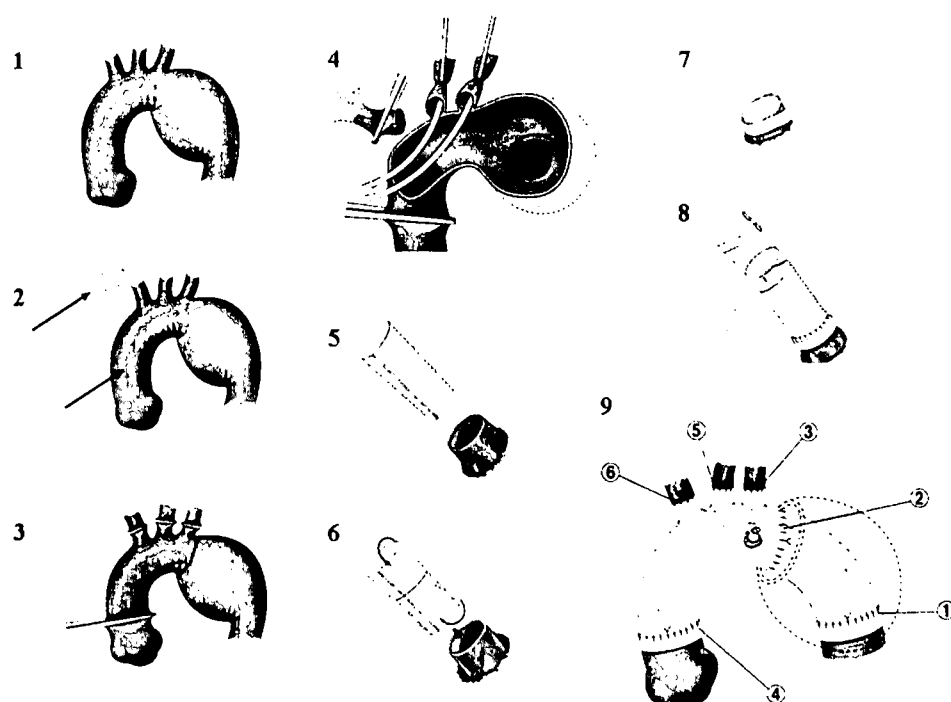


Fig 3. Integrated total arch replacement using antegrade selective cerebral perfusion with right axillary artery perfusion. (1) Arch or distal arch aneurysm. (2) Ascending aorta and right axillary artery cannulation for cardiopulmonary bypass. (3) Induction of hypothermic circulatory arrest with the arch vessels clamped. (4) Selective cerebral perfusion with right axillary artery, left common carotid artery, left subclavian artery perfusion. (5) Original stepwise technique. (6) Refined stepwise technique with mini-elephant trunk. (7) Distal anastomosis. (8) Graft-to-graft anastomosis. (9) Total arch replacement using quadrifurcated graft. Circled numbers show the turn of the anastomosis.

#### Definition of Neurologic Deficits and Other Variables

Permanent neurologic dysfunction (PND) was defined as the presence of permanent neurologic deficits either focal or global in nature, persisting at discharge. Transient neurologic dysfunction (TND) was defined as the occurrence of postoperative confusion, agitation, delirium, or prolonged obtundation [12]. Cerebral hypoperfusion was defined as the preoperative presence of more than 50% stenosis of the arch vessels or the intracranial vessels, or both, on echo or magnetic resonance angiography study, or hypoperfusion on acetazolamide-loading cerebral flow scintigraphy.

#### Data Collection and Statistical Analysis

Medical records were reviewed for clinical variables including preoperative status, intraoperative data, postoperative complications, and mid-term survival. Follow-up was 100% complete. The mean follow-up period

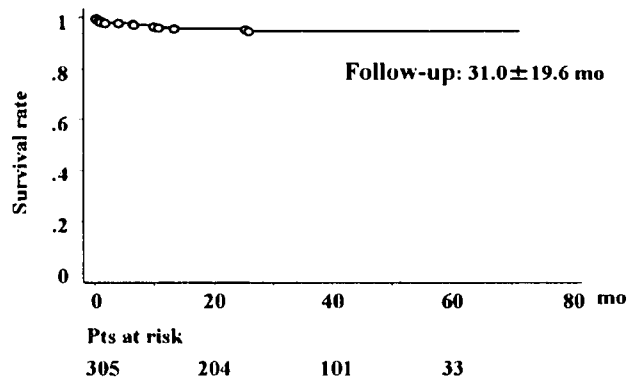


Fig 4. Mid-term survival (Kaplan-Meier estimates).

was  $31.0 \pm 19.6$  months. We retrospectively reviewed the overall outcome of TAR and investigated risk factors for hospital mortality and cerebral morbidity by multivariate logistic regression analyses.

Statistical analysis was done with SPSS software (SPSS Inc, Chicago, IL). Values are expressed as the mean  $\pm$  standard deviation or medians (range), with values of  $p < 0.05$  considered significant. Logistic regression was used to investigate risk factors for mortality and cerebral morbidity. Kaplan-Meier estimates were used to calculate survival rates.

#### Results

The mean of the lowest nasopharyngeal temperature was  $23.1^\circ \pm 3.7^\circ\text{C}$ . The durations of hypothermic circulatory arrest for open distal anastomosis, myocardial ischemia, SCP, CPB, and surgery were  $60.9 \pm 16.8$ ,  $125.2 \pm 39.3$ ,  $150.1 \pm 39.0$ ,  $229.8 \pm 91.4$ , and  $466.4 \pm 175.8$  minutes, respectively. No patients died within 24 hours after surgery; however, 6 patients (1.9%) died within 30 days after surgery from low output syndrome in 1 patient, respiratory failure due to pulmonary bleeding in 1, sepsis (mediastinitis) in 2 [1] patients, and bowel necrosis in 2 patients. Four months after surgery, another 84-year-old patient died from sepsis caused by stent graft infection after a second procedure that followed TAR during the same hospitalization. Thus, there were 7 (2.3%) early deaths. PND developed in 5 (1.6%) patients and TND developed in 20 (6.6%). The mid-term survival rate was  $94.6 \pm 1.5\%$  at 3 years (Fig 4).

On multivariate logistic regression analyses, prolonged surgery was the only risk factor for early mortality (odds ratio [OR], 1.011,  $p = 0.027$ ). Risk factors for TND were

preoperative cerebral hypoperfusion (OR, 0.204,  $p = 0.014$ ) and for PND, male gender (OR, 0.011,  $p = 0.017$ ). Cerebral hypoperfusion (OR, 0.360,  $p = 0.049$ ) and male gender (OR, 0.267,  $p = 0.030$ ) were predictors of any neurologic complication, including both TND and PND.

### Comment

Great advances in TAR commenced with the induction of RCP with profound HCA in 1993 [5, 6, 8]. This widely accepted adjunct improved overall outcome remarkably [12-16]. However, many patients still sustained TND, especially after prolonged HCA even with RCP [5, 6, 13-16], although Okita and colleagues [5] at our institute reported no difference. Reich and colleagues [17] reported that profound HCA exceeding 25 minutes and advanced age were associated with memory and fine motor deficits and prolonged hospital stay. The incidence and severity of TND correlates with poor performance on neuropsychologic testing, which predicts continued deficits in memory and motor function [18]. To decrease TND, we switched our strategy for brain protection from RCP to SCP, which is basically physiologic and has a longer cerebral safety margin. Since the beginning of 2000, we have consistently performed SCP for brain protection [9].

With SCP, however, atheromatous cerebral emboli remain a major concern. A variety of embolic phenomena are caused by systemic CPB perfusion through the ascending aorta across the arch aneurysm or by retrograde femoral artery perfusion. Arch vessel cannulation also carries a risk of cerebral embolization [17, 18]. For these reasons, an alternative perfusion pathway using the right axillary artery has been routinely used for both CPB and SCP [9].

The right axillary artery can easily be exposed and cannulated and is less atherosclerotic than the arch. Unfortunately, in Japanese patients, particularly small women, the axillary artery is too small to accept larger-size cannulae, so that additional cannulation through the femoral artery or the ascending aorta is necessary for systemic CPB flow. Femoral artery cannulation was previously performed. Retrograde femoral artery perfusion was useful not only for flushing out debris in the descending aorta but also to check for bleeding from the key distal anastomosis in the descending aorta.

The combination of right axillary artery and femoral artery perfusion was used for approximately 3 years, between 2000 and 2002, and we have previously reported its advantages [9]. With this combination, downstream flow through the right axillary artery can compete with retrograde femoral artery perfusion in the descending aorta and may prevent cerebral emboli. However, in the absence of atherosclerosis, ascending aorta cannulation, which yields antegrade CPB flow, has become our first choice rather than femoral artery perfusion [19].

We believe that right axillary artery cannulation is of use even with ascending aorta cannulation because the switch from systemic perfusion by way of CPB to SCP is easy, with no discontinuity, and cannulation-induced

emboli from the brachiocephalic artery can be avoided. We have therefore been able to increase core temperature to 28°C [20]. If the ascending aorta is atherosclerotic, however, the femoral artery is chosen as an alternative site of cannulation.

We have thus continued integrated TAR using SCP with right axillary artery perfusion in the last 6 years. In this study, the early and mid-term outcomes were reviewed, with assessment of significant determinants for mortality and cerebral morbidity. Our integrated TAR yielded a satisfactory 2.3% early mortality rate, even with difficult surgery including a two-stage repair of extensive thoracic aortic aneurysms involving the arch, and even for elderly individuals with a median age of 73 years. The current outcome is comparable or superior to those described in previous reports [21-23].

Multivariate analysis demonstrated that only prolonged surgery was an independent determinant of early death. In contrast, Kazui and colleagues [3] reported that chronic renal failure, long CPB time (>300 minutes), participation in an early series, and shock were risk factors for death in their first study, and PND in a more recent study [4]. No other factors such as age, coexisting coronary artery disease, reoperative surgery, dissection, neurologic comorbidities, postoperative neurologic complications, or concomitant surgery including coronary artery bypass or root surgery were significant predictors of early mortality.

Preoperatively, 30.2% of the patients had coexisting coronary artery disease. The strategy for treatment of coronary artery disease associated with arch aneurysms is still controversial. Cardiologists tend to suggest safer catheter intervention before TAR because TAR has a high mortality risk and most patients who need TAR are old. Conversely, prompt performance of combined TAR with coronary artery bypass grafting (CABG) is recommended by surgeons because CABG can be performed concomitantly with a low risk. In the present series, TAR and CABG were performed together in 62 patients, 3 of whom died, yielding a mortality rate of 4.8%. The causes of death were unrelated to coronary artery disease: bowel necrosis in 2 patients and mediastinitis in 1. We therefore believe that use of combined TAR with CABG is justified.

Ergin and colleagues [12, 18] reported that postoperative cerebral morbidity after TAR remains a major problem resulting in mortality and serious morbidity. The present study did not yield similar results. Multivariate analysis revealed preoperative cerebral hypoperfusion—including old cerebral infarction—to be a risk factor for TND, although it was not an independent predictor for PND. This finding was expected. TND is considered to be due to cerebral hypoperfusion during CPB, or HCA with selective or retrograde cerebral perfusion [12]. Conversely, most strokes are considered due to embolism originating from hematoma or atheroma in the aorta or in the arch vessels [12]. For patients with cerebral hypoperfusion before surgery, our strategies were modified to include higher CPB perfusion pressure (>60 mm Hg), more profound hypothermia (20° to 22°C), and higher SCP flow rates, with increases in SCP pressure of 20% to

30%. These refinements yielded good outcomes empirically.

On multivariate analysis, male gender was the only significant determinant of PND. As mentioned, the cause of PND is believed to be emboli caused by atheroma in the ascending aorta/aortic arch and in the arch vessels, particularly under well-established brain protection, whether in conjunction with RCP or SCP [12]. In the present series, 78.0% of the 305 patients were men, and all patients who sustained PND were men. Male gender is widely considered a risk factor for atherosclerotic change in all arteries. This finding was therefore also expected.

The degree of atheromatous change was not assessed in this study, although atherosclerotic aneurysm was evaluated as a potential risk factor. It is of interest that the Mt. Sinai group [7] assessed clot/atheroma as a risk factor for adverse outcome including cerebral complications; however, it is difficult to quantitatively evaluate the degree or amount of atheromatous lesions.

For patients with severe atheromatous lesions in the arch vessels or their orifices, adequate brain protection technique is still controversial. RCP has been criticized because prolonged HCA results in cerebral morbidity [5, 6, 13-15], whereas SCP theoretically has a longer cerebral safety margin [2-4]. However, SCP—requiring cannulation of the arch vessels—has the potential for cerebral embolism, which has been considered its worst shortcoming [8, 12].

In our strategy involving right axillary artery cannulation, we can avoid cannulation of the brachiocephalic artery, which sometimes exhibits atheromatous change. Fortunately, the left common carotid artery is generally less atheromatous, making its cannulation easy and safe. Cannulation of the left subclavian artery is sometimes dangerous because it often has the most severe atheromatous changes of the three arch vessels. In these situations, cannulation must be carefully performed, or patients must be cooled to below 22° to 23°C and the left subclavian artery left uncannulated.

Atheroma in the ascending aorta and the aortic arch is another potential source of emboli to the brain. Atheromatous change in the ascending aorta and the arch should be assessed by preoperative computed tomography or epiaortic echo examination, and ascending aortic cannulation for CPB should be carefully performed. The impact of right axillary artery perfusion on cerebral safety in TAR has been elucidated in this study.

In addition, since 2000 we have used a unique stepwise technique for easy and secure anastomosis [11, 12]. With this technique, distal anastomosis has become much easier, with good exposure of the anastomosis site even in difficult aneurysms extending distally. In TAR through a median approach, the distal anastomosis is a key aspect. One shortcoming of the stepwise anastomosis is the need for another graft-to-graft anastomosis, but this normally takes only 5 to 10 minutes. Another is the possibility of dislodgement of atheroma in the descending aorta. One patient who experienced bowel necrosis a few days after surgery required resection of the gut.

However, we believe the stepwise anastomosis technique is useful and safe overall, particularly for aneurysms extending distally, and consequently will improve the overall outcome of integrated TAR with SCP and right axillary artery perfusion. The recent outcome of integrated TAR using SCP with right axillary artery cannulation was satisfactory, with low hospital mortality and cerebral morbidity rates.

## References

1. Bachet J, Guilmet D, Goudout B, et al. Antegrade cerebral perfusion in operations on the proximal thoracic aorta. *Ann Thorac Surg* 1999;67:1874-8.
2. Kazui T, Washiyama N, Muhammad BA, et al. Total arch replacement using aortic arch branched grafts with the aid of antegrade selective cerebral perfusion. *Ann Thorac Surg* 2000;70:3-8.
3. Kazui T, Washiyama N, Muhammad BA, Terada H, Yamashita K, Takinami M. Improved results of atherosclerotic arch aneurysm operations with a refined technique. *J Thorac Cardiovasc Surg* 2001;121:491-9.
4. Kazui T, Yamashita K, Washiyama N, et al. Usefulness of antegrade selective cerebral perfusion during aortic arch operations. *Ann Thorac Surg* 2002;74:S1806-9.
5. Okita Y, Takamoto S, Ando M, Morota T, Matsukawa R, Kawashima Y. Mortality and cerebral outcome in patients who underwent aortic arch operations using deep hypothermic circulatory arrest with retrograde cerebral perfusion: no relation of early death, stroke, and delirium to the duration of circulatory arrest. *J Thorac Cardiovasc Surg* 1998;115:129-38.
6. Okita Y, Ando M, Minatoya K, Kitamura S, Takamoto S, Nakajima N. Predictive factors for mortality and cerebral complications in atherosclerotic aneurysm of the aortic arch. *Ann Thorac Surg* 1999;67:72-8.
7. Strauch JT, Spielvogel D, Griep RB, et al. Technical advances in total arch aortic replacement. *Ann Thorac Surg* 2004;77:581-90.
8. Ueda Y, Miki S, Ogino H, et al. Protective effect of continuous retrograde cerebral perfusion on the brain during deep hypothermic systemic circulatory arrest. *J Cardiac Surg* 1994;9:584-95.
9. Numata S, Ogino H, Ando M, et al. Total arch replacement using antegrade selective cerebral perfusion with right axillary artery perfusion. *Euro J Cardiothorac Surg* 2003;23:771-5.
10. Ogino H, Ando M, Sasaki H, Minatoya K. Total arch replacement using a stepwise distal anastomosis for arch aneurysms with distal extension. *Eur J Cardiothorac Surg* 2006;29:255-7.
11. Minatoya K, Ogino H, Matsuda H, Sasaki H, Yagihara T, Kitamura S. Surgical management of distal arch aneurysm: another approach with improved results. *Ann Thorac Surg* 2006;81:1353-7.
12. Ergin MA, Galla JD, Lansman SL, Quintann C, Bodian C, Griep RB. Hypothermic circulatory arrest in operations on the thoracic aorta: determinants of operative mortality and neurologic outcome. *J Thorac Cardiovasc Surg* 1994;107:788-99.
13. Coselli JS, LeMaire SA. Experience with retrograde cerebral perfusion during proximal aortic surgery in 290 patients. *J Card Surg* 1997;12(Suppl):322-5.
14. Bavaria JE, Pochettino A. Retrograde cerebral perfusion in aortic arch surgery: efficacy and possible mechanisms of brain protection. *Semin Thorac Cardiovasc Surg* 1997;9:222-32.
15. Usui A, Abe T, Murase M. Early clinical results of retrograde cerebral perfusion for aortic arch operations in Japan. *Ann Thorac Surg* 1996;62:94-104.

16. Ogino H, Ueda Y, Sugita T, et al. Monitoring of regional cerebral oxygenation by near-infrared spectroscopy during continuous retrograde cerebral perfusion for aortic arch surgery. *Euro J Cardiothorac Surg* 1998;14:415-8.
17. Reich DL, Uysal S, Griep RB, et al. Neuropsychologic outcome after deep hypothermic circulatory arrest in adults. *J Thorac Cardiovasc Surg* 1999;177:156-63.
18. Ergin MA, Uysal S, Griep RB, et al. Temporary neurological dysfunction after deep hypothermic circulatory arrest: a clinical marker of long-term functional deficit. *Ann Thorac Surg* 1999;67:1887-90.
19. Westaby S, Katsumata T. Proximal aortic perfusion for complex arch and descending aortic disease. *J Thorac Cardiovasc Surg* 1998;115:162-7.
20. Jacobs MJ, deMol BA, Veldman DJ. Aortic arch and proximal supraaortic arterial repair under continuous antegrade cerebral perfusion and moderate hypothermia. *Cardiovasc Surg* 2001;9:396-402.
21. Di Eusanio M, Schepens MA, Kazui T, et al. Brain protection using antegrade selective cerebral perfusion: a multicenter study. *Ann Thorac Surg* 2003;76:1181-9.
22. Spielvogel D, Halstead JC, Griep RB, et al. Aortic arch replacement using a trifurcated graft: simple, versatile, and safe. *Ann Thorac Surg* 2005;80:90-5.
23. Kouchoukos NT, Masetti P. Total aortic arch replacement with a branched graft and limited circulatory arrest of the brain. *J Thorac Cardiovasc Surg* 2005;129:1207-8.



# Aortic Arch Replacement Using Selective Cerebral Perfusion

Teruhisa Kazui, MD, PhD, Katsushi Yamashita, MD, PhD, Naoki Washiyama, MD, PhD, Hitoshi Terada, MD, PhD, Abul Hasan Muhammad Bashar, MBBS, PhD, Kazuchika Suzuki, MD, PhD, and Takayasu Suzuki, MD

First Department of Surgery, Hamamatsu University School of Medicine, Hamamatsu, Japan

**Background.** The present study was conducted to report our clinical experience with aortic arch replacement using selective cerebral perfusion (SCP) and determine the independent predictors of in-hospital mortality and neurologic outcome.

**Methods.** We studied 472 consecutive patients who underwent aortic arch replacement using SCP between January 1986 and February 2006. All operations were performed with the aid of hypothermic extracorporeal circulation, SCP, and in most cases, systemic circulatory arrest for open distal anastomosis. The etiology of aortic diseases included acute aortic dissection in 126 patients (27%), chronic aortic dissection in 102 (21%), and degenerative aneurysm in 245 (52%). Total arch replacement was performed in 420 patients (89%). Mean SCP time was  $88 \pm 32$  minutes.

**Results.** The overall in-hospital mortality was 9.3%, but it dropped significantly to 4.1% in the most recent 266

patients. Independent predictors of in-hospital mortality were early series, renal/mesenteric ischemia, pump time, increasing age, chronic renal dysfunction, history of cerebrovascular accident (CVA), and previous ascending or arch operation. Overall postoperative temporary and permanent neurologic dysfunction were 4.7% and 3.2%, respectively. A history of CVA was the only predictor of temporary neurologic dysfunction, whereas CVA and pump time were independent predictors of permanent neurologic dysfunction. SCP time had no significant correlation with in-hospital mortality and neurologic outcome.

**Conclusions.** SCP facilitates complicated aortic arch replacement, resulting in a reduction of mortality and morbidity for arch aneurysms or dissections.

(Ann Thorac Surg 2007;83:S796-8)

© 2007 by The Society of Thoracic Surgeons

It is essential to select optimal strategies for cerebral protection and surgical technique of arch repair to improve the surgical outcome of arch aneurysms or dissections. Antegrade selective cerebral perfusion (SCP) has been the cerebral protection method of choice at our institution if the required cerebral protection time will exceed 30 minutes [1-4].

The aim of the present study was to report the clinical experience with SCP during aortic arch replacement and to determine the independent predictors of in-hospital mortality and neurologic outcome.

## Material and Methods

This was a retrospective study in which individual patient data were not revealed. For this type of study, individual patient consent and institutional approval are waived.

Between January 1986 and February 2006, 589 patients were operated on for arch aneurysm or dissection using hypothermic cardiopulmonary bypass (CPB), and deep

hypothermic circulatory arrest (DHCA), with or without retrograde cerebral perfusion (RCP) or antegrade SCP. Included in this study are 472 patients (79%) who received the operation with the aid of SCP. Their mean age was  $64 \pm 13$  years (range, 18 to 92 years), and 65% were men. A total of 126 patients (27%) were treated for acute dissection, 102 (21%) for chronic dissection, and 245 (52%) for degenerative and atherosclerotic aneurysm. Emergent operations were performed on 138 patients (29%) within 24 hours of admission for rupture of their aneurysm or acute dissection.

Preoperative complications included shock in 40 patients (8.5%), chronic obstructive pulmonary disease in 44 (9.3%), a history of cerebrovascular accident in 70 (14.8%), coronary artery disease in 68 (14.4%), and chronic renal dysfunction in 49 (10.4%), with 12 (2.5%) requiring hemodialysis. Aortic dissection-related complications included cardiac tamponade in 52 (11.0%), myocardial ischemia in 10 (2.1%), cerebral ischemia in 13 (2.8%), renal/mesenteric ischemia in 12 (2.5%), and leg ischemia in 17 (3.6%). Eighty patients (17%) had undergone previous cardiovascular procedures.

In all elective cases, preoperative cerebral four-vessel (bilateral internal carotid and vertebral artery) angiography, cerebral computed tomographic scanning, or magnetic resonance imaging were performed to rule out

Presented at Aortic Surgery Symposium X, New York, NY, April 27-28, 2006.

Address correspondence to Dr Kazui, First Department of Surgery, Hamamatsu University School of Medicine, 1-20-1 Handayama, Hamamatsu 431-3192, Japan; e-mail: tkazui@hama-med.ac.jp.

© 2007 by The Society of Thoracic Surgeons  
Published by Elsevier Inc

0003-4975/07/\$32.00  
doi:10.1016/j.athoracsur.2006.10.082

cerebrovascular disease and to select the site of cerebral perfusion.

Operations were performed through a median sternotomy in 446 patients (94%) and through median sternotomy with opening of the left pleura in 13 (3%). A left anterior thoracotomy was used in 13 (3%) for an extended descending aortic replacement. The site of arterial cannulation for CPB in most of the recent cases was the ascending aorta, and the right axillary artery was used when necessary.

The details of hypothermic CPB and antegrade SCP have been described previously [1, 3]. Briefly, systemic circulation is arrested when the patient is cooled by extracorporeal circulation to a rectal temperature of 25°C (usually dropping later to 22°C). Both innominate and left common carotid arteries are cannulated and are perfused at a rate of 10 mL/(kg · min) by a single pump. The left subclavian artery is kept cross-clamped during SCP, except in cases where an additional left subclavian artery perfusion is performed: (1) occlusion of the right vertebral artery, (2) lack of efficient intracranial arterial communication, or (3) dominant left vertebral artery. The right radial arterial pressure and bilateral catheter tip pressure are adjusted to about 40 mm Hg to regulate perfusion pressure. During CPB, arterial blood pH is managed according to the  $\alpha$ -stat strategy.

More recently, unilateral cerebral perfusion through the right axillary artery instead of bilateral cerebral perfusion has been used in selected patients undergoing hemiarch replacement for acute type-A aortic dissection. CPB is instituted through the right axillary artery. After cooling to a rectal temperature of 20°C, both innominate and left common carotid arteries are cross-clamped at their origins, and systemic circulatory arrest is induced.

Table 1. Surgical Technique

Technique/Procedure	No. (%)
<b>Surgical technique</b>	
Patch aortoplasty	3 (1)
AAR + HAR	49 (10)
AAR + TAR	225 (48)
AAR + TAR + DAR	168 (35)
TAR	19 (4)
TAR + DAR	8 (2)
Total TAR	420 (89)
<b>Concomitant procedures</b>	
Composite graft replacement (redo)	55 (8)
CABG	64
AVR	18
AV resuspension	27
MVR/MAP	5
AAA repair	3
Miscellaneous	9

AAA = abdominal aortic aneurysm; AAR = ascending aortic replacement; AV = aortic valve; AVR = aortic valve replacement; CABG = coronary artery bypass grafting; DAR = descending aortic replacement; HAR = hemiarch replacement; MVR/MAP = mitral valve replacement/mitral annuloplasty; Redo = redo composite graft replacement; TAR = total arch replacement.

Table 2. Independent Predictors for In-Hospital Mortality and Neurologic Outcome

Independent Variables	OR (95% CI)	p Value
<b>In-hospital mortality</b>		
Early series	7.122 (2.83, 17.9)	<0.0001
Renal/mesenteric ischemia	35.68 (16.56, 194.2)	<0.0001
Pump time	1.010 (1.005, 1.015)	0.0002
Increasing age	1.075 (1.029, 1.122)	0.0012
Chronic renal dysfunction	3.413 (1.33, 8.75)	0.0107
History of CVA	2.896 (1.20, 7.00)	0.0182
Previous ascending/arch operation	3.934 (1.19, 13.0)	0.0250
<b>Temporary neurologic dysfunction</b>		
History of CVA	3.42 (1.36, 8.64)	0.0092
<b>Permanent neurologic dysfunction</b>		
History of CVA	12.32 (3.92, 38.8)	<0.0001
Pump time	1.009 (1.004, 1.015)	0.0017

CI = confidence interval; CVA = cerebrovascular accident; OR = odds ratio.

Then, unilateral cerebral perfusion through the right axillary artery is maintained at a flow rate of 5 to 10 mL/(kg · min). The number of arch vessels used for SCP in our series was a single vessel in 24 patients (5%), two vessels in 438 (93%), and three vessels in 10 (2%).

Real-time intraoperative monitoring of SCP includes perfusion pressure and flow rates, two-channel serial electroencephalography, and two-channel near-infrared spectroscopy. If available, internal jugular venous oxygen saturation and transcranial Doppler sonography are also used.

Open distal anastomosis has been used in 98% of patients since March 1987. Operative techniques used in this series are listed in Table 1. Patch angioplasty of the aortic arch was used in the initial 3 patients (1%), and graft replacement was performed in the remaining 469 (99%). Ascending aortic replacement (AAR) and hemiarch replacement (HAR) were performed in 49 patients (10%); AAR and total arch replacement (TAR) in 225 patients (48%); AAR, TAR, and descending aortic replacement (DAR) in 168 (35%); isolated TAR in 19 patients (4%), and TAR and DAR in 8 patients (2%). Overall, TAR was performed in 420 patients (89%). TAR with a concomitant elephant trunk technique was performed in 63 patients (13%).

The en bloc repair or island technique for TAR was used in the initial 21 patients (5%), and the remaining 399 patients (95%) underwent the separated graft technique in which an aortic arch branched graft was used. A total of 166 patients (35%) had 181 concomitant procedures, which are summarized in Table 1.

## Results

The overall in-hospital mortality was 9.3% (44/472). In-hospital mortality was 16.0% in the early series (1986 to

1996) of 206 patients and 4.1% ( $n = 11$ ) in the 266 patients in the late series (1997 to 2006;  $p < 0.001$ ), even with the inclusion of emergent cases. Table 2 summarizes the independent predictors of in-hospital death as estimated by multivariable step-wise logistic regression analysis. It revealed that early series, renal/mesenteric ischemia owing to acute dissection, pump time, increasing age, chronic renal dysfunction, history of CVA, and previous ascending/arch operation were significant independent predictors of in-hospital mortality.

The overall postoperative temporary and permanent neurologic dysfunction rates were 4.7% and 3.2% in the early series and 4.9% and 3.8%, respectively, in the late series (NS). Multivariable analysis indicated that a history of CVA was the only independent predictor of temporary neurologic dysfunction, and CVA and pump time were independent predictors of permanent neurologic dysfunction (Table 2).

Mean SCP time was  $88.2 \pm 32.2$  minutes. There was no significant correlation between SCP time and in-hospital mortality or neurologic outcome.

### Comment

Cerebral protection methods currently used are DHCA with or without RCP, and antegrade SCP. Several experimental and clinical studies indicate that antegrade SCP presents several advantages compared with DHCA with or without RCP. Antegrade SCP can extend the safe duration of circulatory arrest up to 90 minutes [5], allowing meticulous aortic arch repair and facilitating the complex and time-consuming TAR. SCP obviates the need for deep hypothermia, thus reducing pump time and the risk of hypothermia-related complications such as pulmonary insufficiency and coagulopathy. SCP is more effective in supplying oxygenated blood to the brain, thus ensuring a more physiologic brain energy metabolism. SCP is therefore considered to be the most reliable method of preventing ischemic injury to the brain.

A suggested major drawback of SCP is the risk of cerebral embolism or malperfusion while cannulating the arch vessels. But complications related to arch vessel cannulation can be completely avoided by transecting each arch vessel 1 cm distal to its origin, where it is free from atheroma or dissection, and by cannulating it through the arteriotomy under direct vision.

In our series, the sites of arch vessel cannulation for SCP were the innominate or right axillary artery and the left common carotid artery. In principle, however, selec-

tion of cannulation sites is determined by the pathophysiology of the intracerebral and extracerebral arterial system as well as the expected duration of cerebral protection, which is related to the underlying disease and the extent of aortic replacement. Using this integrated cerebral protection method of SCP with systemic circulatory arrest, we were able to perform TAR in a more aggressive manner to include even the acute aortic dissection cases and to extend aortic replacement down to the mid-descending aorta through a median sternotomy alone.

We prefer the separated graft TAR technique to the en bloc technique because it presents several advantages:

1. in aged patients, atherosclerotic lesions near the origin of the arch vessels can be completely resected;
2. in patients with acute dissection, graft anastomoses can be performed at the intact distal sites of the arch vessel where dissection has not extended;
3. the pathologic portion of the aortic arch can be completely resected in Marfan patients; and
4. bleeding from the site of the arch vessel anastomoses can be controlled easily.

The average SCP time was 88 minutes in the present series, and it had no significant correlation with in-hospital mortality or neurologic outcome.

In summary, with the refined use of antegrade SCP and the separated graft technique, we could substantially reduce in-hospital mortality and neurologic complications in recent patients with arch aneurysm or dissection.

### References

1. Kazui T, Washiyama N, Bashar AHM, et al. Total arch replacement using aortic arch branched grafts with the aid of antegrade selective cerebral perfusion. *Ann Thorac Surg* 2000;70:3-9.
2. Kazui T, Washiyama N, Bashar AHM, et al. Extended total arch replacement for acute type A aortic dissection: experience with seventy patients. *J Thorac Cardiovasc Surg* 2000;119:558-65.
3. Kazui T, Washiyama N, Bashar AHM, Terada H, Yamashita K, Takinami M. Improved results of atherosclerotic arch aneurysm operations with a refined technique. *J Thorac Cardiovasc Surg* 2001;121:491-9.
4. Kazui T, Yamashita K, Washiyama N, et al. Usefulness of antegrade selective cerebral perfusion during aortic arch operations. *Ann Thorac Surg* 2002;74:S1806-9.
5. Sakurada T, Kazui T, Tanaka H, Komatsu S. Comparative experimental study of cerebral protection during aortic arch reconstruction. *Ann Thorac Surg* 1996;61:1348-54.

# Effect of prophylactically administered edaravone during antegrade cerebral perfusion in a canine model of old cerebral infarction

Takayasu Suzuki, MD,<sup>a</sup> Teruhisa Kazui, MD, PhD,<sup>a</sup> Seiji Yamamoto, MD, PhD,<sup>b</sup> Naoki Washiyama, MD, PhD,<sup>a</sup> Kazuhiro Ohkura, MD, PhD,<sup>a</sup> Kentaro Ohishi, PhD,<sup>b</sup> Abul Hasan Muhammad Bashar, MBBS, PhD,<sup>a</sup> Katsushi Yamashita, MD, PhD,<sup>a</sup> Hitoshi Terada, MD, PhD,<sup>a</sup> Kazuchika Suzuki, MD, PhD,<sup>a</sup> Satoshi Akuzawa, MD,<sup>a</sup> and Michio Fujie, MS<sup>c</sup>

**Objective:** Reactive free radical species are thought to be involved in postoperative neurologic dysfunction after antegrade selective cerebral perfusion in brains with old infarction. We assessed the brain protective effect of prophylactically administered edaravone, a free radical scavenger, for antegrade selective cerebral perfusion in brains with or without old infarction in a canine model.

**Methods:** A canine model of old cerebral infarction was created by injecting cylindrical silicone embolus into the middle cerebral artery. Animals showing obvious neurologic deficits and surviving 4 weeks or longer were included in the model. Deep hypothermia with antegrade selective cerebral perfusion was performed in both intact (non-edaravone, group A; edaravone-treated, group B) and infarcted animals (non-edaravone, group C; edaravone-treated, group D). Serum concentrations of malondialdehyde, hexanoyl-lysine, glutamate, and venous-arterial lactate difference were measured, and central conduction time and amplitude of somatosensory evoked potentials were assessed during the operation.

**Results:** Compared with the intact groups, serum concentrations of malondialdehyde and hexanoyl-lysine in group C significantly increased at the end of antegrade selective cerebral perfusion, whereas that of glutamate did so in the rewarming phase. Increases in all these biochemical parameters were suppressed in group D. In group C, the venous-arterial lactate difference was significantly greater in the rewarming phase at 28°C compared with intact groups. A significant prolongation of postoperative central conduction time and decrease in neuronal activity were detected in group C, both of which recovered in group D.

**Conclusion:** Prophylactic administration of edaravone exerted a significant protective effect against postoperative neurologic dysfunction after antegrade selective cerebral perfusion in a canine model with old cerebral infarction.

From the First Department of Surgery,<sup>a</sup> Photon Medical Research Center,<sup>b</sup> and Research Equipment Center,<sup>c</sup> Hamamatsu University School of Medicine, Hamamatsu, Japan.

Received for publication Aug 10, 2006; revisions received Oct 9, 2006; accepted for publication Oct 30, 2006.

Address for reprints: Takayasu Suzuki, MD, The First Department of Surgery, Hamamatsu University School of Medicine, 1-20-1 Handayama, Hamamatsu, 431-3192, Japan (E-mail: tac.sz@hama-med.ac.jp).

J Thorac Cardiovasc Surg 2007;133:710-6  
0022-5223/\$32.00

Copyright © 2007 by The American Association for Thoracic Surgery

doi:10.1016/j.jtcvs.2006.10.032

Postoperative neurologic dysfunction is one of the most serious complications after aortic arch operation. The incidence of this complication has decreased in recent times because of improvements in operative techniques and cerebral protection methods.<sup>1</sup> Antegrade selective cerebral perfusion (ASCP) has been found to be the safest method of brain protection during aortic arch surgery with respect to energy metabolism and time limitation.<sup>2,3</sup> Clinical practice has indicated that ASCP can reduce cerebral injury during aortic arch operation more effectively compared with other methods for cerebral protection, including deep hypothermic circulatory arrest with or without retrograde cerebral perfusion.<sup>4</sup> Although our total arch replacement assisted with ASCP has resulted in a lower rate of mortality and morbidity,<sup>5</sup> a multivariable analysis of 220 patients revealed that a history of

**Abbreviations and Acronyms**

ASCP	= antegrade selective cerebral perfusion
CCT	= central conduction time
CPB	= cardiopulmonary bypass
HEL	= hexanoyl-lysine
MDA	= malondialdehyde
VALD	= venous-arterial lactate difference

cerebral infarction should be regarded as an independent predictor of postoperative neurologic dysfunction.<sup>6</sup>

Our previous canine studies showed that ASCP in animals with old cerebral infarction induced ischemic neurologic damage and that it increased the production of free radicals, suggesting oxidative damage in the peri-infarct region of the brain.<sup>7,8</sup> Many previous reports described accelerated production of free radicals in acute cerebral infarction resulting in neurologic damage, and free radical scavenger has already been found to be effective in attenuating such neurologic damage in clinical situations.<sup>9,10</sup> Similarly, a recent experimental study from our laboratory documented that edaravone (Mitsubishi Pharma Co, Tokyo, Japan), a commercially available free radical scavenger, was effective in attenuating acute ischemic neurologic damage in the rabbit spinal cord.<sup>11</sup> However, the exact relationship between free radicals and old cerebral infarction is unknown. A pharmacologic agent with a similar protective effect on brains with old cerebral infarct can be of great clinical relevance during an aortic arch operation with ASCP. Therefore, in the present study, we assessed the neuroprotective effect of prophylactically administered edaravone for ASCP in brains with or without old cerebral infarction in a canine model.

**Materials and Methods**

The study was approved by the Animal Care and Use Committee of Hamamatsu University School of Medicine. All animals received human care in compliance with the "Guide for the Care and Use of Laboratory Animals," published by the National Institutes of Health (NIH publication 85-23, revised 1985), and the "Guidelines for Animal Experimentation," formulated by Hamamatsu University School of Medicine (published 1987, revised 1991).

**Cerebral Infarct Model**

Our technique of creating a cerebral infarct model has been described.<sup>7</sup> In short, the left common carotid artery with its bifurcation was surgically exposed, and a cylindrical silicone embolus was injected into the left internal carotid artery. Nonvisualization of the left middle cerebral artery in the subsequent angiogram suggested that the embolus was located in the proximal left middle cerebral artery. Twelve hours later, the dogs were evaluated with a neurologic scoring system consisting of 5 grades (score 0: no neurologic deficit; score 1: walks with limp or circles to the side of lesion; score 2: walks poorly and stands but cannot support the body with

a left limb held off the ground; score 3: cannot stand without support; and score 4: dead).<sup>12</sup> Only the dogs with neurologic scores of 2 and 3, and surviving 4 weeks or longer were included in the cerebral infarct model.

**Animal Preparation**

After general anesthesia with an intravenous injection of pentobarbital sodium (30 mg/kg), mechanical ventilation was started. A 19-gauge detaining needle was inserted into the right brachial artery for blood sampling and blood pressure monitoring. A 4F catheter was placed into the right maxillary vein for sampling of venous blood for blood gas analysis and lactate measurement. An additional dose of pentobarbital sodium (15 mg/kg) was given before the beginning of rewarming.

**Cardiopulmonary Bypass**

After median sternotomy and full heparinization (300 U/kg), cardiopulmonary bypass (CPB) was instituted by inserting the arterial cannula into the ascending aorta, and the venous cannulae into the superior and inferior vena cavae. The perfusion system, consisting of a roller pump and membrane oxygenator (Senkoika Corp, Tokyo, Japan), was primed with lactated Ringer solution. A second dose of heparin (150 U/kg) was added before the beginning of rewarming. Alpha-stat strategy was used for blood pH management.

**Measurement of Somatosensory Evoked Potentials**

Single-channel recordings were obtained on a Nicolet Compact Four/CA 2000 (Nicolet JAPAN Corp, Tokyo, Japan). Three needle electrodes were positioned: the first over the head approximately 2 cm dorsal to the coronal suture, the second in the upper right-hand side of the sternum, and the third (the reference electrode) on the right shoulder. The median nerve of the right forelimb was exposed and stimulated with a bipolar stimulator. The pulse duration used was 100 msec, and the strength of the stimulating current was 2 to 5 mA with a frequency of 5.1 Hz. A total of 300 responses were obtained and averaged with automatic artifact rejection by setting the filter between approximately 5 and 1000 Hz. The central conduction time (CCT), indicating the transmission time of neuronal activity in the brain, was measured as an interpeak latency of N2 (the second negative wave) and N4 (the fourth negative wave). The amplitude ratio between N4 and N1 (the first negative wave), an indicator of neuronal activity in the sensory cortex, was calculated. The preoperative and postoperative values were compared.

**Experimental Protocol**

Twenty-four female mongrel dogs were divided into the following 4 groups: group A, intact, non-edaravone group (n = 6); group B, intact, edaravone-treated group (n = 6); group C, infarct, non-edaravone group (n = 6); and group D, infarct, edaravone-treated group (n = 6). Animals of all 4 groups underwent deep hypothermia with ASCP. CPB flow was maintained at approximately 50 to 80 mL/kg/min in accordance with the amount of venous return. After the animals were cooled to a rectal temperature of 20°C, ASCP was initiated at a flow rate of 10 mL/kg/min by clamping the proximal ascending aorta, the left subclavian artery, and the descending aorta. The lower half of the body was not perfused

during ASCP. After 120 minutes of ASCP, CPB was returned to its original flow rate. Then, rewarming to a rectal temperature of 36°C was performed. Differences between the rectal and arterial temperatures were always kept within 5°C in both cooling and rewarming phases.

### Drug Delivery Protocol

In the edaravone-treated groups, first, edaravone 1.5 mg/kg in 100 mL normal saline solution was dripped into the extracorporeal circuit just before the beginning of cooling. Because it takes approximately 30 minutes to obtain a steady plasma level of edaravone after its intravenous injection, we made sure that the first dose of edaravone was completed 30 minutes before the initiation of ASCP.<sup>13</sup> To ensure a stable plasma level of the drug until the end of the experiment, a second dose of edaravone (1.5 mg/kg) was added to the circuit in the same method 30 minutes after the first. For the non-edaravone group, only 100 mL of normal saline solution without edaravone was administered into the circuit at the same time points.

### Protocol for Blood Biochemistry

Blood samples were obtained on the following 8 occasions: (1) before the operation; (2) 5 minutes after the initiation of CPB; (3) on reaching a rectal temperature of 28°C in the cooling phase; (4) on reaching a rectal temperature of 20°C in the cooling phase; (5) 60 minutes after the initiation of ASCP; (6) at the end of ASCP; (7) on reaching a rectal temperature of 28°C in the rewarming phase; and (8) on reaching a rectal temperature of 36°C in the rewarming phase. Sampled blood was centrifuged, and protein was extracted from the serum. Malondialdehyde (MDA), a marker of free radical production and lipid peroxidation of membrane polyunsaturated fatty acid, was measured by means of thiobarbituric acid fluorescence (FP-777; Nihon Bunko, Tokyo, Japan).<sup>14,15</sup> Hexanoyl-lysine (HEL) formed by the reaction between linoleic acid hydroperoxide and lysine is another biomarker of oxidative stress, which was measured by the enzyme-linked immunosorbent assay method using the HEL adduct enzyme-linked immunosorbent assay kit (Japan Institute for the Control of Aging, Shizuoka, Japan).<sup>16,17</sup> Serum glutamate, a biomarker of neural cell damage, was measured on a column packed with reverse-phase support with a special device (PICO-TAG; Waters Corp, Milford, Mass). Blood lactate was measured using a blood gas analyzer (Stat Profile Ultra M; Nova Biomedical Corp, Tokyo, Japan), and the venous-arterial lactate difference (VALD) was calculated.

### Statistical Analysis

All values are expressed as means  $\pm$  standard error. One-way analysis of variance was used for comparison among the groups. When the 1-way analysis of variance showed a significant difference ( $P < .05$ ), we compared the 2 groups by using the Tukey honestly significant difference test.

### Results

Important preoperative and intraoperative data are shown in Table 1. There were no significant differences in the preoperative physiologic variables and the intraoperative data among the groups.

### Blood Biochemistry

The preoperative biochemical parameters did not show any significant differences among the groups. Serum concentration of MDA in group C was significantly higher than that in the intact groups (groups A and B) at the end of ASCP ( $P = .012$ ). In addition, the level was significantly higher in comparison with that in groups A and B, as well as that in group D in the rewarming phase ( $P = .047$  at 28°C;  $P = .003$  at 36°C) (Figure 1). In group C, the serum concentration of HEL became significantly higher compared with that in groups A and B, and group D at the end of ASCP, with the differences continuing to widen until the end of the experiment ( $P = .005$  at the end of ASCP;  $P = .0013$  at 28°C;  $P = .0001$  at 36°C) (Figure 2). Serum concentrations of glutamate in group C were significantly higher in comparison with groups A and B, and group D during the rewarming phase ( $P = .001$  at 28°C,  $P = .0006$  at 36°C) (Figure 3). In group C, VALD was significantly greater than that in the intact groups at 28°C in the rewarming phase ( $P = .0082$ ), although the difference was not significant when compared with group D (Figure 4). However, the 2 intact groups did not differ significantly with regard to the above parameters. Likewise, values in group D were not significantly different when compared with those in the intact groups.

### Somatosensory Evoked Potentials

The preoperative CCT and N4/N1 amplitude ratio did not show any difference among the groups. In group C, the postoperative CCT was significantly prolonged compared with that in the intact groups (A and B) and group D (group A, 109%  $\pm$  3.6%; group B, 98.7%  $\pm$  4.1%; group C, 195.6%  $\pm$  25.7%; group D, 142.3%  $\pm$  5.4%;  $P = .0002$ ) (Figure 5). Moreover, in group C, the postoperative N4/N1 amplitude ratio decreased significantly compared with that in the intact groups and group D (group A, 90.2%  $\pm$  7.1%; group B, 101%  $\pm$  7.1%; group C, 30.8%  $\pm$  8.1%; group D, 60.9%  $\pm$  5.3%;  $P < .0001$ ). No significant differences were noted between the 2 intact groups with regard to the postoperative CCT and N4/N1 amplitude ratio. Values in group D were also not significantly different compared with those in the intact groups.

### Discussion

In brains with old infarction, ischemia can occur in the peri-infarct area, where the baseline blood flow is low. Such regions are known as chronic penumbra, which are nourished by collateral blood flow.<sup>18</sup> In the present study, we maintained a cerebral perfusion flow of 10 mL/kg per minute (perfusion pressure 40–50 mm Hg) during ASCP, which is consistent with our clinical practice. This perfusion flow is adequate for normal brains because they have a wider safety margin for cerebral ischemia.<sup>19</sup> However, the

TABLE 1. Preoperative and intraoperative data

	Intact group		Infarct group		P value*
	Group A (non-edaravone)	Group B (edaravone-treated)	Group C (non-edaravone)	Group D (edaravone-treated)	
Age (mo)	13.3 ± 0.7	13.7 ± 1.0	15.2 ± 0.6	15.8 ± 0.5	.06
Body weight (kg)	13.8 ± 0.7	13.1 ± 0.9	13.9 ± 0.8	13.6 ± 1.7	.90
Duration after CI (mo)	—	—	3.5 ± 0.4	4.0 ± 0.3	.26
Preoperative Ht (%)	35.5 ± 1.3	33.8 ± 1.2	36.5 ± 1.9	34.3 ± 1.3	.57
MAP (mm Hg)					
Preoperative	135.3 ± 9.3	127.5 ± 3.8	134.3 ± 3.6	129.5 ± 8.5	.82
On CPB	76.2 ± 4.7	74.5 ± 3.3	77.2 ± 4.2	75.8 ± 2.4	.97
Cooling 28°C	66.5 ± 3.9	65.2 ± 3.4	66.8 ± 4.3	62.3 ± 4.5	.86
Cooling 20°C	59.5 ± 2.7	56.5 ± 2.9	60.2 ± 2.8	59.7 ± 4.0	.84
ASCP 60 min	43.5 ± 2.3	42.3 ± 2.0	43.0 ± 4.6	44.2 ± 3.3	.98
End of ASCP	49.0 ± 5.1	46.0 ± 3.4	45.8 ± 3.8	43.2 ± 2.8	.77
Rewarming 28°C	75.3 ± 6.0	74.8 ± 5.2	75.0 ± 6.7	69.5 ± 3.2	.85
Rewarming 36°C	78.2 ± 3.8	73.3 ± 2.6	74.8 ± 5.7	72.2 ± 4.6	.78
Pao <sub>2</sub> (mm Hg)					
Preoperative	106.5 ± 7.5	104.1 ± 7.2	115.8 ± 36.2	103.5 ± 11.8	.84
On CPB	272.3 ± 72.4	161.9 ± 20.8	214.6 ± 50.4	248.3 ± 66.2	.55
Cooling 28°C	347.4 ± 64.1	396.9 ± 53.8	469.1 ± 61.4	467.0 ± 49.6	.39
Cooling 20°C	735.2 ± 31.2	655.6 ± 21.0	562.9 ± 77.5	679.7 ± 66.7	.19
ASCP 60 min	683.1 ± 61.9	754.7 ± 60.1	792.2 ± 32.8	797.1 ± 25.4	.33
End of ASCP	729.7 ± 32.7	766.7 ± 7.6	688.0 ± 28.7	718.3 ± 40.5	.34
Rewarming 28°C	446.8 ± 41.1	454.8 ± 72.1	498.6 ± 23.4	466.5 ± 21.5	.85
Rewarming 36°C	200.1 ± 53.2	151.3 ± 22.4	203.8 ± 73.9	145.4 ± 28.7	.75
Paco <sub>2</sub> (mm Hg)					
Preoperative	29.2 ± 3.6	33.1 ± 6.5	26.8 ± 4.9	36.0 ± 8.2	.72
On CPB	30.5 ± 2.7	32.4 ± 1.4	35.8 ± 1.3	29.4 ± 1.4	.10
Cooling 28°C	37.2 ± 5.2	41.5 ± 1.5	37.3 ± 1.4	36.4 ± 1.7	.61
Cooling 20°C	35.7 ± 5.3	41.5 ± 2.0	36.5 ± 0.9	36.7 ± 1.6	.46
ASCP 60 min	26.5 ± 2.1	30.9 ± 2.0	34.0 ± 0.8	31.3 ± 2.9	.13
End of ASCP	27.1 ± 1.5	31.9 ± 0.6	32.0 ± 1.5	29.1 ± 2.5	.14
Rewarming 28°C	31.2 ± 3.9	28.1 ± 0.7	28.8 ± 2.9	27.0 ± 0.7	.67
Rewarming 36°C	30.8 ± 4.2	30.5 ± 0.4	29.0 ± 2.4	27.8 ± 2.2	.85
Arterial pH					
Preoperative	7.44 ± 0.02	7.43 ± 0.03	7.46 ± 0.02	7.42 ± 0.01	.48
On CPB	7.38 ± 0.03	7.37 ± 0.02	7.39 ± 0.03	7.37 ± 0.02	.87
Cooling 28°C	7.35 ± 0.03	7.36 ± 0.03	7.34 ± 0.04	7.34 ± 0.02	.95
Cooling 20°C	7.37 ± 0.03	7.37 ± 0.01	7.35 ± 0.04	7.34 ± 0.01	.91
ASCP 60 min	7.37 ± 0.02	7.36 ± 0.02	7.35 ± 0.03	7.35 ± 0.02	.90
End of ASCP	7.36 ± 0.02	7.37 ± 0.01	7.36 ± 0.03	7.37 ± 0.02	.98
Rewarming 28°C	7.36 ± 0.02	7.34 ± 0.01	7.34 ± 0.03	7.36 ± 0.02	.95
Rewarming 36°C	7.37 ± 0.02	7.33 ± 0.02	7.35 ± 0.02	7.36 ± 0.03	.88
Time required (min)					
Cooling	58.2 ± 3.5	54.8 ± 3.8	56.7 ± 2.1	58.6 ± 4.0	.86
Rewarming	75.6 ± 5.3	72.8 ± 3.2	72.7 ± 3.8	75.7 ± 5.7	.94

CI, Cerebral infarction; Ht, hematocrit; MAP, mean artery pressure; CPB, cardiopulmonary bypass; ASCP, antegrade selective cerebral perfusion. \*One-way analysis of variance.

flow may not be adequate for the chronic penumbra region. Ning and colleagues<sup>20</sup> reported an accelerated free radical production in the peri-infarct region after transient focal ischemia in mice brain. Thus, it seems that brain ischemia and the consequent free radical production in the chronic

penumbra region cause neurologic dysfunction after ASCP for brain with old infarction.

It is thought that hypothermic ASCP itself can also give rise to cerebral ischemia, particularly in a setting of old cerebral infarction. The cold perfusion of ASCP may cause

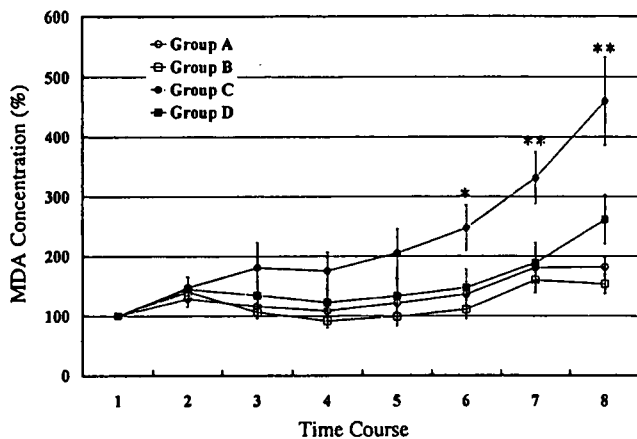


Figure 1. Changes in serum MDA concentration. Values at different time points are expressed as percentages of the preoperative value (see text). In group C, values significantly increased at time points 6 to 8 (\*group C vs groups A and B,  $P < .05$ ; \*\*group C vs groups A, B, and D,  $P < .05$ ). MDA, Malondialdehyde.

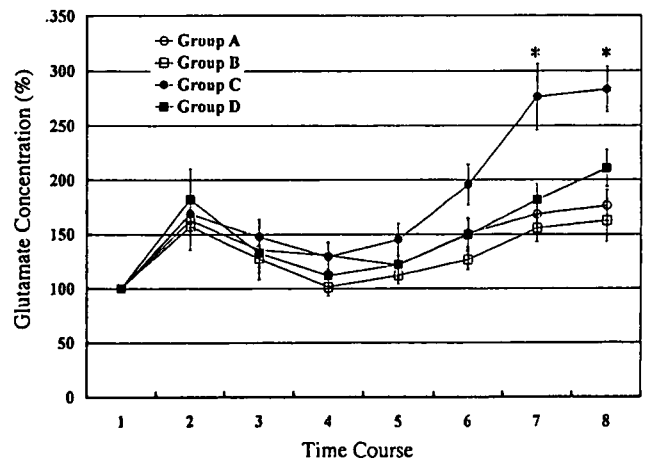


Figure 3. Changes in serum glutamate concentration. Values at different time points are expressed as percentages of the preoperative value (see text). In group C, values significantly increased compared with that in all other groups during the rewarming phase (\*group C vs groups A, B, and D,  $P < .001$ ).

the loss of cerebral autoregulation,<sup>21</sup> which may result in cerebral vasoconstriction. This, in turn, may lead to a global reduction in cerebral blood flow. Moreover, phenomena such as low flow-induced astrocyte edema<sup>22</sup> and cerebral vasospasm may also contribute to a further reduction in cerebral blood flow, particularly at the penumbral region.

Brain ischemia initiates a complex cascade of metabolic events, several of which involve the generation of nitrogen and oxygen free radicals. These free radicals and related reactive chemical species mediate much of the damage that occurs after transient brain ischemia and in the penumbral region of infarcts caused by permanent ischemia.<sup>23</sup> Free

radical species lead to oxidation of lipids, protein, and nucleic acid, which might alter cellular function in a critical way, resulting in neurologic injury and subsequent neurologic dysfunction.<sup>24,25</sup> Aldehydes, such as MDA and 4-hydroxy-2-nonenal, have been well-known products of lipid peroxidation.<sup>14,26</sup> HEL is a novel lipid hydroperoxide-modified lysine residue formed in the earlier stage of lipid peroxidation by oxidative modification of linoleic acid or arachidonic acid.<sup>16,17</sup> To our knowledge, it has not been previously used as a marker of free radical production in a cerebral infarction model. Be-

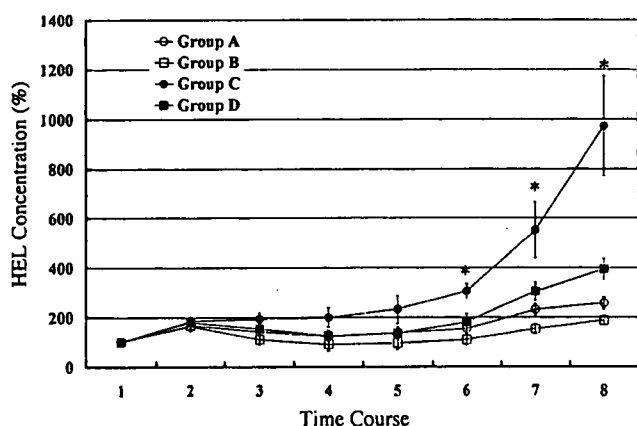


Figure 2. Changes in serum HEL concentration. Values at different time points are expressed as percentages of the preoperative value (see text). In group C, values significantly increased compared with that in all other groups at points 6 to 8 (\*group C vs groups A, B, and D,  $P < .001$ ). HEL, Hexanoyl-lysine.

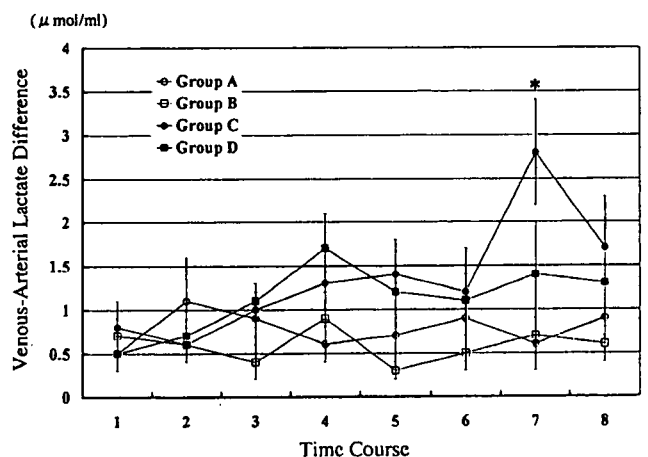
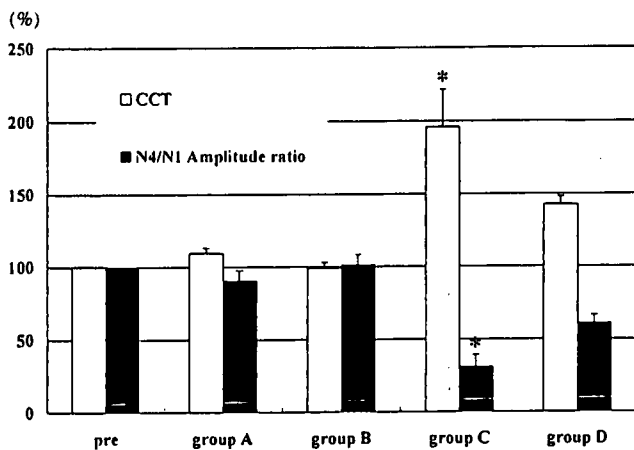


Figure 4. Level of VALD. Values are shown at different time points (see text). In group C, VALD was significantly greater than that in the intact groups at 28°C in the rewarming phase (\*group C vs groups A and B,  $P < .001$ ). VALD, Venous-arterial lactate difference.

CSP





**Figure 5.** Changes in CCT and N4/N1 amplitude ratio. Values are expressed as percentages of the preoperative values (see text). In group C, postoperative CCT was significantly prolonged compared with that in all other groups. The postoperative N4/N1 amplitude ratio in group C decreased significantly compared with that in all other groups (\*group C vs groups A, B, and D,  $P < .0001$ ). CCT, Central conduction time.

cause brain is a fat-rich tissue, we believe that HEL can be a reliable biochemical marker of free radical production induced by ischemic brain injury.

In the present study, the animals in group C (the cerebral infarct group) showed a remarkable increase in serum HEL and MDA at the end of ASCP. These findings suggested that ASCP induced ischemia in brains with old cerebral infarction, which resulted in accelerated free radical production. Moreover, in group C, we observed a prolongation of CCT and a decrease in the N4/N1 amplitude ratio, whereas none of these changes were seen in the intact animals. Previous studies demonstrated that impaired somatosensory evoked potential was associated with cerebral injury in permanent ischemic models.<sup>27,28</sup> Our findings were consistent with the above findings in the sense that we also found brains with old infarction showing functional impairment with acceleration of free radical production caused by ischemia during ASCP, whereas the intact brain showed no such evidence of ischemic damage.

The animals in group D (the edaravone-treated infarct group) showed a reduction in the level of serum MDA and HEL concentrations compared with those in the non-edaravone-treated infarct animals. A decrease in postoperative CCT prolongation and the recovery of postoperative N4/N1 amplitude ratio were also noted in group D, suggesting that free radical scavenging was effective in reducing neurologic dysfunction after ASCP in brains with old infarction. Although the cerebral protective effect of edaravone in acute cerebral ischemia is well described,<sup>9,10,22</sup> to our knowledge, this is the first report

demonstrating the neuroprotective effect of edaravone during CPB for permanent cerebral infarction.

In our study, increasing free radical production was found from the point of ASCP termination until the end of the experiment in group C. Serum glutamate also showed a parallel increase during the rewarming phase in this group. In the rewarming phase, VALD also became greater in group C, perhaps indicating an acceleration of anaerobic glycolysis in the brain tissue.<sup>29</sup> These findings may be explained by neural cell damage being worsened by accelerated free radical production and increased cellular metabolism. It is important to note that the serum concentration of glutamate decreased in the edaravone-treated infarct group (group D) in this study. This suggests that edaravone attenuated ischemic and free radical-mediated neural cell damage and by doing so, reduced neurologic dysfunction that was documented by the results of somatosensory evoked potential examination in group D. From the above results, it is evident that in brains with old infarction, free radical scavenging provides an effective way to attenuate functional and metabolic damage to neural cells within the chronic penumbra region in the rewarming phase after ASCP.

However, the present study has a number of important limitations. Although it can be assumed from the biochemical assessment performed in the present study that brain ischemia causes free radical production in the chronic penumbra region, the actual regional cerebral blood flow during ASCP was not measured. Thus, the relationship between ischemia and free radical-mediated neurologic injury is not directly evident. Transcranial Doppler sonography or near-infrared spectroscopy may be used to measure regional cerebral blood flow.<sup>30</sup> Moreover, we could not perform brain histopathology to document ischemia-induced tissue damage in a graded manner.

## Conclusions

We examined the influences of prophylactic administration of edaravone, a free radical scavenger, on brains with or without old cerebral infarction in dogs undergoing ASCP. Cerebral ischemia occurred during experimental ASCP resulting in postoperative neurologic dysfunction, which was attenuated by prophylactic administration of edaravone. It is therefore expected that prophylactic administration of edaravone could be useful for brain protection in ASCP for high-risk patients with a history of cerebral infarction.

## References

- Di Eusano M, Schepens MAAM, Morshuis WJ, Di Bartolomeo R, Pierangeli A, Dossche KM. Antegrade selective cerebral perfusion during operations on the thoracic aorta: factors influencing survival and neurologic outcome in 413 patients. *J Thorac Cardiovasc Surg.* 2002;124:1080-6.
- Swain JA, McDonald TJ, Griffith PK, Balaban RS, Clark RE, Ceckler T. Low-flow hypothermic CPB protects the brain. *J Thorac Cardiovasc Surg.* 1991;102:76-84.

3. Sukurada T, Kazui T, Tanaka H, Komatsu S. Comparative experimental study of cerebral protection during aortic arch reconstruction. *Ann Thorac Surg.* 1996;61:1348-54.
4. Hagl C, Ergin MA, Galla JD, Lansman SL, McCullough JN, Spielvogel D, et al. Neurologic outcome after ascending aorta-aortic arch operations: effect of brain protection technique in high risk patients. *J Thorac Cardiovasc Surg.* 2001;121:1107-21.
5. Kazui T, Washiyama N, Muhammad BAH, Terada H, Yamashita K, Takinami M. Improved results of atherosclerotic arch aneurysm operations with a refined technique. *J Thorac Cardiovasc Surg.* 2001;121:491-9.
6. Kazui T, Washiyama N, Bashar ABH, Terada H, Yamashita K, Takinami M, et al. Total arch replacement using aortic arch branched grafts with the aid of antegrade selective cerebral perfusion. *Ann Thorac Surg.* 2000;70:3-9.
7. Washiyama N, Kazui T, Takinami M, Yamashita K, Fujita S, Terada H, et al. Experimental study on the effect of antegrade cerebral perfusion on brains with old cerebral infarction. *J Thorac Cardiovasc Surg.* 2001;122:734-40.
8. Ohkura K, Kazui T, Yamamoto S, Yamashita K, Tarada H, Washiyama N, et al. Comparison of pH management during antegrade selective cerebral perfusion in canine models with old cerebral infarction. *J Thorac Cardiovasc Surg.* 2004;128:378-85.
9. Mizuno A, Umemura K, Nakashima M. Inhibitory effects of MCI-186, free radical scavenger, on cerebral ischemia following rat middle cerebral artery occlusion. *Gen Pharmacol.* 1998;30:575-8.
10. Edaravone Acute Infarction Study Group. Effect of a novel free radical scavenger, edaravone (MCI-186), on acute brain infarction. Randomized, placebo-controlled, double-blind study at multicenters. *Cerebrovasc Dis.* 2003;15:222-9.
11. Kazuchika S, Kazui T, Terada H, Umemura K, Ikeda Y, Bashar ABH, et al. Experimental study on the protective effects of edaravone against ischemic spinal cord injury. *J Thorac Cardiovasc Surg.* 2005;130:1586-92.
12. Smith AL, Hoff JT, Nielsen SL, Larson CP. Barbiturate protection in acute focal cerebral ischemia. *Stroke.* 1974;5:1-7.
13. Takamatsu Y, Watanabe T. Studies on the concentrations of 3-methyl-1-phenyl-2-pyrazolin-5-one (MCI-186) in dog plasma and cerebral spinal fluid. *Jpn Pharmacol Ther.* 1997;25(suppl):S1785-91.
14. Lantos J, Temes G, Roth R, Morvay G. Alterations in malondialdehyde concentration of jugular vein blood following transient brain ischemia: the effect of lactic acidosis. *Acta Physiol Hung.* 1994;82:229-36.
15. Ohkawa H, Ohnishi N, Yagi K. Assay for lipid peroxides in animal tissues by thiobarbituric reaction. *Anal Biochem.* 1979;95:351-8.
16. Kato Y, Mori Y, Makino Y, Morimatsu Y, Hiroi S, Ishikawa T, et al. Formation of Nε-(hexanonyl)lysine in protein exposed to lipid hydroperoxide. *J Biol Chem.* 1999;274:20406-14.
17. Kato Y, Osawa T. Detection of lipid hydroperoxide-derived modification with polyclonal antibodies. *Methods Mol Biol.* 2002;186:37-44.
18. Paulson OB. Regional cerebral blood flow in apoplexy due to occlusion of the middle cerebral artery. *Neurology.* 1970;20:63-77.
19. Tanaka H, Kazui T, Sato H, Inoue N, Yamada O, Komatsu S. Experimental study on the optimum flow rate and pressure for selective cerebral perfusion. *Ann Thorac Surg.* 1995;59:651-7.
20. Zhang N, Komine-Kobayashi M, Tanaka R, Liu M, Mizuno Y, Urabe T. Edaravone reduces early accumulation of oxidative products and sequential inflammatory responses after transient focal ischemia in mice brain. *Stroke.* 2005;36:2220-5.
21. Watanabe T, Oshikiri N, Inui K, Kuraoka S, Minowa T, Hosaka J, et al. Optimal blood flow for cooled brain at 20°C. *Ann Thorac Surg.* 1999;68:864-9.
22. Swanson RA, Ying W, Kauppinen TM. Astrocyte influence on ischemic neuronal death. *Curr Mol Med.* 2004;4:193-205.
23. Love S. Oxidative stress in brain ischemia. *Brain Pathol.* 1999;9:119-31.
24. Lewen A, Matz P, Cfan PH. Free radical pathways in CNS injury. *J Neurotrauma.* 2000;17:871-90.
25. Floyd RA, Carney JM. Free radical damage to protein and DNA: mechanism involved and relevant observations on brain undergoing oxidative stress. *Ann Neurol.* 1992;32(suppl):S22-7.
26. Toshino H, Hattori N, Urabe T, Uchida K, Tanaka M, Mizuno Y. Postischemic accumulation of lipid peroxidation products in the rat brain: immunohistochemical detection of 4-hydroxy-2-nonenal modified proteins. *Brain Res.* 1997;767:81-6.
27. Meyer KL, Dempsey RJ, Roy MW, Donaldson DL. Somatosensory evoked potentials as a measure of experimental cerebral ischemia. *J Neurosurg.* 1985;62:269-75.
28. Skeigh JW, Havill JH, Frith R, Kersel D, Marsh N, Ulyatt D. Somatosensory evoked potentials in severe traumatic brain injury: a blinded study. *J Neurosurg.* 1999;91:577-80.
29. Michenfelder JD, Mittle JH. The relationship among canine brain temperature, metabolism, and function during hypothermia. *Anesthesiology.* 1991;75:130-6.
30. Yamashita K, Kazui T, Tarada H, Washiyama N, Suzuki K, Bashar AH. Cerebral oxygenation monitoring for total arch replacement using selective cerebral perfusion. *Ann Thorac Surg.* 2001;72:503-8.

# Total Aortic Arch Replacement in Patients With Arch Vessel Anomalies

Kazuchika Suzuki, MD, PhD, Teruhisa Kazui, MD, PhD,  
Abul Hasan Muhammad Bashar, MBBS, PhD, Katsushi Yamashita, MD, PhD,  
Hitoshi Terada, MD, PhD, Naoki Washiyama, MD, PhD, and Takayasu Suzuki, MD

First Department of Surgery, Hamamatsu University School of Medicine, Hamamatsu, Japan

**Background.** The presence of anomalous arch vessels has considerable impact on aortic arch reconstruction techniques and cerebral protection methods when the separated graft technique is adopted to perform total arch replacement. We analyzed our experience of total arch replacement in patients with arch vessel anomalies.

**Methods.** Among the 220 patients undergoing total arch replacement at our institution, 21 patients (9.5%) had various arch vessel anomalies. Common brachiocephalic trunk was found in 8 patients (3.6%); an isolated left vertebral artery in 9 (4.1%); aberrant right subclavian artery in 3 (1.4%); and coexistent common brachiocephalic trunk and isolated left vertebral artery in 1 (0.5%). In 4 of the 9 patients with isolated left vertebral artery, preoperative diagnosis was possible with magnetic resonance angiography or three-dimensional computed tomography. In cases with common brachiocephalic trunk, total arch replacement could be performed with the usual techniques after separating the innominate and left com-

mon carotid arteries from each other. The isolated left vertebral artery was anastomosed to the left subclavian artery graft in 7 patients and to the native left subclavian artery in 2. In the aberrant right subclavian artery variety, a distal aortic anastomosis was performed distal to the orifice of this anomalous artery. The aberrant vessel was reconstructed on the right side of the trachea and esophagus.

**Results.** There was no early or in-hospital mortality. No neurologic complication attributable to the arch vessel anomalies was found.

**Conclusions.** A precise preoperative diagnosis is very important for the selection of an appropriate surgical strategy in patients with arch vessel anomalies. Magnetic resonance angiography and three-dimensional computed tomography may be useful diagnostic tools in these patients.

(Ann Thorac Surg 2006;81:2079–83)

© 2006 by The Society of Thoracic Surgeons

According to available data, the incidence of various types of arch vessel anomalies is about 17% among the general population in Japan [1]. Among the American population, the incidence is reported to be as high as 34% [2]. Although it is rare for the anomalous arch vessels to cause symptoms that are severe enough to necessitate surgical intervention, their presence influences the total arch replacement (TAR) operations to a significant extent. This is particularly true when the TAR is carried out using the separated graft technique, which otherwise offers a number of advantages over the en-bloc repair technique. With the separated graft technique, the arch vessel anastomoses can be performed at a site that is free from atherosclerotic plaques or dissection. Control of bleeding from the arch vessel anastomotic sites is also easier with the former technique. Although the difference between the two techniques is not always significant in terms of major outcome variables [3], we prefer the separated graft technique popularized by Kazui and colleagues [4] for its above-mentioned advantages. The usefulness of this technique is getting increasing recog-

nition as evident from the growing number of centers that now use the technique for TAR [5, 6]. With this technique, however, the presence of anomalous arch vessels often requires changes in the arch reconstruction technique as well as the cerebral protection methods. Although reports of TAR in patients having arch vessel anomalies are increasing [7–12], there is no literature summarizing the various aspects of TAR in such patients. In this study, we analyzed our experience with TAR in this specific group of patients to assess the difficulties encountered during surgery.

## Patients and Methods

The study was approved by the institutional review board of the Hamamatsu University School of Medicine. Informed written consent was also obtained from each individual patient. Between March 1997 and November 2005, 220 patients underwent TAR for atherosclerotic aneurysm or aortic dissection at our institution. Of them, a total of 21 patients (9.5%) had various arch vessel anomalies in the presence of a normal left aortic arch. A classification of the arch vessel anomalies is shown in Figure 1. Routine preoperative investigations in non-emergent cases included enhanced computed tomo-

Accepted for publication Dec 20, 2005.

Address correspondence to Dr K. Suzuki, The First Department of Surgery, Hamamatsu University School of Medicine, 1-20-1 Handayama, Hamamatsu, 431-3192, Japan; e-mail: kazuchi@fj9.so-net.ne.jp.

© 2006 by The Society of Thoracic Surgeons  
Published by Elsevier Inc

0003-4975/06/\$32.00  
doi:10.1016/j.athoracsur.2005.12.062

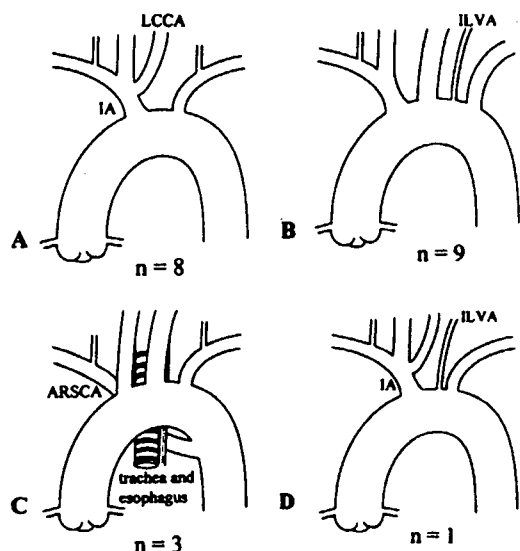


Fig 1. (A) Common brachiocephalic trunk (CBT); left common carotid artery (LCCA) and innominate artery (IA) originate from the common trunk. (B) Isolated left vertebral artery (ILVA); a left vertebral artery arising directly from the aortic arch. (C) Aberrant right subclavian artery (ARSCA); a right subclavian artery arising from the proximal descending aorta as the fourth aortic arch branch and passing behind the esophagus and trachea. (D) Coexistent common brachiocephalic trunk and isolated left vertebral artery.

graphic scan and digital subtraction angiography, whereas magnetic resonance angiography and three-dimensional computed tomographic scan were used only in the recent cases. Common brachiocephalic trunk (CBT), in which the left common carotid artery and the innominate artery originate from a common trunk (Fig 1A) was found in 8 patients (3.6%). Isolated left vertebral artery (ILVA), which is defined as a left vertebral artery taking off directly from the aortic arch (Figs 1B, 2), was present in 9 patients (4.1%). Although preoperative digital subtraction angiography was routinely performed, it could not give the conclusive diagnosis of the ILVA in any of the patients. In 4 of the 9 patients, the anomaly was diagnosed preoperatively: 3 with the help of magnetic resonance angiography and 1 with three-dimensional computed tomographic scan. Aberrant right subclavian artery (ARSCA), which is a right subclavian artery arising from the proximal descending aorta as the fourth aortic arch branch and passing behind the esophagus and trachea (Fig 1C), was found in 3 patients (1.4%). The remaining 1 patient (0.5%) who had both CBT and ILVA (Fig 1D) was included in the ILVA group. The patient characteristics in the three groups are shown in Table 1. There were no symptoms attributable to the arch vessel anomalies except in 1 patient with ARSCA, who complained of dysphagia.

All patients underwent TAR under moderately hypothermic circulatory arrest and with the aid of antegrade selective cerebral perfusion (SCP). The details of our cerebral protection and arch reconstruction techniques have been described elsewhere [13]. In brief, after median sternotomy, cardiopulmonary bypass was estab-

lished with the arterial inflow through the ascending aorta or right axillary artery and venous drainage from the right atrium. Systemic cooling was then started. When the rectal temperature reached 25°C, circulatory arrest was induced, and SCP was started through the innominate and the left common carotid arteries after cannulating the vessels with balloon-tipped catheters. The flow rate for SCP was 10 mL · kg<sup>-1</sup> · min<sup>-1</sup>. Then the distal aortic anastomosis was performed with a four-branched aortic arch graft (Hemashield, Meadox Medical, Oakland, NJ). After the completion of this anastomosis, the circulation was restarted with perfusion through the side branch of the graft. The reconstruction of left subclavian artery was performed next, and systemic rewarming was started. Then anastomoses of the proximal aorta, innominate artery, and left common carotid artery were performed in that order to complete the arch reconstruction. Electroencephalography is used as the intraoperative neurologic monitor on most occasions. Transcranial Doppler sonography, jugular venous oxygen saturation, and multichannel near-infrared spectroscopy are used to monitor the cerebral blood flow during antegrade SCP. The specific cerebral protection and arch reconstruction techniques required for each individual type of arch vessel anomaly are described below.

#### Common Brachiocephalic Trunk

First the innominate and the left common carotid arteries were separated from each other and were cannulated separately with balloon-tipped catheters for SCP. This ensured a cerebral protection and arch vessel reconstruction procedure that were, basically, similar to the TAR



Fig 2. Preoperative magnetic resonance angiogram showing the dominant isolated left vertebral artery (arrow).