

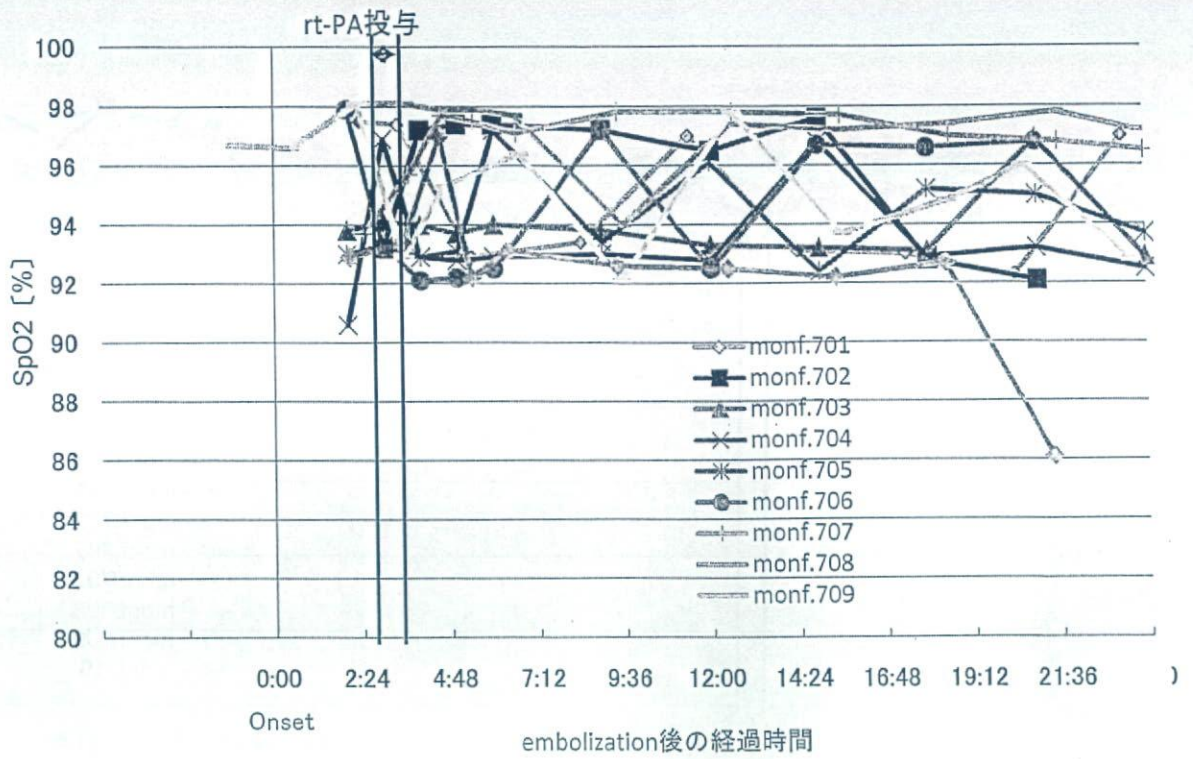図5 SpO2の経時的変化

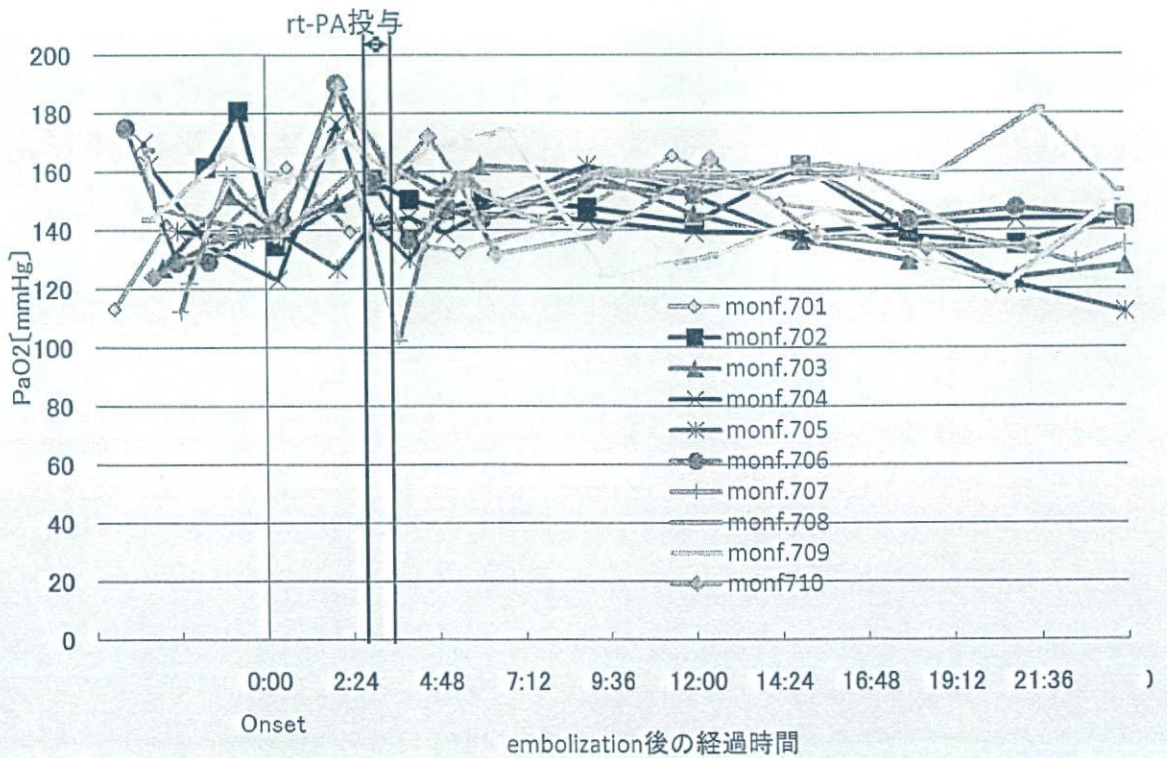


図6 PaO2の経時的変化

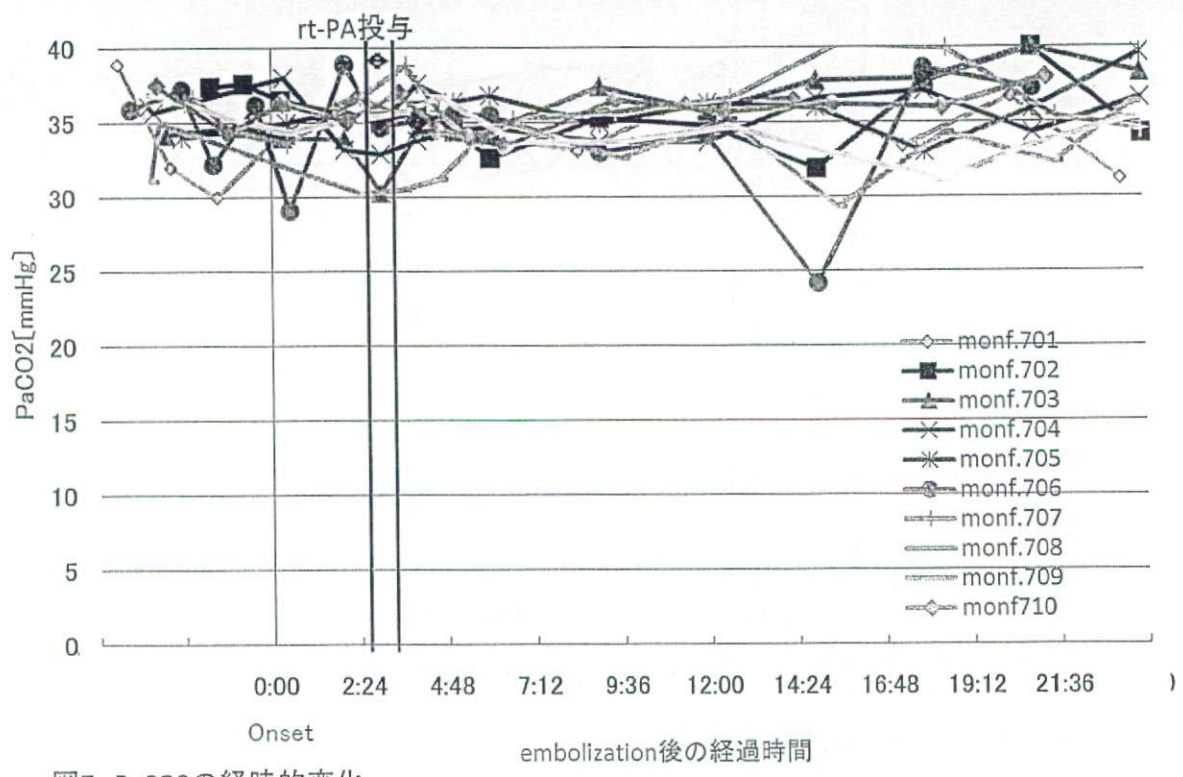


図7 PaCO2の経時的変化

図8 経時的頭部画像

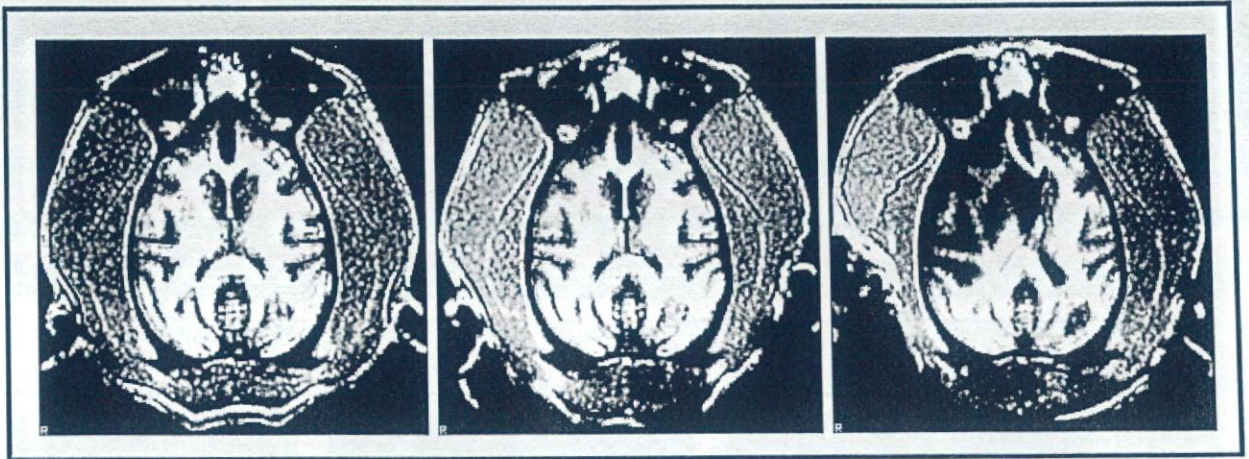
701

pre

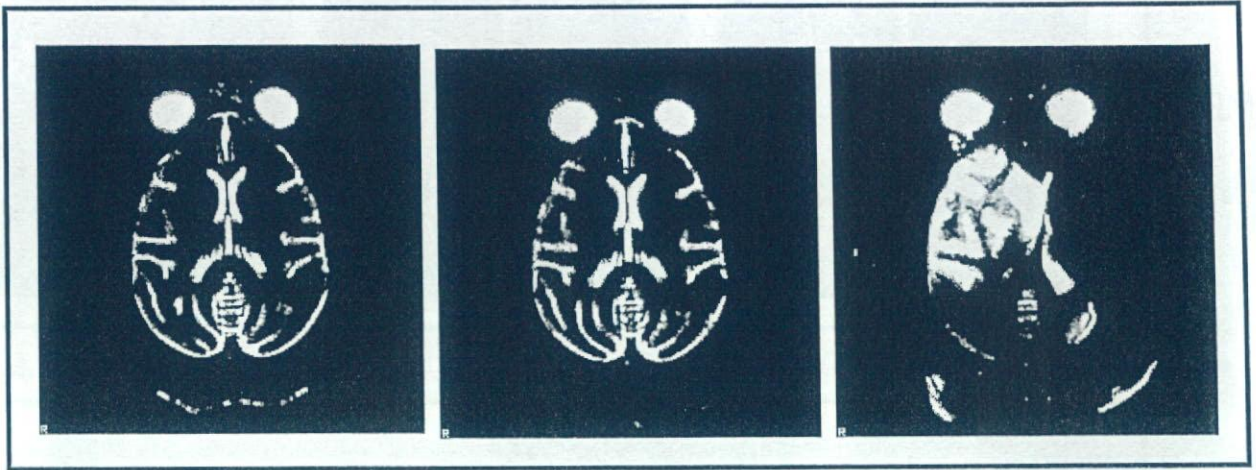
Post embolization

24hrs after embolization

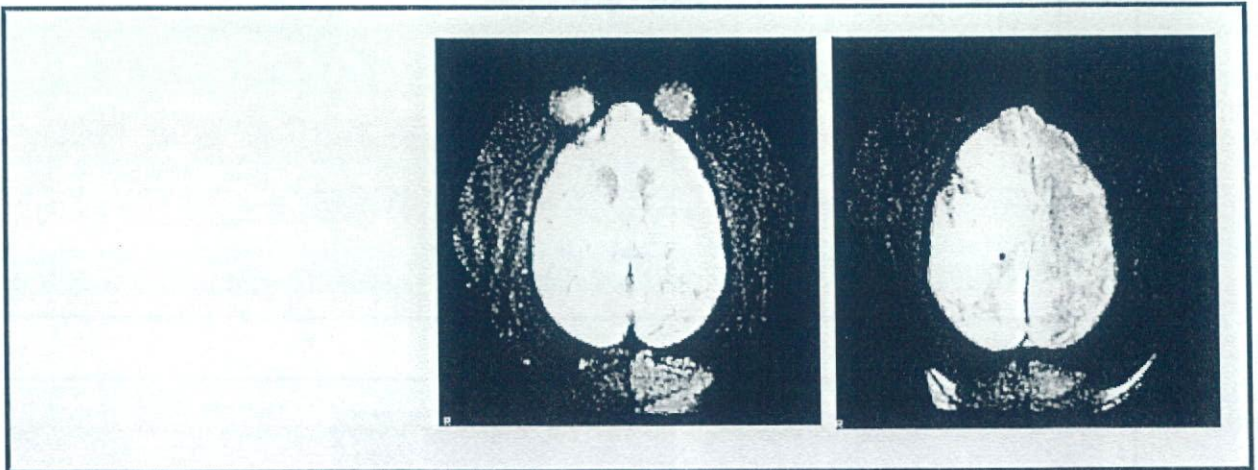
T1



T2



T2*



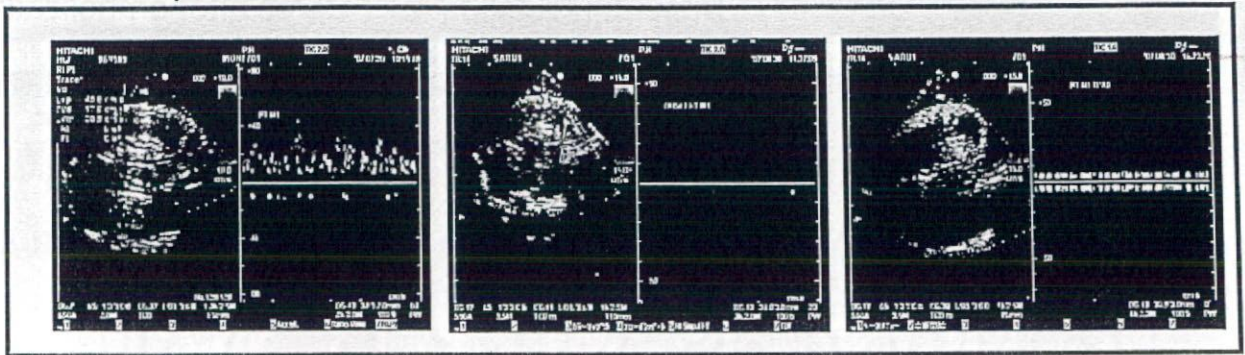
701

pre

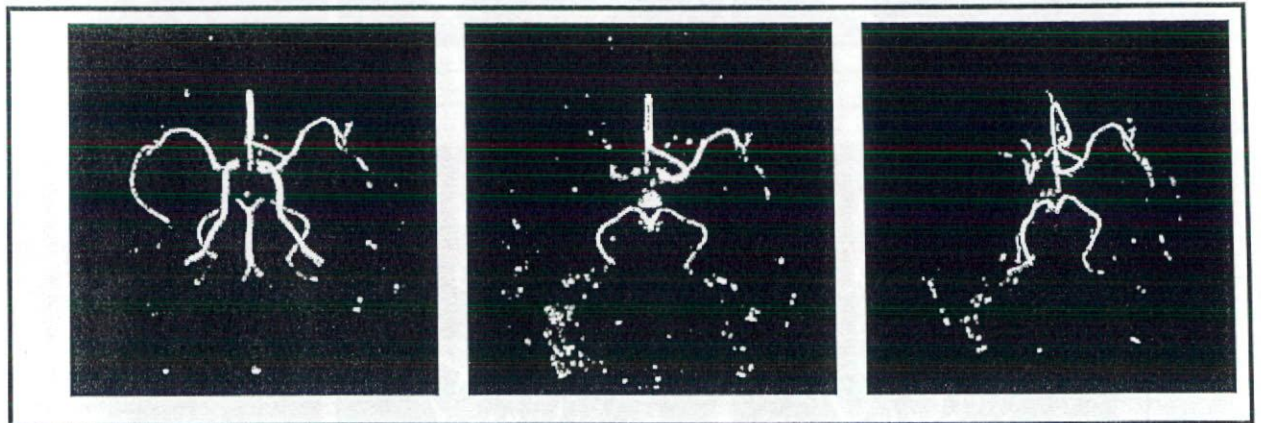
Post embolization

24hrs after embolization

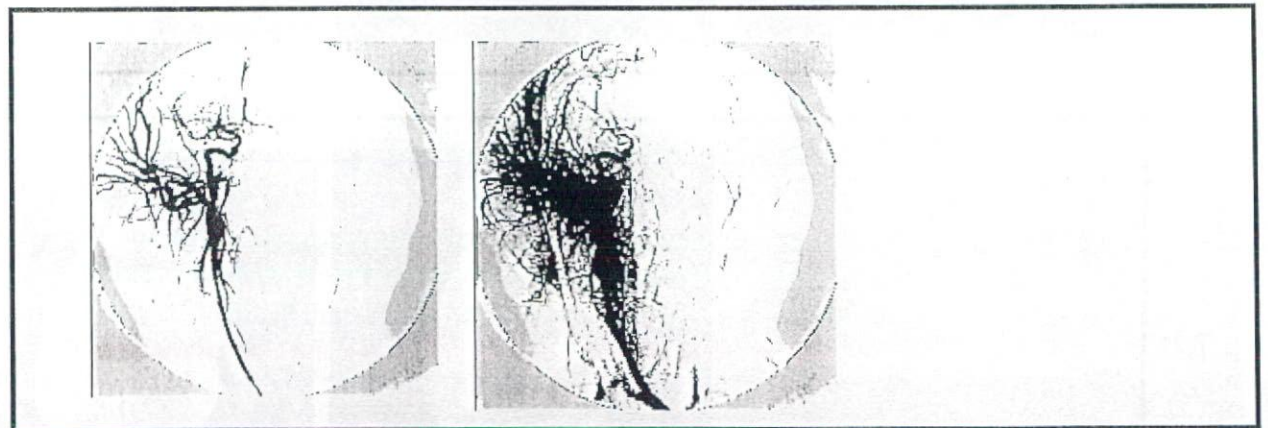
US



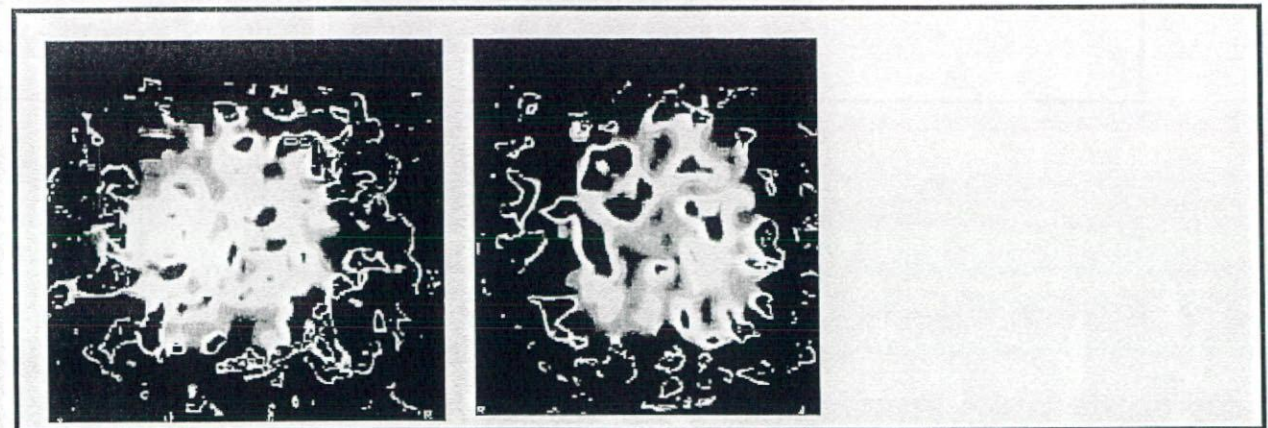
MRA



angio



OEF



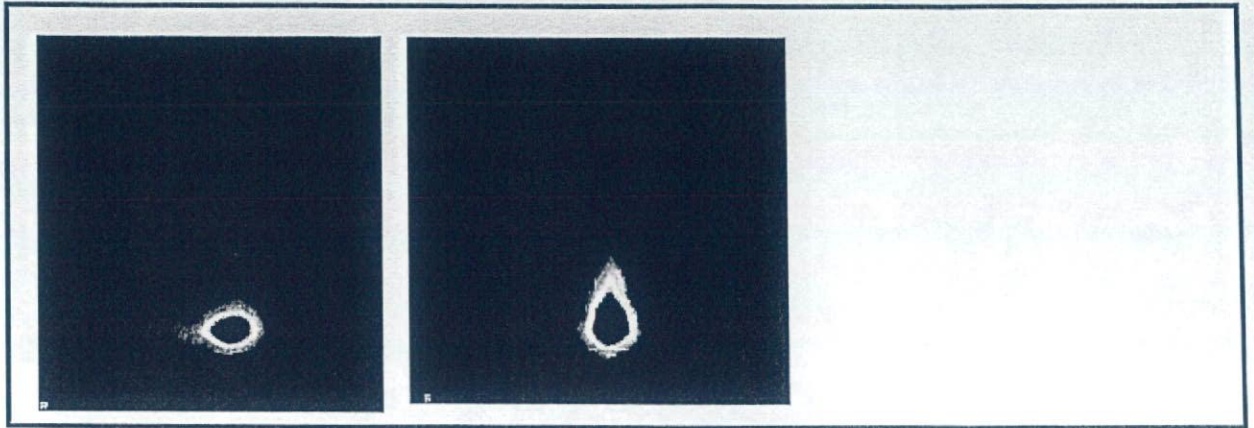
701

pre

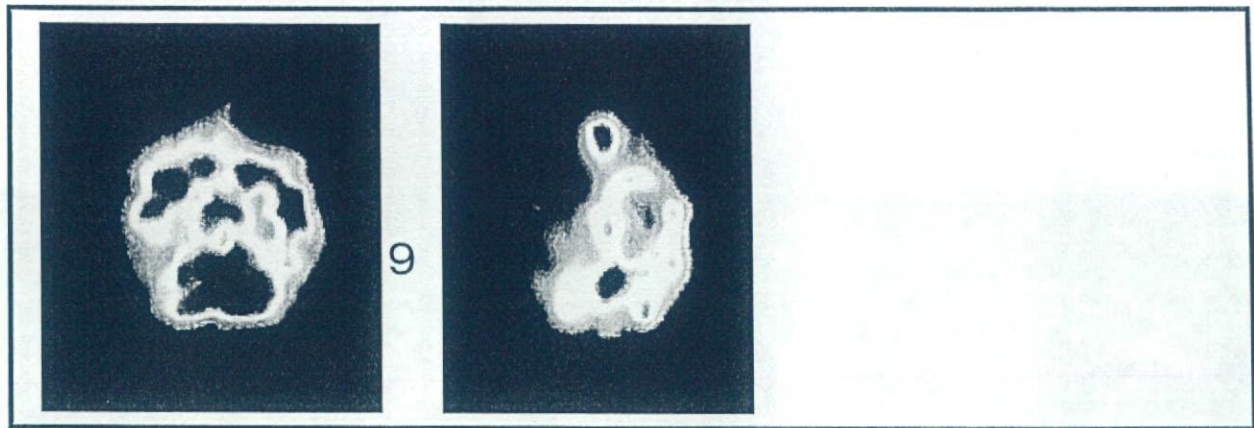
Post embolization

24hrs after embolization

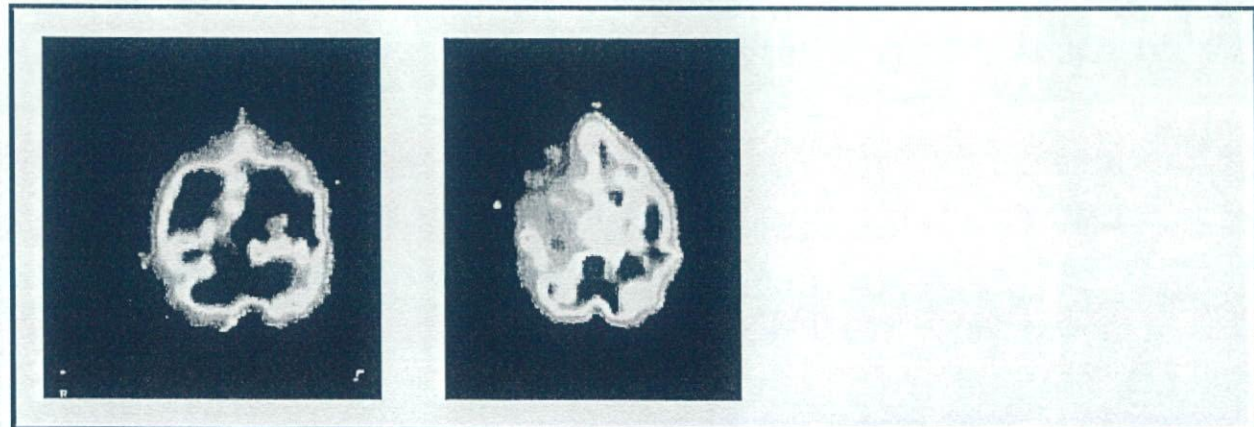
CBV



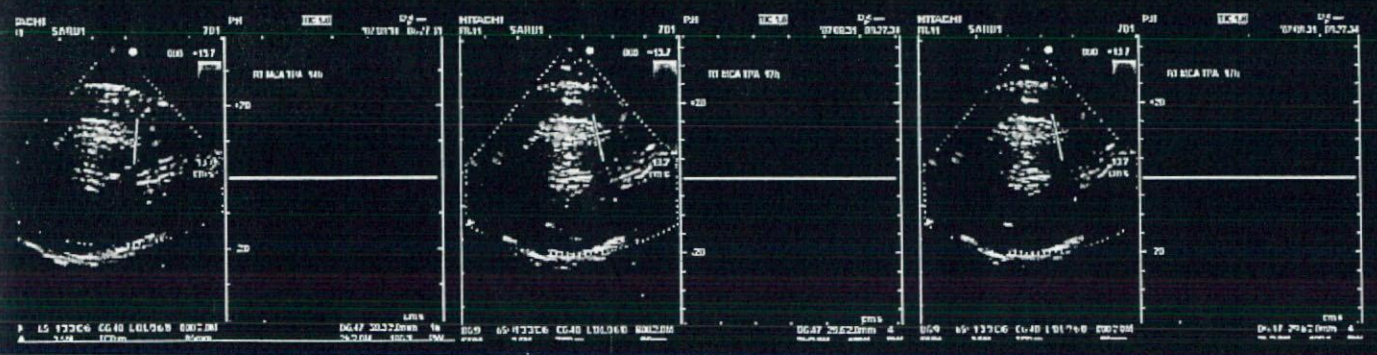
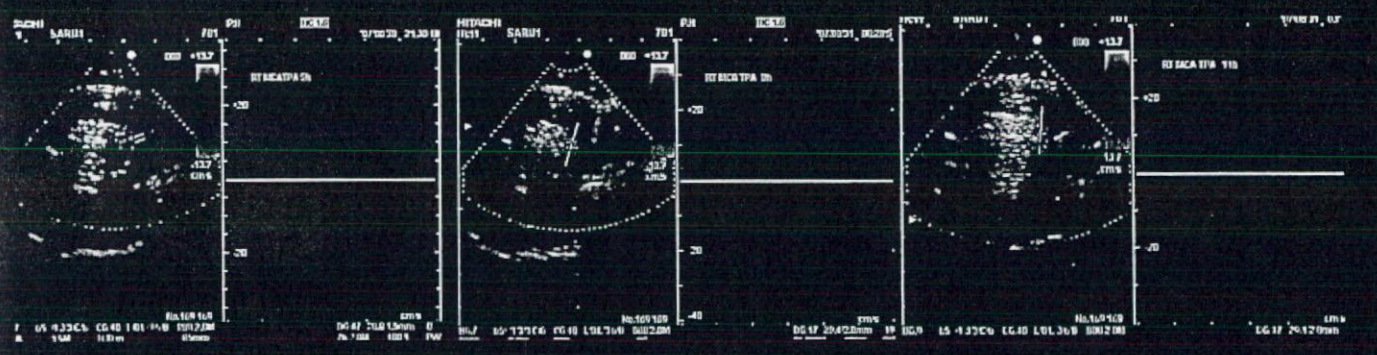
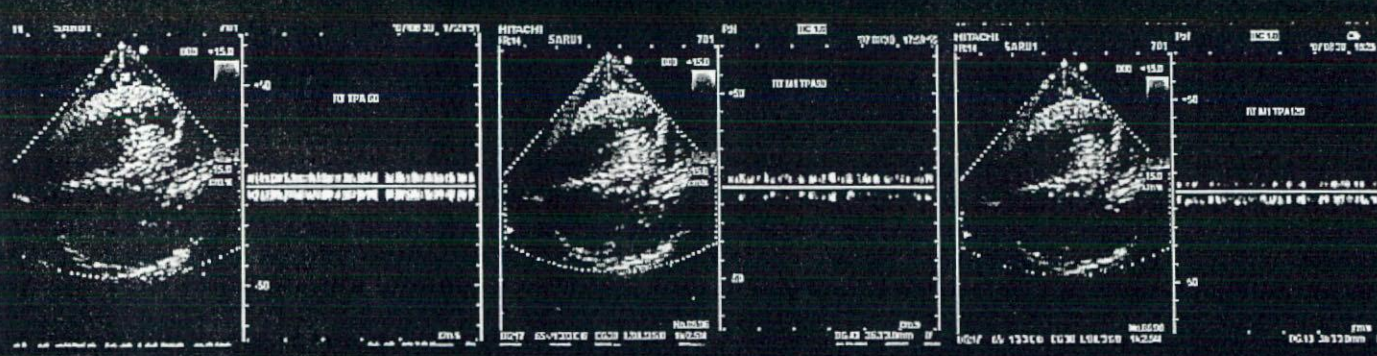
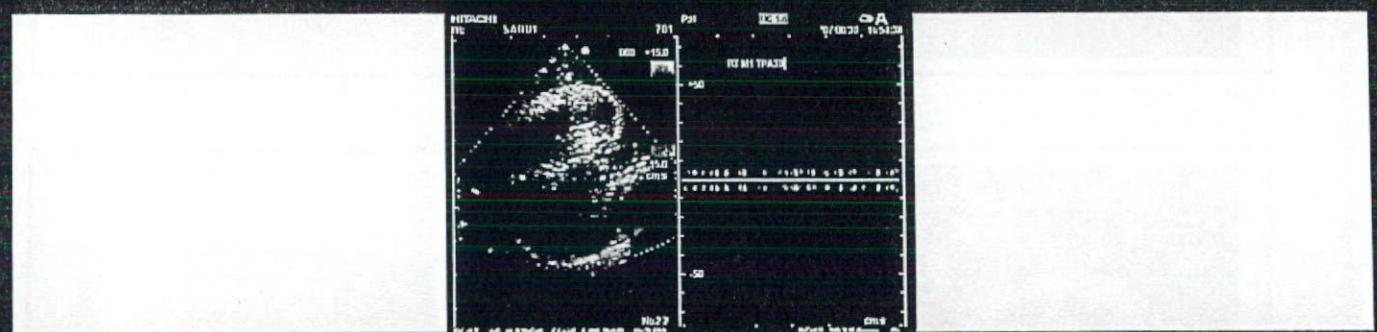
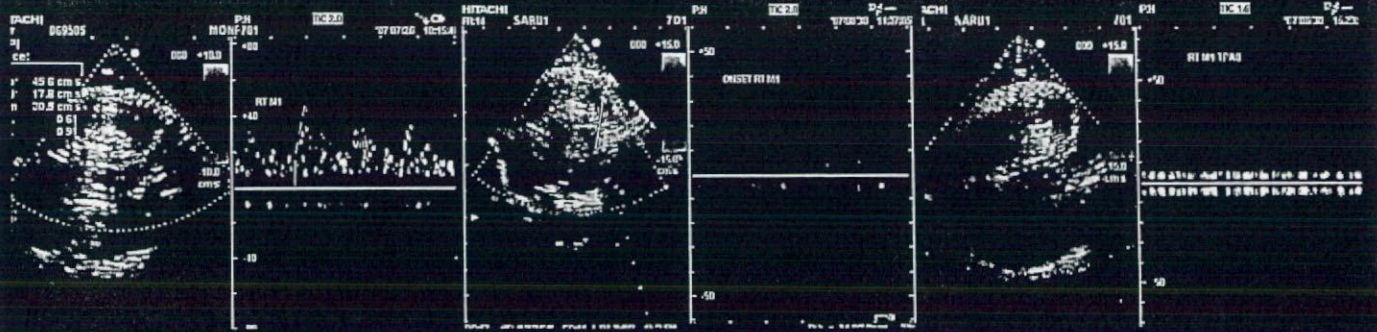
CBF



CM
RO2



- OEF 腦 酸素摄取率
- CBV 腦 血液量
- CBF 血流值
- CMR02 腦 酸素代謝量

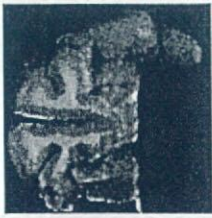

monf701 0

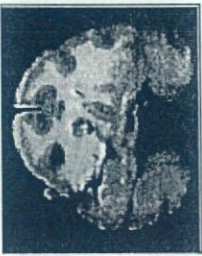

病理肉眼

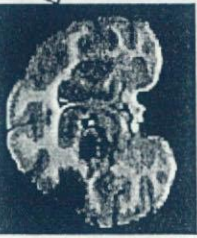
1



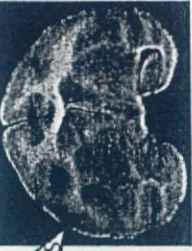2



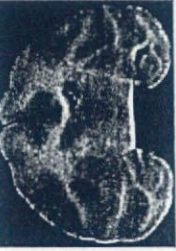3



4



5

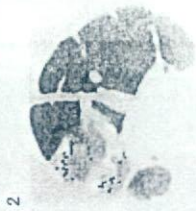

0

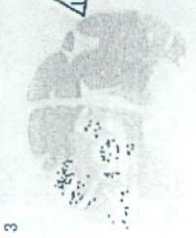

病理光顯

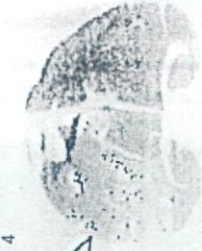1



2



3

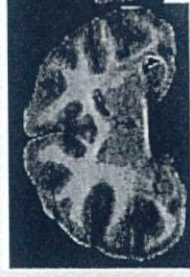

4



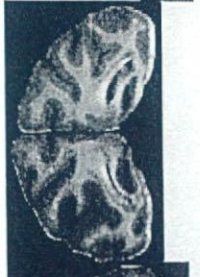5

6




病理肉眼

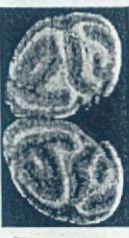7



8



9



6



病理光顯

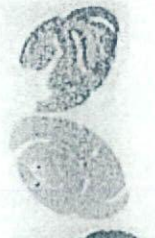7



8



9



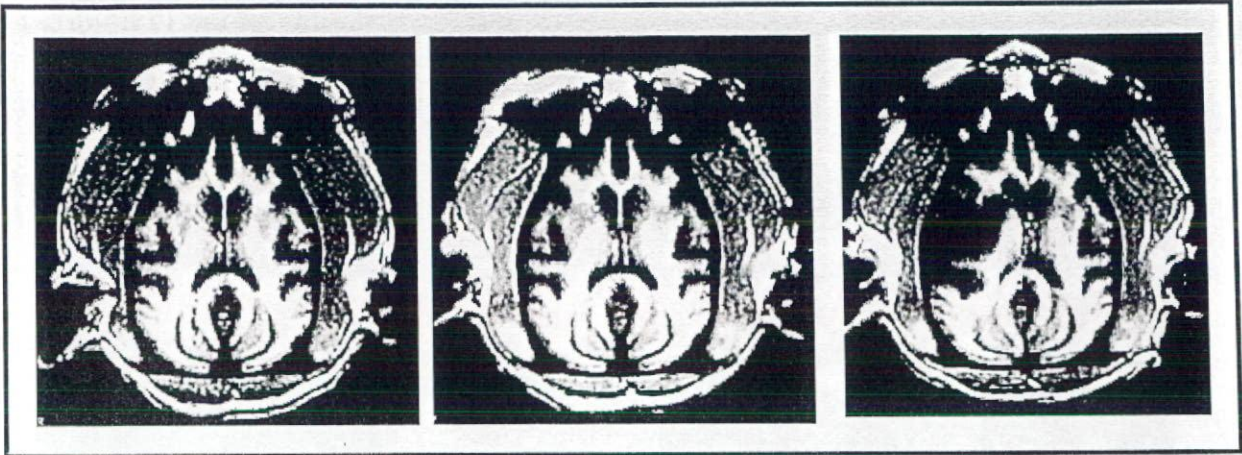702

pre

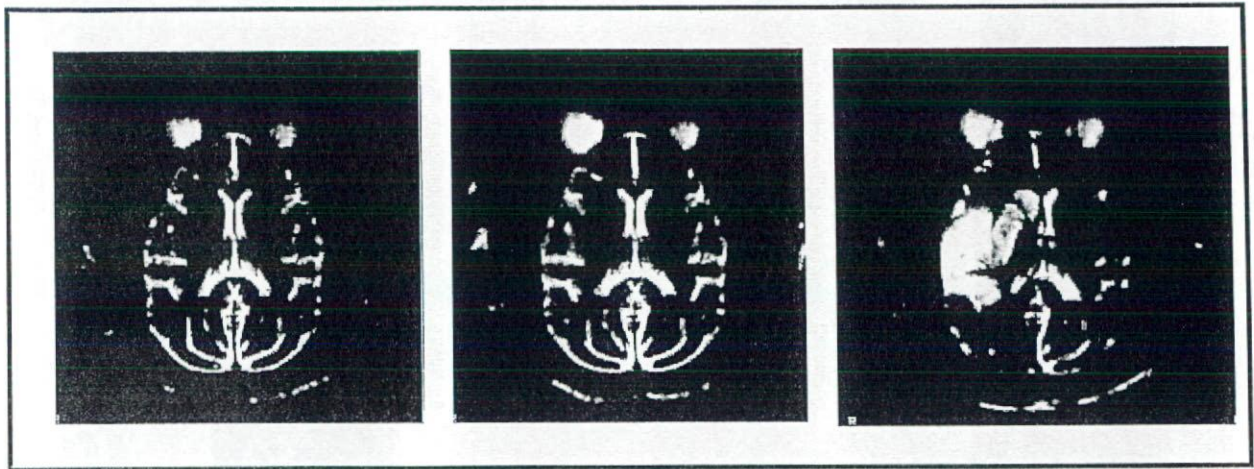
Post embolization

24hrs after embolization

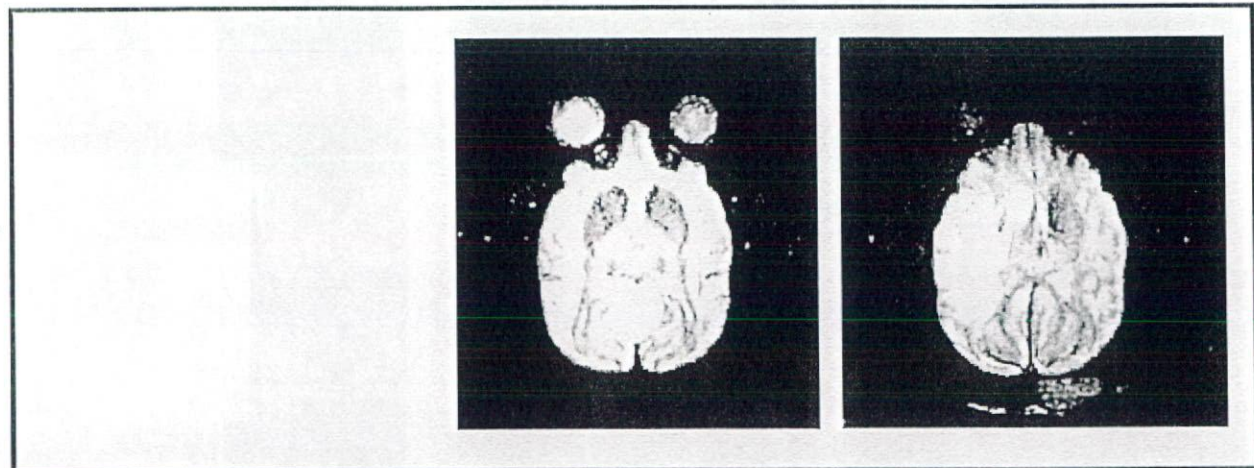T1



T2



T2*



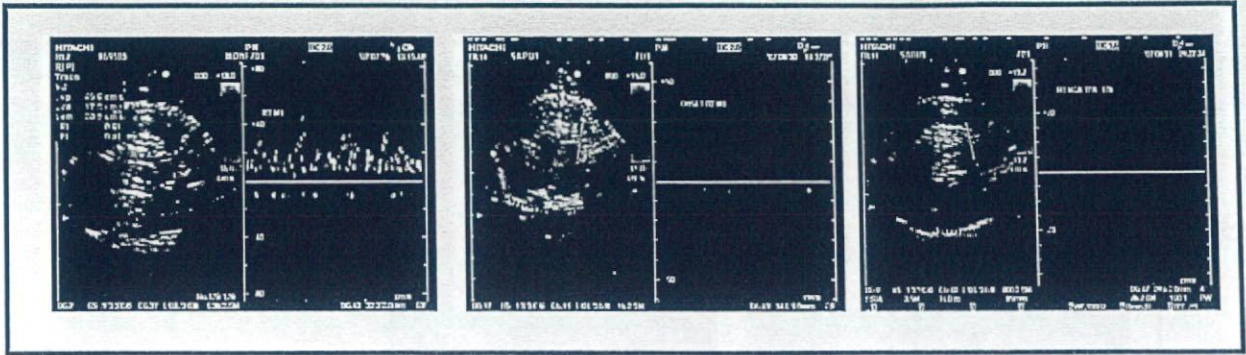
702

pre

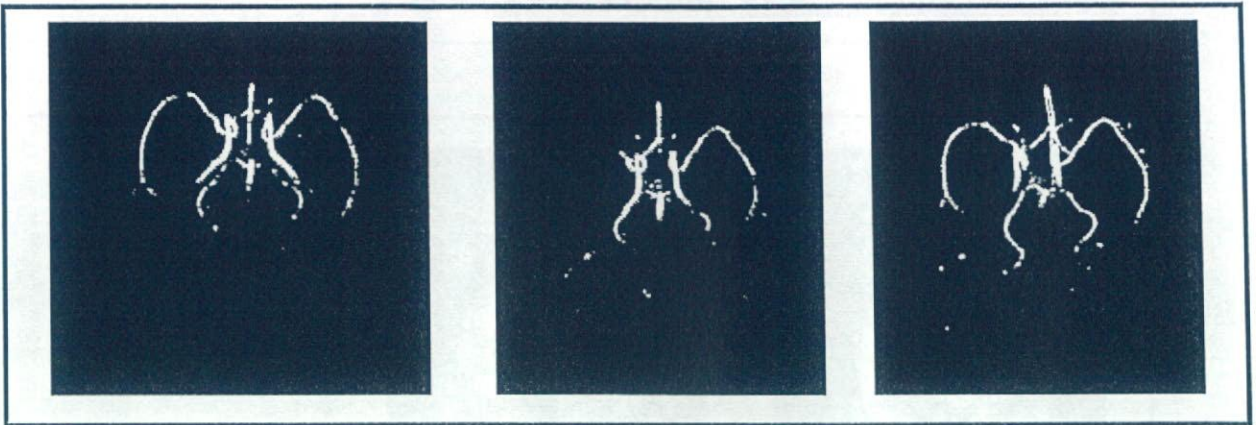
Post embolization

24hrs after embolization

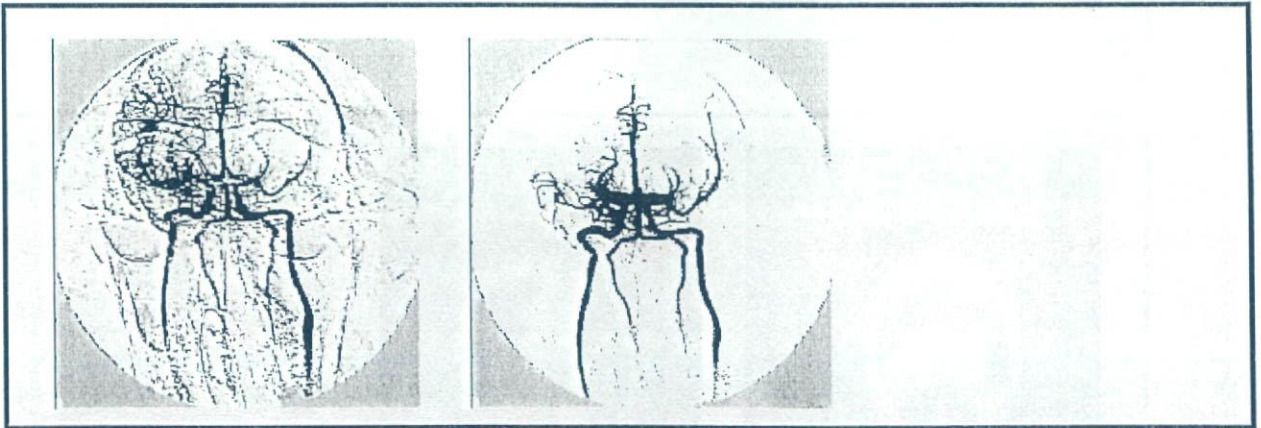
US



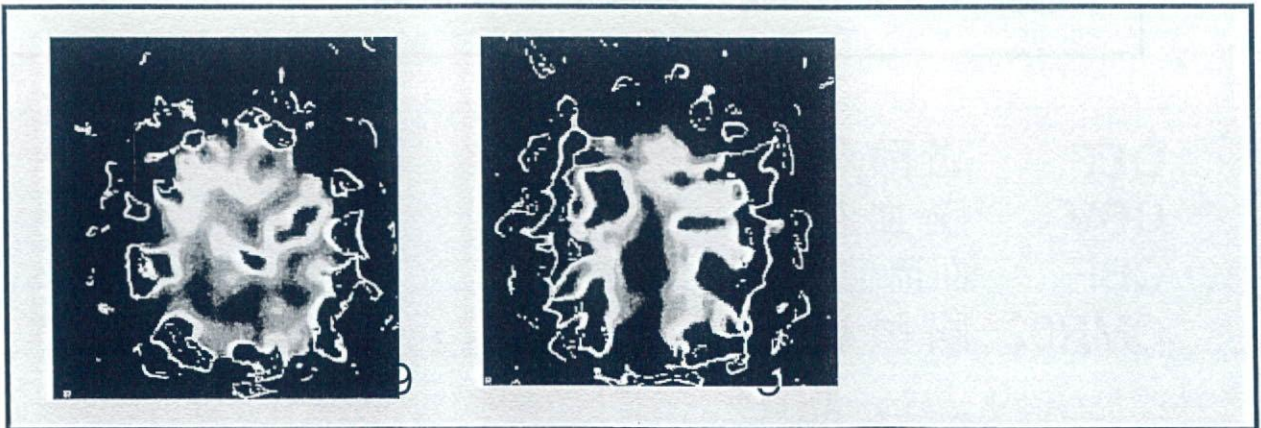
MRA



angio



OEF




702

pre

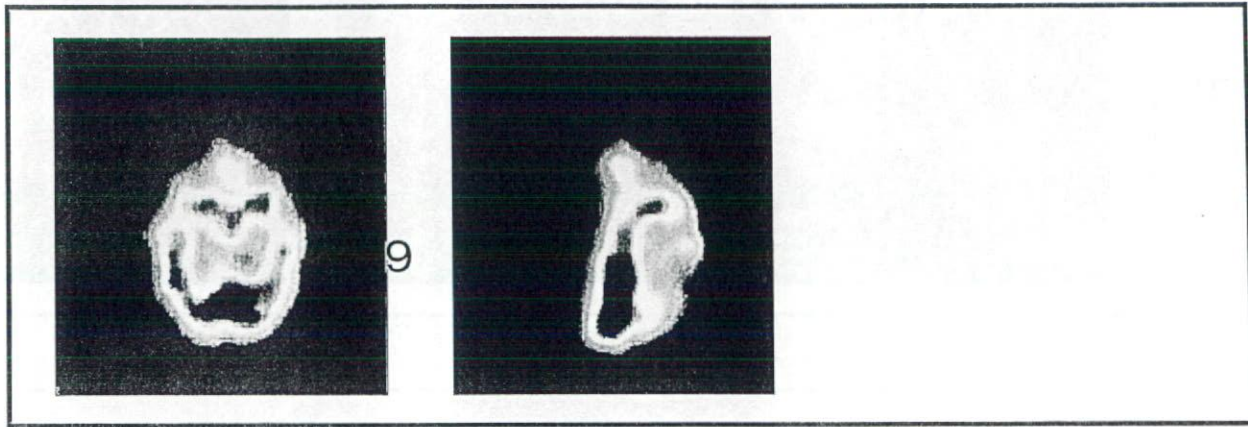
Post embolization

24hrs after embolization

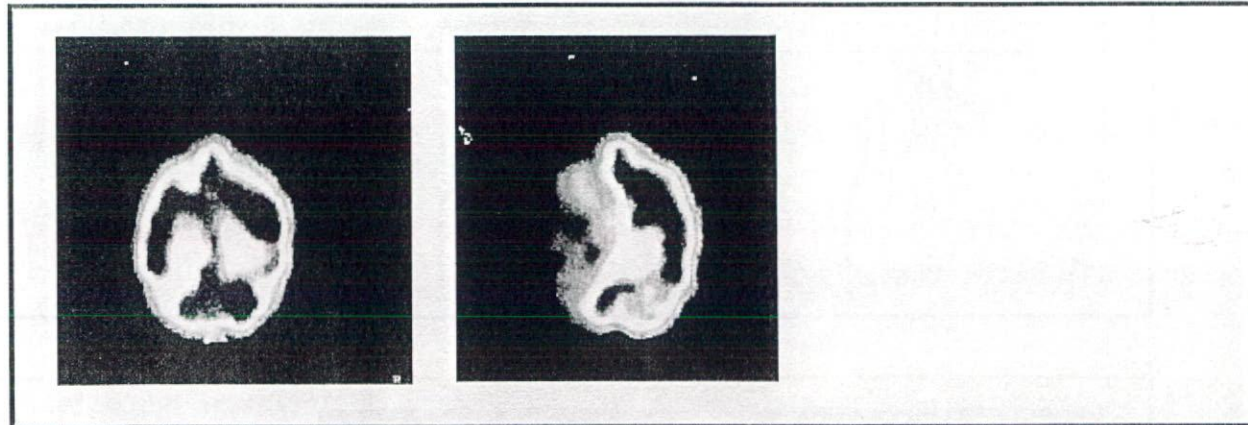
CBV



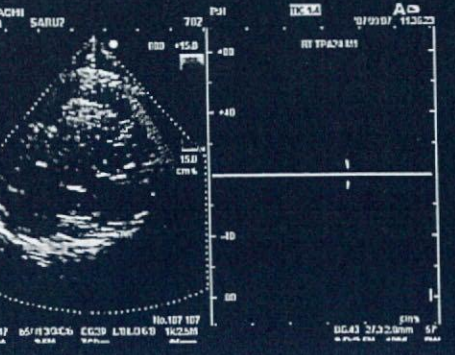
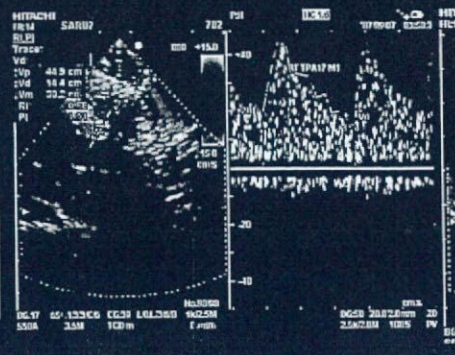
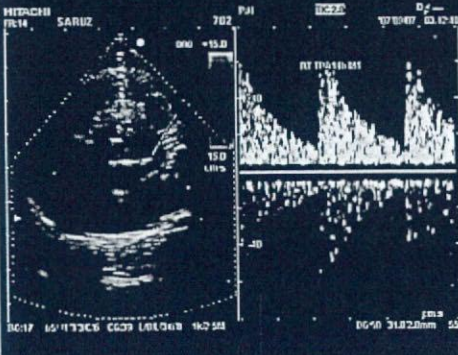

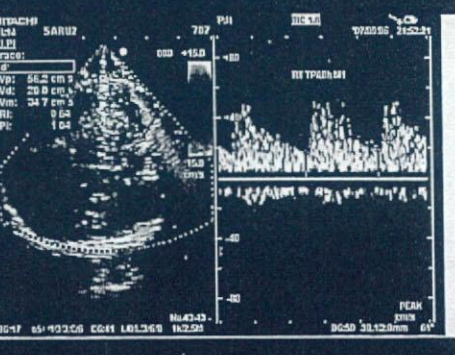
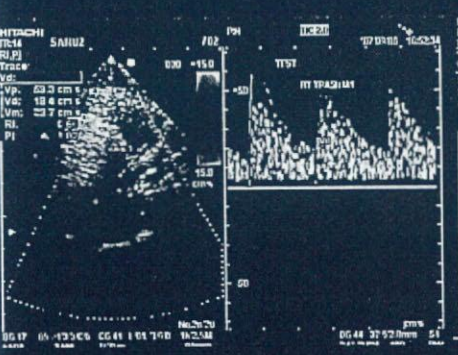
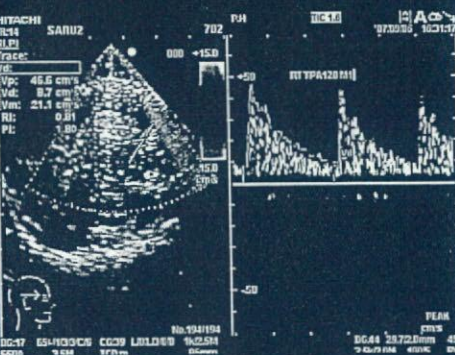
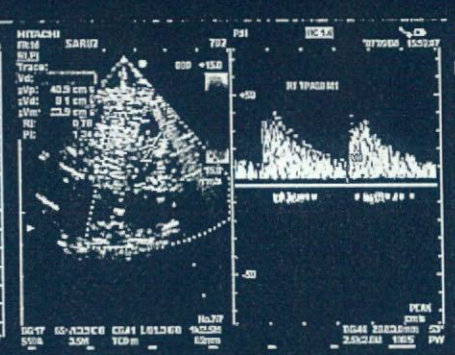
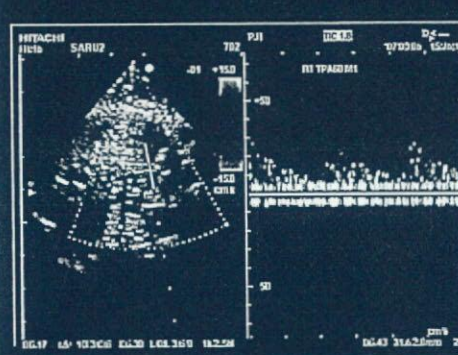

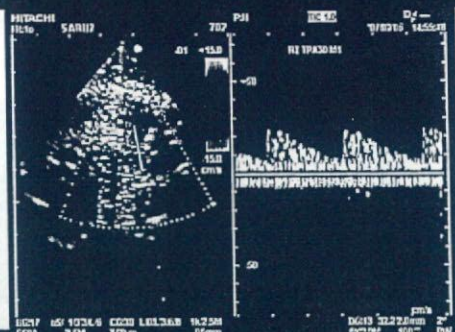

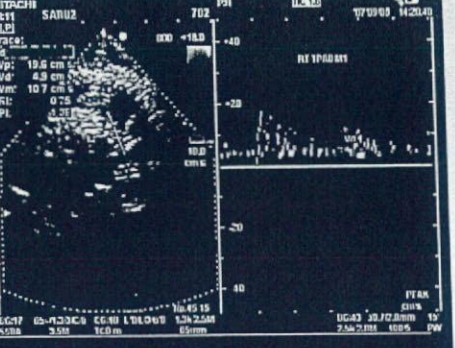
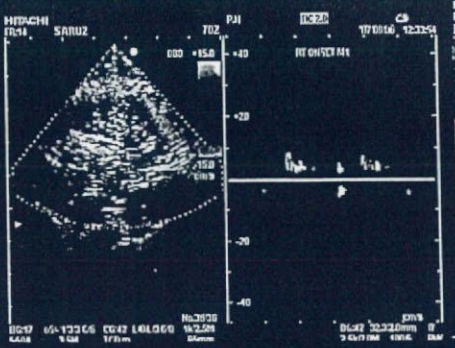
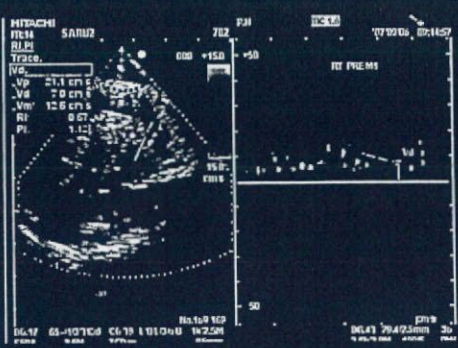
CBF



CM
RO2



- OEF** 腦 酸素攝取率
- CBV** 腦 血液量
- CBF** 血流值
- CMRO2** 腦 酸素代謝量

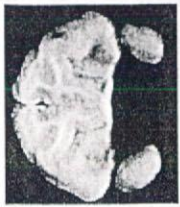

monf702 0

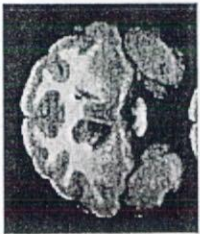

病理肉眼

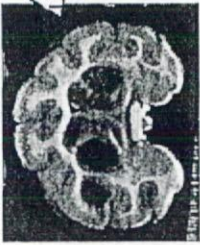
1



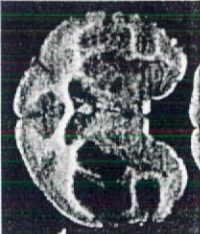2



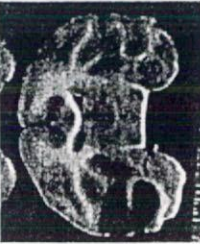3



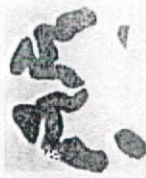4



5

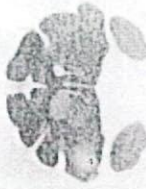

0

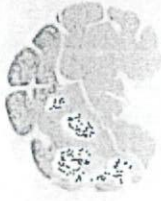

病理光顯

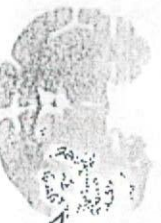1



2



3

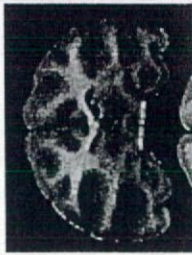

4



5

6

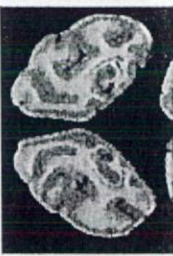

病理肉眼

7



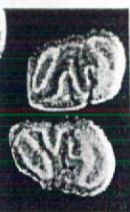8



9



10



6



病理光顯

7



8



9



10

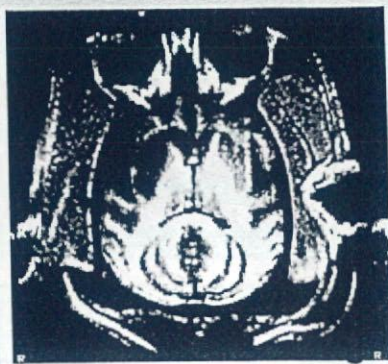
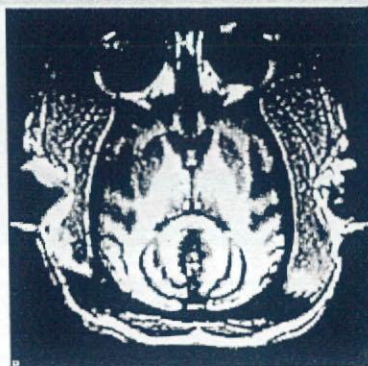
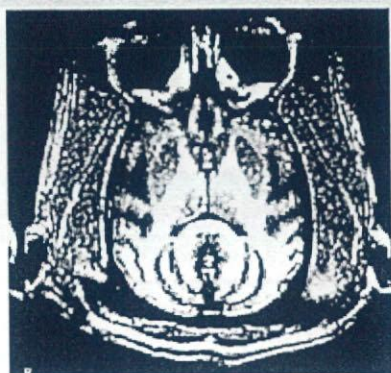
703

pre

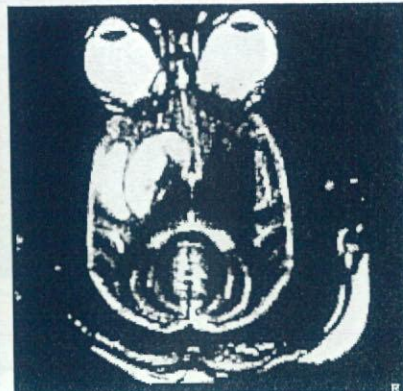
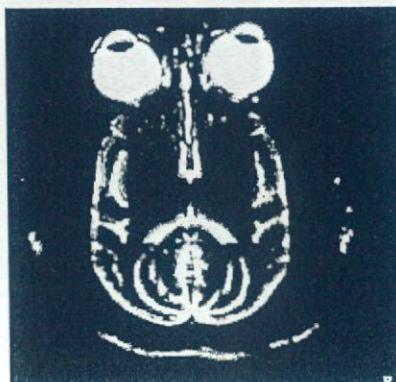
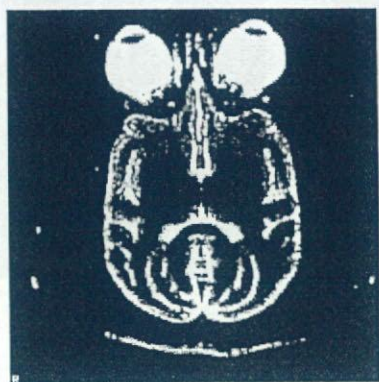
Post embolization

24hrs after embolization

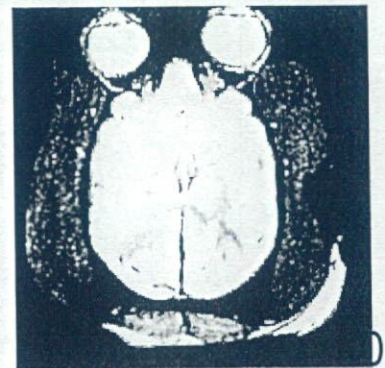
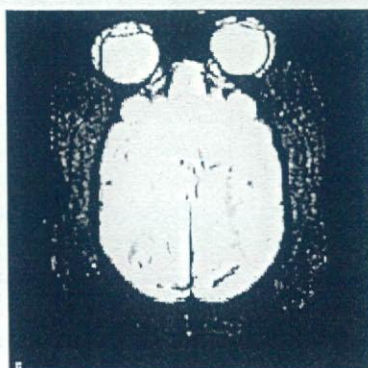
T1



T2



T2*



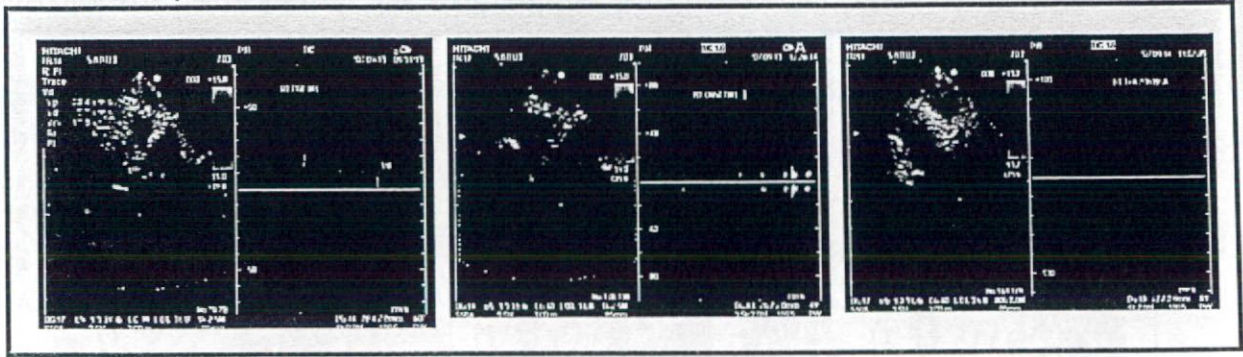
703

pre

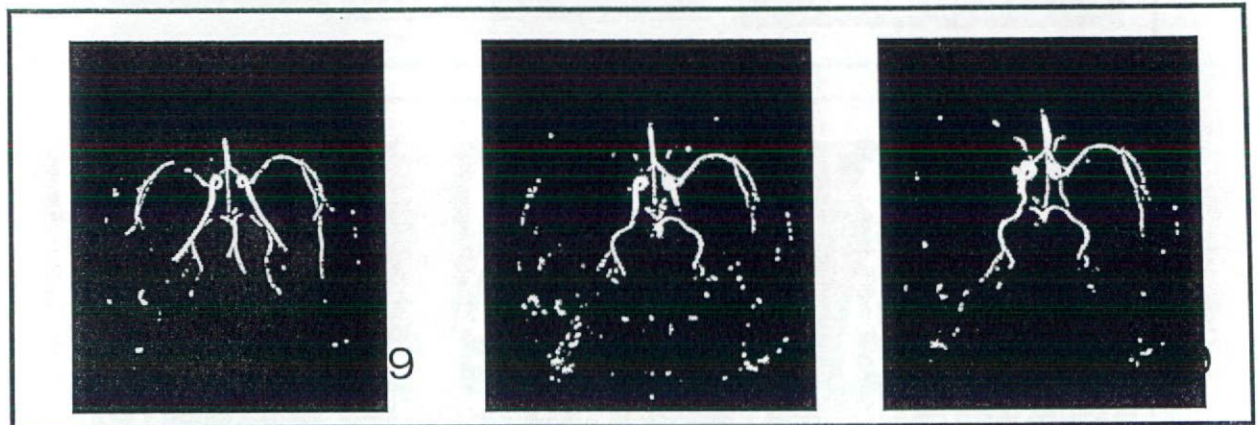
Post embolization

24hrs after embolization

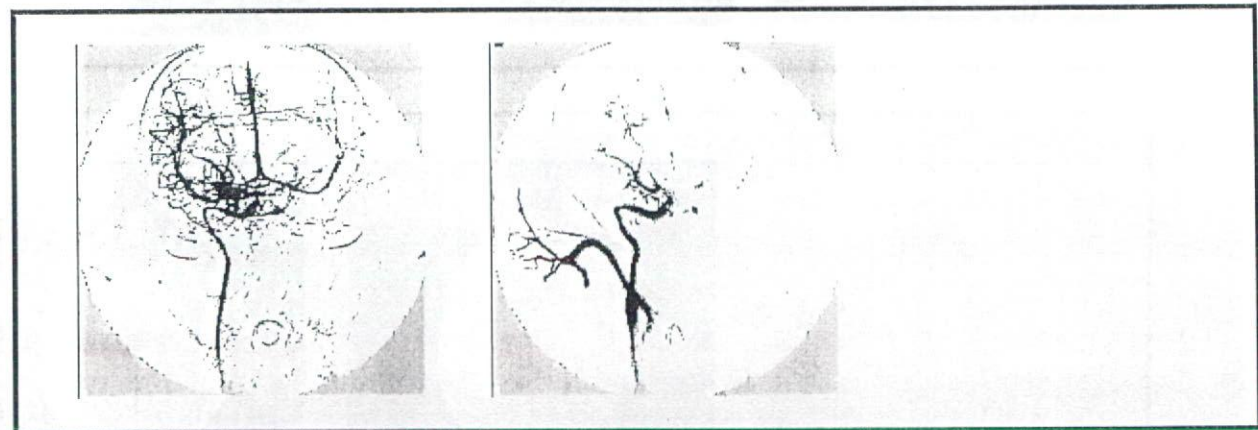
US



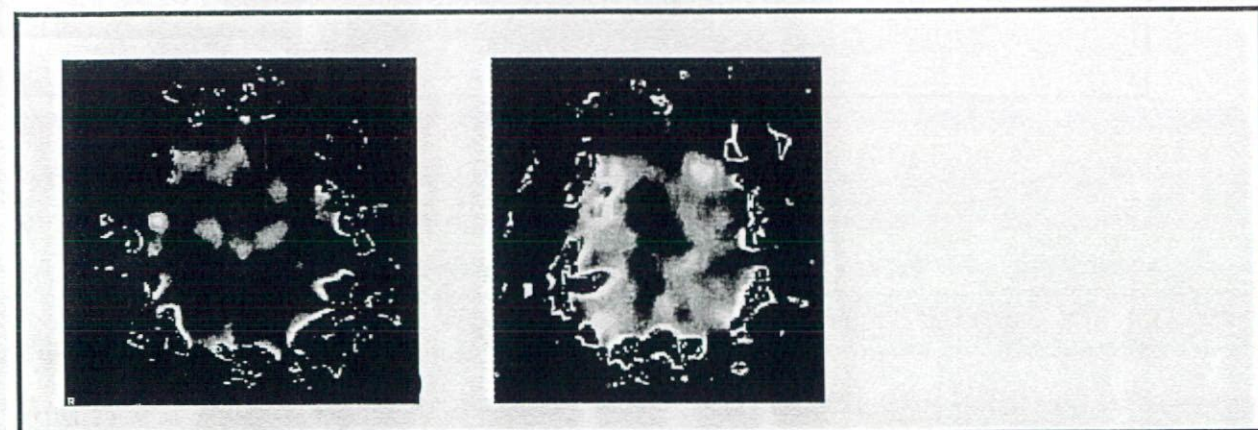
MRA



angio



OEF



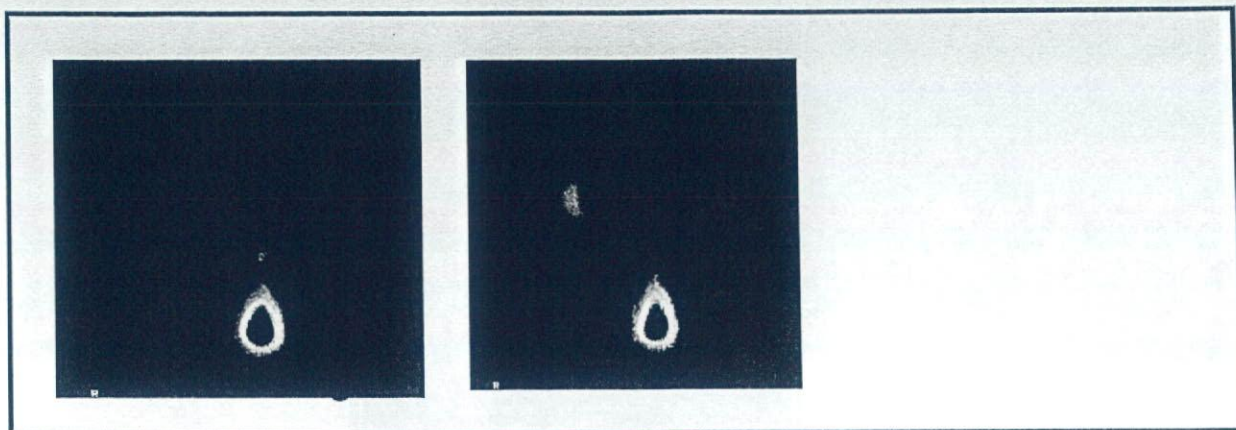
703

pre

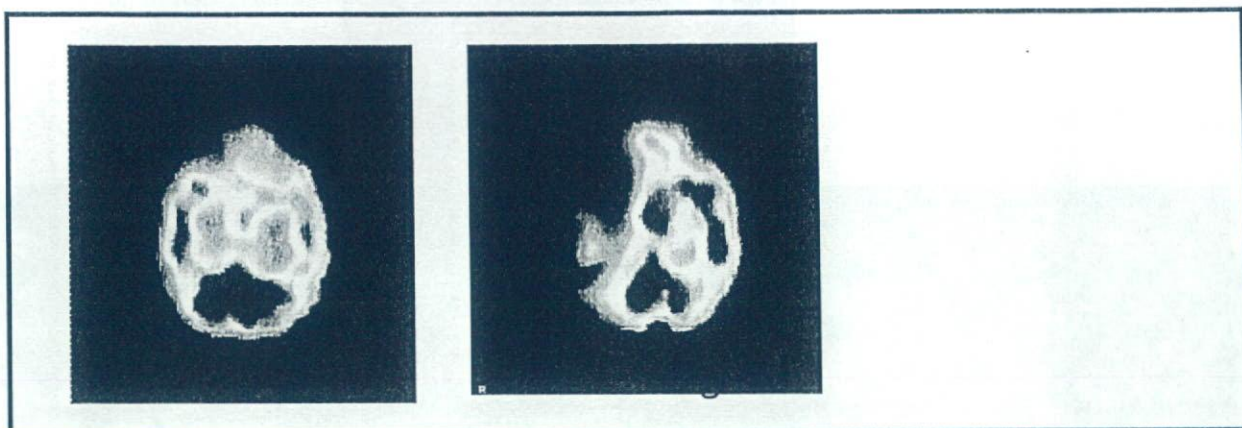
Post embolization

24hrs after embolization

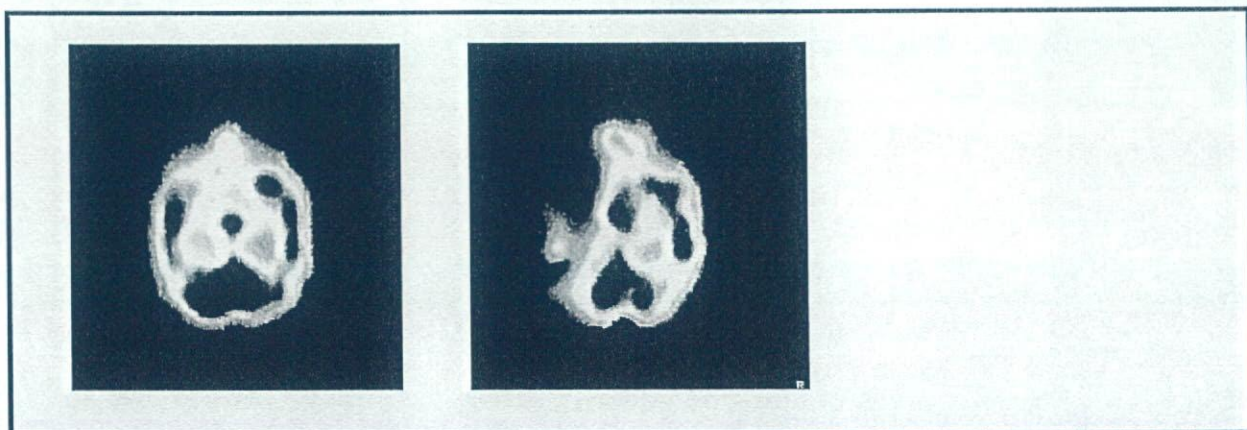
CBV



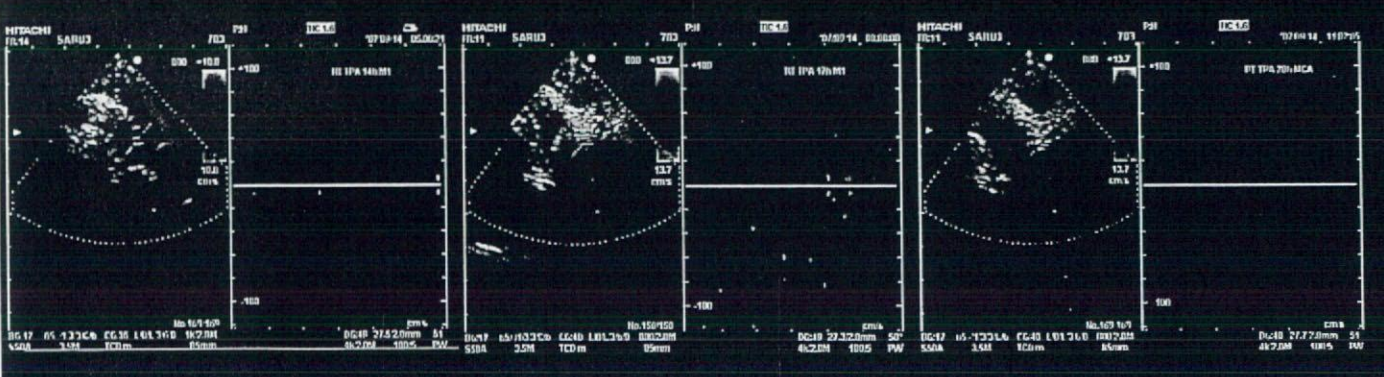
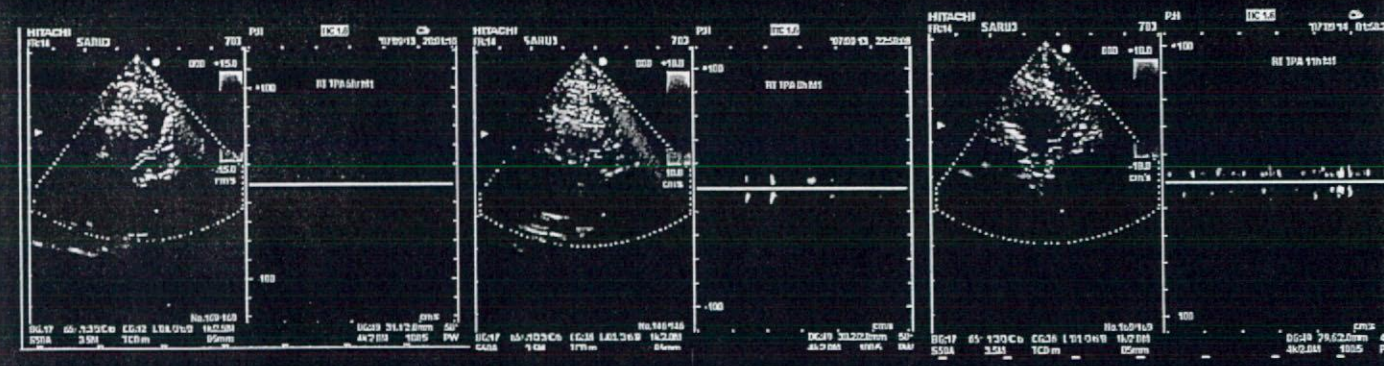
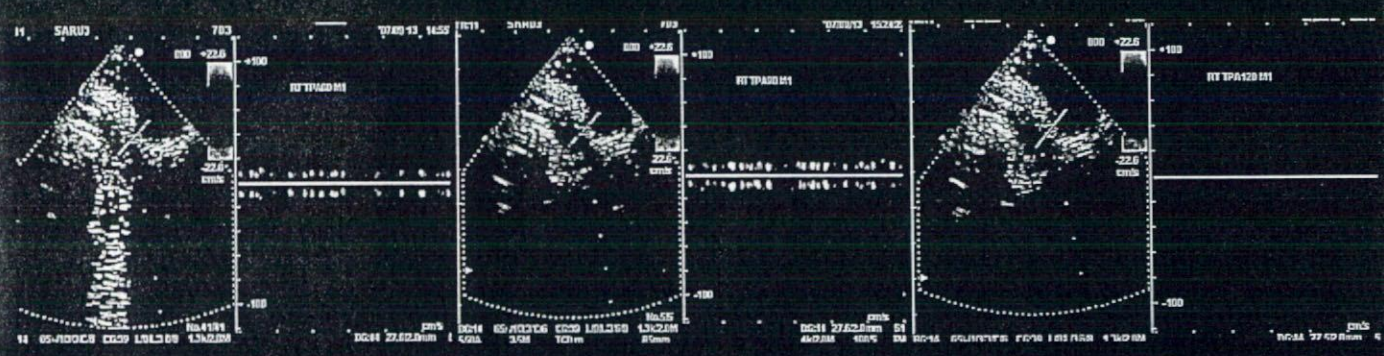
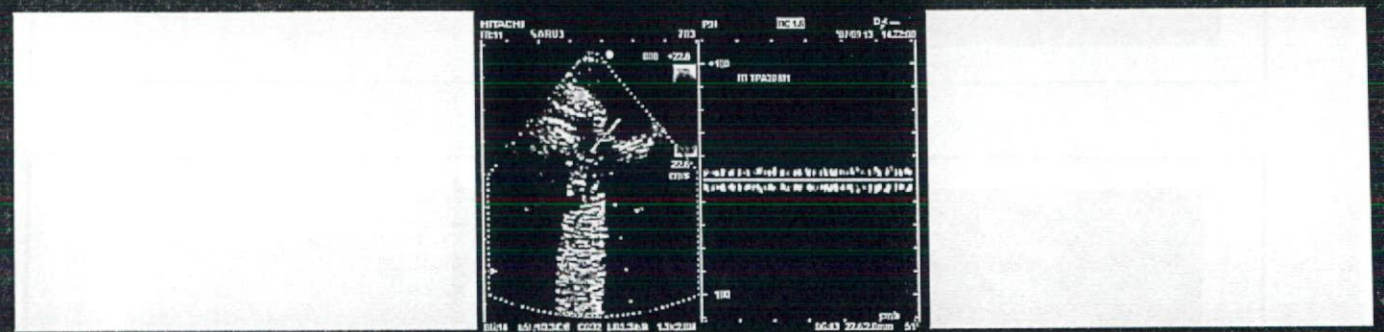

CBF



CM
RO2



OEF 腦 酸素攝取率
CBV 腦 血液量
CBF 血流值
CMR02 腦 酸素代謝量



monF703 0

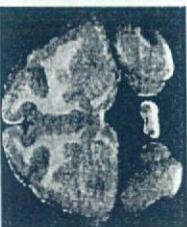

病理肉眼

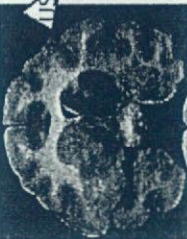1



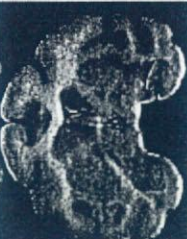2



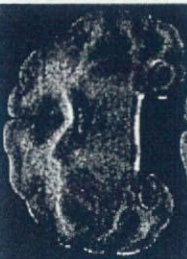3



4



5

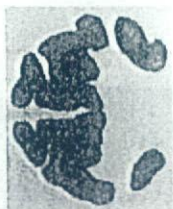

0



病理光顯

1



2



3

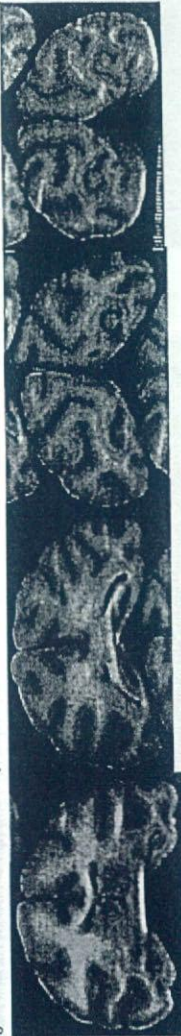

4



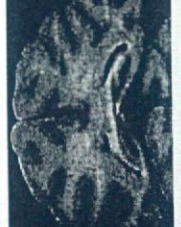5

6



病理肉眼

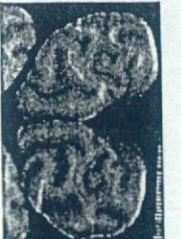7



8



9



6



病理光顯

7



8



9



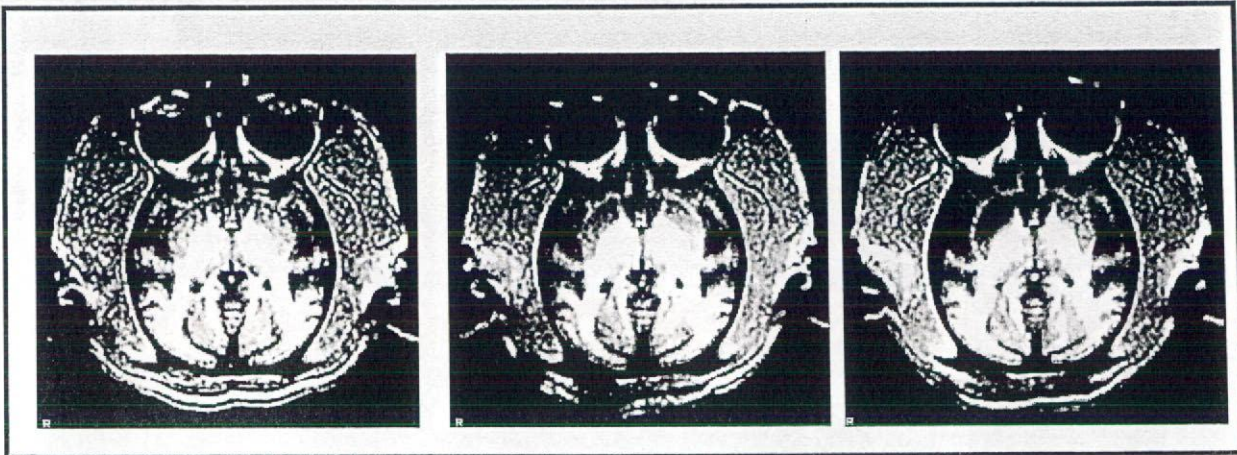
704

pre

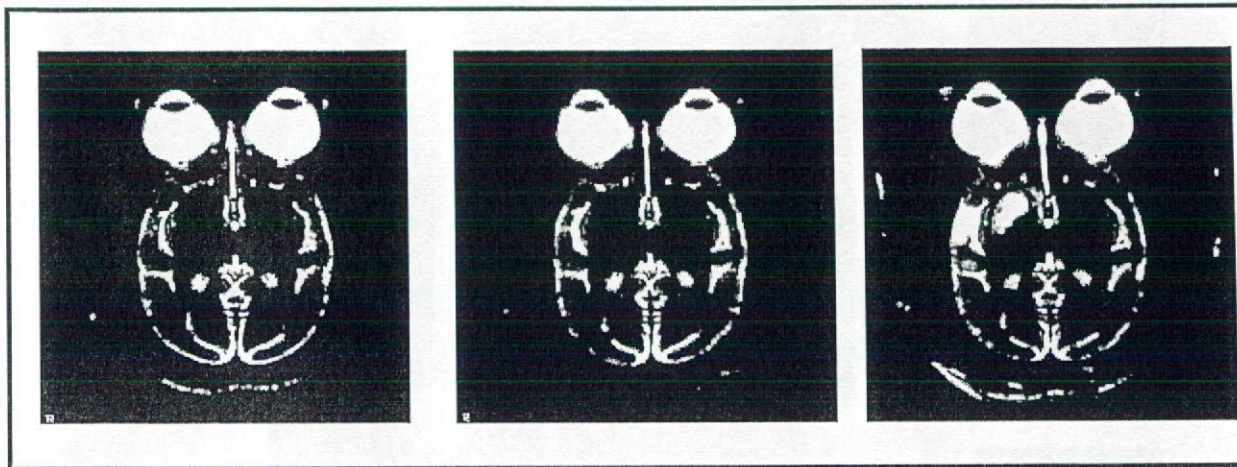
Post embolization

24hrs after embolization

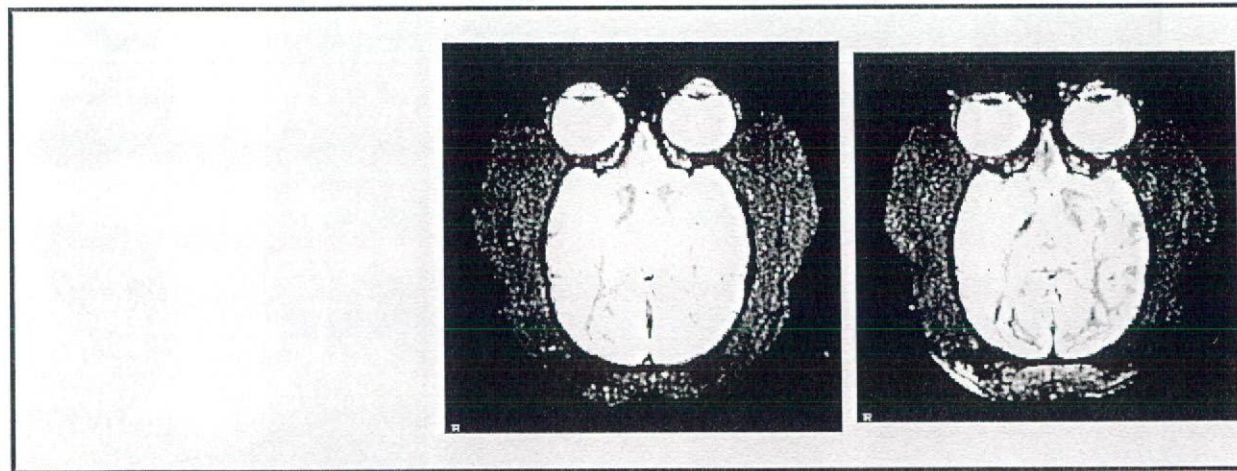
T1



T2



T2*



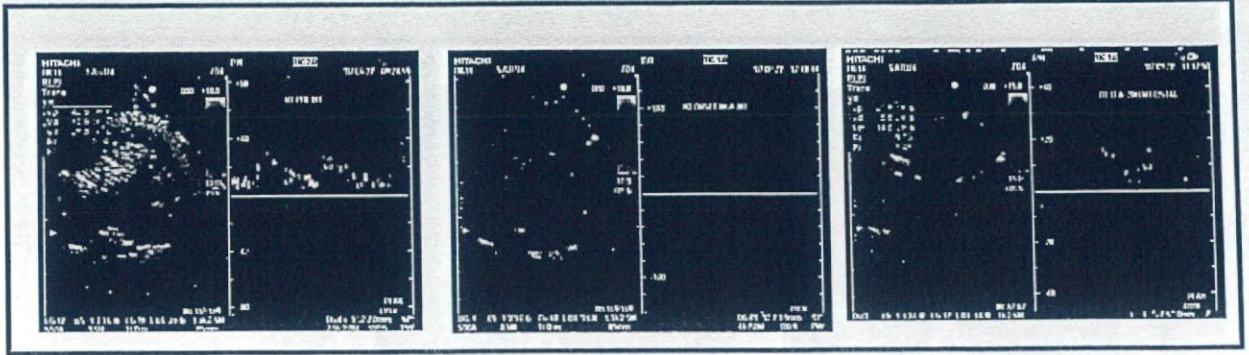
704

pre

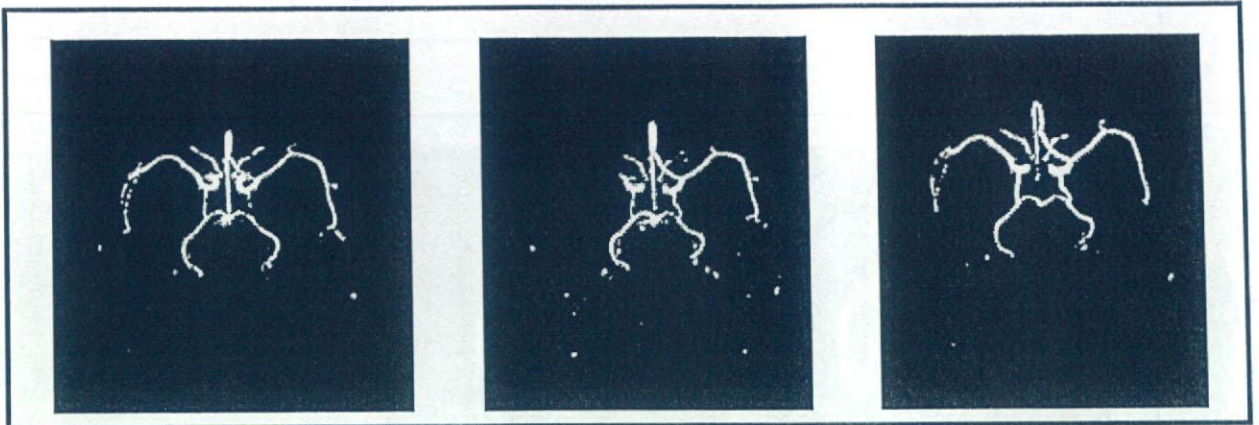
Post embolization

24hrs after embolization

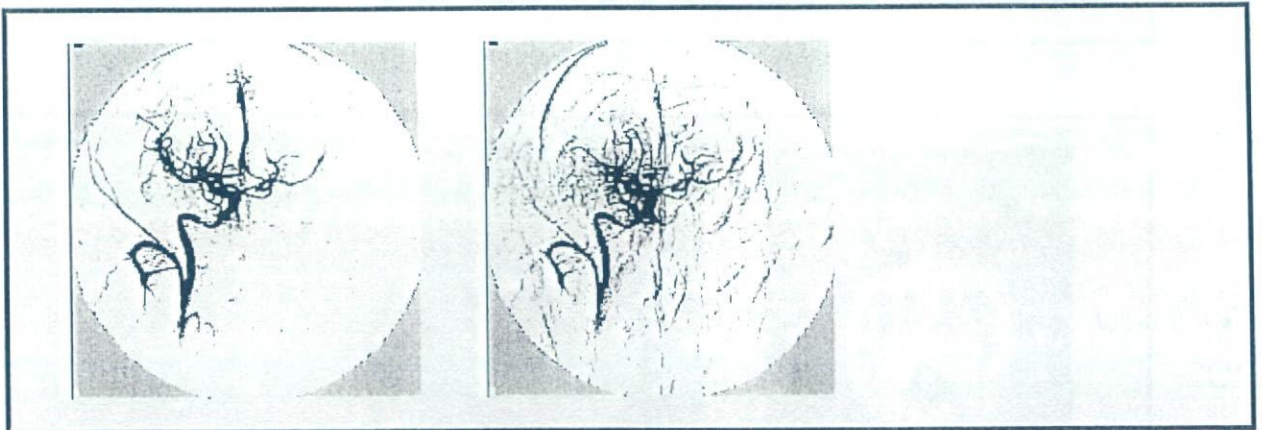
US



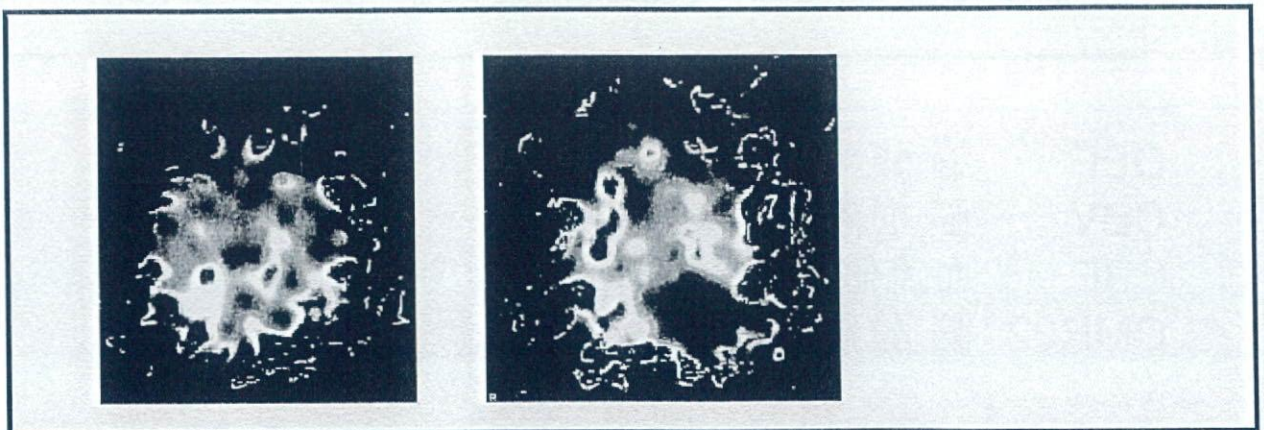
MRA



angio



OEF



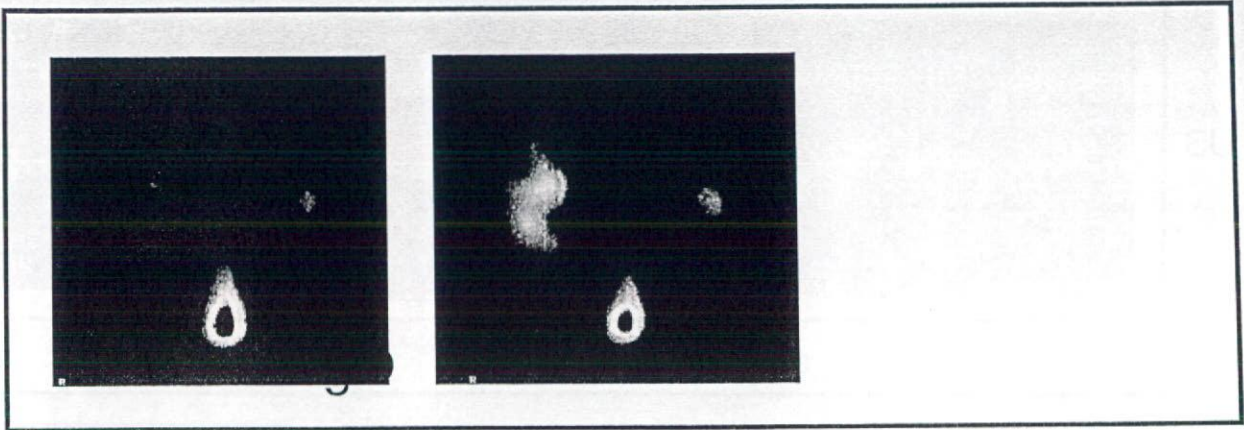
704

pre

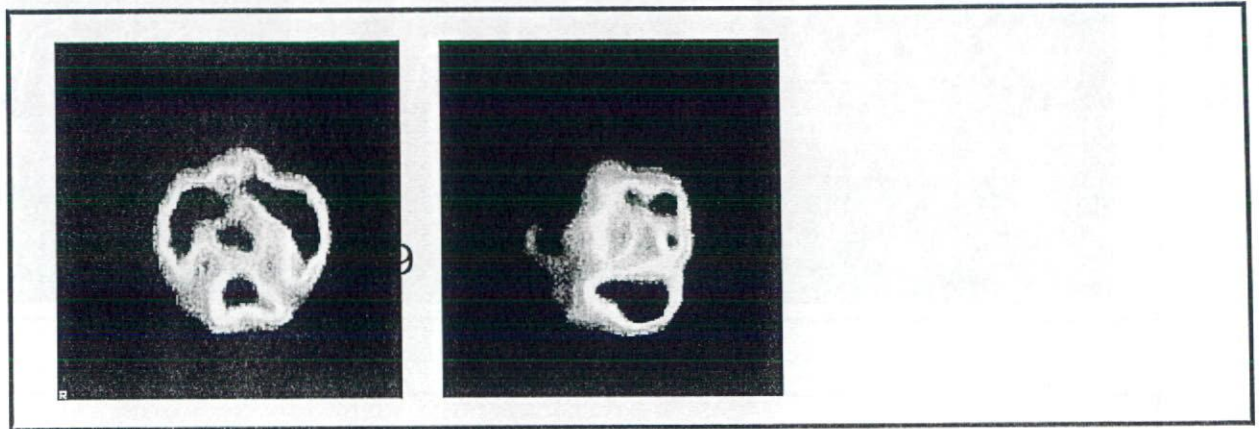
Post embolization

24hrs after embolization

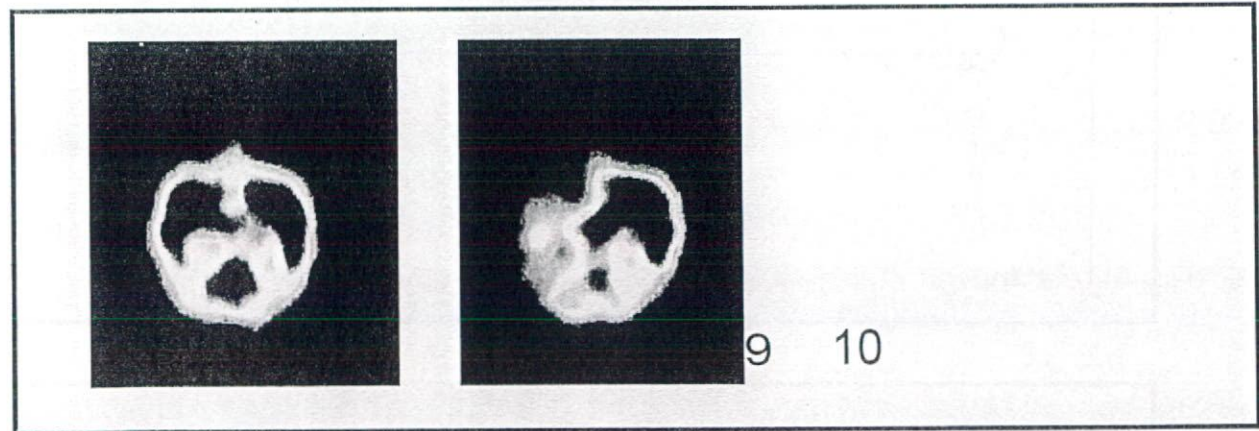
CBV



CBF



CM
RO2



- OEF 腦 酸素攝取率
- CBV 腦 血液量
- CBF 血流值
- CMR02 腦 酸素代謝量