[3] U. Kuhl, M. Pauschinger, P.L. Schwimmbeck, B. Seeberg, C. Lober, M. Noutsias, M. Poller, H.P. Schultheiss, Interferon-beta treatment eliminates cardiotropic viruses and improves left ventricular function in patients with myocardial persistence of viral genomes and left ventricular dysfunction, Circulation 107 (2003) 2793–2798.

[4] D.M. McNamara, R. Holubkov, R.C. Starling, G.W. Dec, E. Loh, G. Torre-Amione, A. Gass, K. Janosko, T. Tokarczyk, P. Kessler, D.L. Mann, A.M. Feldman, Controlled trial of intravenous immune globulin in recent-onset dilated cardiomyopathy, Circulation 103 (2001) 2254–2259.

[5] T. Sudoh, N. Minamino, K. Kangawa, H. Matsuo, C-type natriuretic peptide (CNP): a new member of natriuretic peptide family identified in porcine brain, Biochem. Biophys. Res. Commun. 168 (1990) 863–870.

[6] M. Furuya, K. Aisaka, T. Miyazaki, N. Honbou, K. Kawashima, T. Ohno, S. Tanaka, N. Minamino, K. Kangawa, H. Matsuo, C-type natriuretic peptide inhibits intimal thickening after vascular injury, Biochem. Biophys. Res. Commun. 193 (1993) 248–253.

[7] T. Horio, T. Tokudome, T. Maki, F. Yoshihara, S. Suga, T. Nishikimi, M. Kojima, Y. Kawano, K. Kangawa, Gene expression, secretion, and autocrine action of C-type natriuretic peptide in cultured adult rat cardiac fibroblasts, Endocrinology 144 (2003) 2279–2284.

[8] T. Tokudome, T. Horio, T. Soeki, K. Mori, I. Kishimoto, S. Suga, F. Yoshihara, Y. Kawano, M. Kohno, K. Kangawa, Inhibitory effect of C-type natriuretic peptide (CNP) on cultured cardiac myocyte hypertrophy: interference between CNP and endothelin-1 signaling pathways, Endocrinology 145 (2004) 2131–2140.

[9] T. Soeki, I. Kishimoto, H. Okumura, T. Tokudome, T. Horio, K. Mori, K. Kangawa, C-type natriuretic peptide, a novel antifibrotic and antihypertrophic agent, prevents cardiac remodeling after myocardial infarction, J. Am. Coll. Cardiol. 45 (2005) 608–616.

[10] T. Kashimura, M. Hayashi, M. Kodama, M. Nakazawa, S. Abe, T. Yoshida, H. Tachikawa, H. Hanawa, K. Kato, K. Watanabe, Y. Aizawa, Effects of imidapril and TA-606 on rat dilated cardiomyopathy after myocarditis, Jpn. Heart J. 44 (2003) 735–744.

[11] M. Kodama, Y. Matsumoto, M. Fujiwara, F. Masani, T. Izumi, A. Shibata, A novel experimental model of giant cell myocarditis induced in rats by immunization with cardiac myosin fraction, Clin. Immunol. Immunopathol. 57 (1990) 250–262.

[12] D.J. Nunez, M.C. Dickson, M.J. Brown, Natriuretic peptide receptor mRNAs in the rat and human heart, J. Clin. Invest. 90 (1992) 1966–1971.

[13] M. Kodama, H. Hanawa, M. Saeki, H. Hosono, T. Inomata, K. Suzuki, A. Shibata, Rat dilated cardiomyopathy after autoimmune giant cell myocarditis, Circ. Res. 75 (1994) 278–284.

[14] T. Itoh, N. Nagaya, S. Murakami, T. Fujii, T. Iwase, H. Ishibashi-Ueda, C. Yutani, M. Yamagishi, H. Kimura, K. Kangawa, C-type natriuretic peptide ameliorates monocrotaline-induced pulmonary hypertension in rats, Am. J. Respir. Crit. Care Med. 170 (2004) 1204–1211.

[15] T. Igaki, H. Itoh, S.I. Suga, N. Hama, Y. Ogawa, Y. Komatsu, J. Yamashita, K. Doi, T.H. Chun, K. Nakao, Effects of intravenously administered C-type natriuretic peptide in humans: comparison with atrial natriuretic peptide, Hypertens. Res. 21 (1998) 7–13.

[16] A. Ahluwalia, R.J. MacAllister, A.J. Hobbs, Vascular actions of natriuretic peptides. Cyclic GMP-dependent and -independent mechanisms, Basic. Res. Cardiol. 99 (2004) 83–89.

[17] H. Osawa, H. Yamabe, M. Kaizuka, N. Tamura, S. Tsunoda, Y. Baba, K. Shirato, F. Tateyama, K. Okumura, C-type natriuretic peptide inhibits proliferation and monocyte chemoattractant protein-1 secretion in cultured human mesangial cells, Nephron 86 (2000) 467–472.

[18] S. Murakami, N. Nagaya, T. Itoh, T. Fujii, T. Iwase, K. Hamada, H. Kimura, K. Kangawa, C-type natriuretic peptide attenuates bleomycin-induced pulmonary fibrosis in mice, Am. J. Physiol. Lung Cell. Mol. Physiol. 287 (2004) L1172–L1177.

[19] K. Yamahara, H. Itoh, T.H. Chun, Y. Ogawa, J. Yamashita, N. Sawada, Y. Fukunaga, M. Sone, T. Yurugi-Kobayashi, K. Miyashita, H. Tsujimoto, H. Kook, R. Feil, D.L. Garbers, F. Hofmann, K. Nakao, Significance and therapeutic potential of the natriuretic peptides/cGMP/cGMP-dependent protein kinase pathway in vascular regeneration, Proc. Natl. Acad. Sci. USA 100 (2003) 3404–3409.

[20] R. Dong, P. Liu, L. Wee, J. Butany, M.J. Sole, Verapamil ameliorates the clinical and pathological course of murine myocarditis, J. Clin. Invest. 90 (1992) 2022–2030.

[21] J.C. Choy, A.H. Lui, F. Moien-Afshari, K. Wei, B. Yanagawa, B.M. McManus, I. Laher, Coxsackievirus B3 infection compromises endothelial-dependent vasodilation of coronary resistance arteries, J. Cardiovasc. Pharmacol. 43 (2004) 39–47.

PEPTIDES 29 (2008) 599–605

available at www.sciencedirect.com

journal homepage: www.elsevier.com/locate/peptides



Plasma adrenomedullin as an independent predictor of future cardiovascular events in high-risk patients: Comparison with C-reactive protein and adiponectin

Hidenori Nishida [a], *Takeshi Horio* [a,*], *Yoshihiko Suzuki* [b], *Yoshio Iwashima* [c], *Kei Kamide* [a], *Kenji Kangawa* [d], *Yuhei Kawano* [a]

[a] *Division of Hypertension and Nephrology, Department of Medicine, National Cardiovascular Center, 5-7-1 Fujishirodai, Suita, Osaka 565-8565, Japan*
[b] *Department of Internal Medicine, Circulatory and Fluid Regulation, Faculty of Medicine, University of Miyazaki, Miyazaki, Japan*
[c] *Department of Geriatric Medicine, Osaka University Graduate School of Medicine, Suita, Japan*
[d] *National Cardiovascular Center Research Institute, Suita, Japan*

ARTICLE INFO

Article history:
Received 30 November 2007
Received in revised form
6 December 2007
Accepted 7 December 2007
Published on line 23 December 2007

Keywords:
Adrenomedullin
C-reactive protein
Adiponectin
Cardiovascular disease
Morbidity

ABSTRACT

This study investigated the predictive power of plasma adrenomedullin (AM) for future cardiovascular (CV) events. In 121 patients with multiple CV risk factors and/or disease, plasma concentrations of AM, high sensitive C-reactive protein (hs-CRP), and adiponectin were measured. During follow-up periods (mean, 3.5 years) after the baseline assessment, 28 patients newly experienced CV events such as stroke/transient ischemic attack, acute coronary syndrome, and congestive heart failure. The plasma level of AM, but not hs-CRP or adiponectin, was significantly higher in patients who had CV events than in event-free subjects. When the patients were divided into three groups by tertiles of basal levels of AM (<10.1, 10.1–13.1, and ≥13.1 fmol/mL), cumulative event-free rates by the Kaplan–Meier method were decreased according to the increase in basal AM levels (83.2%, 68.6%, and 52.8% in the lowest, middle, and highest tertiles of AM, respectively; log-rank test, $P = 0.033$). By univariate Cox regression analysis, previous coronary artery disease, creatinine clearance, and plasma AM and hs-CRP levels were significantly associated with CV events during follow-up. Among these possible predictors, high plasma AM ($P = 0.004$) and low creatinine clearance ($P = 0.043$) were independent determinants for morbidity in multivariate analysis. These findings indicate that plasma AM is a powerful independent predictor of future CV events in high-risk patients, suggesting its predictive value is superior to that of hs-CRP or adiponectin.

1. Introduction

Adrenomedullin (AM) is a potent vasodilator peptide that was originally isolated from human pheochromocytoma [14]. Subsequent studies have revealed that AM is widely distributed in various organs and tissues including the cardiovascular (CV) system [6,38,39]. Plasma levels of AM are elevated in various CV disorders, such as essential hypertension [8,17,24], chronic renal failure [8,24], coronary artery disease [15,22,41], congestive heart failure [11,25], ischemic

* *Corresponding author*. Tel.: +81 6 6833 5012; fax: +81 6 6872 8091.
E-mail address: thorio@ri.ncvc.go.jp (T. Horio).
0196-9781/$ – see front matter
doi:10.1016/j.peptides.2007.12.006

stroke [7], and peripheral artery disease [40,41], and the degree of increase in AM levels is shown to be in proportion to the clinical severity of the disease [8,15,17,22,24,25,40]. These previous findings suggest that plasma AM may be a biochemical marker reflecting the presence and severity of CV complications in patients with CV risk factors. However, it remains unclear whether plasma AM levels have a predictive value for the occurrence of future CV events in such patients.

It is currently recognized that low-grade inflammation and insulin resistance contribute importantly to the initiation and progression of CV lesions [19,20]. In fact, many studies have shown that a mild increase in C-reactive protein (CRP), a sensitive inflammatory marker, is an independent predictor of future CV events [1,31–34,36]. It has also been shown that decreased blood levels of adiponectin, an adipocytokine with insulin sensitizing, anti-inflammatory, and anti-atherogenic properties, are a novel predictive factor for atherosclerotic CV disease [5,9,16,37,47]. In the present study, we aimed to determine whether an elevated level of plasma AM is a significant predictor of future CV events in high-risk patients, comparing its predictive power with those of CRP and adiponectin.

2. Methods

2.1. Study subjects

A total of 121 patients with two or more CV risk factors and/or diseases were enrolled in the present study. All subjects were inpatients who were admitted to the National Cardiovascular Center, Suita, Japan, for examination and treatment of hypertension, diabetes mellitus, and CV diseases including stable coronary artery disease. Patients with acute coronary syndrome (i.e., acute myocardial infarction and unstable angina pectoris) or congestive heart failure were excluded from the study. Hypertension was defined as a systolic blood pressure of ≥140 mmHg and/or a diastolic blood pressure of ≥90 mmHg by repeated measurements or when subjects had already been treated with antihypertensive drugs. Diabetes mellitus was diagnosed according to the American Diabetes Association criteria (a fasting plasma glucose of ≥126 mg/dL and/or a plasma glucose level at 2 h after 75 g oral glucose load of ≥200 mg/dL), or when medication was taken for treatment of hyperglycemia. Diagnosis of hyperlipidemia required a serum total cholesterol level of ≥220 mg/dL and/or a serum triglyceride level of ≥150 mg/dL or the use of lipid-lowering drugs. Coronary artery disease was diagnosed by electrocardiographic, radioisotope cardiographic, and coronary angiographic criteria. All subjects gave their informed consent to participate in the present study. All procedures of the present study were carried out in accordance with institutional and national ethical guidelines for human studies.

2.2. Biochemical measurement

Peripheral blood samples were obtained at rest in the supine position. Blood for AM measurement was immediately transferred into ice-chilled glass tubes containing disodium EDTA (1 mg/mL) and aprotinin (500 U/mL) and centrifuged for 10 min at 4 °C. Plasma samples were frozen and stored at −80 °C until assayed. Human AM concentration was measured by immunoradiometric assay using a specific kit (AM RIA SHIONOGI, Shionogi Pharmaceutical Co. Ltd., Osaka, Japan), as described previously [27].

Plasma adiponectin was determined by a sandwich ELISA system (Adiponectin ELISA Kit, Otsuka Pharmaceutical Co. Ltd.), as previously reported [9,10]. High sensitive CRP (hs-CRP) was measured by nephelometry (SRL Inc., Tokyo, Japan). Fasting plasma glucose, hemoglobin A1c, total cholesterol, triglycerides, high-density lipoprotein (HDL) cholesterol, and serum creatinine were determined by standard laboratory measurements. Creatinine clearance was calculated from the Cockcroft–Gault formula [3].

2.3. Follow-up

After the initial assessment, all patients periodically visited our hospital for the treatment of risk factors (hypertension, diabetes mellitus, and/or hyperlipidemia) and CV diseases. CV events as clinical endpoints were stroke and transient ischemic attack confirmed by clinical symptoms, computed tomography, magnetic resonance angiography, and/or cerebrovascular angiography findings, acute coronary syndrome confirmed by electrocardiographic changes, coronary angiography, and/or myocardial scintigraphy findings, and congestive heart failure requiring hospitalization. Congestive heart failure was defined as clinical symptoms and signs (dyspnea, pulmonary rale, and/or leg edema), hypoxemia, and findings of chest radiography (pulmonary congestion and/or pleural effusion). Diagnosis of heart failure and need for admission were determined by clinical physicians who were blind to the basal level of AM, hs-CRP, or adiponectin. For patients who experienced multiple episodes, the analysis included only the first event. For patients without any CV event mentioned above, the date of censor was that of the last contact with the subject. The mean follow-up period was 42.0 months (0.3–81.3 months).

2.4. Statistical analysis

Statistical analysis was performed using StatView Version 5 Software (Abacus Concepts Inc., Berkeley, CA). Values were expressed as mean ± S.D. An unpaired Student's t-test was used for comparison between the two groups. The significance of differences among the three groups was evaluated by an unpaired ANOVA with subsequent Scheffe's multiple comparison test. Event-free curves were derived by means of the Kaplan–Meier method and were compared by log-rank test. The predictive value for CV events was tested by univariate Cox proportional hazards regression analysis. Then, a multivariate analysis using stepwise regression model was applied to identify independent predictors and their prognostic power. A value of $P < 0.05$ was accepted as statistically significant.

3. Results

Baseline clinical characteristics of total study subjects are shown in Table 1. The present subjects had a high percentage

Table 1 – Clinical characteristics of total subjects (n = 121)

Variable	
Age (years)	67.6 ± 9.5
Sex (men) (%)	68.6
Body mass index (kg/m^2)	23.6 ± 4.4
Hypertension (%)	84.3
Diabetes mellitus (%)	44.6
Hyperlipidemia (%)	57.0
Smokers (current or past) (%)	76.0
Previous coronary artery disease (%)	48.8
Systolic blood pressure (mmHg)	136 ± 18
Diastolic blood pressure (mmHg)	73 ± 11
Heart rate (beats/min)	65 ± 8
Fasting plasma glucose (mg/dL)	106 ± 31
Hemoglobin A1c (%)	6.2 ± 1.6
Total cholesterol (mg/dL)	191 ± 30
Triglycerides (mg/dL)	114 ± 51
HDL cholesterol (mg/dL)	45.1 ± 13.4
Creatinine clearance (mL/min)	78.6 ± 35.5

Values are mean ± S.D. or percentage.

Table 2 – Association of basal AM, hs-CRP, and adiponectin levels with the following CV events

Variable	CV event		P
	(−) (n = 93)	(+) (n = 28)	
AM (fmol/mL)	11.6 ± 3.3	14.6 ± 6.3	<0.001
Hs-CRP (mg/dL)	0.23 ± 0.30	0.31 ± 0.65	0.359
Adiponectin (μg/mL)	5.8 ± 4.7	7.2 ± 5.6	0.214

Values are mean ± S.D.

of CV risk factors such as hypertension, diabetes mellitus, hyperlipidemia, and smoking habit, although their blood pressure, plasma glucose, and serum lipid levels were controlled by adequate treatments. In addition, 59 patients (48.8%) had a history of coronary artery disease.

During follow-up periods after the baseline assessment, 28 patients newly experienced major CV events. There were six subjects with cerebral infarction, one with cerebral hemorrhage, five with transient ischemic attack, six with unstable angina pectoris, one with acute myocardial infarction, and nine with congestive heart failure. The plasma AM level was significantly higher in patients who had CV events than in event-free subjects (Table 2). There was no significant difference in hs-CRP or adiponectin level between the two groups.

All subjects were divided into three groups according to tertiles of basal AM levels (<10.1, 10.1–13.1, and ≥13.1 fmol/mL). Mean plasma levels of basal AM in the lowest, middle, and highest tertile groups were 8.3 ± 1.1, 11.5 ± 1.0, and 16.9 ± 4.1 fmol/mL, respectively (Table 3). Age, sex, body mass index, prevalence of hypertension, diabetes mellitus, and hyperlipidemia, smoking habit, blood pressure, heart rate, and glucose and lipid parameters did not differ among the three groups. The group in the highest tertile of AM had a significantly higher rate of past history of coronary artery disease, and lower creatinine clearance compared with the other two groups. Hs-CRP and adiponectin levels were also elevated in the highest tertile than in the lowest and/or middle tertiles. CV event-free Kaplan–Meier curves in the three groups are presented in Fig. 1. Cumulative event-free rates in the lowest, middle, and highest tertiles of AM were 83.2%, 68.6%, and 52.8%, respectively. These curves showed that higher basal levels of plasma AM were significantly associated with higher rate of CV events during follow-up (log-rank test, P = 0.033).

Table 3 – Clinical characteristics of three groups divided by tertiles of basal AM levels

Variable	Lowest tertile (n = 40)	Middle tertile (n = 40)	Highest tertile (n = 41)
Age (years)	66.6 ± 8.4	66.8 ± 10.6	69.3 ± 9.3
Sex (men) (%)	75.0	60.0	70.7
Body mass index (kg/m^2)	24.3 ± 3.9	24.3 ± 5.6	22.1 ± 3.0
Hypertension (%)	80.0	77.5	95.1
Diabetes mellitus (%)	37.5	55.0	41.5
Hyperlipidemia (%)	67.5	55.0	48.8
Smokers (current or past) (%)	77.5	67.5	82.9
Previous coronary artery disease (%)	35.0	40.0	70.7*,−
Systolic blood pressure (mmHg)	133 ± 14	135 ± 22	139 ± 16
Diastolic blood pressure (mmHg)	74 ± 9	73 ± 12	71 ± 11
Heart rate (beats/min)	65 ± 9	64 ± 8	65 ± 8
Fasting plasma glucose (mg/dL)	109 ± 30	103 ± 27	107 ± 35
Hemoglobin A1c (%)	6.4 ± 2.1	6.2 ± 1.3	6.0 ± 1.2
Total cholesterol (mg/dL)	191 ± 31	199 ± 29	183 ± 29
Triglycerides (mg/dL)	125 ± 59	109 ± 51	108 ± 39
HDL cholesterol (mg/dL)	44.6 ± 12.6	47.7 ± 14.7	43.0 ± 12.6
Creatinine clearance (mL/min)	87.4 ± 26.1	85.4 ± 39.1	63.3 ± 35.4*,−
AM (fmol/mL)	8.3 ± 1.1	11.5 ± 1.0*	16.9 ± 4.1*,−
Hs-CRP (mg/dL)	0.11 ± 0.14	0.17 ± 0.23	0.47 ± 0.60*,−
Adiponectin (μg/mL)	4.7 ± 3.5	6.4 ± 4.4	7.5 ± 6.2*

Values are mean ± S.D. or percentage.
* P < 0.05 vs. lowest tertile.
− P < 0.05 vs. middle tertile.

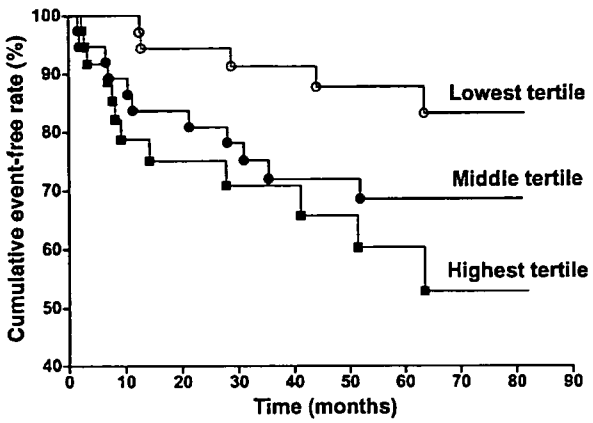

Fig. 1 – CV event-free curves obtained with the Kaplan–Meier method in the three groups divided by tertiles of basal AM levels. Cumulative event-free rates in the lowest, middle, and highest tertiles were 83.2%, 68.6%, and 52.8%, respectively (log-rank test, P = 0.033). Lowest tertile, basal AM <10.1 fmol/mL (n = 40); middle tertile, basal AM ≥10.1 and <13.1 fmol/mL (n = 40); highest tertile, basal AM ≥13.1 fmol/mL (n = 41).

Cox regression analysis was performed to examine the predictive power of plasma AM for future CV events, comparing with those of hs-CRP and adiponectin. In the univariate analysis, past history of coronary artery disease, creatinine clearance, and plasma hs-CRP in addition to plasma AM were significantly related to the incidence of CV events during the follow-up periods (Table 4). Among these possible predictive factors, high plasma AM and low creatinine clearance were independent predictors of CV events in the multivariate analysis, and the predictive value of AM for morbidity was most significant (+10% per 1-fmol/mL increase in AM, P = 0.004). Furthermore, even when the multivariate regression was reanalyzed after excluding subjects with previous coronary artery disease, the predictive value of AM for CV events was still significant, independently of creatinine clearance and other variables (hazard ratio 1.20 (per 1 fmol/mL increase), 95% confidence interval 1.06–1.35, P = 0.004).

4. Discussion

Plasma AM levels are known to be elevated in various pathological states, including several CV diseases [7,8,11, 15,17,22,24,25,40,41]. In addition, some studies showed that AM level was a predictor of survival in patients with acute myocardial infarction and chronic heart failure [12,23,29,30]. However, there have been no reports examining whether plasma AM can predict the occurrence of CV events in subjects with CV risk factors. Thus, the present study has demonstrated for the first time that an increased level of plasma AM becomes a significant predictor of future CV events in high-risk patients, independently of a variety of influencing factors.

In this study, we compared the predictive power of AM with those of hs-CRP and adiponectin. Our findings showed that neither hs-CRP nor adiponectin was an independent

Table 4 – Predictors of future CV events by univariate and multivariate Cox regression analysis

	Hazard ratio (95% CI)	P
Univariate analysis		
Age, 10 years	1.34 (0.88–2.04)	0.174
Sex, male	1.13 (0.50–2.56)	0.772
Body mass index, 1 kg/m^2	0.97 (0.88–1.07)	0.523
Hypertension, yes	2.02 (0.61–6.71)	0.249
Diabetes mellitus, yes	1.90 (0.89–4.06)	0.097
Hyperlipidemia, yes	1.00 (0.47–2.11)	0.999
Smoking (current or past), yes	1.65 (0.63–4.33)	0.313
Previous coronary artery disease, yes	2.90 (1.31–6.43)	0.009
Systolic blood pressure, 10 mmHg	1.03 (0.83–1.27)	0.799
Diastolic blood pressure, 10 mmHg	0.90 (0.65–1.24)	0.509
Heart rate, 5 beats/min	1.02 (0.83–1.27)	0.828
Fasting plasma glucose, 10 mg/dL	1.07 (0.97–1.19)	0.196
Hemoglobin A1c, 1%	1.14 (0.96–1.36)	0.126
Total cholesterol, 10 mg/dL	0.90 (0.80–1.02)	0.102
Triglycerides, 10 mg/dL	1.00 (0.94–1.07)	0.960
HDL cholesterol, 5 mg/dL	1.02 (0.90–1.16)	0.769
Creatinine clearance, 10 mL/min	0.80 (0.70–0.93)	0.003
AM, 1 fmol/mL	1.13 (1.06–1.19)	<0.001
Hs-CRP, 0.1 mg/dL	1.08 (1.00–1.18)	0.047
Adiponectin, 1 μg/mL	1.08 (0.99–1.16)	0.054
Multivariate analysis		
Creatinine clearance, 10 mL/min	0.87 (0.76–0.99)	0.043
AM, 1 fmol/mL	1.10 (1.03–1.18)	0.004

CI: confidence interval. In the multivariate analysis using stepwise regression model, all factors that had a significant association in the univariate analysis, i.e., previous coronary artery disease, creatinine clearance, AM, and hs-CRP, were included as possible independent variables.

predictor of future CV events, in contrast to the powerful prognostic value of AM. Several large epidemiological studies have suggested that CRP measurement predicts the risk of future CV events [1,31–34,36], whereas others have failed to identify CRP as a significant independent risk factor, especially after using multivariate analysis [28,42,44]. Hs-CRP was one of the significant predictors of CV events in univariate Cox regression analysis of the present study. However, since there was a close correlation between hs-CRP and AM levels (data not shown) and the predictive power of hs-CRP was weaker than that of AM in univariate analysis, hs-CPR might not become an independent predictor in multivariate analysis. As for adiponectin, it has been shown that low levels of plasma adiponectin are a predictor of CV events and mortality [4,5,9,16,37,47], but some studies reported that adiponectin did not predict future risk of coronary artery disease after adjusted for classical risk factors [18,35]. In addition, recent studies revealed that high, rather than low, adiponectin levels were associated with increased mortality and incidence of myocardial infarction in patients with chronic heart failure, chronic kidney disease, and stable angina [2,13,21]. Thus, the value of adiponectin as an independent risk marker for CV events and mortality remains controversial at present.

Although the exact reason behind the superiority of plasma AM over hs-CRP and adiponectin as a predictor of CV events in the present study remains to be elucidated, a number of mechanisms may be involved. AM is produced in various organs and tissues, but the main source of circulating AM is the blood vessels (especially vascular endothelial cells) [38], in contrast to the major sites of the production of CRP and adiponectin. Therefore, AM may directly reflect vascular inflammation and endothelial injury during the initiation and development of atherosclerosis. In fact, increased plasma levels of AM were reported to be associated with the progression of atherosclerotic lesions [7,40]. Furthermore, since several studies have shown that ischemic and hypoxic conditions stimulate the production and secretion of AM [26,43,46], it is possible that the increase in baseline AM might be induced by silent cerebral or cardiac ischemia before attack. Plasma AM has also been shown to increase in response to left ventricular systolic and diastolic dysfunction [23,25,45], suggesting the possibility that baseline AM in our subjects could detect latent cardiac disorders. Therefore, as AM comprehensively reflects vascular inflammation and injury, atherosclerotic change, systemic and myocardial ischemia, and cardiac dysfunction, plasma AM might become a sensitive marker of future CV disease.

There were some limitations in the present study. The sample size of our subjects was small to evaluate the predictive power of AM discretely for cerebrovascular, coronary, and heart failure events. In addition, the prognostic value of AM for all-cause and CV death could not be investigated. As another limitation of this study, we did not consider the influence of medication during follow-up on the occurrence of CV disease. Therefore, the use of statin, aspirin, renin angiotensin system inhibitors, and β-blockers and the alteration of dosage of these drugs after the initial assessment might bias the outcome of the present study. Furthermore, we did not examine the change of plasma AM levels during follow-up periods. It is possible that the prognostic potential of AM may be raised by serially evaluating its plasma level in high-risk patients.

In conclusion, the present findings indicate that plasma AM is a powerful independent predictor of future CV events in patients with multiple CV risk factors, and suggest that its prognostic value is superior to that of hs-CRP or adiponectin. However, further investigations using larger population of high-risk patients will be required to establish the usefulness of AM as a novel predictive marker for CV diseases.

Acknowledgments

This study was supported by the Program for Promotion of Fundamental Studies in Health Sciences of the Pharmaceuticals and Medical Devices Agency (PMDA). The authors thank Yoko Saito for her technical assistance.

REFERENCES

[1] Best LG, Zhang Y, Lee ET, Yeh JL, Cowan L, Palmieri V, et al. C-reactive protein as a predictor of cardiovascular risk in a population with a high prevalence of diabetes: the Strong Heart Study. Circulation 2005;112:1289–95.

[2] Cavusoglu E, Ruwende C, Chopra V, Yanamadala S, Eng C, Clark LT, et al. Adiponectin is an independent predictor of all-cause mortality, cardiac mortality, and myocardial infarction in patients presenting with chest pain. Eur Heart J 2006;27:2300–9.

[3] Cockcroft DW, Gault MH. Prediction of creatinine clearance from serum creatinine. Nephron 1976;16:31–41.

[4] Efstathiou SP, Tsioulos DI, Tsiakou AG, Gratsias YE, Pefanis AV, Mountokalakis TD. Plasma adiponectin levels and five-year survival after first-ever ischemic stroke. Stroke 2005;36:1915–9.

[5] Frystyk J, Berne C, Berglund L, Jensevik K, Flyvbjerg A, Zethelius B. Serum adiponectin is a predictor of coronary heart disease: a population-based 10-year follow-up study in elderly men. J Clin Endocrinol Metab 2007;92:571–6.

[6] Horio T, Nishikimi T, Yoshihara F, Nagaya N, Matsuo H, Takishita S, et al. Production and secretion of adrenomedullin in cultured rat cardiac myocytes and nonmyocytes: stimulation by interleukin-1β and tumor necrosis factor-α. Endocrinology 1998;139: 4576–80.

[7] Hosomi N, Ohyama H, Takahashi T, Shinomiya K, Naya T, Ban CR, et al. Plasma adrenomedullin and carotid atherosclerosis in atherothrombotic ischemic stroke. J Hypertens 2004;22:1945–51.

[8] Ishimitsu T, Nishikimi T, Saito Y, Kitamura K, Eto T, Kangawa K, et al. Plasma levels of adrenomedullin, a newly identified hypotensive peptide, in patients with hypertension and renal failure. J Clin Invest 1994;94: 2158–61.

[9] Iwashima Y, Horio T, Kumada M, Suzuki Y, Kihara S, Rakugi H, et al. Adiponectin and renal function, and implication as a risk of cardiovascular disease. Am J Cardiol 2006;98: 1603–8.

[10] Iwashima Y, Horio T, Suzuki Y, Kihara S, Rakugi H, Kangawa K, et al. Adiponectin and inflammatory markers in peripheral arterial occlusive disease. Atherosclerosis 2006;188:384–90.

[11] Jougasaki M, Wei CM, McKinley LJ, Burnett Jr JC. Elevation of circulating and ventricular adrenomedullin in human congestive heart failure. Circulation 1995;92:286–9.
[12] Katayama T, Nakashima H, Furudono S, Honda Y, Suzuki S, Yano K. Evaluation of neurohumoral activation (adrenomedullin, BNP, catecholamines, etc.) in patients with acute myocardial infarction. Intern Med 2004;43: 1015–22.
[13] Kistorp C, Faber J, Galatius S, Gustafsson F, Frystyk J, Flyvbjerg A, et al. Plasma adiponectin, body mass index, and mortality in patients with chronic heart failure. Circulation 2005;112:1756–62.
[14] Kitamura K, Kangawa K, Kawamoto M, Ichiki Y, Nakamura S, Matsuo H, et al. Adrenomedullin: a novel hypotensive peptide isolated from human pheochromocytoma. Biochem Biophys Res Commun 1993;192:553–60.
[15] Kobayashi K, Kitamura K, Hirayama N, Date H, Kashiwagi T, Ikushima I, et al. Increased plasma adrenomedullin in acute myocardial infarction. Am Heart J 1996;131:676–80.
[16] Koenig W, Khuseyinova N, Baumert J, Meisinger C, Lowel H. Serum concentrations of adiponectin and risk of type 2 diabetes mellitus and coronary heart disease in apparently healthy middle-aged men: results from the 18-year follow-up of a large cohort from southern Germany. J Am Coll Cardiol 2006;48:1369–77.
[17] Kohno M, Hanehira T, Kano H, Horio T, Yokokawa K, Ikeda M, et al. Plasma adrenomedullin concentrations in essential hypertension. Hypertension 1996;27:102–7.
[18] Lawlor DA, Davey Smith G, Ebrahim S, Thompson C, Sattar N. Plasma adiponectin levels are associated with insulin resistance, but do not predict future risk of coronary heart disease in women. J Clin Endocrinol Metab 2005;90:5677–83.
[19] Libby P, Ridker PM, Maseri A. Inflammation and atherosclerosis. Circulation 2002;105:1135–43.
[20] McFarlane SI, Banerji M, Sowers JR. Insulin resistance and cardiovascular disease. J Clin Endocrinol Metab 2001;86:713–8.
[21] Menon V, Li L, Wang X, Greene T, Balakrishnan V, Madero M, et al. Adiponectin and mortality in patients with chronic kidney disease. J Am Soc Nephrol 2006;17:2599–606.
[22] Miyao Y, Nishikimi T, Goto Y, Miyazaki S, Daikoku S, Morii I, et al. Increased plasma adrenomedullin levels in patients with acute myocardial infarction in proportion to the clinical severity. Heart 1998;79:39–44.
[23] Nagaya N, Nishikimi T, Uematsu M, Yoshitomi Y, Miyao Y, Miyazaki S, et al. Plasma adrenomedullin as an indicator of prognosis after acute myocardial infarction. Heart 1999;81:483–7.
[24] Nishikimi T, Horio T, Kohmoto Y, Yoshihara F, Nagaya N, Inenaga T, et al. Molecular forms of plasma and urinary adrenomedullin in normal, essential hypertension and chronic renal failure. J Hypertens 2001;19:765–73.
[25] Nishikimi T, Saito Y, Kitamura K, Ishimitsu T, Eto T, Kangawa K, et al. Increased plasma levels of adrenomedullin in patients with heart failure. J Am Coll Cardiol 1995;26:1424–31.
[26] Ogita T, Hashimoto E, Yamasaki M, Nakaoka T, Matsuoka R, Kira Y, et al. Hypoxic induction of adrenomedullin in cultured human umbilical vein endothelial cells. J Hypertens 2001;19:603–8.
[27] Ohta H, Tsuji T, Asai S, Tanizaki S, Sasakura K, Teraoka H, et al. A simple immunoradiometric assay for measuring the entire molecules of adrenomedullin in human plasma. Clin Chim Acta 1999;287:131–43.
[28] Pirro M, Bergeron J, Dagenais GR, Bernard PM, Cantin B, Despres JP, et al. Age and duration of follow-up as modulators of the risk for ischemic heart disease associated with high plasma C-reactive protein levels in men. Arch Intern Med 2001;161:2474–80.
[29] Pousset F, Masson F, Chavirovskaia O, Isnard R, Carayon A, Golmard JL, et al. Plasma adrenomedullin, a new independent predictor of prognosis in patients with chronic heart failure. Eur Heart J 2000;21:1009–14.
[30] Richards AM, Doughty R, Nicholls MG, MacMahon S, Sharpe N, Murphy J, et al. Plasma N-terminal pro-brain natriuretic peptide and adrenomedullin: prognostic utility and prediction of benefit from carvedilol in chronic ischemic left ventricular dysfunction. J Am Coll Cardiol 2001;37: 1781–7.
[31] Ridker PM, Cushman M, Stampfer MJ, Tracy RP, Hennekens CH. Inflammation, aspirin, and the risk of cardiovascular disease in apparently healthy men. N Engl J Med 1997;336:973–9.
[32] Ridker PM, Hennekens CH, Buring JE, Rifai N. C-reactive protein and other markers of inflammation in the prediction of cardiovascular disease in women. N Engl J Med 2000;342:836–43.
[33] Ridker PM, Rifai N, Rose L, Buring JE, Cook NR. Comparison of C-reactive protein and low-density lipoprotein cholesterol levels in the prediction of first cardiovascular events. N Engl J Med 2002;347:1557–65.
[34] Rutter MK, Meigs JB, Sullivan LM, D'Agostino Sr RB, Wilson PWF. C-reactive protein, the metabolic syndrome, and prediction of cardiovascular events in the Framingham Offspring Study. Circulation 2004;110:380–5.
[35] Sattar N, Wannamethee G, Sarwar N, Tchernova J, Cherry L, Wallace AM, et al. Adiponectin and coronary heart disease: a prospective study and meta-analysis. Circulation 2006;114:623–9.
[36] Schulze MB, Rimm EB, Li T, Rifai N, Stampfer MJ, Hu FB. C-reactive protein and incident cardiovascular events among men with diabetes. Diabetes Care 2004;27:889–94.
[37] Schulze MB, Shai I, Rimm EB, Li T, Rifai N, Hu FB. Adiponectin and future coronary heart disease events among men with type 2 diabetes. Diabetes 2005;54: 534–9.
[38] Sugo S, Minamino N, Kangawa K, Miyamoto K, Kitamura K, Sakata J, et al. Endothelial cells actively synthesize and secrete adrenomedullin. Biochem Biophys Res Commun 1994;201:1160–6.
[39] Sugo S, Minamino N, Shoji H, Kangawa K, Kitamura K, Eto T, et al. Production and secretion of adrenomedullin from vascular smooth muscle cells: augmented production by tumor necrosis factor-α. Biochem Biophys Res Commun 1994;203:719–26.
[40] Suzuki Y, Horio T, Hayashi T, Nonogi H, Kitamura K, Eto T, et al. Plasma adrenomedullin concentration is increased in patients with peripheral arterial occlusive disease associated with vascular inflammation. Regul Pept 2004;118:99–104.
[41] Suzuki Y, Horio T, Nonogi H, Hayashi T, Kitamura K, Eto T, et al. Adrenomedullin as a sensitive marker for coronary and peripheral arterial complications in patients with atherosclerotic risks. Peptides 2004;25:1321–6.
[42] van der Meer IM, de Maat MP, Kiliaan AJ, van der Kuip DA, Hofman A, Witteman JC. The value of C-reactive protein in cardiovascular risk prediction: the Rotterdam Study. Arch Intern Med 2003;163:1323–8.
[43] Wang X, Yue TL, Barone FC, White RF, Clark RK, Willette RN, et al. Discovery of adrenomedullin in rat ischemic cortex and evidence for its role in exacerbating focal brain ischemic damage. Proc Natl Acad Sci USA 1995;92:11480–4.
[44] Wilson PW, Nam BH, Pencina M, D'Agostino Sr RB, Benjamin EJ, O'Donnell CJ. C-reactive protein and risk of cardiovascular disease in men and women from the Framingham Heart Study. Arch Intern Med 2005;165: 2473–8.

[45] Yoshihara F, Horio T, Nakamura S, Yoshii M, Ogata C, Nakahama H, et al. Adrenomedullin reflects cardiac dysfunction, excessive blood volume, and inflammation in hemodialysis patients. Kidney Int 2005;68:1355–63.
[46] Yoshihara F, Horio T, Nishikimi T, Matsuo H, Kangawa K. Possible involvement of oxidative stress in hypoxia-induced adrenomedullin secretion in cultured rat cardiomyocytes. Eur J Pharmacol 2002;436:1–6.
[47] Zoccali C, Mallamaci F, Tripepi G, Benedetto FA, Cutrupi S, Parlongo S, et al. Adiponectin, metabolic risk factors, and cardiovascular events among patients with end-stage renal disease. J Am Soc Nephrol 2002;13:134–41.

ELSEVIER

Cardiovascular Research 76 (2007) 110–118

Cardiovascular Research

www.elsevier.com/locate/cardiores

Infusion of adrenomedullin improves acute myocarditis *via* attenuation of myocardial inflammation and edema

Bobby Yanagawa [a,1], Masaharu Kataoka [a,1], Shunsuke Ohnishi [a,*,1], Makoto Kodama [b], Koichi Tanaka [a], Yoshinori Miyahara [a], Hatsue Ishibashi-Ueda [c], Yoshifusa Aizawa [b], Kenji Kangawa [d], Noritoshi Nagaya [a,*]

[a] *Department of Regenerative Medicine and Tissue Engineering, National Cardiovascular Center Research Institute, Osaka, Japan*
[b] *Division of Cardiology, Niigata University Graduate School of Medical and Dental Sciences, Niigata, Japan*
[c] *Department of Pathology, National Cardiovascular Center, Osaka, Japan*
[d] *Department of Biochemistry, National Cardiovascular Center Research Institute, Osaka, Japan*

Received 23 January 2006; received in revised form 7 May 2007; accepted 24 May 2007
Available online 6 June 2007
Time for primary review 23 days

Abstract

Objective: Our aim was to assess whether adrenomedullin (AM), a potent vasodilator peptide with a variety of cardioprotective effects, has a therapeutic potential for the treatment of acute myocarditis in a rat model.
Methods: One week after myosin injection, rats received a continuous infusion of AM or vehicle for 2 weeks, and pathological and physiological investigations were performed.
Results: AM treatment significantly reduced the infiltration of inflammatory cells in myocarditic hearts, and decreased the expressions of macrophage chemoattractant protein-1, matrix metalloproteinase-2 and transforming growth factor-β. Myocardial edema indicated by increased heart weight to body weight ratio and wall thickness was attenuated by AM infusion (5.7±0.5 *vs.* 6.5±0.4 g/kg, and 1.9±0.3 *vs.* 2.8±0.5 mm, respectively). Infusion of AM significantly improved left ventricular maximum d*P*/d*t* and fractional shortening of myocarditic hearts (4203±640 *vs.* 3450±607 mm Hg/s, and 21.3±4.1 *vs.* 14.7±5.1%, respectively).
Conclusion: Infusion of AM improved cardiac function and pathological findings in a rat model of acute myocarditis. Thus, infusion of AM may be a potent therapeutic strategy for acute myocarditis.

Keywords: Autoimmune myocarditis; Adrenomedullin; Angiogenesis; Inflammation

1. Introduction

Acute myocarditis is a non-ischemic heart disease characterized by myocardial inflammation and edema. This disease is associated with rapidly progressive heart failure, arrhythmias and sudden death [1]. Although early evidence for efficacy of immunoglobulin and interferon therapy appears promising, these results have yet to be demonstrated in randomized or controlled clinical trials [2]. Current therapeutic options are restricted to supportive care for heart failure or arrhythmias [3]. The lack of specific treatment and the potential severity of the illness emphasize the importance of novel and effective therapeutic strategies for myocarditis.

Adrenomedullin (AM) is a potent vasodilator peptide that was originally isolated from human pheochromocytoma [4]. Earlier studies have shown that AM has beneficial hemodynamic effects on failing hearts *via* its vasodilatory action and diuretic effects [5,6]. Furthermore, AM has direct cardioprotective effects such as anti-inflammatory effects [7], inhibition

* Corresponding authors. Department of Regenerative Medicine and Tissue Engineering, National Cardiovascular Center Research Institute, 5-7-1 Fujishirodai, Suita, Osaka 565-8565, Japan. Tel.: +81 6 6833 5012; fax: +81 6 6835 5496.
E-mail addresses: sonishi@ri.ncvc.go.jp (S. Ohnishi), nnagaya@ri.ncvc.go.jp (N. Nagaya).
[1] These authors contributed equally to this work.

0008-6363/$ - see front matter © 2007 European Society of Cardiology. Published by Elsevier B.V. All rights reserved.
doi:10.1016/j.cardiores.2007.05.027

of apoptosis [8], induction of angiogenesis [9] and attenuation of myocardial hypertrophy [10]. Interestingly, AM has also been shown to decrease endothelial hyperpermeability in the heart [11]. These findings raise the possibility that infusion of AM may attenuate myocardial inflammation and edema in acute myocarditis. Although previous findings have demonstrated that infusion of AM is effective for heart failure, its therapeutic effects in acute myocarditis are still unknown.

Experimental autoimmune myocarditis can be induced in rats by immunizing them with cardiac myosin, providing a model that resembles human giant cell myocarditis [12,13]. Although the majority of acute myocarditis is linked to a viral infection such as coxsackievirus B3, this viral infection can in some cases cause an autoimmune myocarditis with chronic myocardial inflammation without viral persistence, due to the exposure of autoantigens such as cardiac myosin to the immune system [14,15].

Thus, the purposes of this study were 1) to investigate whether infusion of AM improves cardiac function and pathological findings including myocardial inflammation and edema in rats with myosin-induced myocarditis, and 2) to investigate the underlying mechanisms responsible for the effects of AM.

2. Methods

2.1. Experimental autoimmune myocarditis

Purified cardiac myosin from the ventricular muscle of pig hearts was prepared according to a procedure described previously [16]. The antigen was dissolved at a concentration of 20 mg/ml in phosphate-buffered saline (PBS) containing 0.3 M KCl mixed with an equal volume of complete Freund's adjuvant (CFA) containing 11 mg/ml of *Mycobacterium tuberculosis* (Difco Laboratories, Sparks, MD, USA).

Male 10-week-old Lewis rats were used in the present study. Rats were anesthetized by intraperitoneal injection of pentobarbital (30 mg/kg) and were given an injection of either 0.2 ml of antigen–adjuvant emulsion or saline mixed with CFA into the footpad. One week after myosin injection, an osmotic pump (Alzet, Cupertino, CA, USA) was filled with either AM (0.05 μg/kg/min) or PBS for 2 weeks, and implanted subcutaneously between the scapulae. This protocol resulted in the creation of 3 groups ($n=11$ in each group): sham rats given PBS (sham group), myosin-treated rats given PBS (control group), and myosin-treated rats given AM (AM group). The dose of AM used in this study has anti-apoptotic effects without significant hypotension [8]. The investigation conforms with the Guide for the Care and Use of Laboratory Animals published by the US National Institutes of Health.

2.2. Histopathology

After completion of hemodynamic measurements on day 21 post-myosin injection, the heart was excised above the origin of the great vessels, and ventricular weight was recorded. Midventricular portions of the heart were formalin-fixed and embedded in paraffin, and 4 μm-sections were cut and stained with hematoxylin and eosin (H&E). H&E-stained sections were graded by a cardiovascular pathologist (H.I-U.) as described previously [17]. Briefly, coagulation necrosis, granulation, inflammation and edema were evaluated without knowledge of the experimental groups on the following scale: 0, no or questionable presence; 1, limited focal distribution less than 25% area of the section; 2, intermediate severity covering less than 50% area of the section; 3, intermediate severity covering greater than 50% and less than 75% area of the section; and 4, coalescent and extensive foci more than 75% area to the entirety of the transversely sectioned ventricular tissue (5 fields per rat, $n=8$ in each group).

2.3. Picrosirius red staining

Paraffin-embedded sections were submitted for picrosirius staining for total collagen distribution. Slides were hydrated, placed in Weigert's iron hematoxylin and in Bouin's fluid (70% saturated aqueous picric acid, 5% acetic acid, 25% formalin) for 10 min. The slides were rinsed in distilled water and placed in 0.025% picrosirius red solution overnight. The sections were rinsed, dehydrated, cleared, and mounted. Amount of collagen stain was quantitated using image analysis software on high-powered (×200) cross-sectional images (10 fields per rat, $n=5$ in each group).

2.4. Immunohistochemistry

Paraffin-embedded heart sections were washed in increasing concentrations of ethanol and then in PBS. Immunohistochemical staining of the sections was performed with antibodies raised against macrophage chemoattractant protein-1 (MCP-1) (BD Bioscience Pharmingen, San Jose, CA, USA) or CD68 (DakoCytomation, Glostrup, Denmark), a marker of monocytes and macrophages. The number of CD68-positive cells was counted with a light microscope (×200, 10 fields per rat, $n = 6$ in each group). To detect capillary endothelial cells, immunohistochemical staining of the sections was performed with a rabbit polyclonal antibody raised against von Willebrand factor (vWF, DakoCytomation). The number of capillary vessels was counted using a light microscope (×200, 10 fields per rat, $n=6$ in each group).

2.5. Western blot analysis

Western blot was performed as previously described [18]. Briefly, LV tissues were homogenized in 0.1% Tween-20 with a protease inhibitor, loaded (40 μg) on a 7.5% sodium dodecyl sulfate-polyacrylamide gel, and blotted onto a polyvinylidene fluoride membrane (Millipore, Billerica, MA, USA). After blocking for 2 h, membranes were incubated with MMP-2 (Laboratory Vision, Fremont, CA, USA) or MMP-9

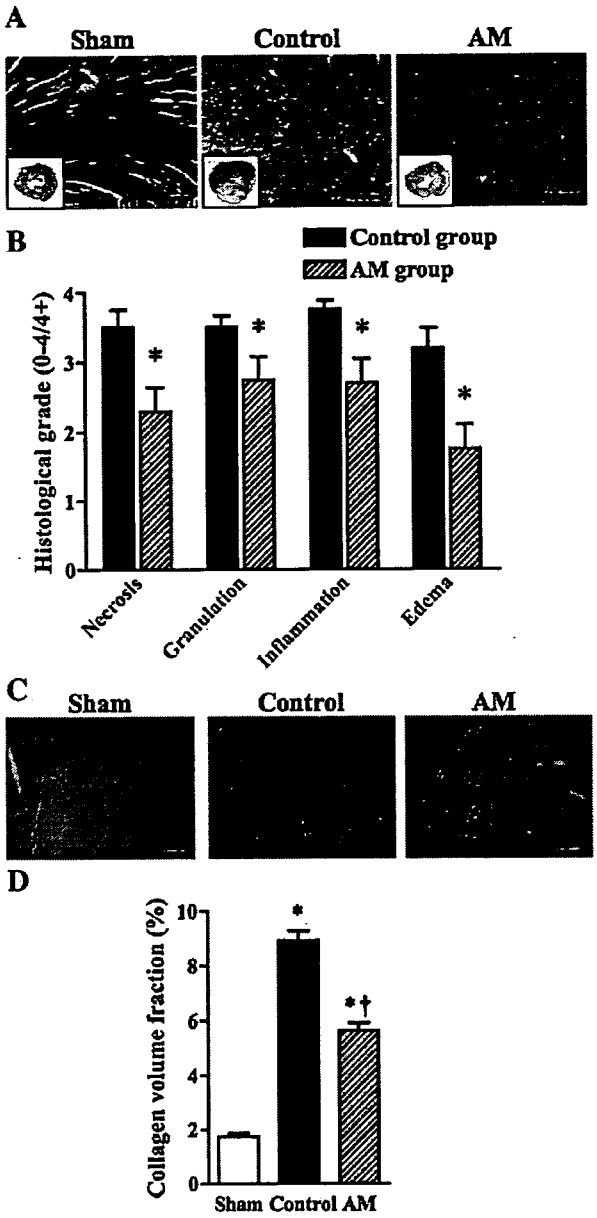

Fig. 1. Pathological findings in acute myocarditis after AM infusion. A: Representative H&E staining of myocardial sections showed markedly decreased inflammation and tissue necrosis in AM-treated hearts as compared to control hearts. Insets are transverse sections of myocardial freewall. B: Semi-quantitative histological grades for necrosis and tissue granulation as well as for inflammation and edema were significantly lower in AM-treated hearts as compared to control hearts ($n=8$ in each group). Sham tissues exhibited no measurable pathological changes. Data are mean±S.E. *, $P<0.05$ *vs.* control. C: Representative picrosirius staining showed decreased collagen deposition in AM-treated hearts as compared to control hearts. D: Collagen volume fraction in 10 random representative fields (×200) confirmed a significant decrease in AM-treated hearts *vs.* control hearts ($n=5$ in each group). Scale bars: 50 μm. Data are mean±S.E. *, $P<0.05$ *vs.* sham; †, $P<0.05$ *vs.* control.

(Chemicon, Temecula, CA, USA) rabbit polyclonal antibodies (1:200), then incubated with peroxidase labeled with secondary antibody (1:1000). Positive protein bands were visualized with an ECL kit (GE Healthcare, Piscataway, NJ, USA) and measured by densitometry. A mouse polyclonal antibody against β-actin (Santa Cruz Biotechnology, Santa Cruz, CA, USA) was used as a control ($n=5$ in each group).

2.6. Quantitative real-time reverse transcription-polymerase chain reaction (RT-PCR)

Heart tissues ($n=5$ in each group) were homogenized with TissueLyser (Qiagen, Hilden, Germany). Total RNA was extracted using RNeasy Mini Kit (Qiagen), followed by reverse transcription into cDNA using the avian myeloblastosis virus transcriptase (Ambion, Austin, TX, USA), according to the manufacturers' protocol. PCR amplification was performed in 50 μl containing 1 μl of cDNA and 25 μl of Power SYBR Green PCR Master Mix (Applied Biosystems, Foster City, CA, USA). The following sequence-specific primers were used for TGF-β, as described previously [19]: forward, 5′-GTTCTTCAATACGTCAGACATTCG-3′; reverse, 5′-CATTATCTTTGCTGTCACAAGAGC-3′. Glyceraldehyde 3-phosphate dehydrogenase (GAPDH) mRNA amplified from the same samples was served as an internal control: forward, 5′-GAACATCATCCCTGCATCCA-3′; reverse, 5′-CCAGTGAGCTTCCCGTTCA-3′. After an initial denaturation at 95 °C for 10 min, a 2-step cycle procedure was used (denaturation at 95 °C for 15 s, annealing and extension at 60 °C for 1 min) for 40 cycles in a 7700 sequence detector (Applied Biosystems). The data were analyzed with Sequence Detection Systems software.

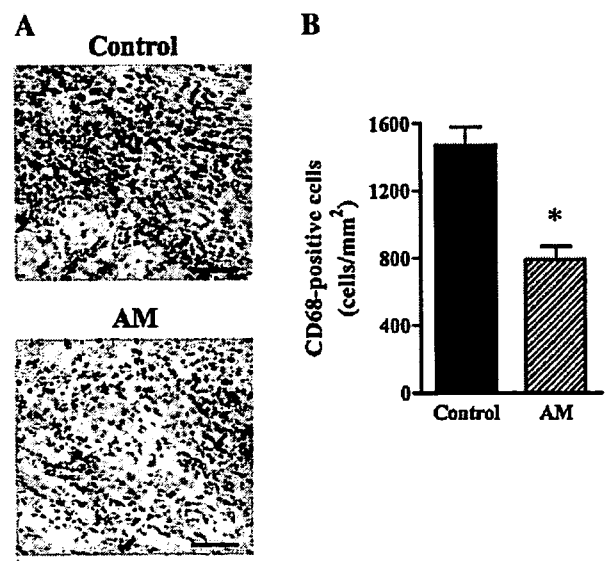

Fig. 2. Infiltration of inflammatory cells in myocardium. A: Immunohistochemical analysis of CD68-positive cell infiltration in myocardium. AM infusion markedly attenuated the increase in CD68-positive cells in myocarditic hearts. Scale bars: 50 μm. B: Semi-quantitative analysis of CD68-positive cell infiltration. CD68-positive cells in 10 random representative high-power fields (×200) confirmed a significant decrease in AM-treated hearts *vs.* control hearts ($n=6$ in each group). Data are mean±S.E. *, $P<0.05$ *vs.* control.

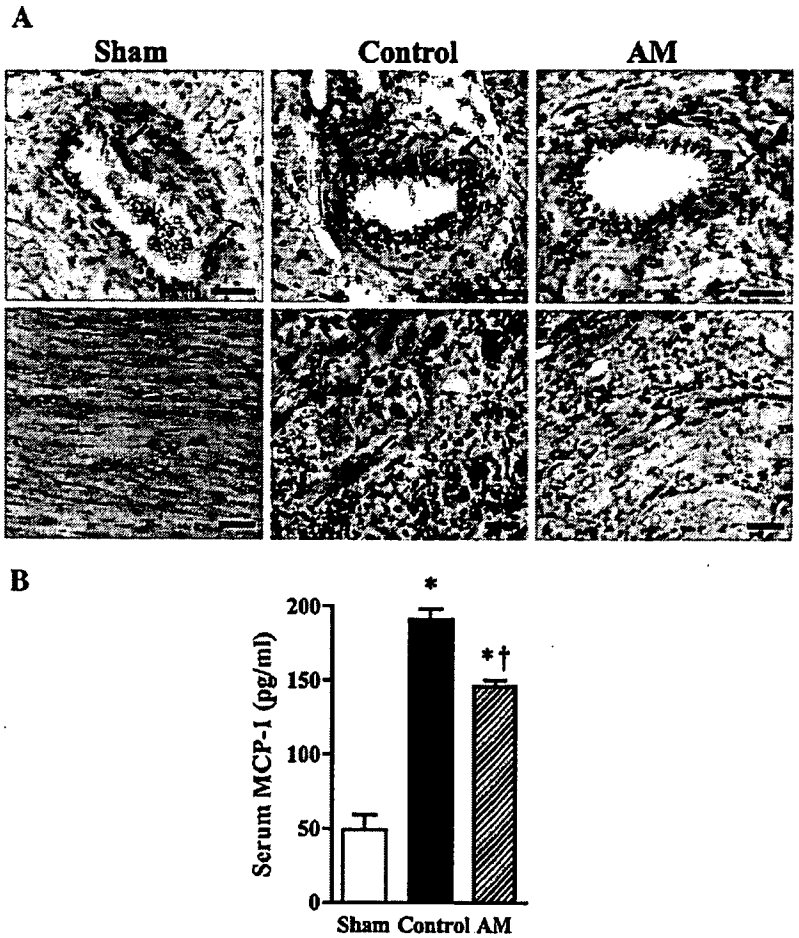

Fig. 3. Effects of AM infusion on MCP-1 expression. A: Representative myocardial sections immunohistochemically stained with anti-MCP-1 antibody showed increased vascular endothelial and myocyte staining of MCP-1 (arrows) and the presence of giant cells (arrowheads) in control hearts as compared to AM-treated hearts. Sham hearts showed subtle endothelial staining. Scale bars: 20 μm. B: Serum MCP-1 level was greatly increased in myocarditic rats. However, the increase in serum MCP-1 was significantly attenuated by AM infusion ($n=6$ in each group). Data are mean±S.E. *, $P<0.05$ *vs.* sham; †, $P<0.05$ *vs.* control.

2.7. Enzyme-linked immunosorbent assay (ELISA)

To investigate the effect of AM infusion on serum MCP-1 level, blood was drawn from the heart before excision ($n=6$ in each group). Blood was centrifuged and serum samples were frozen and stored at −80 °C. Serum MCP-1 level was measured by ELISA according to the manufacturer's instructions (Invitrogen, Carlsbad, CA, USA).

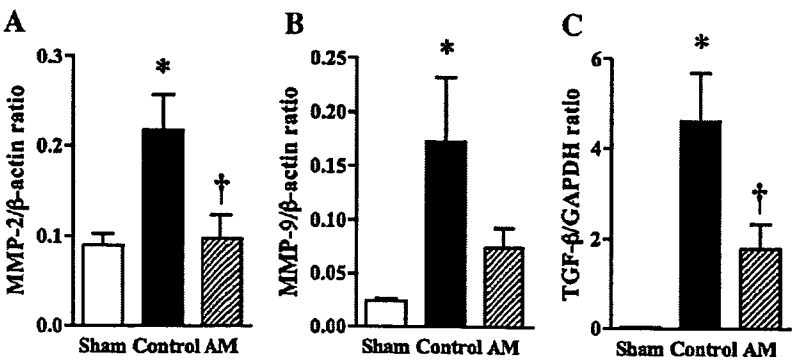

Fig. 4. Effects of AM infusion on MMP and TGF-β expression. A and B: Western blot analysis for MMP-2 (A) and -9 (B) expression. Levels of MMP-2 and -9 were significantly increased in control hearts. MMP-2 expression was markedly decreased by AM infusion, and MMP-9 expression tended to be decreased after AM infusion ($n=5$ in each group). C: Quantitative real-time reverse transcription-polymerase chain reaction (RT-PCR) for TGF-β expression. Expression of TGF-β was increased in myocarditis and significantly decreased by AM treatment ($n=5$ in each group). Data are mean±S.E. *, $P<0.05$ *vs.* sham; †, $P<0.05$ *vs.* control.

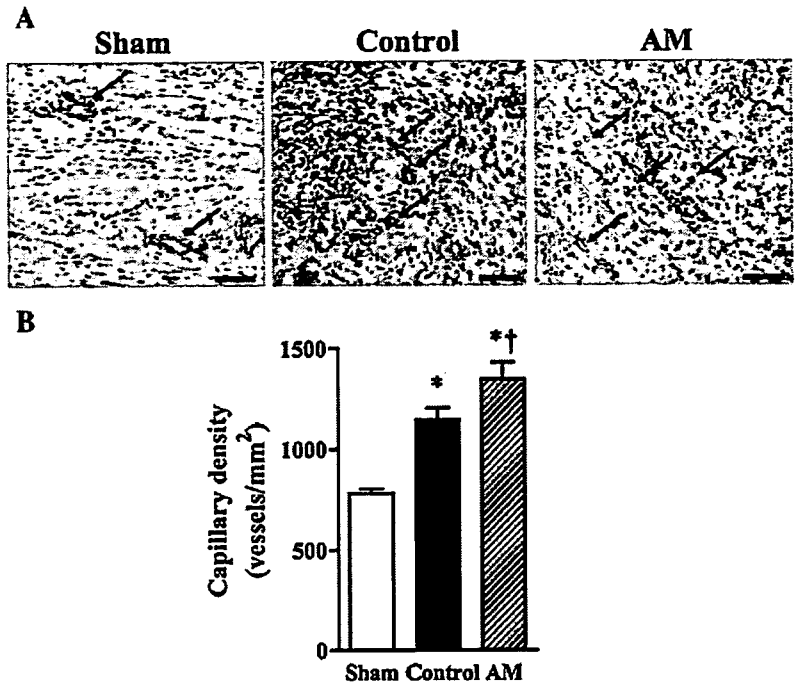

Fig. 5. Increased endothelial regeneration with AM infusion. A: Immunohistochemical demonstration of von Willebrand factor in myocardium. Arrows indicate microvasculature. Scale bars: 20 μm. B: Capillary density measured in 10 random representative high-power fields (×200) showed a significant increase in control hearts and a further increase in AM-treated hearts *vs.* sham hearts ($n=6$ in each group). Data are mean±S.E. *, $P<0.05$ *vs.* sham; †, $P<0.05$ *vs.* control.

2.8. Hemodynamic study

Hemodynamic measurements were taken on day 21 post-myosin injection ($n=7$ in each group). Rats were anesthetized by intraperitoneal injection of pentobarbital sodium (30 mg/kg) as a supplement to maintain mild anesthesia. A 1.5 Fr micromanometer-tipped catheter (Millar Instruments, Houston, TX, USA) was advanced into the left ventricle through the right carotid artery, and a polyethylene catheter (PE-50) was advanced into the right ventricle through the right jugular vein to measure right ventricular pressure. Heart rate was also monitored by electrocardiography. As hemodynamic indices, heart rate, mean arterial pressure, LV end-diastolic pressure, maximum dP/dt, and minimum dP/dt were used.

2.9. Echocardiography

Echocardiography was performed on day 21 post-myosin injection. A 12-MHz probe was placed in the left 4th intercostal space for M-mode imaging using 2D echocardiography (Sonos 5500, Philips, Bothell, WA, USA). M-mode tracings were obtained at the level of the papillary muscles. Anterior and posterior end-diastolic wall thickness, left ventricular (LV) end-diastolic and end-systolic dimension, LV fractional shortening (FS), and LV ejection fraction (EF) were measured in three consecutive cardiac cycles by the American Society for Echocardiology leading-edge method ($n=10$ in each group). EF and FS were calculated from the following formula, respectively:

$$EF = (\text{end-diastolic volume} - \text{end-systolic volume}) / \text{end-diastolic volume}$$

$$FS = (\text{end-diastolic diameter} - \text{end-systolic diameter}) / \text{end-diastolic diameter}$$

2.10. Statistical analysis

All data were expressed as mean±S.E. Comparisons of parameters among the groups were made by one-way

Table 1
Physiological profiles of three experimental groups

	Sham	Control	AM
Body weight, g	236±2	197±2*	199±2*
Ventricular weight, g	0.70±0.01	1.28±0.02*	1.15±0.03*†
Lung/body weight	4.9±0.4	4.9±0.5	5.0±0.8
Heart rate, bpm	432±10	373±11	393±6
MAP, mm Hg	103±3	77±5*	93±3†
LVSP, mm Hg	127±3	103±5*	117±3†
LVEDP, mm Hg	4±1	21±5*	14±3

Sham, sham rats given vehicle; Control, myosin-treated rats given vehicle; AM, myosin-treated rats given AM; MAP, mean arterial pressure; LVSP, left ventricular systolic pressure; LVEDP, left ventricular end-diastolic pressure. Data are mean±S.E. *$P<0.05$ *vs.* sham; †$P<0.05$ *vs.* control. $n=7$ in each group.

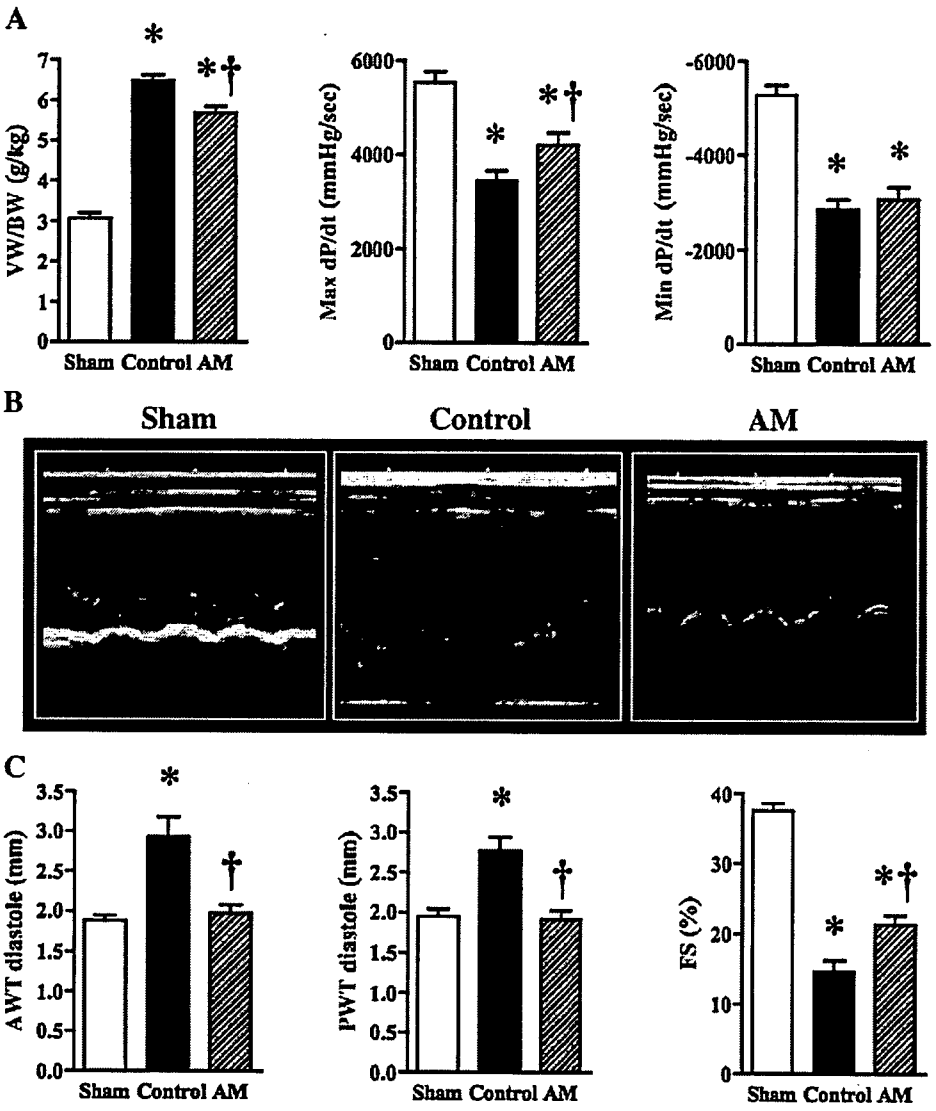

Fig. 6. Effects of AM infusion on physiologic properties and hemodynamic parameters. A: Effects of AM infusion on physiologic properties ($n=7$ in each group). B: Representative echocardiographic images show wall thickening and poor movement in myocarditis and improvement with AM treatment. C: Effects of AM infusion on echocardiographic findings ($n=10$ in each group). VW/BW, ventricular weight/body weight ratio; Max dP/dt, maximum dP/dt; Min dP/dt, minimum dP/dt; AWT, anterior wall thickness; PWT, posterior wall thickness; %FS, %fractional shortening. Data are mean ± S.E. *, $P<0.05$ *vs.* sham; †, $P<0.05$ *vs.* control.

ANOVA, followed by Newman–Keuls' test. Comparisons of parameters between two groups were made by Student's *t*-test. A value of $P<0.05$ was considered statistically significant.

3. Results

3.1. Histopathological improvement after AM infusion

Sections of left ventricular tissue demonstrated substantial myocardial necrosis, infiltration of inflammatory cells and edema in the control group, which was significantly limited primarily to areas directly adjacent to arterial vessels with AM treatment (Fig. 1, panel A). Blinded histological grading confirmed decreased myocyte necrosis, granulation, inflammation and tissue edema in the AM group as compared in the control group (Fig. 1, panel B). Picrosirius red staining revealed increased collagen deposition in the control group (Fig. 1, panel C). However, AM infusion attenuated collagen deposition in the myocardium (Fig. 1, panel D).

Table 2
Echocardiographic findings

	Sham	Control	AM
LVDd, mm	4.9±0.1	6.5±0.2*	7.3±0.3*
LVDs, mm	3.1±0.1	5.7±0.2*	5.7±0.3*
EF, %	75±1	35±3*	52±2*†

Sham, sham rats given vehicle; Control, myosin-treated rats given vehicle; AM, myosin-treated rats given AM; LVDd, left ventricular diastolic dimension; LVDs, left ventricular systolic dimension; EF, ejection fraction. Data are mean ± S.E. *$P<0.05$ *vs.* sham; †$P<0.05$ *vs.* control. $n=10$ in each group.

3.2. Infiltration of CD68-positive cells in myocardium

A significant decrease in infiltration of CD68-positive inflammatory cells was observed in the AM group as compared to the control group (790±80 *vs.* 1468±109 cells/mm^2; Fig. 2, panel A and B). Sham tissues showed little or no myocardial CD68 positivity (data not shown).

3.3. Expression of MCP-1 after AM infusion

The expression of MCP-1 was increased in myocarditis; it was localized to the vascular endothelium and also in myocytes surrounding and adjacent to the areas of inflammation (Fig. 3, panel A). Heart sections in the AM group showed a partial decrease in MCP-1 expression. Serum MCP-1 level was greatly increased in the control group, whereas a significant decrease was observed in the AM group (Fig. 3, panel B).

3.4. Effects of AM infusion on MMPs and TGF-β expression

Western blotting analysis revealed that myocardial levels of MMP-2 and -9 were significantly increased in the control group. MMP-2 expression was markedly decreased by AM infusion, and MMP-9 expression tended to be decreased after AM infusion (Fig. 4, panel A). Quantitative real-time RT-PCR analysis demonstrated increased expression of TGF-β in the heart of the control group which was significantly attenuated by AM treatment (Fig. 4, panel B). AM infusion did not significantly influence cardiac expression of IL-1β and TNF-α (data not shown).

3.5. Angiogenesis induced by AM infusion

To determine the effect of AM treatment on angiogenesis, vWF-stained heart sections were subjected to capillary density counting. Capillary density was increased in the control group, particularly in areas directly adjacent to tissue necrosis (1146±57 *vs.* 782±21 cells/mm^2, Fig. 5, panel A and B). However, in AM-treated tissues, capillary density was further significantly increased not only in the peri-necrotic areas but also in apparently healthy myocardium (1347±82 *vs.* 1146±57cells/mm^2), suggesting that stimulation of angiogenesis was further augmented by AM treatment.

3.6. Heart weight and hemodynamics after AM infusion

The physiological and catheter-derived functional properties on day 21 post-myosin injection are summarized in Table 1 and Fig. 6, panel A. Myocarditic hearts showed significantly increased heart weight to body weight ratio, which was decreased by AM treatment. AM treatment also significantly improved maximum dP/dt. For both minimum dP/dt and LVEDP, we did not find significant differences. On echocardiography, AM administration significantly attenuated increased wall thickness after acute myocarditis. AM significantly improved LV fractional shortening and ejection fraction, although LVDd did not significantly differ between control and AM groups (Table 2 and Fig. 6, panel B and C).

4. Discussion

In the present study, AM treatment showed the following effects in acute myocarditis: 1) reduced necrosis, inflammation and edema in the myocardium; 2) attenuated expression of MCP-1, MMP-2 and TGF-β; 3) increased capillary density suggestive of angiogenesis; and 4) improved cardiac function.

This experimental autoimmune myocarditis model is triphasic, consisting of an antigen priming phase from days 0 to 14, an autoimmune response phase from days 14 to 21, and a reparative phase thereafter, associated chronically with a dilated cardiomyopathy phenotype [20]. MCP-1 expression is increased in the heart from days 15 to 27 post-myosin injection, and serum MCP-1 level is elevated from days 15 to 24 [21]. We treated rats with AM at 1 week after myosin injection, corresponding to an early time point in the disease process. Pathological examination demonstrated that infusion of AM attenuated myocyte necrosis and inflammation in acute myocarditis. This observation was supported by a decrease in infiltration of CD68-positive inflammatory cells in the myocardium. Interestingly, both MCP-1 expressions in the myocardium and serum MCP-1 level were decreased after AM infusion. MCP-1 is a member of the C–C subfamily of chemokines with chemoattractant activity for major inflammatory cells such as monocytes and T lymphocytes [22], and this model of acute myocarditis has previously been shown to be associated with MCP-1 [21]. Thus, the decrease in CD68-positive cell infiltration in the myocardium following this treatment may be attributable to inhibition of MCP-1 production by AM. The inhibitory effect of AM on MCP-1 expression is consistent with a previous *in vitro* study showing that AM inhibited pressure-induced MCP-1 expression in mesangial cells [23]. Recently, it has been demonstrated that AM has anti-inflammatory effects through modulation of macrophage migration inhibitory factor secretion [24]. Importantly, overexpression of MCP-1 induces myocarditis and subsequent development of heart failure [25]. These findings suggest that the inhibitory effect on MCP-1 expression and subsequent anti-inflammatory effect of AM are possible mechanisms of the improvement in acute myocarditis.

We found a significant increase in heart weight to body weight ratio and wall thickness 3 weeks after myosin injection. These results indicate exaggerated edematous changes in myocarditic hearts. Infusion of AM reduced overall heart weight to body weight ratio and wall thickness in myocarditic hearts and attenuated histological edematous changes. Earlier studies have demonstrated that AM decreases vascular congestion and endothelial hyperpermeability in the heart [11], reduces hyperpermeability of cultured endothelial cells and inhibits pulmonary edema [26]. Thus, it is interesting to speculate that the attenuation of edematous changes in the

heart may be attributable to reduction of endothelial hyperpermeability by AM.

In the present study, AM infusion significantly increased the capillary density in myocarditic hearts. In fact, earlier studies have demonstrated angiogenic properties of AM *in vitro* and *in vivo* [27–29]. Importantly, improvement in myocardial vascular supply has been shown to decrease necrosis and inflammation in viral myocarditis [30,31]. These results suggest that AM-induced angiogenesis in the myocardium may be responsible for the improvement in acute myocarditis, which was indicated by reduced necrosis and inflammation in myocarditic hearts.

As previously mentioned, experimental autoimmune myocarditis chronically develops into a dilated cardiomyopathy phenotype [20]. MMPs have been associated with left ventricular remodeling [32] and here we showed increased expression of MMP-2 and -9 as well as increased collagen deposition in myocarditic hearts. In the present study, AM treatment significantly reduced both MMP-2 expression and collagen deposition. In addition, our observation demonstrated that the expression of TGF-β, a profibrogenic factor, was also attenuated by AM treatment. It has been demonstrated that AM decreases the expression of TGF-β in experimental mesangioproliferative glomerulonephritis [33]. These results suggest that AM may have beneficial effects on myocardium, possibly through regulation of factors involved in LV remodeling. In the present study, LVDd did not significantly differ between the control and AM groups. However, it should be noted that AM significantly reduced wall thickness possibly due to reduction of myocardial edema, leading to a slight increase in the inner diameter of the LV and a significant increase in ejection fraction. The major effect of AM was to reduce myocardial edema but not remodeling, despite reducing biochemical markers of remodeling.

Earlier studies have shown that short-term infusion of AM decreases arterial pressure and increases cardiac output in patients with acute heart failure [5]. These findings suggest that the improvement in cardiac function after acute myocarditis may be mediated partly by the hemodynamic effects of AM. However, despite the well-characterized vasorelaxant properties of AM [4], there was a significant increase in mean arterial pressure after AM treatment in our model. These findings suggest that AM induced limited direct hemodynamic action. Taking these findings together, the improvement of cardiac function after AM treatment may have been mediated by the improvement of pathological findings including necrosis, inflammation and edema in the myocardium rather than by AM-induced hemodynamic effects.

In conclusion, infusion of AM improved cardiac function and pathological findings including inflammatory infiltration and edema in a rat model of acute myocarditis. The beneficial effects of AM may occur at least in part by inhibitory effects on MCP-1, MMP-2 and TGF-β, and by enhancement of angiogenesis after acute myocarditis. Thus, infusion of AM may be a potent therapeutic strategy for acute myocarditis.

Acknowledgements

This work was supported by research grants for Cardiovascular Disease (16C-6 and 17A-1) and Comprehensive Research on Aging and Health from the Ministry of Health, Labour and Welfare, the Program for Promotion of Fundamental Studies in Health Sciences of the National Institute of Biomedical Innovation (NIBIO); and Health and Labor Sciences Research Grants (Human Genome Tissue Engineering 009).

References

[1] Levi D, Alejos J. Diagnosis and treatment of pediatric viral myocarditis. Curr Opin Cardiol 2001;16:77–83.
[2] Liu Z, Yuan J, Yanagawa B, Qiu D, McManus BM, Yang D. Coxsackievirus-induced myocarditis: new trends in treatment. Expert Rev Anti Infect Ther 2005;3:641–50.
[3] Feldman AM, McNamara D. Myocarditis. N Engl J Med 2000;343: 1388–98.
[4] Kitamura K, Kangawa K, Kawamoto M, Ichiki Y, Nakamura S, Matsuo H, et al. Adrenomedullin: a novel hypotensive peptide isolated from human pheochromocytoma. Biochem Biophys Res Commun 1993;192:553–60.
[5] Nagaya N, Satoh T, Nishikimi T, Uematsu M, Furuichi S, Sakamaki F, et al. Hemodynamic renal and hormonal effects of adrenomedullin infusion in patients with congestive heart failure. Circulation 2000;101:498–503.
[6] Oya H, Nagaya N, Furuichi S, Nishikimi T, Ueno K, Nakanishi N, et al. Comparison of intravenous adrenomedullin with atrial natriuretic peptide in patients with congestive heart failure. Am J Cardiol 2000;86:94–8.
[7] Clementi G, Caruso A, Cutuli VM, Prato A, Mangano NG, Amico-Roxas M. Antiinflammatory activity of adrenomedullin in the acetic acid peritonitis in rats. Life Sci 1999;65:PL203–8.
[8] Okumura H, Nagaya N, Itoh T, Okano I, Hino J, Mori K, et al. Adrenomedullin infusion attenuates myocardial ischemia/reperfusion injury through the phosphatidylinositol 3-kinase/Akt-dependent pathway. Circulation 2004;109:242–8.
[9] Iwase T, Nagaya N, Fujii T, Itoh T, Ishibashi-Ueda H, Yamagishi M, et al. Adrenomedullin enhances angiogenic potency of bone marrow transplantation in a rat model of hindlimb ischemia. Circulation 2005;111: 356–62.
[10] Tsuruda T, Kato J, Kitamura K, Kuwasako K, Imamura T, Koiwaya Y, et al. Adrenomedullin: a possible autocrine or paracrine inhibitor of hypertrophy of cardiomyocytes. Hypertension 1998;31:505–10.
[11] Chu DQ, Smith DM, Brain SD. Studies of the microvascular effects of adrenomedullin and related peptides. Peptides 2001;22:1881–6.
[12] Kodama M, Matsumoto Y, Fujiwara M, Zhang SS, Hanawa H, Itoh E, et al. Characteristics of giant cells and factors related to the formation of giant cells in myocarditis. Circ Res 1991;69:1042–50.
[13] Kodama M, Matsumoto Y, Fujiwara M, Masani F, Izumi T, Shibata A. A novel experimental model of giant cell myocarditis induced in rats by immunization with cardiac myosin fraction. Clin Immunol Immunopathol 1990;57:250–62.
[14] Fairweather D, Kaya Z, Shellam GR, Lawson CM, Rose NR. From infection to autoimmunity. J Autoimmun 2001;16:175–86.
[15] Cunningham MW. T cell mimicry in inflammatory heart disease. Mol Immunol 2004;40:1121–7.
[16] O'Connell JBRD. Myocarditis and specific myocardial diseases. New York: McGraw-Hill; 1994. Pages.
[17] Yanagawa B, Spiller OB, Choy J, Luo H, Cheung P, Zhang HM, et al. Coxsackievirus B3-associated myocardial pathology and viral load reduced by recombinant soluble human decay-accelerating factor in mice. Lab Invest 2003;83:75–85.
[18] Nagaya N, Kangawa K, Itoh T, Iwase T, Murakami S, Miyahara Y, et al. Transplantation of mesenchymal stem cells improves cardiac function in a rat model of dilated cardiomyopathy. Circulation 2005;112:1128–35.

[19] Hanawa H, Abe S, Hayashi M, Yoshida T, Yoshida K, Shiono T, et al. Time course of gene expression in rat experimental autoimmune myocarditis. Clin Sci (Lond) 2002;103:623–32.
[20] Kodama M, Hanawa H, Saeki M, Hosono H, Inomata T, Suzuki K, et al. Rat dilated cardiomyopathy after autoimmune giant cell myocarditis. Circ Res 1994;75:278–84.
[21] Fuse K, Kodama M, Hanawa H, Okura Y, Ito M, Shiono T, et al. Enhanced expression and production of monocyte chemoattractant protein-1 in myocarditis. Clin Exp Immunol 2001;124:346–52.
[22] Rollins BJ. Chemokines. Blood 1997;90:909–28.
[23] Iwamoto M, Osajima A, Tamura M, Suda T, Ota T, Kanegae K, et al. Adrenomedullin inhibits pressure-induced mesangial MCP-1 expression through activation of protein kinase A. J Nephrol 2003;16:673–81.
[24] Wong LY, Cheung BM, Li YY, Tang F. Adrenomedullin is both proinflammatory and antiinflammatory: its effects on gene expression and secretion of cytokines and macrophage migration inhibitory factor in NR8383 macrophage cell line. Endocrinology 2005;146:1321–7.
[25] Kolattukudy PE, Quach T, Bergese S, Breckenridge S, Hensley J, Altschuld R, et al. Myocarditis induced by targeted expression of the MCP-1 gene in murine cardiac muscle. Am J Pathol 1998;152:101–11.
[26] Hippenstiel S, Witzenrath M, Schmeck B, Hocke A, Krisp M, Krull M, et al. Adrenomedullin reduces endothelial hyperpermeability. Circ Res 2002;91:618–25.
[27] Kim W, Moon SO, Sung MJ, Kim SH, Lee S, Kim HJ, et al. Protective effect of adrenomedullin in mannitol-induced apoptosis. Apoptosis 2002;7:527–36.
[28] Tokunaga N, Nagaya N, Shirai M, Tanaka E, Ishibashi-Ueda H, Harada-Shiba M, et al. Adrenomedullin gene transfer induces therapeutic angiogenesis in a rabbit model of chronic hind limb ischemia: benefits of a novel nonviral vector gelatin. Circulation 2004;109:526–31.
[29] Nagaya N, Mori H, Murakami S, Kangawa K, Kitamura S. Adrenomedullin: angiogenesis and gene therapy. Am J Physiol Regul Integr Comp Physiol 2005;288:R1432–7.
[30] Lee JK, Zaidi SH, Liu P, Dawood F, Cheah AY, Wen WH, et al. A serine elastase inhibitor reduces inflammation and fibrosis and preserves cardiac function after experimentally-induced murine myocarditis. Nat Med 1998;4:1383–91.
[31] Ono K, Matsumori A, Shioi T, Furukawa Y, Sasayama S. Contribution of endothelin-1 to myocardial injury in a murine model of myocarditis: acute effects of bosentan an endothelin receptor antagonist. Circulation 1999;100:1823–9.
[32] Tsuruda T, Costello-Boerrigter LC, Burnett JC. Matrix metalloproteinases: pathways of induction by bioactive molecules. Heart Fail Rev 2004;9:53–61.
[33] Plank C, Hartner A, Klanke B, Geissler B, Porst M, Amann K, et al. Adrenomedullin reduces mesangial cell number and glomerular inflammation in experimental mesangioproliferative glomerulonephritis. Kidney Int 2005;68:1086–95.

Am J Physiol Lung Cell Mol Physiol 293: L446–L452, 2007.
First published June 8, 2007; doi:10.1152/ajplung.00412.2005.

Adrenomedullin ameliorates lipopolysaccharide-induced acute lung injury in rats

Takefumi Itoh,[1,2] Hiroaki Obata,[1,3] Shinsuke Murakami,[1,2] Kaoru Hamada,[2] Kenji Kangawa,[4] Hiroshi Kimura,[2] and Noritoshi Nagaya[1,5]

[1]*Department of Regenerative Medicine and Tissue Engineering, National Cardiovascular Center Research Institute, Osaka, Japan;* [2]*Second Department of Internal Medicine, Nara Medical University, Nara, Japan;* [3]*Division of Cardiology, Niigata University Graduate School of Medical and Dental Sciences, Niigata, Japan; and Departments of* [4]*Biochemistry and* [5]*Internal Medicine, National Cardiovascular Center, Osaka, Japan*

Submitted 26 September 2005; accepted in final form 5 June 2007

Itoh T, Obata H, Murakami S, Hamada K, Kangawa K, Kimura H, Nagaya N. Adrenomedullin ameliorates lipopolysaccharide-induced acute lung injury in rats. *Am J Physiol Lung Cell Mol Physiol* 293: L446–L452, 2007. First published June 8, 2007; doi:10.1152/ajplung.00412.2005.—Adrenomedullin (AM), an endogenous peptide, has been shown to have a variety of protective effects on the cardiovascular system. However, the effect of AM on acute lung injury remains unknown. Accordingly, we investigated whether AM infusion ameliorates lipopolysaccharide (LPS)-induced acute lung injury in rats. Rats were randomized to receive continuous intravenous infusion of AM (0.1 $\mu g \cdot kg^{-1} \cdot min^{-1}$) or vehicle through a microosmotic pump. The animals were intratracheally injected with either LPS (1 mg/kg) or saline. At 6 and 18 h after intratracheal instillation, we performed histological examination and bronchoalveolar lavage and assessed the lung wet/dry weight ratio as an index of acute lung injury. Then we measured the numbers of total cells and neutrophils and the levels of tumor necrosis factor (TNF)-α and cytokine-induced neutrophil chemoattractant (CINC) in bronchoalveolar lavage fluid (BALF). In addition, we evaluated BALF total protein and albumin levels as indexes of lung permeability. LPS instillation caused severe acute lung injury, as indicated by the histological findings and the lung wet/dry weight ratio. However, AM infusion attenuated these LPS-induced abnormalities. AM decreased the numbers of total cells and neutrophils and the levels of TNF-α and CINC in BALF. AM also reduced BALF total protein and albumin levels. In addition, AM significantly suppressed apoptosis of alveolar wall cells as indicated by cleaved caspase-3 staining. In conclusion, continuous infusion of AM ameliorated LPS-induced acute lung injury in rats. This beneficial effect of AM on acute lung injury may be mediated by inhibition of inflammation, hyperpermeability, and alveolar wall cell apoptosis.

apoptosis; hyperpermeability; inflammation

ACUTE RESPIRATORY DISTRESS syndrome (ARDS) is a life-threatening disease characterized by diffuse lung injury that leads to respiratory failure and death (2, 12). Its mortality remains high despite recent advances in intensive care (4, 38). Therefore, a novel therapeutic strategy for ARDS is desirable. Potential mechanisms that induce ARDS include lung inflammation and hyperpermeability (4, 36). Lung inflammation induces the production of various molecules that mediate lung injury such as arachidonic acid metabolites (2, 16), proteases (59), and free radicals (10, 40). Lung hyperpermeability contributes to the development of pulmonary edema, resulting in abnormal gas exchange. Furthermore, apoptosis of several cell types, including neutrophils, alveolar epithelial cells, and endothelial cells, is involved in the pathogenesis of acute lung injury in ARDS (9, 24, 26). Thus a therapeutic strategy against these abnormalities may be effective for the treatment of ARDS.

Adrenomedullin (AM) is an endogenous peptide that was originally isolated from human pheochromocytoma (20). It has been shown to have a variety of protective effects on the cardiovascular system in addition to vasodilator activity (6, 18, 27–29, 32). It has been shown to inhibit inflammatory cytokine production (13, 14, 53). AM also has been reported to reduce endothelial hyperpermeability through a cyclic adenosine 3′,5′-monophosphate-dependent mechanism (11). Furthermore, AM has been reported to protect against apoptosis through a phosphatidylinositol 3-kinase/Akt-dependent pathway (15, 19, 34, 39, 45). Considering that AM has been shown to attenuate organ injury in sepsis models (7, 41, 51), it may have protective effects against inflammation, hyperpermeability, and cell apoptosis, which are responsible for acute lung injury in ARDS. However, the effects and mechanisms of AM in acute lung injury remain unknown.

Lipopolysaccharide (LPS), a bacterial cell wall component, is a stimulus for the initiation of local acute inflammation. Intratracheal instillation of LPS in animals has gained wide acceptance as an experimental model of ARDS (5). Thus the purposes of this study were *1*) to investigate whether AM infusion ameliorates acute lung injury and *2*) to examine the underlying mechanisms responsible for the effects of AM on acute lung injury.

METHODS

Animals. All protocols were performed in accordance with the guidelines of the Animal Care Ethics Committee of the National Cardiovascular Center Research Institute. Adult male Sprague-Dawley rats weighing 180–200 g were used in this study. Rats were assigned to receive a continuous infusion of AM or vehicle and underwent intratracheal instillation of either LPS or 0.9% saline. This protocol resulted in the creation of four groups: sham rats given vehicle (Sham-Vehicle group; n = 34), sham rats treated with AM (Sham-AM group; n = 34), LPS rats given vehicle (LPS-Vehicle group; n = 34), and LPS rats treated with AM (LPS-AM group; n = 34).

Experimental protocol. After the rats were anesthetized by intraperitoneal injection of pentobarbital (30 mg/kg), they were given a

Address for reprint requests and other correspondence: N. Nagaya, Dept. of Regenerative Medicine and Tissue Engineering, National Cardiovascular Center Research Institute, 5-7-1 Fujishirodai, Suita, Osaka 565-8565, Japan (e-mail: nnagaya@ri.ncvc.go.jp).

The costs of publication of this article were defrayed in part by the payment of page charges. The article must therefore be hereby marked "*advertisement*" in accordance with 18 U.S.C. Section 1734 solely to indicate this fact.

continuous intravenous infusion of either AM or saline vehicle via a microosmotic pump (2001D; Alzet, Palo Alto, CA). Briefly, an osmotic pump was filled with either AM or saline and was set to deliver a dose of 0.1 $\mu g \cdot kg^{-1} \cdot min^{-1}$, attached to a catheter (PE-60) placed in the left jugular vein, and implanted subcutaneously between the scapulae. The rats were allowed to recover from the anesthesia and were maintained on standard rat chow. Two hours after implantation, the rats were intratracheally injected with either 1 mg/kg LPS (*Escherichia coli* 055:B5; Sigma, St. Louis, MO) dissolved in 0.3 ml saline or vehicle (0.3 ml saline) under anesthesia. We measured the LPS content in the saline by using the Limulus amoebocyte lysate test (E-Toxate; Sigma). The saline used in this study contained <6 pg LPS/ml. After recovery from anesthesia, the animals were again maintained on standard rat chow. The animals showed no sign of distress with this procedure. All rats remained alive after intratracheal instillation of LPS.

The animals were killed with an overdose of pentobarbital, and the following parameters were analyzed. Bronchoalveolar lavage (BAL) was performed at 6 and 18 h after intratracheal instillation (n = 8 each). Histological examination was performed in another group of rats at 6 and 18 h (n = 5 each). To estimate the circulating level of AM, blood sampling was performed at 18 h. To evaluate the severity of acute lung injury, the lung wet/dry weight ratio was calculated at 18 h in the rats that were not subjected to BAL or histological examination (n = 8 each). The wet lung weight was measured immediately after dissection, and the dried lung weight was estimated after oven drying at 60°C for 72 h. The experimental design is summarized in Fig. 1.

Preparation of AM. Recombinant human AM was obtained from Shionogi (Osaka, Japan). The homogeneity of AM was confirmed by reverse-phase high-performance liquid chromatography and amino acid analysis. AM was stored at −80°C until the time of preparation for infusion.

Measurement of AM. Blood was immediately transferred into a chilled glass tube containing disodium EDTA (1 mg/ml) and aprotinin (500 U/ml) and was centrifuged immediately at 4°C. Plasma samples were frozen and stored at −80°C. Human AM was measured by using a specific immunoradiometric assay kit (AM RIA; Shionogi) (33). Rat AM was also measured by using this assay kit with some modifications, as reported previously (31).

BAL analysis. BAL was performed through a tracheal cannula with 5 ml saline solution. This procedure was performed twice. A 500-μl aliquot of BAL fluid (BALF) was reserved for determination of the total number of cells and cell differentiation, and the remainder was centrifuged immediately at 700 g for 5 min at 4°C. The supernatant of BALF was immediately stored at −80°C before assays. The total number of cells was counted by using a standard hemocytometer. Cell differentiation was examined by counting at least 200 cells on a smear prepared by using cytospin and Wright-Giemsa staining.

Tumor necrosis factor-α and cytokine-induced neutrophil chemoattractant assays. BALF tumor necrosis factor (TNF)-α and cytokine-induced neutrophil chemoattractant (CINC) levels were measured by using a rat TNF-α ELISA kit (BioSource International, Camarillo, CA) and a rat Gro/CINC-1 kit (Amersham Biosciences, Piscataway, NJ), respectively.

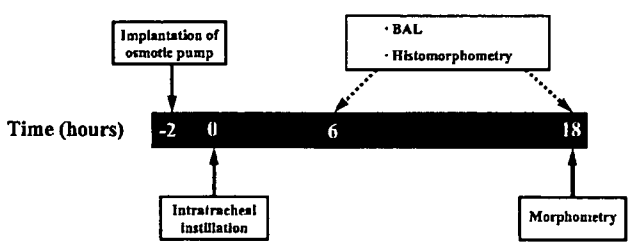

Fig. 1. Study protocol timeline. Implantation of osmotic pump, intratracheal instillation, bronchoalveolar lavage (BAL), histomorphometry, and morphometry were performed.

Total protein and albumin assays. To investigate the effect of AM on lung permeability, BALF total protein and albumin levels were measured by using a Bradford assay (Bio-Rad, Tokyo, Japan) and a bromcresol green assay (Sigma), respectively.

Histological examination. The lungs were fixed with 4% paraformaldehyde and were embedded in paraffin. Paraffin sections 4-μm thick were stained with hematoxylin and eosin for examination by light microscopy. Lung injury was graded from 0 (normal) to 4 (severe) in four categories: interstitial inflammation, neutrophil infiltration, congestion, and edema (42). Lung-injury score was calculated by adding the individual scores for each category. Grading was performed by a blinded pathologist. Lung-injury score for each animal was calculated as the mean of four lung sections. Paraffin sections were obtained from individual rats at 6 or 18 h after intratracheal instillation (n = 5 per group).

Immunohistochemical study. To investigate the effect of AM on lung apoptosis, tissue sections were stained for cleaved caspase-3, a key executor of apoptosis, by using a rabbit polyclonal anti-cleaved caspase-3 antibody (Cell Signaling Technology, Beverly, MA). The number of cleaved caspase-3-positive alveolar wall cells was determined in 10 randomly chosen fields (×400) per section. The percentage of cleaved caspase-3-positive inflammatory cells was calculated (number of cleaved caspase-3-positive inflammatory cells/total number of inflammatory cells × 100) in 10 randomly chosen fields (×400) per section, as previously described (21). The mean of four sections per animal was determined in a blinded manner. Paraffin sections 4-μm thick were obtained from the lungs at 6 h after intratracheal instillation (n = 5 per group).

Statistical analysis. All data are expressed as means ± SE. All data have been tested for normality by using the Shapiro-Wilk normality test and were determined to have a normal distribution. Homogeneity of variance was tested by using Bartlett's test. When Bartlett's test indicated that the group comparisons had equal variance, one-way ANOVA and Newman-Keuls' test were used. When the group data showed unequal variance, nonparametric statistical analysis was used. A value of $P < 0.05$ was considered statistically significant.

RESULTS

Inhibition of LPS-induced acute lung injury by AM. Photomicrographs showed that intratracheal instillation of LPS caused infiltration of inflammatory cells into the lung interstitium and alveolar spaces, alveolar wall thickening, and intra-alveolar exudation at 6 and 18 h after LPS instillation. (Fig. 2*A*). However, AM infusion attenuated these histological changes. Semiquantitative assessment using lung-injury score demonstrated that the degree of lung injury in the LPS-AM group was lower than that in the LPS-Vehicle group at 6 and 18 h after LPS instillation (Fig. 2*B*). The lung wet/dry weight ratio was significantly increased at 18 h after LPS instillation (Fig. 3). AM infusion significantly attenuated the increase in the lung wet/dry weight ratio compared with vehicle. AM infusion did not induce any changes in lung histology and the lung wet/dry weight ratio in Sham rats. AM infusion tended to decrease systemic blood pressure but did not cause severe hypotension in LPS rats (121 ± 8 to 114 ± 10 mmHg).

Plasma AM level. Plasma AM level was significantly higher in LPS rats than in Sham rats (10 ± 1 vs. 3 ± 1 fmol/ml, $P <$ 0.05). Furthermore, the level was markedly increased in LPS

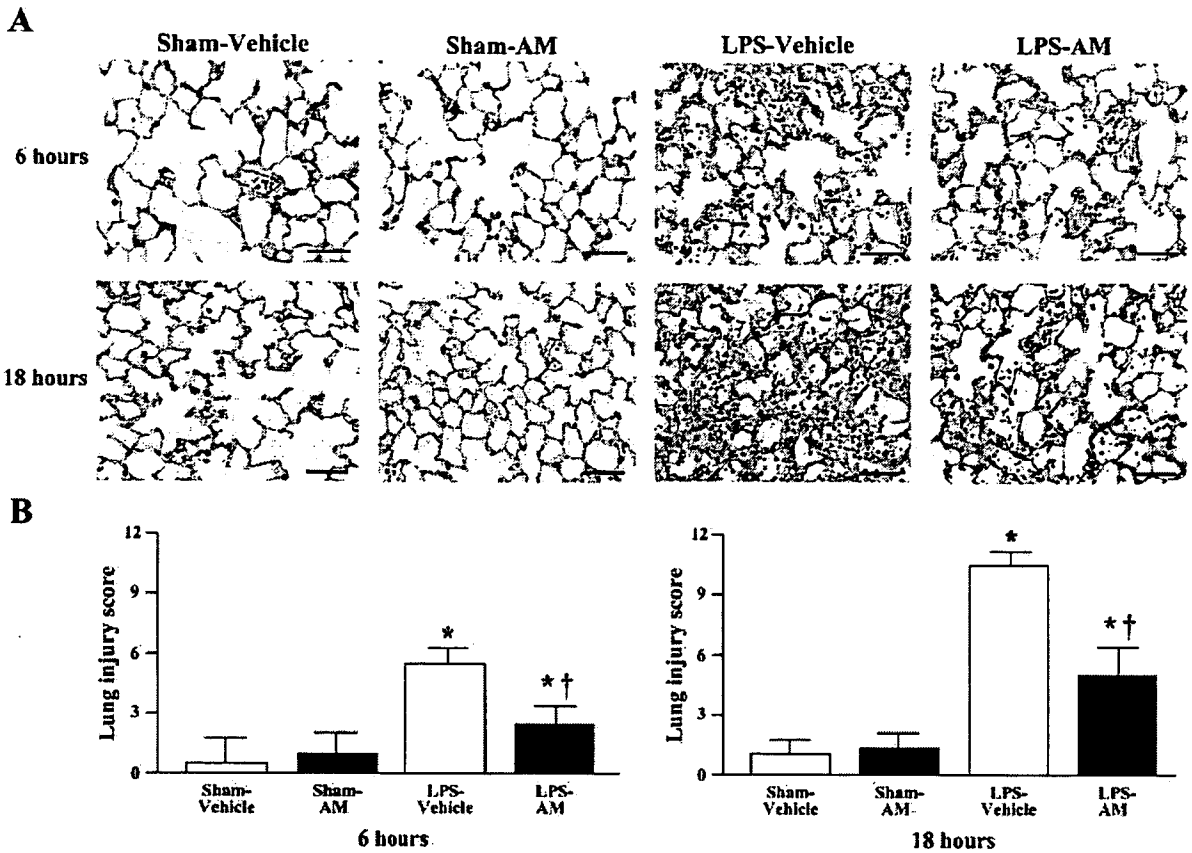

Fig. 2. *A*: representative photomicrographs of lung tissues stained with hematoxylin and eosin at 6 and 18 h after lipopolysaccharide (LPS) instillation. Intratracheal instillation of LPS caused infiltration of inflammatory cells into lung interstitium and alveolar spaces, alveolar wall thickening, and intra-alveolar exudation. Scale bars, 50 μm. *B*: semiquantitative analysis of lung tissues by lung-injury score. Lung-injury score was significantly decreased in LPS-adrenomedullin (AM) group compared with LPS-Vehicle (saline) group. Data are means ± SE. $*P < 0.05$ vs. Sham-Vehicle; $†P < 0.05$ vs. LPS-Vehicle.

rats treated with AM (32 ± 3 fmol/ml) compared with in those given vehicle ($P < 0.01$). These results suggest that the administered AM reached pharmacological levels.

Effects of AM on LPS-induced lung inflammation. The recovery rate of BALF was >80% in all groups. The numbers of total cells and neutrophils were significantly increased at 6 and 18 h after LPS instillation (Fig. 4, *A* and *B*). However, the numbers of these cells in the LPS-AM group were significantly lower than those in the LPS-Vehicle group. The BALF TNF-α level was significantly increased at 6 and 18 h after LPS instillation (Fig. 4*C*). Similarly, the BALF CINC level was significantly increased after LPS instillation (Fig. 4*D*). AM infusion significantly attenuated the increases in BALF TNF-α and CINC levels. AM infusion did not significantly alter BAL data in sham rats.

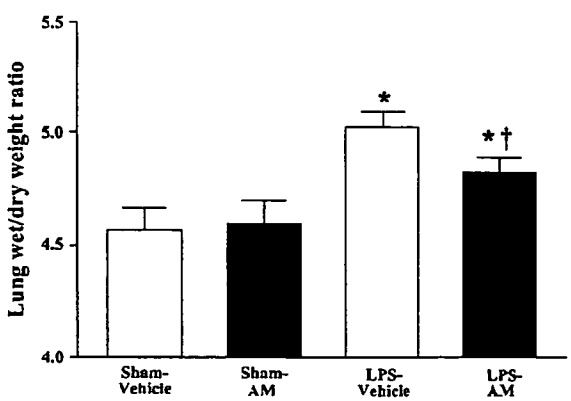

Fig. 3. Effect of AM infusion on lung weight after LPS instillation. Data are means ± SE. $*P < 0.05$ vs. Sham-Vehicle; $†P < 0.05$ vs. LPS-Vehicle.

Effects of AM on LPS-induced lung hyperpermeability. The BALF total protein and albumin levels, markers for lung permeability, were significantly increased at 6 and 18 h after LPS instillation (Fig. 5). AM infusion significantly attenuated the increases in BALF total protein and albumin levels.

Effect of AM on LPS-induced alveolar wall cell apoptosis. Cleaved caspase-3-positive cells were frequently observed in the alveolar wall at 6 h after LPS instillation (Fig. 6*A*). AM infusion markedly decreased cleaved caspase-3-positive cells in the alveolar wall. Semiquantitative analysis demonstrated a significant increase in the number of cleaved caspase-3-positive alveolar wall cells after LPS instillation, and the increase in the LPS-AM group was significantly attenuated compared with that in the LPS-Vehicle group (Fig. 6*B*). AM infusion did not significantly change the percentage of cleaved caspase-3-positive inflammatory cells compared with vehicle infusion (3 ± 2 vs. 4 ± 1%).