

day by gavage on GD 7 through 11 in the study of fetal anomalies or on GD 8 through 11 in the study of postnatal fate of anomalies.

Observation of congenital malformations for the study of fetal anomalies

After oral administration of PB, clinical signs were observed and body weights were measured daily in each dam. On GD 20, the dams were sacrificed by ether anesthesia, and the number of corpora lutea was recorded for each dam. The uterus of each dam was examined for the number of implantation sites, resorptions, or live and dead fetuses. All live fetuses were sexed, weighed, and examined for external malformations. Approximately two-thirds of the live fetuses were fixed in 10% formalin solution and then in Bouin's solution and the head were examined by the freehand razor blade sectioning method of Wilson (1965). The visceral and thoracic organs of these fetuses were examined by the microdissection method of Nishimura (1974). The remaining fetuses were fixed in 90% ethanol and processed for skeletal specimens by the method of Dawson (1926), and then examined for skeletal malformations and variations, or degree of ossification.

Overriding aorta, double outlet right ventricle and transposition of great arteries were diagnosed according to the following definitions of morphological characteristics, as illustrated in Figure 1. Overriding aorta was defined as the aorta arising from the biventricles. Double outlet right ventricle was defined as both the aorta and the pulmonary artery arising from the right ventricle. Transposition of great arteries was defined as the aorta arising from the right ventricle and the pulmonary artery arising from the left ventricle.

Observations of cardiovascular malformations for the study of postnatal fate of anomalies

Body weights of dams were recorded daily. After PB administration, the dams were observed daily for clinical signs and allowed to deliver naturally. The day of parturition was defined as postnatal day (PND) 0. The live neonates were sexed, and examined for external malformations and clinical signs. The litter weight was measured on PND 0, 4, 7, 14 and 21. The live pups were culled to 4 males and 4 females in each litter on PND 4, and then euthanized by ether anesthesia for cardiovascular examination on PND 21. Dead, moribund or culled pups were also examined for cardiovascular malformations, using the same methods described above.

Statistical analysis

Incidences of external, cardiovascular and skeletal anomalies, expressed as fetal unit, were analyzed by χ^2 test. Other parameters were analyzed by the following algorithm described by Yamazaki *et al.* (1981) and Hamada *et al.* (1998): Bartlett's test was used to determine whether or not the variance was homogeneous or not. When the variance was homogeneous, the one-way ANOVA was applied. When the variance was not homogeneous, the Kruskal-Wallis rank sum test was performed by arranging all data of the control and exposed groups in descending order. Statistical differences in the means and the rank means among the groups were analyzed by Dunnett's multiple comparison test, and the same multiple comparison test by rank, respectively. Two-sided analysis with a *P*-value of 0.05 or 0.01 was performed.

RESULTS

Effects of PB on dams

No deaths occurred in any dam administered PB at a dose of 80 or 120 mg/kg/day during gestation. Ataxic gait, loss of righting reflex, decreased locomotor activity, salivation and lacrimation were observed after the oral administration of 80 and 120 mg/kg PB. These signs disappeared at least within 48 h after the second day of administration of PB. There was no significant difference in body weight between any PB-administered group and the control (Data not shown). No macroscopic change was observed in any PB-administered dam at cesarean section on GD 20 or at the necropsy on PND 21.

Effects of PB on fetuses

Table 1 shows the reproductive parameters of dams administered PB on two consecutive days during gestation. Percent postimplantation loss was significantly increased in the group administered PB at 120 mg/kg on GD 10–11. No significant difference in fetal body weight was found between any PB-administered group and the control.

Table 2 shows the external, visceral, and skeletal anomalies observed in fetuses from the dams administered PB on 2 consecutive days during gestation. No significant increases in the incidences of external malformations were observed in any PB-administered group. Incidences of visceral malformations were sig-

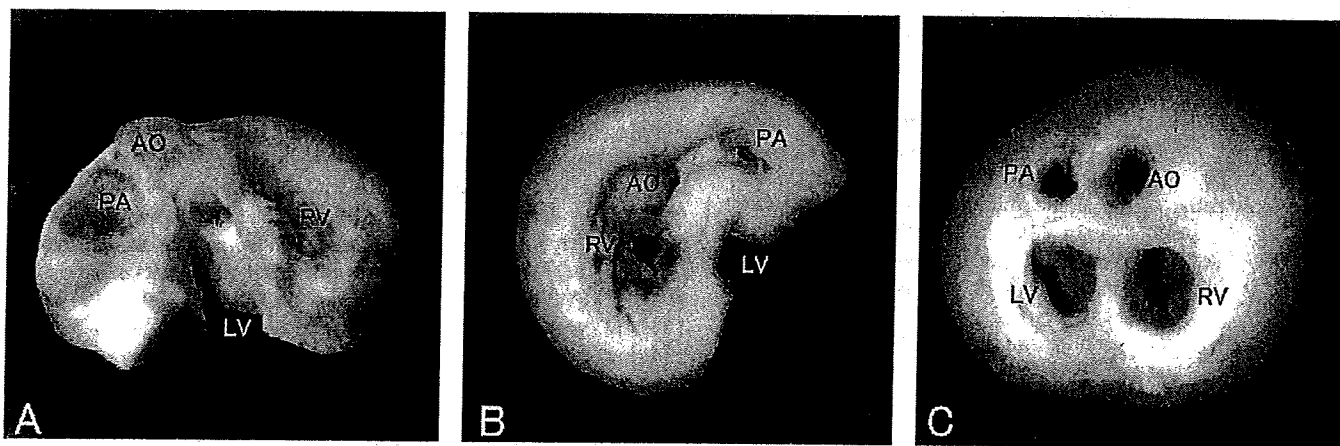


Fig. 1 Three types of cardiovascular malformations induced in fetuses from dams administered PB at a dose of 120 mg/kg for 2 consecutive days during gestation. (A) Overriding aorta with VSD: the aorta arising from the biventricles. (B) Double outlet right ventricular with VSD: both the aorta and pulmonary artery arising from the right ventricle. (C) Transposition of great artery: the aorta arising from right ventricle and pulmonary artery arising from left ventricle. AO, PA, RV and LV indicate aorta, pulmonary artery, right ventricle and left ventricle, respectively.

Table 1 Reproductive parameters of dams administered PB by gavage at a dose of 80 or 120 mg/kg/day on two consecutive days during gestation

Dose (mg/kg/day)	0							80							120						
	Administration period (GD)																				
No. dams	7-11	7-8	8-9	9-10	10-11	7-8	8-9	9-10	10-11	7-8	8-9	9-10	10-11	7-8	8-9	9-10	10-11				
No. corpora lutea (total no.)	18.9 ± 1.6 (151)	17.9 ± 2.5 (125)	19.4 ± 1.6 (136)	19.1 ± 2.0 (134)	18.4 ± 2.2 (129)	18.0 ± 1.9 (144)	18.8 ± 2.4 (150)	19.1 ± 2.0 (134)	18.4 ± 2.2 (129)	18.0 ± 1.9 (144)	18.8 ± 2.4 (150)	16.9 ± 3.4 (135)	16.8 ± 2.2 (134)	18.0 ± 1.9 (144)	18.8 ± 2.4 (150)	16.9 ± 3.4 (135)	16.8 ± 2.2 (134)				
No. implantations (total no.)	17.3 ± 3.6 (138)	15.7 ± 1.3 (110)	16.4 ± 2.3 (117)	16.7 ± 2.2 (117)	16.3 ± 1.7 (114)	16.3 ± 1.8 (130)	15.9 ± 1.6 (127)	16.7 ± 2.2 (117)	16.3 ± 1.7 (114)	16.3 ± 1.8 (130)	15.9 ± 1.6 (127)	14.8 ± 2.4 (118)	14.8 ± 2.4 (118)	16.3 ± 1.8 (130)	15.9 ± 1.6 (127)	14.8 ± 2.4 (118)	14.8 ± 2.4 (118)				
No. intrauterine death (total no.)	0.5 ± 0.8 (4)	1.4 ± 1.7 (10)	1.6 ± 1.5 (11)	0.9 ± 0.9 (6)	0.4 ± 0.5 (3)	1.4 ± 1.1 (11)	2.9 ± 5.0 (23)	0.9 ± 0.9 (6)	0.4 ± 0.5 (3)	1.4 ± 1.1 (11)	2.9 ± 5.0 (23)	1.8 ± 0.9 (14)	3.3 ± 3.4 (26)	1.4 ± 1.1 (11)	2.9 ± 5.0 (23)	1.8 ± 0.9 (14)	3.3 ± 3.4 (26)				
Postimplantation loss no. (%)†	2.8 ± 4.1	9.7 ± 12.3	9.8 ± 10.0	5.5 ± 5.9	2.7 ± 3.4	8.7 ± 8.1	18.8 ± 33.3	5.5 ± 5.9	2.7 ± 3.4	8.7 ± 8.1	18.8 ± 33.3	12.3 ± 6.4	24.5 ± 28.3*	8.7 ± 8.1	18.8 ± 33.3	12.3 ± 6.4	24.5 ± 28.3*				
No. live fetuses (total no.)	16.8 ± 3.5 (134)	14.3 ± 2.7 (100)	15.1 ± 2.6 (106)	15.9 ± 2.6 (111)	15.9 ± 1.8 (111)	14.9 ± 2.2 (119)	13.0 ± 5.5 (104)	15.9 ± 2.6 (111)	15.9 ± 1.8 (111)	14.9 ± 2.2 (119)	13.0 ± 5.5 (104)	13.0 ± 2.7 (104)	11.5 ± 4.8 (92)	14.9 ± 2.2 (119)	13.0 ± 5.5 (104)	13.0 ± 2.7 (104)	11.5 ± 4.8 (92)				
Fetal body weight (g)																					
Males (total no.)	3.11 ± 0.23 (65)	3.24 ± 0.21 (49)	3.08 ± 0.31 (53)	3.05 ± 0.13 (56)	3.08 ± 0.22 (49)	3.18 ± 0.28 (57)	3.05 ± 0.26 (49)	3.05 ± 0.13 (56)	3.08 ± 0.22 (49)	3.18 ± 0.28 (57)	3.05 ± 0.26 (49)	3.07 ± 0.41 (60)	3.13 ± 0.53 (53)	3.18 ± 0.28 (57)	3.05 ± 0.26 (49)	3.07 ± 0.41 (60)	3.13 ± 0.53 (53)				
Females (total no.)	2.99 ± 0.31 (69)	3.12 ± 0.23 (51)	3.03 ± 0.20 (53)	2.98 ± 0.09 (55)	3.00 ± 0.24 (62)	3.02 ± 0.26 (62)	2.93 ± 0.21 (55)	2.98 ± 0.09 (55)	3.00 ± 0.24 (62)	3.02 ± 0.26 (62)	2.93 ± 0.21 (55)	2.90 ± 0.31 (44)	3.03 ± 0.42 (39)	3.02 ± 0.26 (62)	2.93 ± 0.21 (55)	2.90 ± 0.31 (44)	3.03 ± 0.42 (39)				

*Significantly different from the control at $P < 0.05$.†(No. implantations - No. live fetuses/No. implantations) × 100
Values are expressed as means ± S.D.

Table 2 Types and incidences of external, visceral and skeletal anomalies in fetuses from the dams administered PB by gavage at a dose of 80 or 120 mg/kg/day on two consecutive days during gestation

Dose (mg/kg/day)	80					120				
	7-11	7-8	8-9	9-10	10-11	7-8	8-9	9-10	10-11	10-11
Administration period (GD)	8	7	7	7	7	8	8	8	8	8
No. dams	133	100	106	111	111	119	104	104	92	92
External observations										
No. fetuses examined	0	0	0	1 (0.9)	1 (0.9)	0	0	2 (2.0)	0	0
No. fetuses with malformations	86	65	68	72	72	76	67	66	59	59
Visceral observations										
No. fetuses examined	1 (1.2)	3 (4.6)	1 (1.5)	2 (2.8)	2 (2.8)	3 (3.9)	24 (35.8**)	31 (47.0**)	14 (23.7**)	14 (23.7**)
No. fetuses with malformations	0	1 (1.5)	1 (1.5)	1 (1.4)	1 (1.4)	1 (1.3)	7 (10.4**)	13 (19.7**)	5 (8.5*)	5 (8.5*)
Isolated ventricular septal defect (VSD)	0	2 (3.1)	0	0	0	0	3 (4.5)	6 (9.1*)	1 (1.7)	1 (1.7)
Overriding aorta	0	0	0	0	0	0	6 (9.0*)	2 (3.0)	1 (1.7)	1 (1.7)
Double outlet right ventricle	0	0	0	0	0	0	4 (6.0)	9 (13.6**)	0	0
Transposition of great arteries	0	0	0	1 (1.4)	0	0	9 (13.4**)	4 (6.1)	2 (3.4)	2 (3.4)
Branching of the right subclavian artery from aorta	0	1 (1.5)	0	0	0	0	0	2 (3.0)	5 (8.5*)	5 (8.5*)
Retrosophageal subclavian artery	0	0	0	0	0	2 (2.6)	0	0	0	0
Common atrioventricular canal	0	0	0	0	0	1 (1.3)	0	0	0	0
Supernumerary azygos vein	0	0	0	0	0	2 (2.6)	1 (1.5)	0	1 (1.7)	1 (1.7)
Atrial septal defect	0	1 (1.5)	0	1 (1.4)	0	0	0	1 (1.5)	0	0
Persistent truncus arteriosus	0	0	0	0	0	2 (2.6)	1 (1.5)	1 (1.5)	3 (5.1)	3 (5.1)
Others†	10 (12.8)	9 (13.8)	4 (5.9)	9 (12.5)	7 (9.7)	10 (13.2)	10 (14.9)	20 (30.3*)	25 (42.4**)	25 (42.4**)
No. fetuses with variations	10 (12.8)	8 (12.3)	4 (5.9)	6 (8.3)	6 (8.3)	9 (11.8)	6 (9.0)	15 (22.7)	24 (40.7**)	24 (40.7**)
Thymic remnant in the neck	0	0	0	0	0	1 (1.3)	3 (4.5)	6 (9.1)	1 (1.7)	1 (1.7)
Persistent left umbilical artery	0	1 (1.5)	0	3 (4.2)	1 (1.4)	0	2 (3.0)	1 (1.5)	0	0
Dilated renal pelvis	47	35	38	39	39	43	37	38	33	33
Skeletal observations										
No. fetuses examined	0	0	0	0	0	1 (2.3)	0	0	0	0
No. fetuses with malformations	0	2 (5.7)	5 (13.2*)	6 (15.4*)	8 (20.5*)	10 (23.3**)	26 (70.3**)	33 (86.8**)	18 (54.5**)	18 (54.5**)
No. fetuses with variations	0	0	0	2 (5.1)	3 (7.7)	3 (7.0)	8 (21.6**)	16 (42.1**)	7 (21.2**)	7 (21.2**)
Splitting of ossification centers of thoracic vertebral bodies	0	1 (2.9)	0	1 (2.6)	3 (7.7)	1 (2.3)	8 (21.6**)	18 (47.3**)	6 (18.2**)	6 (18.2**)
Dumbbell shape of ossification centers of thoracic vertebral bodies	0	0	0	0	0	0	1 (2.7)	3 (7.9)	0	0
Extra 14th ribs	0	0	5 (13.2*)	3 (7.7)	2 (5.1)	3 (7.0)	17 (45.9**)	14 (36.8**)	7 (21.2**)	7 (21.2**)
Rudimentary 14th ribs	0	1 (2.9)	0	0	0	3 (7.0)	4 (10.8)	2 (5.3)	1 (3.0)	1 (3.0)
Others‡										

*Significantly different from the control at $P < 0.05$.

**Significantly different from the control at $P < 0.01$.

†Included cor trioculare, small left ventricular chamber, double aortic arch, right-sided aortic arch, vascular ring, situs invs. and abnormal lung lobation; ‡included splitting of ossification centers of lumbar vertebral bodies, dumbbell shape of ossification centers of lumbar vertebral bodies, rudimentary cervical ribs and asymmetry of the sternbrae. The percent value is indicated in parenthesis.

nificantly increased in the groups administered PB at 120 mg/kg on GD 8–9, 9–10 and 10–11. Almost all the malformations observed in the fetuses from the PB-administered dams originated from the cardiovascular system. The malformations observed at high frequency included the isolated ventricular septal defect (VSD), overriding aorta, double outlet right ventricle, transposition of great arteries, branching of the right subclavian artery from the aorta and retroesophageal right subclavian artery. Three representative types of cardiovascular malformations, overriding aorta, transposition of great arteries and double outlet right ventricle are illustrated in Figure 1. These malformations were mostly accompanied by VSD. The incidence of visceral variations was also increased in the groups administered PB at 120 mg/kg on GD 9–10 and 10–11. The increased type of variation was thymic remnant in the neck.

Although the incidence of skeletal malformations was not increased in any PB-administered group, the incidences of skeletal variations were increased in fetuses from the dams administered PB at 80 mg/kg on GD 8–9, 9–10 and 10–11, and from all the dams administered PB at 120 mg/kg. The principal skeletal variations included splitting or dumbbell shape of ossification centers of thoracic vertebral bodies and rudimentary 14th rib. In addition, delayed ossification of interparietal, maxilla and cervical vertebra were observed at high frequency in fetuses from the PB-administered dams (Data not shown).

Cardiovascular malformations observed in pups

Table 3 shows the effects on pups from the dams administered PB at a dose of 120 mg/kg/day on 2 consecutive days during gestation. No developmental parameters of pups were affected by prenatal PB exposure when observed on PND 0. However, both the number of live pups and viability tended to decrease in the groups administered PB on GD 9–10 or 10–11, when observed on PND 4.

Table 4 shows the incidences of cardiovascular malformations in pups from the dams administered PB at 120 mg/kg/day on two consecutive days during gestation. Numbers of dead or moribund pups bearing cardiovascular malformations were significantly increased in the groups administered PB on GD 8–9, 9–10 or 10–11. The malformations observed at high frequency included overriding aorta, double outlet right ventricle, transposition of great arteries and patent ductus arteriosus. The number of pups bearing cardiovascular malformations culled on PND 4 was significantly increased in the group administered 120 mg/kg PB on GD 10–11. The isolated VSD was the most commonly observed malformation. Incidences of cardiovascular malformations observed on PND 21 were significantly increased in the groups treated with PB on GD 8–9, 9–10 and 10–11. Those increased incidences were primarily attributed to the increased number of isolated VSD.

DISCUSSION

Maternal toxicity of PB

Two-day administration of PB by gavage at a dose of 80 or 120 mg/kg/day to pregnant rats did not affect body weight gain but induced clinical signs such as loss of righting reflex, ataxic gait and decreased locomotor activity of dams. Terada *et al.* (1987) reported that administration of PB to pregnant rats at 80 mg/kg/day by gavage on GD 7–17 induced neurotoxicologic signs and retarded body weight gain. Vorhees (1983) reported that the body weights of pregnant rats administered PB at 80 mg/kg/day on GD 7–18 were decreased, whereas a daily dose of 125 mg/kg for 12 days caused deaths of the pregnant rats. It is considered therefore that the present dose levels and repetitions of PB did not induce systemic toxicologic signs such as retarded body weight gain in the dams, but elicited pharmacologic actions of PB that caused the clinical signs.

Table 3 Developmental effects on pups from the dams administered PB by gavage at a dose of 120 mg/kg/day on two consecutive days during gestation

Dose (mg/kg/day)	0		120	
Administration period (GD)	8–11	8–9	9–10	10–11
No. dams with live pups	9	9	10	9
Gestation length (day)	22.0 ± 0.0	22.0 ± 0.0	22.2 ± 0.4	22.1 ± 0.3
No. implantations (total no.)	15.0 ± 2.6† (135)	14.9 ± 1.8 (134)	13.9 ± 4.7 (139)	14.2 ± 3.5 (128)
PND 0				
No. neonates born (total no.)	14.3 ± 2.3 (129)	13.2 ± 1.8 (119)	13.0 ± 4.3 (130)	13.0 ± 3.2 (117)
No. live neonates (total no.)	14.2 ± 2.4 (128)	12.9 ± 1.9 (116)	12.1 ± 3.9 (121)	12.6 ± 3.2 (113)
Pups weight (g)	6.3 ± 0.8	6.1 ± 0.5	5.9 ± 0.8	5.9 ± 0.5
PND 4				
No. live pups (total no.)	12.9 ± 3.0 (116)	11.6 ± 3.0 (104)	9.4 ± 4.2 (94)	9.3 ± 3.0 (84)
Viability (%)†	90.8 ± 15.6	88.8 ± 16.3	78.6 ± 37.1	77.6 ± 24.2
No. pups after culling (total no.)	8.0 ± 0.0 (72)	7.8 ± 0.7 (70)	6.5 ± 1.7 (65)	7.1 ± 1.2 (64)
Pups weight after culling (g)	10.1 ± 1.6	9.4 ± 1.1	9.2 ± 1.9	8.9 ± 1.7
PND 21				
No. live pups (total no.)	8.0 ± 0.0 (72)	7.8 ± 0.7 (70)	6.5 ± 1.7 (65)	7.0 ± 1.1 (63)
Viability (%)‡	100.0 ± 0.0	100.0 ± 0.0	100.0 ± 0.0	98.6 ± 4.2
Pups weight (g)	56.7 ± 5.5	55.0 ± 3.0	53.6 ± 6.1	52.1 ± 10.0

†(No. live pups on PND 4/No. live neonates on PND 0) × 100.

‡(No. live pups on PND 21/No. of live pups on PND 4) × 100.

Values are expressed as means ± SD.

Table 4 Incidence of cardiovascular malformations found in pups from the dams administered PB by gavage at a dose of 120 mg/kg on two consecutive days during gestation

Dose (mg/kg/day)	0		120	
	8-11	8-9	9-10	10-11
No. dams	9	9	10	9
No. pups examined (A + B + C)	123	116	122	105
Pups with cardiovascular malformations	0 (0)	24 (20.7)**	36 (35.2)**	33 (31.4)**
No. pups died or sacrificed for moribund during breast-feeding (A)	3	12	31	23
Pupa with cardiovascular malformations	0 (0)	12 (100)**	27 (87.1)**	19 (82.6)**
Isolated ventricular septal defect (VSD)	0	0	4 (12.9)	0
Overriding aorta	0	3 (25.0)	11 (35.4)	10 (43.5)
Double outlet right ventricle	0	2 (16.7)	3 (9.7)	5 (21.7)
Transposition of great arteries	0	2 (16.7)	5 (16.1)	0
Patent ductus arteriosus	0	2 (16.7)	6 (19.4)	7 (30.4)
Persistent atrioventricular canal	0	1 (8.3)	1 (3.2)	0
Coarctation of aorta	0	2 (16.7)	0	0
Branching of the right subclavian artery from aorta	0	0	1 (3.2)	1 (4.3)
Retroesophageal subclavian artery	0	0	0	2 (8.7)
Persistent truncus arteriosus	0	1 (8.3)	0	0
Atrophy left atrial chamber	0	0	1 (3.2)	0
Vascular ring	0	0	0	1 (4.3)
Supernumerary azygos vein	0	1 (8.3)	0	0
No. pups alive during breast-feeding (B + C)	120	104	91	82
Alive neonates with cardiovascular malformations	0 (0)	12 (11.5)**	9 (9.9)**	14 (17.1)**
No. pups culled at PND 4 (B)	48	34	26	20
Pups with cardiovascular malformations	0 (0)	4 (11.8)	2 (7.7)	3 (15.0)*
Isolated VSD	0	1 (2.9)	1 (2.2)	3 (15.0)*
Overriding aorta	0	1 (2.9)	0	0
Double outlet right ventricle	0	0	1 (6.6)	0
Branching of the right subclavian artery from aorta	0	1 (2.9)	0	0
No. pups at PND 21 (C)	72	70	65	62
Pups with cardiovascular malformations	0 (0)	8 (11.4)**	7 (10.8)**	11 (17.7)**
Isolated VSD	0	7 (8.6)*	4 (6.2)	8 (12.9)**
Overriding aorta	0	0	1 (1.5)	0
Double outlet right ventricle	0	0	0	1 (1.6)
Patent ductus arteriosus	0	0	1 (1.5)	1 (1.6)
Right-sided aortic arch	0	0	0	1 (1.6)
Vascular ring	0	0	0	1 (1.6)
Branching of the right subclavian artery from aorta	0	1 (1.4)	0	0

*Significantly different from control group at $P < 0.05$.

**Significantly different from control group at $P < 0.01$.

The percent value is indicated in parenthesis.

Fetal toxicity of PB

Maternal exposure to PB at a dose of 120 mg/kg/day on two consecutive days during gestation increased postimplantation loss, whereas a dose of 80 mg/kg did not affect the viability of fetuses. The present finding of no increased postimplantation loss in the dams administered PB at 80 mg/kg/day is compatible with the

results of the two previous studies by Vorhees (1983) and Terada *et al.* (1987).

Cardiovascular malformations were increased in fetuses from the dams administered PB at 120 mg/kg/day on GD 8-9, 9-10 and 10-11, but not in any fetus from the dams administered PB at 80 mg/kg/day. The malformations observed in the present study were

characterized by overriding aorta, double outlet right ventricle and transposition of great arteries. Terada *et al.* (1987) reported that maternal exposure to PB 80 mg/kg/day on GD 7–17 caused VSD, overriding aorta and double outlet right ventricle in rat fetuses but did not induce transposition of great arteries. On the other hand, Vorhees (1983) reported that maternal exposure to PB at 80 mg/kg/day on GD 7–18 marginally increased the incidences of incomplete ventricular septum and ringed aorta in rat fetuses. The difference between the two studies and the present study might be attributable to differences in dose levels and the administration period of PB. In addition, the differences between Vorhees's (1983) study and the present one can be attributed partly to a methodologic difference in the detection of cardiovascular malformations. Wilson's (1965) method which Vorhees (1983) used for detection of cardiovascular malformations was to prepare 1 mm-thick transverse slices of fetal trunk by freehand razor blade sectioning in the regions from the shoulder joint through the thoracic and abdominal cavities and organs. On the other hand, Nishimura's method used in the present study was to examine the great vessels, the heart and its transverse sections with a dissecting microscope after fixation with Bouin's solution. Nishimura (1974) argued that Wilson's method was not suitable for the detection of subtle cardiovascular malformations, because of the freehand transverse sectioning of the fetal trunk.

Severe cardiovascular malformations, such as transposition of the great arteries, the double outlet right ventricle and the overriding aorta, induced at high frequency by the PB administration on GD 8–10 in the present study, are in agreement with the types and severities of cardiovascular malformations which were reported to be induced at high frequency in mouse fetuses (Davis & Sadler 1981; Irie *et al.* 1990; Yasui *et al.* 1995; Shoji *et al.* 2005) and in hamster fetuses (Taylor *et al.* 1980) from the dams administered retinoic acid. These severe cardiovascular malformations induced by maternal exposure to retinoic acid appeared to be similar to those induced in rat fetuses from the dams administered PB, as reported by Terada *et al.* (1987) and in the present study.

Furthermore, Shoji *et al.* (2005) reported that excessive exposure of mouse dams to tretinoin (retinoic acid) induced craniofacial anomalies in fetuses, such as micrognathia and sacral caudal anomalies which were termed as DiGeorge–Velocardiofacial Syndromes in the human case. Teratogenic studies with laboratory animals demonstrated PB-induced cleft palate in mice (Walker & Patterson 1974; Sullivan & McElhatton 1975), skeletal malformation in rats (McCull *et al.* 1963) and skull defects in rabbits (McCull 1967). The types of retinoic acid-induced skeletal anomalies (Shoji *et al.* 2005) were found to be different from those of the skeletal anomalies in fetuses from the PB-administered dams reported in the rat studies by Terada *et al.* (1987) and McCull *et al.* (1963, 1967) and in the present study, as well as in the mouse studies by Walker and Patterson (1974) and Sullivan and McElhatton (1975). Further study will be needed to explore any causative factor to elucidate possible differences and similarities in types of anomalies between retinoic acid and PB, and to further clarify the mechanisms underlying the PB-induced cardiovascular malformations and skeletal anomalies, as suggested by a cellular hypothesis for formation of the retinoic acid-induced cardiovascular malformations proposed by Yasui *et al.* (1995).

Postnatal fate of cardiovascular malformations

The tendency toward decrease in viability during the period from PND 0–4 in the PB-administered groups found in the present study was consistent with the results of Vorhees's (1983) study. Vorhees reported that the number of postnatal deaths before weaning increased in rat pups from the dams administered PB on both

GD 7–10 and GD 11–14, but not in pups from those treated with PB on GD 15–18. The period of GD in which on the increased number of postnatal deaths was observed in Vorhees's study was similar to the critical period for induction of the life-threatening cardiovascular malformations in fetuses found in the present study. However, Vorhees did not further examine the types of cardiovascular malformations that caused the increased mortality in the prenatal and preweaning offspring. Since the neonates were found to suffer from overriding aorta, double outlet right ventricle and transposition of great arteries in the present study, it can be inferred on the basis of the present study that the postnatal deaths resulted from the life-threatening cardiovascular malformations.

On the other hand, isolated VSD was not observed frequently in the dead pups from the PB-administered dams. It has been reported that VSDs did not affect postnatal survival in the rat pups of TMD 400 mg/kg-treated dams, and that the VSDs closed spontaneously during the neonatal period (Solomon *et al.* 1997). However, the postnatal fate of the PB-induced cardiovascular malformations was characterized by persistence of isolated VSD. The present results are in good agreement with those of Fleeman *et al.* (2004) who demonstrated that TMD-treatment-induced VSDs were closed postnatally, and the timing of closure and survivability depended on the severity of the VSDs.

VSD, overriding aorta, double outlet right ventricle, transposition of great arteries and persistent truncus arteriosus found in the present study may be considered to be part of an anatomical continuum in order of increasing severity, resulting from deficiency in the conotruncal region of the fetal heart (Daft *et al.* 1986; Veuthey *et al.* 1990). Severity of these cardiovascular malformations was reported to be based on varying degrees of malrotation of the great vessels with subsequent channeling of blood in improper pathways and on the degree of conotruncal deficiency (Daft *et al.* 1986). Recently, Hoffman and Kaplan (2002) reported an attempt to categorize congenital heart disease into three forms, minor, moderately severe and severe, in order to estimate the variations in reported incidences of congenital heart disease.

The present findings are compatible with a previous report showing that human pregnancies with exposure to phenobarbital monotherapy are associated with increased risk of infant malformations, including coarctation of the aorta with abnormal valves, ventricular septal defect and tetralogy of Fallot (Holmes *et al.* 2004). Although the teratogenic PB dose found in the present study was much higher than the reported human therapeutic dose (Kaneko 1991; Moore *et al.* 2000), the present findings would provide an animal-experimental basis for assessing the increased risk of congenital heart disease in human offspring from mothers who use PB as monotherapy or in combination.

ACKNOWLEDGMENTS

We thank Dr T. Matsushima and Dr M. Mizutani for their encouragement and valuable advice in the present study and Dr H. Arito and Dr T. Takeuchi for their review of the manuscript.

REFERENCES

- Bossi L (1983) Fetal effects of anticonvulsants. In: Morselli PL, Pippenger CE, Penry JK (eds). *Antiepileptic Drug Therapy in Pediatrics*. Raven Press, New York, pp. 37–64.
- Daft PA, Johnston MC, Suik KK (1986) Abnormal heart and great vessel development following acute ethanol exposure in mice. *Teratology* 33: 93–104.
- Davis LA, Sadler TW (1981) Effects of vitamin A on endocardial cushion development in the mouse heart. *Teratology* 24: 139–148.

- Dawson AB (1926) A note on the staining of the skeleton of cleared specimens with alizarin red S. *Stain Technol* 1: 123-125.
- Finnell RH, Bielec B, Nau H (1997) Anticonvulsant drugs: Mechanisms and pathogenesis of teratogenicity. In: Kavlock RJ, Daston GP (eds). *Drug Toxicity in Embryonic Development II: Advances in Understanding Mechanisms of Birth Defects: Mechanistic Understanding of Human Developmental Toxicants*, Vol. 124. Springer-Verlag, New York, pp. 121-159.
- Fleeman TL, Cappon GD, Hurtt ME (2004) Postnatal closure of membranous ventricular septal defects in Sprague-Dawley rat pups after maternal exposure with trimethadione. *Birth Defects Res B Dev Reprod Toxicol* 71: 185-190.
- Hamada C, Yoshino K, Abe I, Matsumoto K, Nomura M, Yoshimura I (1998) Detection of an outlier and evaluation of its influence in chronic toxicity studies. *Drug Inf J* 32: 201-212.
- Hoffman JJ, Kaplan S (2002) The incidence of congenital heart disease. *J Am Coll Cardiol* 39: 1890-1199.
- Holmes LB, Wyszynski DF, Lieberman E (2004) The AED (antiepileptic drug) pregnancy registry. *Arch Neurol* 61: 673-678.
- Irie K, Ando M, Takao A (1990) All-trans retinoic acid induced cardiovascular malformations. *Ann NY Acad Sci* 588: 387-388.
- Kaneko S (1991) Antiepileptic drug therapy and reproductive consequences: Functional and morphologic effects. *Reprod Toxicol* 5: 179-198.
- Kaneko S, Kondo T (1995) Antiepileptic agents and birth defects. *CNS Drugs* 3: 41-55.
- McCull JD (1967) Effect of some therapeutic agents on the rabbit fetus. *Toxicol Appl Pharmacol* 10: 244-252.
- McCull JD, Globus M, Robinson S (1963) Drug induced skeletal malformations in the rat. *Experientia* 19: 183-184.
- Moore SJ, Turnpenny P, Quinn A *et al.* (2000) A clinical study of 57 children with fetal anticonvulsant syndromes. *J Med Genet* 37: 489-497.
- Nishimura K (1974) A microdissection method for detecting thoracic visceral malformations in mouse and rat fetuses. *Congenit Anom Kyoto* 14: 23-40. (In Japanese.)
- Schardein JL (2000) Anticonvulsants. *Chemically Induced Birth Defects*, 3rd edn. Marcel Dekker, Inc., New York, pp. 179-235.
- Shoji S, Sawada K, Shoji I, Azad M, Fukui Y, Tashiro S (2005) Conotruncal anomalies and neurocristopathy following maternal excess tretinoin exposure. *Birth Defects Res a Clin Mol Teratol* 73: 361. (Abstract).
- Solomon HM, Wier PJ, Fish CJ *et al.* (1997) Spontaneous and induced alterations in the cardiac membranous ventricular septum of fetal, weanling, and adult rats. *Teratology* 55: 185-194.
- Sullivan FM, McElhatton PR (1975) Teratogenic activity of the antiepileptic drugs phenobarbital, phenytoin, and primidone in mice. *Toxicol Appl Pharmacol* 34: 271-282.
- Sullivan FM, McElhatton PR (1977) A comparison of the teratogenic activity of the antiepileptic drugs carbamazepine, clonazepam, ethosuximide, phenobarbital, phenytoin, and primidone in mice. *Toxicol Appl Pharmacol* 40: 365-378.
- Taylor LM, Wiley MJ, Agur A (1980) Retinoic acid-induced heart malformations in the hamster. *Teratology* 21: 193-197.
- Terada Y, Mukumoto K, Shigematsu K, Nishimura K, Ohnishi K (1987) Reproduction studies of zonisamide. (5) A comparison of the teratogenic effect of zonisamide and phenobarbital in rats. *Jpn Pharmacol Ther* 15: 127-143. (In Japanese.)
- Veuthey S, Sexieder T, Scott WJ Jr (1990) Pathogenesis of cardiac anomalies induced by trimethadione in the rat. In: Clark BB, Takao A (eds). *Developmental Cardiology Morphogenesis and Function*. Futura Publishing Co., Inc, Mount Kisco, NY, pp. 453-465.
- Vorhees's CV (1983) Fetal anticonvulsant syndrome in rats: Dose- and period-response relationships of prenatal diphenylhydantoin, trimethadione and phenobarbital exposure on the structural and functional development of the offspring. *J Pharmacol Exp Ther* 227: 274-287.
- Walker BE, Patterson A (1974) Induction of cleft palate in mice by tranquilizers and barbiturates. *Teratology* 10: 159-164.
- Wilson JG (1965) Methods for administering agents and detecting malformations in experimental animals. In: Wilson JG, Warkany J (eds). *Teratology: Principles and Techniques*. The University of Chicago Press, Chicago, pp. 262-277.
- Yamazaki M, Noguchi Y, Tanda M, Shintani S (1981) Statistical methods appropriate for general toxicological studies in rats. Algorithms for multiple comparisons of treatment groups with control. *J Takeda Res Lab* 40: 163-187. (In Japanese.)
- Yasui H, Nakazawa M, Morishima M, Miyagawa-Tomita S, Momma K (1995) Morphological observations on the pathogenetic process of transposition of the great arteries induced by retinoic acid in mice. *Circulation* 91: 2478-2486.

INFLUENCE OF DI-(2-ETHYLHEXYL)PHTHALATE ON FETAL TESTICULAR DEVELOPMENT BY ORAL ADMINISTRATION TO PREGNANT RATS

Mariko SHIROTA¹, Yoshiaki SAITO¹, Kiyoshi IMAI^{1*}, Shinji HORIUCHI¹, Shinsuke YOSHIMURA¹, Masako SATO^{1**}, Tetsuji NAGAO^{1***}, Hiroshi ONO¹ and Masanobu KATOH²

¹ Hatano Research Institute, Food and Drug Safety Center, 729-5 Ochiai, Hadano, Kanagawa 257-8523, Japan

² Mitsubishi Chemical Safety Institute Ltd, 2-1-30 Shiba, Minato-ku Tokyo 105-0014, Japan

(Received January 18, 2005; Accepted April 8, 2005)

ABSTRACT — Influence of di-(2-ethylhexyl)phthalate (DEHP) on testicular development was studied by oral administration of DEHP at doses of 500 and 1000 mg/kg/day to pregnant rats on gestational days (G) 7 to 18. Ethinyl estradiol (EE) at dose levels of 0.25 and 0.5 mg/kg/day was used as a reference substance. Each 5-6 pregnant rats were sacrificed and their fetuses were examined on G12, 14, 16, 18 and 20. Fetal deaths averaging 20-36% were observed at every examination in the group receiving 1000 mg/kg of DEHP. Increases of fetal deaths over 50% were also observed in the reference group that received 0.5 mg/kg of EE. Microscopic examination of the fetal testis in groups treated with DEHP revealed degeneration of germ cells in G16 fetuses and localized proliferation or hyperplasia of interstitial cells in G18 and 20 fetuses. Germ cells having more than two nuclei were observed in a few cases including the control testes of G14 fetuses. These multinucleated cells were observed frequently in G20 fetuses treated with DEHP. Examination of testes of naturally delivered offspring of dams treated with 1000 mg/kg of DEHP at 7 weeks of age revealed scattered atrophy or dilatation of seminiferous tubules.

Another experiment was carried out to confirm the dose of DEHP affecting testicular development and spermatogenesis. DEHP was given to pregnant rats at doses of 125, 250 and 500 mg/kg/day during G7-18. Similar histopathological changes were observed in fetal testes of the group exposed to 500 and 250 mg/kg of DEHP, but not in those exposed to 125 mg/kg. In postnatal examinations, however, no abnormality was found in the testes at 5 and 10 weeks after birth in any of the treated groups. Furthermore, no abnormal findings were observed in the function of sperm, sperm counts and sperm morphology in the offspring of the group treated with DEHP during the fetal period at 10 weeks of age. Thus, 125 mg/kg/day is considered the no-observed-effect-level of DEHP on testicular development of rats by exposure *in utero* during the period of organogenesis.

KEY WORDS: Phthalic acid ester, Developmental toxicity, Testicular toxicity, Sertoli cells, Sperm function, Rats

INTRODUCTION

It has been shown that high doses of phthalic acid esters exert testicular toxicity in animals (Calley *et al.*, 1966; Gangolli, 1982). Toxic effects on the testis were similarly observed with a variety of phthalate esters such as di-(2-ethylhexyl) phthalate (DEHP) (Gray *et*

al., 1977), dibutylphthalate, (Cater *et al.*, 1977) and di-n-pentylphthalate (Creasy *et al.*, 1983, 1987). Among a variety of phthalate esters, DEHP has been investigated most frequently as a representative substance of phthalic acid esters. The mechanism of the testicular toxicity of phthalates is not yet wholly clear, although the damaging effect on Sertoli cells and blood-testis

Correspondence: Hiroshi ONO

Present address: * Biosafety Research Center, Foods, Drugs and Pesticides, 582-9 Shiohinden, Fukude-cho, Iwata-gun, Shizuoka 437-1213, Japan

** Syngenta Japan, 1-8-10 Harumi, Chuo-ku, Tokyo 104-6021, Japan

*** Department of Life Sciences, Faculty of Science and Technology, Kinki University, 3-4-1 Kowakae, Higashi-Osaka, Osaka 557-8502, Japan

Vol. 30 No. 3

barrier has been considered (Gray and Butterworth, 1980). We have conducted a series of experiments on testicular toxicity of DEHP in rats, and have clarified that ultrastructural changes were induced in seminiferous tubules at stages from IX to I of the spermatogenic cycle in 8 week-old Sprague-Dawley rats, 3 to 18 hr after single-dose administration of 2,800 mg/kg of DEHP (Saitoh *et al.*, 1997). Noteworthy changes were degeneration of spermatocytes, dilatation of rough-surfaced endoplasmic reticulum, especially those in the vicinity of the tight junction of ectoplasmic specialization of Sertoli cells, and disintegration of the intercellular junction between Sertoli cells. In a study utilizing electron microscopic autoradiography, we have demonstrated the distribution of phthalic acid into the testis, especially to Sertoli cells (Ono *et al.*, 2004). We have also observed that clear structural changes of testes were induced with single oral dose of 1400 mg/kg, and that the non-toxic dose level of DEHP on testes was 700 mg/kg in mature rats. Furthermore, we have employed a lanthanum trace method to examine the effects of DEHP on Sertoli cell function, especially on the condition of blood-testis barrier in rats (Saitoh *et al.*, 1997). In this study, lanthanum particles were observed 6 hr after administration at the tight junction between Sertoli cells, which showed that the function of Sertoli cells to maintain the blood-testis-barrier was affected with DEHP as early as 6 hr after oral administration, but had recovered by 24 hr. The fetal stage is known to be vulnerable to chemical exposure, and the effects on gonadal and endocrine systems are of special concern. In this context, de Kretser and Kerr (1994) described that the blood-testis barrier in rats was established during 16~19 days of postnatal life. In the present study, influence of *in utero* exposure to DEHP on development of testes in rats was examined. Ethinyl estradiol was used as a reference substance for estrogenic activity of DEHP, if any.

MATERIALS AND METHODS

Materials

Di-(2-ethylhexyl)phthalate (DEHP) was purchased from Wako Pure Chemical Industries Ltd. and was diluted with corn oil (Nacalai Tesque Inc.) to a concentration appropriate for administration at the constant volume of 5 mL/kg. Ethinyl estradiol (EE, Wako Pure Chemical) was suspended in corn oil on the same principle and used as the reference compound.

Animals

Adult rats of Sprague-Dawley strain (Crj: CD IGS) were purchased from Charles River Japan Inc., and were kept for a week to acclimatize them to the laboratory condition. The animals were reared individually in a metallic cage sized 220×270×190 mm, in a room with conditioned temperature at 24~26°C and relative humidity within 50~65%. Lighting was alternated at 12 hr intervals (lights on 7:00~19:00). Appropriate bedding material such as White flake (Charles River) was provided for pregnant and nursing rats. The animals were fed with pellet food (CE-2, CLEA Japan Inc.) *ad libitum* and were supplied with tap water.

A female rat was mated with a male and a vaginal smear specimen was examined every morning. The day when a vaginal plug or sperm in the specimen was confirmed was defined as gestational day (G) 0. The pregnant animals were allocated to groups in a random fashion stratified by body weight on the day of administration (G7).

Dosage and administration

Preliminary dose-finding study showed that administration of 2000 mg/kg/day DEHP to pregnant rats from G7 to G18 caused high incidence of absorption of embryos and fetal deaths. Similar administration of 1000 mg/kg/day of DEHP caused a few fetal deaths and some pathological findings in the testis. Thus the doses of DEHP were decided on 1000 mg/kg for the highest and 500 mg/kg for the lowest in the first experiment. The doses of DEHP in Experiment 2 were selected to be 500, 250 and 125 mg/kg, considering the results of the first experiment. The doses of EE were set at 0.5 and 0.25 mg/kg referring to the study by Yasuda *et al.* (1985) in mice. Oral administration by gavage was started on G7 and continued till G18.

Experimental design

The study was designed in two phases; observation of the histopathological changes of testicular development by intra-uterine exposure to DEHP was made in Experiment 1, including the dose finding, and in Experiment 2 a search for the no-effect level was attempted, together with confirmation of the findings in Experiment 1.

In Experiment 1, 28-30 dams per group were given oral administration of DEHP, EE or the vehicle from G7 to G18. Each 6 of these dams were killed by ether inhalation on G12, 14, 16, 18 and 20 to examine their fetuses. In addition, each 5 dams of groups given 500 and 1000 mg/kg of DEHP were allowed to deliver

DEHP on rat testicular development.

spontaneously to examine postnatal changes in the testis and epididymis of their offspring. The male offspring were reared and kept until examination at 7 weeks of age.

In Experiment 2, each 11-12 pregnant females were given oral administration of DEHP or vehicle. Each 3 dams of the groups were submitted to Caesarean section on G20 to examine their fetuses. Other dams were allowed to deliver spontaneously and male offspring chosen for examination at 5 and 10 weeks of age. The day of delivery was defined as Day 0 of lactation.

Observations of dams

Dams were examined daily for general conditions in all experiments and body weight was measured occasionally. Delivery and nursing conditions were observed and the numbers of fetuses delivered and live offspring were determined. From these data and the number of implantations counted at the necropsy, viability of the offspring, namely, delivery index (fetuses delivered/implantation sites, %), birth index (live offspring at birth/implantation sites, %), viability index (live offspring on day 4 of lactation/live offspring at birth, %) and weaning index (live offspring on day 21 of lactation/live offspring on day 4 of lactation, %), were determined.

Examination of the fetuses and offspring

In Experiment 1, fetuses on G12 were collected only for histopathological examination. Live fetuses collected on G14, 16, 18 and 20 were weighed and the external appearances examined. Whole bodies and testes from these live fetuses were submitted for histopathological or electron microscopic examination. The testes and epididymides of male offspring of the DEHP-treated groups were collected at 7 weeks of age for histopathological examination.

For histopathological examination, the specimens were fixated in Bouin's solution and then immersed in a buffered neutral formalin solution. The fixed tissues were embedded in paraffin and cut in 4 μm slices. These sections were stained with hematoxylin and eosin (HE) and were examined under light microscopy.

For electron microscopic examination, the tissues were immersed in an ice-cold mixture of 2% paraformaldehyde buffered with 0.1 M *s*-collidine and 1.25% glutaraldehyde for 3 hr. The fixed tissues were cut into small pieces and post-fixed with 2% osmium tetroxide buffered with 0.1 M *s*-collidine. The post-fixed tis-

ues were dehydrated in ethanol and embedded in epoxy resin (Quetol-651, Nissin EM, Tokyo). Semi-thin sections (1 μm) were stained with toluidine blue and observed under a light microscope. Representative areas were selected from the testis preparations and ultra-thin sections were prepared and stained with uranyl acetate and lead citrate, and then examined with an electron microscope (H-7100, Hitachi, Tokyo).

In Experiment 2, all of the live fetuses examined on G20 were weighed by sex and examined for their external appearance, and then testes were dissected from live male fetuses for histopathological examination as described in Experiment 1, and for staining of androgen receptors. The offspring were weighed and reared until examination. Each 4 male offspring from each group were killed at 5 and 10 weeks of age, and testes with epididymides were dissected and HE-stained thin sections prepared as described above. For electron microscopic examination, each 2 male offspring were used and fixation was performed by a systemic perfusion of a mixture solution of 2% paraformaldehyde buffered with 0.1 M *s*-collidine and 2.5% glutaraldehyde from the aorta to the body with a perfusion pump under sodium pentobarbital anesthesia. The testes were submitted to electron microscopic observation. The other 4 offspring of each group were killed by ether inhalation at 10 weeks of age to obtain their testes and epididymides for sperm examination.

Immunohistochemistry of androgen receptors

In addition, in order to confirm the development of hormone receptors, expression of androgen receptors in the testis was observed by an immunohistochemical method (Dalgaard *et al.*, 2001), using a rabbit polyclonal antibody for N-terminal of the androgen receptor (AR-20, Santa Cruz Biotechnology, Santa Cruz, CA, USA).

Examination of spermatogenesis

In Experiment 2 the seminiferous epithelium cycle was examined on testis sections stained with HE obtained at 5 weeks of age, and the spermatogenic stage was determined according to the simplified method described by Matsui *et al.* (1996). Briefly, seminiferous tubules on a specimen were classified into four groups by spermatogenic stages I-VI, VII-VIII, IX-XI and XII-XIV (Dym and Clermont, 1970). One corresponding section of the testis was stained with periodic acid Schiff (PAS) to confirm acrosomes of spermatogonia. Each 5 seminiferous tubules belonging to 4 groups were chosen and the numbers of germ

cells and Sertoli cells in a tubule determined to calculate a ratio of germ cells to Sertoli cells in each group.

Analysis of morphology and function of sperm

Sperm were collected through micropuncture of the cauda epididymis of rats at 10 weeks of age, and were examined as previously described (Sato *et al.*, 2000). Sperm motility was measured using a computer-assisted sperm motion analysis system (HTM-IVOS ver 10.6, Hamilton-Thorne Research, Beverly, MA, USA) and for morphological analysis of spermatozoa as described previously (Sato *et al.*, 2002a). After the collection of sperm for motility analysis, the cauda epididymis was dissected at the transition point to the vas deferens and at the middle of the cauda and body of epididymis, weighed and then stored at -20°C . The frozen cauda epididymis was thawed to room temperature and homogenized in distilled water. The sperm heads in the homogenate were counted with HTM-IVOS as previously described (Sato *et al.*, 2002b).

Statistical analysis

When uniformity of variance was confirmed among the groups by the method of Bartlett, data obtained were analyzed by ANOVA (Yoshimura, 1986). When the uniformity was not confirmed, Kruskal-Wallis's rank-sum test was applied instead (Yoshimura, 1986). When significant differences between groups were observed in either of the analyses, Dunnett test was applied for a comparison between the control and treated groups of either DEHP or EE (Yoshimura, 1986). A *p* value less than 0.05 was considered statistically significant.

RESULTS

Effects of DEHP treatment on dams

Daily oral administration of DEHP at a level of 1000 mg/kg and EE at levels of 0.25 and 0.5 mg/kg slightly suppressed body weight gain of pregnant rats during the treatment period. Administration of the lower dose levels of DEHP did not affect maternal body weight (Tables 1 and 2).

Effects of maternal treatment with DEHP on fetuses and offspring

Reproductive performance data, including fetal weights on G14, 16, 18 and 20 in Experiment 1, are summarized in Table 1. Oral DEHP treatment at 1000 mg/kg reduced fetal body weights at G14 and 18 sig-

nificantly ($p < 0.01$) as compared with those of the control group. Furthermore, 1000 mg/kg of DEHP treatment increased intrauterine mortality to 20-36%. DEHP treatment at 500 mg/kg did not cause increase in fetal deaths and changes in fetal body weight significantly. Treatment with 0.5 mg/kg of EE also increased intrauterine mortality of fetuses, even to more than 50% on G16 and 20.

External observation of fetuses on G20 revealed various malformations in treated groups. Two fetuses with branchyury from a single dam given 500 mg/kg DEHP were observed and each one fetus with general edema, club foot or anal atresia and 3 fetuses with kinked tail from a single dam given 1000 mg/kg of DEHP were observed. In the group treated with 0.5 mg/kg of EE, one fetus with kinked tail was observed. Two out of 5 dams given 500 mg/kg DEHP did not deliver any offspring because of early embryonic loss. However, 1000 mg/kg of DEHP did not cause any abnormality in delivery.

In Experiment 2, DEHP-treatment up to 500 mg/kg did not show any marked effect on fetuses (Table 2). External malformations observed in the 500 mg/kg group in Experiment 1 were not reproduced in Experiment 2. Birth weights of the offspring were significantly higher in the groups exposed to DEHP at 250 and 500 mg/kg than control. Viability and growth rate of the offspring are summarized in Table 3. Differences of body weight among the groups were insignificant on the 4th day of lactation.

Histopathological findings of fetuses and offspring

Histopathological findings of fetal testes in Experiment 1 are summarized in Table 4. Representative photographs are shown in Photos 1-3. The testis was not distinguishable in the fetuses on G12, when a few round germ cells with clear cytoplasm were scattered in mesenchyma around mesonephros. The testis was distinguished morphologically on G14, when the germinal ridge was formed and a few germ cells, some showing mitosis, were seen in the gonadal cord. On G16, the testicular cord became prominent, containing many round nucleated germ cells and Sertoli cells on its margin (Photo 1a). On G18, the interstitium was widened in the center of the gonad containing rich interstitial cells (Photo 2a), when the density of germ cells in the reproductive tract was increased. On G20, the testicular cord developed further, although the tubular structure was not yet formed (Photo 3a).

No abnormalities were observed in any group on G14. On G16, degeneration of germ cells was noted in

DEHP on rat testicular development.

Table 1. Viability and development of fetuses exposed to di-(2-ethylhexyl)phthalate (DEHP) or ethinyl estradiol (EE) during gestational days 7-18 (Experiment 1).

	DEHP (mg/kg)			EE (mg/kg)	
	0 ^a	500	1000	0.25	0.5
<u>Gestational day 14</u>	(6)	(6)	(6)	(5)	(5)
Maternal body weight (g)	336.9 ± 17.4	326.5 ± 31.0	320.2 ± 14.9**	295.7 ± 14.7**	278.4 ± 22.7**
Implantations	17.0 ± 1.4	15.0 ± 1.7	16.2 ± 1.2	15.6 ± 1.1	13.6 ± 4.7
Intrauterine mortality (%)	7.1 ± 5.9	3.0 ± 5.0	20.3 ± 18.4	3.8 ± 5.6	6.9 ± 9.4
Live fetuses	15.8 ± 2.1	14.5 ± 1.2	12.8 ± 2.9	15.0 ± 1.4	12.6 ± 4.5
Mean fetal weight (g)	0.16 ± 0.02	0.15 ± 0.01	0.12 ± 0.02**	0.15 ± 0.01	0.15 ± 0.02
<u>Gestational day 16</u>	(5)	(6)	(6)	(0)	(5)
Maternal body weight (g)	344.9 ± 4.9	344.3 ± 21.3	311.4 ± 20.0**		285.7 ± 30.4**
Implantations	15.4 ± 1.3	16.0 ± 1.3	15.3 ± 1.6		13.6 ± 6.2
Intrauterine mortality (%)	1.3 ± 2.8	12.4 ± 7.6	33.1 ± 31.3		72.0 ± 36.9
Live fetuses	15.2 ± 1.3	14.0 ± 1.4	10.2 ± 4.8		4.2 ± 5.4
Mean fetal weight (g)	0.44 ± 0.02	0.43 ± 0.02	0.37 ± 0.04		0.42 ± 0.02 ^b
<u>Gestational day 18</u>	(6)	(6)	(6)	(4)	(5)
Maternal body weight (g)	370.7 ± 36.5	360.0 ± 36.6	335.5 ± 20.2*	327.6 ± 42.4*	321.7 ± 16.3**
Implantations	14.5 ± 1.4	15.2 ± 2.6	14.8 ± 1.6	15.3 ± 2.2	14.4 ± 2.4
Intrauterine mortality (%)	3.6 ± 6.3	1.0 ± 2.4	35.6 ± 36.5	5.7 ± 7.9	1.3 ± 3.0
Live fetuses	14.0 ± 1.8	15.0 ± 2.5	9.5 ± 5.6	14.3 ± 1.0	14.2 ± 2.4
Mean fetal weight (g)	1.35 ± 0.07	1.32 ± 0.06	1.03 ± 0.13**	1.33 ± 0.05	1.25 ± 0.10
<u>Gestational day 20</u>	(6)	(6)	(6)	(0)	(2)
Maternal body weight (g)	404.2 ± 6.5	410.8 ± 30.2	365.0 ± 25.4**		322.8
Implantations	14.7 ± 1.6	14.8 ± 2.6	14.5 ± 1.5		15.5
Intrauterine mortality (%)	0.0 ± 0.0	2.7 ± 4.4	36.4 ± 26.5		50.8
Live fetuses	14.7 ± 1.6	14.5 ± 2.9	9.0 ± 3.5		7.5
Mean fetal weight (g)	3.68 ± 0.20	3.52 ± 0.14	2.82 ± 0.11		2.90
External malformations	0.0 ± 0.0	2.22 ± 5.44	6.25 ± 15.31		7.14

^a Vehicle control (corn oil, 5 mL/kg). ^b Data from 3 dams having live fetuses.

* Significantly different from control (p<0.05). ** Significantly different from control (p<0.01).

Table 2. Reproductive parameters on gestational day 20 in rats treated with di-(2-ethylhexyl) phthalate (DEHP) during gestational days 7-18 (Experiment 2).

	DEHP (mg/kg)			
	0 ^a	125	250	500
<u>Gestational day 20</u>				
Dams examined	3	3	3	3
Maternal body weight (g)	408.3 ± 32.6	428.8 ± 42.5	399.3 ± 43.4	427.9 ± 50.8
Implantations	14.7 ± 0.6	15.0 ± 2.6	14.0 ± 1.7	16.0 ± 1.7
Intrauterine mortality (%)	2.2 ± 3.9	0	2.8 ± 4.8	4.1 ± 3.6
Live fetuses	14.3 ± 0.6	15.0 ± 2.6	13.7 ± 2.3	15.3 ± 1.5
Males	5.3 ± 1.2	7.0 ± 3.5	6.3 ± 2.1	9.3 ± 2.1
Females	9.0 ± 1.0	8.0 ± 1.0	7.3 ± 0.6	6.0 ± 1.0
Sex ratio (%)	37.2 ± 7.6	44.7 ± 17.2	45.5 ± 8.5	60.5 ± 9.1
Fetal body weight (g)	14.0 ± 1.8	15.0 ± 2.5	9.5 ± 5.6	14.2 ± 2.4
Males	3.77 ± 0.13	3.86 ± 0.40	4.02 ± 0.13	3.57 ± 0.14
Females	3.51 ± 0.14	3.67 ± 0.34	3.77 ± 0.16	3.40 ± 0.03
External malformations	0	0	0	0

Values represent mean ± S.D.

^a Vehicle control (corn oil, 5 mL/kg).

one of 12 examined fetuses of the 1000 mg/kg DEHP group (Photos 1b, 1c). No such findings were noted in other fetuses of the group exposed to DEHP at 1000 mg/kg and also at 500 mg/kg. On G18, interstitial cells were increased in number and aggregated topically in the 500 mg/kg DEHP group (Photo 2b), and the hyperplasia of interstitial cells was intensified in the 1000 mg/kg DEHP group (Photo 2c), while such findings were not noted in any testes of fetuses exposed to EE. Testicular size was smaller in the groups of 1000 mg/kg DEHP and 0.5 mg/kg EE on G18 and G20. On G20, germ cells having more than two nuclei were noted and thickened seminiferous cords containing rich germ cells were seldom observed in the 500 mg/kg DEHP group. In fetal testes of the 1000 mg/kg DEHP group hyperplasia of interstitial cells, multinucleated germ cells were also seen (Photos 3b, 3c). Topically thickened seminiferous cords due to aggregation of germ

cells were observed frequently in this group.

Table 5 summarizes histopathological findings in the testis of the offspring in Experiment 1. Representative pictures are shown in Photos 4~6. In the offspring at 7 weeks after birth prenatally exposed to DEHP at a level of 500 mg/kg, no obvious abnormalities were found except for multinucleated giant cells in the seminiferous tubules and cell debris in the epididymal lumens (Photos 4a, 4b). In the 1000 mg/kg-exposed group, however, most of the animals had developed abnormalities, such as branched seminiferous tubules with atrophy and/or dilatation, multinucleated giant cells and dilatation of rete testis (Photos 4c, 5a, 5b). In addition to these findings, testes from several animals in this group showed hyperplasia of the interstitial cells (Photo 4c), necrosis and/or mineralization of testes, foreign body giant cells, focal loss of seminiferous tubules and malformed seminiferous tubules (Photos

Table 3. Reproductive data and development of the offspring treated with di-(2-ethylhexyl) phthalate (DEHP) during gestational days 7-18 (Experiment 2).

	DEHP (mg/kg)			
	0 ^a	125	250	500
Dams examined	8	9	8	8
Gestation length (days)	21.8 ± 0.5	22.0 ± 0.0	22.0 ± 0.0	22.0 ± 0.0
Implantation sites	15.4 ± 1.2	15.6 ± 2.4	15.4 ± 1.1	14.9 ± 1.2
<u>At birth (Day 0 of lactation)</u>				
Live offspring	14.0 ± 2.1	14.6 ± 2.6	14.4 ± 1.7	14.1 ± 1.2
Birth index (%) ^b	90.8 ± 9.0	93.2 ± 6.3	93.5 ± 8.8	95.1 ± 5.7
Sex ratio (%)	42.0 ± 10.4	45.7 ± 8.9	42.9 ± 12.3	50.5 ± 12.3
Body weight, males (g)	6.5 ± 0.3	6.7 ± 0.5	7.0 ± 0.5	7.1 ± 0.3*
Body weight, females (g)	6.1 ± 0.3	6.3 ± 0.5	6.7 ± 0.6*	6.7 ± 0.3*
<u>Day 4 of lactation</u>				
Live offspring	13.9 ± 2.2	14.3 ± 2.5	14.4 ± 1.7	14.0 ± 1.3
Viability (%)	99.0 ± 2.7	98.6 ± 2.8	100.0 ± 0.0	99.1 ± 2.5
Sex ratio (%)	42.3 ± 10.1	46.3 ± 8.5	42.9 ± 12.3	50.9 ± 11.4
Body weight, males (g)	10.3 ± 1.1	10.4 ± 1.0	10.7 ± 0.7	10.5 ± 1.3
Body weight, females (g)	9.8 ± 1.2	9.7 ± 1.0	10.3 ± 0.8	10.0 ± 1.3
Body weight, preserved males (g) ^c	10.4 ± 0.9	10.7 ± 0.7	11.0 ± 0.5	10.7 ± 0.1
<u>Day 7 of lactation</u>				
Body weight, preserved males (g)	17.1 ± 2.3	16.9 ± 1.0	18.2 ± 0.7	17.2 ± 0.2
<u>Day 14 of lactation</u>				
Body weight, preserved males (g)	36.1 ± 2.8	34.5 ± 1.5	37.5 ± 0.8	37.6 ± 1.3
<u>At weaning (Day 21 of lactation)</u>				
Body weight, preserved males (g)	58.7 ± 4.7	57.1 ± 4.1	62.2 ± 1.5	60.5 ± 3.3
Weaning index (%)	100.0 ± 0.0	100.0 ± 0.0	100.0 ± 0.0	100.0 ± 0.0

Values represent mean ± S.D. * Significantly different from control ($p < 0.05$).

^a Vehicle control (corn oil, 5 mL/kg). ^b Live offspring/implantation sites.

^c Each 2~3 male offspring from dams were preserved.

DEHP on rat testicular development.

Table 4. Histopathological findings of testes of fetuses exposed to di-(2-ethylhexyl) phthalate (DEHP) or ethinyl estradiol (EE) during gestational days 7-18 (Experiment I).

Group	DEHP 0 mg/kg			DEHP 500 mg/kg			DEHP 1000 mg/kg			EE 0.25 mg/kg			EE 0.5 mg/kg		
	-	±	+	-	±	+	-	±	+	-	±	+	-	±	+
<u>Gestational day 12</u>	(12)			(10)			(10)						(10)		
Degeneration of fetal tissue	12	0	0	10	0	0	8	0	2	0			2	0	8
<u>Gestational day 14</u>	(9)			(9)			(9)				(9)		(9)		
Multinucleated germ cells	8	1	0	9	0	0	8	1	0	0	9	0	8	1	0
<u>Gestational day 16</u>	(10)			(10)			(12)						(4)		
Degeneration of germ cells	10	0	0	10	0	0	11	0	1	0			4	0	0
Multinucleated germ cells	10	0	0	9	1	0	10	2	0	0			4	0	0
<u>Gestational day 18</u>	(20)			(20)			(10)				(11)		(16)		
Multinucleated germ cells	20	0	0	18	2	0	10	0	0	0	11	0	14	2	0
Increased germ cells in a cord	20	0	0	20	0	0	8	2	0	0	11	0	16	0	0
Hyperplasia of interstitial cells	20	0	0	8	12	0	0	3	7	0	11	0	16	0	0
Decrease in testicular size	20	0	0	20	0	0	4	0	6	0	11	0	9	7	0
<u>Gestational day 20</u>	(17)			(17)			(18)						(8)		
Multinucleated germ cells	16	1	0	0	0	10	7	0	3	13	2	0	4	4	0
Increased germ cells in a cord	17	0	0	14	3	0	0	1	12	5	0	0	5	3	0
Hyperplasia of interstitial cells	17	0	0	0	0	14	0	0	1	17	0	0	8	0	0
Decrease in testicular size	17	0	0	17	0	0	5	8	5	0	0	0	5	3	0

- : negative, ± : very slight, + : slight, ++ : moderate, +++ : severe.
 Figures in parentheses show number of dams examined.

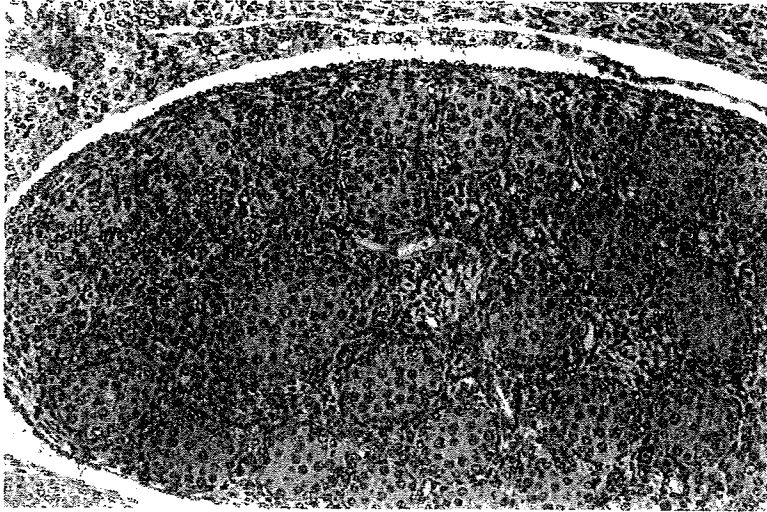


Photo 1-a. Transverse section of a fetus from the control group on G16 showing the genital ridge. HE stain, $\times 160$.

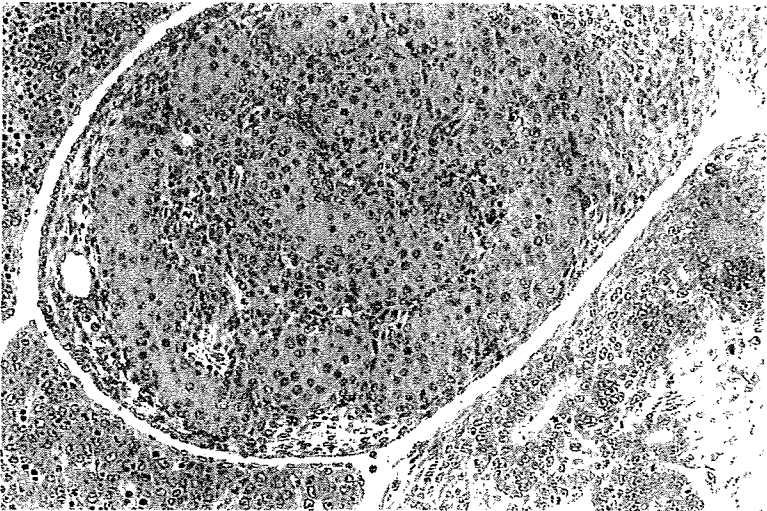


Photo 1-b. Transverse section of a fetus from the 1000 mg/kg DEHP group on G16 showing no abnormality in the genital ridge. HE stain, $\times 160$.

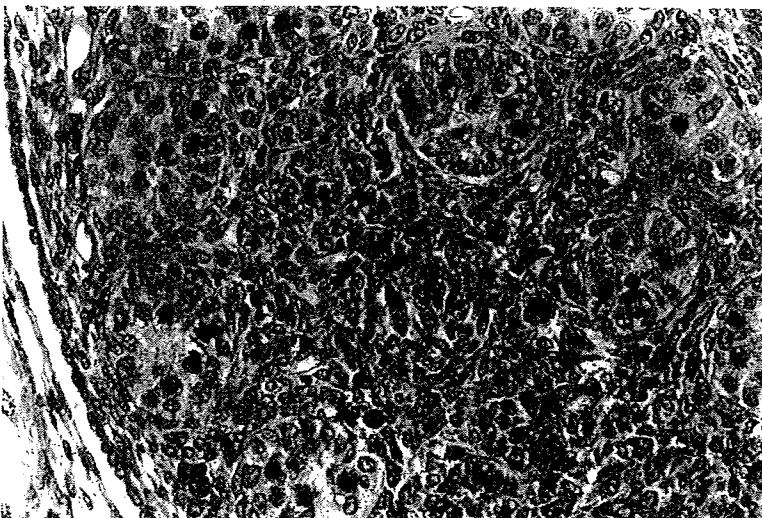


Photo 1-c. Transverse section of a fetus from the 1000 mg/kg DEHP group on G16 showing the genital ridge. Many germ cells are degenerated and densely stained. HE stain, $\times 310$.

DEHP on rat testicular development.



Photo 2-a. Testis of a G18 rat fetus from the control group. HE stain, $\times 160$.

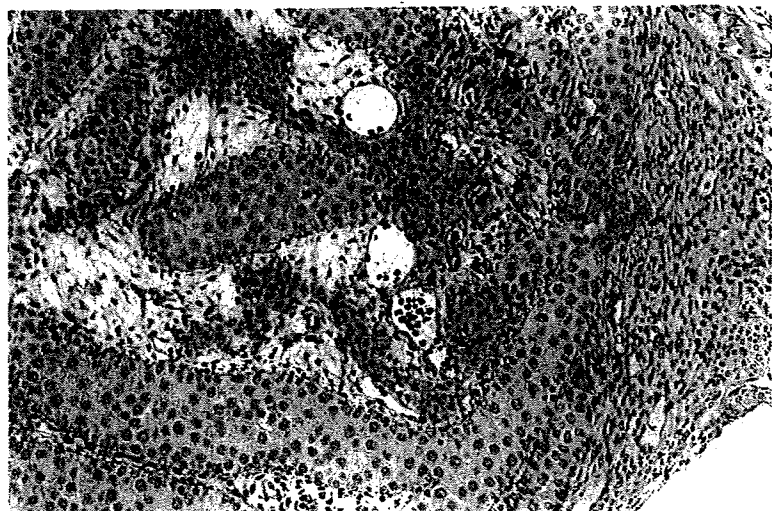

Photo 2-b. Testis of a G18 fetus from a rat treated with 500 mg/kg of DEHP showing hyperplasia of interstitial cells. HE stain, $\times 160$.

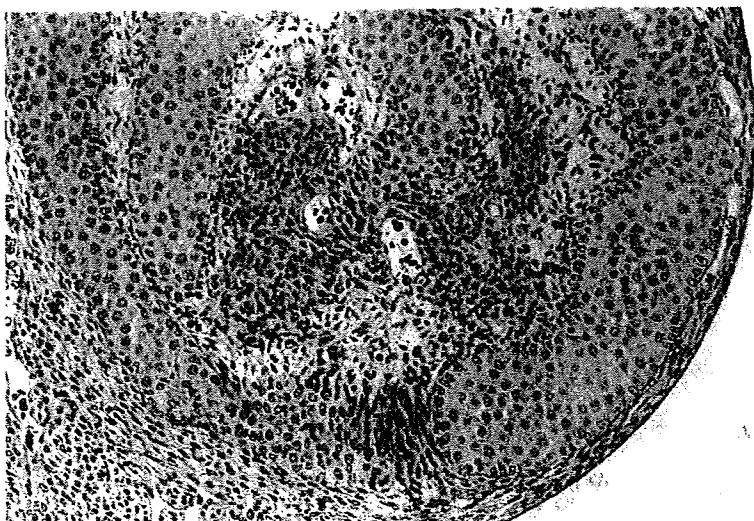


Photo 2-c. Testis of a G18 fetus from a rat treated with 1000 mg/kg DEHP showing hyperplasia of interstitial cells. HE stain, $\times 160$.

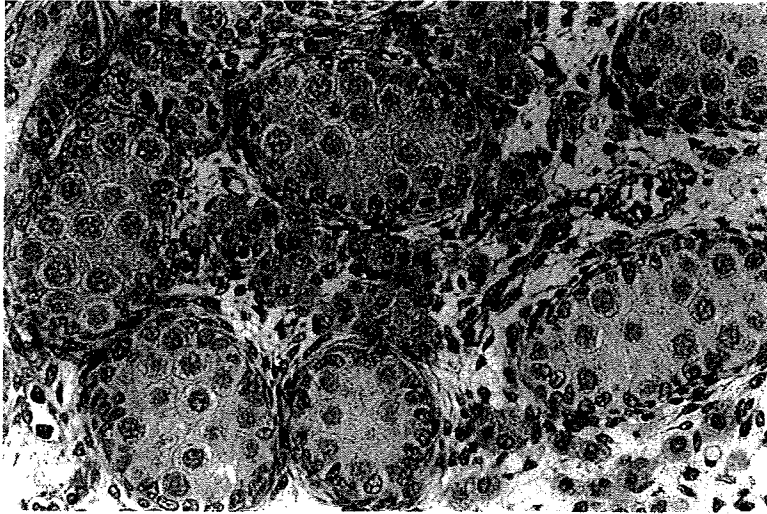


Photo 3-a. Testis of a G20 fetus from the control group showing the seminiferous cords and interstitial cells. HE stain, $\times 310$.

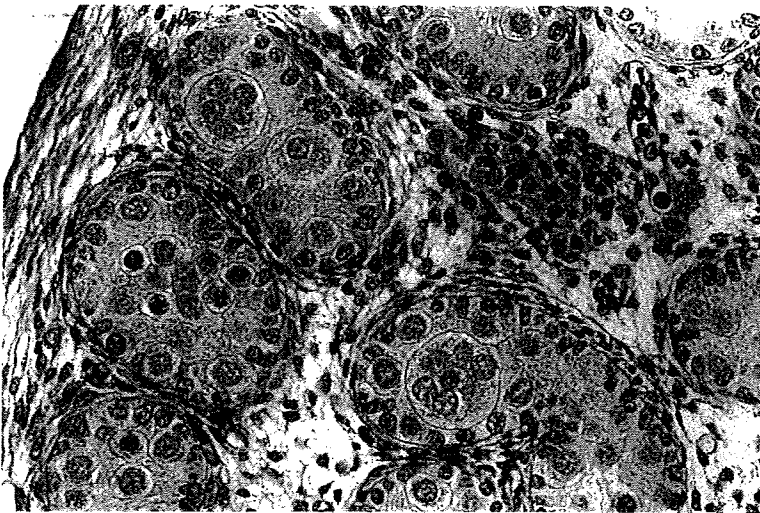


Photo 3-b. Testis of a G20 fetus from the group treated with 500 mg/kg of DEHP showing multinucleated germ cells in seminiferous cords. HE stain, $\times 310$.

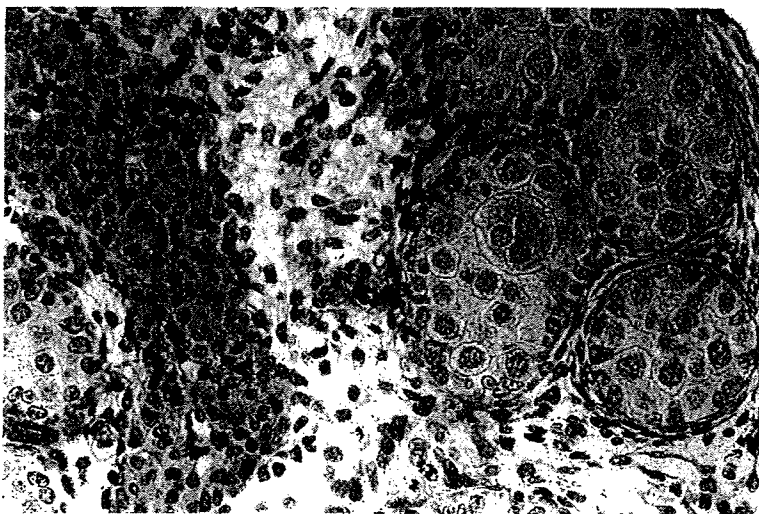


Photo 3-c. Testis of a G20 fetus from the group treated with 1000 mg/kg of DEHP showing multinucleated germ cells in seminiferous cords, and hyperplastic smaller-sized interstitial cells. HE stain, $\times 310$.

DEHP on rat testicular development.

5a, 5b). In their epididymides, atrophy was found in all of the animals and cell debris in the epididymal lumen was also found (Photos 6a, 6b).

Effects of the lower doses of DEHP on testicular development were examined in Experiment 2. Table 6 summarizes histopathological findings of fetal testes on G20 and testes of offspring at 5 and 10 weeks of age in Experiment 2. Multinucleated germ cells were found in the fetal testes of all the groups exposed to DEHP, although its incidence was very low in the 125 mg/kg group. In the groups exposed to 250 mg/kg and 500 mg/kg of DEHP, partly thickened germinal cords due to aggregation of increased number of germ cells and hyperplasia of the interstitial cells were observed. Degenerated germ cells and apoptosis were observed in a few animals in the group exposed to 500 mg/kg of DEHP. These findings are comparable to those in DEHP-exposed testes at the same dose in Experiment 1.

In contrast to the findings of the fetal testes, no abnormalities were found in testes of the offspring at 5 and 10 weeks of age in any group in histopathological examination. Furthermore, the seminiferous cycles in the testis determined at 5 weeks of age were compara-

ble between control and DEHP-exposed groups (Table 7).

Electron microscopic findings of fetuses

Electron microscopic examination of fetal testes was performed in Experiment 1. In the fetal testis of the groups exposed to DEHP at 500 and 1000 mg/kg, degenerated germ cells were found in the testicular cord on G16 (Photo 7), and smaller-sized interstitial cells containing fewer lipid droplets were noted on G18 (Photo 8a). These changes of the interstitial cells became more obvious on G20 (Photo 8b).

In the fetal testis from the group exposed to EE at 0.5 mg/kg, degeneration of germ cells was found only on G14. No abnormalities such as those observed with DEHP treatment were found on G16, 18 and 20. Slightly swollen mitochondria and hyperplastic smooth endoplasmic reticulum were noted in interstitial cells on G18 and 20. Furthermore, degeneration of interstitial cells surrounded by neutrophils infiltration were observed on G20.

In examination of offspring at 5 and 10 weeks after birth in Experiment 2, ultrastructural changes were not observed in the testis and epididymides of any

Table 5. Histopathological findings in the testis and epididymis of offspring exposed to DEHP during gestational days 7-18 (Experiment 1) 7 weeks after birth.

Group	DEHP 500 mg/kg (6)					DEHP 1000 mg/kg (12)					
	Grade	-	±	+	++	+++	-	±	+	++	+++
Testis											
Atrophy of seminiferous tubules	6	0	0	0	0	2	2	4	3	1	
Multinucleated giant cells	5	1	0	0	0	0	3	5	4	0	
Dilatation of seminiferous tubules	6	0	0	0	0	2	0	4	6	0	
Dilatation of rete testis	6	0	0	0	0	8	2	1	1	0	
Hyperplasia of interstitial cells	6	0	0	0	0	10	1	1	0	0	
Necrosis	6	0	0	0	0	11	0	0	0	1	
Mineralization	6	0	0	0	0	10	0	1	1	0	
Foreign body giant cells	6	0	0	0	0	10	0	1	1	0	
Focal loss of seminiferous tubules	6	0	0	0	0	11	0	1	0	0	
Malformation of seminiferous tubules	6	0	0	0	0	11	0	1	0	0	
Epididymis											
Atrophy	6	0	0	0	0	0	1	2	2	7	
Cell debris in lumens	0	0	6	0	0	3	3	6	0	0	
Dilatation of lumens	6	0	0	0	0	8	0	3	1	0	
Infiltration of lymphocytes	6	0	0	0	0	8	2	2	0	0	
Granuloma	6	0	0	0	0	11	0	0	1	0	

Figures in parentheses indicate number of offspring examined.

- : not observed, ± : very slight, + : slight, ++ : moderate, +++ : severe.

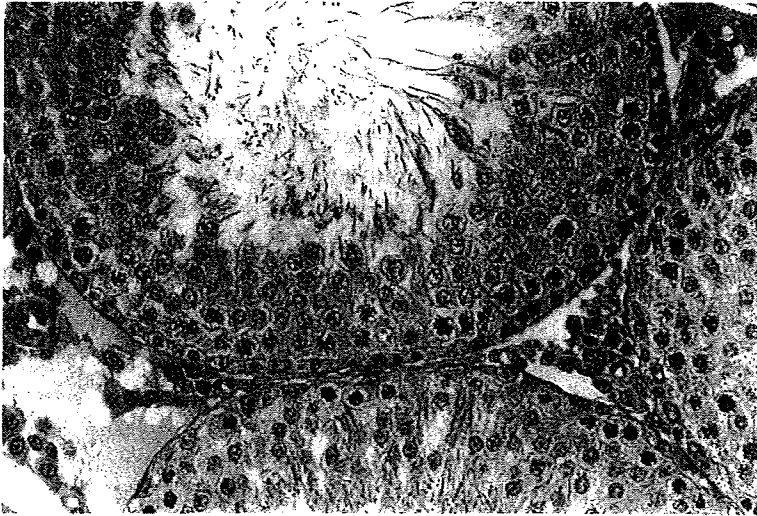


Photo 4-a. Testis of a 7-week-old rat treated with 500 mg/kg of DEHP *in utero* showing no abnormalities in the seminiferous tubules and interstitial cells. HE stain, $\times 310$.

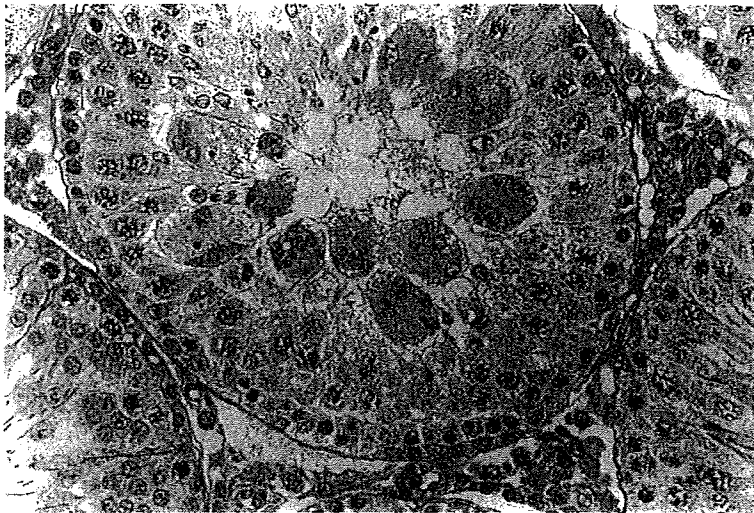


Photo 4-b. Testis of a rat of the same group as Photo 4-a, showing multinucleated giant cells in a seminiferous tubule. HE stain, $\times 310$.

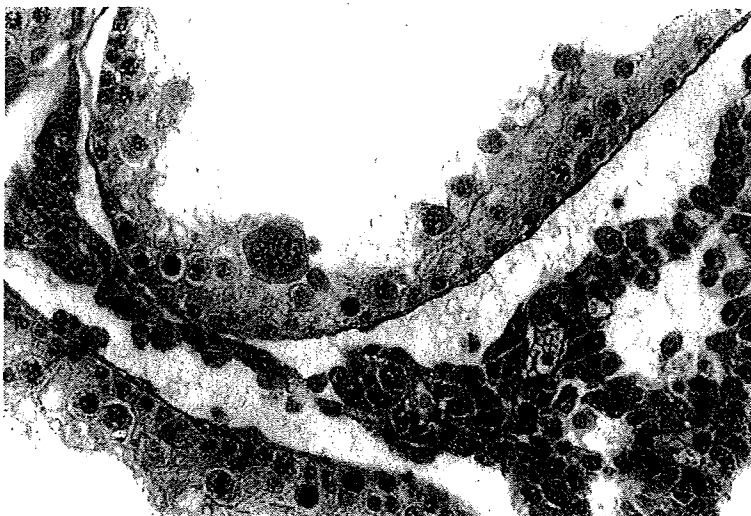


Photo 4-c. Testis of a 7-week-old rat treated with 1000 mg/kg of DEHP *in utero*, showing atrophy of seminiferous tubule epithelia with multinucleated giant cell in the lumen, and also hyperplasia of interstitial cells. HE stain, $\times 310$.

DEHP on rat testicular development.

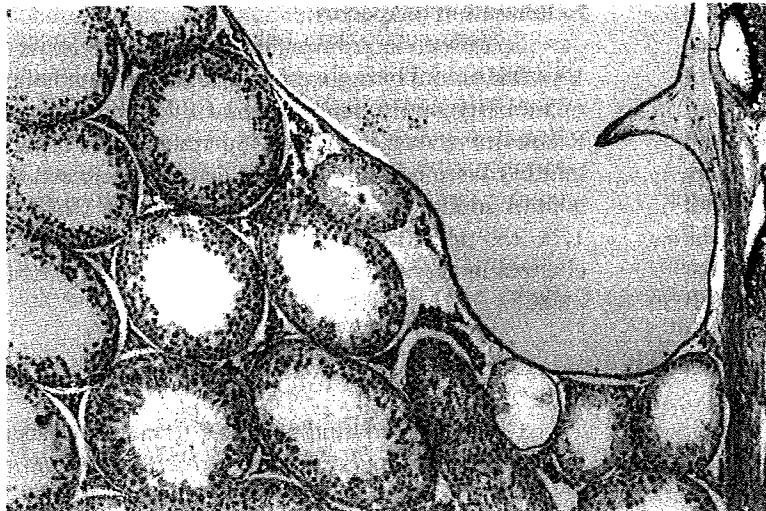


Photo 5-a. Testis of a 7-week-old rat treated with 1000 mg/kg of DEHP *in utero*, showing dilatation of seminiferous tubules and of rete testis. HE stain, $\times 80$.

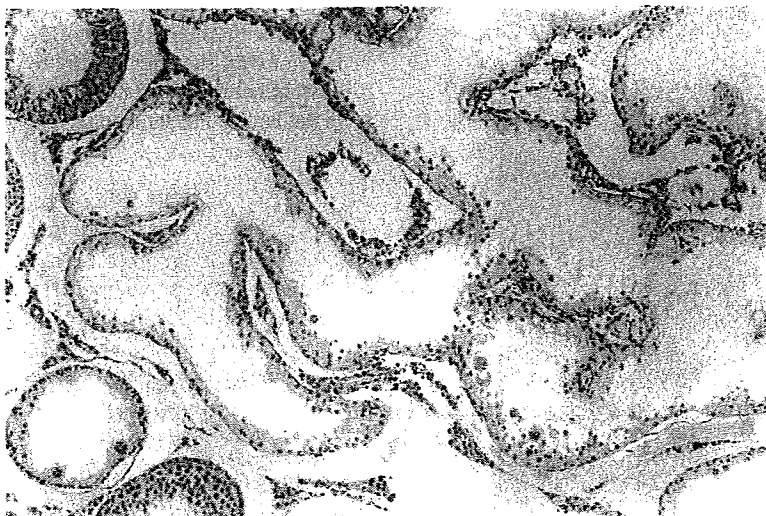


Photo 5-b. Testis from a 7-week-old rat treated with 1000 mg/kg of DEHP *in utero*, showing branching of atrophic seminiferous tubules. HE stain, $\times 80$.

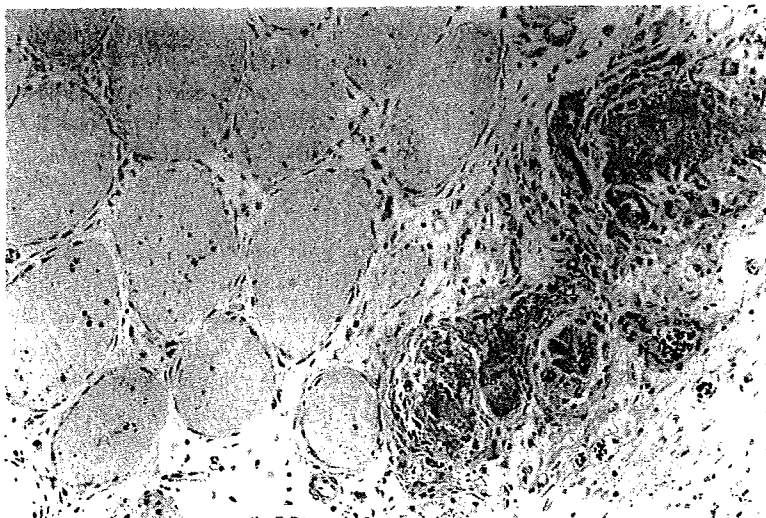


Photo 5-c. Testis of a 7-week-old rat treated with 1000 mg/kg of DEHP *in utero*, showing extensive necrosis and foreign body giant cells. HE stain, $\times 160$.