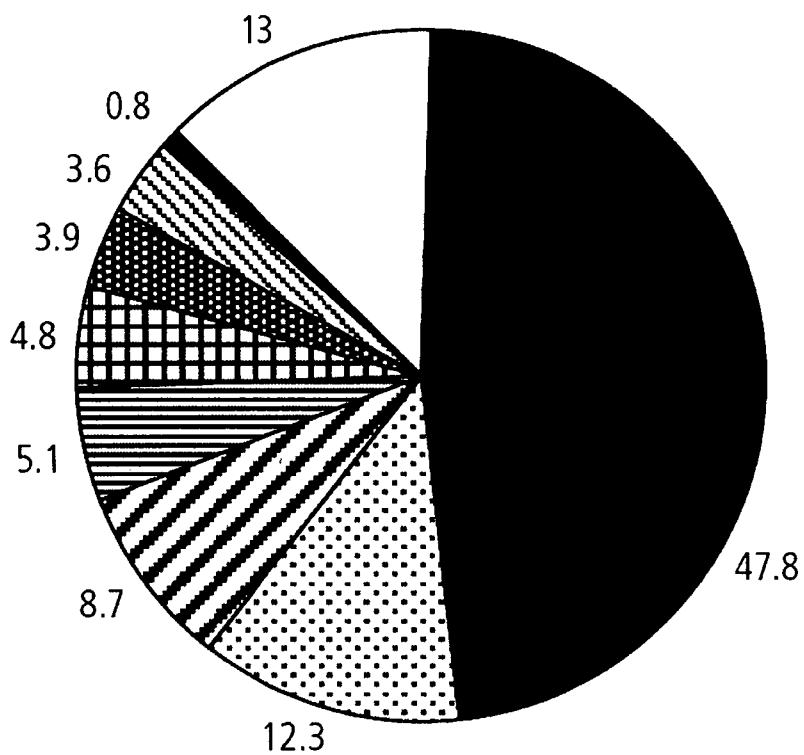


Figure 1. Global causes of blindness as a proportion of total blindness in the year 2002

(WHO).



- Cataract
- Childhood blindness
- Glaucoma
- AMD^a
- Onchocerciasis
- Corneal opacities
- Diabetic retinopathy
- Trachoma
- Others

^aAMD = Age-related macular degeneration.

Figure 2. Schematic diagram of the human eye.

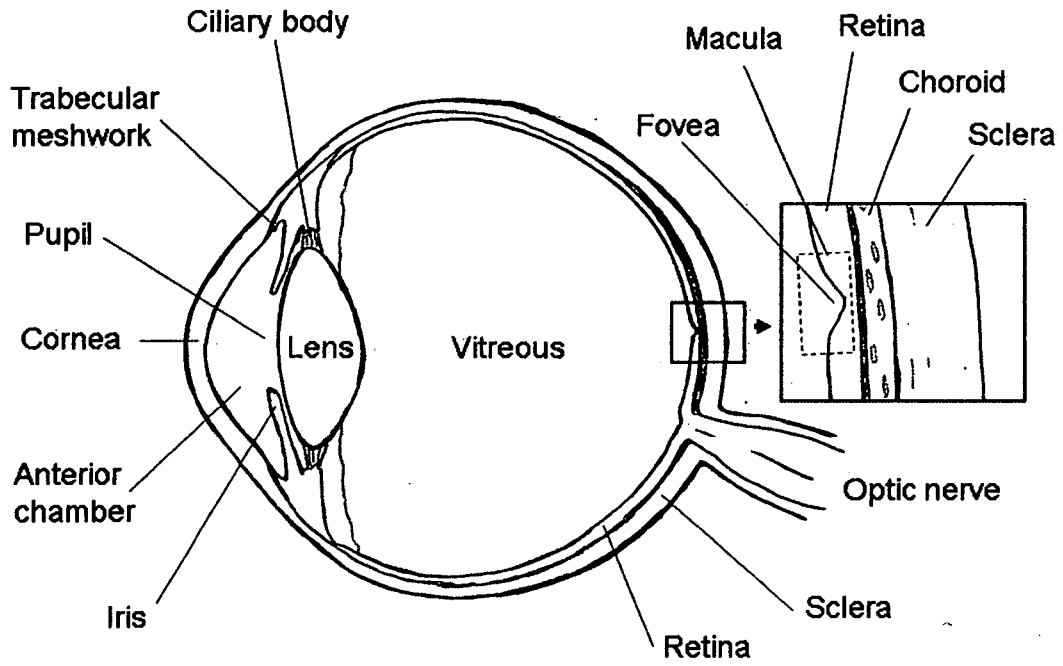


Figure 3. Fundus photograph of a normal human retina showing the location of the macula and the fovea.

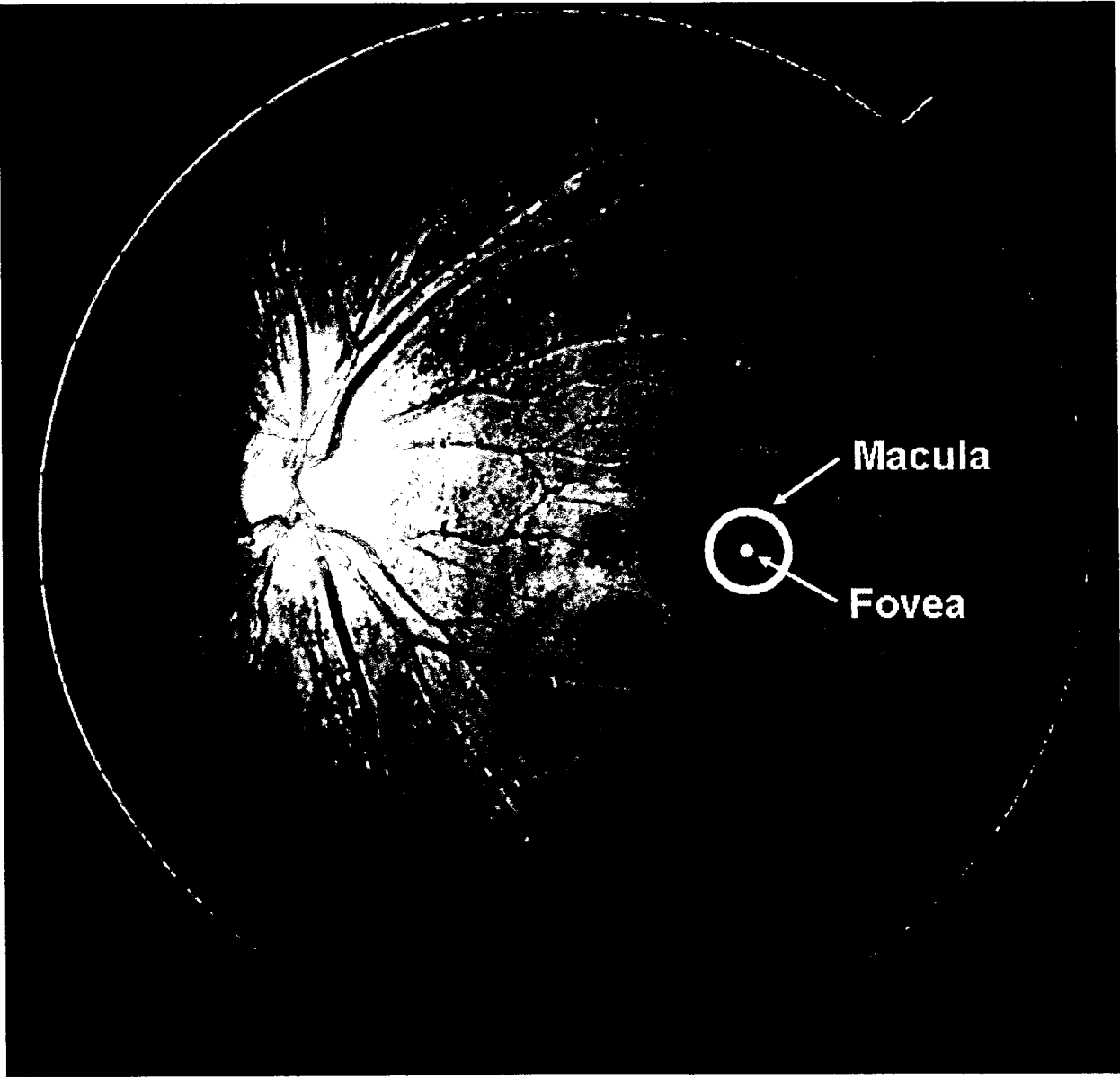


Figure 4. Retinal histological section showing the accumulation of drusen between the retinal pigment epithelium and Bruch's membrane in a primate model of AMD.

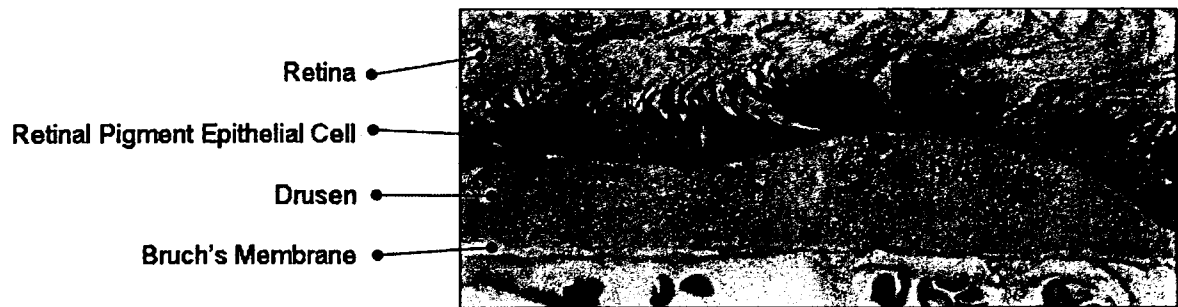


Figure 5. Photographs of the fundus of two monkeys with AMD in the Tsukuba Primate Research Center showing drusen.

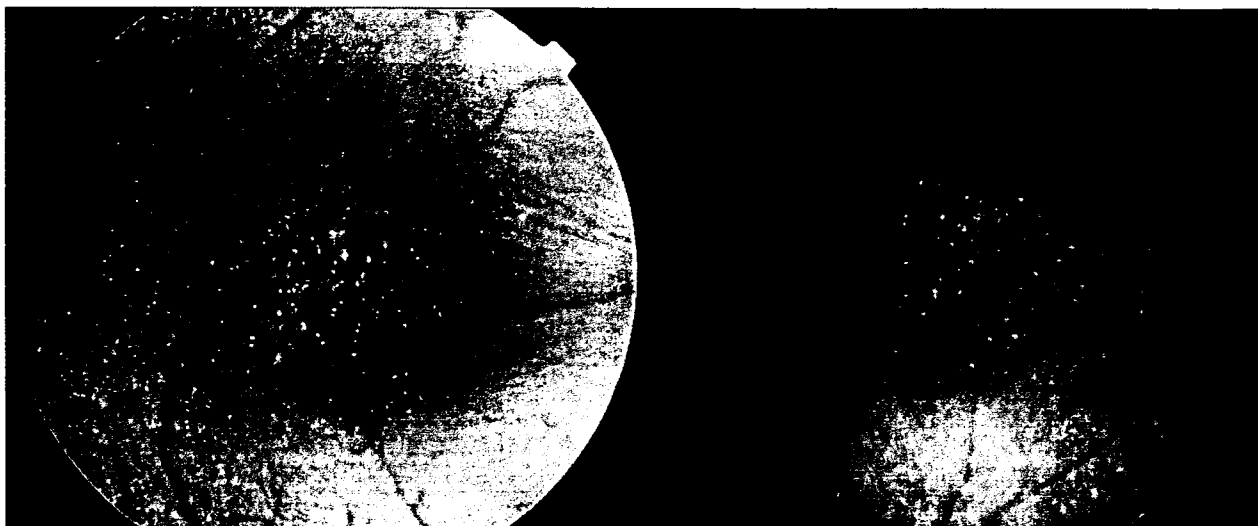
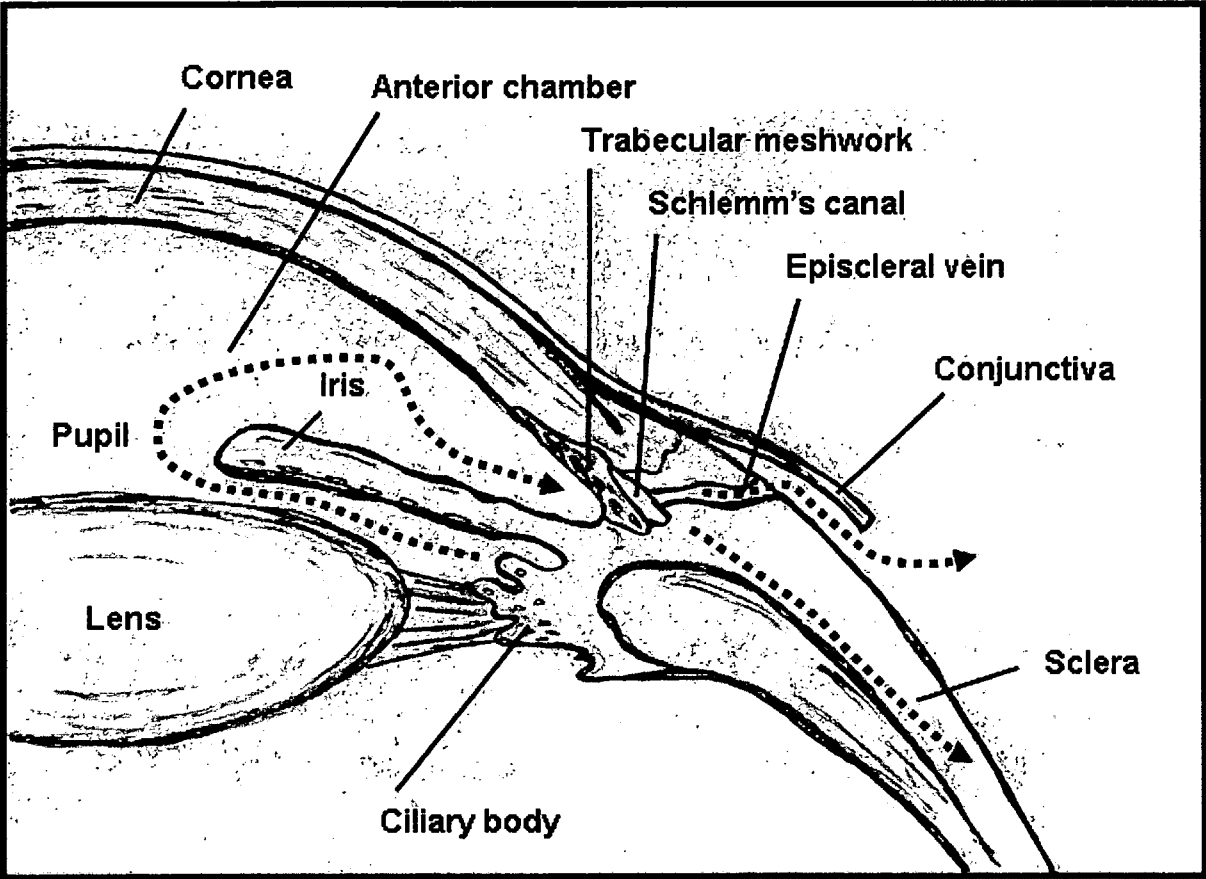


Figure 6. Schematic diagram of the anterior segment of the eye showing the trabecular meshwork and uveoscleral outflow pathways of aqueous humor.



References

- (1) Heiba IM, Elston RC, Klein BE, Klein R. Sibling correlations and segregation analysis of age-related maculopathy: The Beaver Dam Eye Study. *Genet Epidemiol* 1994;11:51-67.
- (2) Seddon JM, Ajani UA, Mitchell BD. Familial aggregation of age-related maculopathy. *Am J Ophthalmology* 1997;123:199-206.
- (3) Hammond CJ, Webster AR, Snieder H, Bird AC, Gilbert CE, Spector TD. Genetic influence on early age-related maculopathy: A twin study. *Ophthalmology* 2002;109:730-736.
- (4) Iyengar SK, Song D, Klein BE, Klein R, Schick JH, Humphrey J, Millard C,

Liptak R, Russo K, Jun G, Lee KE, Fijal B, Elston RC. Dissection of genomewide-scan data in extended families reveals a major locus and oligogenic susceptibility for age-related macular degeneration. *Am J Hum Genet* 2004;74:20-39.

(5) Schick JH, Iyengar SK, Klein BE, Klein R, Reading K, Liptak R, Millard C, Lee KE, Tomany SC, Moore EL, Fijal BA, Elston RC. A whole-genome screen of a quantitative trait of age-related maculopathy in sibships from the Beaver Dam Eye Study. *Am J Hum Genet* 2003;72:1412-24.

(6) Majewski J, Schultz DW, Weleber RG, Schain MB, Edwards AO, Matise TC, Acott TS, Ott J, Klein ML. Age-related macular degeneration--a genome scan in extended families. *Am J Hum Genet* 2003;73:540-50.

(7) Klein RJ, Zeiss C, Chew EY, Tsai JY, Sackler RS, Haynes C, Henning AK, SanGiovanni JP, Mane SM, Mayne ST, Bracken MB, Ferris FL, Ott J, Barnstable C, Hoh J. Complement factor H polymorphism in age-related macular degeneration.

Science 2005;308:385-389.

(8) Edwards AO, Ritter R 3rd, Abel KJ, Manning A, Panhuysen C, Farrer LA.

Complement factor H polymorphism and age-related macular degeneration.

Science 2005;308:421-424.

(9) Haines JL, Hauser MA, Schmidt S, Scott WK, Olson LM, Gallins P, Spencer KL,

Kwan SY, Nouredine M, Gilbert JR, Schnetz-Boutaud N, Agarwal A, Postel EA,

Pericak-Vance MA. Complement factor H variant increases the risk of age-related

macular degeneration. Science 2005;308:419-421.

(10) Hageman GS, Anderson DH, Johnson LV, Hancox LS, Taiber AJ, Hardisty LI,

Hageman JL, Stockman HA, Borchardt JD, Gehrs KM, Smith RJ, Silvestri G, Russell

SR, Klaver CC, Barbazetto I, Chang S, Yannuzzi LA, Barile GR, Merriam JC, Smith

RT, Olsh AK, Bergeron J, Zernant J, Merriam JE, Gold B, Dean M, Allikmets R.

A common haplotype in the complement regulatory gene factor H (HF1/CFH)

predisposes individuals to age-related macular degeneration. Proc Natl Acad Sci U S A
2005;102:7227-7232.

(11) Okamoto H, Umeda S, Obazawa M, Minami M, Noda T, Mizota A, Honda M,
Tanaka

M, Koyama R, Takagi I, Sakamoto Y, Saito Y, Miyake Y, Iwata T. Complement factor H
polymorphisms in Japanese population with age-related macular degeneration.
Mol Vis 2006;12:156-158.

(12) Gotoh N, Yamada R, Hiratani H, Renault V, Kuroiwa S, Monet M, Toyoda S,
Chida S, Mandai M, Otani A, Yoshimura N, Matsuda F. No association between
complement factor H gene polymorphism and exudative age-related macular
degeneration in Japanese. Hum Genet 2006;120:139-143.

(13) Gold B, Merriam JE, Zernant J, Hancox LS, Taiber AJ, Gehrs K, Cramer K, Neel
J, Bergeron J, Barile GR, Smith RT; AMD Genetics Clinical Study Group; Hageman

GS, Dean M, Allikmets R. Variation in factor B (BF) and complement component 2 (C2) genes is associated with age-related macular degeneration. Nat Genet 2006;38:458-462.

(14) Russell SR, Mullins RF, Schneider BL, Hageman GS. Location, substructure, and composition of basal laminar drusen compared with drusen associated with aging and age-related macular degeneration. Am J Ophthalmol 2000;129:205-214.

(15) Mullins RF, Russell SR, Anderson DH, Hageman GS. Drusen associated with aging and age-related macular degeneration contain proteins common to extracellular deposits associated with atherosclerosis, elastosis, amyloidosis, and dense deposit disease. FASEB J 2000;14:835-846.

(16) Chader GJ. Animal models in research on retinal degenerations: Past progress and future hope. Vision Res 2002;42:393-399.

(17) Stafford TJ, Anness SH, Fine BS. Spontaneous degenerative maculopathy in the monkey. *Ophthalmology* 1984;91:513-521.

(18) El-Mofty A, Gouras P, Eisner G, Balazs EA. Macular degeneration in rhesus monkey (*Macaca mulatta*). *Exp Eye Res* 1978;27:499-502.

(19) Nicolas MG, Fujiki K, Murayama K, Suzuki MT, Mineki R, Hayakawa M, Yoshikawa Y, Cho F, Kanai A. Studies on the mechanism of early onset macular degeneration in cynomolgus (*Macaca fascicularis*) monkeys. I. Abnormal concentrations of two proteins in the retina. *Exp Eye Res* 1996;62:211-219.

(20) Nicolas MG, Fujiki K, Murayama K, Suzuki MT, Shindo N, Hotta Y, Iwata F, Fujimura T, Yoshikawa Y, Cho F, Kanai A. Studies on the mechanism of early onset macular degeneration in cynomolgus monkeys. II. Suppression of metallothionein synthesis in the retina in oxidative stress. *Exp Eye Res* 1996;62:399-408.

(21) Suzuki MT, Terao K, Yoshikawa Y. Familial early onset macular degeneration in cynomolgus monkeys (*Macaca fascicularis*). *Primates* 2003;44:291-294.

(22) Umeda S, Ayyagari R, Allikmets R, Suzuki MT, Karoukis AJ, Ambasudhan R, Zernant J, Okamoto H, Ono F, Terao K, Mizota A, Yoshikawa Y, Tanaka Y, Iwata T. Early-onset macular degeneration with drusen in a cynomolgus monkey (*Macaca fascicularis*) pedigree: exclusion of 13 candidate genes and loci. *Invest Ophthalmol Vis Sci* 2005;46:683-691.

(23) Umeda S, Suzuki MT, Okamoto H, Ono F, Mizota A, Terao K, Yoshikawa Y, Tanaka Y, Iwata T. Molecular composition of drusen and possible involvement of anti-retinal autoimmunity in two different forms of macular degeneration in cynomolgus monkey (*Macaca fascicularis*). *FASEB J* 2005;19:1683-1685.

(24) Ambati J, Anand A, Fernandez S, Sakurai E, Lynn BC, Kuziel WA, Rollins BJ,

Ambati BK. An animal model of age-related macular degeneration in senescent Ccl-2- or Ccr-2-deficient mice. *Nat Med* 2003;9:1390-1397.

(25) Malek G, Johnson LV, Mace BE, Saloupis P, Schmechel DE, Rickman DW, Toth CA, Sullivan PM, Bowes Rickman C. Apolipoprotein E allele-dependent pathogenesis: a model for age-related retinal degeneration. *Proc Natl Acad Sci U S A.* 2005;102:11900-11905.

(26) Imamura Y, Noda S, Hashizume K, Shinoda K, Yamaguchi M, Uchiyama S, Shimizu T, Mizushima Y, Shirasawa T, Tsubota K. Drusen, choroidal neovascularization, and retinal pigment epithelium dysfunction in SOD1-deficient mice: a model of age-related macular degeneration. *Proc Natl Acad Sci U S A* 2006;103:11282-11287.

(27) Nozaki M, Raisler BJ, Sakurai E, Sarma JV, Barnum SR, Lambris JD, Chen Y,

Zhang K, Ambati BK, Baffi JZ, Ambati J. Drusen complement components C3a and C5a promote choroidal neovascularization. *Proc Natl Acad Sci U S A* 2006;103:2328-2333.

(28) Quigley HA, Broman AT. The number of people with glaucoma worldwide in 2010 and 2020. *Br J Ophthalmol* 2006;90:262-267.

(29) Gaasterland D, Kupfer C. Experimental glaucoma in the rhesus monkey. *Invest Ophthalmol Vis Sci* 1974;13:455-457.

(30) Quigley HA, Hohman RM. Laser energy levels for trabecular meshwork damage in the primate eye. *Invest Ophthalmol Vis Sci* 1983;24:1305-1307.

(31) Quigley HA, Addicks EM. Chronic experimental glaucoma in primates. I. Production of elevated intraocular pressure by anterior chamber injection of autologous ghost red blood cells. *Invest Ophthalmol Vis Sci* 1980;19:126-136.

(32) Weber AJ, Zelenak D. Experimental glaucoma in the primate induced by latex microspheres. *J Neurosci Methods* 2001;111:39-48.

(33) Kaufman PL, Lutjen-Drecoll E, Hubbard WC, Erickson KA. Obstruction of aqueous humor outflow by cross-linked polyacrylamide microgels in bovine, monkey, and human eyes. *Ophthalmology* 1994;101:1672-1679.

(34) Zimmerman LE, De Venecia G, Hamasaki DI. Pathology of the optic nerve in experimental acute glaucoma. *Invest Ophthalmol* 1967;6:109-125.

(35) Amfrmary MF. Aqueous outflow facility in monkeys and the effect of topical corticoids. *Invest Ophthalmol* 1964;3:534-538.

(36) Rasmussen CA, Kaufman PL. Primate glaucoma models. *J Glaucoma* 2005;14:311-314.

(37) Quigley HA, Nickells RW, Kerrigan LA, Pease ME, Thibault DJ, Zack DJ. Retinal ganglion cell death in experimental glaucoma and after axotomy occurs by apoptosis.

Invest Ophthalmol Vis Sci 1995;36:774-786.

(38) Miyahara T, Kikuchi T, Akimoto M, Kurokawa T, Shibuki H, Yoshimura N. Gene microarray analysis of experimental glaucomatous retina from cynomologous monkey.

Invest Ophthalmol Vis Sci 2003;44:4347-4356.

(39) Moore CG, Milne ST, Morrison JC. Noninvasive measurement of rat intraocular pressure with the Tono-Pen. Invest Ophthalmol Vis Sci 1993;34:363-369.

(40) Morrison JC, Moore CG, Deppmeier LM, Gold BG, Meshul CK, Johnson EC. A rat model of chronic pressure-induced optic nerve damage. Exp Eye Res 1997;64:85-96.

(41) Ueda J, Sawaguchi S, Hanyu T, Yaoeda K, Fukuchi T, Abe H et al. Experimental

glaucoma model in the rat induced by laser trabecular photocoagulation after an intracameral injection of India ink. *Japan J Ophthalmol* 1998;42:337-344.

(42) Levkovitch-Verbin H, Quigley HA, Martin KR, Valenta D, Baumrind LA, Pease ME.

Translimbal laser photocoagulation to the trabecular meshwork as a model of glaucoma in rats. *Invest Ophthalmol Vis Sci* 2002;43:402-410.

(43) Shareef SR, Garcia-Valenzuela E, Salierno A, Walsh J, Sharma SC. Chronic ocular hypertension following episcleral venous occlusion in rats [letter]. *Exp Eye Res* 1995;61:379-382.

(44) Garcia-Valenzuela E, Shareef S, Walsh J, Sharma SC. Programmed cell death of retinal ganglion cells during experimental glaucoma. *Exp Eye Res* 1995;61:33-44.

(45) Johnson EC, Morrison JC, Farrell S, Deppmeier L, Moore CG, McGinty MR. The effect of chronically elevated intraocular pressure on the rat optic nerve head

extracellular matrix. *Exp Eye Res* 1996;62:663-674.

(46) Bayer AU, Danias J, Brodie S, Maag KP, Chen B, Shen F et al. Electroretinographic abnormalities in a rat glaucoma model with chronic elevated intraocular pressure. *Exp Eye Res* 2001;72:667-677.

(47) McKinnon SJ, Lehman DM, Tahzib NG, Ransom NL, Reitsamer HA, Liston P et al. Baculoviral IAP repeat-containing-4 protects optic nerve axons in a rat glaucoma model. *Mol Ther* 2002;5:780-787.

(48) Ahmed F, Brown KM, Stephan DA, Morrison JC, Johnson EC, Tomarev SI. Microarray analysis of changes in mRNA levels in the rat retina after experimental elevation of intraocular pressure. *Invest Ophthalmol Vis Sci* 2004;45:1247-1258.

(49) Thanos S, Naskar R. Correlation between retinal ganglion cell death and chronically developing inherited glaucoma in a new rat mutant. *Exp Eye Res*

2004;79:119-129.

(50) May CA, Lutjen-Drecoll E. Morphology of the murine optic nerve. Invest Ophthalmol

Vis Sci 2002;43:2206-2212.

(51) Savinova OV, Sugiyama F, Martin JE, Tomarev SI, Paigen BJ, Smith RS et al.

Intraocular pressure in genetically distinct mice: an update and strain survey. BMC

Genet 2001;2:12.

(52) Senatorov VV, Malyukova I, Fariss R, Wawrousek E, Swaminathan S, Sharan SK,

Tomarev S. Expression of mutated mouse myocilin induces open-angle glaucoma in

transgenic mice. J. Neurosci. 2006, in press.

(53) Mabuchi F, Lindsey JD, Aihara M, Mackey MR, Weinreb RN. Optic nerve damage