

**Abstract**

*Objective:* To describe the clinical features of Creutzfeldt-Jakob disease with a substitution of arginine for methionine (M232R substitution) at codon 232 (CJD232) of the prion protein gene (PRNP). *Patients and methods:* We evaluated the clinical and laboratory features of 20 CJD232 patients: age of onset, initial symptoms, duration until becoming akinetic and mute, duration until occurrence of periodic sharp and wave complexes on EEG (PSWC), MRI findings, and the presence of CSF 14-3-3 protein. Immunohistochemically, prion protein (PrP) deposition was studied. *Results:* None of the patients had a family history of CJD. We recognized two clinical phenotypes: a rapidly progressive type (rapid-type) and a slowly progressive type (slow-type). Out of 20 patients, 15 became akinetic and mute, demonstrated myoclonus, and showed PSWC within a mean duration of 3.1, 2.4, and 2.8 months, respectively (rapid-type). Five showed slowly progressive clinical courses (slow-type). Five became akinetic and mute and four demonstrated myoclonus within a mean duration of 20.6 and 15.3 months, respectively, which were significantly longer than those in the rapid-type. Only one demonstrated PSWC 13 months after the onset. Diffuse synaptic-type deposition was demonstrated in four rapid-type patients, and perivacuolar and diffuse synaptic-type deposition in two, and diffuse synaptic-type deposition in one slow-type patient. Three of 50 suspected but non-CJD patients had the M232R substitution. *Conclusions:* Patients with CJD232 had no family history like patients with sCJD, and showed two different clinical phenotypes in spite of having the same PRNP genotype. More studies are needed to determine whether M232R substitution causes the disease and influences the disease progression.

## Introduction

Human prion diseases are divided into three types: sporadic, genetic, and infectious prion disease. Genetic prion disease, which is defined as prion disease with causative abnormalities of the prion protein gene (PRNP), accounts for approximately 10 to 15% of all prion disease cases, and includes genetic Creutzfeldt-jakob disease (gCJD), Gerstmann-Sträussler-Scheinker disease (GSS), and fatal familial insomnia (FFI).<sup>1</sup> In general, the clinical features of gCJD are more various compared with those of sporadic CJD (sCJD) and are regulated by the genotype.<sup>2</sup> Therefore, gCJD, even if its clinical features are quite different from those of sCJD, especially those of the most often encountered type of sCJD with methionine homozygosity at codon 129 of PRNP and type 1 protease-resistant prion protein (MM1),<sup>3</sup> can be diagnosed by examining the genotype. To clarify the clinical features of CJD, which associates with a substitution in PRNP, will provide an important clue that can lead to genetic examination.

To date, more than 30 causative mutations have been recognized and individual PRNP mutations show variable geographical distribution and frequency. The cardinal characteristic of gCJD is that more than half of the patients lack family history.

CJD patients associated with a substitution of arginine for methionine at codon 232 (M232R substitution) in PRNP with no relevant family history have been reported in Japan.<sup>4-10</sup> Previously, the clinical features of CJD with the M232R substitution (CJD232) were thought to be similar to those of typical sCJD with MM1,<sup>3</sup> which accounts for the vast majority of sCJD in terms of clinical features, including EEG findings.<sup>5,6,9</sup> However, cases of CJD232 that showed a longer clinical course and lacked the characteristic periodic sharp and wave complexes (PSWC) have been reported.<sup>7,8</sup> We have experienced eight cases of CJD232. Five of them showed a rapid clinical course and typical CJD features, while the others showed very slow progression and atypical features. We studied the clinical features of 20 CJD232 patients, including our original patients, and found that there were two different major clinical phenotypes with the same genotype, including polymorphisms at codons 129 and 219 of PRNP; one progressed rapidly, and the other progressed slowly. Better understanding of the clinical features of CJD232 would contribute to the diagnosis of CJD232, especially in patients with atypical clinical features.

## Patients and Methods

Twenty-four patients with CJD232 were included in this study: eight were our original ones, seven were obtained by reviewing the literature<sup>5-10</sup> and nine were found by reviewing the clinical records of CJD patients reported to the Creutzfeldt-Jakob Disease Surveillance Committee, Japan. We excluded two patients because they had double point mutations at codon 180 and at codon 232<sup>10</sup> and one patient because her polymorphism at codons 129 and 219 of PRNP was uncertain.<sup>5</sup> Therefore, 21 patients were enrolled in this study. The nine who were proven at autopsy are indicated by asterisks in Figure 1.

We first evaluated the duration from onset until the patients manifested akinetic mutism. As shown in Figure 1, 15 became akinetic and mute within six months, while five did not become so until 15 months after the onset. These CJD232 patients appeared to be comprised of two different groups: one was a rapidly progressive type (rapid-type) and the other was a slowly progressive type (slow-type). We evaluated the age of onset, initial symptoms, duration from onset to the appearance of myoclonus, duration from onset to akinetic mutism, duration from onset to occurrence of PSWC, results of MRI, and the presence of 14-3-3 protein in the CSF of the two types. The patient marked by a question mark in Figure 1 was excluded from the evaluation. We were unable to determine which group this 50-year-old man belonged to because he had not become akinetic and mute and was still able to converse with simple words seven months after the onset when he suddenly died due to a myocardial incident.<sup>8</sup> Thus, the clinical data of 20 patients were finally used for this study.

In one of the rapid-type patients and in three of the slow-type patients including a previously reported 64-year-old woman,<sup>7</sup> immunohistochemical staining of PrP using monoclonal antibody 3F4 (Prionics, Schlieren, Switzerland) was performed. Including the previously reported pathological findings of three patients belonging to the rapid-type,<sup>6</sup> immunohistochemical staining of PrP in both groups were studied. In each group, the molecular type of the abnormal isoform of prion protein (PrP<sup>Sc</sup>) was studied.

The Mann-Whitney U test was used for statistical comparison of the age of onset and the duration until the appearance of myoclonus and akinetic mutism from the onset between the rapid-type and the slow-type. The Grubbs-Smirnov critical test was used for statistical analysis of the duration until the appearance of PSWC from the onset between the rapid-type and the slow-type. Fisher's exact probability test was used for comparison of the male to female ratio, and the rates of myoclonus, akinetic mutism, and PSWC between the two types.

It was also used for comparison of the positive rate of 14-3-3 immunoassay and MRI between the two types.

## RESULTS

Reviewing the clinical records of the enrolled patients, we found that no patients of either group had a family history of prion disease or dementia.

Fifteen patients, eight men and seven women, with a mean onset age of  $65.4 \pm 5.2$  (Mean  $\pm$  SD) years could be categorized as the rapid-type. Of those, seven with an initial symptom of progressive dementia or memory disturbance, two with visual symptoms, two with cerebellar ataxia, two with involuntary movement, and two with other symptoms. All except for one uncertain patient demonstrated myoclonus  $2.4 \pm 1.8$  months after the onset. All became akinetic and mute within a mean duration of  $3.1 \pm 1.5$  months, and demonstrated PSWC (Fig. 2A and 2B) within a mean duration of  $2.8 \pm 1.8$  months. CJD-related high intensity lesions<sup>11</sup> were detected in eight of the nine patients examined by MRI. Similar to sCJD, three patterns existed: in one, high intensity lesions appeared mainly in the striatum (Fig. 3A); in another, they appeared in the striatum and the cortical ribbon equally (Fig. 3B); and in yet another, they appeared mainly in the cortical ribbon (Fig. 3C). The 14-3-3 protein assay was positive in all of the eight patients examined. All 15 patients showed MM129, 14 showed glutamic acid homozygosity at codon 219 (GG219) and one showed glutaminic acid/lysine heterozygosity at codon 219 in the PRNP analysis. These clinical features closely resembled typical sCJD with MM1.<sup>3</sup> Immunohistochemical staining of PrP in four patients (one original patient and three previously reported patients<sup>6</sup>) revealed a diffuse synaptic-type deposit (Fig. 4A). The molecular type of PrP<sup>Sc</sup> in one patient was type 1.

Five patients, two men and three women, with a mean onset age of  $59.0 \pm 12.8$  years could be categorized as the slow-type. Three had an initial symptom of progressive dementia or memory disturbance, one showed psychiatric symptoms, and one had dressing apraxia. Four of five patients demonstrated myoclonus  $15.3 \pm 12.3$  months after the onset, and the remaining one did not demonstrate myoclonus during the 13-month observation period. All became akinetic and mute within a mean duration of  $20.6 \pm 4.4$  months. None except for one demonstrated PSWC within the observation period of  $23.8 \pm 13.7$  months (Fig. 2C and 2D). CJD-related high-intensity lesions<sup>11</sup> were detected in four of the five patients examined by MRI. One showed high-intensity lesions in the cortical ribbon (Fig. 3D and 3E), while in the

others such lesions appeared in both the striatum and cortical ribbon (Fig. 3F). The medial thalami showed high-intensity lesions in all three patients examined by DWI (white arrows in Fig. 3D and 3E, and black arrows in Fig. 3F). The 14-3-3 protein assay was positive in all four patients examined. In the PRNP analysis, all five patients showed MM129 and GG219. Immunohistochemical staining in two patients revealed predominantly perivacuolar-type PrP deposits in the cerebral cortex (Fig. 4B), but also partly the diffuse synaptic-type deposits. In one patient, only the diffuse synaptic-type deposits were revealed. The molecular type of PrP<sup>Sc</sup> in one patient who had predominantly perivacuolar-type PrP deposits was type 1+2.

Between the two groups, there were no differences in the age at onset, male to female ratio, or positive rate of 14-3-3 protein immunoassay. Similar to sCJD, there were three patterns of high-intensity lesions shown by MRI in the rapid-type. We were unable to distinguish the rapid-type of CJD232 from sCJD based on the clinical features including MRI findings. Patients with the slow-type did not have fewer lesions than patients with the rapid-type at diagnosis. High-intensity lesions in the medial thalamus depicted by DWI were a common finding of the slow-type (Fig. 3A – 3F). There was no difference in the rate of myoclonus between the two groups, but the duration until the appearance from the onset was longer in the slow-type compared with the rapid-type ( $p < 0.005$ ). All patients became akinetic and mute in both types, but the duration until becoming akinetic and mute from the onset in the slow-type was longer than that in the rapid-type ( $p < 0.001$ ). Concerning PSWC, all patients in the rapid-type demonstrated PSWC  $2.8 \pm 1.8$  months after the onset. However, in the observation period of  $21.6 \pm 12.8$  months, only one patient with the slow-type demonstrated PSWC 13 months after onset, which was later compared with that of the rapid-type ( $p < 0.01$ ). The rate of PSWC in the slow-type was lower than that in the rapid-type ( $p < 0.01$ ). Since there were no differences in the polymorphisms of codons 129 and 219 between the two groups, such polymorphisms would not be determinants of the disease subtype. Based on the differences in the clinical and laboratory findings (Table), we considered that these two types represented completely different phenotypes of exactly the same genotype.

By reviewing the investigative reports collected by the Creutzfeldt-Jakob Disease Surveillance Committee, Japan, as of February 2006, PRNP information was available from 511 patients: 317 were acknowledged as sporadic CJD, 41 as infectious CJD, 103 as genetic prion disease that included 28 CJD with V180I (CJD180), 27 GSS with P102L, 23 CJD with

E200K, and 13 CJD232, and 50 as non-CJD. Three of the 50 non-CJD patients who had no family history of prion disease had the M232R substitution: one was previously reported, pathologically confirmed dementia with Lewy bodies,<sup>12</sup> one was encephalitis, and one was not diagnosed yet, but was confirmed as not having CJD because his symptoms rather fluctuated. There remains the possibility that the M232R substitution is a rare polymorphism, not a causative point mutation,<sup>6</sup> although the M232R substitution was not found among 100 healthy controls.<sup>4</sup>

## DISCUSSION

In the present study, by reviewing the clinical and laboratory findings of 21 patients, we found that there were two distinct phenotypes in CJD232 in spite of the same genotype of PRNP, M232R, MM129, and GG219. Different phenotypes with the same pathogenic changes of PRNP are known in several types of genetic prion disease.<sup>14-21</sup> Fatal familial insomnia and gCJD with a common point mutation at codon 178 are well-known. However, the different phenotypes are regulated by a polymorphism at codon 129.<sup>14,15</sup> Similarly, a phenotypic variant of gCJD with a point mutation of glutamic acid to lysine at codon 200 (CJD200) is coupled with valine at codon 129.<sup>19</sup> On the other hand, a thalamic variant of CJD200, which has the same polymorphism of MM129 as the vast majority of CJD200, has been reported,<sup>17,21</sup> although it is exceptional. In our results, 15 of the patients were the rapid-type, five were the slow-type. In CJD232, the slow-type, which has uncommon clinical features, is not exceptional and constitutes one of the major phenotypes because 25% of patients with CJD232 belong to the slow-type. Similarly, there are two different major phenotypes that are not influenced by the polymorphism of codon 129 and 219 in Gerstmann-Sträussler-Scherinker disease with a point mutation of proline to leucine at codon 102 of PRNP (GSS102), which is characterized by chronic cerebellar ataxia of long duration (several years or more) associated with neurological signs including dementia.<sup>21</sup> In GSS102, a sCJD-like variant of short duration (less than one year) has been reported.<sup>16</sup> In twenty-seven patients with GSS102 recognized by the Creutzfeldt-Jakob Disease Surveillance Committee, Japan until February 2006, five (18.5%) were this sCJD-like variant. It should be emphasized that CJD232 has two major different phenotypes with the completely same genotype of PRNP that is undoubtedly a major factor which influences the clinical phenotype.<sup>2,22,23,24</sup>

The gender and age at onset influence the disease progression.<sup>25</sup> However, there were no

significant differences in the male to female ratio and age at onset between the two types in our series of CJD232. The molecular type of PrP<sup>Sc</sup> is another factor that is closely associated with the clinical and pathological phenotypes of sCJD.<sup>26</sup> Unfortunately, the molecular type of PrP<sup>Sc</sup> have not been sufficiently examined. One previously reported patient<sup>27</sup> in the rapid-type group had type 1 and one patient in the slow-type group had type 1+2. This difference may be a determinant of the clinical phenotypes of CJD232. More studies are needed to determine the relationship between the clinical phenotype and the molecular type of PrP<sup>Sc</sup>.

Immunohistochemical staining of PrP from four patients with the rapid-type revealed a diffuse synaptic-type deposit similar to that found in sCJD with MM1.<sup>28</sup> The synaptic-type PrP deposit may be an important pathological findings of the rapid-type. If so, we cannot differentiate the rapid-type of CJD232 from sCJD with MM1 based on the pathological findings. PrP immunohistochemical staining of three patients with the slow-type revealed that two had a perivacuolar-type and diffuse synaptic-type PrP deposits and one had only diffuse synaptic-type deposits. These pathological results suggest that the rapid-type might be a homogeneous group and the slow-type might not be. The number of studied patients in the two groups was too small to determine the pattern. If the PrP<sup>Sc</sup> type 1+2 and the perivacuolar-type PrP deposits are key pathological features of the slow-type of CJD232, these may be related to the absence or late occurrence of myoclonus and PSWC on EEG, and the slower progression of the disease.

Diagnosing the rapid-type of CJD232 is not difficult because the patients start with progressing dementia, cerebellar ataxia, and visual problems, rapidly progress to akinetic mutism, demonstrate PSWC, are positive for 14-3-3 protein in the CSF immunoassay, and have characteristic MRI findings. These clinical features including the MRI findings are very similar to those of typical sCJD with MM1<sup>3</sup> that accounts for the vast majority of sCJD. We can easily suspect CJD when we encounter such patients. Genetic examination of PRNP is necessary to differentiate the rapid-type of CJD232 from sCJD with MM1<sup>3</sup> since a patient with CJD232 usually has no family history of prion disease or dementia, and differentiating CJD232 from sCJD with MM1<sup>3</sup> is difficult when based on the clinical and laboratory features alone.

On the other hand, diagnosing the slow-type of CJD232 is not easy because the patients initially manifest non-characteristic dementia or memory disturbance, or psychiatric symptoms as in other neurodegenerative disorders, progress relatively slowly, do not become

akinetic and mute within a year, and do not demonstrate PSWC. When we diagnose the slow-type of CJD232, we cannot rely on PSWC, the presence of which is the most widely accepted diagnostic marker at the present time. In addition to the slow progression, the lack of a family history may cause this disease to be confused with other neurodegenerative disorders such as Alzheimer's disease, dementia with Lewy bodies, corticobasal degeneration, frontotemporal dementia, etc., especially in the early phase. MRI, especially DWI,<sup>11</sup> is very useful to distinguish the slow-type of CJD232 from other neurodegenerative disorders, because the slow-type of CJD232 demonstrates CJD-related high-intensity lesions in DWI, whereas the above-mentioned neurodegenerative disorders do not demonstrate abnormal changes in signal intensities. There has been a report of suspected CJD patients who had M232R and in whom a final pathological diagnosis of dementia with Lewy bodies demonstrated no signal changes in DWI.<sup>12</sup> In our series of three patients with the slow-type examined by DWI, medial thalamic lesions were demonstrated. However, these lesions are not specific for the slow-type of CJD232, and we sometimes encounter them in sCJD.<sup>29</sup> The major differential diagnosis of the slow-type of CJD232 is sCJD with the MM2-cortical type,<sup>3</sup> because the slow-type of CJD232 usually fulfills the previously advocated diagnostic criteria for sCJD with the MM2 cortical type.<sup>30</sup> It is hardly possible clinically to distinguish the slow-type of CJD232 from sCJD with the MM2 cortical type. However, the molecular type of PrP<sup>Sc</sup> in one patient of the slow-type CJD232 was type 1+2, not type 2. The molecular types of PrP<sup>Sc</sup> in each group may be different, although the presence of perivacuolar-type PrP deposits is also a finding of sCJD with the MM2-cortical type.<sup>3</sup> PRNP study is indispensable to distinguish between the two groups and molecular typing may be able to distinguish between them. We did not find any peculiar lesions of the slow-type such as a remarkable high intensity lesion in the cerebral cortex except for those in the medial occipital and cerebellar cortices which are characteristic of fCJD with a point mutation of valine to isoleucine at codon 180 (CJD180), which is an unusual type of fCJD.<sup>13</sup> The degree of the abnormalities in MRI did not correlate with the disease severity. To diagnose the slow type of CJD232, recognizing the clinical phenotype that demonstrates uncommon clinical and laboratory features found in other neurodegenerative disorders with dementia and performing genetic examination of PRNP are important.

Other characteristics of CJD232 are that CJD232 patients have no family history of CJD or dementia in either type and are reported only in Japan. More than half of genetic prion



disease patients with various PRNP mutations lack family histories and the lack of family histories is not restricted to CJD232.<sup>1</sup> De novo mutations<sup>31</sup> and very low penetration<sup>32</sup> are considered as the reasons. Individual PRNP mutations also show variable geographical distributions.<sup>1</sup> The M232R substitution may influence the disease progression because the M232R substitution extended the incubation time in an experimental transmission study using humanized knock-in mice.<sup>33</sup> Three suspected patients with M232R substitution but with a final diagnosis of diseases other than CJD have been reported to the Creutzfeldt-Jakob Disease Surveillance Committee, Japan because they had the M232R substitution, not because they had clinical symptoms suspecting CJD. Therefore, we think that the prevalence of six percents in 50 non-CJD patients is not the same as that of normal Japanese population. At least, it cannot be said that all patients having the M232R substitution demonstrate the symptoms of CJD232, and it does not seem to be supported that M232R substitution is a causative mutation. On the other hand, two probable CJD patients with M232R substitution in one family have been reported.<sup>6</sup> We cannot overlook these patients based on the fact that M232R substitution is very rare.<sup>4</sup> Whether M232R is really a causative mutation or only a rare polymorphism is another issue that needs to be resolved. We need more studies of CJD patients with M232R substitution, and especially the correlation between the pathological findings including the molecular type of PrP<sup>Sc</sup> and immunohistochemical staining of PrP and the clinical findings should be clarified to determine whether it influences the disease progression. We need to study the morbidity of a population having the M232R substitution to determine whether it is a causative mutation or not.

### **Acknowledgement**

We thank Mr. Brent Bell for reading the manuscript. We also wish to thank all the doctors for their care of the patients. This study was based on the fruits of the Creutzfeldt-Jakob Disease Surveillance Committee, Japan and was supported in part by a grant from the Research Committee on Prion Disease and Slow Virus Infection, Ministry of Labor and Health, Japan. Yusei Shiga, Tetsuyuki Kitamoto, Shigetoshi Kuroda, Takeshi Sato, Yoshikazu Nakamura, Masahito Yamada, and Hidehiro Mizusawa are the members of the Creutzfeldt-Jakob disease Surveillance Committee, Japan. The Surveillance study of the Creutzfeldt-Jakob Disease Surveillance Committee, Japan was approved by the ethics committee of Kanazawa University.

## References

1. Kovács GG, Puopolo M, Ladogana A, et al. (2005) Genetic prion disease: the EURO-CJD experience. *Hum Genet* 118: 166-174.
2. Kovács GG, Trabattoni G, Heinfellner JA, Ironside JW, Knight RSG, Budka H. (2002) Mutations of the prion protein gene: Phenotypic spectrum. *J Neurol* 249: 1567-1582.
3. Parchi P, Giese A, Capellari S, et al. (1999) Classification of sporadic Creutzfeldt-Jakob disease based on molecular and phenotypic analysis of 300 subjects. *Ann Neurol* 46: 224-233.
4. Kitamoto T, Ohta M, Doh-ura K, Hitoshi S, Terao Y, Tateishi J. (1993) Novel missense variants of prion protein in Creutzfeldt-Jakob disease or Gerstmann-Sträussler Syndrome. *Biochem Biophys Res Commun* 191: 709-714.
5. Shimizu T, Tanaka K, Tanahashi N, Fukuuchi Y, Kitamoto T. (1994) Creutzfeldt-Jakob disease with a point mutation at codon 232 of prion protein —A case report—. *Clin Neurol* 34: 590-592.
6. Hoque MZ, Kitamoto T, Furukawa H, et al. (1996) Mutation in the prion protein gene at codon 232 in Japanese patients with Creutzfeldt-Jakob disease: a clinicopathological, immunohistochemical and transmission study. *Acta Neuropathol* 92: 441-446.
7. Satoh A, Goto H, Satoh H, et al. (1997) A case of Creutzfeldt-Jakob disease with a point mutation at codon 232: Correlation of MRI and neurological findings. *Neurology* 49: 1469-1470.
8. Saito T, Isozumi K, Komatsumoto S, Nara M, Suzuki K, Doh-ura K. (2000) A case of codon 232 mutation-induced Creutzfeldt-Jakob disease visualized by the MRI-FLAIR images with atypical clinical symptoms. *Clin Neurol* 40: 51-54.
9. Tagawa A, Natsuno T, Suzuki M, Ono S, Shimizu N. (2001) Creutzfeldt-Jakob disease with codon 232 point mutation and showing myoclonus and PSD in the early stage. A case report. *Neurol Med* 54: 161-165.
10. Hitoshi S, Nagura H, Yamanouchi H, Kitamoto T. (1993) Double mutations at codon 180 and codon 232 of the PRNP gene in an apparently sporadic case of Creutzfeldt-Jakob disease. *J Neurol Sci* 120: 208-212.
11. Shiga Y, Miyazawa K, Sato S, et al. (2004) Diffusion-weighted MRI abnormalities as an early diagnostic marker for Creutzfeldt-Jakob disease. *Neurology* 63: 443-449.
12. Koide T, Ohtake H, Nakajima T, et al. (2002) A patient with dementia with Lewy bodies

- and codon 232 mutation of PRNP. *Neurology* 59: 1619-1621.
13. Jin K, Shiga Y, Shibuya S, et al. (2004) Clinical features of Creutzfeldt-Jakob disease with V180I mutation. *Neurology* 62: 502-505.
  14. Goldfarb LG, Peterson RB, Tabaton M, et al. (1992) Fatal familial insomnia and familial Creutzfeldt-Jakob disease: disease phenotype determined by a DNA polymorphism. *Science* 258: 806-808.
  15. Monari L, Chen SG, Brown P, et al. (1994) Fatal familial insomnia and familial Creutzfeldt-Jakob disease: different prion proteins determined by a DNA polymorphism. *Proc Natl Acad Sci* 91: 2839-2842.
  16. Barbanti P, Fabbrini G, Salvatore M, et al. (1996) Polymorphism at codon 129 or 219 of PRNP and clinical heterogeneity in a previously unreported family with Gerstmann-Sträussler-Scherinker disease (PrP-P102L mutation). *Neurology* 47: 734-741.
  17. Chapman J, Arlazoroff A, Goldfarb LG, et al. (1996) Fatal insomnia in a case of familial Creutzfeldt-Jakob disease with the codon 200<sup>Lys</sup> mutation. *Neurology* 46: 758-761.
  18. Young K, Clark HB, Piccardo P, Dlouhy SR, Ghetti B. (1997) Gerstmann-Sträussler-Scherinker disease with the PRNP P102L mutation and valine at codon 129. *Molecular Brain Research* 44: 147-150.
  19. Hainfellner JA, Parchi P, Kitamoto T, Jarius C, Gambetti P, Budka H. (1999) A novel phenotype in familial Creutzfeldt-Jakob disease: Prion protein gene E200K mutation coupled with valine at codon 129 and type 2 protease-resistant prion protein. *Ann Neurol* 45: 812-816.
  20. Yamada M, Itoh Y, Inaba A, et al. (1999) An inherited prion disease with a PrP P105L mutation: Clinicopathologic and PrP heterogeneity. *Neurology* 53: 181-188.
  21. Teratuto AL, Piccardo P, Reich EG, et al. (2002) Insomnia associated with thalamic involvement in E200K Creutzfeldt-Jakob disease. *Neurology* 58: 362-267.
  22. Doh-ura K, Tateishi J, Sasaki H, Kitamoto T, Sasaki Y. (1989) Pro-leu change at position 102 of prion protein is the most common but not the sole mutation related to Gerstmann-Sträussler syndrome. *Biochem Biophys Res Commun* 163: 974-979.
  23. Furukawa H, Kitamoto T, Tanaka Y, Tateishi J. (1995) New variant prion protein in a Japanese family with Gerstmann-Sträussler-Scheinker syndrome. *Brain Res Mol Brain Res* 30; 385-388.

24. Shibuya S, Higuchi J, Shin RW, Tateishi J, Kitamoto T. (1998) Codon 219 Lys allele of PRNP is not found in sporadic Creutzfeldt-Jakob disease. *Ann Neurol* 43: 826-828.
25. Pocchiari M, Puopolo M, Croes EA, et al. (2004) Predictors of survival in sporadic Creutzfeldt-Jakob disease and other human transmissible spongiform encephalopathies. *Brain* 127: 2348-2359.
26. Hill AF, Joiner S, Wadsworth JD, et al. (2003) Molecular classification of sporadic Creutzfeldt-Jakob disease. *Brain* 126: 1333-1346.
27. Satoh K, Muramoto T, Tanaka T, et al. (2003) Association of an 11-12 kDa protease-resistant prion protein fragment with subtypes of dura graft-associated Creutzfeldt-Jakob disease and other prion diseases. *J General Virol* 84: 2885-2893.
28. Kitamoto T, Shin RW, Doh-ura K, et al. (1992) Abnormal isoform of prion proteins accumulates in the synaptic structures of the central nervous system in patients with Creutzfeldt-Jakob disease. *Am J Pathol* 140: 1285-1294.
29. Young GS, Geschwind MD, Fischbein NJ, et al. (2005) Diffusion-weighted and fluid-attenuated inversion recovery imaging in Creutzfeldt-Jakob disease: High sensitivity and specificity for diagnosis. *Am J Neuroradiol* 26: 1551-1562.
30. Hamaguchi T, Kitamoto T, Sato T, et al. (2005) Clinical diagnosis of MM2-type sporadic Creutzfeldt-Jakob disease. *Neurology* 64: 643-648.
31. Dagvadorj A, Peterson RB, Lee HS, et al. (2003) Spontaneous mutations in the prion protein gene causing transmissible spongiform encephalopathy. *Ann Neurol* 52: 355-359.
32. Mitrova E, Belay GI. (2002) Creutzfeldt-Jakob disease with E200K mutation in Slovakia: characterization and development. *Acta Virol* 46: 31-39.
33. Taguchi Y, Mohri S, Ironside JW, Muramoto T, Kitamoto T. (2003) Humanized knock-in mice expressing chimeric prion protein showed varied susceptibility to different human prions. *Am J Pathol* 163: 2585-2593.

**Figure legend****Figure 1. *The duration from the onset to akinetic mutism***

The X-axis shows the duration (months) and the Y-axis shows the accumulative number of patients. Black circles indicate patients who became akinetic and mute; the white circle indicates a patient who had not become akinetic and mute. The white circle with a question mark indicates a 50-year-old-male patient who suddenly died seven months after the onset because of a myocardial incident. Since he had not become akinetic and mute, and was able to converse with simple words, we excluded him from further analyses. Asterisks indicate autopsy proven patients. We recognize two different groups concerning the duration from the onset to akinetic mutism: a rapidly progressive type and a slowly progressive type.

**Figure 2. *EEG of representative patients of the rapid-type group and the slow-type group.***

Figures A and B were recorded from the same 55-year-old woman in the rapid-type group.

Figures C and D were recorded from the same 69-year-old woman in the slow-type group.

A: EEG obtained two and half months after onset demonstrated high amplitude periodic sharp and wave complexes (PSWC) at a frequency of 1.5 Hz characteristic of CJD.

B: EEG obtained five months after the onset demonstrated PSWC at a frequency of 1 Hz. The amplitude was lower than that of Figure 1A, and the background activities were flattened.

EEG rapidly deteriorated.

C: EEG obtained four months after the onset. The background activities were 8 Hz mixed with no apparent slow activities. PSWC was not demonstrated.

D: EEG obtained twelve months after the onset. The background activities were 5 Hz mixed with  $\delta$  activities. However, PSWC was not yet demonstrated.

**Figure 3. *DWI of the rapid-type group (A – C) and the slow-type group (D – F)***

A: DWI obtained from a 55-year-old woman demonstrating high-intensity lesions mainly in the bilateral striatum. The right temporal cortex demonstrated slightly high-intensity lesions.

B: DWI obtained from a 60-year-old woman demonstrating high intensity lesions in the frontal, temporal, occipital and insular cortex, and the striatum. The right side predominated.

C: DWI obtained from a 62-year-old woman demonstrating high-intensity lesions in the bilateral occipital and insular cortex. The right temporal cortex was also depicted as an area of high intensity. We did not find high-intensity lesions in the striatum.

D: DWI obtained from a 69-year-old woman demonstrating high-intensity lesions in the bilateral frontal and insular cortex. The bilateral caudate head showed slightly high-intensity lesions. Interestingly, the bilateral medial thalami showed high-intensity lesions with the so-called hockey stick sign (white arrows).

E: DWI obtained from a 70-year-old man demonstrating high-intensity lesions in the bilateral frontal, occipital, and insular cortex. The right medial thalamus also showed high intensity (white arrow).

F: DWI obtained from a 52-year-old man demonstrating high-intensity lesions in the right temporal cortex and the left striatum. The bilateral medial thalami also showed high intensity lesion (black arrows).

Figure 4. *Immunohistochemical staining of abnormal PrP using monoclonal antibody 3F4*

A: Anti-PrP immunostaining in a 67-year-old woman suffering from the rapid-type of CJD232 with an initial symptom of cerebellar ataxia. The molecular layer of the cerebellum shows a diffuse synaptic-type PrP deposit. Photographed at 200 times magnification.

B: Anti-PrP immunostaining in a 64-year-old woman suffering from the slow-type of CJD 232 with an initial symptom of dressing apraxia. This patient was previously reported by Satoh et al. (1997). The perivacuolar-type PrP deposit is predominantly demonstrated in the temporal cerebral cortex. Photographed at 50 times magnification.

C: Anti-PrP immunostaining in the same patient with Figure 4B. The synaptic-type PrP deposit is demonstrated in the occipital cerebral cortex. Photographed at 50 times magnification.

Table. Comparison of clinical and laboratory features between the rapid-type (R-type) and the slow-type (S-type) of CJD232

Clinical features	R-type (N=15)	S-type (N=5)	p
Age at onset (Year)	65.4 ± 5.2	59.0 ± 12.8	NS
Men : Women	8 : 7	2 : 3	NS
Family history	0/15 positive	0/5 positive	NS
Initial symptoms	7: progressive dementia 2: visual symptoms 2: cerebellar ataxia 2: involuntary movement 2: others	3: progressive dementia 1: psychiatric symptoms 1: dressing apraxia	
Myoclonus (Mo)†	2.4 ± 1.8	15.3 ± 12.3	<0.005
Positive rate	14/14§	4/5*	NS
Akinetic mutism (Mo)†	3.1 ± 1.5	20.6 ± 4.4	<0.001
Positive rate	15/15	5/5	NS
14-3-3 protein	8/8 positive	4/4 positive	NS
PSWC (Mo) †	2.8 ± 1.8	13	<0.01
Positive rate	15/15	1/5**	<0.01
MRI	8/9 positive	4/5 positive	NS
Codon 129	15: Met/Met	5: Met/Met	
Codon 219	14: Glu/Glu 1: Glu/Lys	5: Glu/Glu	
Autopsied cases	5/15	3/5	
PrP immunostaining	Synaptic: 4	Synaptic + Perivacuolar: 2 Synaptic: 1	
PrP type	Type 1: 1	Type 1 + 2: 1	

Values are means ± SD where applicable.

†The duration until the appearance of myoclonus, akinetic mutism, and PSWC from the onset.

§ It was uncertain whether myoclonus had appeared or not in one patient.

\*Mean observation period was 14.8 ± 10.7 months.

\*\* Mean observation period was 21.6 ± 12.8 months.

R-type = the rapid-type of CJD232; S-type = the slow-type of CJD232; PSWC = periodic sharp and wave complexes in EEG; PRNP = prion protein gene; Met/Met = methionine homozygosity; Glu/Glu = glutamic acid homozygosity; Glu/Lys = heterozygosity of glutamic acid and lysine; NS = not significant.



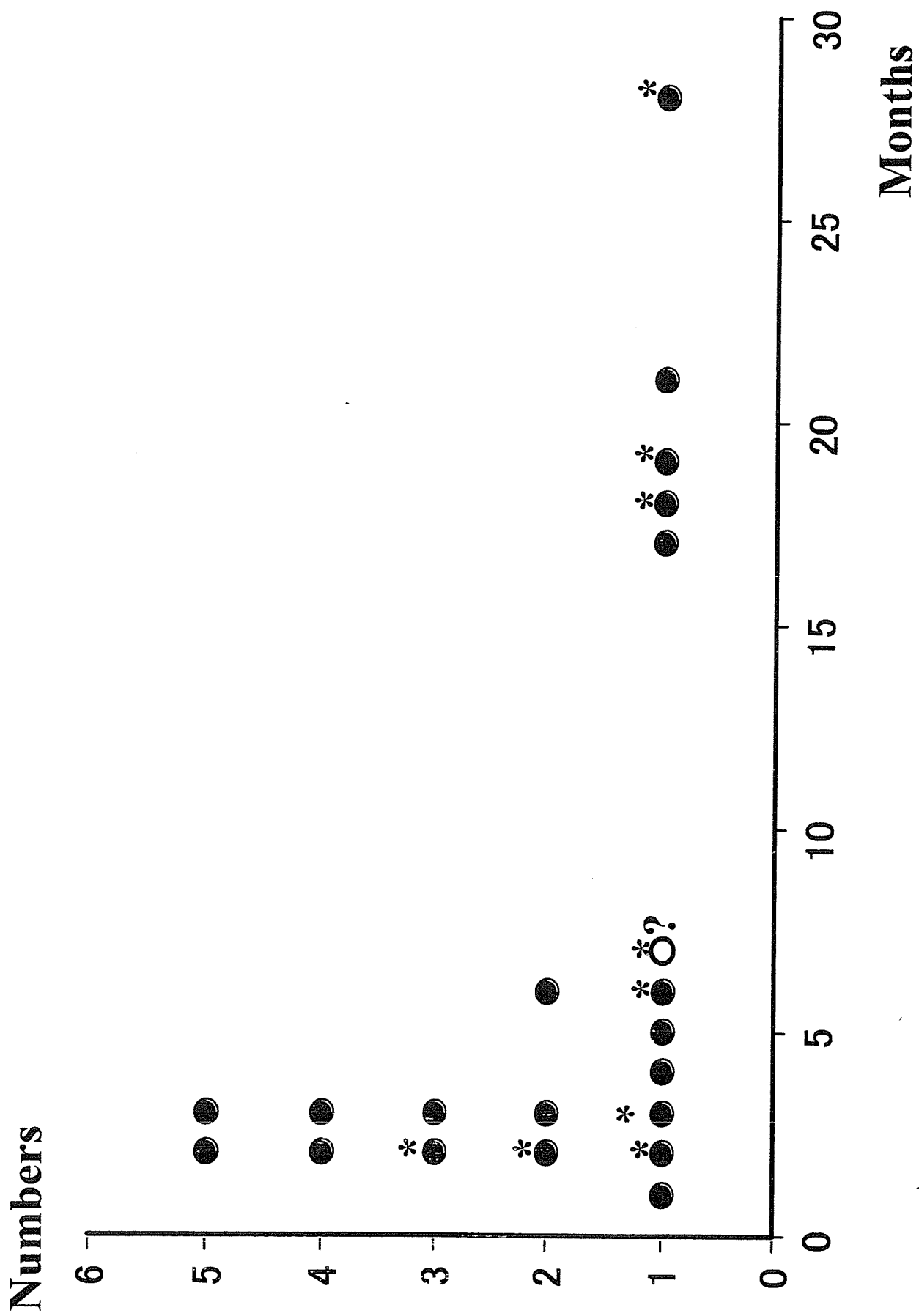
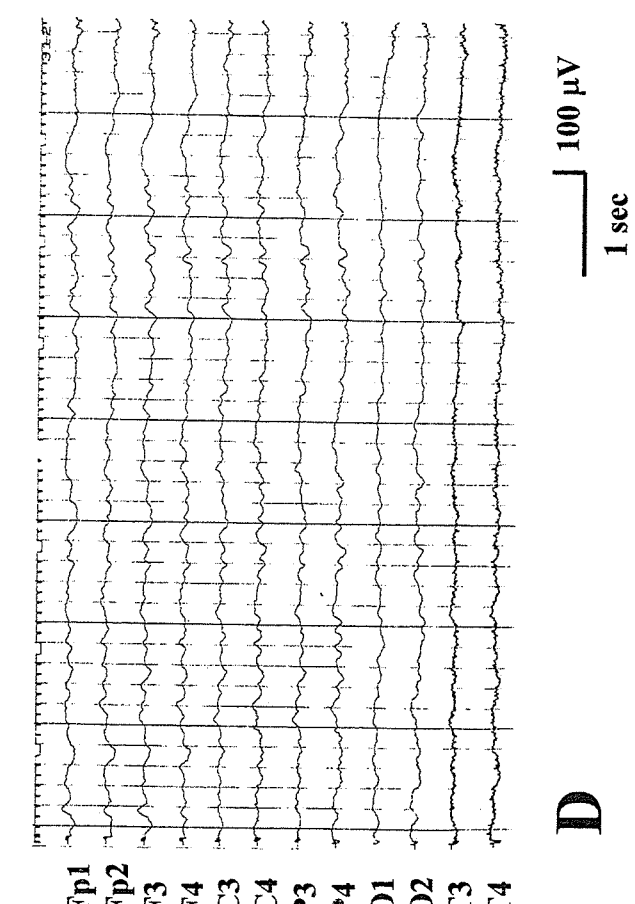
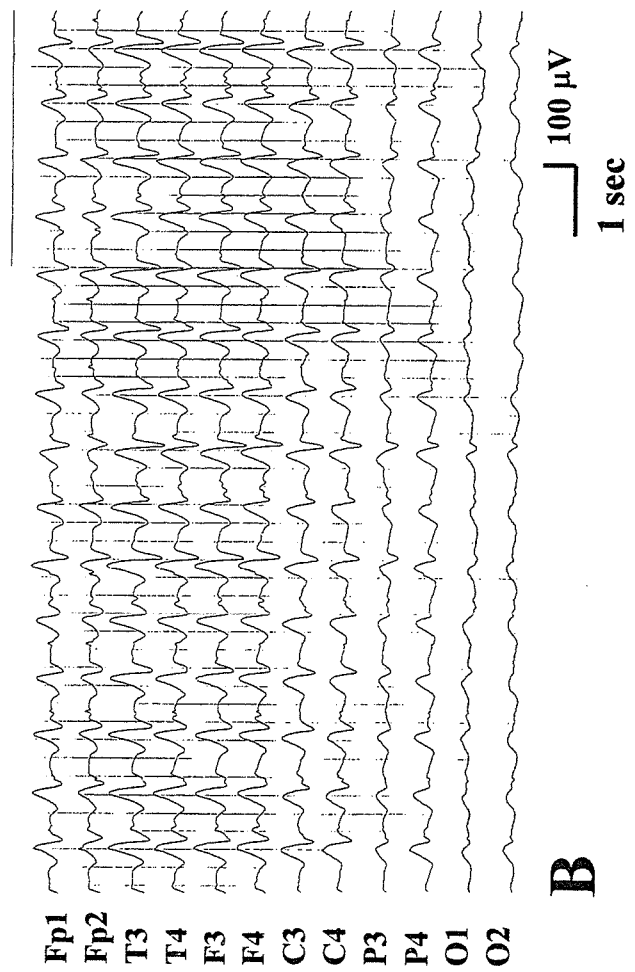

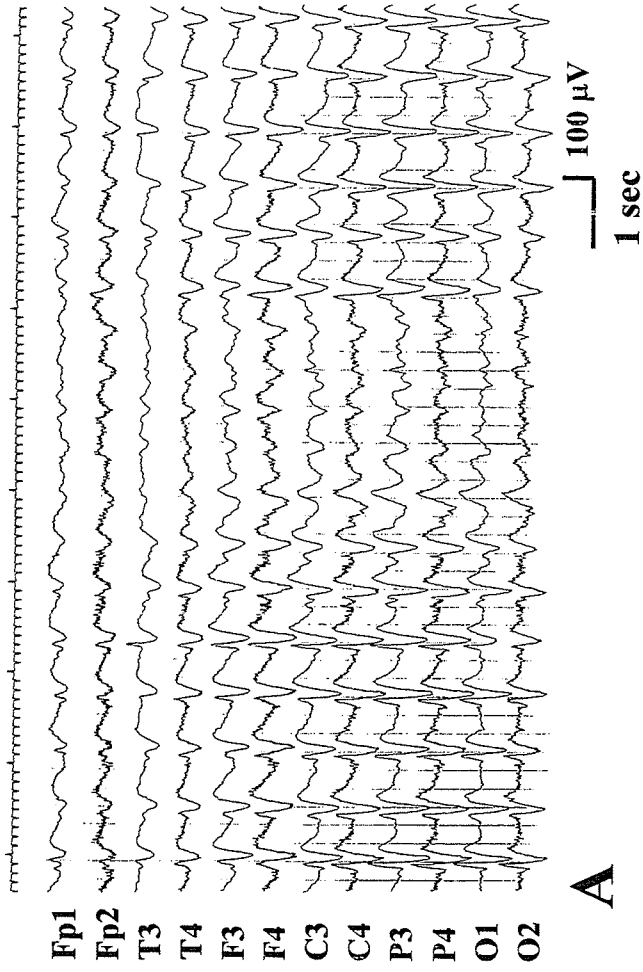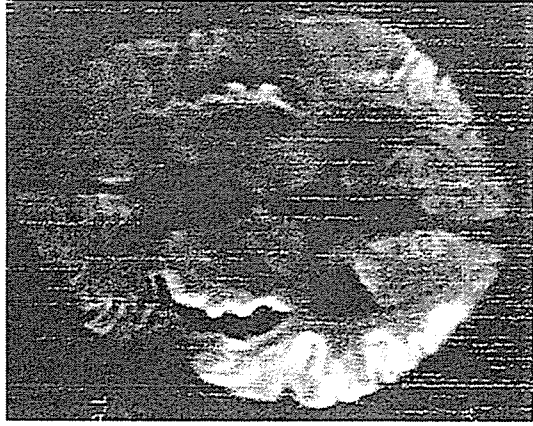


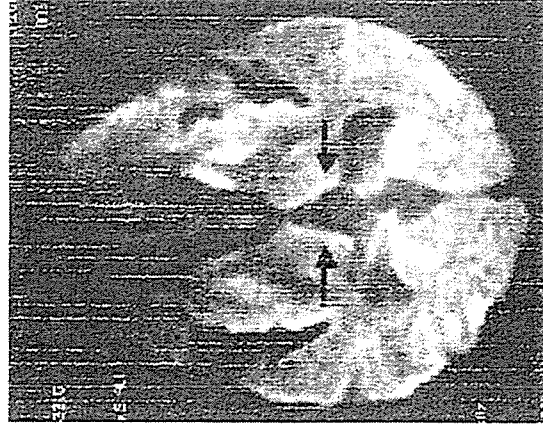
Figure 1



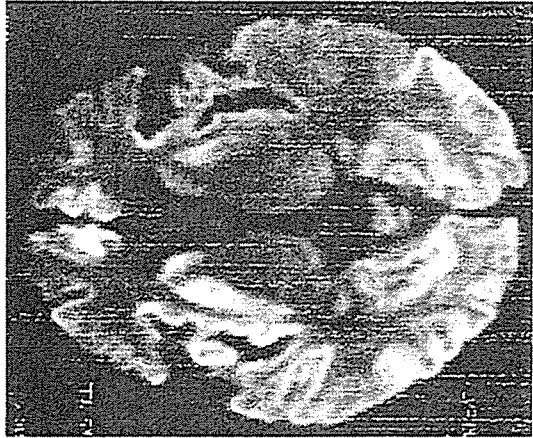**Figure 2**



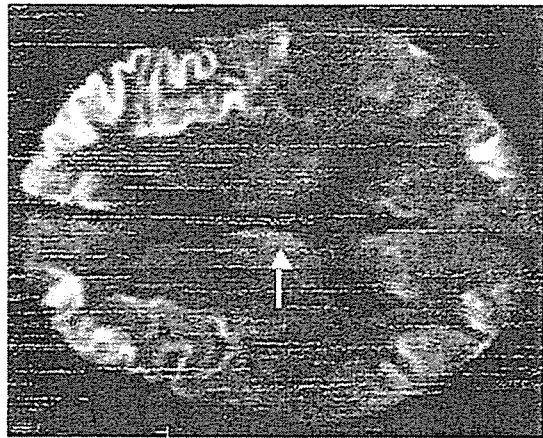
**C**



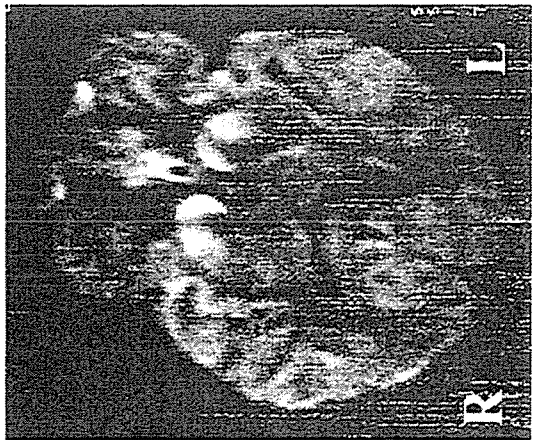
**F**



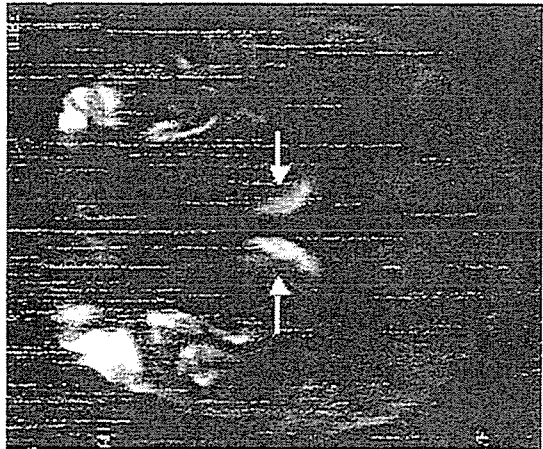
**B**



**E**




**A**




**D**

**Figure 3**


**A**



**B**



**C**



**Figure 4**