

3. Lee SG, Park KM, Hwang S et al. Congestion of right liver graft in living donor liver transplantation. *Transplantation* 2001; 71: 812–817.
4. Maetani Y, Itoh K, Egawa H et al. Factors influencing liver regeneration following living-donor liver transplantation of the right hepatic lobe. *Transplantation* 2003; 75: 97–102.
5. Inomata Y, Uemoto S, Asonuma K, Egawa H. Right lobe graft in living donor liver transplantation. *Transplantation* 2000; 69: 258–264.
6. Fang ST, Lo CM, Lui CL. Technical refinement in adult-to-adult living donor liver transplantation using right lobe graft. *Ann Surg* 2000; 231: 126–131.
7. Marcos A, Fisher R, Ham J et al. Right lobe living donor liver transplantation. *Transplantation* 1999; 68: 798–803.
8. Lee SG, Park KM, Hwang S et al. Modified right lobe liver graft from a living donor to prevent congestion. *Transplantation* 2002; 74: 54–59.
9. Ghobrial RM, Hsieh CB, Lerner S et al. Technical challenges of hepatic venous outflow reconstruction in right lobe adult living donor liver transplantation. *Liver Transplant* 2001; 7: 551–555.
10. Lamade W, Giombitza G, Fischer L et al. The impact of 3-dimensional reconstruction on operation planning in liver surgery. *Arch Surg* 2000; 135: 1256–1261.
11. Holger B, Andrea S, Heinz-Otto P. Computer-assisted planning and decision-making in living-donor liver transplantation. In: Tanaka K, Inomata Y, eds. *Living-Donor Liver Transplantation*, 1st edition. Spain: Prous Science; 23–28.
12. Inomata Y, Tanaka K, Egawa H, Uemoto S, Ozaki N, Okajima H. The evolution of immunosuppression with FK506 in pediatric living related liver transplantation. *Transplantation* 1996; 61: 247–252.
13. Tanabe M, Shimazu M, Wakabayashi G et al. Intraportal infusion therapy as a novel approach to adult ABO-incompatible liver transplantation. *Transplantation* 2002; 73: 1959–1961.
14. Inomata Y, Egawa H. Surgical procedure for right lobectomy. In: Tanaka K, Inomata Y, eds. *Living-Donor Liver Transplantation*, 1st edition. Spain: Prous Science; 43–58.
15. Tanaka K, Uemoto S, Tokunaga Y et al. Surgical techniques and innovations in living related liver transplantation. *Ann Surg* 1993; 217: 82–91.
16. Akabayashi A, Slingsby BT, Fujita M. The first donor death after living-related liver transplantation. *Transplantation* 2004; 77: 634.
17. Hasegawa K, Yazumi S, Egawa H et al. Endoscopic management of postoperative biliary complications in donors for living donor liver transplantation. *Clin Gastroenterol Hepatol* 2003; 1: 183–188.
18. Lo CM, Fan ST, Liu CL, Wong J. Hepatic venoplasty in living-donor liver transplantation using right lobe graft with middle hepatic vein. *Transplantation* 2003; 75: 358–360.
19. Hisatsune H, Yazumi S, Egawa H et al. Endoscopic management of biliary strictures after duct-to-duct biliary reconstruction in right-lobe living-donor liver transplantation. *Transplantation* 2003; 76: 810–815.
20. Yamaoka Y, Washida M, Honda K et al. Liver transplantation using a right lobe graft from living related donor. *Transplantation* 1994; 57: 1127–1130.
21. Ito T, Kiuchi T, Egawa H et al. Surgery-related morbidity in living donors of right-lobe liver graft: lessons from the first 200 cases. *Transplantation* 2003; 76: 158–163.
22. Fang ST, Lo CM, Liu CL, Wang WX, Wong J. Safety and necessity of including the middle hepatic vein in the right lobe graft in adult-to-adult live donor liver transplantation. *Ann Surg* 2003; 238: 137–148.
23. Cattral MS, Greig PD, Muradali D, Grant D. Reconstruction of middle hepatic vein of a living-donor right lobe liver graft with recipient left portal vein. *Transplantation* 2001; 71: 1864–1866.
24. Sano K, Makuuchi M, Miki K et al. Evaluation of hepatic venous congestion: proposed indication criteria for hepatic vein reconstruction. *Ann Surg* 2002; 236: 241–247.
25. Cui D, Kiuchi T, Egawa H et al. Microcirculatory changes in right lobe grafts in living-donor liver transplantation: a near-infrared spectrometry study. *Transplantation* 2001; 72: 291–295.
26. Ito T, Kiuchi K, Yamamoto H et al. Efficacy of anterior segment drainage reconstruction in right lobe liver grafts from living donors. *Transplantation* 2004; 77: 865–868.
27. Nakamura S, Tsuzuki T. Surgical anatomy of the hepatic veins and the inferior vena cava. *Surg Gynecol Obstet* 1981; 152: 43–51.
28. Kinkhabwala M, Guarrera J, Leno R, Brown R et al. Outflow reconstruction in right hepatic live donor liver transplantation. *Surgery* 2003; 133: 243–250.
29. De Villa VH, Chen CL, Chen YS et al. Right lobe living donor liver transplantation—addressing the middle hepatic vein controversy. *Ann Surg* 2003; 238: 275–282.
30. Ito T, Kiuchi T, Yamamoto H et al. Changes in portal venous pressure in the early phase after living donor liver transplantation: pathogenesis and clinical implications. *Transplantation* 2003; 75: 1313–1317.
31. Takada Y, Ueda M, Ishikawa Y et al. End-to-side portocaval shunting for a small-for-size graft in living donor liver transplantation. *Liver Transplant* 2004; 10: 807–810.
32. Boillot O, Delafosse B, Mechet I, Boucaud C, Pouyet M. Small-for-size partial liver graft in an adult recipient; a new transplant technique. *Lancet* 2002; 359: 406–407.
33. Masetti M, Siniscalchi A, Pietri LD et al. Living donor liver transplantation with left liver graft. *Am J Transplant* 2004; 4: 1713–1716.
34. Kido M, Ku Y, Tominaga M et al. Significant role of middle hepatic vein in remnant liver regeneration of right lobe living donors. *Transplantation* 2003; 75: 1598–1600.
35. Inomata Y, Kiuchi T, Kim ID et al. Auxiliary partial orthotopic living donor liver transplantation as an aid for small-for-size grafts in larger recipients. *Transplantation* 1999; 67: 1314–1319.
36. Kaihara S, Ogura Y, Kasahara M, Oike F, You Y, Tanaka K. A case of adult-to-adult living donor liver transplantation using right and left lateral lobe grafts from 2 donors. *Surgery* 2002; 131: 682–684.
37. Lee SG, Hwang S, Park K et al. An adult-to-adult living donor liver transplant using dual left lobe grafts. *Surgery* 2001; 129: 647–650.



## Living-donor liver transplantation for situs inversus: 2 case reports

Hideya Kamei\*, Mureo Kasahara, Kenji Uryuhara, Koichi Kozaki, Kohei Ogawa,  
Yasuhiro Ogura, Yasuhiro Fujimoto, Yasutsugu Takada, Koichi Tanaka

*Department of Transplantation and Immunology, Kyoto University Graduate School of Medicine, Kyoto, 606-8397 Japan*

### Index words:

Living-donor liver  
transplantation;  
Situs inversus

**Abstract** Two cases of living-donor liver transplantation performed in patients with situs inversus are reported. The authors discuss the operative management for a situs inversus recipient to undergo liver transplantation.

© 2005 Elsevier Inc. All rights reserved.

Liver transplantation has been accepted as the treatment of choice for patients with end-stage liver disease. Biliary atresia is one of the most common indications in children for liver transplantation. The disorder is associated with other congenital abnormalities in 10% to 27% of patients, which includes situs inversus [1].

Situs inversus is characterized by a mirror image orientation of the abdominal and thoracic viscera relative to the midline. The etiology of this disease is unclear, and the incidence is very low, as it occurs in less than 0.005% of the general population [2]. Situs inversus may occur in up to 28% of children with biliary atresia [3,4].

Situs inversus was once considered a contraindication to liver transplantation because of technical difficulties inherent in the procedure. Patients with a combination of vascular anomalies, including an interrupted inferior vena cava (IVC), a preduodenal portal vein, and an anomalous hepatic arterial anatomy, have been highly questionable candidates for liver transplantation [5], but it is very controversial.

We present 2 cases of living-donor liver transplantation performed in patients with situs inversus. In this report, we discuss the operative management for a situs inversus recipient to undergo liver transplantation.

### 1. Case report

#### 1.1. Case 1

A 5-year-old boy presented with end-stage liver disease for living-related liver transplantation. He had a history of biliary atresia and had undergone a Kasai portoenterostomy at the age of 13 months. At that time, he was noted to have situs inversus, polysplenia, intestinal malrotation, and preduodenal portal vein.

After the Kasai operation, ascending cholangitis frequently occurred, and he developed liver failure. The father, who was selected as an organ donor, had normal abdominal anatomy by computed tomography scan. A left lateral segment was harvested as a graft. The procedure was performed as reported previously [6].

In the recipient operation, complete situs inversus, including nonrotation of the gut, polysplenia, and a preduodenal portal vein, was verified. The retrohepatic IVC was absent, and the hepatic veins drained directly into

\* Corresponding author. Department of Transplant Surgery, Nagoya University School of Medicine, Nagoya 466-8550, Japan. Tel.: +81 52 744 2237; fax: +81 52 744 2248.

E-mail address: hkamechan@yahoo.co.jp (H. Kamei).

the right atrium. The right and left hepatic arteries independently originated directly from the supraceliac aorta. The graft was placed in the midline position to align the vascular anastomoses.

The donor left hepatic vein was anastomosed directly to the shared hepatic vein ostium in an end-to-end fashion. Because of sclerosis and narrowing of the wall, the portal vein of the recipient was resected at the confluence of the splenic vein and the superior mesenteric vein superior to the pancreas. The inferior mesenteric vein of the donor, which was the interposition vein graft, was anastomosed to the recipient portal vein in an end-to-end fashion. On the opposite side, transversing over the duodenum, it was anastomosed to the donor left portal branch in an end-to-end fashion. In spite of transversing over the duodenum, the anastomotic site was not under tension. The recipient hepatic artery was anastomosed to the donor left hepatic artery using microvascular techniques [7]. The bile duct was anastomosed to the previously created Roux-en-Y limb. A 4F polyvinylalcohol tube was inserted as an external stent to prevent anastomotic stenosis or obstruction.

Postoperatively, the graft function was excellent. During the 9-year follow-up, the patient did well without any surgical complications.

## 1.2. Case 2

A 2-year 4-month-old girl presented at Kyoto University Hospital with progressive hepatic failure secondary to biliary atresia after a Kasai portoenterostomy. She had undergone the procedure at the age of 2 months, at which time she was noted to have situs inversus with dextrocardia, polysplenia, intestinal malrotation, and a preduodenal portal vein. After the Kasai operation, the patient had frequent episodes of ascending cholangitis and had developed liver failure 2 years after the initial Kasai operation.

Her parents were evaluated as potential organ donors for liver transplantation, and both of them had normal anatomic findings on computed tomography scan. The mother was selected as the organ donor because the father had a fatty liver. A left lateral segment from her mother was harvested as a graft.

In the recipient operation, complete situs inversus, including nonrotation of the gut, polysplenia, a left-positioned vena cava, and a preduodenal portal vein, was verified. The proper hepatic artery arose directly from the supraceliac aorta and bifurcated into a left and right hepatic artery.

The graft was placed in the left side of the abdominal cavity. The graft had separate segments 2 and 3 veins, and both veins were independently anastomosed to the recipient hepatic vein orifice, because they were too far apart to make a single anastomosis. An orifice was created to connect the left and middle hepatic veins by incising the IVC, and this structure was then anastomosed end-to-end to the graft segment 2 vein. The right hepatic vein of the recipient was sutured from the left corner to adjust the size and anasto-

**Table 1** Profiles of cases

	Case 1	Case 2
Age (y)	5	2
Weight (kg)	15	10.5
Native liver abnormalities	Absence of retrohepatic IVC preduodenal PV right and left HA direct from aorta independently	Left-sided IVC preduodenal PV proper HA direct from aorta
Donor relation	Father	Mother
Blood type combination	Identical	Identical
GRWR	1.56	2.28

GRWR indicates graft-to-recipient weight ratio; PV, portal vein; HA, hepatic artery.

mosed end-to-end to the graft segment 3 vein. Because of sclerosis and narrowing of the wall, the portal vein of the recipient was resected superior to the pancreas. Then, the donor ovarian vein, which was the interposition vein graft, was anastomosed to the recipient portal vein in an end-to-end fashion. On the opposite side, transversing the duodenum, the vein graft was anastomosed to the donor left portal branch in an end-to-end fashion without tension. The recipient right hepatic artery was anastomosed to the donor left hepatic artery using microvascular techniques. The bile duct anastomosis was created with the Roux-en-Y limb in the usual fashion, and a 4 French polyvinylalcohol tube was inserted. Postoperatively, the graft function was excellent. Currently, 2 years and 9 months after liver transplantation, the patient is doing well.

## 2. Discussion

The prevalence of situs inversus in the general population is difficult to establish. The estimated incidence is between 0.002% and 0.1% [8]. Nearly 80% of these patients are affected with other congenital malformations, including visceral and vascular anomalies and biliary atresia, which is one of the most common indications for liver transplantation [3,9]. Biliary atresia in association with other congenital structural anomalies has a poor prognosis, and these patients continue to have poor bile secretion after Kasai portoenterostomy [10]. Complex vascular anomalies associated with situs inversus increased the technical difficulty of the operation and resulted in a high mortality rate in these patients, especially in the context of an interrupted IVC, a preduodenal portal vein, and an anomalous hepatic artery origin. The technical aspects of performing liver transplantation in these patients are more challenging than simply overcoming the mirror-image liver anatomy.

Mattei et al [11] described the results of 26 patients with situs inversus who had undergone liver transplantation. In that report, they stated that the anatomic variations

encountered most frequently were a preduodenal portal vein (69%), an absent infrahepatic IVC (50%), and an aberrant hepatic artery distribution (35%), which included an accessory artery. Despite these anatomic variations, the majority of vascular anastomoses were performed in a standard fashion.

We encountered 2 variations in the IVC anatomy: a left-sided IVC and an absent infrahepatic IVC (Table 1). In both cases, hepatic vein reconstruction was performed by our standard technique, the preparation for IVC anastomosis was managed easily, and the postoperative hepatic venous outflow was excellent.

The predominant portal vein anomaly in situs inversus patients is a preduodenal portal vein. This anomaly rarely interferes with a simple end-to-end anastomosis, and vascular grafts are usually not necessary, when the preduodenal portal vein is sufficiently mobilized and not injured. The portal vein of the recipient with biliary atresia is often atrophic and sclerotic because of repeated episode of cholangitis. Interposition vein grafting is useful to prevent an anastomosis under tension, especially if transversing the duodenum. The discrepancy of the distance from the portal vein to the hepatic vein between graft and recipient may be problematic. This discrepancy may result in kinking of the reconstructed portal vein, which can lead to portal vein thrombosis and graft failure. In the case of patient with preduodenal portal vein, the portal vein was reconstructed in a preduodenal position resulting in a straight line. Preduodenal reconstruction of the portal vein is a feasible and effective method to deal with mismatched distance [12].

An aberrant hepatic artery supply is commonly encountered in patients with situs inversus. However, current microvascular techniques permit the construction of an end-to-end anastomosis that maintains adequate arterial flow.

In liver transplantation to situs inversus patients, the evaluation of the donor is important. Familial situs inversus has been reported only sporadically, but a case of living-donor liver transplantation from a situs inversus to another has been reported. Therefore, donor selection should properly evaluate liver anatomy [13].

Situs inversus is not a contraindication to liver transplantation, and prolonged survival can be achieved. The anatomic variants encountered can be managed with conventional techniques but sometimes demand creative surgical solution. Reconstruction of preduodenal portal vein with interposition vein graft is useful to confirm the enough length and prevent overstretching of anastomosis, especially when it is atrophic and sclerotic.

## References

- [1] Lilly JR, Chandra RS. Surgical hazards of co-existing anomalies in the congenital biliary atresia. *Surg Gynecol Obstet* 1974;139:49-54.
- [2] Mayo CW, Rice RG. Situs inversus totalis: a statistical review of data on seventy-six cases with special reference to disease of the biliary tract. *Arch Surg* 1949;58:724-30.
- [3] Ruben GD, Templeton Jr JM, Ziegler MM. Situs inversus: the complex including neonatal intestinal obstruction. *J Pediatr Surg* 1983;18:751-6.
- [4] Millis JM, Brems JJ, Hiatt JR, et al. Orthotopic liver transplantation for biliary atresia. Evolution of management. *Arch Surg* 1988;123:1237-9.
- [5] Lilly JR, Starzl TE. Liver transplantation in children with biliary atresia and vascular anomalies. *J Pediatr Surg* 1974;9:707-14.
- [6] Tanaka K, Uemoto S, Tokunaga W, et al. Surgical techniques and innovations in living related liver transplantation. *Ann Surg* 1993;217:82-91.
- [7] Inomoto T, Nushizawa F, Sasaki H, et al. Experiences of 120 microsurgical reconstructions of hepatic artery in living related liver transplantation. *Surgery* 1996;119:20-6.
- [8] Blegan HM. Surgery in situs inversus. *Ann Surg* 1949;129:244-59.
- [9] Fonkalsrud E, Tompkins R, Clatworthy Jr H. Abdominal manifestation of situs inversus in infants and children. *Arch Surg* 1966;92:791-5.
- [10] Tanano H, Hasegawa T, Kawahara H, et al. Biliary atresia associated with congenital structural anomalies. *J Pediatr Surg* 1999;34:1687-90.
- [11] Mattei P, Wise B, Schwarz K, et al. Orthotopic liver transplantation in patients with biliary atresia and situs inversus. *Pediatr Surg Int* 1998;14:104-10.
- [12] Kasahara M, Kiuchi T, Haga H, et al. Monosegmental living-donor liver transplantation for infantile hepatic hemangioendothelioma. *J Pediatr Surg* 2003;38:1108-11.
- [13] Sugawara Y, Makuuchi M, Takayama T, et al. Liver transplantation from situs inversus to situs inversus. *Liver Transpl* 2001;7(9):829-30.



## Proinflammatory and Antiinflammatory Cytokine Production During Ischemia-Reperfusion Injury in a Case of Identical Twin Living Donor Liver Transplantation Using No Immunosuppression

X. Zhao, T. Koshiba, Y. Fujimoto, J. Pirenne, A. Yoshizawa, T. Ito, H. Kamei, K. Jobara, K. Ogawa, K. Uryuhara, Y. Takada, and K. Tanaka

### ABSTRACT

**Background.** Bolus steroids are usually administered prior to graft reperfusion in an attempt to provide protection against ischemia reperfusion injury (IRI). However, the anti-IRI properties of steroids have not been established. Living donor liver transplantation (LDLT) between identical twins provides a unique opportunity to study the natural production of cytokines during transplantation without the confounding influences of the alloimmune response or of immunosuppression in particular steroids.

**Methods.** A 38-year-old male with hepatitis C virus-related cirrhosis and multiple hepatocellular carcinomas received a hepatic right lobe graft from his identical twin. No immunosuppression was administered, not even intraoperative bolus steroids. IRI was assessed by serum transaminases as well as by proinflammatory interleukin (IL) IL-1 $\beta$ , tumor necrosis factor (TNF)- $\alpha$ , IL-8 cytokines and for potent regenerative/anti-inflammatory (IL-6, IL-10) mediators.

**Results.** Despite no administration of steroids, low peak levels of serum transaminases were observed. Serum IL-6 and IL-10 dramatically and rapidly increased during liver transplantation, namely, 160 and 20 times higher than baseline, respectively. In contrast, IL-1 $\beta$  and TNF- $\alpha$  remained low during and after transplantation and an increase in IL-8 was less obvious.

**Conclusion.** Syngeneic LDLT without intraoperative bolus steroids is feasible, yielding no penalty in terms of IRI. A predominance of protective cytokines was observed in the absence of steroids. Thus, the concept that intraoperative administration of steroids is necessary to protect liver transplants from IRI must be revisited.

IT has long been assumed that proinflammatory cytokines play a pivotal role in liver tissue damage during hepatic ischemia-reperfusion injury (IRI). Bolus steroids are usually administered prior to liver graft reperfusion based on the assumption that steroids protect against IRI by suppressing production of proinflammatory cytokines. This assumption has been recently challenged, however, by the results of clinical and rodent experiments demonstrating that steroids can paradoxically aggravate IRI by impairing hepatocyte regeneration.<sup>1-3</sup> In the meantime; a beneficial role has been experimentally established for hepatocyte regenerative and antiinflammatory protective cytokines, such as interleukin (IL)-6 and IL-10.<sup>4-5</sup>

We report a case of living donor liver transplantation

(LDLT) between identical twins without any immunosuppression, including intraoperative bolus steroids. This case provided a unique opportunity to study the natural produc-

From the Department of Transplantation and Immunology (X.Z., Y.F., A.Y., T.I., H.K., K.J., K.O., K.U., Y.T., K.T.) and Horizontal Medical Research Organization (T.K.), Transplant Tolerance Unit, Kyoto University, Faculty of Medicine, Kyoto, Japan; and Abdominal Transplant Surgery Department (J.P.), University Hospital Leuven, Leuven Belgium.

Address reprint requests to Takaaki Koshiba, MD, PhD, Horizontal Medical Research Organization, Transplant Tolerance Unit, Kyoto University, Faculty of Medicine, 54 Kawara-cho, Shogoin, Sakyo-ku, Kyoto 606-8507, Japan. E-mail: tkoshiba@kuhp.kyoto-u.ac.jp

0041-1345/05/\$-see front matter  
doi:10.1016/j.transproceed.2004.12.272

© 2005 by Elsevier Inc. All rights reserved.  
360 Park Avenue South, New York, NY 10010-1710

Table 1. Changes in AST and ALT Serum Levels

	Before	Reperfusion	1 hr	6 hr	12 hr	18 hr	Day 1	Day 2	Day 3	Day 5	Day 7
AST	139	167	464	<u>550</u>	435	359	369	328	212	99	81
ALT	97	80	<u>511</u>	481	445	475	490	511	390	229	169

Peak values of AST and ALT are underlined.

tion of proinflammatory and hepatocyte protective cytokines during hepatic IRI because of the absence of confounding effects due to an alloimmune response or immunosuppression.

## MATERIALS AND METHODS

### Syngeneic LDLT

A 38-year-old man underwent right lobe LDLT on November 11, 2003 to treat hepatitis C virus-related cirrhosis and hepatocellular carcinomas. The liver donor was the patient's twin brother. Their HLA phenotypes were confirmed to be identical by HLA DNA typing. The weight of the graft was 810 g, and the recipient's body weight was 63 kg (graft/body weight ratio, 1.29%). Cold and warm ischemia times were 23 minutes and 50 minutes, respectively, compared with  $85.5 \pm 105.6$  minutes and  $43.5 \pm 14.2$  minutes for other LDLT patients receiving a right lobe.

### Immunosuppression

No immunosuppression was administered, not even intraoperative bolus steroids.

### Measurement of Serum Aminotransferases and Cytokines

Blood samples were sequentially collected before and at the beginning of the operation; at reperfusion; and 10 minutes, 1, 2, 3, 6, 12, and 18 hours later followed by once daily for 3 days posttransplant. IRI was assessed by measuring serum alanine aminotransferase (ALT) and aspartate aminotransferase (AST). Proinflammatory cytokines (interleukin [IL]-1 $\beta$ , tumor necrosis factor [TNF]- $\alpha$ , IL-8) and hepatocyte protective cytokines (IL-6, IL-10) were evaluated by ELISA in an independent laboratory in a blinded manner.

## RESULTS

Despite no steroids being administered, peak levels of serum transaminases (ALT/AST: 511/550 IU/L; Table 1) were low and comparable to those usually observed in our LDLT patients receiving intraoperative steroids mean  $\pm$  SD (AST/ALT:  $449 \pm 952/476 \pm 609$  IU/L;  $n = 117$ ). The kinetics of the serum cytokines (Fig 1) showed IL-6 to dramatically increase after removal of the native liver, rapidly reaching its highest value at the time of reperfusion (843 pg/mL, 160 times higher than the baseline value at the beginning of the operation; Fig 1A). IL-10 also rapidly increased: the peak value was 39 pg/mL at 1 hour after reperfusion, 20 times higher than the baseline value at the beginning of the operation (Fig 1B). In marked contrast, TNF- $\alpha$  was undetectable both during and after LTx at all time points (Fig 1C). The pretransplant IL-1 $\beta$  level was relatively high, but showed an abrupt decline during the anhepatic phase remaining low thereafter (Fig 1D). IL-8

slowly increased during LTx but reached its highest value only postoperatively: namely, peak value of 58.4 pg/mL at 6 hours after reperfusion, which is 20 times higher than the baseline value at the beginning of the operation (Fig 1E). No surgical complications were observed post-LTx.

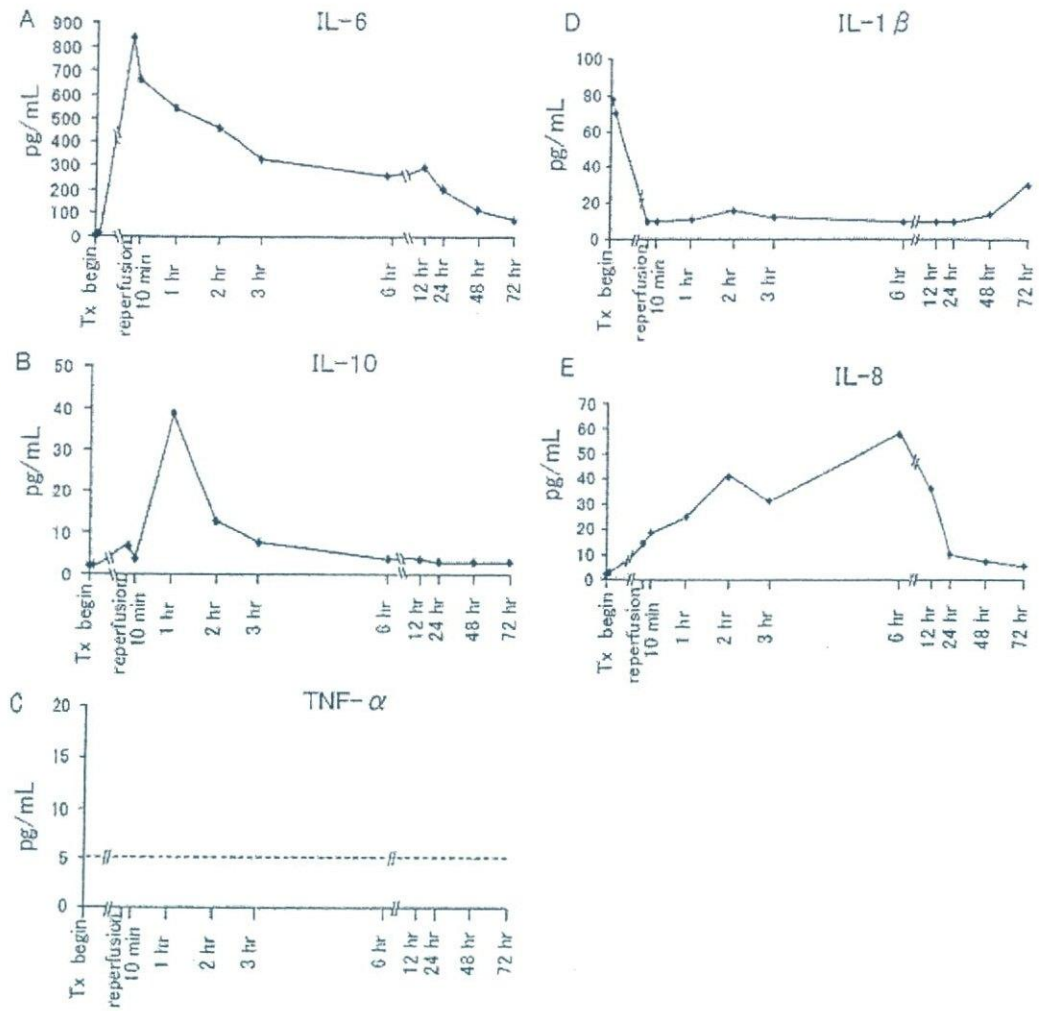
## DISCUSSION

TNF- $\alpha$  and IL-1 are the two proinflammatory cytokines most commonly implicated in hepatic IRI. Both, mediators induce production of IL-8—a chemoattractant for neutrophils.<sup>6</sup> Some cytokines such as IL-6 appear to have dual functions, participating in both inflammatory responses and cellular regeneration. IL-6 knockout mice show an aggravation of warm IRI with impaired hepatocyte regeneration.<sup>4</sup> In contrast, antiinflammatory cytokines, such as IL-10, may also play an important role in protection of the liver by counteracting the inflammatory response.<sup>5</sup> Therefore, it may well be that intraoperative steroids, although effective in blocking inflammatory responses, negatively affect beneficial hepatocyte protective cytokines, which are important for graft recovery from IRI. Since we plan to continue the use of small-for-size grafts for adult LDLT, the ability of the liver to initiate regeneration or counteract inflammatory responses has become especially important.

In animal experiments on reperfusion injury, the kinetics and function of various cytokines are usually investigated in syngeneic organ transplant models that have an absence of an alloimmune response and no immunosuppression. However, cases of syngeneic organ transplants especially liver transplants, between identical twins have been rare. Our case reported here has, therefore, provided a unique and important opportunity to study the natural production of proinflammatory and hepatocyte protective cytokines during human hepatic IRI.

In contrast to the classic concept of the role of proinflammatory cytokines in hepatic IRI, the increase in serum IL-1 $\beta$ , TNF- $\alpha$ , and IL-8 was not prominent despite the absence of steroids. In contrast, serum levels of IL-6 and IL-10 were dramatically and rapidly elevated after removal of the native liver. Some investigators have also found that liver surgery induces cytokine responses characterized predominantly by an early appearance of IL-6 and IL-10, whereas the levels of TNF- $\alpha$  remain low and IL-1 $\beta$  is undetectable.<sup>7</sup> Therefore, this cytokine imbalance may naturally occur during surgical operations on the liver.

In conclusion, we have found that, despite the complete absence of steroid administration, posttransplant peak levels of serum ALT/AST were unexpectedly low, while serum IL-6 (cytokine essential for liver regeneration) and IL-10 (antiinflammatory cytokine) were dramatically and rapidly



**Fig 1.** Kinetics of serum cytokines. IL-6 rapidly increased after removal of the native liver and reached its maximum value 2 hours after reperfusion (A). IL-10 strongly and rapidly increase and peaked 1 hour after reperfusion (B). In contrast, TNF- $\alpha$  was not detectable either during or after transplantation at all the time points tested (C), while IL-1 $\beta$  levels declined during anhepatic time and remained low thereafter (D). IL-8 slowly increased but reached its highest value post-operatively (E). Tx: transplantation.

increased during LTx. In contrast, increases in serum IL-1 $\beta$ , TNF- $\alpha$ , and IL-8 (proinflammatory cytokines) were not prominent. The predominant balance of hepatocyte protective cytokines (IL-6 and IL-10) during LTx may contribute to the protection of liver grafts from IRI. Of special interest is that this naturally occurring favorable balance was observed in the complete absence of steroids. Therefore, the concept that intraoperative administration of steroids is necessary to provide protection against IRI in LTx warrants reexamination.

#### REFERENCES

- Sileri P, Schena S, Fukada J, et al: Corticosteroids enhance hepatic injury following ischemia-reperfusion. *Transplant Proc* 33:3712, 2001
- Debonera F, Krasinkas AM, Gelman AE, et al: Dexamethasone inhibits early regenerative response of rat liver after cold preservation and transplantation. *Hepatology* 38:1563, 2003
- Pirrenne J, Van Gelder F, Koshiba T, et al: Influence of intraoperative steroids on ischemia/reperfusion injury (IRI) after liver transplantation (LTx). *Am J Transplant* 1(suppl 1):316, 2001
- Camargo CA Jr, Madden JF, Gao W, et al: Interleukin-6 protects liver against warm ischemia/reperfusion injury and promotes hepatocyte proliferation in the rodent. *Hepatology* 26:1513, 1997
- Yoshidome H, Kato A, Edwards MJ, et al: Interleukin-10 suppresses hepatic ischemia/reperfusion injury in mice: implications of a central role for nuclear factor kappa B. *Hepatology* 30:203, 1999
- Jaeschke H: Molecular mechanisms of hepatic ischemia reperfusion injury and preconditioning. *Am J Physiol Gastrointest Liver Physiol* 284:G15, 2003
- Jerin A, Pozar-Lukanovic N, Sojar V, et al: Balance of pro- and anti-inflammatory cytokines in liver surgery. *Clin Chem Lab Med* 41:899, 2003



## Portal Vein Complications in the Long-Term Course After Pediatric Living Donor Liver Transplantation

M. Ueda, H. Egawa, K. Ogawa, K. Uryuhara, Y. Fujimoto, M. Kasahara, Y. Ogura, K. Kozaki, Y. Takada, and K. Tanaka

### ABSTRACT

The frequency and the outcome of patients with portal vein (PV) complications in the long-term course after pediatric living donor liver transplantation (LDLT) have rarely been reported. Between June 1990 and September 2003, 527 pediatric patients underwent primary LDLT with left lobe grafts, among which 479 patients with functioning grafts at 3 months after LDLT were included in this analysis. The ages ranged from 29 days to 17 years, 3 months (median: 1 year, 9 months) and body weight from 3.1 kg to 62.4 kg (median: 9.6 kg). Biliary cirrhosis was the most common cause for LDLT (81%). The PV was anastomosed with or without a vein graft. Thirty-nine patients (8%) showed a PV complication (stenosis: 16; obstruction: 17; thrombus: 2; twist: 3). Their ages ranged from 4 months to 17 years, 3 months (median: 1 year) and their body weight from 3.8 kg to 44.8 kg (median: 8.5 kg) at operation. PV complications were detected between 4 and 116 months (median: 14 months) after the transplant. Splenomegaly and decreased platelet counts were observed in more than 90% of the patients with a PV complication. In 27 patients (71%), interventional venoplasty was successful. Eleven patients had obstruction of the PV (2.3%) including three who showed cirrhosis; one with severe pulmonary hypertension; one death after retransplantation; and one alive after retransplantation. Moderate fibrosis was found in two patients at 3 and 2 years after the procedure, one of whom had the complication of a moderate intrapulmonary shunt. Early detection of PV stenosis with these two markers can lead to successful angioplasty and avoid graft loss.

**M**ORE THAN 10 YEARS have passed since the introduction of living donor liver transplantation (LDLT) for pediatric patients with end-stage liver disease. Segmental liver grafts from adult donors have larger vessel pedicles compared to those of small pediatric patients. Furthermore, the vessel pedicles in the grafts are short compared with those in whole liver grafts from deceased donors.<sup>1</sup> In addition, the option to obtain vessel grafts is limited in LDLT.<sup>2</sup> These inconveniences require technical refinements for the anastomoses of segmental liver grafts with the recipient vessels. So far, vascular complications during the long-term course after pediatric LDLT have rarely been reported. In this report, we review portal vein (PV) complications in the long-term course of 527 pediatric LDLTs over the last 13 years.

### PATIENTS AND METHODS

From June 1990 to September 2003, 527 pediatric patients received primary LDLT with left-side grafts, including lateral segment, left

lobe grafts, and monosegments. We reviewed the records of the medical courses in 479 patients with functioning grafts at 3 months after LDLT. Their ages ranged from 29 days to 17 years, 3 months (median: 1 year, 9 months) body weight, from 3.1 kg to 62.4 kg (median: 9.6 kg) at the time of LDLT. Primary diseases were biliary cirrhosis in 384 patients (81%); metabolic diseases in 35 patients (7%); fulminant hepatic failure in 24 patients (5%); liver cirrhosis in 15 patients (3%); tumors in 15 patients (3%); and other

From the Department of Transplantation Immunology, Kyoto University Faculty of Medicine, Kyoto University, Kyoto, Japan.

Supported in part by the Grant-in-Aid for Scientific Research from the Ministry of Education, Culture, Sports, Science and Technology and for Research on Human Genome, Tissue Engineering Food Biotechnology, Health Sciences Research Grants, Ministry of Health, Labor and Welfare of Japan.

Address reprint requests to Mikiko Ueda, MD, Department of Transplantation Immunology, Kyoto University Faculty of Medicine, 54 Kawara-cho, Sakyo-ku, Kyoto 606-8507, Japan. E-mail: mikiko@kuhp.kyoto-u.ac.jp

0041-1345/05/\$-see front matter  
doi:10.1016/j.transproceed.2005.01.044

© 2005 by Elsevier Inc. All rights reserved.  
360 Park Avenue South, New York, NY 10010-1710



Table 1. Outcomes of Venoplasty for Portal Vein Complications

	Stenosis	Obstruction	Thrombus	Twist	Total
Number	16	17	2	3	38
Succeeded	16 (100%)	8 (47%)	0 (0%)	3 (100%)	27 (71%)
Failed	0 (0%)	9 (53%)	0 (0%)	0 (0%)	9 (24%)
No change	0 (0%)	0 (0%)	2 (100%)	0 (0%)	2 (5%)
Recurrence	5 (31%)	4 (23.5%)	1 (50%)	0 (0%)	10 (26%)

etiologies in 6 (1%). Fifty-two percent of patients were under 2 years old. The donor and recipient operations were performed at the same time. When the native portal vein of the recipient was stenotic, we obtained a vein graft using either the ovarian vein of maternal donors or the inferior mesenteric vein of paternal donors. Segmental grafts were transplanted in piggyback fashion.<sup>3</sup> The graft PV was anastomosed directly with the trunk or the branch patch of the recipient PV, when there were no stenotic changes in the recipient PV.<sup>4</sup> When the PV trunk was stenotic, the native PV was removed and anastomosed to the confluence of the splenic vein and the superior mesenteric vein, or to an interposed vein graft, according to the distance between graft PV and the native PV. If the vein graft was small in diameter, it was patched. Blood flow in the portal vein was confirmed after reperfusion of the grafts by Doppler ultrasonography during operation and once or twice in a week while the patients stayed in the hospital. Patients were followed by blood tests every 1 to 2 months and by Doppler ultrasonography every 3 to 6 months. When a PV complication was suspected by clinical signs, it was confirmed by the Doppler ultrasonography and addressed by interventional venoplasty. However, in some patients, Doppler ultrasonography first revealed a PV complication requiring interventional venoplasty. We analyzed the frequency, age, and body weight at transplant, graft-versus-recipient body weight ratio, time from LDLT to diagnosis, symptoms and signs, findings on portography, results of interventional venoplasty, and long-term outcomes of patients with PV complications.

## RESULTS

PV complications occurred in 39 patients (8%) of ages ranging from 4 months to 17 years, 3 months (median: 1 year) and body weights ranging from 3.8 kg to 44.8 kg (median: 8.5 kg). The period between LDLT and the diagnosis of a PV complication was between 4 and 116 months (median: 14 months). The graft-versus-recipient body weight ratios were significantly larger in 39 patients with PV complication (range: 0.86 to 5.6, mean: 2.97) than those in 440 patients without a PV complication (range: 0.6 to 7.68, mean: 2.52;  $P < .03$ ). The diagnosis of a PV complication occurred within the first 6 months in five patients; between 6 months and 1 year in 10 patients, between 1 year to 2 years in nine patients; between 2 years and 3 years in eight patients; between 3 years and 5 years in six patients; and later than 5 years in one patient. Symptoms of a PV complication included gastrointestinal bleeding in 23%; liver dysfunction in 64%; splenomegaly in 95%; and decreased platelet counts below the lower limits of the normal ranges in 100%. Eleven patients (33%) had a vein graft placed at the time of LDLT. Portography was performed in 38 patients (97%). One patient did not receive portography because it took almost 2 years for the treat-

ment of repeated stenosis of the choledochojejunostomy by external biliary drainage.

The radiological findings were classified into four groups: PV stenosis at the anastomotic sites with detectable blood flow in 16 patients (42%); obstruction of the PV with no blood flow in 17 patients (45%); partial thrombus in the PV with detectable blood flow in two patients (5%); and twist of the anastomotic sites with elastic expansion by the balloon pressure in three patients (7.5%; Table 1). In all 38 patients, interventional venoplasty was performed. In 27 patients (71%), venoplasty was successful with recovery of portal flow without the major pressure gaps between pre- and poststenotic sites. These patients had displayed PV stenosis ( $n = 16$ ), PV obstruction ( $n = 8$ ) twist ( $n = 3$ ). In nine patients with PV obstruction, venoplasty failed (24%). Two patients with a PV thrombus received thrombolytic therapy after venoplasty through a catheter placed into the PV with no major effects; one patient showed complete obstruction of the PV after splenectomy; and one patient underwent surgical thrombectomy but had a recurrent PV thrombus. Repeated venoplasty was required due to recurrence of the PV complication in five patients out of 16 stenotic patients; 4 out of 17 obstructed patients, and one patient with a partial thrombus. In 26 out of 27 patients with successful-interventional venoplasty, the platelet counts significantly increased from a median of  $9.5 \times 10^4/\mu\text{L}$  (range: 2.9 to 18.8) before venoplasty to the median of  $17.5 \times 10^4/\mu\text{L}$  (range: 2.0 to 21.8;  $P < .0001$ ). The long-term outcomes in 11 patients with obstructed PVs, including nine patients with failed venoplasty, one patient with no treatment for PV thrombus due to long-term external biliary drainage for repeated stenosis of choledochojejunostomy, and one patient who previously had a PV thrombus and had complete obstruction of PV after splenectomy are shown in Fig 1. Cirrhosis was histologically evident in three patients, one of whom has been alive for 9 years after the diagnosis of PV occlusion with the complication of severe hepatopulmonary syndrome. At the moment, the pulmonary hypertension is severe excluding retransplantation. Another two patients lost their grafts at 5 years and at 2 years after the diagnosis due to biliary cirrhosis. One died early after retransplantation due to sepsis and the other is alive for more than 3 years after retransplantation. Moderate fibrosis was seen at 40 months and 25 months after the diagnosis of PV occlusion in two patients, the former being complicated by a moderate intrapulmonary shunt. No fibrotic changes were found in three patients at 50, 27, and 23 months after the diagnosis of PV occlusion without specific complica-

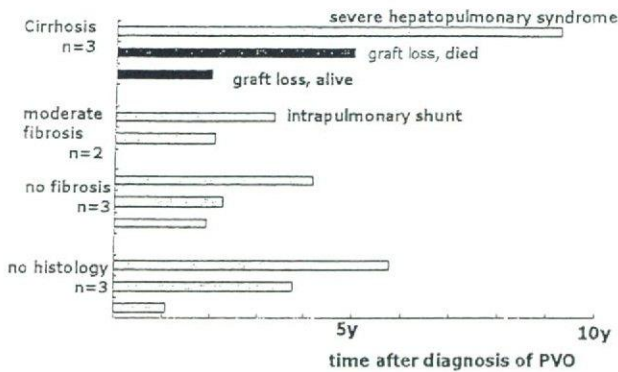


Fig 1. Outcomes of patients with PV obstructions ( $n = 11$ , 2.3%).

tions. The other three patients are alive for 69, 45, and 13 months after the diagnosis of PV occlusion, although they did not undergo a liver biopsy nor a radiological examination in the last 1 to 2 years. Patients without PV obstruction after venoplasty are all alive.

#### DISCUSSION

In pediatric LDLT, size mismatch between graft vessels from adult donors and the recipient native veins and short pedicles demands frequent usage of vein grafts that can affect the patency of the anastomotic sites in the long term. In addition a major indication for LDLT is biliary atresia in smaller patients age less than 2 years. The patients' PVs are sometimes complicated by sclerosis or narrowing due to repeated cholangitis or repeated previous laparotomies. However, the frequency and long-term outcomes of vascular complications in pediatric LDLT have rarely been reported. Buell et al reported vascular complications in pediatric patients with whole liver grafts and segmental grafts in a large series of 600 transplants.<sup>5</sup> The incidence of PV complications was high among LDLT (27%) compared to that in reduced an split-liver transplantations (1%) or in whole liver transplantation (1%) from a deceased donor. They also reported that the patients with LDLT, especially those requiring a PV anastomosis with vein grafts, showed 71% PV complications, while LDLT without vein grafts in the PV anastomosis showed 13% PV complications. Therefore, they concluded not to use vein grafts for the PV anastomosis, which resulted in a significant decrease in the complication rates.

Our series is large and includes only LDLTs for pediatric patients. The rate of long-term PV complication was low (8%), although vein grafts were used when indicated. The Chicago group often used cryopreserved vein grafts from deceased donors in pediatric LDLTs that may be a reason why the rate of long-term PV complication was so high. We used mostly fresh ovarian veins from maternal donors or fresh inferior mesenteric veins from paternal donors. Among patients with PV complications, the rate of PV

anastomosis with vein grafts was high (33%) in this series. Therefore the use of a vein graft remains a risk factor for PV complications. The graft-versus-recipient body weight ratio was significantly larger with the median of 3.1% among the patients with PV complications, which means that this ratio is a risk factor for a PV complication. The frequency of diagnosis of PV complications was high in the first year, followed by the second to fifth years after LDLT. As to the symptoms and signs of a PV complication, gastrointestinal bleeding, splenomegaly, and/or liver dysfunction were confirmed as previously observed in patients with PV complications. One of the most characteristic findings was a decreased platelet count. Significant recovery of the platelet count was observed in all patients with successful venoplasty at 6 months to 1 year after treatment. Thrombocytopenia was a distinctive feature of chronic liver dysfunction with fibrotic changes.

PV obstruction in the long-term course was rare in our series (2%). However, two patients received re-LDLT due to graft dysfunction with biliary cirrhosis. In patients with long-term PV obstruction after liver transplantation, ischemic damage to the hepatic parenchyma and ischemic biliary pathology may cause biliary cirrhosis of the graft, even though cavernous formation of the PV developed around the obstructed PV. Even when hepatic grafts are free from severe fibrosis, portosystemic shunt may cause an intrapulmonary shunt or pulmonary hypertension, as observed in one patient with moderate fibrotic changes in the liver graft and with moderate intrapulmonary shunt. With the progress of hepatopulmonary syndrome, retransplantation may be required. One patient with long-term PV obstruction already showed severe pulmonary hypertension when diagnosed, which exceeded the application of retransplantation at the moment.

To avoid graft loss from ischemia-induced biliary cirrhosis or to avoid the severe complication of hepatopulmonary syndrome requiring retransplantation, early detection of a PV complication is essential. Platelet counts and spleen size should be monitored regularly in the long-term follow-up of pediatric patients after LDLT, combined with regular evaluation of PV flow by Doppler ultrasonography, to detect a PV complication early and avoid graft loss.

#### REFERENCES

1. Broelsch CE, Whittington PF, Edmond JC, et al: Liver transplantation in children from living related donors: surgical techniques and results. *Ann Surg* 213:428, 1991
2. Tokunaga Y, Tanaka K, Yamaoka Y, et al: Portal vein graft in living related hepatic transplantation. *J Am Coll Surg* 178:297, 1994
3. Tanaka K, Uemoto S, Tokunaga Y, et al: Surgical techniques and innovations in living related liver transplantation. *Ann Surg* 217:82, 1992
4. Marwan IK, Fawzy ATI, Egawa H, et al: Innovative techniques for and results of portal vein reconstruction in living-related liver transplantation. *Surgery* 125:265, 1999
5. Buell JF, Funaki B, Cronin DC, et al: Long-term venous complications after full-size and segmental pediatric liver transplantation. *Ann Surg* 236:658, 2002



## New Protocol of Immunosuppression for Liver Transplantation Across ABO Barrier: The Use of Rituximab, Hepatic Arterial Infusion, and Preservation of Spleen

A. Yoshizawa, S. Sakamoto, K. Ogawa, M. Kasahara, K. Uryuhara, F. Oike, M. Ueda, Y. Takada, H. Egawa, and K. Tanaka

### ABSTRACT

**Introduction.** An ABO-incompatible (ABO-I) living donor liver transplantation (LDLT) is a challenge. Until 2000 systemic multidrug immunosuppression and splenectomy was the gold standard with poor results. Application of local administration with prostaglandin E1 (PGE1) and steroids via a portal vein (PV) catheter dramatically improved the survival from 20% to 60% but PV thrombus became a problem (35%). To solve it, an hepatic arterial (HA) catheter was used instead of a PV catheter and splenectomy was omitted. Although the PV thrombus problem was resolved, the ABO antibody titers significantly increased, and two cases of uncontrollable humoral rejection (HR) were experienced. In this study, Rituximab was introduced instead of splenectomy to decrease the antibody. We report the efficacy of prophylaxis with Rituximab for ABO-I LDLT.

**Methods.** Eight patients received Rituximab at 2 to 14 days before LDLT. During the operation, the spleen was preserved. Methylprednisolone and PGE1 were administered via an HA catheter for 2 to 3 weeks after LDLT in addition to an immunosuppressive regimen consisting of tacrolimus and steroids. Antibody titers were measured serially.

**Result.** There was no clinical HR. Two patients died of complications unrelated to HR. The antibody titer decreased compared to patients without splenectomy/rituximab. B cells (CD19) were depleted from peripheral blood for up to 3 months. Cytomegalovirus infections were decreased compared to patients with splenectomy ( $P = .085$ ).

**Conclusion.** Rituximab prophylaxis and HA infusion therapy prevented clinical HR, which may provide a breakthrough to overcome the ABO blood-type barrier in liver transplantation.

**I**N JAPAN, LIVING DONOR transplantation (LDLT) is sometimes the only available option for patients with end-stage liver disease because brain-dead donors are rare. In LDLT donor selection is limited to relatives. When the only available graft is ABO-incompatible (ABO-I), liver transplantation must be performed across the ABO blood-type barrier. ABO-incompatibility has a big impact in living donor LDLT especially among adult recipients (over 16 years old).<sup>1</sup> Until 2000, the gold standard for ABO incompatibility was plasmapheresis, systemic use of multiple immunosuppressive drugs and splenectomy; the 5-year survival was poor (22%). Local administration of prostaglandin E1 (PGE1), steroid, and Gabexate Mesilate via portal vein (PV) catheter, as introduced by Keio University<sup>2</sup>

remarkably improved the results (60%). Hepatic arterial (HA) infusion therapy in addition to PV infusion improved the 1-year survival to 85.7%. However, these cases showed frequent PV thrombosis (37.5%), which was assumed to be due to the PV catheter and the splenectomy. To resolve it, HA infusion therapy without a PV catheter or splenectomy was used, but the anti-ABO antibody titer significantly

From the Kyoto University Graduate School of Medicine, Department of Transplantation and Immunology, Kyoto, Japan. Address reprint requests to Atsushi Yoshizawa, Kyoto University Graduate School of Medicine, Department of Transplantation and Immunology, 54 Kawara-Cho, Shougoin, Sakyo-Ku, KYOTO, Japan 606-8507. E-mail: ayoshi14@kuhp.kyoto-u.ac.jp

0041-1345/05/\$-see front matter  
doi:10.1016/j.transproceed.2005.03.148

© 2005 by Elsevier Inc. All rights reserved.  
360 Park Avenue South, New York, NY 10010-1710

increased and two cases showed uncontrollable total hepatic necrosis. In this study, Rituximab instead of splenectomy was introduced to decrease the antibody. We report the efficacy of prophylaxis with Rituximab for ABO-I LDLT.

#### MATERIALS AND METHODS

##### Patients

The eight patients involved in this study were aged 29 to 65 years including seven women. The original diseases were four cirrhosis, three primary biliary cirrhosis, one Wilson's disease. The mean observation period was 3.6 months (range 2 to 7 month).

##### Protocol

At 2 to 14 days before transplantation, one dose of rituximab (375 mg/m<sup>2</sup>) was administered. Before LDLT, plasmapheresis was performed to reduce the anti-ABO antibody to less than 1:8 at transplantation. During the operation, the spleen was preserved, and an HA catheter inserted. After operation, PGE1 (0.01  $\gamma$ ) and methylprednisolone (125 mg/body) were administered through the HA catheter for 2 to 3 weeks. Systemic immunosuppression consisted of tacrolimus, methylprednisolone, and cyclophosphamide (2 mg/kg/d intravenous for 2 weeks, and oral by for another 2 weeks). The antibody titer was serially examined, and a liver biopsy performed when liver function tests were elevated. Statistical analysis was performed by 2 student *t* or chi-square tests.

#### RESULT

There was no clinical humoral rejection, hepatic necrosis, or intrahepatic biliary complications. The peak anti-ABO antibody titer after LDLT was  $252.6 \pm 356$  and  $162.6 \pm 175.1$  for IgM and IgG, respectively. The peak titer decreased, though it showed no significant difference compared to the titers observed with infusion therapy without splenectomy ( $580 \pm 1099$  vs  $375 \pm 693$ ;  $P = .31$ ). Rejection was observed in three cases (38%) with no significant difference between HA infusion therapy with/without splenectomy. Two recipients died of complications, aspiration pneumonia and intestinal perforation, which were not directly related to humoral rejection. The 38% incidence of cytomegalovirus disease was significantly less than that of patients with splenectomy (81%;  $P = .018$ ).

#### DISCUSSION

Fatal complications attributed to ABO-I liver transplantation are hepatic necrosis and intrahepatic biliary complication, evidences of clinical humoral rejection. This process leads to circulation disturbances due to local DIC caused by an antibody-complement reaction. In this study histological evidence of humoral rejection was defined by signs of periportal edema and necrosis.<sup>3</sup> There was a correlation between clinical/histological humoral rejection and the anti-ABO antibody titer. The ABO-related humoral immune response is activated for 1 to 3 weeks after liver transplantation, and then naturally decreases. It is important to control humoral immune response, that is, to decrease the ABO antibody titers immediately after LDLT. Splenectomy decreases antibody titers but may cause permanent immunodeficiency as well as PV thrombosis. So splenectomy may become a risk factor for infectious diseases such as viral infections. In this regard, prophylactic rituximab is preferable because it is reversible immunosuppression.

After up-regulation of humoral immune response, the use of rituximab rescue was not effective to decrease antibody titers and prevent progression of clinical humoral rejection in our experience. In contrast prophylaxis by rituximab for ABO-I LDLT was not equivalent to splenectomy. We must consider the mode of delivery, timing, any dosage of rituximab, but this protocol successfully prevented clinical humoral rejection. In conclusion, prophylactic rituximab and HA infusion therapy may become a standard protocol for ABO-I LDLT.

#### REFERENCES

1. Egawa H, Oike F, Buhler L, et al: Impact of recipient age on outcome of ABO-incompatible living-donor liver transplantation. *Transplantation* 77:403, 2004
2. Tanabe M, Shimazu M, Wakabayashi G, et al: Intraportal infusion therapy as a novel approach to adult ABO-incompatible liver transplantation. *Transplantation* 73:1959, 2002
3. Haga H, Egawa H, Shirase T, et al: Periportal edema and necrosis as diagnostic histological features of early humoral rejection in ABO-incompatible liver transplantation. *Liver Transpl* 10:16, 2004

## Living-Donor Liver Transplantation for Hepatoblastoma

Mureo Kasahara<sup>a,\*</sup>, Mikiko Ueda<sup>b</sup>, Hironori Haga<sup>a</sup>, Hidefumi Hiramatsu<sup>c</sup>, Michihiro Kobayashi<sup>c</sup>, Souichi Adachi<sup>c</sup>, Seisuke Sakamoto<sup>b</sup>, Fumitaka Oike<sup>b</sup>, Hiroto Egawa<sup>a</sup>, Yasutsugu Takada<sup>b</sup> and Koichi Tanaka<sup>a,b</sup>

<sup>a</sup> Organ Transplant Unit, Department of Transplant Surgery, Kyoto University Hospital, Kyoto, Japan

<sup>b</sup> Department of Transplant Surgery, Kyoto University Hospital, Kyoto, Japan

<sup>c</sup> Department of Pediatrics, Kyoto University Hospital, Kyoto, Japan

\* Corresponding author: Mureo Kasahara, mureo@kuhp.kyoto-u.ac.jp

Hepatoblastoma is the most common malignant liver tumor in children. Recently, liver transplantation has been indicated for unresectable hepatoblastoma. We retrospectively reviewed 14 children with a diagnosis of hepatoblastoma who had undergone living-donor liver transplantation (LDLT) at Kyoto University Hospital. During the period from June 1990 to December 2004, 607 children underwent LDLT. Of these interventions, 2.3% were performed for hepatoblastoma. Based on radiological findings, the pre-treatment extent of disease (PRETEXT) grouping was used for pre-treatment staging of the tumor. There were grade III in seven patients and grade IV in seven patients. Thirteen patients received chemotherapy, and seven underwent hepatectomy 11 times. Immunosuppressive treatment consisted of tacrolimus monotherapy in 11 patients. Actuarial 1- and 5-year graft and patient survival rates were 78.6% and 65.5%. The poor prognostic factors were macroscopic venous invasion and extrahepatic involvement with 1-year and 5-year survival rates of 33.0% and 0%. Pediatric patients without these factors showed an acceptable 5-year survival rate of 90.9%. LDLT provides a valuable alternative with excellent results in children with hepatoblastoma because it allows optimal timing of the liver transplantation, given the absence of delay between the completion of chemotherapy and planned liver transplantation.

**Key words:** Chemotherapy, hepatectomy, hepatoblastoma, living donor, liver transplantation

Received 10 March 2005, revised 19 April 2005 and accepted for publication 28 April 2005

### Introduction

Hepatoblastoma is the most common malignant liver tumor in children, and is seen mostly in patients aged 2 years and under. Congenital anomalies are present in 5.5% of patients with hepatoblastoma (1). While a variety of histological patterns are noted, prognosis is primarily dependent on the surgical resectability of the tumor, with an overall survival rate of approximately 60%. Prognosis is better with the fetal-predominant type than with other types (2). Through combined improvements in imaging, surgical resection and systemic chemotherapy, higher survival rates have been achieved. While disease-free patient survival rates have been dramatically improved by cisplatin chemotherapy regimens, liver transplantation remains an alternative curative treatment for patients whose liver tumor is unresectable following systemic chemotherapy or radical hepatectomy (3,4). Initial studies of liver transplantation in children with unresectable hepatoblastoma report a 50% survival rate. While tumor recurrence was the most common cause of patient death, most of these patients had not received adjuvant chemotherapy (5,6).

Over the last decade, living-donor liver transplantation (LDLT) has become the primary therapeutic modality for end-stage liver disease in children (7). LDLT provides a valuable alternative in children with hepatoblastoma because it allows optimal timing of the liver transplantation, given that there is no delay between the completion of chemotherapy and the planned liver transplantation. We report here the long-term outcome of 14 children with hepatoblastoma who underwent LDLT at Kyoto University Hospital, Kyoto, Japan.

### Patients and Methods

During the period from June 1990 to December 2004, 607 children (aged under 15 years) underwent LDLT at Kyoto University Hospital. Of these children, 14 (2.3%) underwent transplantation due to hepatoblastoma. All children (10 boys and four girls; age range: 9 months–12 years) underwent serial contrast-enhanced computed tomography (CT), magnetic resonance imaging and bone scanning to assess both response to treatment and extrahepatic disease. Ten children underwent liver biopsy at the time of presentation. Two congenital anomalies were presented: biliary atresia (case 4) and absence of inferior vena cava (IVC) (case 7). All patients had elevated alpha-fetoprotein (AFP) levels at the time of diagnosis, which ranged from 2619–2 700 000 ng/mL (normal range: <15 ng/mL). The overall follow-up

period ranged from 6 to 81 months, and the median follow-up for the survivors was 42 months.

Thirteen children, except for a child with biliary atresia, received preoperative chemotherapy. Each child received from 2 to 17 cycles of chemotherapy (median: six cycles) before LDLT in an attempt to shrink the primary tumor and eliminate micrometastatic disease (Table 1). Preoperative chemotherapy protocol using a combination of cisplatin (CDDP) and tetrahydropyridoxorubicin (Adriamycin®) [THP-ADR]; Japanese study group for pediatric liver tumor protocol-1 (JPLT-1) was indicated as an initial protocol in 13 cases (8,9). Eight children (cases 2, 3, 7, 8, 11, 12, 13 and 14) showed poor response to JPLT-1 chemotherapy. An additional protocol using a combination of ifosfamide (IFO), carboplatin (CBDCA), THP-ADR and etoposide (VP-16®) [JPLT-2] was initiated in five patients (cases 1, 11, 12, 13 and 14). Three children (cases 5, 7 and 12) underwent autologous peripheral blood stem cell transplantation after undergoing high-dose chemotherapy using a combination of IFO, etoposide, CBDCA and melphalan (L-PAM) (Hi-MEC protocol) or IFO, etoposide, L-PAM and thiotepa (Hi-MT protocol) proposed by the JPLT group (9,10). If the patient showed sufficient response and no dose-dependent side effects to preoperative chemotherapy, the same preoperative chemotherapy regimen was adapted postoperatively. If not, irinotecan (CPT-11) was used as a postoperative chemotherapy.

Before referral to Kyoto University Hospital, seven children underwent hepatectomy 11 times after systemic chemotherapy. Liver resections performed included three right hepatectomies; two right trisectionectomies; two left hepatectomies and four nonanatomical tumor nucleations. Seven children had disease recurrence in the liver after prior resection, and further resection was not possible. Case 4 with biliary atresia had undergone Kasai's porto-enterostomy at the age of 47 days (11). The patient presented with liver failure, pathological fractures and growth retardation. The liver tumor was diagnosed by CT scan just before LDLT. Three children (cases 3, 13 and 14) showed the tumor invasion to all four sectors of the liver after chemotherapy, and two children (cases 6 and 9) showed close proximity to hepatic vessels. These children remained to have unresectable hepatoblastoma. In summary, seven children underwent 'primary' liver transplantation and seven underwent 'rescue' liver transplantation.

The indication for transplantation was unresectable liver tumor in 12 patients, acute liver failure after systemic chemotherapy in one patient (case 1) and biliary cirrhosis associated with extrahepatic biliary atresia in another patient. Case 1 received six cycles of chemotherapy, thereafter the patient showed hyperbilirubinemia, hyperammonemia and coagulopathy. Despite the conventional treatment with blood exchange, the patient's condition deteriorated and LDLT was indicated for acute liver failure. The PRETEXT system based on radiological findings was used for clinical grouping of hepatoblastoma (12). According to PRETEXT staging system, a tumor occupying 1, 2, 3 or 4 adjacent liver sector is defined as PRETEXT I, II, III or IV, respectively. The PRETEXT grouping was III and IV in seven patients and in seven patients, respectively. All the children were judged to have an unresectable tumor after laparotomy. Case 2 showed a major portal vein tumor thrombus, case 3 revealed suspected tumor involvement of the stomach and case 11 showed suspected hilar lymph node swelling and direct IVC invasion, which was completely resectable together with total hepatectomy. The median interval between onset of hepatoblastoma and LDLT was 12 months (range: 2–59 months). The median interval between the last cycle of chemotherapy and LDLT was 23 days (range: 15–44 days).

The potential live donor candidates were evaluated through the use of liver function tests; determination of blood type; human leucocyte antigen typing and determination of anatomical variation and graft size using 3D-CT volumetry. There were four blood-type compatible and 10 identical grafts. Graft type was selected according to the graft-to-recipient weight ratio

Table 1: Clinical data on 14 children undergoing living-donor liver transplantation for hepatoblastoma

Patient	Age/Sex	Serum AFP at diagnosis	PRETEXT group	Pre-LDLT operation	Pre-LDLT initial chemotherapy	Serum AFP at LDLT	Donor age (years)	Relation	Graft type	GRWR (%)
1	9 m/M	677 400	III	None	CDDP+THP-ADR	4390	35	Father	LLS	6.83
2	7 y/M	529 000	IV	Right hepatectomy	CDDP+THP-ADR	54 700	37	Mother	Left	1.52
3	2 y/M	590 000	IV	None	CDDP+THP-ADR	5749	27	Father	LLS	2.50
4	4 y/F	12 900	III	Kasai	None	12 924	30	Father	LLS	2.32
5	10 y/M	2600	IV	Right trisectionectomy	CDDP+THP-ADR#	383	47	Father	Left	1.22
6	3 y/F	1 500 000	IV	None	CDDP+THP-ADR	10	40	Father	LLS	1.50
7	5 y/M	15 000	III	Right hepatectomy	CDDP+THP-ADR+VP-16#	37	29	Mother	LLS	1.63
8	6 y/M	2 700 000	IV	Right trisectionectomy, S3	CDDP+THP-ADR	1411	32	Mother	Left	1.32
9	4 y/M	266 000	IV	None	CDDP+THP-ADR	7040	25	Father	LLS	1.07
10	12 y/M	36 200	III	Left hepatectomy	CDDP+THP-ADR	113	40	Mother	Left	0.96
11	3 y/F	887 800	IV	Right lo hepatectomy, S3, S4	CDDP+THP-ADR	170 910	31	Father	LLS	1.65
12	9 y/M	3800	III	Left hepatectomy, S8	CDDP+THP-ADR+VP-16#	12	44	Father	LLS	2.29
13	11 m/F	1 000 000	III	None	CDDP+THP-ADR	7008	41	Mother	Mono	3.08
14	4 y/M	1 880 000	III	None	CDDP+THP-ADR	1 175 690	29	Mother	LLS	1.60

LDLT, living-donor liver transplantation; AFP, alpha-fetoprotein; PRETEXT, pre-treatment extent of disease based on radiological findings; GRWR, graft-to-recipient weight ratio; CDDP, cisplatin; THP-ADR, tetrahydropyridoxorubicin; LLS, left lateral segment; VP-16, etoposide; #with blood stem cell transplantation.

(GRWR) (13). The graft types were one monosegmental graft (segment III), nine left lateral segments and four left lobe grafts (Table 1). All the donors were discharged from the hospital within 12 days after donation without complications.

Immunosuppression consisted of tacrolimus monotherapy in 11 patients, and tacrolimus and low-dose steroid therapy in three. Methylprednisolone was only given at the time of graft reperfusion intraoperatively (10 mg/kg). Low-dose steroid therapy was tapered off on postoperative days 19, 45 and 40 in cases 4, 5 and 9, respectively. Tacrolimus administration was started from 1 day before transplantation, except for one patient with acute liver failure (case 1). Target whole blood trough level of tacrolimus was 10–12 ng/mL for the first 2 weeks, approximately 10 ng/mL for the following 2 weeks and 5–10 ng/mL thereafter.

This study was approved by the institutional review board and informed consent was obtained in all the cases.

**Results**

Serum AFP level at LDLT were in the range of 9.5–1 175 690 ng/mL (median: 5070 ng/mL). All patients underwent LDLT using a standard procedure (14). Biliary reconstruction was achieved using Roux-en-Y hepaticojejunostomy in 11 patients and duct-to-duct anastomosis in three. The duct-to-duct biliary anastomosis was started at the posterior wall with continuous suture, after which the interrupted anterior anastomosis was completed with magnificent glasses. All patients received hilar lymph node dissection, and the hilar lymph node was positive in case 11. Hilar vascular dissection was performed before mobilization of the native liver to prevent the spread of malignant cells.

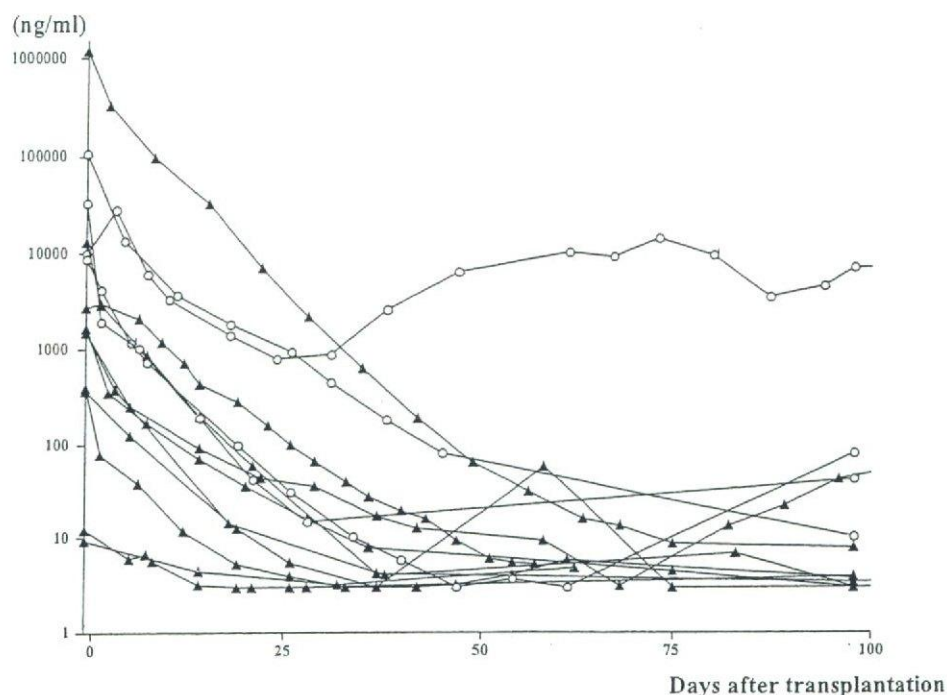
At the time of transplantation, case 3 had an exophytic extension of the primary tumor involving the stomach. This child underwent complete resection of the extrahepatic extension including resection of the body of stomach at the time of transplantation. Case 11 showed direct IVC invasion and hilar lymph node metastasis. The liver and involved IVC were removed and the graft hepatic vein was directly anastomosed with the suprahepatic IVC in end-to-end fashion, given that the IVC was not reconstructed. Case 7 showed congenital absence of IVC. The left and middle hepatic vein was directly drained to right atrium. The left hepatic vein of graft to left and middle hepatic vein anastomosis was made. Venovenous bypass or portocaval shunt was not used in any of the cases. Duration and blood loss of the recipient operation was 691.8 ± 178.3 min (range: 426–1086 min) and 851.7 ± 445.4 g (range: 210–1870 g). Cold and warm ischemic times were 50 ± 31 min and 39.3 ± 7.3 min, respectively.

Histopathological examination of the explanted liver is listed in Table 2. There were six embryonal, four fetal, three embryonal and fetal, and one microtrabecular pattern. Twelve patients (85.7%) showed vascular invasions. Two children showed macrovascular invasion: case 2 in segment III portal vein, and case 11 in the IVC.

**Table 2:** Outcomes of 14 children receiving living-donor liver transplantation for hepatoblastoma

Patient	Histology Type	Vascular invasion	Complications	Adjuvant chemotherapy	Follow-up time (months)	Latest serum AFP	Current status
1	Microtrabecular	Hepatic vein	None	CPM+5-FU	9	43	Died on POD 280 (recurrence)
2	Embryonal	Hepatic and portal vein	None	CPM+CBDCA+VP-16+L-PAM#	32	10.4	Died on POD 960 (recurrence)
3	Embryonal	Hepatic and portal vein	None	CBDCA+VP-16+5-FU	11	81	Died on POD 330 (recurrence)
4	Embryonal	Portal vein	None	CBDCA+THP-ADR	81	3.5	ANED
5	Fetal	None	None	CBDCA+THP-ADR	794	3.9	ANED
6	Fetal	None	None	CDDP+THP-ADR	67	3	ANED
7	Embryonal and fetal	Portal vein	Intra abdominal bleeding	CPM	55	3	ANED
8	Embryonal	Portal vein	Biliary stricture		42	3	ANED
9	Embryonal	Hepatic and portal vein	Biliary stricture	CDDP+THP-ADR	36	3	ANED
10	Fetal	Hepatic and portal vein	Biliary stricture	CBDCA+VP-16	21	3	ANED
11	Embryonal	Hepatic and portal vein	Intestinal perforation	CPT-11	6	300	Died on POD 202 (recurrence)
12	Fetal	Portal vein	Biliary leakage	CPT-11	17	4	ANED
13	Embryonal and fetal	Portal vein	Biliary stricture	CPT-11	8	4.5	ANED
14	Embryonal and fetal	Hepatic and portal vein	None	CPT-11	6	8.1	ANED

AFP, alpha-fetoprotein; CPM, cyclophosphamide; 5-FU, fluorouracil; POD, postoperative day; CBDCA, carboplatin; VP-16, etoposide; L-PAM, melphalan; #with blood stem cell transplantation and partial hepatectomy; THP-ADR, tetrahydropyranyl-doxorubicin; ANED, alive with no evidence of disease; CDDP, cisplatin; CPT-11, irinotecan.



**Figure 1: Serum alpha-feto level after-fetoprotein levels after living-donor liver transplantation.** Open circle: Child with tumor recurrence, Closed triangle: Child without tumor recurrence.

The post-LDLT course was uneventful in seven children. Two children required a laparotomy for intra-abdominal bleeding on day 6 (case 7) and intestinal perforation on day 6 (case 11), but then made a complete recovery. Five children (35.7%) had biliary complications. Three children with duct-to-duct biliary reconstruction showed biliary stricture (cases 9 and 10) and leakage (case 12). Two of them (cases 9 and 12) required conversion to Roux-en-Y biliary anastomosis on days 350 and 29, respectively. A further three patients with biliary stricture (cases 8, 10 and 13) were successfully managed with radiological intervention.

Five children (35.7%) experienced histologically proven acute cellular rejection, and this was successfully treated with steroid bolus injection therapy. Thereafter, no further maintenance doses of steroids were given in these cases. Cases 5 and 7 had achieved withdrawal from immunosuppressive therapy at postoperative years 5 and 3, respectively.

Postoperative adjuvant chemotherapy was performed in 13 patients (Table 2). CDDP (or CBDCA) and THP-ADR was used in four cases, CBDCA and etoposide in three, cyclophosphamide in two and irinotecan (CPT-11) in the remaining four. Postoperative chemotherapy was started on median day 33 (range: 0–150 days); this was dependent

on the postoperative condition of the patient. Four patients (cases 1, 2, 3 and 11) died from tumor recurrence on days 280, 960, 330 and 202 after LDLT, respectively. Case 2, who showed tumor recurrence in the graft liver, received partial hepatectomy after high-dose chemotherapy and stem cell transplantation 16 months after LDLT. Cases 1, 3 and 11 showed multiple lung metastasis at postoperative months 6, 2 and 2, respectively.

Ten children are doing well, showing normal graft function and no evidence of tumor recurrence was found at a median follow-up after LDLT of 42 months. Postoperative AFP levels are shown in Figure 1. Serum AFP level was decreased in all of our cases just after LDLT. Consequently, actuarial 1- and 5-year graft and patient survival rates were 78.6% and 65.5%, respectively (Figure 2). The better patient survival was seen in the fetal type than the other types (100% vs. 50.0% in 5-year survival), however, no statistical difference was found among the histological types. There was no significant difference in the patient survival regarding PRETEXT grouping, history of previous hepatectomy, response to preoperative chemotherapy and serum AFP levels. However, children with macroscopic vascular extension and extrahepatic organ involvement were shown to have significantly worse patient 1- and 5-year survival rate: 33.3% vs. 90.9%, and 0% vs. 90.9% ( $p < 0.01$ ), respectively.



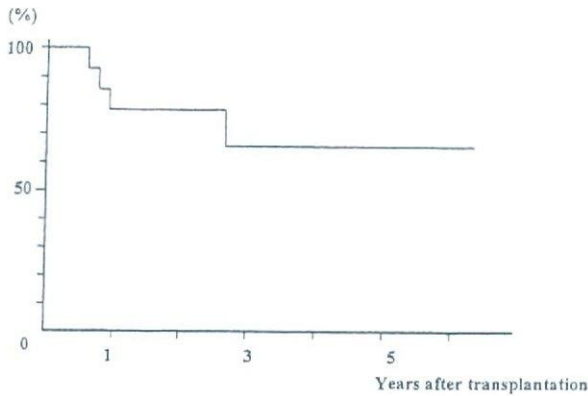


Figure 2: Patient survival after living-donor liver transplantation.

## Discussion

The aim of this study was to evaluate the outcome of children who underwent LDLT as a curative treatment for hepatoblastoma at Kyoto University. To the best of our knowledge, this is the first report on long-term follow-up of LDLT for hepatoblastoma.

The administration of an optimal chemotherapy regimen such as the JPLT protocol in this study has substantially improved the outcome of children with hepatoblastoma with a 6-year survival rate of 73.4% (9). Although adjuvant chemotherapy makes the primary tumor resectable in 75–85% of the cases, factors still remain which limit the possibility of undergoing radical resection: invasion of main vascular trunks; extension of the tumor to all hepatic lobes; poor response to chemotherapy and intrahepatic recurrence (15). Based on the findings of a previous study that the multifocal hepatoblastoma may arise from multiple foci of genetically altered embryonal liver cells, total hepatectomy with liver transplantation might be an attractive treatment modality for unresectable hepatoblastoma (16).

In this study, LDLT was indicated in 14 children with unresectable hepatoblastoma with or without extrahepatic involvement after several courses of adjuvant chemotherapy. The actual 1- and 5-year survival rates are 78.6% and 65.5%, respectively, which are comparable with survival rates following both radical resection and deceased liver transplantation (6,9,15–18). Four children (28.6%) died from tumor recurrence after LDLT.

Patient selection might be crucial in determining the efficacy of liver transplantation for hepatoblastoma. PRETEXT grouping, history of previous hepatectomy, response to preoperative chemotherapy, histology of hepatoblastoma and serum AFP levels were not a prognostic factor in the present series. Contrary to the previous report from

the Pittsburgh experience, macroscopic venous invasion (cases 2 and 11) and extrahepatic involvements (cases 3 and 11) were shown to be poor prognostic factors, with 1- and 5-year survival rates of 33.0% and 0%, respectively (17). The children without these factors showed an acceptable 5-year survival rate of 90.9%. Although the number of patients included in this study was limited and the follow-up period was too short to enable any valid conclusions to be drawn, these results suggest that macroscopic venous invasion and extrahepatic involvement at the time of transplantation might be considered as relative contraindications for liver transplantation in hepatoblastoma.

Postoperative biliary complications were observed in five children (35.7%), which is higher than the incidence in children undergoing LDLT for other indications (19). In this study, all of the children with duct-to-duct biliary reconstruction had biliary complications. Because of radical hilar lymph node dissection during transplant surgery, an insufficient blood supply to the native common bile duct may have induced an increased incidence of biliary complications in pediatric hepatoblastoma patients with duct-to-duct anastomosis. Our current preference is to use the Roux-en-Y hepaticojejunostomy for children with hepatoblastoma.

Postoperative immunosuppression consisted of tacrolimus monotherapy or tacrolimus with early steroid withdrawal in this study. Steroid-free immunosuppression may reduce opportunistic infections and malignancies in already immunocompromised children with hepatoblastoma due to reiterated preoperative chemotherapy (20,21). There is no difference among the type of immunosuppression received in post-transplant tumor recurrence, and the potential benefits of steroid-free immunosuppression on hepatoblastoma recurrence require further evaluation.

The necessity of post-transplant chemotherapy remains an open debate. It was reported that 30% of children with localized hepatoblastoma developed recurrent disease after complete resection (22). In the present series, 85.7% of the children had vascular invasion, and it is possible that manipulating of the malignant cells when handling the native liver during transplantation provoked micrometastasis. In this respect, post-transplant chemotherapy should be done in all patients. It is sometimes difficult to adapt the preoperative chemotherapy regimen postoperatively, because of side effects such as cardiac, renal and hearing impairment. Recently, the efficiency of irinotecan (CPT-11) for hepatoblastoma with significant anti-tumor effects was reported (23–26). We used novel protocol with irinotecan (CPT-11) in four patients, a patient who showed poor response to the preoperative chemotherapy regimen. The following irinotecan (CPT-11) regimen was used: irinotecan (CPT-11) infusion of 20 mg/m<sup>2</sup>/day on days 1–5, repeated every 7 days for 2 weeks. A minimum of three cycles of chemotherapy was given post-transplantation. Whereas myelosuppression and diarrhea have been the

dose-limiting toxicities, all four children in the present series tolerated therapy, even when immunosuppressive therapy was administered (27).

Concern existed that survival was highly unlikely in the present children without liver transplantation, and that additional time without chemotherapy while waiting for the tumor to become evident would allow for the further dissemination of the tumor, which might then contraindicate transplant surgery. LDLT provides adequate timing of transplant surgery: in this study, the median interval between the last cycle of chemotherapy and LDLT was 23 days. Chemotherapy may play a role to prevent regrowth of the tumor while the child is awaiting transplantation (28).

Recently, Otte et al. reported the world experience of liver transplantation for hepatoblastoma, and demonstrated that the survival of 'primary' liver transplantation is superior to 'rescue' liver transplantation. Liver transplantation should be considered for every child presenting with unresectable disease (29). We agree with this suggestion that heroic attempts at partial hepatectomy surgery should be avoided. However, it was reported that children with recurrent hepatoblastoma could sometimes be treated with aggressive hepatectomy, and that high-dose chemotherapy with peripheral blood stem cell transplantation provided curative potential in some patients (9,30). The present study demonstrated that history of previous hepatectomy ('rescue' liver transplantation) was not a prognostic factor after LDLT. The results seen here suggest that aggressive hepatectomy following chemotherapy with or without peripheral blood stem cell transplantation might be one potential treatment modality prior to liver transplantation. The JPLT-2 protocol study using high-dose chemotherapy with stem cell rescue is currently underway to draw a definite conclusion about this treatment modality (9). Priority is given to aggressive hepatectomy combined with chemotherapy; accordingly, when conventional resection seems too difficult, the patient should be proposed for transplantation, as recommended by Pimpalwar et al. (15).

In conclusion, LDLT was indicated in 14 children with hepatoblastoma, but better results after LDLT are desirable. Macroscopic venous invasion and extrahepatic involvements at the time of transplantation might be considered as relative contraindications for liver transplantation in hepatoblastoma. Extensive investigations are essential to understand the factors leading to tumor recurrence after LDLT and, more importantly, to identify prognostic factors in children with hepatoblastoma.

## Acknowledgments

This work was supported in part by grants from the Scientific Research Fund of the Ministry of Education and by a Research Grant for Organ Transplant from the Ministry of Health and Welfare, Japan.

## References

1. Stocker JT, Ihsak KG. Hepatoblastoma. In: Okuda K, Ishak KG, eds. Neoplasms of the liver. New York: Springer-Verlag, 1987:127-136.
2. Stocker JT. Hepatic tumors in children. In: Suchy FJ, ed. Liver disease in children. Missouri: Mosby-Year Book, 1994:901-928.
3. Stringer MD, Hennayake S, Howard ER et al. Improved outcome for children with hepatoblastoma. *Br J Surg* 1995; 82: 386-391.
4. Ninane J, Perilongo G, Stalens JP et al. Effectiveness and toxicity of cisplatin and doxorubicin (PLADO) in childhood hepatoblastoma and hepatocellular carcinoma: a SIOP pilot study. *Med Pediatr Oncol* 1991; 19: 199-203.
5. Penn I. Hepatic transplantation for primary and metastatic cancers of the liver. *Surgery* 1991; 110: 726-735.
6. Koneru B, Flye MW, Busuttill RW et al. Liver transplantation for hepatoblastoma: the American experience. *Ann Surg* 1991; 213: 118-121.
7. Tanaka K, Uemoto S, Tokunaga Y et al. Surgical techniques and innovations in living related liver transplantation. *Ann Surg* 1993; 217: 82-91.
8. Sasaki F, Matsunaga T, Iwafuchi M et al. Outcome of hepatoblastoma treated with the JPLT-1 (Japanese Study Group for Pediatric Liver Tumor); a report from the Japanese study group for pediatric liver tumor. *J Pediatr Surg* 2002; 37: 851-856.
9. Suita S, Tajiri T, Mizote H et al. Improved survival outcome for hepatoblastoma based on an optimal chemotherapeutic regimen—a report from the study group for pediatric solid malignant tumors in the Kyusyu area. *J Pediatr Surg* 2004; 39: 195-199.
10. Matsunaga T, Sasaki F, Ohira M et al. Analysis of treatment outcome for children with recurrent or metastatic hepatoblastoma. *Pediatr Surg Int* 2003; 19: 142-146.
11. Tatekawa Y, Asonuma K, Uemoto S, Inomata Y, Tanaka K. Liver transplantation for biliary atresia associated with malignant hepatic tumors. *J Pediatr Surg* 2001; 36: 436-439.
12. Brown J, Perilongo G, Shafford E et al. Pretreatment prognostic factors for children with Hepatoblastoma—results from the International Society of Pediatric Oncology (SIOP). Study SIOPEL 1. *Eur J Cancer* 2000; 36: 1418-1425.
13. Kiuchi T, Kasahara M, Uryuhara K et al. Impact of graft-size mismatching on graft prognosis in liver transplantation from living donors. *Transplantation* 1999; 67: 321-327.
14. Tanaka K, Uemoto S, Tokunaga Y et al. Surgical techniques and innovations in living related liver transplantation. *Ann Surg* 1993; 217: 81-92.
15. Pimpalwar AP, Sharif K, Ramani P et al. Strategy for hepatoblastoma management: transplant versus nontransplant surgery. *J Pediatr Surg* 2002; 37: 240-245.
16. Schweinitz VD, Hecker H, Schmidt VAG et al. Prognostic factors and staging systems in childhood hepatoblastoma. *Int J Cancer* 1997; 74: 593-599.
17. Reyes JD, Caerr B, Dvorcibik I et al. Liver transplantation and chemotherapy for hepatoblastoma and hepatocellular cancer in childhood and adolescence. *J Pediatr* 2000; 136: 795-804.
18. Molmenti EP, Wilkinson K, Molenti H et al. Treatment of unresectable Hepatoblastoma with liver transplantation in the pediatric population. *Am J Transplant* 2002; 2: 535-538.
19. Egawa H, Inomata Y, Uemoto S et al. Biliary anastomotic complications in 400 living related liver transplantation. *World J Surg* 2001; 25: 1300-1307.
20. Lionakis MS, Kontoyianmis DP. Glucocorticoids and invasive fungal infections. *Lancet* 2003; 362: 1828-1838.

## Living-Donor Liver Transplantation for Hepatoblastoma

21. Padbury RT, Toogood GJ, McMaster P. Withdrawal of immunosuppression in liver allograft recipients. *Liver Transpl Surg* 1998; 4: 242-248.
22. Feusner JH, Haas JE, Campbell JR, Lloyd DA, Ablin AR. Treatment of pulmonary metastasis of initial stage I hepatoblastoma in childhood. Report from the children cancer group. *Cancer* 1993; 71: 859-864.
23. Katzenstein HM, Rigsby C, Shaw PH et al. Novel therapeutic approaches in the treatment of children with hepatoblastoma. *J Pediatr Hematol Oncol* 2002; 24: 751-755.
24. Palmer RD, Williams DM. Dramatic response of multiply relapsed hepatoblastoma to irinotecan (CPT-11). *Med Pediatr Oncol* 2003; 41: 78-80.
25. Nitschke R, Parkhurst J, Sullivan J et al. Topotecan in pediatric patients with recurrent and progressive solid tumors: a Pediatric Oncology Group phase II study. *J Pediatr Hematol Oncol* 1998; 20: 315-318.
26. Blaney S, Berg SL, Pratt C et al. A phase I study of irinotecan in pediatric patients: a pediatric oncology group study. *Clin Cancer Res* 2001; 7: 32-37.
27. Tubergen DG, Stewart CF, Pratt CB et al. Phase I trial and pharmacokinetic (PK) and pharmacodynamics (PD) study of topotecan using a five-day course in children with refractory solid tumors: a pediatric oncology group study. *J Pediatr Hematol Oncol* 1996; 18: 352-361.
28. Nakakura EK, Choti MA. Management of hepatocellular carcinoma. *Oncology* 2000; 14: 1085-1098.
29. Otte JB, Pritchard J, Aronson DC et al. Liver transplantation for hepatoblastoma: results from the international society of pediatric oncology (SIOP) study SIOPEL-1 and review of the world experience. *Pediatr Blood Cancer* 2004; 42: 74-83.
30. Yoshinari M, Imaizumi M, Hayashi Y et al. Peripheral blood stem cell transplantation for hepatoblastoma with microscopic residue: a therapeutic approach for incompletely resected tumor. *Tohoku J Exp Med* 1998; 184: 247-254.

# PHARMACODYNAMICS AND DRUG ACTION

## Pharmacodynamic analysis of tacrolimus and cyclosporine in living-donor liver transplant patients

**Background:** The calcineurin inhibitors tacrolimus and cyclosporine (INN, ciclosporin) have been widely used to prevent allograft rejection after transplantation. We investigated pharmacodynamic properties of the 2 drugs and their clinical relevance in liver transplantation.

**Methods:** Forty de novo living-donor liver transplant patients participated in this study, and they were treated with either tacrolimus (N = 30) or cyclosporine (N = 10). We simultaneously measured blood drug concentrations and calcineurin phosphatase activity in peripheral blood mononuclear cells during the first 14 postoperative days. Nephrotoxicity and acute rejection were also examined in relation to the blood drug concentrations and calcineurin activity.

**Results:** Calcineurin activity was only partially inhibited by tacrolimus concentrations greater than 20 ng/mL, although it could be almost completely inhibited by cyclosporine concentrations greater than 700 ng/mL. According to a maximum effect model, the population mean estimates of the EC<sub>50</sub> (blood concentration that yields a half-maximal effect) for tacrolimus and cyclosporine were 26.4 ng/mL (95% confidence interval [CI], 15.7-37.1 ng/mL) and 200 ng/mL (95% CI, 127-274 ng/mL), respectively. Patients with nephrotoxicity in both groups had significantly higher trough concentrations compared with those without this adverse event. In addition, patients with acute rejection in the tacrolimus group had significantly lower trough concentrations and higher calcineurin activity than those without a rejection episode.

**Conclusions:** The inhibitory effects on calcineurin activity in peripheral blood mononuclear cells differed between tacrolimus and cyclosporine in living-donor liver transplant patients. Pharmacodynamic assessment in combination with blood concentration monitoring may be useful for determining the individual therapeutic range of tacrolimus and cyclosporine. (Clin Pharmacol Ther 2005;78:168-81.)

Masahide Fukudo, MS, Ikuko Yano, PhD, Satohiro Masuda, PhD, Sachio Fukatsu, BS, Toshiya Katsura, PhD, Yasuhiro Ogura, MD, Fumitaka Oike, MD, Yasutsugu Takada, MD, Koichi Tanaka, MD, and Ken-ichi Inui, PhD *Kyoto, Japan*

Living-donor liver transplantation is now acknowledged as a life-saving therapy for patients with end-stage liver failure. Tacrolimus and cyclosporine (INN,

ciclosporin) have been cornerstone immunosuppressants in the prevention of acute rejections after liver transplantation.<sup>1,2</sup> They have a similar mechanism of action involving the formation of a complex with their

From the Department of Pharmacy, Kyoto University Hospital, and Department of Transplantation and Immunology, Graduate School of Medicine, Kyoto University.

This work was supported in part by the 21st Century COE Program "Knowledge Information Infrastructure for Genome Science"; by a grant in aid from the Japan Health Sciences Foundation; by a grant in aid for scientific research from the Ministry of Education, Culture, Sports, Science and Technology of Japan; and by Novartis Ciclosporin Pharmacology-Clinical Forum Research Grant 2004. Masahide Fukudo is a Research Fellow of the Japan Society for the Promotion of Science.

Received for publication December 15, 2004; accepted April 11, 2005.

Available online July 11, 2005.

Reprint requests: Ken-ichi Inui, PhD, Department of Pharmacy, Kyoto University Hospital, Sakyo-ku, Kyoto 606-8507, Japan.

E-mail: [inui@kuhp.kyoto-u.ac.jp](mailto:inui@kuhp.kyoto-u.ac.jp)

0009-9236/\$30.00

Copyright © 2005 by the American Society for Clinical Pharmacology and Therapeutics.

doi:10.1016/j.cpt.2005.04.008