

TABLE IV. Multivariate Analysis for Factors Influencing the Survival of Patients With HCV-Associated Cirrhosis

Factors	Category	Hazard ratio	95% Confidence interval	P-value
Albumin	<4.0 g/dl	1.65	1.25–1.65	<0.001
$\alpha$ -fetoprotein	>20 ng/ml	1.55	1.19–1.55	<0.001
Total alcohol	>500 kg	1.49	1.10–1.49	0.009
Age	>55 years	1.47	1.12–1.47	0.006
ICG R <sub>15</sub>	>30%	1.39	1.07–1.39	0.016

the survival tended to be better in patients infected with HBV of genotype C than B, the difference fell just short of being significant ( $P = 0.08$ ).

### DISCUSSION

There are an estimated 170 million people infected persistently with HCV [Cohen, 1999] and 350 million with HBV [Lee, 1997] in the world. In Japan alone, approximately one million patients are presumed to be infected with persistent HCV or HBV by surveys on first-time blood donors [Tanaka et al., 2004]. As on April 2002, a national program was launched for identifying persistent HCV and HBV infections in Japanese older than 40 years in a 5-year project. Since viral hepatitis progresses insidiously, cirrhosis will be diagnosed in many HCV and HBV carriers who are recognized during the survey. Hence, there is a pressing need to foretell the prognosis of cirrhotic patients in special terms of survival and development of hepatocellular carcinoma in them. The present study for long-term prognosis of cirrhotic patients was planned and conducted for such purposes. It is an extension to a previous study in 1993 in which 795 cirrhotic patients were evaluated for factors influencing the development of hepatocellular carcinoma [Ikeda et al., 1993].

Differences between HCV and HBV infections in terms of survival as well as development of hepatocellular carcinoma having emerged in the previous study [Ikeda et al., 1993] is confirmed and extended in the present study with new insights. To exclude any influence of antiviral treatment, only cirrhotic patients in the Child-Pugh class A who had not received antiviral treatment entered this study; they all were followed-up

for longer than 1 year after they were diagnosed with compensated cirrhosis. Overall incidence rates of yearly deaths in the 490 patients with HCV and the 167 with HBV were 6.3% and 3.6%, respectively, and those of hepatocellular carcinoma were 8.3% and 3.3% during observation periods ranging up to 20 years. When the yearly incidence of hepatocellular carcinoma was estimated by the Kaplan–Meier life-table method during the first 10 years, it was 6.0% for patients with HCV and 3.3% for those with HBV. The yearly incidence of hepatocellular carcinoma in cirrhotic patients with HCV at 8.3% in this study is compared with 7.0% in Taiwan [Tsai et al., 1997] as well as 5.9% in Spain [Planas et al., 2004], while it is much higher than 3% in France [Serfaty et al., 1998]. The incidence of hepatocellular carcinoma in those with HBV at 3.3%, however, is lower than 6.6% in Taiwan [Tsai et al., 1997] but much higher than 1.5–1.8% in European patients [Fattovich et al., 1995; Benvegna et al., 2004].

The influence of viral genotypes on the survival of patients with compensated cirrhosis was evaluated both in HCV and HBV infections. There were no appreciable differences in the survival between patients with HCV genotype 1 and non-1, in agreement with previous reports [Zhou et al., 1996; Serfaty et al., 1998]. It is surprising, however, that the survival tended to be better in patients with HBV genotype C than B ( $P = 0.08$ ), despite overwhelming evidence for HBV genotype C inducing more severe liver disease than HBV genotype B [Orito et al., 2001; Kao, 2002; Miyakawa and Mizokami, 2003]. This may have reflected a referral bias towards patients with advanced liver disease who would visit hospitals [Sumi et al., 2003]. Most patients infected with HBV genotype B

TABLE V. Univariate Analysis for Factors Influencing the Survival of Patients With HBV-Associated Cirrhosis

Factors	Category	Alive (n = 107)	Dead (n = 60)	Differences (P-value)
Age	>45 years	44 (41.1%)	34 (56.7%)	0.045
Gender	Male	74 (69.2%)	51 (85.0%)	0.003
HBeAg	Positive	45 (42.1%)	34 (56.7%)	0.004
Transfusion	Received	10 (9.3%)	5 (8.3%)	NS
Total alcohol	>500 kg	13 (12.1%)	13 (21.7%)	0.048
AST (U/L)	>77 U/L	20 (18.7%)	11 (18.3%)	NS
ALT (U/L)	>100 U/L	16 (15.0%)	10 (16.7%)	NS
Zinc turbidity test	>12	20 (18.7%)	18 (30.0%)	0.014
Albumin	>4.0 g/dl	78 (72.9%)	40 (66.7%)	0.009
Bilirubin	>1.5 mg/dl	11 (10.3%)	7 (11.7%)	NS
$\alpha$ -fetoprotein	>20 ng/ml	34 (31.8%)	24 (40.0%)	0.044
Platelets	<100 × 10 <sup>3</sup> /mm <sup>3</sup>	25 (23.4%)	27 (45.0%)	<0.001
ICG R <sub>15</sub>	>30%	12 (11.2%)	15 (25.0%)	<0.001

TABLE VI. Multivariate Analysis for Factors Influencing the Survival of Patients With HBV-Associated Cirrhosis

Factors	Category	Hazard ratio	95% Confidence interval	P-value
Gender	Male	4.43	1.72–11.44	0.002
Age	>45 years	2.24	1.27–3.95	0.005
ICG <sub>15</sub>	>30%	2.14	1.10–4.17	0.025
HBeAg	Positive	2.11	1.21–3.69	0.009
Platelets	<100 × 10 <sup>3</sup> /mm <sup>3</sup>	1.91	1.08–3.36	0.026

resolve hepatitis spontaneously, while only a fraction develop serious disease.

There have been only a few studies that compare the natural history of compensated cirrhosis between patients with HCV and HBV infections in substantial numbers [Chiaromonte et al., 1999; Fattovich et al., 2002]. The results of the present study are in accord with their finding in some aspects, but not in others. Remarkably, there is a substantial discrepancy in the cause of death in cirrhotic patients between Western countries and Japan. Most patients with cirrhosis in Western countries die of hepatic decompensation, while hepatocellular carcinoma is the leading cause of death in Japan. The role of hepatocellular carcinoma in death may differ between cirrhotic patients with HCV and HBV infections. During follow-up ranging to 20 years, hepatocellular carcinoma caused death more frequently in cirrhotic patients infected with HCV than HBV (74.1% [200/270] vs. 58.3% [35/60],  $P = 0.018$ ). Conversely, decompensation was somewhat lower as a cause of death in cirrhotic patients with HCV than HBV infections (17.8% vs. 28.3%,  $P = 0.073$ ).

In an international multicenter study conducted in Europe, 297 patients with cirrhosis had been followed-up for 6.5 years since they developed cirrhosis without receiving antiviral treatment [Fattovich et al., 2002]. Hepatocellular carcinoma developed in 23 of the 136 (17%) patients with HCV, compared with 22 of 161 (14%) with HBV. Likewise, in a multicenter study carried out in Italy [Chiaromonte et al., 1999], the development of hepatocellular carcinoma during 5.4 years was not significantly different between patients infected with

HCV and HBV, although it tended to be more frequent in those with HCV (20.5%) than HBV (9.1%). In the European study [Fattovich et al., 2002], decompensation was the cause of death or transplantation in 18 of 35 (51%) patients with HCV and 21 of 35 (60%) with HBV, in contrast to 17.8% and 28.3%, respectively, in the present study.

There are differences in factors influencing the natural history of patients with compensated cirrhosis, who are infected with HCV or HBV, between European and Asian countries. Unlike in European countries where HBV is transmitted during the adulthood by sexual contacts or intravenous drug use, HBV in Japan has been transmitted perinatally or during the infancy until 1986 when the national immunoprophylaxis in high-risk babies was initiated [Koyama et al., 2003; Noto et al., 2003]. Hence, the duration of HBV infection is much different between Europe and Japan, with possible exception of Italy and Greece where perinatal transmission once prevailed. Moreover, patients with cirrhosis die of decompensation less frequently in Japan than in Europe. The reason could be attributed partly to routine screening of varices and prophylaxis of bleeding that has become routine in Japan.

It would be important to determine factors for long-term survival in the management of cirrhotic patients. Factors influencing survival were evaluated in multivariate analysis for classifying cirrhotic patients into three groups with respective low, medium, and high risks for survival, respectively, in HCV or HBV infection (Fig. 2). These protocols would be useful in taking care of patients in accordance with their different risks, for

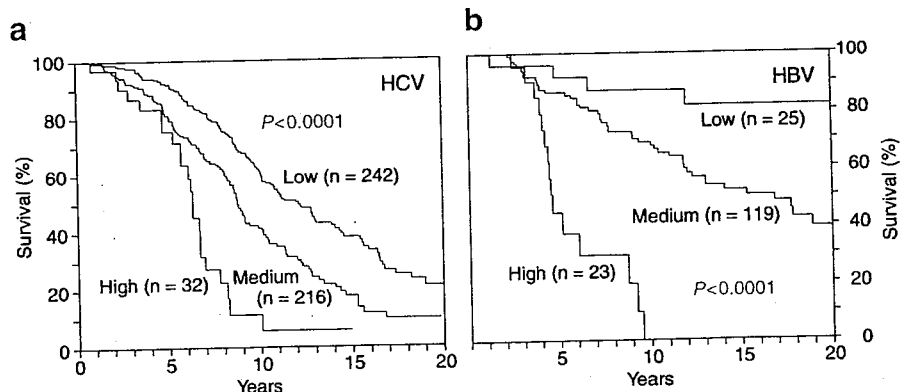


Fig. 2. Kaplan-Meier life tables for survival of patients with compensated cirrhosis who were infected with HCV (a) or HBV (b) and had low, medium, or high risk. High, medium, and low risk were defined by the sum of risk factors at 0–1, 2–3, and 4–5, respectively, in patients with HCV and that at 0–1, 2–4, and 5–6 in those with HBV; the male gender was scored 2 due to its hazard ratio twice as high as the other factors.

providing them with timely treatment towards an extended survival. In addition, they would help in selecting patients for antiviral treatment [Nishiguchi et al., 1995; Mazzella et al., 1996; Benvegna et al., 1998; Kasahara et al., 1998; Poynard and Opolon, 1998; Reddy et al., 1999]. Furthermore, the patients who need liver transplantation would be identified well beforehand by these systems, and better still, the need for liver transplantation may be delayed or prevented by timely medical interventions.

## REFERENCES

- Benvegna L, Chemello L, Noventa F, Fattovich G, Pontisso P, Alberti A. 1998. Retrospective analysis of the effect of interferon therapy on the clinical outcome of patients with viral cirrhosis. *Cancer* 83:901-909.
- Benvegna L, Gios M, Boccato S, Alberti A. 2004. Natural history of compensated viral cirrhosis: A prospective study on the incidence and hierarchy of major complications. *Gut* 53:744-749.
- Chayama K, Tsubota A, Arase Y, Saitoh S, Koida I, Ikeda K, Matsumoto T, Kobayashi M, Iwasaki S, Koyama S, Morinaga T, Kumada H. 1993. Genotypic subtyping of hepatitis C virus. *J Gastroenterol Hepatol* 8:150-156.
- Chiaromonte M, Stroffolini T, Vian A, Stazi MA, Floreani A, Lorenzoni U, Lobello S, Farinati F, Naccarato R. 1999. Rate of incidence of hepatocellular carcinoma in patients with compensated viral cirrhosis. *Cancer* 85:2132-2137.
- Cohen J. 1999. The scientific challenge of hepatitis C. *Science* 285:26-30.
- Fattovich G, Giustina G, Schalm SW, Hadziyannis S, Sanchez-Tapias J, Almasio P, Christensen E, Krogsgaard K, Degos F, de Moura MC, Solinas A, Noventa F, Realdi G. 1995. Occurrence of hepatocellular carcinoma and decompensation in western European patients with cirrhosis type B. *Hepatology* 21:77-82.
- Fattovich G, Giustina G, Degos F, Tremolada F, Diodati G, Almasio P, Nevens F, Solinas A, Mura D, Brouwer JT, Thomas H, Njapoum C, Casarin C, Bonetti P, Fuschi P, Basho J, Tocco A, Bhalla A, Galassini R, Noventa F, Schalm SW, Realdi G. 1997. Morbidity and mortality in compensated cirrhosis type C: A retrospective follow-up study of 384 patients. *Gastroenterology* 112:463-472.
- Fattovich G, Pantalena M, Zagni I, Realdi G, Schalm SW, Christensen E. 2002. Effect of hepatitis B and C virus infections on the natural history of compensated cirrhosis: A cohort study of 297 patients. *Am J Gastroenterol* 97:2886-2895.
- Hu KQ, Tong MJ. 1999. The long-term outcomes of patients with compensated hepatitis C virus-related cirrhosis and history of parenteral exposure in the United States. *Hepatology* 29:1311-1316.
- Ikeda K, Saitoh S, Koida I, Arase Y, Tsubota A, Chayama K, Kumada H, Kawanishi M. 1993. A multivariate analysis of risk factors for hepatocellular carcinogenesis: A prospective observation of 795 patients with viral and alcoholic cirrhosis. *Hepatology* 18:47-53.
- Kao JH. 2002. Hepatitis B viral genotypes: Clinical relevance and molecular characteristics. *J Gastroenterol Hepatol* 17:643-650.
- Kasahara A, Hayashi N, Mochizuki K, Takayanagi M, Yoshioka K, Kakumu S, Iijima A, Urushihara A, Kiyosawa K, Okuda M, Hino K, Okita K. 1998. Risk factors for hepatocellular carcinoma and its incidence after interferon treatment in patients with chronic hepatitis C. *Hepatology* 27:1394-1402.
- Kato Y, Nakata K, Omagari K, Furukawa R, Kusumoto Y, Mori I, Tajima H, Tanioka H, Yano M, Nagataki S. 1994. Risk of hepatocellular carcinoma in patients with cirrhosis in Japan. Analysis of infectious hepatitis viruses. *Cancer* 74:2234-2238.
- Kato H, Orito E, Sugauchi F, Ueda R, Gish RG, Usuda S, Miyakawa Y, Mizokami M. 2001. Determination of hepatitis B virus genotype G by polymerase chain reaction with hemi-nested primers. *J Virol Methods* 98:153-159.
- Kato H, Gish RG, Bzowej N, Newsom M, Sugauchi F, Tanaka Y, Kato T, Orito E, Usuda S, Ueda R, Miyakawa Y, Mizokami M. 2004. Eight genotypes (A-H) of hepatitis B virus infecting patients from San Francisco and their demographic, clinical, and virological characteristics. *J Med Virol* 73:516-521.
- Kew MC, Popper H. 1984. Relationship between hepatocellular carcinoma and cirrhosis. *Semin Liver Dis* 4:136-146.
- Koyama T, Matsuda I, Sato S, Yoshizawa H. 2003. Prevention of perinatal hepatitis B virus transmission by combined passive-active immunoprophylaxis in Iwate, Japan (1981-1992) and epidemiological evidence for its efficacy. *Hepato Res* 26:287-292.
- Lee WM. 1997. Hepatitis B virus infection. *N Engl J Med* 337:1733-1745.
- Mazzella G, Accogli E, Sottili S, Festi D, Orsini M, Salzetta A, Novelli V, Cipolla A, Fabbri C, Pezzoli A, Roda E. 1996. Alpha interferon treatment may prevent hepatocellular carcinoma in HCV-related liver cirrhosis. *J Hepatol* 24:141-147.
- Miyakawa Y, Mizokami M. 2003. Classifying hepatitis B virus genotypes. *Intervirology* 46:329-338.
- Niederer C, Lange S, Heintges T, Erhardt A, Buschkamp M, Hurter D, Nawrocki M, Kruska L, Hensel F, Petry W, Haussinger D. 1998. Prognosis of chronic hepatitis C: Results of a large, prospective cohort study. *Hepatology* 28:1687-1695.
- Nishiguchi S, Kuroki T, Nakatani S, Morimoto H, Takeda T, Nakajima S, Shiomi S, Seki S, Kobayashi K, Otani S. 1995. Randomised trial of effects of interferon-alpha on incidence of hepatocellular carcinoma in chronic active hepatitis C with cirrhosis. *Lancet* 346:1051-1055.
- Noto H, Terao T, Ryou S, Hirose Y, Yoshida T, Ookubo H, Mito H, Yoshizawa H. 2003. Combined passive and active immunoprophylaxis for preventing perinatal transmission of the hepatitis B virus carrier state in Shizuoka, Japan during 1980-1994. *J Gastroenterol Hepatol* 18:943-949.
- Orito E, Mizokami M, Sakugawa H, Michitaka K, Ishikawa K, Ichida T, Okanoue T, Yotsuyanagi H, Iino S. 2001. A case-control study for clinical and molecular biological differences between hepatitis B viruses of genotypes B and C. *Hepatology* 33:218-223.
- Planas R, Balleste B, Alvarez MA, Rivera M, Montoliu S, Galeras JA, Santos J, Coll S, Morillas RM, Sola R. 2004. Natural history of decompensated hepatitis C virus-related cirrhosis. A study of 200 patients. *J Hepatol* 40:823-830.
- Poynard T, Opolon P. 1998. Hepatitis C: Somber views of natural history and optimistic views of interferon treatment? *Hepatology* 27:1443-1444.
- Pugh RN, Murray-Lyon IM, Dawson JL, Pietroni MC, Williams R. 1973. Transection of the oesophagus for bleeding oesophageal varices. *Br J Surg* 60:646-649.
- Reddy KR, Hoofnagle JH, Tong MJ, Lee WM, Pockros P, Heathcote EJ, Albert D, Joh T. 1999. Racial differences in responses to therapy with interferon in chronic hepatitis C. *Hepatology* 30:787-793.
- Serfaty L, Aumaitre H, Chazouilleres O, Bonnard AM, Rosmorduc O, Poupon RE, Poupon R. 1998. Determinants of outcome of compensated hepatitis C virus-related cirrhosis. *Hepatology* 27:1435-1440.
- Sumi H, Yokosuka O, Seki N, Arai M, Imazeki F, Kurihara T, Kanda T, Fukai K, Kato M, Saisho H. 2003. Influence of hepatitis B virus genotypes on the progression of chronic type B liver disease. *Hepatology* 37:19-26.
- Tanaka J, Kumagai J, Katayama K, Komiya Y, Mizui M, Yamanaka R, Suzuki K, Miyakawa Y, Yoshizawa H. 2004. Sex- and age-specific carriers of hepatitis B and C viruses in Japan estimated by the prevalence in the 3,485,648 first-time blood donors during 1995-2000. *Intervirology* 47:32-40.
- Tsai JF, Jeng JE, Ho MS, Chang WY, Hsieh MY, Lin ZY, Tsai JH. 1997. Effect of hepatitis C and B virus infection on risk of hepatocellular carcinoma: A prospective study. *Br J Cancer* 76:968-974.
- Usuda S, Okamoto H, Iwanari H, Baba K, Tsuda F, Miyakawa Y, Mayumi M. 1999. Serological detection of hepatitis B virus genotypes by ELISA with monoclonal antibodies to type-specific epitopes in the preS2-region product. *J Virol Methods* 80:97-112.
- Usuda S, Okamoto H, Tanaka T, Kidd-Ljunggren K, Holland PV, Miyakawa Y, Mayumi M. 2000. Differentiation of hepatitis B virus genotypes D and E by ELISA using monoclonal antibodies to epitopes on the preS2-region product. *J Virol Methods* 87:81-89.
- Zhou S, Terrault NA, Ferrell L, Hahn JA, Lau JY, Simmonds P, Roberts JP, Lake JR, Ascher NL, Wright TL. 1996. Severity of liver disease in liver transplantation recipients with hepatitis C virus infection: Relationship to genotype and level of viremia. *Hepatology* 24:1041-1046.

# Dysplastic Nodules Frequently Develop into Hepatocellular Carcinoma in Patients with Chronic Viral Hepatitis and Cirrhosis

Masahiro Kobayashi, M.D.  
 Kenji Ikeda, M.D.  
 Tetsuya Hosaka, M.D.  
 Hitomi Sezaki, M.D.  
 Takashi Someya, M.D.  
 Norio Akuta, M.D.  
 Fumitaka Suzuki, M.D.  
 Yoshiyuki Suzuki, M.D.  
 Satoshi Saitoh, M.D.  
 Yasuji Arase, M.D.  
 Hiromitsu Kumada, M.D.

Department of Gastroenterology, Toranomon Hospital, Tokyo, Japan.

Supported in part by a Research Grant from the Japanese Ministry of Health, Labor and Welfare, and Okinaka Memorial Foundation of Toranomon Hospital.

Address for reprints: Masahiro Kobayashi, M.D., Department of Gastroenterology, Toranomon Hospital, 2-2-two Toranomon, Minato-ku, Tokyo 105-8470, Japan; Fax: (011) 81 (44) 860-1623. E-mail: mshkobayashi@toranomon.gr.jp

Received February 25, 2005; revision received June 21, 2005; accepted August 4, 2005.

**BACKGROUND.** Advances in imaging technology have enhanced the detection of small nodular lesions during the course of chronic liver disease.

**METHODS.** Between 1995 and 2002, the authors examined 154 consecutive patients with small hepatic nodules without hepatocellular carcinoma (HCC) over a median duration of 2.8 years. The median size of these nodules was 14 mm (range, 7–40 mm). The initial histopathologic diagnosis included high-grade dysplastic nodule (HGDN) ( $n = 13$ ), low-grade dysplastic nodule (LGDN) ( $n = 42$ ), and regenerative nodule (RN) ( $n = 99$ ).

**RESULTS.** A total of 29 (18.8%) nodules developed into HCC during the observation period. Cumulative HCC development rates at the first, third, and fifth year were 46.2%, 61.5%, and 80.8% for HGDN; 2.6%, 30.2%, and 36.6% for LGDN; and 3.3%, 9.7%, and 12.4% for RN, respectively. The rate of HCC development was significantly higher in the HGDN group than for other types ( $P < 0.001$ ). Multivariate analysis disclosed that histopathologic diagnosis ( $P < 0.001$ ) and findings on computed tomographic arterial portography (CT-AP) ( $P = 0.004$ ) were significantly associated with future HCC development. The hazard ratios of HGDN and LGDN were 16.8 (95% confidence interval [CI], 6.19–45.6) and 2.96 (95% CI, 1.20–7.31), respectively. A decrease in portal blood flow also showed a significantly high hazard ratio of 3.04 (95% CI, 1.42–6.50). Approximate annual development rate to HCC was 20% in patients with HGDN and 10% in LGDN.

**CONCLUSION.** HGDN should be considered a precancerous lesion when it appears during follow-up of chronic viral hepatitis or cirrhosis. Reduced portal blood flow in the nodule on computed tomography-AP is also an important predictor for development of hepatocellular carcinoma. *Cancer* 2006;106:636–47.

© 2005 American Cancer Society.

**KEYWORDS:** hepatocellular carcinoma, dysplastic nodule, multistep carcinogenesis.

**W**ith advances in imaging diagnosis, hepatic nodular lesions are now frequently found during the course of chronic liver disease.<sup>1–6</sup> According to a previous study, hepatocellular carcinoma (HCC) develops at a rate of about 3–10% per year in patients with chronic viral hepatitis and cirrhosis.<sup>7–10</sup>

If an intrahepatic nodular lesion is found, it is always necessary to consider development of HCC. Screening for HCC is mostly performed by ultrasonography (US). If hepatic nodular lesions are found on US, further imaging diagnosis such as computed tomography (CT), magnetic resonance imaging (MRI), and hepatic angiography are performed to decide if the nodules represent HCC. Fine needle aspiration biopsies are considered only when HCC is not diagnosed by

such imaging techniques, because careless needle insertion into HCC may lead to tumor seeding to the surrounding liver tissue.<sup>11,12</sup>

Some hepatic nodules are diagnosed as HCC by both imaging and biopsy examination and can be treated with appropriate modalities, whereas others are diagnosed as nonmalignant. During the observation of such "nonmalignant" hepatic nodules, some progress to HCC while others disappear or stay unchanged for long periods.

It is generally considered that there are two different pathways to the development of HCC.<sup>13,14</sup> One is a "multistep" carcinogenesis process similar to the process described for colorectal cancer,<sup>15,16</sup> and the other is called "de novo" carcinogenesis. With the former type, it is important to determine which types of hepatic nodules are precancerous. In other words, identification of risk factors for development of HCC is necessary for follow-up of such hepatic nodules.

The aim of the present study was to elucidate outcomes and factors associated with development of HCC during long-term follow-up of small hepatic nodules that were initially diagnosed as nonmalignant lesions.

## MATERIALS AND METHODS

### Patients

Medical records of patients who were hospitalized for evaluation of hepatic nodular lesions at Toranomon Hospital between 1995 and 2002 were reviewed retrospectively. A total of 1425 patients were hospitalized during this period, and 1171 (82.2%) of the 1425 patients were already diagnosed as HCC by detailed image analysis. Fine needle aspiration biopsies were carried out in the remaining 254 (17.8%) patients and 88 (34.6%) were histologically diagnosed as HCC. After exclusion of hepatic hemangiomas ( $n = 4$ ), focal nodular hyperplasia ( $n = 3$ ), and alcoholic hyperplastic nodules ( $n = 5$ ), the remaining 154 patients who had a histologic diagnosis, but were not diagnosed as HCC, were enrolled in the current study. If two or more hepatic nodules were observed in the same patient, then the largest nodule was included in the current study. Clinical backgrounds of these patients are listed in Table 1. The background of all 154 patients included chronic liver disease as 108 (70.1%) patients were positive for hepatitis C virus (HCV), 32 (20.8%) patients were positive for hepatitis B virus (HBV), and 2 (1.3%) patients were positive for both HCV and HBV. Twelve (7.8%) of 154 were negative for both HCV and HBV. Among these 12 patients, only 4 (33.3%) had a history of habitual heavy alcohol intake of more than 80 g per day. In addition, cirrhosis was evident in 124 (80.5%) patients. In our institution, informed consent

**TABLE 1**  
Clinical Background of 154 Patients with Small Hepatic Nodular Lesions

Characteristic	Median (range)
Age in yrs	63 (33-81)
Gender, male:female <sup>a</sup>	101:53
HBV:HCV:HBV+HCV:others <sup>a</sup>	32:108:2:12
Previous history of HCC, yes:no <sup>a</sup>	40:114
Presence of cirrhosis, yes:no <sup>a</sup>	124:30
Diameter of nodule, mm	14 (7-40)
Albumin, g/dL	3.7 (2.6-4.7)
Bilirubin, mg/dL	1.0 (0.4-3.1)
ICG R15, %	27 (4-79)
Platelet, $\times 10^4/\text{mm}^3$	10.2 (3.4-38.0)
Prothrombin time, %	88 (50-100)
AFP, ng/mL	13 (1-1070)
DCP, AU/mL	13 (<10-182)
Observation periods, yrs	2.8 (0.1-8.9)

HBV: hepatitis B virus; HCV: hepatitis C virus; HCC: hepatocellular carcinoma. ICG R15: indocyanine green retention rate at 15 minutes; AFP: alpha-fetoprotein; DCP: des-gamma-carboxy prothrombin.

<sup>a</sup>Data are expressed as ratios, not median and range.

is not required for reviewing patient records, including images, and, therefore, no such consent was obtained. However, at the time of the study, each patient provided informed consent for conducting imaging studies, including dye injection and needle biopsy.

### Image Analysis

US or helical dynamic CT was carried out every 3 months for follow-up and examined for a change in imaging findings. US examination was generally performed with B-mode fundamental and harmonic imaging. Contrast-enhanced US using Levovist (Schering, Berlin, Germany) was performed in some cases. Dynamic CT scans were performed using a single-detector helical CT scanner (Hi-Speed advantage SG, GE Yokogawa Medical Systems, Tokyo, Japan). Furthermore, all CT scans taken throughout the study were performed using this scanner. In these studies, 95 mL of 350 mg I/mL Iomeprol (Iomeron 350, Eisai, Tokyo), as the contrast medium, was rapidly injected intravenously at 0.06 mL/kg body weight/sec. Phase-1, -2, and -3 imaging were performed at 25, 60, and 180 seconds (slice thickness: 10 mm, 5 mm, and 10 mm, respectively) after the start of injection, respectively.

The radiologic study was conducted by intra-arterial digital subtraction angiography, including celiac and mesenteric angiography and selective angiography of the common hepatic artery. Computed tomographic arterial portography (CT-AP) and computed tomographic hepatic angiography (CT-HA) were carried out in the CT room after completion of hepatic

angiography using 5-French catheter. CT-AP scans were carried out with slip-ring technology, 5-mm thick sections, and 5-mm collimation. Overlapping reconstructions were obtained every 2.5 mm. Data acquisition was started 25 seconds after initiation of a transcatheter injection into the superior mesenteric artery of 90 mL of nonionic contrast material containing 120 mg I/mL at 3 mL/sec, by using an automated power injector. The duration of scanning was around 25–35 seconds, depending on liver size, during a single breath hold. CT-HA scans were also obtained with 5-mm thick sections, 5-mm collimation, 2.5-mm reconstruction intervals. Data acquisition was started 10 seconds after initiation of a transcatheter hepatic artery injection (using the same automated power injector) of 20–30 mL of nonionic contrast material that contained 70 mg I/mL at 1.0 mL/sec.

Both CT-AP and CT-HA were qualitatively analyzed retrospectively, and the final diagnosis was established by consensus between two experienced radiologists who were blinded to the histologic diagnosis and clinical outcome. The CT-AP findings in hepatic nodules were classified as isoattenuating or low-attenuating, compared with the surrounding liver parenchyma. If only part of the nodule was hypodense, then we defined such nodule as low-attenuating. Likewise, CT-HA findings were classified as isoattenuating or high-attenuating compared with surrounding liver parenchyma. Because we were interested in increased intranodular arterial blood flow in the current study, if the nodule was hypodense on CT-HA, it was regarded as isoattenuating.

#### **Follow-Up Protocol**

On the basis of the above-mentioned strategies, when the tumor diameter enlarged or there was a change in US pattern or change of enhancement features, reexamination, including imaging and tumor biopsy, was considered. When a typical hypervascular staining pattern was obtained on angiography or a hyperattenuating nodule was detected on the arterial phase of the dynamic CT, the nodule was diagnosed as HCC without histologic examination.

#### **Histopathologic Examination**

All specimens were obtained by percutaneous fine needle aspiration biopsy (FNAB) by using a 21-gauge Mashima needle under US guidance. Tissue samples were collected not only from tumor tissue but also from nontumor tissue to compare architectural and nuclear differences. To avoid misdiagnosis due to sampling error or variation, sampling was carried out at least twice from different areas of the nodule. Furthermore, the US image was recorded on a video re-

order to confirm that tumor samples were correctly obtained. Sections of 3–6- $\mu$ m in thickness were cut after formalin-fixation and paraffin-embedding of specimens. Sections were stained with hematoxylin and eosin (H & E) and silver for reticulin fibers.

Tissue samples obtained by tumor biopsy were classified into HCC, high-grade dysplastic nodule (HGDN), low-grade dysplastic nodule (LGDN), or regenerative nodule (RN), according to criteria proposed by an international working party.<sup>17</sup> In brief, LGDN was characterized by a slight increase (< 1.5 times) of cell density and nuclear-cytoplasmic ratio compared with the surrounding liver tissue, an absence of structural dysplasia, and sometimes showed a large or small change. HGDN also had features of LGDN, and, in addition, there was an increase in cell density of between 1.5 to 2 times, high nuclear-cytoplasmic ratio, cytoplasmic basophilia, and irregular nuclear contour. If stromal or portal tract invasion of the tumor was seen in the specimen, the nodule was considered well differentiated HCC.<sup>18</sup>

#### **Statistical Analysis**

Differences in background features and laboratory data among the three groups were analyzed by the chi-square test and Kruskal-Wallis test. The time between first biopsy and development of HCC was analyzed by using the Kaplan-Meier technique, and differences in curves were tested by using the log-rank test. Independent risk factors associated with HCC progression rate were studied using stepwise Cox regression analysis.<sup>19</sup> Potential risk factors for malignant transformation that were assessed included the following 18 variables: age, gender, etiology of background liver disease, previous history of HCC, presence of cirrhosis, albumin, bilirubin, indocyanine green retention rate at 15 minutes (ICG R15), platelet count, prothrombin time, alpha fetoprotein ( $\alpha$ -fetoprotein (AFP)), des-gamma-carboxy prothrombin (DCP), diameter of the nodule, US pattern, conventional CT findings, CT-AP findings, and CT-HA findings. A probability of < 0.05 was considered significant. Data analysis was performed using SPSS statistical software version 10 (SPSS Inc., Chicago, Illinois).

## **RESULTS**

### **Image Diagnosis and Malignant Transformation of Hepatic Nodular Lesions**

Each imaging technique and lesion feature were examined. Because all tissue samples in the current study were obtained under US guidance, the detection rate on US was 100%. Of hepatic lesions examined, 85 (55.2%) nodules were low-echoic whereas the remain-

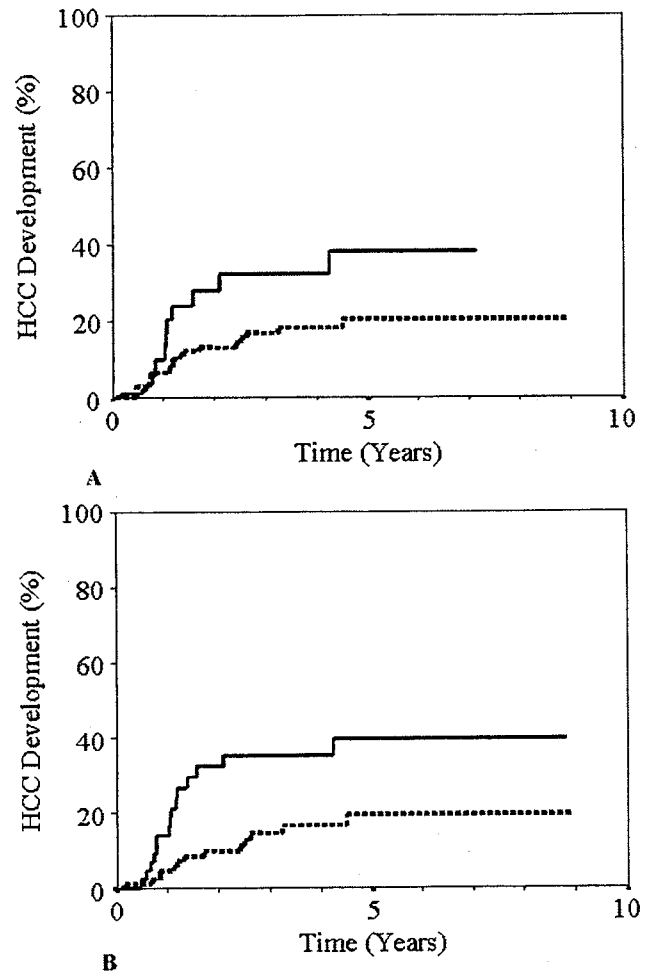
ing 69 (44.8%) were high-echoic. Furthermore, 35 (22.7%) nodules were observed on helical dynamic CT. Among these, 26 were isoattenuating at arterial phase and low-attenuating at portal venous phase and/or the equilibrium phase. The other nine showed low attenuation throughout the scanning. None of the nodules was high-attenuating at the arterial phase on CT.

CT-AP was carried out in 144 patients and 49 (34.0%) nodules were detected. Among these, 30 nodules were slightly low attenuating, whereas the remaining 19 were markedly low attenuating relative to surrounding liver parenchyma. CT-HA was performed in 142 patients and 40 (28.2%) nodules were detected. Only 10 nodules were high attenuating, whereas 30 nodules were low attenuating on CT-HA.

The cumulative HCC development rate was evaluated by Kaplan–Meier method for each imaging diagnosis. The HCC development rates for high echoic nodules were 4.8% at 1 year, 13.7% at 3 years, and 22.5% at 5 years. These rates were 9.8%, 25.7%, and 25.7% for low-echoic nodules, respectively, and the rates were not significantly different between the high- and low-echoic groups. The HCC development rate of CT-detected and -undetected nodules were 9.7% and 4.3% at 1 year, 32.2% and 16.8% at 3 years, and 38.3% and 20.6% at 5 years, respectively. CT-detected nodules were more likely to transform to HCC than CT-undetected nodules (log-rank test,  $P = 0.039$ ) (Fig. 1A). HCC developed from CT-AP low-attenuating nodules at a rate of 13.8%, 35.3%, and 39.7% at 1, 3, and 5 years, respectively. These rates were 4.7%, 14.5%, and 19.4%, respectively, for nodules that did not show low attenuation. The CT-AP low-attenuation nodules often transformed to HCC (log-rank test,  $P = 0.005$ ) (Fig. 1B). Similarly, HCC developed from CT-HA high-attenuation nodules at a rate of 9.2%, 20.0%, and 30.5% at 1, 3, and 5 years, respectively. These rates were 5.7%, 18.3%, and 23.4%, respectively, for high-attenuation nodules, and the rates were not significantly different between the two groups.

#### Histologic Diagnosis and Malignant Transformation of Hepatic Nodular Lesions

Histologic diagnosis of 154 nodules based on examination of initial biopsies was as follows: HGDN,  $n = 13$ ; LGDN,  $n = 42$ ; whereas the remaining 99 nodules did not show any abnormal histologic features and were, therefore, considered RN. The clinical backgrounds of the three groups classified by histologic features are summarized in Table 2. There were no differences in these parameters among the three groups. Tumor diameter, US pattern, detection of the nodule on dynamic CT, and attenuation pattern on



**FIGURE 1.** Cumulative HCC development rate of hepatic nodular lesions based on (A) detection by computed tomography (CT). Solid line: HCC developed from CT-detected nodules, dashed line: HCC from CT-undetected nodules (log-rank test:  $P = 0.039$ ), and (B) CT-AP findings. Solid line: HCC from low-attenuating nodules, dashed line: HCC from no attenuation lesions (log-rank test:  $P = 0.005$ ).

CT-AP and CT-HA were also compared (Table 3), but there were no significant differences among the three groups.

Twenty-nine (18.8%) patients of 154 with nodules progressed to HCC during the median follow-up of 2.8 years. The diagnosis of HCC was made histologically ( $n = 24$ ) or by imaging modalities ( $n = 5$ ). The 24 HCC that were histologically diagnosed comprised well differentiated HCC ( $n = 16$ ) and moderately differentiated HCC ( $n = 8$ ). The cumulative HCC progression rate was 7.0% at 1 year, 16.1% at 2 years, 19.9% at 3 years, and 24.4% at 5 years. The first histologic diagnosis and the final outcome of the 154 nodules at the end of the observation period are shown in Figure 2. A total of 9 (69.2%) of 13 nodules transformed to HCC

**TABLE 2**  
Comparison of Background of Patients with Small Hepatic Nodules with Regard to Initial Histologic Diagnosis

Parameter	HGDN (n = 13)	LGDN (n = 42)	LRN (n = 99)	Significance
Age, yrs <sup>a</sup>	64 (34-70)	64 (39-76)	61 (33-81)	NS
Gender, male:female	9:4	24:18	68:31	NS
HBV:HCV:HBV+HCV:others	3:10:0:0	10:31:0:1	19:67:2:11	NS
Previous history of HCC, yes:no	10:3	33:9	71:28	NS
Presence of cirrhosis, yes:no	10:3	36:6	78:21	NS
Albumin, g/dL <sup>a</sup>	3.4 (3.1-4.0)	3.6 (2.7-4.4)	3.7 (2.6-4.7)	NS
Bilirubin, mg/dL <sup>a</sup>	1.1 (0.7-1.8)	1.1 (0.4-2.6)	1.0 (0.4-3.1)	NS
ICG R15, % <sup>a</sup>	33 (20-46)	28 (4-56)	24 (7-79)	NS
Platelet, ×10 <sup>4</sup> /mm <sup>3a</sup>	9.3 (5.0-15.8)	9.8 (3.5-38.0)	10.4 (3.4-38.0)	NS
Prothrombin time, % <sup>a</sup>	86 (45-100)	86 (54-100)	88 (52-100)	NS
AFP, ng/mL <sup>a</sup>	13 (2-244)	16 (1-403)	11 (2-1070)	NS
DCP, AU/mL <sup>a</sup>	12 (<10-31)	13 (<10-182)	13 (<10-178)	NS

HGDN: high-grade dysplastic nodule; LGDN: low-grade dysplastic nodule; LRN: large regenerative nodule; HBV: hepatitis B virus; HCV: hepatitis C virus; HCC: hepatocellular carcinoma; ICG R15: indocyanine green retention rate at 15 minutes; AFP: alpha-fetoprotein; DCP: des-gamma-carboxy prothrombin.


<sup>a</sup>Data are expressed as median (range).

**TABLE 3**  
Tumor Diameter and Image Characteristics of HGDN, LGDN, and RN

Image characteristics	HGDN (n = 13)	LGDN (n = 42)	LRN (n = 99)	Significance
Diameter of nodule <sup>a</sup>	15 (10-25)	14 (7-23)	14 (7-40)	NS
Ultrasonography, high echo: low echo	3:10	18:24	48:51	NS
Detection on dynamic CT, yes:no	2:11	9:33	24:75	NS
Low attenuating area on CT-AP, yes:no	6:7	14:25	29:63	NS
High attenuating area on CT-HA, yes:no	1:12	4:34	5:86	NS

HGDN: high-grade dysplastic nodule; LGDN: low-grade dysplastic nodule; LRN: large regenerative nodule; CT-AP: computed tomographic-arterial portography; CT-HA: computed tomographic-hepatic angiography; NS: not significant.

<sup>a</sup>Data are expressed as median (range).



**FIGURE 2.** Initial histologic diagnoses and outcomes of 154 patients with small hepatic nodular lesions.

from HGDN. Only one nodule disappeared during the follow-up period. Similarly, 11 (26.2%) nodules of 42 progressed to HCC from LGDN, and 5 (11.9%) nodules disappeared. A total of 9 (9.1%) HCC arose from RNs at first biopsy, and 37 (37.4%) disappeared.

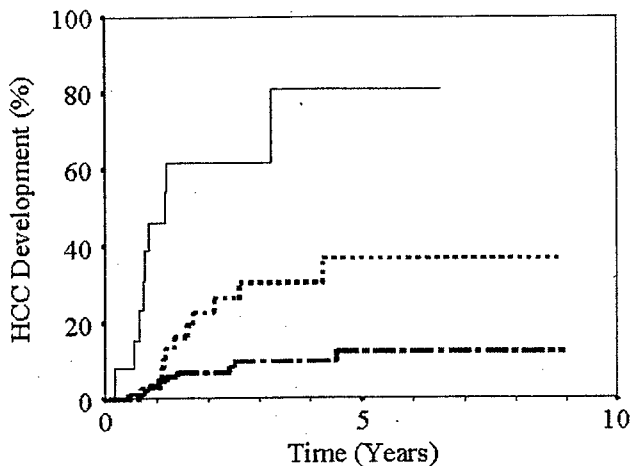
The cumulative HCC development rate calculated by the Kaplan-Meier method was 7.0% at 1 year, 19.9% at 3 years, and 24.4% at 5 years. The develop-

ment of HCC occurred within the first 5 years, and no patient has subsequently developed HCC to date. Figure 3 shows HCC development rate according to each tissue diagnosis. The HCC transformation rate from HGDN was 46.2% at 1 year, 61.5% at 2 and 3 years, and 80.8% at 5 years. The rate of development of HCC from LGDN was 2.6% at 1 year, 30.2% at 3 years, and 36.6% at 5 years. Similarly, HCC developed from RNs at a rate of 3.3% at 1 year, and 9.7% at 3 years, and 12.4% at 5 years. HCC developed more often from HGDN nodules than from LGDN and RN (log-rank test,  $P < 0.0001$ ).

**Predictive Factors for Development of HCC from Hepatic Nodular Lesions**

To elucidate predictive factors for development of HCC from hepatic lesions, both patient and tumor characteristics were analyzed by the log-rank test. Age > 60 years, ICG R15 > 30%, tumor diameter >14 mm, detection of the nodule on conventional helical dynamic CT, decrease of portal blood flow in the hepatic





**FIGURE 3.** Cumulative HCC development rate from high-grade dysplastic nodules (HGDN, continuous line), low-grade DN (LGDN, dotted line), and regenerative nodules (RN, dashed line). HGDN developed into HCC more often compared with LGDN and RN ( $P < 0.0001$ ).

**TABLE 4**  
Factors Associated with HCC Progression from Hepatic Nodular Lesions by Multivariate Analysis (Cox Proportional Hazard Model)

Factors	Category	Hazard ratio (95% CI)	P value
Histology			
LRN	1	1	< 0.001
LGDN	2	2.96 (1.20-7.31)	
HGDN	3	16.8 (6.19-45.6)	
CT-AP			
Low attenuation, -	1	1	0.004
Low attenuation, +	2	3.04 (1.42-6.50)	

HCC: hepatocellular carcinoma; CI: confidence interval; LRN: large regenerative nodule; LDGN: low-grade dysplastic nodule; HGDN: high-grade dysplastic nodule; CT-AP: computed tomographic-arterial portography.

nodule on CT-AP, and liver histology on tumor biopsy were significant factors by univariate analysis. Furthermore, the etiology of chronic liver disease, serum albumin, serum bilirubin, prothrombin time, serum AFP level, serum DCP level, platelet count, US pattern, and hyperattenuation on CT-HA were not significant.

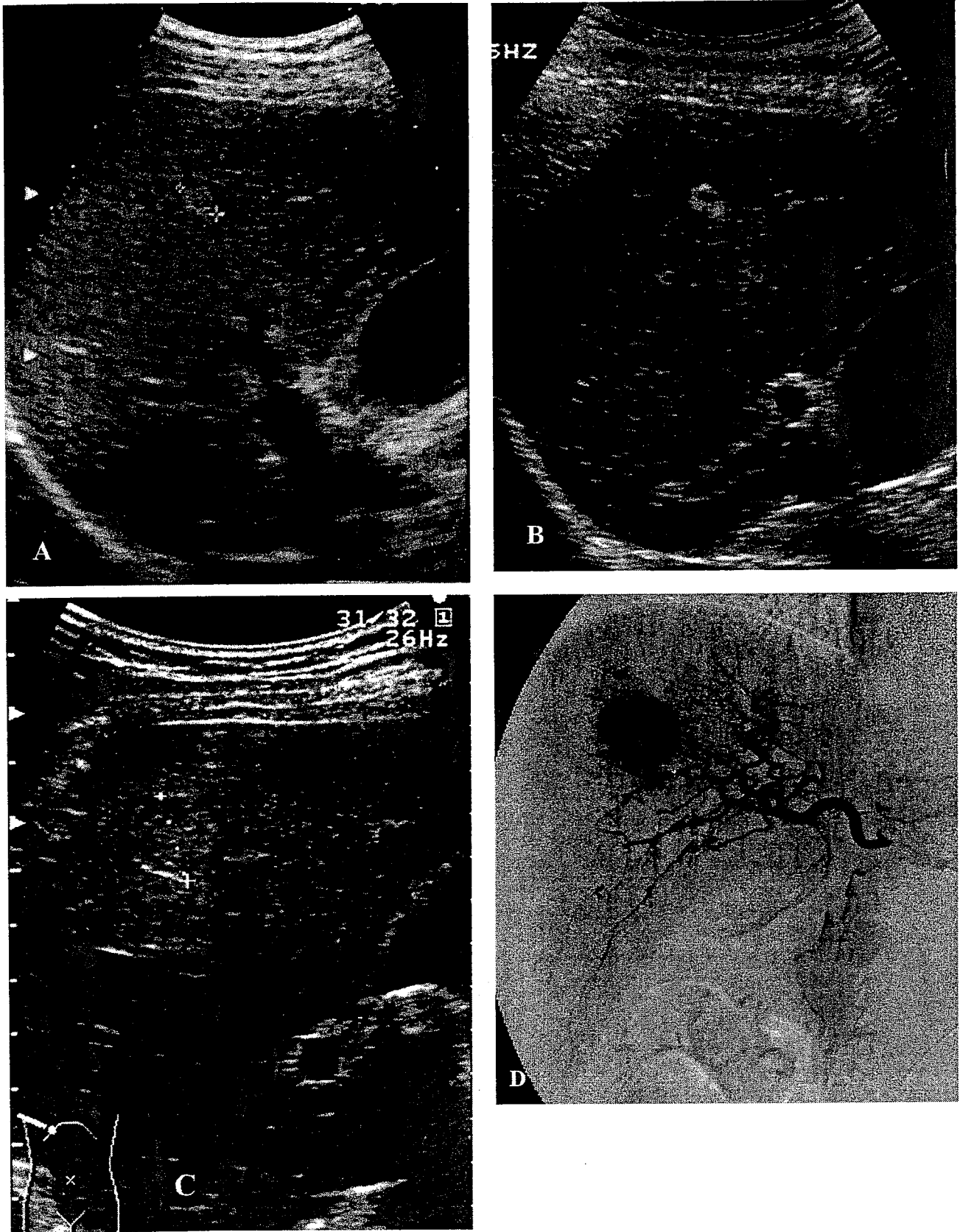
Subsequently, multivariate analysis by the Cox proportional hazard model was performed to adjust for the confounding effect on each variable. Histologic diagnosis was the most significant factor for development of HCC ( $P < 0.0001$ ). Compared with RN, the rate of development of HCC in HGDN was as much as 16.8-fold higher (95% confidence interval [CI], 6.19-45.6), and in LGDN was 2.96-fold (95% CI, 1.20-7.31) higher. Decreased portal blood flow in the nodule on CT-AP was also significant (hazard ratio [HR], 3.04; 95% CI, 1.42-6.50;  $P = 0.004$ ) (Table 4).

In addition, HCC developed at other sites of the liver during observation in 49 patients. However, there was no correlation between malignant transformation of the observed nodule and the subsequent development of HCC in other sites. In addition, no HCC developed from smaller nodules that were identified on first examination, during the follow-up period.

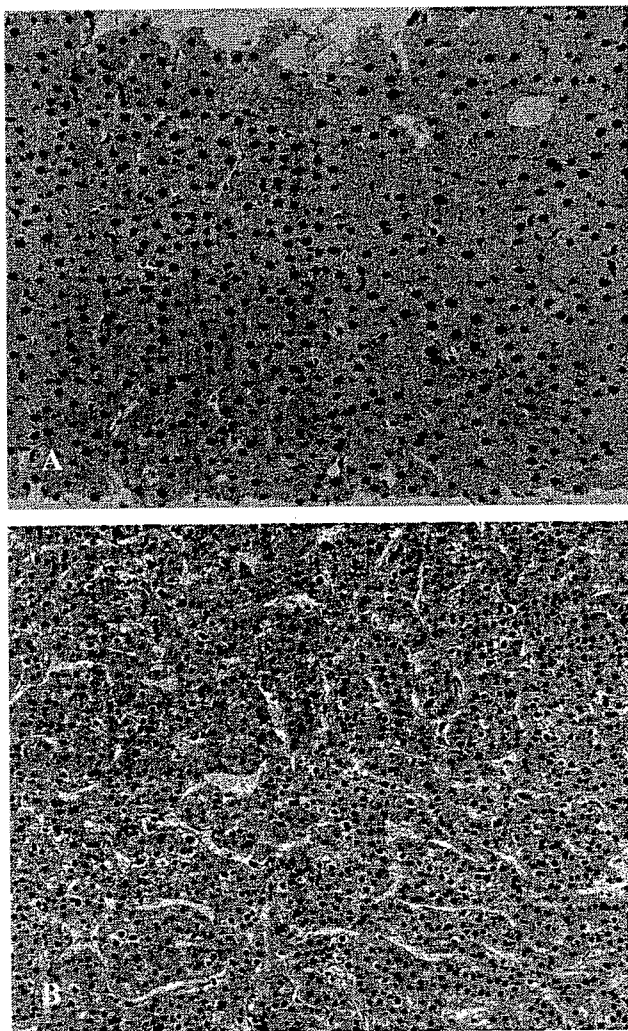
#### Case Reports of Hepatic Nodule Transforming to HCC during Four-Year Follow-Up

Figure 4 shows a case of HCC that progressed from a dysplastic nodule. This patient was a 61-year-old male with hepatitis C virus (HCV)-related cirrhosis. A 6-mm diameter hyperechoic nodule was found on US during the course of cirrhosis (Fig. 4A). Although detailed imaging analysis, including dynamic CT, hepatic angiography, CT-HA, and CT-AP, was carried out, the nodule was not detected with these modalities. FNAB was performed under US guidance, and the histologic diagnosis obtained from the specimen was LGDN (Fig. 5A). Therefore, the nodule was carefully followed up every 3 months on US. Three years later, the nodule was a little enlarged to 9 mm in diameter, and low-echoic foci appeared inside the nodule (Fig. 4B). Another year later, diameter of the tumor rapidly increased to 17 mm, and the nodule showed a "mosaic pattern," which is the typical sign of classical HCC on US (Fig. 4C). On this account, HCC development of the nodule was strongly suspected. Hepatic angiography was then carried out and showed typical hypervascular staining (Fig. 4D). The nodule was surgically resected afterward, and the specimen showed histologic features of moderately differentiated HCC (Fig. 5B).

Figure 6 shows another case of HCC that progressed from HGDN. This patient was a 65-year-old male with HCV-related cirrhosis. A 16-mm diameter hyperechoic nodule was found on US during the course of cirrhosis (Fig. 6A). The nodule was not detected on helical dynamic CT. Hepatic angiography, including CT-AP and CT-HA, was carried out, and a vague slightly low-attenuating area detected on both CT-AP and CT-HA (Fig. 6B-C). FNAB was performed under US guidance, and the histologic diagnosis was HGDN (Fig. 7A). Two years later, the nodule was found slightly enlarged to 20 mm in diameter on US, and the nodule became detectable on dynamic CT. (Fig. 6D). Furthermore, detailed image diagnosis was performed. Although there was no hypervascular staining on hepatic angiography, a relatively well bordered low-attenuating area was detected on CT-AP (Fig. 6E). In addition, a slightly high-attenuating rim was noted in the low-attenuating area on CT-HA (Fig. 6F). The nodule was surgically resected afterward, and the



**FIGURE 4.** (A) A 6-mm diameter hyperechoic nodule appeared on ultrasonography (US) during the follow-up of HCV-related cirrhosis. (B) Four years later, the nodule increased in size to 9 mm in diameter and low-echoic foci appeared inside the nodule. (C) The nodule rapidly grew in size within 1 more year and showed a "mosaic pattern" on US. (D) Hepatic angiography was carried out before surgical resection. The angiogram showed typical hypervascular staining of HCC in the right lobe of the liver.



**FIGURE 5. (A)** Liver tissue sample obtained at first biopsy. The cell density and nuclear-cytoplasmic ratio was slightly increased (left) compared with the surrounding liver tissue (right). Small cell change was also observed and the histologic diagnosis was low-grade dysplastic nodule. **(B)** Liver tissue obtained by surgical resection. The tissue showed a trabecular pattern. The histologic diagnosis was well to moderately differentiated HCC. H&E staining in both panels; original magnification  $\times 100$ .

specimen showed histologic features of well differentiated HCC (Fig. 7B).

#### Comparison of Tumor Diameter at First Biopsy and End of Observation Period

The above-mentioned analysis reviewed predictive factors for development of HCC by liver tissue diagnosis at the first tumor biopsy. When we observed a change in nodule diameter during follow-up of more than 5 mm, HCC developed in 10 of 17 patients, whereas HCC developed in only 12 of 137 nodules in

which the diameter enlarged by less than 5 mm. The relation between tumor enlargement and HCC progression was statistically significant ( $P < 0.001$ ).

#### DISCUSSION

The importance of dysplastic nodules as precancerous lesions of HCC is well established in Japan,<sup>13,20-24</sup> but less emphasized in Western countries.<sup>25</sup> Sakamoto et al. studied 320 resected liver tissues and concluded that multistep carcinogenesis is one pathway to HCC development.<sup>13</sup> Furthermore, several reports from Western countries in explanted whole liver from non-Japanese patients suggested that macroregenerative nodules may also represent precancerous lesions.<sup>26,27</sup>

However, consistent with previous reports, not all hepatic nodular lesions that we found on screening by US progressed to HCC.<sup>23,24,28</sup> Some nodules remained unchanged, and other nodules disappeared during long-term observation. Therefore, identification of true precancerous liver lesions, especially among patients with chronic liver disease, is important. The aims of the current study were to estimate the HCC progression rate of hepatic nodular lesions and to examine factors associated with malignant transformation.

Several reports have examined HCC development from borderline lesions;<sup>23,24,28-31</sup> however, no reports have included as many patients as the current study of 154 patients who were histologically diagnosed with dysplastic nodules and fully examined by imaging procedures before tumor biopsy. Notably, all patients also received imaging diagnosis every 3 months with a median follow-up of 2.8 years.

Twenty-nine of 154 (18.8%) hepatic nodules in our study transformed into HCC. The cumulative HCC development rates for such intrahepatic nodular lesions were 7.0% at 1 year, 19.9% at 3 years, and 27.4% at 5 years. Our findings are similar to those of Borzio et al.,<sup>28</sup> who reported an HCC rate of 31% in 90 large regenerative and dysplastic nodules and Seki et al.,<sup>24</sup> who reported HCC development in 12.1% of 33 dysplastic nodules measuring  $< 3$  cm diameter at diagnosis.

With respect to predictive factors for development of HCC, age  $> 60$  years, ICG R15  $> 30\%$ , tumor diameter  $> 14$  mm, detection of a nodule on dynamic CT, decrease of portal blood flow in the hepatic nodule on CT-AP, and liver histology of tumor biopsy were significant factors by univariate analysis. The severity of background liver disease also has been reported as an important risk factor for development of HCC.<sup>7-10</sup> Therefore, high ICG R15 may affect potential HCC development. With respect to the effect of age, underlying liver disease would be expected to advance with

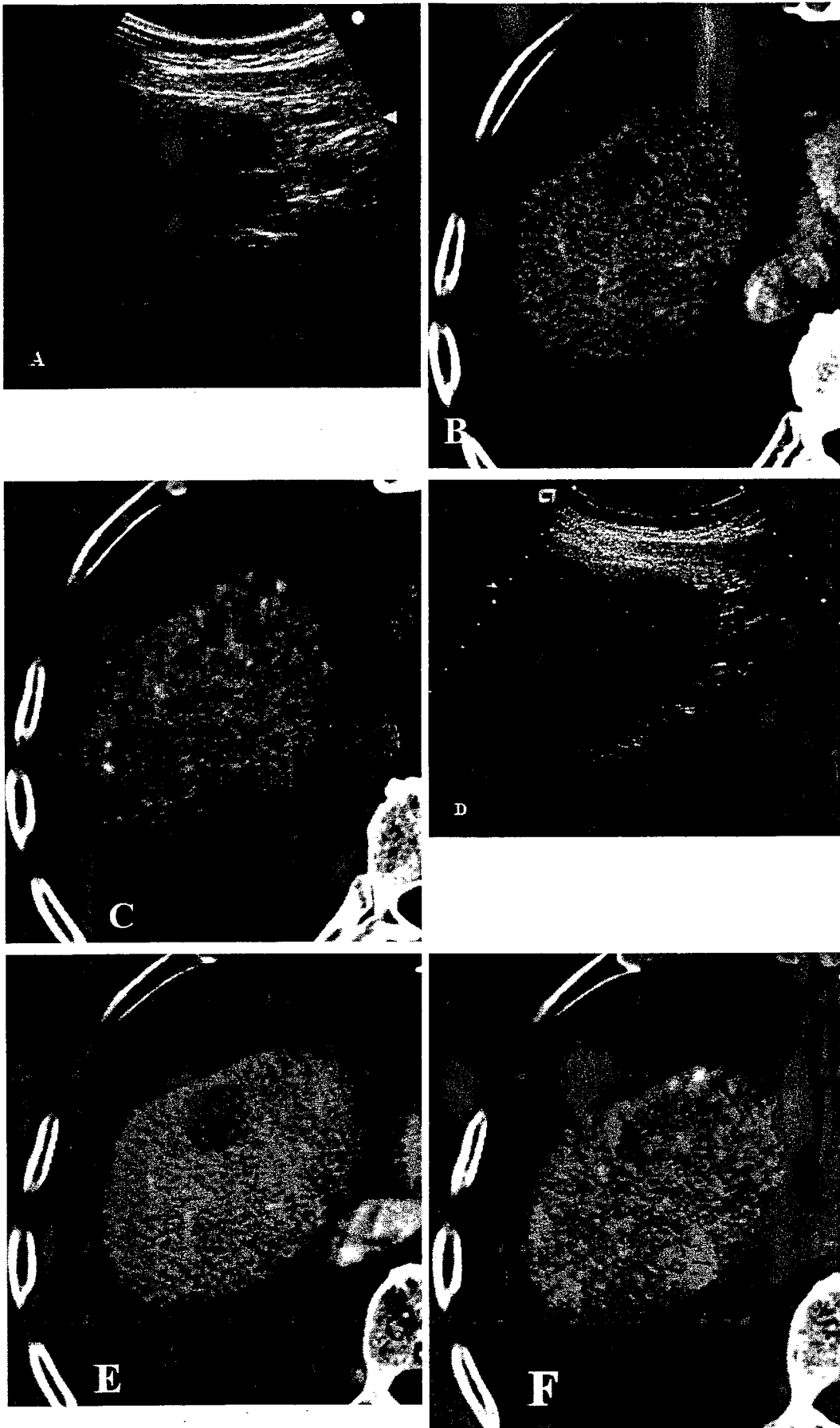



FIGURE 6

aging, and genetic mutation of oncogenes or tumor suppressor genes could occur at higher frequency with aging. We speculate that such alterations may generally increase risk of carcinogenesis with increasing age.



With respect to tumor diameter, it is intuitive that larger nodules could represent a more advanced stage in multistep carcinogenesis, and, thus, would progress to HCC more frequently than smaller ones. There is a problem of lead-time bias at this point. However, in our study, 133 of the 154 (86.4%) patients had undergone US screening before the first detection of hepatic nodules, and, thus, lead-time bias should have been minimized.

In multivariate analysis, histologic diagnosis and decrease of portal flow in CT-AP were independent factors for prediction of malignant transformation. In our study, we classified liver histology into three groups; HGDN, LGDN, and RN. According to this classification, as predicted, the progression rate of HCC from HGDN was significantly high, and the annual HCC development rate exceeded 30% in the first 2 years. The regression coefficient of HGDN in multivariate analysis was as much as 16.8 compared with RN. Therefore, we can conclude that HGDN was a true precancerous lesion of HCC.

Because of radiologic innovations, the relation between tumor progression and vascular supply of hepatic tumors is well documented. Hayashi et al.<sup>29</sup> followed up dysplastic nodules detected on CT-HA and CT-AP and described how portal blood flow in the nodule gradually decreased with acquisition of malignant tumor features. These results are consistent with our results in that in both univariate and multivariate analyses, reduced portal blood flow was a risk factor for HCC development. We realize that CT-AP and CT-HA are rather invasive methods and cannot easily be conducted repeatedly. Dysplastic nodules or RNs are usually isovascular or hypovascular.<sup>29</sup> In fact, in our patients, the arterial phase on dynamic CT was isoattenuating in 26 and low-attenuating in the remaining 9, and all 35 nodules were low-attenuating at portal venous phase and/or the equilibrium phase. Although



**FIGURE 6.** (A) A 16-mm diameter hyperechoic nodule was found on US during the course of cirrhosis. (B) A vague and slightly low-attenuating area was detected on both CT-AP. (C) The nodule showed slightly hypoattenuating area on CT-HA. (D) Two years later, the nodule increased in size to 20 mm in diameter on US. (E) Further detailed image diagnosis was performed and a relatively well bordered low-attenuating area was detected on CT-AP. (F) In addition, a slightly high-attenuating rim appeared in the low-attenuating area on CT-HA.



**FIGURE 7.** (A) The first histopathologic diagnosis based on examination of US-guided fine needle aspiration biopsy of the nodule was high-grade dysplastic nodule. (B) The nodule was subsequently resected surgically, and the specimen showed histopathologic features of well differentiated HCC. H&E staining in both panels; original magnification  $\times 100$ .

detection of the nodule on dynamic CT was significant for predicting HCC transformation, as determined by univariate analysis, this was not significant by multivariate analysis. This could mean that CT-AP is superior to dynamic CT in detecting reduced portal blood flow and, hence, a better predictor of progression to HCC.

With respect to evaluation of tumor arterial blood flow, although we reviewed the results of CT-HA in our patients, we could not determine the relation between arterial blood flow and tumor progression. Hepatic arterial flow decreased in dysplastic nodules and in early stage HCC, and then it increased as lesions progressed to classic HCC.<sup>29</sup> Such a two-phase arterial

flow change may have complicated our statistical analysis.

Previous studies showed the usefulness of MRI for characterization of hepatic nodular lesions.<sup>32-35</sup> Earls et al.<sup>32</sup> examined thin-section MRIs of explanted liver and reported that MRI depicted 41 of 42 (98%) hepatic nodular lesions, which included dysplastic nodules as well as HCC. Furthermore, Matsui et al.<sup>33</sup> demonstrated that hyperplastic adenomatous nodules were hyperintense on T1-weighted spin-echo imaging and hypointense on T2-weighted spin-echo imaging, and both features were useful for the differentiation of such borderline lesions from HCC in the cirrhotic liver. Furthermore, other groups also indicated the superiority of dynamic contrast-enhanced MRI and ferumoxides-enhanced MRI relative to CT for diagnosis of small HCC.<sup>34,35</sup> We also examined dynamic MRI in 48 patients and ferumoxides MRI in 25 patients. Because the number of these patients was small, we did not include MRI results in our analysis. Choi et al.<sup>34</sup> indicated that ferumoxides-magnetic resonance imaging can be used instead of CT-AP and CT-HA, because both modalities have almost the same sensitivity and high specificity for diagnosis of HCC. Further studies are needed to confirm the usefulness of ferumoxides-MRI for diagnosis of malignant transformation of hepatic nodular lesions.

There are certain limitations in our study. First, tumor biopsy was usually carried out under US guidance, and, therefore, nodules that were not observed on US were not included in this study. In our clinical practice, we sometimes find hepatic nodules that show low attenuation on CT-HA and/or CT-AP, but they are barely observed on US. Tsuchiyama et al.<sup>31</sup> examined repeated CT-HA and reported that 18.8% of small stained spots progressed to HCC during a mean follow-up of 29 months. Indeed, it is technically difficult to confirm such nodules histologically, and detailed investigation is required in the future.

Second, problems of sampling error and sampling variation are always inherent in this kind of examination. Indeed, nine patients in our study progressed to HCC despite histologic diagnosis of RN at first biopsy. In these cases, we cannot exclude sampling errors or sampling variation. However, to minimize such problems, we routinely recorded the scene of the US-guided biopsy on video recorder to confirm that the sample was actually from the nodule. In addition, it is possible that samples obtained by needle biopsy did not reflect the most malignant part of the nodule, particularly when the nodule was heterogeneous. On this account, we usually obtained samples from two or more parts of a nodule to prevent sampling variation.

If a nodule showed a heterogeneous US pattern, we obtained samples from each part of the nodule.

We recognized limitations of biopsy diagnosis for predicting HCC progression, as nine patients whose initial histologic diagnosis was RN later developed HCC. For this reason, it is necessary to include imaging diagnostic techniques such as CT-HA or CT-AP to predict liver cancer development.

Our present results allow us to conclude that dysplastic nodules, in particular HGDN, are true precancerous lesions of HCC. Hemodynamic changes in these nodules predicted progression to HCC; however, angio-computed tomography is an invasive examination, and repeated studies are not feasible. Recently, it was reported that HCC and borderline lesions, like dysplastic or regenerative nodules, can be discriminated by Levovist contrast-enhanced US.<sup>36,37</sup> Because commercial use of Levovist was not possible until 1999 in our country, we have not included this technique in the current study. We are very interested in whether contrast-enhanced harmonic US is useful in predicting HCC development from hepatic nodular lesions, as this examination is less invasive than CT-HA or CT-AP and does not require hospitalization.

On the basis of changes observed during follow-up, our results indicated that enlargement of tumor diameter was the most important factor suggesting malignant transformation. Changes in US pattern also indicated HCC development. Indeed, low-echoic foci appeared in the center of hyperechoic nodules preceding HCC diagnosis in four patients who developed HCC. This finding is consistent with multistep carcinogenesis in HCC.

## REFERENCES

1. Baron RL, Oliver JH 3rd, Dodd GD 3rd, Nalesnik M, Holbert BL, Carr B. Hepatocellular carcinoma: evaluation with biphasic, contrast-enhanced, helical CT. *Radiology*. 1996;199:505-511.
2. Oliver JH, III, Baron RL, Federle MP, Rockette HE Jr. Detecting hepatocellular carcinoma: value of unenhanced or arterial phase CT imaging or both used in conjunction with conventional portal venous phase contrast-enhanced CT imaging. *AJR Am J Roentgenol*. 1996;167:71-77.
3. Hollett MD, Jeffrey RB Jr., Nino-Murcia M, Jorgensen MJ, Harris DP. Dual-phase helical CT of the liver: value of early hepatic arterial phase scans in the detection of small (1.5 cm) malignant hepatic neoplasms. *AJR*. 1995;164:879-884.
4. Larson RE, Semelka RC, Bagley AS, Molina PL, Brown ED, Lee JK. Hypervascular malignant liver lesions: comparison of various MR imaging pulse sequences and dynamic CT. *Radiology*. 1994;192:393-399.
5. Yamashita Y, Hatanaka Y, Yamamoto H, et al. Differential diagnosis of focal liver lesions: role of spin-echo and contrast-enhanced dynamic MR imaging. *Radiology*. 1994;193:59-65.

6. Peterson MS, Baron RL, Murakami T. Hepatic malignancies: usefulness of acquisition of multiple arterial and portal venous phase images at dynamic gadolinium-enhanced MR imaging. *Radiology*. 1996;201:337-345.
7. Ikeda K, Saitoh S, Koida I, et al. A multivariate analysis of risk factors for hepatocellular carcinogenesis: a prospective observation of 795 patients with viral and alcoholic cirrhosis. *Hepatology*. 1993;18:47-53.
8. Kasahara A, Hayashi N, Mochizuki K, et al. Risk factors for hepatocellular carcinoma and its incidence after interferon treatment in patients with chronic hepatitis C. Osaka Liver Disease Study Group. *Hepatology*. 1998;27:1394-1402.
9. Tsai JF, Jeng JE, Ho MS, et al. Effect of hepatitis C and B virus infection on risk of hepatocellular carcinoma: a prospective study. *Br J Cancer*. 1997;7:968-974.
10. Benvegna L, Gios M, Boccato S, Alberti A. Natural history of compensated viral cirrhosis: a prospective study on the incidence and hierarchy of major complications. *Gut*. 2004;53:744-749.
11. Sakurai M, Okamura J, Seki K, Kuroda C. Needle tract implantation of hepatocellular carcinoma after percutaneous liver biopsy. *Am J Surg Pathol*. 1983;7:191-195.
12. Smith EH. Complications of percutaneous abdominal fine-needle biopsy. Review. *Radiology*. 1991;178:253-258.
13. Sakamoto M, Hirohashi S, Shimosato Y. Early stages of multi-step hepatocarcinogenesis: adenomatous hyperplasia and early hepatocellular carcinoma. *Hum Pathol*. 1991;22:172-178.
14. Rogler CE, Chisari FV. Cellular and molecular mechanisms of hepatocarcinogenesis. *Semin Liver Dis*. 1992;12:265-278.
15. Fearon ER, Vogelstein B. A genetic model for colorectal tumorigenesis. *Cell*. 1990;61:759-767.
16. Cho KR, Vogelstein B. Genetic alterations in the adenoma-carcinoma sequence. *Cancer*. 1992;70(suppl 6):1727-1731.
17. International Working Party, terminology of nodular lesions of the liver. *Hepatology*. 1995;22:983-993.
18. Nakano M, Saito A, Yamamoto M, Doi M, Takasaki K. Stromal and blood vessel wall invasion in well-differentiated hepatocellular carcinoma. *Liver*. 1997;17:41-46.
19. Cox DR. Regression models and life tables. *J R Stat Soc*. 1972;34:187-220.
20. Takayama T, Makuuchi M, Hirohashi S, et al. Malignant transformation of adenomatous hyperplasia to hepatocellular carcinoma. *Lancet*. 1990;336:1150-1153.
21. Nakanuma Y, Terada T, Terasaki S, et al. "Atypical adenomatous hyperplasia" in liver cirrhosis: low-grade hepatocellular carcinoma or borderline lesion? *Histopathology*. 1990;17:27-35.
22. Eguchi A, Nakashima O, Okudaira S, Sugihara S, Kojiro M. Adenomatous hyperplasia in the vicinity of small hepatocellular carcinoma. *Hepatology*. 1992;15:843-848.
23. Terasaki S, Kaneko S, Kobayashi K, Nonomura A, Nakanuma Y. Histological features predicting malignant transformation of nonmalignant hepatocellular nodules: a prospective study. *Gastroenterology*. 1998;115:1216-1222.
24. Seki S, Sakaguchi H, Kitada T, et al. Outcomes of dysplastic nodules in human cirrhotic liver: a clinicopathological study. *Clin Cancer Res*. 2000;6:3469-3473.
25. Ferrell L, Wright T, Lake J, Roberts J, Ascher N. Incidence and diagnostic features of macroregenerative nodules vs. small hepatocellular carcinoma in cirrhotic livers. *Hepatology*. 1992;16:1372-1381.
26. Theise ND, Schwartz M, Miller C, Thung SN. Macroregenerative nodules and hepatocellular carcinoma in forty-four sequential adult liver explants with cirrhosis. *Hepatology*. 1992;16:949-955.
27. Hytiroglou P, Theise ND, Schwartz M, Mor E, Miller C, Thung SN. Macroregenerative nodules in a series of adult cirrhotic liver explants: issues of classification and nomenclature. *Hepatology*. 1995;21:703-708.
28. Borzio M, Fargion S, Borzio F, et al. Impact of large regenerative, low grade and high grade dysplastic nodules in hepatocellular carcinoma development. *J Hepatol*. 2003;39:208-214.
29. Hayashi M, Matsui O, Ueda K, et al. Correlation between the blood supply and grade of malignancy of hepatocellular nodules associated with liver cirrhosis: evaluation by CT during intraarterial injection of contrast medium. *AJR Am J Roentgenol*. 1999;172:969-976.
30. Lim JH, Cho JM, Kim EY, Park CK. Dysplastic nodules in liver cirrhosis: evaluation of hemodynamics with CT during arterial portography and CT hepatic arteriography. *Radiology*. 2000;214:869-874.
31. Tsuchiyama T, Terasaki S, Kaneko S, Kaji K, Kobayashi K, Matsui O. Tiny staining spots in liver cirrhosis associated with HCV infection observed by computed tomographic hepatic arteriography: follow-up study. *J Gastroenterol*. 2002;37:807-814.
32. Earls JP, Theise ND, Weinreb JC, et al. Dysplastic nodules and hepatocellular carcinoma: thin-section MR imaging of explanted cirrhotic livers with pathologic correlation. *Radiology*. 1996;1:207-214.
33. Matsui O, Kadoya M, Kameyama T, et al. Adenomatous hyperplastic nodules in the cirrhotic liver: differentiation from hepatocellular carcinoma with MR imaging. *Radiology*. 1989;173:123-126.
34. Choi D, Kim S, Lim J, et al. Preoperative detection of hepatocellular carcinoma: ferumoxides-enhanced MR imaging versus combined helical CT during arterial portography and CT hepatic arteriography. *AJR Am J Roentgenol*. 2001;176:475-482.
35. Bluemke DA, Paulson EK, Choti MA, DeSena S, Clavien PA. Detection of hepatic lesions in candidates for surgery: comparison of ferumoxides-enhanced MR imaging and dual-phase helical CT. *AJR Am J Roentgenol*. 2000;175:1653-1658.
36. Fracanzani AL, Burdick L, Borzio M, et al. Contrast-enhanced Doppler ultrasonography in the diagnosis of hepatocellular carcinoma and premalignant lesions in patients with cirrhosis. *Hepatology*. 2001;34:1109-1112.
37. Suzuki Y, Fujimoto Y, Hosoki Y, et al. Clinical utility of sequential imaging of hepatocellular carcinoma by contrast-enhanced power Doppler ultrasonography. *Eur J Radiol*. 2003;48:214-219.

## Prediction model of hepatocarcinogenesis for patients with hepatitis C virus-related cirrhosis. Validation with internal and external cohorts

Kenji Ikeda<sup>1,\*</sup>, Yasuji Arase<sup>1</sup>, Satoshi Saitoh<sup>1</sup>, Masahiro Kobayashi<sup>1</sup>, Takashi Someya<sup>1</sup>, Tetsuya Hosaka<sup>1</sup>, Norio Akuta<sup>1</sup>, Yoshiyuki Suzuki<sup>1</sup>, Fumitaka Suzuki<sup>1</sup>, Hitomi Sezaki<sup>1</sup>, Hiromitsu Kumada<sup>1</sup>, Akihisa Tanaka<sup>2</sup>, Hideharu Harada<sup>2</sup>

<sup>1</sup>Department of Gastroenterology, Okinaka Memorial Institute for Medical Research, Toranomon Hospital, Toranomon 2-2-2, Minato-ku, Tokyo 105-8470, Japan

<sup>2</sup>Department of Gastroenterology, Tokyo National Hospital, National Hospital Organization, Tokyo, Japan

See Editorial, pages 1013–1016

**Background/Aims:** To estimate hepatocarcinogenesis rates in patients with hepatitis C virus (HCV)-related cirrhosis, an accurate prediction table was created.

**Methods:** A total of 183 patients between 1974 and 1990 were assessed for carcinogenesis rate and risk factors. Predicted carcinogenesis rates were validated using a cohort from the same hospital between 1991 and 2003 ( $n=302$ ) and an external cohort from Tokyo National Hospital between 1975 and 2002 ( $n=205$ ).

**Results:** The carcinogenesis rates in the primary cohort were 28.9% at the 5th year and 54.0% at the 10th year. A proportional hazard model identified alpha-fetoprotein ( $\geq 20$  ng/ml, hazard ratio 2.30, 95% confidence interval 1.55–3.42), age ( $\geq 55$  years, 2.02, 95% CI 1.32–3.08), gender (male, 1.58, 95% CI 1.05–2.38), and platelet count ( $< 100,000$  counts/mm<sup>3</sup>, 1.54, 95% CI 1.04–2.28) as independently associated with carcinogenesis. When carcinogenesis rates were simulated in 16 conditions according to four binary variables, the 5th- and 10th-year rates varied from 9 to 64%, and 21–93%, respectively. Actual carcinogenesis rates in the internal and external validation cohorts were similar to those of the simulated curves.

**Conclusions:** Simulated carcinogenesis rates were applicable to patients with HCV-related cirrhosis. Since, hepatocarcinogenesis rates markedly varied among patients depending on background features, we should consider stratifying them for cancer screening and cancer prevention programs.

© 2006 European Association for the Study of the Liver. Published by Elsevier B.V. All rights reserved.

**Keywords:** Cirrhosis; Hepatocellular carcinoma; Carcinogenesis; Hepatitis C virus; Simulation; Proportional hazard model; Validation; Prediction

### 1. Introduction

There is increasing evidence that chronic hepatitis C virus (HCV) infection is closely associated with the occurrence of hepatocellular carcinoma (HCC) [1–4]. The

incidence of patients with HCV-related HCC has increased recently in several parts of the world [5–9]. In Japan, blood transfusion and parenteral drug use became prevalent in 1960s, and patients with HCV-related cirrhosis gradually increased around 1980s. Since, an effective and truly curative therapy for a large and advanced HCC still remains limited at best, evaluation and assessment of carcinogenesis in chronic liver disease and detection at an early stage of HCC are of great importance. Reports of HCC development rates in HCV-cirrhosis differ [10–13], probably due to

Received 5 February 2005; received in revised form 31 January 2006; accepted 20 February 2006; available online 13 March 2006

\* Corresponding author. Tel.: +81 44 877 5111; fax: +81 44 860 1623.  
E-mail address: ikedakenji@tora.email.ne.jp (K. Ikeda).



differences of patient characteristics in varied study populations. The lack of reliable data as to the natural history of cirrhosis makes it difficult to evaluate the exact role and cost-effectiveness of interferon therapy.

Platelet count has been used to predict hepatocarcinogenesis [10,13,14], but its usefulness for distinguishing the HCC appearance rate is based on discrimination between chronic hepatitis and cirrhosis [15–18]. Predicting carcinogenesis solely on the basis of platelet count is less valuable in a cohort of patients with cirrhosis, because the liver disease has already advanced to a certain stage with a uniformly low platelet count. When a cohort of patients with HCV-related cirrhosis is analyzed by platelet count, it is usually not possible to discriminate between a super-high-risk group for carcinogenesis and a relatively low-risk group. The availability of a general model that can accurately predict the HCC development rate in HCV-related disease based on readily available data would be helpful in planning the treatment of these patients. Moreover, such a model could be used for the selection and stratification of patients for clinical trials.

In this study, we tried to develop a prediction model for hepatocarcinogenesis rate, using a large cohort with a long observation period. This model was also validated with two independent patient cohorts for generalization and clinical application.

## 2. Patients and methods

### 2.1. Study population

Among 457 consecutive patients diagnosed with liver cirrhosis between 1974 and 1990 at Toranomon Hospital, Tokyo, 258 patients had positive anti-HCV antibody (second-generation anti-HCV, enzyme-linked immunosorbent assay, Dainabot, Japan), positive HCV-RNA, and negative hepatitis B surface antigen (HBsAg, radioimmunoassay, Dainabot, Tokyo, Japan). Among them, 75 patients met either of the following exclusion criteria: (1) possible association with HCC, (2) association of hemochromatosis, autoimmune liver disease, primary biliary cirrhosis, alpha-1-antitrypsin deficiency, or Wilson disease, (3) daily drinking habit of 75 g or more, (4) alpha-fetoprotein (AFP) of 400 ng/ml or higher, (5) advanced and decompensated stage of cirrhosis with encephalopathy and refractory ascites, or (6) a short follow-up period of 6 months or less. We excluded those patients with Child–Pugh [19] stage C, because of substantial difference in carcinogenesis [20,21]. Consequently, 183 patients were retrospectively analyzed for HCC appearance rate.

### 2.2. Background and laboratory data

Table 1 summarizes the profiles and data of the 183 patients at the time of diagnosis. The group consisted of 92 men and 91 women aged from 28 to 80 (median, 55 years). The diagnosis of cirrhosis was made by peritoneoscopy, biopsy or both in 118 patients, and by clinical symptoms with ultrasonographic findings in 55 patients. When the ultrasonography (US) showed a typical irregular-surfaced liver with coarse internal architecture in addition to overt ascites or esophageal varices demonstrated by fiberoptic examination, we regarded the disease as cirrhosis. Although 12.7% of patients (23/181) showed normal aminotransferases at the time of the diagnosis of cirrhosis, all of those patients had been followed up as having chronic hepatitis with fluctuated aminotransferases.

**Table 1**

**Patient profiles and laboratory data at the time of diagnosis of cirrhosis (primary cohort of Toranomon Hospital between 1974 and 1990, n = 183)**

Demography and backgrounds		
Total number		183
Sex (M/F)		92/91
Age, median (range)		55 (28–80)
Diagnostic method		
Peritoneoscopy and/or biopsy		118 (64.5%)
Clinical (ultrasonography plus varices or ascites)		65 (35.5%)
History of blood transfusion		82 (44.8%)
Diabetes mellitus		23 (12.6%)
Previous medical history of chronic hepatitis		34 (18.6%)
Interferon therapy during observation		24 (12.0%)
Refractory ascites and/or encephalopathy		0
Hepatitis B surface antigen, positive		0 (100%)
Anti-hepatitis C virus, positive		183 (100%)
Hepatitis C virus RNA, positive		183 (100%)
Child–Pugh score A		136 (74.3%)
Child–Pugh score B		47 (25.7%)
Observation period (year) median (range)		10.5 (0.5–26.0)
Laboratory data		
	Median (range)	Valid data
Albumin (normal, 3.9–5.1 g/dl)	3.9 (2.5–5.1)	183
Bilirubin (normal, 0.3–1.1 mg/dl)	1.1 (0.4–4.4)	183
Aspartic transaminase (normal, $\leq 38$ IU/L <sup>a</sup> )	69 (17–372)	181
Alanine transaminase (normal, $\leq 50$ IU/L <sup>a</sup> )	56 (9–282)	181
Platelet (normal, $149\text{--}315 \times 1000^3/\text{mm}^3$ )	95 (33–213)	183
ICG R15 <sup>b</sup> (normal, $\leq 10\%$ )	27 (6–81)	173
Prothrombin time (normal, $\geq 70\%$ )	79 (54–100)	183
Gamma-globulin (normal, $< 1.5$ g/dl)	1.9 (1.0–3.5)	174
Alpha-fetoprotein (normal, $< 5$ mg/L)	16.5 (3–256)	166
HCV genotype <sup>c</sup>		
1b	107 (69.9%)	153
2a/2b	39 (25.5%)	
Combined/others	7 (4.6%)	
Not examined	30	

<sup>a</sup> Numbers of normal aspartic and alanine transaminases were 25 (13.8%) and 69 (38.1%), respectively. Both transaminases were normal at the time of the diagnosis of cirrhosis in 23 patients (12.7%).

<sup>b</sup> ICG R15: indocyanine green retention rate at 15 min.

<sup>c</sup> HCV genotyping was classified according to Simmonds et al. [22].

HCV-RNA measurement and HCV genotyping [22] are analyzed with nested polymerase chain reaction using initial sera stored at  $-80^\circ\text{C}$ .

### 2.3. Follow-up of patients and diagnosis of hepatocellular carcinoma

Patients were followed-up monthly following the diagnosis of cirrhosis by monitoring hematological and biochemical data. Diagnostic imaging by US was taken approximately once a year in each patient. After 1987, imaging procedures with US or computerized tomography (CT) were performed twice or more per year in the majority of patients for early detection of HCC. HCC was diagnosed by typical hypervascular characteristics on angiography. When combined use of imagings could not demonstrate a typical image of HCC (13/107, 12.1%), a fine needle biopsy was obtained for microscopic examination.

Twenty-four patients (13.1%) received interferon during the follow-up period. Since the therapy could affect the natural clinical course of viral hepatitis, they were treated as censored at the time of the initiation of interferon in the analysis. Sixteen (8.7%) cases were lost to follow-up, and median observation period was 10.5 years (range, 7.0–14.9). Those patients lost to follow-up were treated as censored data in the following statistics.

Any death unrelated to liver disease and cirrhosis-related liver failure were also classified as withdrawal and regarded as a censored case.

#### 2.4. Statistical analysis and predictive model for carcinogenesis

The HCC development rate was analyzed using Kaplan–Meier technique [23] and differences in curves were tested using the log-rank test. The independent risk factors associated with the rate of HCC development were studied using stepwise method of non-time-dependent Cox regression analysis [24]. Potential risk factors assessed for liver carcinogenesis included the following 16 variables: age, sex, HCV genotype, association of diabetes mellitus, total alcohol intake (cumulative alcohol intake  $\geq 200$  kg), family history of liver disease, history of blood transfusion, association of ascites, serum aspartic transaminase (AST), alanine transaminase (ALT), gamma-glutamyl transpeptidase (GGT), globulin, platelet count, AFP, indocyanine green retention rate at 15 min (ICG R15), and Child–Pugh score [19]. Each variable was transformed into categorical data consisting of two simple ordinal numbers (zero or one) for univariate and multivariate analyses. Although, proper transformation of variables were recommended in this kind of study [25], logarithmic transformation was not employed even for variables with non-symmetric distribution, because simple dichotomization also seemed reliable and robust statistically and because the simplicity was considered to bring about eventual clinical usefulness. Although, a cut-off value of 20 ng/ml proved to be an important point in our previous studies about prediction of liver cancer development in cirrhosis [10,26], other threshold values of dichotomizations were chosen from near figures to median values. In running the proportional regression analysis, care was taken to avoid overfitting the model by studying no more than one variable for every 10 events of carcinogenesis. Goodness-of-fit test together with log-minus-log plot was performed to confirm the proportionality assumption in the model. Since, missing data was not replaced, reduced numbers of cases were used in multivariate analysis. A *P*-value of less than 0.05 was considered to be significant.

The prognostic model was generated using Cox's regression procedure from the database of the 183 cirrhotic patients in Toranomon Hospital from 1974 to 1990. Using a final model for prediction of HCC appearance, carcinogenesis rate was predicted by substituting the corresponding ordinal numbers (zero or one) for every significant covariate in a given condition of the patients. Simulated carcinogenesis rates were computed for each state consisting of all statistically significant variables.

An internal and external cohorts of patients with HCV-positive cirrhosis verified the predicted carcinogenesis rates and curves: a cohort of 302 patients with HCV-cirrhosis diagnosed at Toranomon Hospital between 1991 and 2003 (internal validation group), and a cohort of 205 patients diagnosed at Tokyo National Hospital, Tokyo, Japan, between 1975 and 2002 (external validation group). The actual survival rates were calculated by the Kaplan–Meier technique in each risk group from the two validation cohorts, and evaluated by log-rank test according to the procedures of Christensen et al. [27].

Data analysis was performed with SAS version 9.1.3 software (SAS Institute, Inc., NC, USA).

The Human Ethics Review Committee of Toranomon Hospital approved the study protocol.

### 3. Results

#### 3.1. Rate of hepatocellular carcinogenesis and risk factors

During the observation period, 107 (58.5%) out of 183 patients with HCV-related cirrhosis developed HCC. The cumulative HCC appearance rates of all patients were 15.0% at the end of the 3rd year, 28.9% at the 5th year, 37.8% at the 7th year, and 54.0% at the 10th year. Crude HCC development curve was drawn together with those of internal and external validation cohorts (Fig. 1).

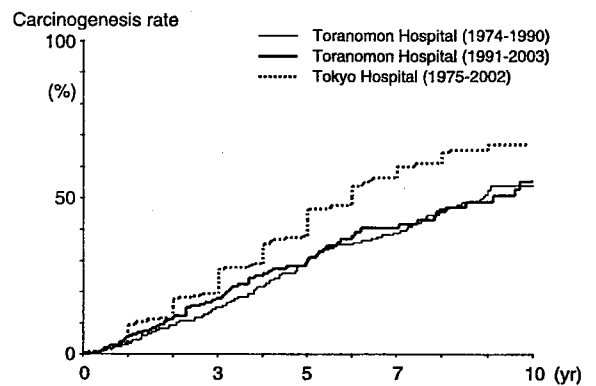


Fig. 1. Cumulative hepatocellular carcinogenesis rates in 183 patients who were diagnosed with HCV-related cirrhosis at Toranomon Hospital between 1974 and 1990. The 5th and 10th year rates were 28.9 and 54.0%, respectively (solid thin line). HCC appearance curves were also drawn in the internal (solid thick line) and external (dotted thick line) validation cohorts. The cancer appearance rate of Tokyo Hospital was significantly higher than those of the other two cohorts from Toranomon Hospital ( $P=0.0015$ , log-rank test).

Carcinogenesis rate in Tokyo Hospital was significantly higher than that of Toranomon Hospital (log-rank test  $P=0.0015$ ). The risk factors for carcinogenesis were explored using non-time dependent proportional hazard analysis. In the final step of multivariate analysis, AFP ( $P<0.001$ ), age ( $P=0.001$ ), sex ( $P=0.030$ ), and platelet count ( $P=0.031$ ), were identified as independent significant predictors of future HCC appearance (Table 2). The hazard ratio of patients with AFP value of  $\geq 20$  ng/ml was 2.30 compared with those with lower AFP value, and the hazard ratio of patients of  $\geq 55$  years of age was 2.02 compared with younger patients. Child–Pugh score did not affect the carcinogenesis rate independently.

As for 23 patients with normal aminotransferases initially, 5- and 10-years carcinogenesis rates were 27.3 and 39.4%, respectively.

#### 3.2. Simulation of carcinogenesis rates in patients with each prognostic factor

Simulated carcinogenesis curves were generated in each patient group with the Cox proportional hazard model by substituting the corresponding value for each parameter. Based on the four significant covariates, a total of 16 carcinogenesis curves were drawn, and simulated carcinogenesis rates were also estimated in the subgroups. To facilitate the practical use of the prediction model for carcinogenesis rate, we tabulated the results of estimated HCC appearance rates at the end of the 5th and 10th year (Table 3), in which calculated rates for a patient could be easily found for a given set of patient parameters (AFP, age, platelet and gender).

The model showed that when a patient is a male younger than 55 years, with a platelet count less than  $100,000/\text{mm}^3$  and an AFP value less than 20 ng/ml, the estimated hepatocarcinogenesis rates are 19% at the end of the 5th

**Table 2**  
**Factors associated with hepatocarcinogenesis (compensated cirrhosis,  $n=183$ , 1974–1990 cohort of Toranomon Hospital)**

Factors	Category	No. of primary cohort	<i>B</i>	SE	Hazard ratio (95% CI)	<i>P</i>
Alpha-fetoprotein	0: <20 (ng/ml)	97	0.83	0.20	1	<0.001
	1: $\geq$ 20 (ng/ml)	69			2.30 (1.55–3.42)	
Age	0: <55 (year)	80	0.74	0.22	1	0.001
	1: $\geq$ 55 (year)	103			2.02 (1.32–3.08)	
Sex	0: Female	91	0.46	0.21	1	0.030
	1: Male	92			1.58 (1.05–2.38)	
Platelet count	0: $\geq$ 100,000/mm <sup>3</sup>	87	0.43	0.20	1	0.031
	1: <100,000/mm <sup>3</sup>	96			1.54 (1.04–2.28)	

year and 43% at the 10th year. The highest carcinogenesis rates were computed for males 55 years or older with a low platelet count and a high AFP value (64% at the 5th year, 93% at the 10th year), while the lowest estimated rates were found in females younger than 55 years with a high platelet count and a low AFP value (9% at the 5th year, 21% at the 10th year).

### 3.3. Validation of the prediction values of carcinogenesis rate

The reliability of the estimated HCC development rates was validated using internal (Toranomon Hospital, 1991–2003) and external (Tokyo National Hospital, 1975–2002) cohorts consisting of patients with HCV-related cirrhosis. Table 4 shows brief characteristics of patients in the two cohorts.

Since, HCC development curves were coarse and unreliable when a subgroup consisted of fewer patient number than 15, six figures of carcinogenesis curves were shown in principal subgroups consisting of  $\geq 20$  patients in each validation cohort (Fig. 2). When the parameters for all of the four significant covariates were at their worst (male  $\geq 55$  years, AFP  $\geq 20$  ng/ml, and platelet count  $< 100,000/\text{mm}^3$ ), the simulated carcinogenesis rates were 64% at the end of the 5th year and 93% at the 10th year. On the other hand, the actual carcinogenesis rates in the internal and external validation cohorts were 54.9 and 61.5% at the 5th year, and 100 and 100% at the 10th year, respectively. The latter curves corresponded significantly with the simulation-generated carcinogenesis rate (Fig. 2a). Similarly, the other five simulated carcinogenesis curves were compared with both internal and external validation cohorts (Fig. 2b–f). Although the remaining 10 curves were not shown because of lack of sufficient patient number in the subgroup, actual carcinogenesis curves for the internal and external cohorts showed very analogous rates to the simulated ones, indicating that the simulation effectively predicted the future carcinogenesis rates. When we compared actual carcinogenesis rates in the validation groups with their calculated simulation values, 74.0% (375/507) and 70.4% (357/507) of the validation values for their 5th and 10th rates were coincident with those of predicted ones and stayed in an interval between +10% and –10% of

simulated values. Although those patients in a large cohort consisting of 15 patients or more (e.g. Fig. 2a–f) usually showed a reliable and consistent values with simulated ones, those in a small cohort often revealed a labile and different values from simulated ones.

When a combined patient group of the three cohorts was analyzed, the same factors proved to affect the HCC appearance rate significantly: AFP (hazard ratio 2.19,  $P < 0.001$ ), age (1.96,  $P < 0.001$ ), sex (1.80,  $P < 0.001$ ), and platelet count (1.51,  $P = 0.009$ ). Hazard ratios with 95% confidence interval and *P*-values were also calculated in the individual validation groups (Table 5).

In addition, we evaluated the ‘group factor’ (study group, internal, and external validation groups) as a covariate in ordinary proportional hazard analysis for a combined patient group. Although, the internal and validation groups showed a slightly low (0.90) and high (1.26) hazard ratios for HCC development compared with that of the study group, the other four factors proved to show higher hazard ratios in the model (Table 6).

**Table 3**  
**Simulated carcinogenesis rates in stratified patient groups according to gender, age, platelet count, and alpha-fetoprotein value**

Gender	Age (years)	Platelet	Alpha-feto-protein (ng/ml)	Simulated carcinogenesis rate (%)	
				5-year	10-year
Men	<55	<100,000/mm <sup>3</sup>	<20	19	43
			$\geq 20$	42	77
		$\geq 100,000/\text{mm}^3$	<20	13	31
			$\geq 20$	32	65
	$\geq 55$	<100,000/mm <sup>3</sup>	<20	32	65
			$\geq 20$	64	93
		$\geq 100,000/\text{mm}^3$	<20	23	50
			$\geq 20$	50	83
Women	<55	<100,000/mm <sup>3</sup>	<20	13	30
			$\geq 20$	30	61
		$\geq 100,000/\text{mm}^3$	<20	9	21
			$\geq 20$	22	47
	$\geq 55$	<100,000/mm <sup>3</sup>	<20	22	49
			$\geq 20$	49	83
		$\geq 100,000/\text{mm}^3$	<20	16	37
			$\geq 20$	37	69

**Table 4**  
**Patient profiles and laboratory data of two cohorts for validation: an internal cohort (Toranomon Hospital from 1991 to 2003,  $n=302$ ) and an external cohort (Tokyo National Hospital,  $n=205$ )**

	Internal cohort (Toranomon Hospital, 1991–2003)		External cohort (Tokyo National Hospital, 1975–2002)	
Demography and backgrounds				
Total number	302		205	
Sex (M/F)	166/136		111/94	
Age (year) <sup>a</sup>	59 (28–80)		62 (13–83)	
Diagnostic method				
Peritoneoscopy and/or biopsy	128		115	
Clinical diagnosis	174		90	
Interferon therapy				
Yes	105 (34.8%)		12 (5.9%)	
No	197		193	
Observation period (year) <sup>a</sup>	5.3 (0.5–13.9)		7.5 (0.5–30.8)	
Laboratory examination				
	Internal cohort (Toranomon Hospital, 1991–2003)	Valid data	External cohort (Tokyo National Hospital, 1975–2002)	Valid data
Platelet ( $\times 1000^3/\text{mm}^3$ ) <sup>a</sup>	91.5 (25–223)	302	100 (19–310)	205
Alpha-fetoprotein (ng/ml) <sup>a</sup>	14 (1–380)	296	15 (2–365)	205

<sup>a</sup> Expressed by median (range).

#### 3.4. Estimation of carcinogenesis rates by number of unfavorable risk factors

The prognostic model showed that the HCC development rate was significantly affected by the following four unfavorable factors: high AFP ( $\geq 20$  ng/ml), older age ( $\geq 55$  years), low platelet count ( $< 100,000/\text{mm}^3$ ), and male sex. Although, limitation of predictability could not be avoided because of different values of hazard ratios, we attempted to make more convenient HCC prediction curves. Five carcinogenesis curves were generated according to the number of unfavorable risk factors among the four significant covariates: no factors, one, two, three, and four unfavorable factors. When no unfavorable factor was found in a cohort of HCV-cirrhosis, the hepatocarcinogenesis rates were 9% at the end of the 5th year and 21% at the 10th year. Similarly, when one, two, three and four factors were found in a cohort, the carcinogenesis rates were 16, 28, 46, and 64% at the 5th year, and 35, 55, 78, and 93% at the 10th year, respectively (log-rank test,  $P=0.0001$ ).

To validate the reliability of the concise prediction curves, the actual carcinogenesis curves were generated by the product-limit method for the 1991–2003 internal cohort of our hospital (Fig. 3). All actual carcinogenesis curves fitted well with the simulated curves, except for the subgroup with 'no unfavorable factors': none of 11 patients in this subgroup developed HCC during a median observation period of 10.0 years (25 percentile 8.1 years, 75 percentile 10.8 years).

## 4. Discussion

Ten-year-rate of HCC development has been reported as 50–80% in some cohorts of HCV-positive cirrhosis

[10–13,28], and the cohorts in our hospital showed 54–55%, and Tokyo Hospital 68%. However, the reasons for the significant differences found in the rates among various hospitals have not been fully elucidated until recently. Many risk factors have been identified as important for the development of HCC in patients with hepatitis or cirrhosis [10,13,29,30], but of even greater interest is the precise prediction of HCC. In order to establish a reliable method for predicting carcinogenesis risk in a variety of patients with HCV-positive cirrhosis (compensated and decompensated), we investigated a large cohort of patients with few dropout cases, using a multivariate proportional model.

In the final step of multivariate analysis, AFP, age, platelet and gender were independently associated with HCC development in the primary cohort of our hospital. A total of 16 simulated carcinogenesis curves were drawn according to the four binary factors. Surprisingly, the estimated carcinogenesis curves significantly differed from each other among the stratified subgroups in our hospital, depending on demographic and background characteristics. In the case of a patient with HCV-cirrhosis, the combination of age, gender, AFP and platelet count could give important prognostic information about future carcinogenesis risk. When HCC appearance rates were simulated under 16 conditions according to the four binary variables identified by multivariate analysis, the 5th year rate varied from 9 to 64%, and 10th year rates from 21 to 93%. On the other hand, aminotransferase level and Child–Pugh score were poor predictors of carcinogenesis in patients with HCV-cirrhosis.

We recognized that the HCC development rate should be evaluated more specifically for each subgroup than for the entire cohort of HCV-positive cirrhosis patients. Integration of the four predictive factors could provide useful information about HCV-related carcinogenesis in actual clinical practice. The reported diversity of carcinogenesis