

## Effects of Statins on Circulating Oxidized Low-density Lipoprotein in Patients With Hypercholesterolemia

Shigenobu INAMI,<sup>1</sup> MD, Kentaro OKAMATSU,<sup>1</sup> MD, Masamichi TAKANO,<sup>1</sup> MD,  
Gen TAKAGI,<sup>1</sup> MD, Shunta SAKAI,<sup>1</sup> MD, Junko SANNO,<sup>1</sup> MD,  
and Kyoichi MIZUNO,<sup>1</sup> MD

### SUMMARY

Recently, it has been reported that circulating oxidized low-density lipoprotein (Ox-LDL) might be a pivotal indicator for coronary artery disease and the severity of acute coronary syndromes. The purpose of this study was to investigate the effects of statins on Ox-LDL in patients with hypercholesterolemia.

Sixteen patients with hypercholesterolemia were randomly assigned to 2 groups, one received 10 mg of pravastatin ( $n = 8$ ) and the other received 20 mg of fluvastatin ( $n = 8$ ). The plasma level of Ox-LDL was measured using a newly developed sandwich enzyme-linked immunosorbent assay (ELISA) method.

There were no differences between the two groups in Ox-LDL, total cholesterol (TC), or LDL cholesterol (LDL-C) at the baseline. The reduction in Ox-LDL in the fluvastatin group was significantly higher than that in the pravastatin group (47.5% versus 25.2%,  $P = 0.033$ ). The reductions in TC and LDL-C did not differ between the two groups. Conclusion: The present study has shown for the first time that the level of circulating Ox-LDL was significantly decreased by treatment with statins. In addition, the lowering effect of statins on the circulating Ox-LDL was independent of their lipid-lowering effect. Fluvastatin was more effective than pravastatin with regard to decreasing the circulating Ox-LDL. (*Jpn Heart J* 2004; 45: 969-975)

**Key words:** Statin, Pleiotropic effect, Oxidized low-density lipoprotein

STATINS have been demonstrated to reduce the risk of coronary heart disease (CHD) via their potent effect on lowering the plasma level of low-density lipoprotein-cholesterol (LDL-C) in several large-scale trials.<sup>1,2)</sup> On the other hand, it has also been reported that not only the increased levels but also the oxidative modification of LDL-C contributes to the development of atherosclerosis and CHD.<sup>3-5)</sup> Therefore, treatment to oxidatively modify LDL-C should be considered in addition to lowering its plasma levels to prevent CHD.

From the <sup>1</sup>Department of Internal Medicine, Chiba Hokusoh Hospital, Nippon Medical School, Chiba, Japan.  
Address for correspondence: Kyoichi Mizuno, MD, Department of Internal Medicine, Chiba Hokusoh Hospital, Nippon Medical School, 1715, Kanakari, Imba-mura, Imba-gun, Chiba 270-1694, Japan.  
Received for publication March 12, 2004.  
Revised and accepted May 10, 2004.

Recently, it has become possible to measure circulating oxidized LDL (Ox-LDL). It was demonstrated that an elevated level of plasma Ox-LDL was associated with the existence of CHD<sup>6)</sup> and the severity of acute coronary syndromes (ACS).<sup>7)</sup> In addition, Hulthe, *et al* demonstrated that the circulating Ox-LDL was associated with the development of subclinical atherosclerosis and inflammatory processes.<sup>8)</sup> Therefore, it would appear to be important to control the plasma level of Ox-LDL in patients with subclinical atherosclerosis as well as stable, unstable ischemic syndromes.

We were unable to find in the literature any reports concerning the effects of statins on circulating Ox-LDL. Several statins can be used clinically. We were particularly interested in fluvastatin, which reportedly has radical scavenging activity and is effective in the oxidative modification of LDL-C,<sup>9-11)</sup> and pravastatin which is used worldwide. The purpose of this study was to investigate the effects of fluvastatin and pravastatin on circulating Ox-LDL. The plasma level of Ox-LDL was measured by a sandwich enzyme-linked immunosorbent assay (ELISA) method, which is a sensitive assay using a monoclonal antibody (DLH3)<sup>12,13)</sup> recently developed by Itabe and Kohno.

#### METHODS

This study is a prospective, randomized trial to investigate the effects of fluvastatin and pravastatin on the plasma levels of Ox-LDL. At our outpatient clinic, we examined 16 patients with hypercholesterolemia (men:  $n = 5$ , women:  $n = 11$ ), who were randomly divided into 2 groups; a fluvastatin group ( $n = 8$ ) and a pravastatin group ( $n = 8$ ). Informed consent was obtained from each subject, and our study protocol was approved by our institutional review boards. All subjects were asked about their medical history and life-style including smoking status, consumption of red wine and other beverages, antioxidant vitamin use, and dietary intake of selected foods. Fluvastatin or pravastatin was administered for 12 weeks orally to the groups without any life-style modification. Standard doses for both drugs (fluvastatin, 20 mg per day and pravastatin 10 mg per day) were used. At the start and end of the study, venous blood samples were withdrawn after a 12 hour-fasting period, with no alcohol intake during the previous 24 hours and no smoking in the morning on that day. The blood samples were collected in EDTA-containing tubes and centrifuged at 3000 g for 15 minutes at room temperature within 20 minutes. The plasma was collected in antioxidant-containing tubes and stored at 0°C. The plasma levels of total cholesterol (TC), triglycerides (TG), LDL-C, high-density lipoprotein-cholesterol (HDL-C), lipoprotein(a) (Lp(a)), and Ox-LDL were also measured.

**Laboratory assays:** The plasma TC, TG, LDL-C, and HDL-C levels were measured using established methods with commercial kits. The plasma Ox-LDL assays were performed by Kyowa Medics Corporation according to the assay described by Kohno, *et al.*<sup>13)</sup> The method includes sandwich-type ELISA using anti-oxidized phosphatidylcholine monoclonal antibody (DLH3) and anti-human apolipoprotein-B antibody.

**Statistical analysis:** The data are presented as the mean  $\pm$  SD. Whether the data were normally distributed or not was examined using the Kolmogorov-Smirnov test. If the data were normally distributed, the unpaired *t*-test was used to compare between the two groups, otherwise the Mann-Whitney U-test was used. Discontinuous parameters were compared by  $\chi^2$  analysis. The correlation between the baseline plasma levels of LDL-C and Ox-LDL was assessed with the Pearson correlation and scatter plots. A *P* value  $< 0.05$  was considered to be statistically significant.

## RESULTS

**Baseline characteristics:** The baseline characteristics for each group are summarized in Table I. The plasma Ox-LDL and lipid levels were similar in the 2 groups at baseline. There were no significant differences in the frequency of coronary risk factors between the 2 groups. None of our subjects was taking antioxidant supplements and none were habitual consumers of red wine. Before intervention, the plasma level of Ox-LDL in our cohort did not correlate with that of LDL.

Table I. Baseline Characteristics of Patients

		Pravastatin (n = 8)	Fluvastatin (n = 8)	P value
Age		62.4 $\pm$ 8.7	61.3 $\pm$ 14.9	0.147
Gender (male)	n (%)	2 (25.0)	3 (37.5)	0.589
Hypertension	n (%)	3 (37.5)	4 (50.0)	0.610
Diabetes mellitus	n (%)	2 (25.0)	1 (12.5)	0.520
Obesity	n (%)	4 (50.0)	4 (50.0)	1.000
Smoking	n (%)	2 (25.0)	2 (25.0)	1.000
Ox-LDL	U/dl	12.0 $\pm$ 5.5	17.8 $\pm$ 9.5	0.157
TC	mg/dL	240.9 $\pm$ 21.3	261.4 $\pm$ 29.5	0.133
LDL-C	mg/dL	166.5 $\pm$ 24.6	178.0 $\pm$ 15.2	0.283
TG	mg/dL	123.8 $\pm$ 61.1	131.6 $\pm$ 42.5	0.771
HDL-C	mg/dL	52.3 $\pm$ 20.5	54.7 $\pm$ 12.5	0.781
Lp (a)	mg/dL	25.6 $\pm$ 15.2	25.3 $\pm$ 14.7	0.968

Values presented are mean  $\pm$  SD or number (%).

Ox-LDL = oxidized low-density lipoprotein; TC = total cholesterol; LDL-C = low-density lipoprotein cholesterol; TG = triglycerides; HDL-C = high-density lipoprotein cholesterol; Lp (a) = Lipoprotein (a).

**Changes in plasma levels of TC, TG, LDL-C, HDL-C, and Lp(a):** In both the fluvastatin and pravastatin groups, the plasma levels of TC and LDL-C decreased significantly after treatment (Table II). Pravastatin and fluvastatin resulted in 12.7% and 14.1% reductions in the plasma levels of TC and 21.5% and 15.1% reductions in LDL-C, respectively. The percent reduction in TC and LDL-C did not differ significantly between the two groups ( $P = 0.66$ ,  $P = 0.19$ , respectively).

Table II. Change in Plasma Levels of Lipids

		Pravastatin		Fluvastatin	
		Before	After	Before	After
TC	mg/dL	240.9 ± 21.3	210.1 ± 19.2*	261.4 ± 29.5	223.3 ± 33.0*
LDL-C	mg/dL	166.5 ± 24.6	130.7 ± 21.2*	178.0 ± 15.2	151.0 ± 27.3*
TG	mg/dL	123.8 ± 61.1	110.3 ± 47.4	131.6 ± 42.5	102.6 ± 37.9
HDL-C	mg/dL	52.3 ± 20.5	55.1 ± 22.6	54.7 ± 12.5	57.8 ± 12.2
Lp (a)	mg/dL	25.6 ± 15.2	26.3 ± 17.9	25.3 ± 14.7	24.4 ± 22.1
Ox-LDL	U/dL	12.0 ± 5.5	9.5 ± 6.1*	17.8 ± 9.5	8.7 ± 4.4*
Ox-LDL/LDL-C	(U/dL)/(mg/dL)	0.071 ± 0.026	0.071 ± 0.038	0.101 ± 0.054	0.058 ± 0.024*

Values presented are mean ± SD.

TC = total cholesterol; LDL-C = low-density lipoprotein cholesterol; TG = triglycerides; HDL-C = high-density lipoprotein cholesterol; Lp (a) = lipoprotein (a); Ox-LDL = oxidized low-density lipoprotein.

\*: versus before treatment  $P < 0.05$ .

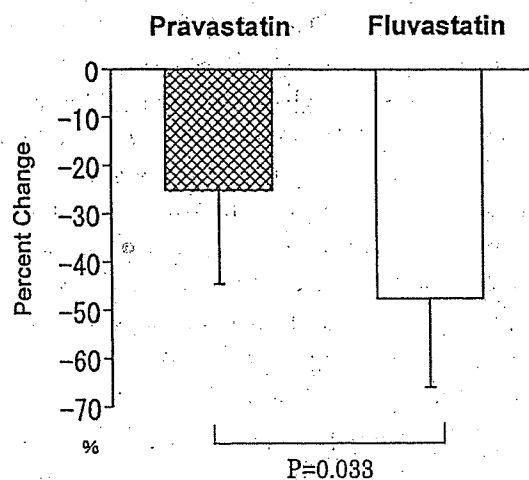


Figure 1. The percent reduction in plasma levels of oxidized low-density lipoprotein.

The percent reduction in the plasma levels of oxidized low-density lipoprotein was significantly higher in the fluvastatin group than in the pravastatin group (47.5% versus 25.2%,  $P = 0.033$ ).

Although the plasma levels of TG decreased and the plasma HDL-C levels increased after treatment in both groups, both changes were not significant. **Changes in the plasma levels of Ox-LDL:** The plasma levels of Ox-LDL in the pravastatin and fluvastatin groups decreased significantly after intervention ( $P = 0.003$ ,  $P = 0.010$ , respectively) (Table II). The percent reduction in the plasma levels of Ox-LDL was significantly higher in the fluvastatin group than in the pravastatin group (47.5% versus 25.2%,  $P = 0.033$ ) (Figure 1). Furthermore, the Ox-LDL/LDL-C ratio in the plasma decreased significantly in the fluvastatin group ( $P = 0.026$ ) (Table II).

### DISCUSSION

As an atherogenic factor, Ox-LDL has been reported to have various actions resulting in the chemotaxis of monocytes, the up-regulation of endothelial adhesion molecules, stimulation of growth factor and chemokine expression, and proliferative effects on smooth muscle cells and monocytes.<sup>14,15</sup> In addition, the cytotoxicity of Ox-LDL from cultured endothelial cells has been clearly demonstrated to be atherogenic. In a pathophysiological study, Ox-LDL was shown to accumulate in atherosclerotic lesions.<sup>16</sup> Although the origin and physiological significance of the circulating Ox-LDL have not been fully clarified, it is believed to originate from atherosclerotic lesions. It is also possible that LDL-C is modified to Ox-LDL during circulation by free-radicals or other molecules. Toshima, *et al* reported that Ox-LDL was significantly elevated in patients with CHD.<sup>6</sup> Ehara, *et al* also showed the clinical relevance of circulating Ox-LDL to the severity of ACS.<sup>7</sup> Furthermore, circulating Ox-LDL was found to be correlated with inflammatory cytokines and clinically silent ultrasound-assessed atherosclerotic changes in the carotid and femoral arteries.<sup>8</sup> Accordingly, it is believed circulating Ox-LDL may be a potential key marker for atherosclerosis and CHD.

The present study proves for the first time that statins can significantly decrease circulating Ox-LDL. It also has demonstrated that the lowering action of fluvastatin on Ox-LDL was stronger than that of pravastatin, while the reductions in LDL-C were not significantly different between the two statins. Fluvastatin has been reported to show radical scavenging activity based on its structure and to reduce the susceptibility of LDL to lipid peroxidation.<sup>10</sup> The results of the present study suggest that fluvastatin could decrease circulating Ox-LDL by not only a lipid-lowering effect, but also by a direct action on the oxidative modification of LDL. Recently, Serruys, *et al* in the LIPS trial have demonstrated that fluvastatin significantly reduced the risk of cardiac events following percutaneous coronary intervention.<sup>17</sup> In this trial, the mean baseline LDL-C was 132 mg/dL, which was the lowest range of those reported in previous major long-term secondary preven-

tion statin trials.<sup>18-20)</sup> Furthermore, in the CARE and LIPID trials, the benefits of pravastatin were diminished in patients with baseline LDL-C values less than 130 mg/dL.<sup>19,21)</sup> In contrast, LIPS showed that the benefit of fluvastatin is equal regardless of the baseline cholesterol values, indicating that fluvastatin has beneficial effects other than its lipid-lowering effect in cardiac events. Recent reports have demonstrated that in addition to their lipid-lowering effects, statins have many pleiotropic effects, such as inhibiting oxidative stress, improving endothelial function, decreasing vascular inflammation, and enhancing plaque stability. Since the chemical structures of statins are distinct from each other, the potencies of their pleiotropic effects are also considered to be different. In addition to its antioxidant activity, fluvastatin may have more potent pleiotropic effects than pravastatin.

**Conclusion:** The present report documents a novel observation that statin therapy results in a significant reduction in circulating Ox-LDL. Furthermore, fluvastatin is more effective than pravastatin in lowering the level of circulating Ox-LDL. In order to elucidate whether treatment for circulating Ox-LDL will have an impact on the development of CHD and ACS, and whether fluvastatin with its direct antioxidant activity will have a beneficial effect on the prevention of the cardiac events, further investigations should be conducted.

#### REFERENCES

1. Randomised trial of cholesterol lowering in 4444 patients with coronary heart disease: the Scandinavian Simvastatin Survival Study (4S). *Lancet* 1994; 344: 1383-9.
2. Shepherd J, Cobbe SM, Ford I, *et al.* Prevention of coronary heart disease with pravastatin in men with hypercholesterolemia. West of Scotland Coronary Prevention Study Group. *N Engl J Med* 1995; 333: 1301-7.
3. Steinberg D, Parthasarathy S, Carew TE, Khoo JC, Witztum JL. Beyond cholesterol. Modifications of low-density lipoprotein that increase its atherogenicity. *N Engl J Med* 1989; 320: 915-24.
4. Witztum JL, Steinberg D. Role of oxidized low density lipoprotein in atherogenesis. *J Clin Invest* 1991; 88: 1785-92.
5. Kita T, Nagano Y, Yokode M, *et al.* Probucol prevents the progression of atherosclerosis in Watanabe heritable hyperlipidemic rabbits, an animal model for familial hypercholesterolemia. *Proc Natl Acad Sci USA* 1987; 84: 5928-31.
6. Toshima S, Hasegawa A, Kurabayashi M, *et al.* Circulating oxidized low density lipoprotein levels. A biochemical risk marker for coronary heart disease. *Arterioscler Thromb Vasc Biol* 2000; 20: 2243-7.
7. Ehara S, Ueda M, Naruko T, *et al.* Elevated levels of oxidized low density lipoprotein show a positive relationship with the severity of acute coronary syndromes. *Circulation* 2001; 103: 1955-60.
8. Hulthe J, Fagerberg B. Circulating oxidized LDL is associated with subclinical atherosclerosis development and inflammatory cytokines (AIR Study). *Thromb Vasc Biol* 2002; 22: 1162-7.
9. Nakamura T, Nishi H, Kokusenya Y, Hirota K, Miura Y. Mechanism of antioxidative activity of fluvastatin-determination of the active position. *Chem Pharm Bull* 2000; 48: 235-7.
10. Hussein O, Schlezinger S, Rosenblat M, Keidar S, Aviram M. Reduced susceptibility of low density lipoprotein (LDL) to lipid peroxidation after fluvastatin therapy is associated with the hypocholesterolemic effect of the drug and its binding to the LDL. *Atherosclerosis* 1997; 128: 11-8.

11. Suzumura K, Yasuhara M, Tanaka K, Odawara A, Narita H, Suzuki T. An in vitro study of the hydroxyl radical scavenging property of fluvastatin, and HMG-CoA reductase inhibitor. *Chem Pharm Bull* 1999; 47: 1010-2.
12. Itabe H, Takeshima E, Iwasaki H, *et al*. A monoclonal antibody against oxidized lipoprotein recognizes foam cells in atherosclerotic lesions. Complex formation of oxidized phosphatidylcholines and polypeptides. *J Biol Chem* 1994; 269: 15274-9.
13. Kohno H, Suéshige N, Oguri K, *et al*. Simple and practical sandwich-type enzyme immunoassay for human oxidatively modified low density lipoprotein using anti-oxidized phosphatidylcholine monoclonal antibody and anti-human apolipoprotein-B antibody. *Clin Biochem* 2000; 33: 243-53.
14. Morel DW, Hessler JR, Chisolm GM. Low density lipoprotein cytotoxicity induced by free radical peroxidation of lipid. *J Lipid Res* 1983; 24: 1070-6.
15. Chisolm GM, Ma G, Irwin KC, *et al*. 7  $\beta$ -hydroperoxycholest-5-en-3  $\beta$ -ol, a component of human atherosclerotic lesions, is the primary cytotoxin of oxidized human low density lipoprotein. *Proc Natl Acad Sci USA* 1994; 91: 11452-6.
16. Yla-Herttuala S, Palinski W, Rosenfeld ME, *et al*. Evidence for the presence of oxidatively modified low density lipoprotein in atherosclerotic lesions of rabbit and man. *J Clin Invest* 1989; 84: 1086-95.
17. Serruys PW, de Feyter P, Macaya C, *et al*. Fluvastatin for prevention of cardiac events following successful first percutaneous coronary intervention: a randomized controlled trial. *JAMA* 2002; 287: 3215-22.
18. Sacks FM, Pfeffer MA, Moye LA, *et al*. The effect of pravastatin on coronary events after myocardial infarction in patients with average cholesterol levels. Cholesterol and Recurrent Events Trial investigators. *N Engl J Med* 1996; 335: 1001-9.
19. Prevention of cardiovascular events and death with pravastatin in patients with coronary heart disease and a broad range of initial cholesterol levels. The Long-Term Intervention with Pravastatin in Ischaemic Disease (LIPID) Study Group. *N Engl J Med* 1998; 339: 1349-57.
20. Collins R, Armitage J, Parish S, Sleight P, Peto R; Heart Protection Study Collaborative Group. MRC/BHF Heart Protection Study of cholesterol-lowering with simvastatin in 5963 people with diabetes: a randomized placebo-controlled trial. *Lancet* 2003; 361: 2005-16.
21. Pfeffer MA, Sacks FM, Moye LA, *et al*. Influence of baseline lipids on effectiveness of pravastatin in the CARE Trial. Cholesterol And Recurrent Events. *J Am Coll Cardiol* 1999; 33: 125-30.

## Variability in Quantitative Measurement of the Same Segment With Two Different Intravascular Ultrasound Systems: In Vivo and In Vitro Studies

Yuxin Li, MD, Junko Honye, MD, Satoshi Saito\*, MD, Tadateru Takayama, MD, Shin-Ichiro Yokoyama, MD, Tadahiro Saruya, MD, Motoko Kotani, MD, Kazuo Harasawa, MD, Hideyuki Ando, MD, Masayoshi Endo, MD, and Katsuo Kanmatsuse, MD

We evaluated two different intravascular ultrasound (IVUS) systems, Atlantis and Intrafocus, to verify their accuracy and reproducibility. In an in vivo study on 20 consecutive patients with coronary artery diseases, the minimum lumen diameter (MLD), vessel diameter, lumen area (LA), vessel area, plaque area, and area stenosis rate (% AS) were respectively measured. In an in vitro study, MLD and LA were measured in four metal tubes with different diameters. All of the measured values except for % AS by Atlantis were significantly larger than the values obtained with Intrafocus. Nonuniform rotational distortion (NURD) was estimated as 34% in Atlantis and 1% in Intrafocus. The measurements by Atlantis were larger than the true values while the measurements by Intrafocus were less than the true values in all four metal tubes. These findings suggest that we should clearly avoid the use of different IVUS systems in the same study. *Catheter Cardiovasc Interv* 2004;62:175-180. © 2004 Wiley-Liss, Inc.

**Key words:** intravascular ultrasound; quantitative measurement; variability of different systems; in vivo

### INTRODUCTION

Intravascular ultrasound (IVUS) has been applied for guidance in percutaneous coronary intervention (PCI). The morphometric measurements of IVUS are clinically important for estimating the residual lumen, vessel, and plaque size in order to determine the device size and endpoint during PCI [1]. Currently, several kinds of IVUS systems are commercially available, and validation studies among these systems are required. Some previous investigations have demonstrated significant differences in image representation among different IVUS systems when diagnosing the tissue components of complex atherosclerotic plaque [2,3]. However, most of the previous studies were performed only in vitro. The purpose of the present investigation was to compare two different mechanical IVUS systems both in vivo and in vitro in terms of quantitative measurements of the lumen, plaque, and vessel sizes.

### MATERIALS AND METHODS

#### Ultrasound Imaging Systems

Two commercially available intravascular ultrasound systems and catheters were employed: a mechanical rotating 40 MHz transducer (Atlantis, 2.6 Fr; Boston Scientific) and a mechanical rotating 35 MHz transducer (Intrafocus, 2.4 Fr; Terumo).

Twenty consecutive patients with native coronary artery disease were enrolled in this study. All patients gave written informed consent for the study. The patients underwent IVUS before and after PCI by both IVUS systems. The IVUS images were optimized under visual inspection by manipulating the system settings provided with each device. Both IVUS catheters were automatically pulled back at 0.5 mm/sec with the same autopull-back device. The IVUS images were continuously recorded on SVHS videotapes.

#### IVUS Imaging Analysis

The IVUS images recorded on the SVHS tapes were analyzed with an IVUS 3D imaging system (NetraIVUS software package for Windows NT, ScImage). In the

Division of Cardiology, Second Department of Medicine, Nihon University School of Medicine, Tokyo, Japan

\*Correspondence to: Dr. Satoshi Saito, Division of Cardiology, Second Department of Medicine, Nihon University School of Medicine, 30-1 Oyaguchi-Kami-machi, Itabashi-ku, Tokyo, 173-8610, Japan. E-mail: satothis@med.nihon-u.ac.jp

Received 25 July 2003; Revision accepted 7 February 2004

DOI 10.1002/ccd.20052

Published online in Wiley InterScience (www.interscience.wiley.com).



coronary arteries with significant stenosis (quantitative coronary angiography  $\geq 75\%$ ), images of the smallest stenotic segments, proximal edges, distal edges, proximal reference segments, and distal reference segments were selected for measurement. In other coronary arteries without significant stenosis, 5 to 10 arbitrary segments were also selected for measurement. In total, 280 pairs of IVUS images from the two systems were selected and stored for further analysis. Two-dimensional longitudinal reconstruction images and short-axis cross-sectional images were used to identify the same location of the images. The images were interpreted and measured by two independent well-trained observers at different times. The two observers were not involved in acquiring the images and had no influence on the system settings.

### Quantitative Analysis

Images with a significantly reduced quality and plaque with a calcium arc  $> 90^\circ$  were excluded. Thus, 247 images were measured. Cross-grids recorded on the IVUS images were used for calibration. The interface between the plaque and lumen and the outer border of the external elastic membrane were traced manually. On the basis of the manual tracing, the computer software determined the following measurement parameters: minimum lumen diameter (MLD), maximum lumen diameter, minimum vessel diameter (MVD), maximum vessel diameter, lumen area (LA), and vessel area (VA). From these direct measurements, the following parameters were estimated: plaque area (PA), calculated as the area within VA minus LA; and plaque area stenosis rate (% AS), calculated as  $PA/VA \times 100\%$ .

### Other Analyses

The plaque characteristics and image quality were also analyzed between the two systems. Plaque calcium was defined as an area of high echo intensity, with acoustic shadowing. The plaque calcium was divided into four semiquantitative types according to the radial degrees of calcium: no calcium, less than  $90^\circ$ , from  $90^\circ$  to  $180^\circ$ , and greater than  $180^\circ$ . We also compared the incidence of nonuniform rotational distortion (NURD) between the two systems, which is an important factor that influences image quality in mechanical IVUS systems.

### In Vitro Study

Four phantom metal cylindrical tubes with different diameters were observed using the two IVUS systems. Images were obtained in a saline-filled tank maintained at  $37^\circ\text{C}$ . Each ultrasound catheter from the two systems was inserted sequentially into the distal edge of the tube and slowly pulled back manually to the proximal edge. All procedures were performed by the same operator for both systems. In each tube, 10 arbitrary segments were

selected for analysis by two independent observers. The measurement parameters consisted of the MLD and LA. After completion of all IVUS measurements, the four tubes were measured with a laser camera for their MLD and LA, and the results obtained were regarded as the actual values. In the procedures for pulling back the catheter manually, the transducer positions were randomly placed in the center or off-center of the tubes. Since angle-related variance in image quality also occurs with an eccentric catheter position [4], we contrasted the distortion index (maximum lumen diameter/MLD) between the central and off-central transducer positions in the two systems.

### Statistical Analysis

Measured values are expressed as mean  $\pm$  standard deviation. The least significant difference (LSD) posthoc test was used to compare the values between the two systems on analysis of variance. Chi-square analysis was employed to compare other values such as the degree of calcification and NURD between the two systems. The interobserver variability was analyzed by linear regression. In these analyses,  $P < 0.05$  was considered as statistically significant.

## RESULTS

### In Vivo Study

The mean age of the 20 patients was  $63 \pm 8$  years (range, 51–78 years). The number of male patients was 17. In total, 280 segments of IVUS images from 47 coronary arteries (RCA, 18; LAD, 20; LCx, 9) were selected for analysis.

Both mechanical rotation systems showed good sensitivities for identifying the lumen boundary and a high identity of representation of the plaque characteristics such as the plaque calcium, low echogenic plaque, high echogenic plaque, lipid pool, plaque rupture, and thrombus.

### Quantitative Variability

Excluding images with a significantly reduced quality and a calcium arc  $> 90^\circ$ , 247 pairs of images were measured. The average values and standard deviations of MLD, MVD, LA, VA, PA, and % AS from the two systems are summarized in Table 1. The measured values of MLD, MVD, LA, VA, and PA by Atlantis were statistically larger than the values obtained with Intrafocus ( $P < 0.05$ ; Fig. 1). The values of % AS from the two systems were similar with no statistical difference.

### Calcium and NURD Variability

Excluding the images with a significantly reduced quality, 268 pairs of images were measured. Table II

**TABLE I. Comparison of Average Measured Values In Vivo\***

	MLD (mm)	MVD (mm)	LA (mm <sup>2</sup> )	VA (mm <sup>3</sup> )	PA (mm <sup>2</sup> )	% AS (%)
Atlantis	3.0 ± 0.7 <sup>a</sup>	4.5 ± 0.6 <sup>a</sup>	9.6 ± 4.1 <sup>a</sup>	18.9 ± 5.0 <sup>a</sup>	9.3 ± 3.2 <sup>a</sup>	49.8 ± 14.6
Intrafocus	2.8 ± 0.6	4.1 ± 0.6	8.0 ± 3.3	15.8 ± 4.1	7.8 ± 2.8	49.7 ± 14.5

\*n = 247 for both systems.

<sup>a</sup>P < 0.05.

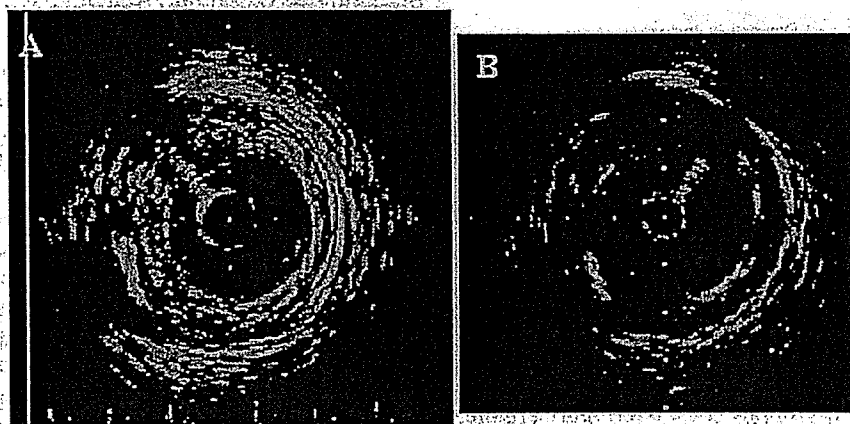


Fig. 1. Images of a coronary artery at the same cross-section obtained with two intravascular ultrasound systems: A: Atlantis. B: Intrafocus. There were no significant differences in representing the plaque characteristics. The measured values from the two systems were as follows. Atlantis: MLD, 2.6 mm; LA, 7.4 mm<sup>2</sup>; VD, 5.2 mm; VA, 23.5 mm<sup>3</sup>. Intrafocus: MLD, 2.5 mm; LA, 6.3 mm<sup>2</sup>; VD, 4.8 mm; VA, 20.7 mm<sup>3</sup>. All parameters from Atlantis were larger than those from Intrafocus.

**TABLE II. Incidence of Plaque Calcium\***

	0°	0-90°	90-180°	> 180°
Atlantis	190	57	16	5
Intrafocus	199	52	13	4

\*n = 268 for both systems.

shows the incidence of the four types of plaque calcium. Atlantis tended to indicate a higher incidence of plaque calcium than Intrafocus, but there was no statistical difference between the two systems ( $P = 0.61$ ).

Among the total of 280 pairs of images, 12 images from Atlantis (4%) could not be analyzed because of a significantly reduced quality with severe NURD. Adding another 83 images from Atlantis with different degrees of NURD that did not significantly influence the image quality, 95 images from Atlantis (34%) were confirmed with NURD by the two observers: NURD was frequently evident at tortuous lesions with calcium and/or near a branch. On the other hand, only two images from Intrafocus (1%) showed NURD. Atlantis thus demonstrated a significantly higher incidence of NURD than Intrafocus ( $P < 0.05$ ).

**TABLE III. Comparison Among Four Tubes: MLD (mm)\***

	Tube 1	Tube 2	Tube 3	Tube 4
Actual value	3.94	4.96	6.92	8.93
Atlantis	3.96 ± 0.23	4.94 ± 0.16	6.80 ± 0.34	8.68 ± 0.34
Intrafocus	3.47 ± 0.05 <sup>a</sup>	4.38 ± 0.06 <sup>a</sup>	6.24 ± 0.13 <sup>a</sup>	8.31 ± 0.14 <sup>a</sup>

\*n = 10 for every tube with both systems.

<sup>a</sup>P < 0.05 vs. actual value.

### In Vitro Study

Table III shows the average MLD values of the four metal tubes obtained with the two systems and the actual values. There was no statistical difference between the values from Atlantis and the actual values, while the values from Intrafocus were significantly less than the actual values ( $P < 0.05$ ).

Table IV shows average LA values among the metal tubes obtained with the two systems and the actual values. The values from Atlantis were larger than the actual values, while the values from Intrafocus were less than the actual values in all four of the metal tubes ( $P < 0.05$ ).

Table V shows the average values of the distortion index (maximum lumen diameter/MLD) between the central and off-central transducer positions in the two

TABLE IV. Comparison Among Four Tubes: LA (mm<sup>2</sup>)\*

	Tube 1	Tube 2	Tube 3	Tube 4
Actual value	12.2	19.3	37.6	62.6
Atlantis	14.3 ± 0.9 <sup>a</sup>	22.4 ± 1.8 <sup>a</sup>	43.1 ± 4.4 <sup>a</sup>	68.0 ± 4.3 <sup>a</sup>
Intrafocus	10.8 ± 0.3 <sup>a</sup>	16.8 ± 0.4 <sup>a</sup>	34.5 ± 0.6 <sup>a</sup>	59.5 ± 2.1 <sup>a</sup>

\*n = 10 for every tube with both systems.

<sup>a</sup>P < 0.05.

TABLE V. Comparison of Distortion Index\*

	Central position	Off-central position
Atlantis	1.07 ± 0.03	1.18 ± 0.09 <sup>b</sup>
Intrafocus	1.07 ± 0.02	1.10 ± 0.03 <sup>a</sup>

\*n = 18 for both systems.

<sup>a</sup>P < 0.05 vs. central.<sup>b</sup>P < 0.05 vs. Intrafocus off-central.

systems. The data were almost equal between the two systems when the transducers were located at the central position within the tubes. Both systems revealed statistically larger distortion indexes when the transducers were placed in off-central positions ( $P < 0.05$ ). Furthermore, the distortion index from Atlantis was significantly larger than that from Intrafocus ( $P < 0.05$ ; Fig. 2).

#### Interobserver Variability

Among all the in vivo and in vitro measured values, there were no statistical differences between the two observers. Table VI shows the correlation coefficients for the relationship between the two independent observers for the in vivo and in vitro measurements. The two observers provided a close correlation for all values ( $P < 0.05$ ), especially the in vitro values.

#### DISCUSSION

IVUS produces unique cross-sectional images of arterial walls that yield accurate morphometric measurements of coronary arteries [5-8]. Some articles have demonstrated considerable variability for IVUS with different systems; this involves imaging preparation (e.g., saline versus blood, room versus body temperature), catheter position, etc. [2,3,8,9]. Most previous investigations were performed in vitro. Our study is the first prospective study to compare different IVUS systems directly in the same arteries in vivo. The major finding was that significant variability exists in the quantitative analysis that can influence the determination of the device sizes and endpoint, although high correlation coefficients were noted between the different systems. Atlantis tended to overestimate the measurements, while Intrafocus underestimated the measurements.

Although both systems were accurate for representing morphologic features, Intrafocus has a greater ability to

avoid NURD, especially in the case of tortuous lesions. To identify calcified plaque by IVUS is important for guiding interventional strategies and for predicting clinical outcome after the interventions. The present data demonstrated that both systems have a similar capability for identifying calcium within the plaque [10,11].

#### Reasons for Variability Between Two Systems

Ultrasound image quality is determined not only by ring-down artifacts, but also by multiple other factors, including the frequency, resolution, distance from the catheter to tissue, catheter size, dynamic range, gain setting, quality of image processing software, rotational speed, noise isolation, and ultrasound beam contours [3,12-14]. In our study, although extensive efforts were made to optimize all of the images obtained from each of the two systems, there were significant differences in system frequency, catheter design, catheter size, transducer size, composition, and electronic processing of the ultrasound backscatter to produce the images [2,15,16]. Measurements on IVUS images obtained in clinical settings are not always optimal because of limited image resolution, eccentric catheter placement, shadowing by calcium within the plaque, catheter artifacts, NURD, and significant movements of the catheter within the vessel. The angle and position of the IVUS catheter are also important factors in image quality and in making quantitative measurements. In our in vitro study, when the transducers were placed in the off-center position, the ultrasound beams were not parallel to the long axis of the tubes so that only elliptical images were obtained. Calcium deposits cause acoustic shadowing and obscure underlying structures behind the calcium. Systolic-to-diastolic differences and beat-to-beat variability should be considered when selecting frames for analysis. The systolic vascular dimensions were significantly greater than the diastolic dimensions [4,13]. The differences between both systems could account for the differences in interpretation and measurements. For example, the speed of ultrasound is 1,562 m/sec in Atlantis and 1,530 m/sec in Intrafocus. Such differences may have contributed to the results. It is important to understand the limitations of each system. We should be careful to determine the size of the device and/or endpoint of coronary intervention and be cautious in interpreting studies performed with the different machines.

#### Interobserver Variability

The present study revealed a high correlation coefficient between the two observers in both systems. This is similar to previous articles that reported a low interobserver variability [1,17-20]. In our study, the high correlation between the two observers may have been due to

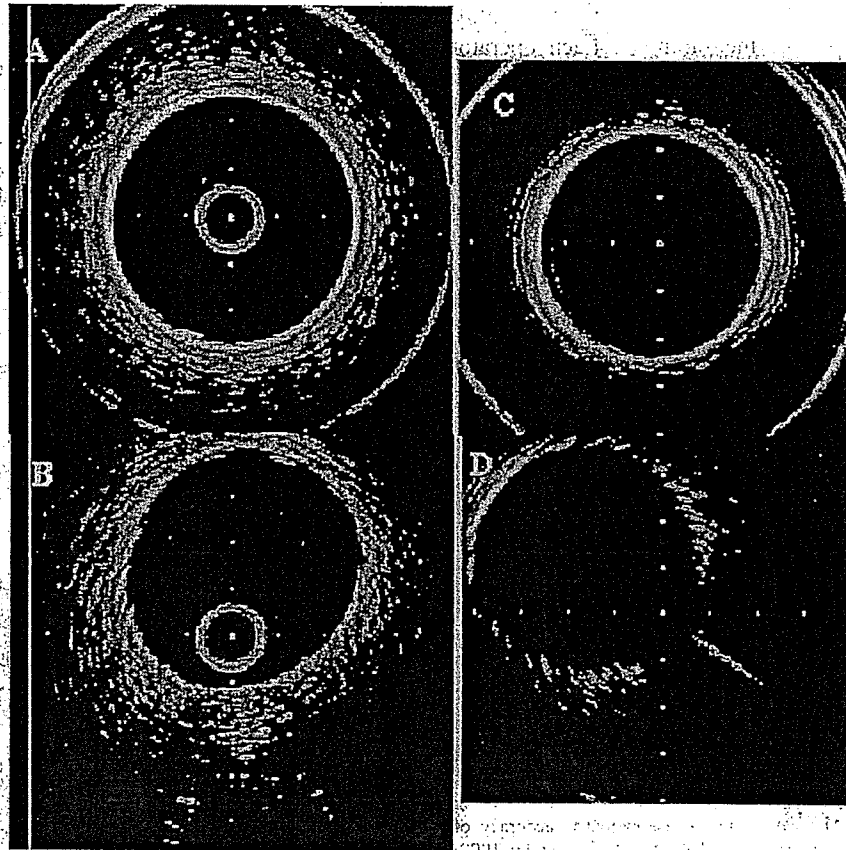


Fig. 2. Images of tube 2 obtained with two IVUS systems. A and B: Atlantis. C and D: Intrafocus. In the two top images, both transducers were placed in the center of the tube. In the two bottom images, both transducers were placed in the off-center position of the tube. The sizes of the tube and measured values were as follows: real diameter, 4.98 mm; real LA, 19.3 mm<sup>2</sup>. A: MLD, 5.2 mm; LD max, 5.4 mm; LA, 22.2 mm<sup>2</sup>; distortion index,

1.04. B: MLD, 4.7 mm; LD max, 5.5 mm; LA, 20.3 mm<sup>2</sup>; distortion index, 1.17. C: MLD, 4.5 mm; LD max, 4.8 mm; LA, 17.4 mm<sup>2</sup>; distortion index, 1.07. D: MLD, 4.3 mm; LD max, 4.8 mm; LA, 16.7 mm<sup>2</sup>; distortion index, 1.12. Measured values were larger than the actual values by Atlantis and less than the actual values by Intrafocus. When the transducers were placed in the off-center position, the cross-section images were represented as ellipses.

TABLE VI. Correlation Coefficients for the Relationship Between Two Independent Observers\*

	In vivo					In vitro	
	MLD	MVD	LA	VA	PA	MLD	LA
Atlantis	0.97	0.96	0.98	0.98	0.93	0.99	0.99
Intrafocus	0.95	0.97	0.98	0.97	0.93	0.99	0.99

\*n = 247 for in vivo; n = 40 for in vitro.

the high resolution of plaque and training levels of each observer.

### Clinical Implications

Since the transducer of Atlantis is pulled back within the sheath, this can ensure stability of long-axis move-

ment. On the other hand, a high incidence of NURD is the most important factor influencing the quality of IVUS images that leads to errors in the measurements. Intrafocus has excellent characteristics for reducing the incidence of NURD. Since the transducer of Intrafocus is pulled back with the catheter itself, long-axis measurement is not precise. We should clearly avoid the use of different IVUS systems in the same study.

There were significant variabilities in quantitative measurement between the two different IVUS systems. These variabilities should be considered when interpreting IVUS results obtained with different systems, especially in purely quantitative studies. We must remember that Intrafocus tends to underestimate measured values when determining the device sizes and endpoint during interventional therapies. On the other hand, the high

frequency of NURD in Atlantis has an important influence on the accuracy of measurement. Each operator should be aware of these variabilities.

## REFERENCES

- GUIDE trial investigators: Discrepancies between angiographic and intravascular ultrasound appearance of coronary lesions undergoing intervention: a report of phase I of the GUIDE trial. *J Am Coll Cardiol* 1993;21:1187A.
- Hiro T, Leung CY, Russo RJ, et al: Variability in tissue characterization of atherosclerotic plaque by intravascular ultrasound: a comparison of four intravascular ultrasound systems. *Am J Cardiol Imaging* 1996;10:209-218.
- Hiro ET, Leung CY, Russo RJ, et al: Variability of a three-layered appearance in intravascular ultrasound coronary images: a comparison of morphometric measurements with four intravascular ultrasound systems. *Am J Cardiol Imaging* 1996;10:219-227.
- Di Mario C, Madretsas S, Linker D, et al: The angle of incidence of the ultrasonic beam: a critical factor for the image quality in intravascular ultrasonography. *Am Heart J* 1993;125:442-448.
- Nishimura RA, Edwards WD, Warner GA, et al: Intravascular ultrasound imaging: in vitro validation and pathologic correlation. *J Am Coll Cardiol* 1990;16:145-154.
- Wenguan L, Gussenhoven WJ, Zhong Y, et al: Validation of quantitative analysis of intravascular ultrasound images. *Int J Cardiol Imaging* 1991;6:247-253.
- Anderson MH, Simpson JA, Katritsis D, et al: Intravascular ultrasound imaging of the coronary arteries: an in vitro evaluation of measurement of area of the lumen and atheroma characterization. *Br Heart J* 1992;68:276-281.
- Chae JS, Brisken AF, Maurer G, et al: Geometric accuracy of intravascular ultrasound imaging. *J Am Soc Echocardiogr* 1992;5:577-587.
- Moriuchi M, Tobis JM, Mahon D, et al: The reproducibility of intravascular ultrasound imaging in vitro. *J Am Soc Echocardiogr* 1990;3:424-430.
- Mintz GS, Douek P, Pichard AD, et al: Target lesion calcification in coronary artery disease: an intravascular ultrasound study. *J Am Coll Cardiol* 1992;20:1149-1155.
- Fitzgerald PJ, Ports TA, Yock PG: Contribution of localized calcium deposits to dissection after angioplasty: an observational study using intravascular ultrasound. *Circulation* 1992;86:64-70.
- ten Hoff H, Korbijn A, Smith TH, et al: Imaging artifacts in mechanically driven ultrasound catheters. *Int J Cardiol Imaging* 1989;4:195-199.
- Crowley RJ, von Behren PL, Couvillon LA, et al: Optimized ultrasound imaging catheters for use in the vascular system. *Int J Cardiol Imaging* 1989;4:145-151.
- Benkeser PJ, Churchwell AP, Lee C, et al: Resolution limitations in intravascular ultrasound imaging. *J Am Soc Echocardiogr* 1993;6:158-165.
- Peters RJ, Kok WF, Rijsterborgh H, et al: Reproducibility of quantitative measurements from intracoronary ultrasound images: beat-to-beat variability and influence of the cardiac cycle. *Eur Heart J* 1996;17:1593-1599.
- Gaster AL, Korsholm B, Thaysen P, et al: Reproducibility of intravascular ultrasound and intracoronary Doppler measurements. *Catheter Cardiovasc Interv* 2001;53:449-458.
- Hausmann D, Lundkvist AJ, Friedrich GJ, et al: Intracoronary ultrasound imaging: intraobserver and interobserver variability of morphometric measurements. *Am Heart J* 1994;128:674-680.
- Podkin BN, Barfiorini AL, Gessert JM, et al: Coronary artery imaging with intravascular high-frequency ultrasound. *Circulation* 1990;81:1575-1585.
- Hodgson M, Graham SP, Savakus AD, et al: Clinical percutaneous imaging of coronary anatomy using an over-the-wire ultrasound catheter system. *Int J Cardiol Imaging* 1989;4:187-193.
- St-Gear FC, Pinto EJ, Alderman EL, et al: Intravascular ultrasound imaging of angiographically normal coronary arteries: an in vivo comparison with quantitative angiography. *J Am Coll Cardiol* 1991;18:952-958.

# Intravascular Ultrasound Evaluation of Ruptured Plaque in the Left Main Coronary Artery Misinterpreted as an Aneurysm by Angiography

Yuxin Li, MD, Junko Honye, MD, Tadateru Takayama, MD, and Satoshi Saito, MD

We report a patient who demonstrated a left main coronary aneurysm by angiography. Intravascular ultrasound (IVUS) revealed that it was in fact an ulceration, which indicated ruptured plaque. This case provides evidence that IVUS can permit a more powerful definition of ruptured plaque than angiography. On IVUS, ulceration exhibits significantly different characteristics from aneurysm. *Catheter Cardiovasc Interv*. 2004;63:314–316.

© 2004 Wiley-Liss, Inc.

Key words: intravascular ultrasound; ulceration; coronary aneurysm

## INTRODUCTION

Although angiography has continued for > 40 years as the predominant method for delineating and diagnosing the coronary anatomy, many studies have challenged the accuracy and reproducibility of this technique [1–3]. Intravascular ultrasound (IVUS) has evolved as a valuable adjunct to angiography due to its visualization of the full circumference of the vessel wall [1,4,5]. We report here a patient with angiographically left main coronary aneurysm that turned out to be an ulcerative lesion on IVUS.

## CASE REPORT

A 50-year-old male who was admitted to hospital because of palpitations and dyspnea was diagnosed as congestive heart failure. An electrocardiogram (ECG) on admission demonstrated atrial flutter and fibrillation. His coronary risk factors were smoking (30 cigarettes a day for 15 years) and hyperlipidemia. His family history for cardiac disease was negative. A transthoracic echocardiogram revealed moderate mitral valve regurgitation.

At the time of undergoing electrophysiologic studies, this patient received coronary angiography to determine if he had coronary heart disease. The coronary angiography disclosed a 99% stenosis at the ostial right coronary artery, a 90% stenosis at the second diagonal branch, and a 90% stenosis at the posterior descending artery of the left circumflex artery. In addition, despite some haziness, the coronary angiography indicated a big coronary aneurysm at the left main trunk (Fig. 1). We successfully treated the calcified lesion at the ostial right coronary artery with stent implantation following rotational atherectomy. To determine the etiology of the

aneurysm at the left main coronary artery, we decided to perform IVUS, which demonstrated that the angiographic aneurysm was in fact an ulcerative lesion with a thin fibrous cap flapping into the lumen (Fig. 2) and the vessel wall was preserved. The lumen diameter was enlarged to 12.0 mm at the ulcerative segment, 8.2 mm at the proximal segment, and 8.0 mm at the distal segment. These findings indicated that this lesion was an unrecognized ruptured plaque. There were no CK or troponin elevation after the procedure. Since there was no significant stenosis in the left main coronary artery, we decided to follow up this patient medically.

## DISCUSSION

A coronary aneurysm is usually diagnosed angiographically as an area of localized coronary dilation whose diameter is 1.5 to 2 times larger than the diameter of the adjacent normal segment [6]. Since coronary angiography demonstrates the contrast-filled lumen contours, it is unable to distinguish true or false aneurysm or other local dilated lesions such as plaque rupture with ulcerative formation [4–6,7–9]. In recent years, IVUS

Division of Cardiology, Second Department of Medicine, Nihon University School of Medicine, Tokyo, Japan

\*Correspondence to: Dr. Satoshi Saito, Division of Cardiology, Second Department of Medicine, Nihon University School of Medicine, 30-1 Oyaguchi-Kami-machi, Itabashi-ku, Tokyo, 173-8610, Japan. E-mail: satoshis@med.nihon-u.ac.jp

Received 25 July 2003; Revision accepted 22 February 2004

DOI: 10.1002/ccd.20087

Published online in Wiley InterScience (www.interscience.wiley.com).






Fig. 1. Coronary angiogram (RAO 30°) indicating a coronary aneurysm (arrow) at the proximal segment of the left main coronary artery.

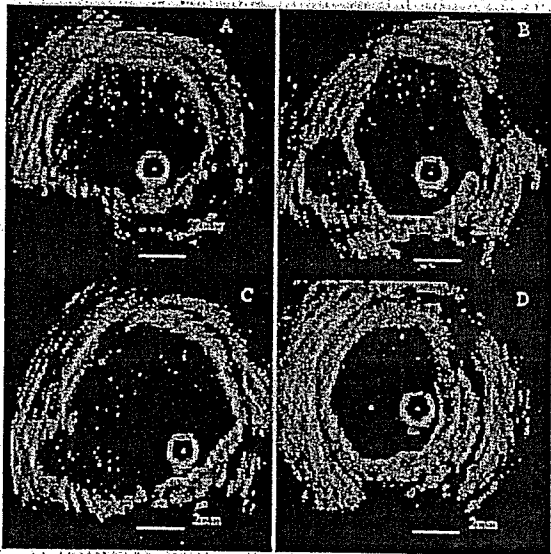


Fig. 2. IVUS images showing an ulcerative lesion in the left main coronary artery. A: Proximal segment. B: Proximal edge of lesion. C: Lesion segment. D: Distal segment. Fibrous and calcified plaque occupied most of the vessel with an ulceration occurring between 6:00 and 9:00 (B and C). Rupture of the fibrous cap was evident overlying the ulceration flapping into the lumen at the proximal edge of the lesion (B). The distal segment revealed mixed plaque (D).

has evolved as a valuable adjunct to angiography, offering detailed high-resolution images of both the lumen and vessel wall [4,6,10,11]. Miskolczi et al. [12] reported that IVUS could permit a more powerful definition of small ulceration than other available diagnostic methods. In the present case, the angiographic aneurysm was so

big that it appeared reasonable to infer that it was an aneurysm. IVUS provided overriding evidence to distinguish a ruptured plaque from coronary aneurysm.

It is important to differentiate ulcerative lesions from aneurysms because their clinical significance is totally different. Aneurysms are thought to involve degenerated media, which offer inadequate support [6,7,13]. Although atherosclerosis plays an important role in the formation of coronary aneurysms, no significant differences in plaque area and plaque composition are found between the aneurysmal segment and adjacent proximal and distal vessel segments. IVUS demonstrates that coronary aneurysms often have a large dilated thin-wall segment opposite the eccentric plaque and the medial boundary can be seen surrounding the dilated lumen [6]. Ulceration, in contrast, is found to involve spontaneous plaque rupture with an emptied plaque cavity. In our case, IVUS images showed typical plaque rupture with ulceration formation: a ruptured plaque contained a cavity that communicated with the lumen with an overlying residual fibrous cap fragment. The rupture appeared to have occurred at the shoulder of the fibrous cap. Plaque rupture is usually encountered in the course of acute coronary syndrome. Since the lesions in patients with acute coronary syndrome are often compensatorily dilated, they sometimes resemble aneurysmal formation on angiography [14].

Pathological examinations reveal that ulcerated plaque represents a disruption of the fibrous cap that leads to exposure of the thrombogenic lipid core into the flowing blood. Histologically, this is identified as an irregular plaque surface with a break in or loss of the fibrous cap usually associated with a surface thrombus directly overlying the lipid-rich necrotic core of the lesion [15]. Yamagishi et al. [16] demonstrated a heterogeneous distribution of regional wall distensibility in noncircumferential lesions, with the regional distensibility index at the lesion portion being significantly lower than that at the normal portion. This may result in a mechanical mismatch between the lesion and normal portions, which could be related to the occurrence of the plaque rupture that is frequently found to take place at the edge of the plaque where the fibrous cap is often thinnest [16]. In the present case, the rupture of the fibrous cap occurred at the boundary of the lesion and proximal segment.

Although plaque rupture is now considered to be a major cause of acute coronary syndrome, there is some evidence to support the hypothesis that spontaneous plaque rupture occurs sporadically and does not necessarily lead to occlusion [7,9,17]. In the present case, since the patient was admitted because of heart failure and arrhythmia, angina symptom might be masked. Both ECG and myocardial scintigraphy failed to show any

signs of myocardial ischemia in the region of the left coronary artery. We think it as a silent plaque rupture.

Besides IVUS, other noninvasive diagnostic modalities can be recommended to diagnose ruptured plaque. Recently, multislice CT has been developed rapidly as an accurate method for assessing coronary artery anatomy. Plaque composition could be clearly differentiated and classified by determining tissue density within the lesion. These noninvasive modalities can be used to assess atherosclerotic plaques responsible for early silent disease and may become important tools for early detection and prevention [18].

The present case provides evidence that IVUS can permit a more powerful definition of ulceration than angiography, and the ulceration exhibits significantly different characteristics from an aneurysm on IVUS.

## REFERENCES

1. Nissen SE, Yock P. Intravascular ultrasound: novel pathophysiological insights and current clinical applications. *Circulation* 2001; 103:604-616.
2. Grondin CM, Dydra I, Pasternac A, et al. Discrepancies between cineangiographic and postmortem findings in patients with coronary artery disease and recent myocardial revascularization. *Circulation* 1974;49:703-709.
3. Vlodaver Z, Frech R, van Tassel RA, et al. Correlation of the antemortem coronary angiogram and the postmortem specimen. *Circulation* 1973;47:162-169.
4. Tobis JM, Mallery J, Mahon D, et al. Intravascular ultrasound imaging of human coronary arteries in vivo: analysis of tissue characterizations with comparison to in vitro histological specimens. *Circulation* 1991;83:913-926.
5. Nissen SE, Gurley JC, Grines CL, et al. Intravascular ultrasound assessment of lumen size and wall morphology in normal subjects and patients with coronary artery disease. *Circulation* 1991;84: 1087-1099.
6. Ge J, Liu F, Kearney P, et al. Intravascular ultrasound approach to the diagnosis of coronary artery aneurysms. *Am Heart J* 1995; 130:765-771.
7. Maehara A, Mintz GS, Castagna MT, et al. Intravascular ultrasound assessment of spontaneous coronary artery dissection. *Am J Cardiol* 2002;89:466-468.
8. Ge J, Erbel R, Zamorano J, et al. Coronary artery remodeling in atherosclerotic disease: an intravascular ultrasonic study in vivo. *Coron Artery Dis* 1993;4:981-986.
9. Baumgart D, Liu F, Haude M, et al. Acute plaque rupture and myocardial stunning in patient with normal coronary arteriography. *Lancet* 1995;346:193-194.
10. Pandian NG, Kreis A, Brockway B, et al. Ultrasound angioscopy: real-time, two-dimensional, intraluminal ultrasound imaging of blood vessels. *Am J Cardiol* 1988;62:493-494.
11. Fitzgerald PJ, Ports TA, Yock PG. Contribution of localized calcium deposits to dissection after angioplasty: an observational study using intravascular ultrasound. *Circulation* 1992;86:64-70.
12. Miskolczi L, Guterman LR, Flaherty JD, et al. Depiction of carotid plaque ulceration and other plaque-related disorders by intravascular sonography: a flow chamber study. *Am J Neuroradiol* 1996;17:1881-1890.
13. Berkoff HA, Rowe GG. Atherosclerotic ulcerative disease and associated aneurysms of the coronary arteries. *Am Heart J* 1975; 90:153-158.
14. Schoenhagen P, Ziada KM, Kapadia SR, et al. Extent and direction of arterial remodeling in stable versus unstable coronary syndromes: an intravascular ultrasound study. *Circulation* 2000; 101:598-603.
15. DiSciascio G, Cowley MJ, Goudreau E, et al. Histopathologic correlates of unstable ischemic syndromes in patients undergoing directional coronary atherectomy: in vivo evidence of thrombosis, ulceration, and inflammation. *Am Heart J* 1994;128:419-426.
16. Yamagishi M, Umeno T, Hongo Y, et al. Intravascular ultrasonic evidence for importance of plaque distribution (eccentric vs circumferential) in determining distensibility of the left anterior descending artery. *Am J Cardiol* 1997;79:1596-1600.
17. Park JB, Tobis JM. Spontaneous plaque rupture and thrombus formation in the left main coronary artery documented by intravascular ultrasound. *Cathet Cardiovasc Diagn* 1997;40:358-360.
18. Schoenhagen P, White RD, Nissen SE, et al. Coronary imaging: angiography shows the stenosis, but IVUS, CT, and MRI show the plaque. *Cleve Clin J Med* 2003;70:713-719.



## 積極的脂質低下による冠動脈病変の 安定化と退縮についての検討

日本大学 循環器内科 高山 忠輝, 齋藤 颯, 猿谷 忠弘, 上松瀬勝男  
 東京大学 循環器内科 本江 純子

### はじめに

不安定狭心症や急性心筋梗塞の多くは、冠動脈プラークの破綻を契機に血栓が形成され、冠動脈の閉塞により発症することが明らかにされ、これらの疾患は同一の病態を基盤として発症するため急性冠症候群 (acute coronary syndrome) と総称される<sup>1,2)</sup>。一般的に破綻しやすいプラークの病理学的特徴としては、コレステロールエステル量が多く、脂質コアの占める割合が大きいソフトプラークであること、線維性被膜 (fibrous cap) が薄いこと、マクロファージなどの炎症細胞の浸潤が強く、線維性被膜の傷害が進んでいることとされる<sup>3)</sup>。冠動脈造影上、中等度病変であっても急性冠症候群の発症は多く、その発症予測や冠動脈プラークの退縮が冠動脈造影にて評価されてきたがそれには限界があり、血管内エコー法 (IVUS) による観察が有用である。

近年、statin系抗高脂血症薬の投与による心血管イベントの抑制効果とIVUSによるプラークの安定化が報告された (GAIN)<sup>4)</sup>。また、プラークの不安定化に酸化LDLの関与が指摘され、抗酸化薬の心血管イベント抑制効果が期待されている<sup>5)</sup>。しかし、現在までのところプラークの安定化を証明する大規模脂質介入試験は行われておらず、IVUSにおけるプラークの退縮についても明

らかにされていない。

そこで、今回われわれは、LDL低下療法ならびに抗酸化薬長期投与によるプラークの変化をIVUSにより観察した。

### 対象および方法

責任冠動脈病変に対するカテーテルインターベンションを施行した虚血性心疾患患者のうち、インターベンション非施行血管に定量的冠動脈造影法 (QCA) 上50%未満の病変に対し、初回造影時および遠隔期 (6ヵ月以上) にIVUSによる観察を行った65症例 (男性28例, 平均年齢61歳) を対象とした。そして対象を3群に分類し、atorvastatin 10 mg/日 (A群), probucol 500 mg/日 (P群), atorvastatin 10 mg/日 および probucol 500 mg/日併用 (A+P群) を6ヵ月間投与し、投与開始時および6ヵ月後においてIVUSによる観察を行った。

IVUSカテーテルはBoston Scientific社製30/40 MHzを使用し、観察病変の遠位部より0.5 mm/秒の速度でautomatic pullbackデバイスを用いて施行した。S-VHSビデオテープに記録されたIVUS画像はScImage社製Netra IVUSにて三次元再構築処理を行い、病変の最狭窄部を中心に15 mmの範囲においてminimum lumen diameter

[Key words] 脂質低下療法, プラーク, 退縮

表1 患者背景

	A群 (n=23)	P群 (n=21)	A+P群 (n=21)
年齢(平均)	62.2±12.0	64.4±8.3	57.6±5.2
観察期間	6.8±2.1	6.4±1.2	6.4±1.1
責任血管	5(50%)	8(80%)	6(60%)
LAD	10(40%)	8(20%)	7(30%)
LCX	7(40%)	6(20%)	5(20%)
RCA	6(20%)	7(60%)	9(50%)
喫煙	15(70%)	14(80%)	16(80%)
高脂血症	15(70%)	14(70%)	15(80%)
高血圧	14(70%)	9(40%)	10(40%)
糖尿病	5(0%)	7(40%)	5(20%)
家族歴	4(20%)	3(10%)	4(20%)

(MLD), vessel diameter, 血管内腔面積, 血管内腔容積, 全血管面積, 全血管容積, プラーク断面積, プラーク容積, 面積狭窄率の計測を行った。また, 提示症例においては, プラーク安定化の評価法として texture videodensitometric analysis を用いた。これには, フクダ電子社製解析ソフト Cardio 2000 に含まれる Contrast time analyst を使用し, 黒から白までの gray scale を256段階に分け, その値をプラーク輝度 (gray value) とした。IVUS 画像において中心部の小円 (IVUS カテーテル自体に相当) を基準とし, 同じイメージ上において ROI を設定し, おおのの gray value を求め, 抗高脂血症薬の投与前後において測定し比較検討した。

### 統計学的検討

コレステロール値, 血管内エコーの計測値については, 平均値±SD とし, 平均値の差の検定は paired t-test にて行い,  $p < 0.05$  を有意とした。また, プラーク容積と IVUS 計測値との相関については単回帰分析にて相関を求めた。

### 結果

患者背景は (表1) に示す。3群間に有意差は

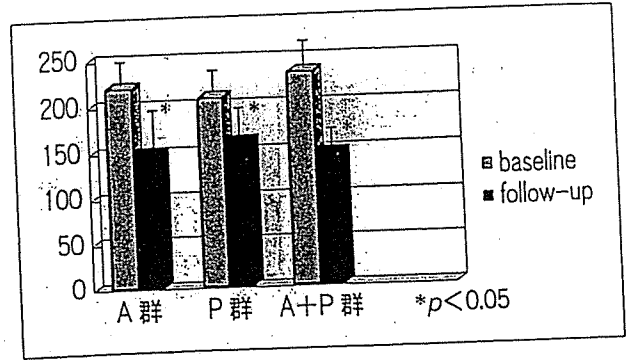


図1 血中総コレステロールの変化

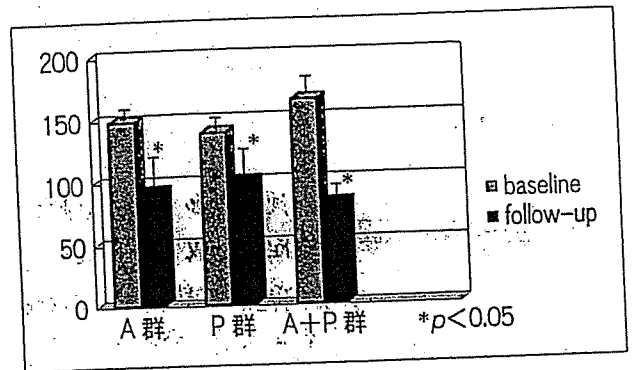


図2 LDLコレステロールの変化

認められなかった。

血中総コレステロールの変化 (図1) は, A群で  $228.0 \pm 22.0$  mg/dl から  $147.01 \pm 36.0$  mg/dl, P群で  $207.0 \pm 34.0$  mg/dl から  $158.0 \pm 27.0$  mg/dl, A+P群で  $233.0 \pm 39.0$  mg/dl から  $140.14 \pm 10.0$  mg/dl とすべての群で有意に減少した。また, LDL (図2) においては, A群で  $149.4 \pm 13.0$  mg/dl から  $88.9 \pm 34.0$  mg/dl, P群で  $138.0 \pm 25.0$  mg/dl から  $99.0 \pm 32.0$  mg/dl, A+P群で  $160.7 \pm 78.0$  mg/dl から  $82.3 \pm 24.0$  mg/dl とA群, A+P群で有意に減少し, A群, A+P群のLDL-Cが100 mg/dl以下となった。また, IVUS所見では, 有意なMLD, プラーク面積, 血管面積, 内腔面積の変化はみられなかった。また, 3Dによる検討 (図3) で, プラーク容積の変化率はA群で-1.4%, P群で-2.0%, A+P群で-6.7%と, AP群で有意に減少した ( $p < 0.05$ )。内腔容積はA群で4.1%, P群で4.0%増加, A+P群で8.2%とA+P群で有意に ( $p < 0.05$ ) 増加

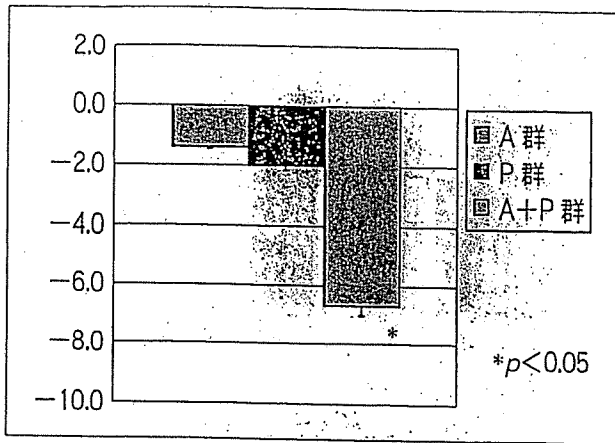


図3 アテロームの変化

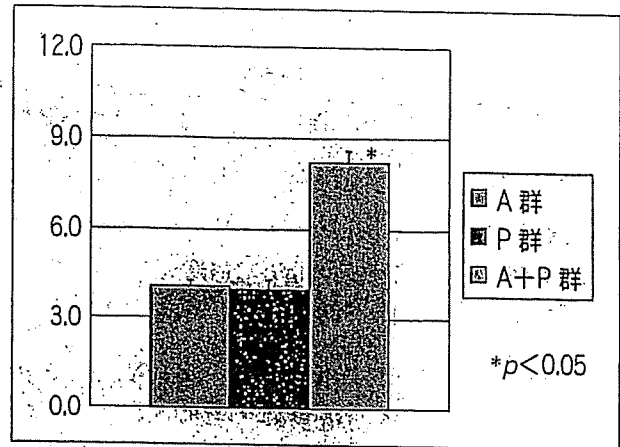


図4 内腔容積の変化

した(図4)。

#### 症例提示(図5)

IVUS上プラーク安定化がみられた1例を提示する(A+P群)。本例はLDLが302 mg/dlから109 mg/dlまで63.9%減少し、6ヵ月後のIVUSにて、プラーク容積は減少し内腔容積が増加し、プラークの退縮が確認された。

#### 考察 抗高脂血症薬投与によるプラークのIVUS所見の変化

statin投与によるlipid lowering therapyのプラーク安定化、退縮に関するIVUSを用いた研究はいくつか報告されており、Takagiら<sup>6)</sup>は、statin投与群において冠動脈の血管面積の増加がなく血管内腔面積の増加が認められた。すなわちプラークの減少により血管内腔面積が増加したと報告した。また、Hamasakiら<sup>7)</sup>はstatin投与によりコレステロールが十分にコントロールされていた群と不十分な群で、冠動脈の血管内腔面積を計測したが、コントロールされている群で有意に大きいことを報告した。Hagenaarsら<sup>8)</sup>は下肢末梢血管を用いた検討であるが、1年間のstatin投与により血管リモデリングによる血管内腔面積の有意な増加が観察されたと報告している。Schartl

ら<sup>4)</sup>はstatinを1年間投与しLDLを100 mg/dl以下にしIVUSによる検討を行った。それによると、プラーク容積の有意な減少はみられなかったものの、プラークのエコー輝度が有意にstatin投与群で上昇したことから、プラークの安定化が示唆されたと報告した。

今回のわれわれのIVUSによる検討では、A+P群で有意に血管内腔容積が増加し、かつ有意なプラーク容積の減少を示したということは、プラークの減少が内腔容積を増加させたと考えられる。A群においても有意ではなかったが、同様な傾向がみられた。これは、今までの報告では1年間という観察期間であったが、今回の検討は6ヵ月間であるためA群では有意な変化がみられなかったと考えられ、LDLがより低値であったこと、A+P群でのみ有意なプラーク退縮が起こり、従来の報告よりも退縮までの時間を短縮させたのではないかと考えられた。また、コレステロール低下療法に基づくプラークの安定化のみならずprobucol併用により抗酸化作用の相乗効果の結果がプラーク退縮を促進したものとも考えられた。今回の検討ではechogenicityによる検討は全例に行われていないが、提示症例ではLDL-Cが68 mg/dlと著明に低下し、gray valueが上昇し、プラーク安定化が示唆された。今後は同様に多くの症例について検討する必要があると考えられた。

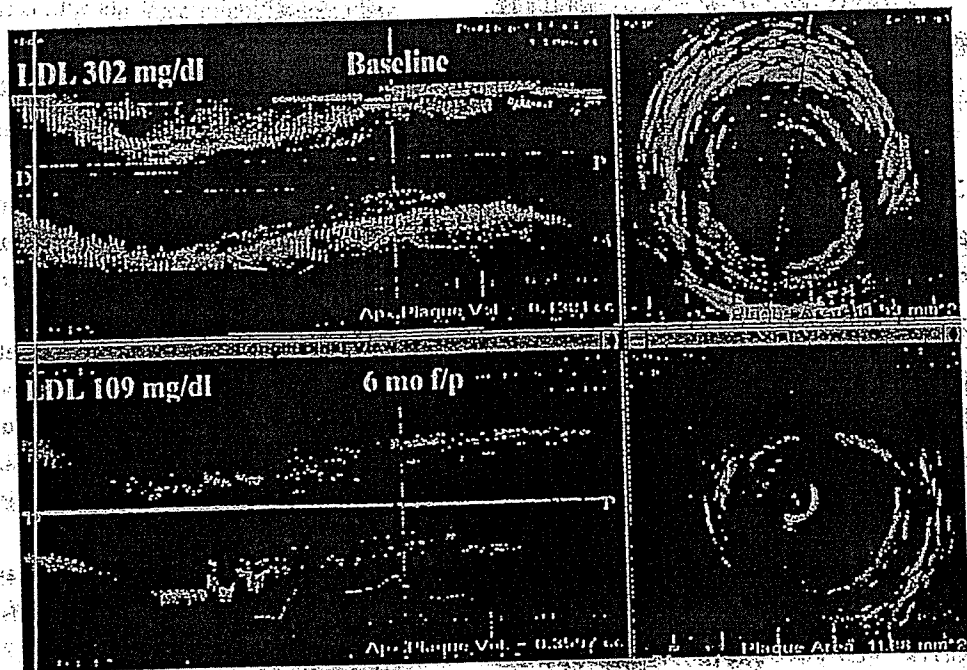


図5 3D-IVUS measurements

### プラーク安定化・退縮の機序についての検討

プラーク安定化・退縮は、コレステロール低下、特に LDL が低下し、酸化 LDL が減少することによりプラークの進展を防止し安定化させるとされる。さらに、statin はコレステロール低下作用による作用以外にもいろいろな直接効果が期待されている。Egashira ら<sup>9)</sup>は pravastatin 投与群と非投与（コントロール）群におけるアセチルコリンの反応性を検討したところ、コントロール群で冠動脈スパズムが有意に多く認められ、pravastatin による内皮機能の改善を報告した。また、statin には LDL の酸化遅延作用が報告されている。Giroux ら<sup>10)</sup>は simvastatin 投与により dose dependent に 36～54% の LDL 酸化作用抑制効果を報告した。また、Ridker ら<sup>11)</sup>は、5年間の pravastatin の投与により CRP を有意に低下させることを報告した（CARE trial）。これらの酸化抑制作用、抗炎症作用とプラーク安定化の過程への関与についても現在さらに検討が進められている。Nissen ら<sup>12)</sup>は、REVERSAL study において、強力な statin 療法を行っても有意なプラーク

クの退縮は認められなかったが、statin の抗炎症作用がプラークの安定化には重要な因子であることを示唆した。

一方、probucol はコレステロール低下作用のみならず強力な抗酸化作用を有する<sup>13)</sup>。Sawayama ら<sup>14)</sup>は、高脂血症患者を probucol 投与群、pravastatin 投与群とプラセボ群で、投与前および2年を経過した時点で、probucol 群および pravastatin 群で頸動脈の内膜-中膜厚が有意に減少した。さらに、多変量解析により probucol 投与自体が LDL の低下とは独立してプラークの退縮と相関が認められたと報告した。また、心疾患の発症率がプラセボ群に比し有意に低値で、probucol の抗酸化作用がプラークの安定化に大きく寄与したものと結論した。MVP study<sup>15)</sup>では、probucol の冠動脈形成術（PTCA）前30日より PTCA 後6ヵ月投与により、再狭窄率がプラセボ群で38.9%であったのに対し probucol 群で20.7%と有意に低い再狭窄率を示し、抗酸化作用による血管リモデリングの予防効果、新生内膜増殖抑制効果が報告された。われわれの今回の検討では6ヵ月間という短期間投与における IVUS による検討であったにもかかわらず、probucol 単独群にお