

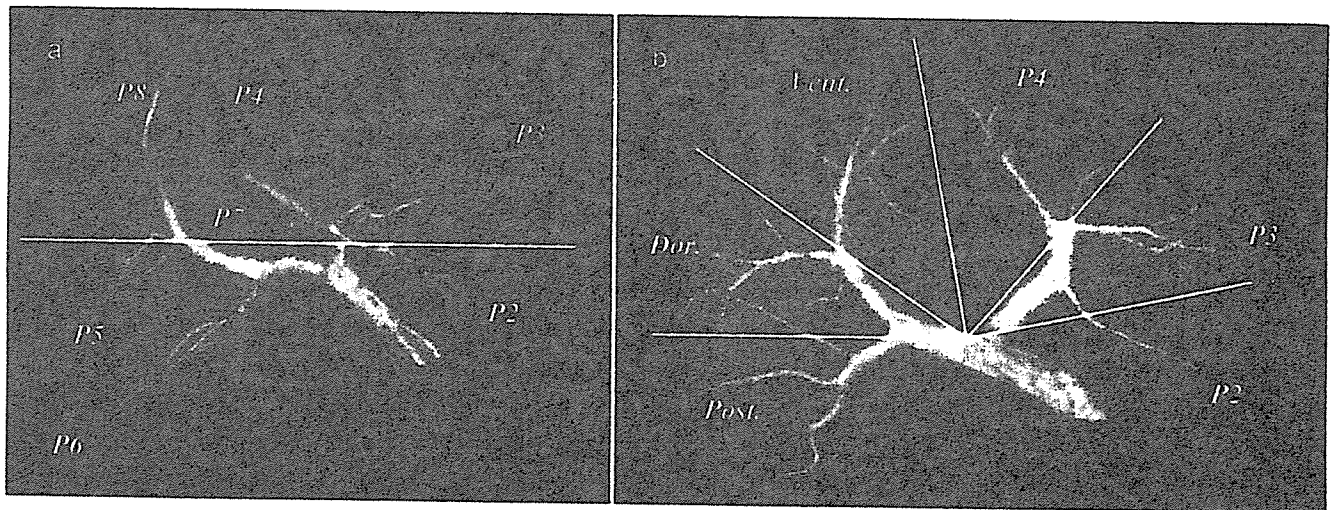図 1 門脈正面像では確かに各区域枝は上下に分岐しているようにみえるが (a)、尾側からみた門脈像では、分岐形態は左右門脈分岐部を中心に放射状に拡がっており、左右対称になっている (b)。したがって、右肝も左肝同様3つの区域に分類が可能である (c)。

脈枝は二次分枝の前後区域枝に分かれ、前区域枝が三次分枝の背側枝と腹側枝に分かれ、左肝同様に後区域と背側区域および腹側区域の3区域に分類されることが考えられる (図1c)。そして背側区域と腹側区域を分ける plane を、左肝の S3 と S4 を分ける umbilical fissure に対応して anterior fissure と呼称している²⁾。

II. 3D Porto-cholangiography からみた肝門部解剖

1. 基本型

われわれの考え方では、門脈は2つの弓から成っている。Ventral arch は UP~左右門脈本幹~前区域枝本幹 (anterior trunk: AT) で構成されており、Dorsal arch は P2~左右門脈本幹~後区域枝で構成されている。胆管は門脈の頭腹側を走行しており、B4、左右肝管 (LHD, RHD)、腹側区域胆管枝 (Bv) が Ventral arch の内側を走行し、B3、B2 が UP を頭側で乗り越えて外側に走行し、背側区域胆管枝 (Bd) と後区域胆管枝 (Bp) が AT を頭側で乗り越えて背側に走行する

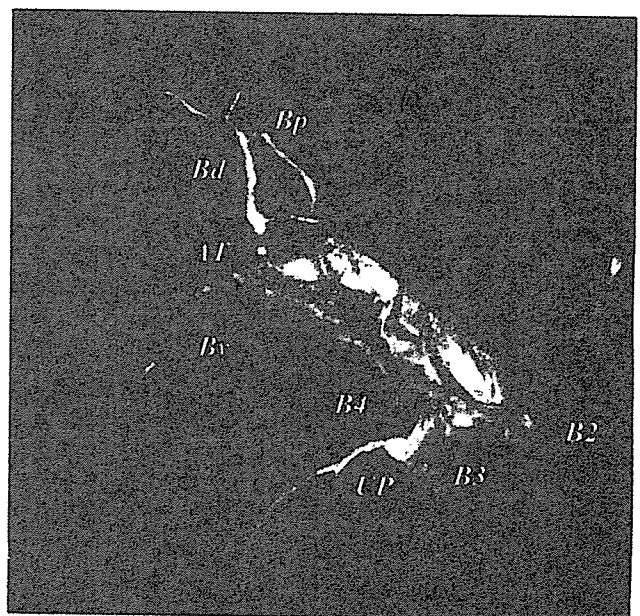


図 2 頭側からみた 3D Porto-cholangiogram
B4, LHD, RHD, Bv が Ventral arch の内側を走行し、B3, B2 が UP を頭側で乗り越えて外側に走行し、Bd と Bp が AT を頭側で乗り越えて背側に走行する。

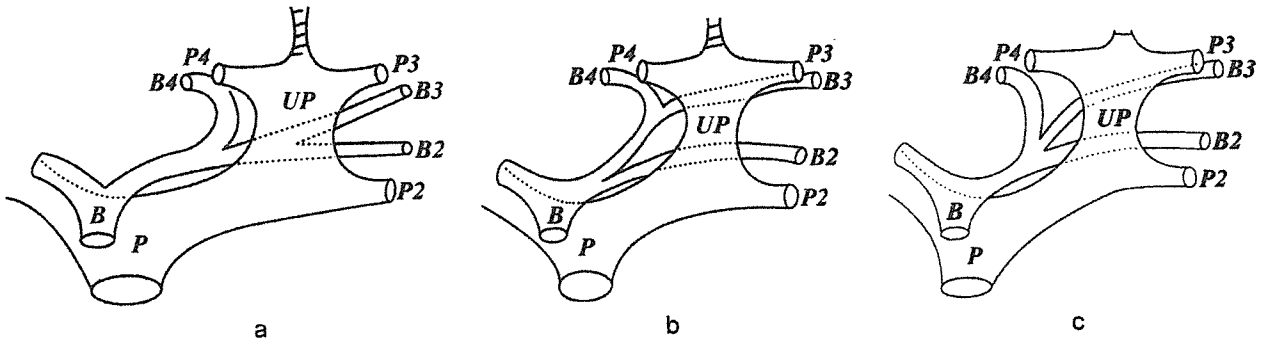


図3 a : Type 1 : B2, B3 が UP 上あるいは左側で合流して外側区域枝を形成し、これに B4 が UP の右側で合流する。
 b : Type 2 : B3, B4 が UP の右側で合流し、さらに右側で B2 が合流する。
 c : Type 3 : B2, B3, B4 が UP の右側でほぼ同時に合流する。

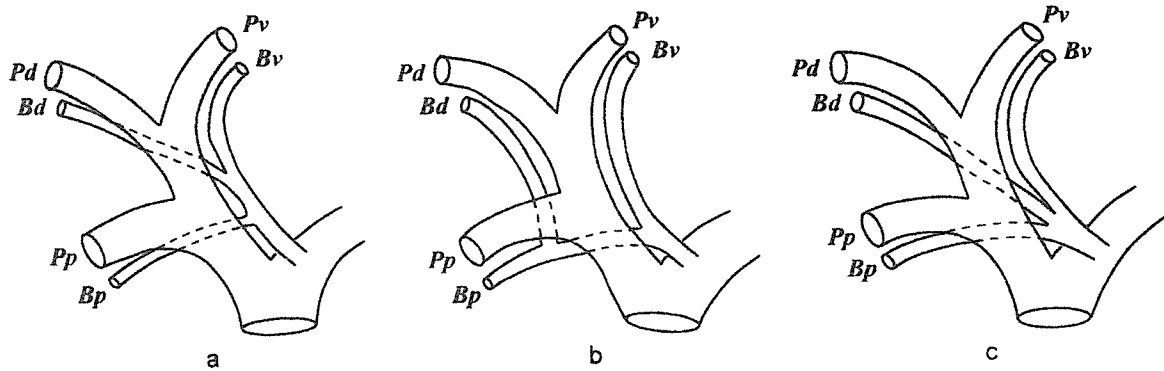


図4 a : Type 1 : Bd が AT の左側で Bv に合流して前区域枝を形成し、これに Bp がやはり AT の左側で合流する。
 b : Type 2 : Bd が AT の右側で Bp に合流して共通管を形成し、これに Bv が AT の左側で合流する。つまり背側区域枝が後区域枝に合流する。
 c : Type 3 : Bv, Bd, Bp が AT の左側でほぼ同時に合流する。

パターンが基本型と考えられる (図2)。この UP および AT を乗り越えて左右に走行する B3, B2 および Bd, Bp の合流部位および走行するルート (南回りなら尾側を走行) にいろいろな変位が認められる。

2. 左門脈と胆管の関係

以下の3パターンが認められる⁶⁾ (図3)。

Type 1 : B2, B3 が UP 上あるいは左側で合流して外側区域枝を形成し、これに B4 が UP の右側で合流する。

Type 2 : B3, B4 が UP の右側で合流し、さらに右側で B2 が合流する。このパターンでは B2 は肝門部近傍に合流している。

Type 3 : B2, B3, B4 が UP の右側でほぼ同時に合流する。

3. 右門脈と胆管の関係

右も左同様3つのパターンが認められる (図4)。

Type 1 : Bd が AT の左側で Bv に合流して前区域枝を形成し、これに Bp がやはり AT の左側で合流す

る (図5)。

Type 2 : Bd が AT の右側で Bp に合流して共通管を形成し、これに Bv が AT の左側で合流する。つまり背側区域枝が後区域枝に合流する (図6)。

Type 3 : Bv, Bd, Bp が AT の左側でほぼ同時に合流する。

ま と め

右肝を腹側区域、背側区域、後区域の3つの区域に分類し、3D Porto-cholangiography を用いて肝門部の胆管と門脈の解剖学的関係を検討した。この新しい肝区域分類の概念を応用することによって、複雑な解剖が比較的簡単に理解できると思われる。

参 考 文 献

- 1) Cho A, Okazumi S, Makino H, et al. : Relation

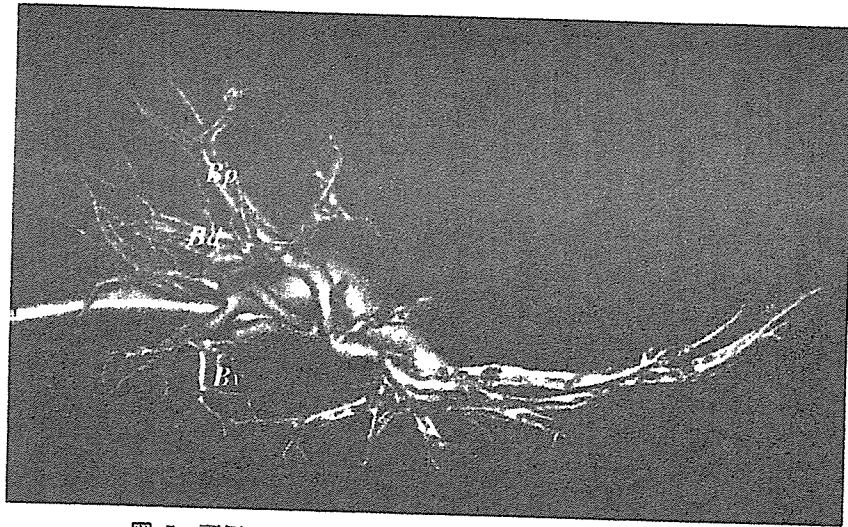


図 5 頭側からみた Type 1 の 3D Porto-cholangiogram

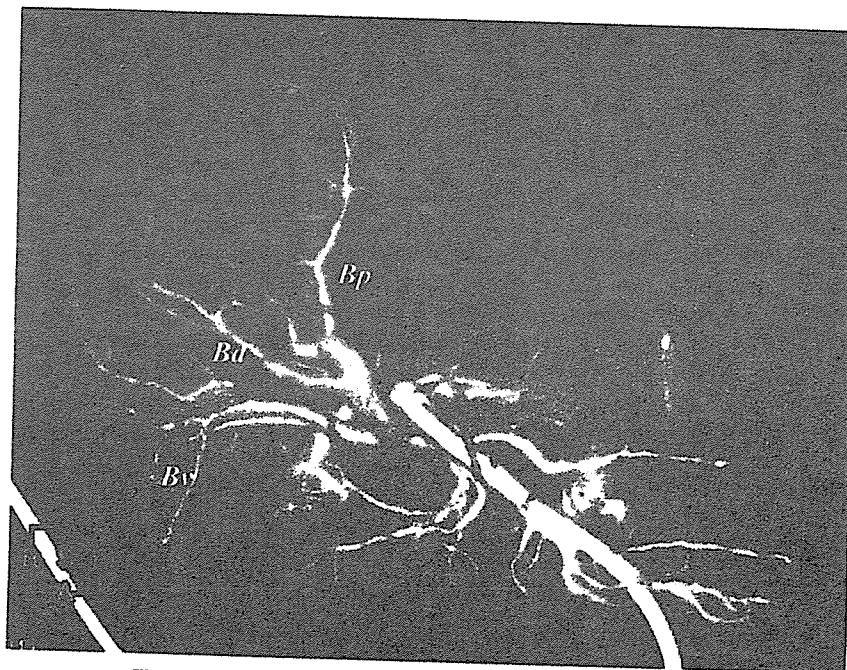


図 6 頭側からみた Type 2 の 3D Porto-cholangiogram

- between hepatic and portal veins in the right parame-dian sector : proposal for anatomical reclas-sification of the liver. *World J Surg* **28** : 8-12, 2004.
- 2) Cho A, Okazumi S, Makino H, et al. : Anterior fissure of the right liver - the third door of the liver. *J Hepatobiliary Pancreat Surg* **11** : 390-396, 2004.
 - 3) Cho A, Okazumi S, Miyazawa Y, et al. : Proposal for a reclassification of liver based anatomy on portal ramifications. *Am J Surg* **189** : 195-199, 2005.
 - 4) Couinaud C : *Surgical anatomy of the liver revisit-*

ed. (Couinaud C), Paris, 1989.

- 5) Cho A, Okazumi S, Takayama W, et al. : Anatomy of the right anterosuperior area (segment 8) of the liver : evaluation with helical CT during arterial portography. *Radiology* **214** : 491-495, 2000.
- 6) Cho A, Okazumi S, Yoshinaga Y, et al. : Relation-ship between left biliary duct system and left portal vein : evaluation with three-dimensional porto-cholangiography. *Radiology* **228** : 246-250, 2003.

* * *

Relationship between right portal and biliary systems based on reclassification of the liver

Akihiro Cho, M.D.^{a,*}, Takehide Asano, M.D.^a, Hiroshi Yamamoto, M.D.^a,
Matsuo Nagata, M.D.^a, Nobuhiro Takiguchi, M.D.^a, Osamu Kainuma, M.D.^a,
Hiroaki Soda, M.D.^a, Mikito Mori, M.D.^a, Souichi Narumoto, M.D.^a,
Shinichi Okazumi, M.D.^b, Harufumi Makino, M.D.^c,
Takenori Ochiai, M.D., Ph.D., F.A.C.S.^b, Munemasa Ryu, M.D.^a

^aDepartment of Surgery, Chiba Cancer Center Hospital, 666-2 Nitonachou, Chuouku, Chiba 260-8717, Japan

^bDepartment of Academic Surgery, Graduate School of Medicine, Chiba University, Chuouku, Chiba, Japan

^cResearch Center for Medical Engineering, Chiba University, Chuouku, Chiba, Japan

Manuscript received January 9, 2006; revised manuscript April 23, 2006

Abstract

Background: Although the anatomy of the right portal and biliary systems and their interrelationships must be understood to safely and satisfactorily perform left-sided resection of hilar cholangiocarcinoma or right-lobe living donor liver transplantation, the anatomies of the right portal and biliary systems are extremely difficult to understand.

Methods: A total of 60 patients with normal liver underwent computed tomography during both portography and cholangiography to evaluate relationships between the right biliary and portal systems based on reclassification of the liver to divide the right liver into 3 segments.

Results: All ventral and posterior ducts constantly join medially to the anterior portal trunk. In contrast, some dorsal ducts join the ventral duct medially and others join the posterior duct lateral to the anterior trunk.

Conclusions: Reclassification of the liver to divide the right liver into 3 segments facilitates an understanding of relationships between the right portal and biliary systems. © 2007 Excerpta Medica Inc. All rights reserved.

Keywords: Hilar cholangiocarcinoma; Living donor liver transplantation; Reclassification of the liver; 3D portochoangiography

Although en bloc resection has contributed to improved long-term survival in patients with hilar cholangiocarcinoma, a formidable challenge remains for surgeons in the complex anatomy of the portal and biliary systems, particularly involving the hepatic hilum [1–4]. In addition, biliary complications such as biliary stricture and anastomotic leakage reportedly remain as serious problems in living donor liver transplantation, and are caused by ischemia of the biliary tract or incomplete understanding of the surgical anatomy of the bile duct system [5–8]. Relationships between the left biliary duct and left portal vein systems have been analyzed using ex vivo cadaveric liver corrosion casts [8–10] and in vivo radiologic analysis [11,12]. In contrast, understanding the segmental anatomy of the right liver is more difficult than that of the left liver because many variations exist and anatomic relationships be-

tween the right biliary duct and the right portal vein system have not been established thoroughly. Reclassification of the liver to divide the right liver into 3 vertical segments has been proposed, to simplify the segmental anatomy of the right liver [13–15]. The present study aimed to re-evaluate relationships between the right biliary duct and right portal vein systems based on this reclassification.

Patients and Methods

Between April 2001 and May 2005, a total of 36 patients underwent percutaneous transhepatic biliary drainage as a result of obstructive jaundice, and 46 patients underwent drip-infusion cholangiography–computed tomography (CT) for preoperative evaluation of laparoscopic cholecystectomy. Of these patients, 71 met the following inclusion criteria: no lesions in the liver, no cirrhosis, no extrahepatic lesions distorting the intrahepatic venous anatomy, and no previous liver surgery. Another 11 patients in whom the right portal vein was

* Corresponding author. Tel.: +81-43-264-5431; fax: +81-43-262-8680.
E-mail address: acho@chiba-cc.jp

absent were excluded. Our study group thus comprised the remaining 60 patients, with a mean age of 62.3 years (range, 16–74 y). The underlying pathology was cholecystolithiasis ($n = 31$), pancreatic cancer ($n = 12$), gallbladder polyp ($n = 8$), bile duct cancer ($n = 5$), and choledocholithiasis ($n = 4$). All study protocols were approved by the institutional review board, and informed consent was obtained from all patients before the procedure was performed. All studies were performed using a LightSpeed Ultra 16-slice multidetector CT scanner (GE Medical Systems, Milwaukee, WI). The 25 patients undergoing percutaneous transhepatic biliary drainage underwent CT after injection of iohexol (Omnipaque, 300 mg/mL of iodine; Daiichi, Tokyo, Japan) diluted 1:10 with saline through biliary catheters. In addition, CT during arterial portography was performed during biliary opacification of contrast medium [14]. In 35 patients, 100 mL of iohexol was injected at 3 mL/s through a 20-gauge intravenous catheter into a medially located antecubital vein using a Dual Shot power injector (Nemoto-kyorindo, Tokyo, Japan) after drip-infusion cholangiography. Neither serious nor minor complications occurred during or after procedures in all patients. CT data were downloaded to an independent workstation equipped with software for perspective volume rendering (Virtual Place; Office Azemoto, Tokyo, Japan). By using this software, 3-dimensional (3D) images were reconstructed. We have previously reported that the right anterior portal vein does not bifurcate into the anterosuperior branch (P8) and anteroinferior branch (P5), instead it bifurcates into the right ventral portal vein and the right dorsal portal vein. Reclassification of the liver to divide the right liver into anterior, middle, and posterior vertical segments has been proposed (Fig. 1) [13–15]. Based on this reclassification of the liver, we assessed the confluence pattern of the right ventral, dorsal, and posterior biliary branches, and the relationship between the right portal and biliary systems. Original consecutive axial CT images and 3D images were interpreted independently in a blinded fashion by 2 of the authors (A.C., H.Y.) who were very familiar with CT features and the anatomy of the liver. Any discrepancies that occurred were resolved by consensus.

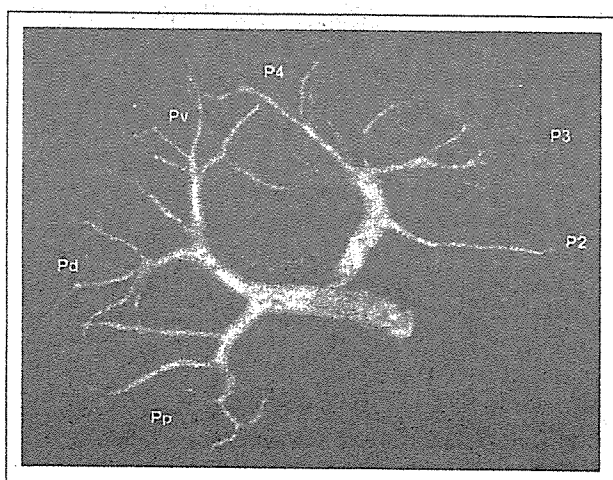


Fig. 1. Computer-generated 3D images of the caudo-cranial view showing ventral portal branches (Pv) and dorsal portal branches (Pd). Pp, right posterior portal vein; P2, left laterosuperior portal branch; P3, left lateroinferior portal branch; P4, medial portal branch. Portal branching pattern seems symmetric.

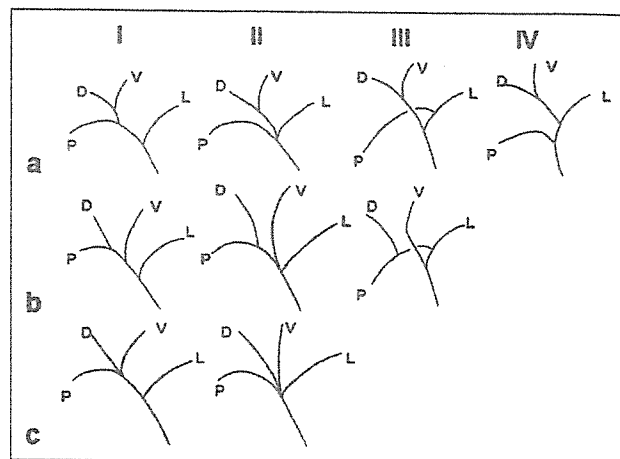


Fig. 2. Confluence patterns of right ventral, dorsal, posterior, and left hepatic ducts. V, ventral duct; D, dorsal duct; P, posterior duct; L, left hepatic duct.

Results

Confluence patterns of left, anterior, and posterior ducts

Confluence patterns were classified as type I (38 patients; 63%), normal configuration; type II (14 patients; 23%), triad confluence; type III (7 patients; 12%), posterior segmental duct joining left hepatic duct; or type IV (1 patient; 2%), distal confluence of the right posterior segmental duct. In type I, the anterior and posterior ducts unite to form the right duct, then the right and left ducts unite. In type II, the anterior, posterior, and left ducts unite immediately. In type III, the posterior and left ducts unite to form the common duct, then the anterior duct joins. In type IV, the anterior and left ducts unite to form the common duct, then the posterior duct joins distally.

Confluence patterns of right ventral, dorsal, and posterior ducts

Three distinct subtypes were detected with regard to confluence patterns of the right ventral, dorsal, and posterior ducts (Fig. 2). Subtype a was characterized by union of the ventral and dorsal ducts to form the anterior duct. Subtype b was characterized by a common trunk of the dorsal and posterior ducts. Subtype c was characterized by immediate union of the ventral, dorsal, and posterior ducts. Types Ia, Ib, and Ic were seen in 30 (50%), 6 (10%), and 2 (3%) of the 60 patients, respectively. Types IIa, IIb, and IIc were seen in 9 (15%), 4 (7%), and 1 (2%) of the 60 patients, respectively. Types IIIa and IIIb were seen in 5 (8%) and 2 (3%) of the 60 patients, respectively. Type IVa was seen in 1 of the 60 patients (2%) (Table 1). Type IIIc and IVc did not exist

Table 1

Confluence patterns of the ventral, dorsal, posterior, and left hepatic ducts

Subtypes of confluence pattern	Confluence patterns of hilar bile ducts			
	I	II	III	IV
a	30 (50)	9 (15)	5 (8)	1 (2)
b	6 (10)	4 (7)	2 (3)	0 (0)
c	2 (3)	1 (2)	—	—
Total	38 (63)	14 (23)	7 (12)	1 (2)

Data in parentheses are percentages.

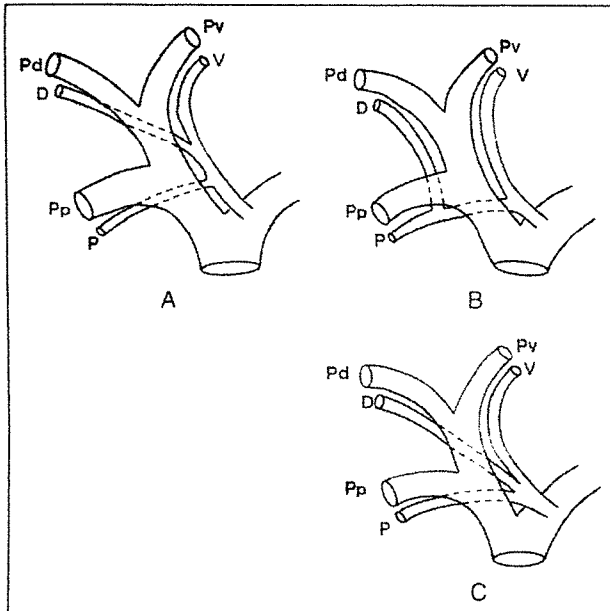


Fig. 3. Variants of right biliary and portal systems. (A) Ventral and dorsal ducts unite medial to the right anterior portal trunk, then the posterior duct also joins medial to the right anterior portal trunk. (B) Posterior and dorsal ducts unite lateral to the right anterior portal trunk, then the ventral duct joins medial to the right anterior portal trunk. (C) Ventral, dorsal, and posterior ducts unite medial to the right anterior portal trunk. PV = ventral portal branch; Pd = dorsal portal branch; Pp = right posterior portal vein; V = ventral duct; D = dorsal duct; P = posterior duct.

theoretically. Type IV b was not detected in the present study.

Relationship between right portal and biliary systems

The orientations in which the right posterior ducts crossed the right portal vein cranially, and in which the right biliary ducts ran superior to the right portal vein were constant (Fig. 3). In all 45 type Ia, IIa, IIIa, and IVa patients, the ventral and dorsal ducts united medial to the right anterior portal trunk, then the posterior duct also joined medial to the right anterior portal trunk (Figs. 3A and 4). In all 12 type Ib, IIb, and IIIb patients, the posterior and dorsal ducts united lateral to the right anterior portal trunk, then the ventral duct joined medial to the right anterior portal trunk (Figs. 3B and 5). In all 3 type Ic and IIc patients, the ventral, dorsal, and posterior ducts united medial to the right anterior portal trunk (Figs. 3C and 6).

Comments

Relationships between the left portal and biliary systems have been analyzed thoroughly using ex vivo corrosion casts [8] and in vivo radiologic examination [11], and is not so difficult to understand. The left biliary ducts are located cranial to the transverse and umbilical portions. Three distinct types can be identified: the segment 2 duct (B2) and segment 3 duct (B3) unite lateral to the umbilical portion, which lies on the umbilical fissure, then the segment 4 duct (B4) joins medial to the umbilical fissure; B3 and B4 unite medial to the umbilical fissure, then B2 joins medial to the umbilical fissure; or B2, B3, and B4 unite medial to the umbilical fissure [8,11]. In contrast, few reports have described relationships between the

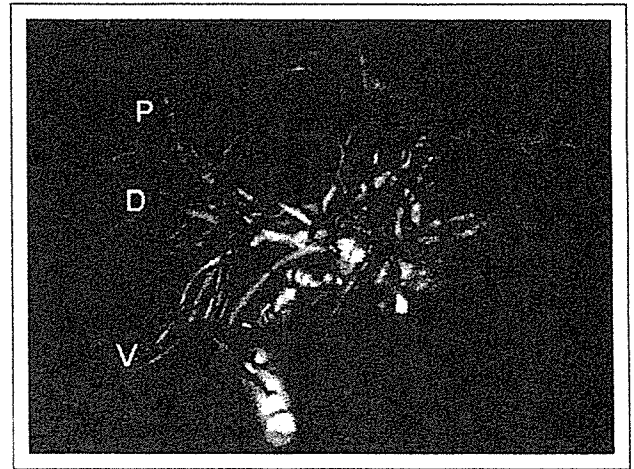


Fig. 4. Three-dimensional portocholangiography showing a craniocaudal view of the portobiliary system. The ventral and dorsal ducts unite to form the anterior duct, then the posterior duct joins (subtype a). V = ventral duct; D = dorsal duct; P = posterior duct.

right portal and biliary systems and understanding based on Couinaud's [9] numbering system is difficult because of the many variations. Recent studies have described the right anterior portal vein as bifurcating into the ventral and dorsal branches [13–17]. Because the right anterior portal vein bifurcated into the ventral and dorsal branches and most posterior portal veins did not bifurcate, we proposed reclassification of the liver to divide the right liver into anterior, middle, and posterior segments, supplied by the ventral, dorsal, and posterior portal branches, respectively [14,15]. The anterior and middle segments proposed by us correspond to the ventral and dorsal regions of Couinaud's [9] segment 8 and 5 (right paramedian sector), respectively, and the posterior segment is equivalent to Couinaud's [9] segment 7 and 6 (right lateral sector). Couinaud [9] divided the left liver into 3 segments, designated as segment 2 (S2), segment 3 (S3), and segment 4 (S4). S2 is supplied by the

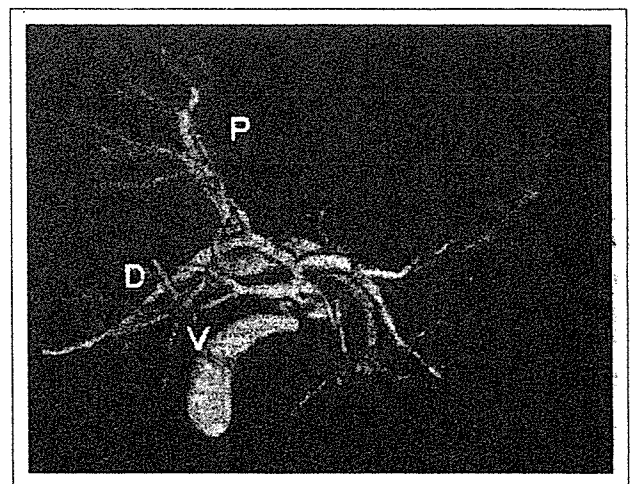


Fig. 5. Three-dimensional portocholangiography showing a craniocaudal view of the portobiliary system. The dorsal and posterior ducts unite, then the ventral duct joins (subtype b). V = ventral duct; D = dorsal duct; P = posterior duct.

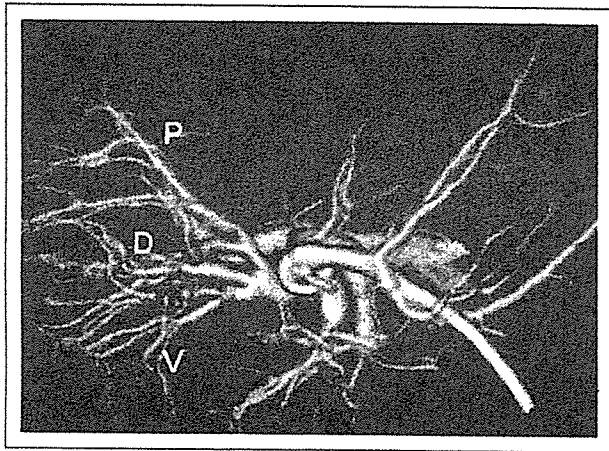


Fig. 6. Three-dimensional portocholangiography showing a craniocaudal view of the portobiliary system. The ventral, dorsal, and posterior ducts unite immediately (subtype c). V = ventral duct; D = dorsal duct; P = posterior duct.

second-order portal vein (P2), and S3 and S4 are each supplied by third-order portal branches (P3 and P4). Portal ramifications thus seem to be symmetric under our new classification because the posterior segment is supplied by the second-order posterior portal vein, and the anterior and middle segments are each supplied by third-order portal branches (ventral and dorsal branches) [14,15]. Thus, the right anterior segment may correspond to segment 4, the right middle segment to segment 3, and the posterior segment to segment 2 [15]. In addition, we proposed the anterior fissure by which the anterior and middle segments were divided [14]. We practically performed segmental hepatic resections along with the anterior fissure [14,15,18,19]. This new anatomic classification may facilitate an understanding of the relationships between the right portal and biliary systems. In the present study, the right portal vein constantly bifurcated into the posterior portal vein and the anterior portal vein, which then bifurcated into the ventral and dorsal branches. In contrast, biliary confluence patterns were classified as type I, normal configuration; type II, triad confluence; type III, posterior segmental duct joining the left hepatic duct; or type IV, distal confluence of the right posterior segmental duct as reported previously [9,10,20]. In addition, 3 distinct relationships exist between the right portal and biliary systems: the ventral and dorsal ducts unite medial to the anterior portal trunk, then the posterior duct joins close to the hepatic hilum; the dorsal and posterior ducts unite lateral to the anterior portal trunk, then the ventral duct joins medial to the anterior portal trunk; or the ventral, dorsal, and posterior ducts unite medial to the anterior portal trunk. Kamiya et al [21], in a review of 107 resected livers, also described the dorsal duct joining the posterior duct in 16.8%. In the left liver, B4 and B2 constantly join medial to the umbilical fissure, and B3 joins either B2 lateral to the umbilical fissure or B4 medial to the umbilical fissure. According to the present study, the ventral duct and posterior duct constantly join medial to the anterior portal trunk, which lies on the anterior fissure [13,14], and the dorsal duct joins either the ventral duct medial to the anterior fissure or the posterior duct lateral to the anterior fissure. We believe that recognition of this relationship

between the right portal and biliary systems is useful to divide the bile duct during the donation of a right liver graft. In addition, the middle segment may be able to be preserved during left-sided resection of hilar cholangiocarcinoma if the dorsal duct joins the posterior duct lateral to the anterior fissure (subtype b). In conclusion, although our study was limited in that no actual gold standard existed for the findings, and comparisons of radiologic and surgical findings must await a future study, we consider that the right liver contains 3, not 4, segments as proposed by Couinaud [9].

References

- [1] Nimura Y, Hayakawa N, Kamiya J, et al. Hepatic segmentectomy with caudate lobe resection for bile duct carcinoma of the hepatic hilus. *World J Surg* 1990;14:535–44.
- [2] Nimura Y, Hayakawa N, Kamiya J, et al. Hilar cholangiocarcinoma—surgical anatomy and curative resection. *J Hepatobiliary Pancreat Surg* 1995;2:239–48.
- [3] Hemming AW, Reed AI, Fujita S, et al. Surgical management of hilar cholangiocarcinoma. *Ann Surg* 2005;241:693–702.
- [4] Otto G, Romanechsen B, Hoppe-Lotichius M, et al. Hilar cholangiocarcinoma: resectability and radicality after routine diagnostic imaging. *J Hepatobiliary Pancreat Surg* 2004;11:310–8.
- [5] Fan ST, Lo CM, Liu CL, et al. Biliary reconstruction and complications of right lobe live donor liver transplantation. *Ann Surg* 2002;236:676–83.
- [6] Lee KW, Joh JW, Kim SJ, et al. High hilar dissection: new technique to reduce biliary complication in living donor liver transplantation. *Liver Transpl* 2004;10:1158–62.
- [7] Fulcher AS, Turner MA, Ham JM. Late biliary complications in right lobe living donor transplantation recipients: imaging findings and therapeutic interventions. *J Comput Assist Tomogr* 2002;26:422–7.
- [8] Reichert PR, Renz JF, D'Albuquerque LA, et al. Surgical anatomy of the left lateral segment as applied to living-donor and split-liver transplantation: a clinicopathologic study. *Ann Surg* 2000;232:658–64.
- [9] Couinaud C. *Surgical anatomy of the liver revisited*. Paris: Couinaud C, 1989.
- [10] Healey JE, Schroy PC. Anatomy of the biliary ducts within the human liver. *Arch Surg* 1953;66:599–616.
- [11] Cho A, Okazumi S, Yoshinaga Y, et al. Relationship between left biliary duct system and left portal vein: evaluation with three-dimensional portocholangiography. *Radiology* 2003;228:246–50.
- [12] Cho A, Ryu M, Kinoshita T, et al. Radiological anatomy of the medial segmental bile duct of the liver assessed by CT cholangiography. *Hepatogastroenterology* 2003;50:945–8.
- [13] Cho A, Okazumi S, Makino H, et al. Relation between hepatic and portal veins in the right paramedian sector: proposal for anatomical reclassification of the liver. *World J Surg* 2004;28:8–12.
- [14] Cho A, Okazumi S, Makino H, et al. Anterior fissure of the right liver—the third door of the liver. *J Hepatobiliary Pancreat Surg* 2004;11:390–6.
- [15] Cho A, Okazumi S, Miyazawa Y, et al. Proposal for a reclassification of liver based anatomy on portal ramifications. *Am J Surg* 2005;189:195–9.
- [16] Cho A, Okazumi S, Takayama W, et al. Anatomy of the right anterosuperior area (segment 8) of the liver: evaluation with helical CT during arterial portography. *Radiology* 2000;214:491–5.
- [17] Kogure K, Kuwano H, Fujimaki N, et al. Reproposal for Hjortsjo's segmental anatomy on the anterior segment in human liver. *Arch Surg* 2002;137:1118–24.
- [18] Cho A, Okazumi S, Miyazawa Y, et al. Limited resection based on reclassification of segment 8 of the liver. *Hepatogastroenterology* 2004;51:575–6.
- [19] Cho A, Okazumi S, Miyazawa Y, et al. Limited resection of the right hemiliver based on reclassification of the right anterior segment of the liver. *Hepatogastroenterology* 2004;51:820–1.
- [20] Kitagawa Y, Nimura Y, Hayakawa N, et al. Intrahepatic segmental bile duct patterns in hepatolithiasis: a comparative cholangiographic study between Taiwan and Japan. *J Hepatobiliary Pancreat Surg* 2003;10:377–81.
- [21] Kamiya J, Nagino M, Uesaka K, et al. Clinicoanatomical studies on the dorsal subsegmental bile duct of the right anterior superior segment of the human liver. *Langenbecks Arch Surg* 2003;388:107–11.

Second Hepatectomy for Recurrent Colorectal Liver Metastasis: Analysis of Preoperative Prognostic Factors

Seiji Ishiguro, MD,¹ Takayuki Akasu, MD,¹ Yoshiya Fujimoto, MD,¹
Junji Yamamoto, MD,² Yoshihiro Sakamoto, MD,² Tsuyoshi Sano, MD,²
Kazuaki Shimada, MD,² Tomoo Kosuge, MD,² Seiichiro Yamamoto, MD,¹
Shin Fujita, MD,¹ and Yoshihiro Moriya, MD¹

¹Colorectal Surgery Division, National Cancer Center Hospital, 5-1-1, Tsukiji, Chuo-ku, Tokyo, 104-0045, Japan

²Hepatobiliary and Pancreatic Surgery Division, National Cancer Center Hospital, 5-1-1, Tsukiji, Chuo-ku, Tokyo, 104-0045, Japan

Background: Second hepatectomy is a potentially curative treatment for patients with hepatic recurrence of colorectal cancer. However, there is still no consensus about the patient selection criteria for second hepatectomy under these circumstances, and the factors affecting prognosis after second hepatectomy remain uncertain.

Methods: Clinicopathologic data for 111 consecutive patients with colorectal liver metastasis who underwent second hepatectomy at a single institution between 1985 and 2004, and for whom complete clinicopathologic reports were available, were subjected to univariate and multivariate analyses.

Results: The morbidity and mortality rates were 14% and 0%, respectively, and the overall 5-year survival rate was 41%. Multivariate analysis revealed that synchronous resection for the first liver metastasis (hazard ratio, 1.8), more than three tumors at the second hepatectomy (1.9), and histopathological involvement of the hepatic vein and/or portal vein by the first liver metastasis (1.7) were independently associated with poor survival. We used these three risk factors to devise a preoperative model for predicting survival. The 5-year survival rates of patients without any risk factors, and with one, two, or three risk factors, were 62%, 38%, 19%, and 0%, respectively.

Conclusions: Second hepatectomy is beneficial for patients without any risk factors. Before second hepatectomy, chemotherapy should be considered for patients with any of these risk factors, especially with two or three factors, in the adjuvant or neoadjuvant setting to prolong survival. These results need to be confirmed and validated in another data set or future prospective trial according to the scoring scheme we outline.

Key Words: Second hepatectomy—Colorectal cancer—Liver metastasis—Prognostic factor—Neoadjuvant chemotherapy.

Hepatectomy is the best and most potentially curative treatment for patients with colorectal liver metastases, yielding a 5-year survival rate of 38% to 51%.^{1–5} After a first hepatectomy, 60% to 70% of

patients will develop recurrent disease, and one-third of these recurrences are limited to the liver.⁶ The safety of hepatectomy has been increasing as a result of improvements in surgical techniques and perioperative management, and second liver resection has also been performed for patients with recurrent colorectal liver metastases. During the past decade, the reported outcomes of second hepatectomy have ranged from 21% to 49% in terms of 5-year survival after surgery. However, after second hepatectomy, some patients develop early recurrence in the liver,

Received July 2, 2006; accepted July 3, 2006; published online September 27, 2006

Address correspondence and reprint requests to: Takayuki Akasu, MD; E-mail: takasu@ncc.go.jp

Published by Springer Science+Business Media, Inc. © 2006 The Society of Surgical Oncology, Inc.

lung, and other organs, and in most of them, the disease is unresectable. Patients who experience recurrence within 6 months after second hepatectomy are already considered to have systemic disease before they undergo surgery. For such patients with systemic colorectal metastases, second hepatectomy is not beneficial and can even be harmful. However, the factors predicting early recurrence and poor outcome have not been established.

The purpose of this study was to find criteria that could be used to identify patients with recurrent liver metastases from colorectal cancer before surgery who would have a poor prognosis after second hepatectomy.

MATERIALS AND METHODS

Between October 1985 and November 2004, data for 111 consecutive patients with recurrent liver metastases from colorectal cancer who underwent first and second hepatectomies at the National Cancer Center Hospital, Tokyo, were collected and reviewed. Patients who did not undergo initial liver resection at our hospital were excluded from the study because we were unable to obtain enough clinicopathologic data for them.

We investigated 27 clinicopathologic variables pertaining to patient characteristics, clinical data, and histopathologic findings, such as sex, age, primary cancer location, lymph node status, timing of first hepatectomy, number of hepatic metastases, tumor diameter, tumor distribution, preoperative serum carcinoembryonic antigen level, extent of liver resection, surgical margin, venous invasion by liver metastases, and bile duct invasion. The extent of liver resection was defined according to the nomenclature; wedge, segmental, and bisegmental resections were classified as minor resection, and hemihepatectomy or more extended resections were classified as major resection. Patient outcomes were determined on the basis of clinical data obtained from the files as of August 2005. The median follow-up period for the 111 patients after second liver resection was 43 months (range, 1–207 months).

The prognostic significance of clinicopathologic factors in relation to survival was investigated by univariate and multivariate analyses. Data were censored in the analysis of overall survival if a patient was alive, and in the analysis of disease-free survival if a patient was alive without recurrent colorectal cancer. Survival rates were calculated by the Kaplan-Meier method and compared statistically by the log-

rank test. Univariate comparisons of survival were performed by the log-rank test and multivariate analysis by the Cox regression model with the forward stepwise method (likelihood ratio). All variables were dichotomized for analysis. All statistical analyses were performed by SPSS for Windows, version 6.0 (SPSS-Japan Inc., Tokyo, Japan). All *P* values were two-sided, and differences at *P* < .05 were considered to be statistically significant.

RESULTS

Patient Characteristics and Follow-up

The 111 patients who underwent second hepatic resection with curative intent included 74 men and 37 women with a mean age of 59 years. The median interval between the first and second hepatic resections was 16 months (range, 4–96 months). At the last follow-up, 37 patients (34%) were alive with no evidence of recurrence, 12 (11%) were alive with disease, 61 (55%) had died of disease, and 1 patient was lost to follow-up. There were 23 actual 5-year survivors. The median follow-up time from primary resection was 69 months (range, 11–249 months), and the median follow-up from the second liver resection was 43 months (range, 1–207 months).

Clinical Features and Pathology

Primary Tumor

The site of the primary cancer was the colon in 75 patients (68%) and the rectum in 36 (32%). Histologically, there were 50 well-differentiated, 58 moderately differentiated, and 1 poorly differentiated adenocarcinoma, and 2 mucinous carcinomas. Metastatic lesions in the liver were found synchronously with the primary tumor in 58 patients (stage IV). Of the 53 patients with metachronous liver metastases, 13 patients had no lymph node metastasis (stage I or II), and 40 patients had lymph node metastasis (stage III).

First Liver Resection

Of the 53 patients with metachronous liver metastases, the median interval between the primary resection and the first hepatectomy was 16 months (range, 4–60 months), and 25 patients (47%) underwent the second hepatectomy within 12 months. Unilobar involvement was observed in 68 patients and bilobar involvement in 43. At the first hepatectomy, 43 patients had a solitary hepatic lesion, 67 had

2 to 12 (median, 3) metastatic nodules, and one patient had more than 50 lesions. The median size of the largest hepatic lesion was 3.3 cm (range, 1.2–10 cm). Minor resection was performed in 93 patients and major resection in 18. The median blood loss was 698 mL (range, 50–3215 mL). Blood transfusion was performed in 17 patients. The surgical margin was negative in 89 patients and positive in 22. Invasions of the portal vein or hepatic vein by the liver metastases were found in 22 patients, and bile duct involvement was found in 39.

Second Liver Resection

The median interval between the first hepatectomy and detection of recurrence was 13 months (range, 2–92 months). Sixty-two patients had a solitary metastasis, and 49 had multiple metastases. The recurrent metastases ranged from 1.2 to 10 cm (median, 3.3 cm) in greatest dimension. Before second hepatectomy, pulmonary resection for lung metastasis was conducted in eight patients, and three patients underwent second hepatectomy and pulmonary resection simultaneously. After first hepatectomy, performed mostly in the 1980s, nine patients received adjuvant hepatic arterial infusion chemotherapy with 5-fluorouracil (5-FU), mitomycin C, and oral capecitabine,⁷ and six patients received oral anticancer drugs for adjuvant therapy (capecitabine in five patients, uracil-tegafur in one). Two patients who underwent colectomy plus simultaneous hepatectomy received adjuvant intravenous 5-FU plus leucovorin or mitomycin C, and one who had initially unresectable liver metastases was provided irinotecan for downstaging.

The second hepatectomy procedures included minor resection in 99 patients, hemihepatectomy in 6 patients, extended hemihepatectomy in 5, extended hemihepatectomy with bile duct reconstruction in 1, and central bisectionectomy in 1. Ninety-three patients had negative margins and 18 had positive margins. The median blood loss during the second liver resection was 913 mL (range, 95–4803 mL), and 22 patients received blood transfusions. No patient died during the perioperative course. Complications occurred in 16 patients (14%), including bile leakage in 8, abscess formation in 4, pleural effusion in 3, cholangitis in 1, and wound infection in 1. Invasions of the portal vein or hepatic vein were found in 25 patients, and bile duct involvement was found in 40.

Survival and Recurrence After Second Hepatectomy

Of the 111 patients who underwent second hepatectomy with curative intent, 61 had died by August 31, 2005. Overall 1-, 3-, and 5-year survival rates were

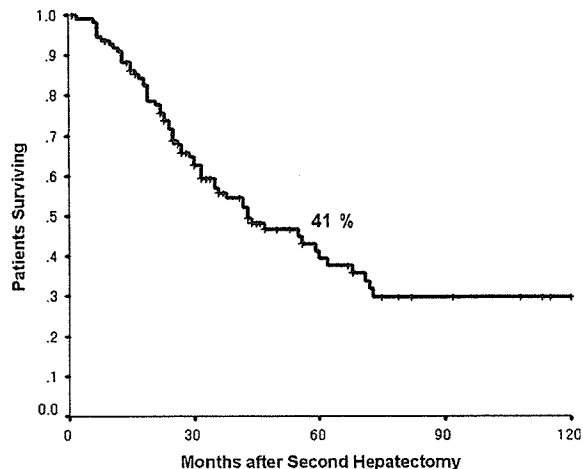


FIG. 1. Overall survival after second hepatectomy in patients with colorectal liver metastases.

91%, 74%, and 41%, respectively, from the time of second liver resection, with a median survival of 43 months (Fig. 1). There were 23 actual 5-year survivors. Recurrence after second hepatectomy occurred in 74 patients. Of these, 39 patients developed liver metastases (27 confined to the liver; 12 involving the liver plus other sites), and 37 developed lung metastases. Of them, 21 patients underwent surgery, including 13 third hepatectomies and 8 pulmonary resections. Twenty-seven patients experienced recurrence within 6 months after the second hepatectomy, and their median survival time was significantly worse than that of the others (15 vs. 60 months, $P = .0001$). Forty-four of the patients who experienced recurrence after second hepatectomy received chemotherapy for treatment. Hepatic arterial infusion chemotherapy was performed in seven patients who had isolated hepatic recurrence. 5-FU was given by infusion to 14 patients; seven received additional mitomycin C. Oral chemotherapy drugs were administered to 7 patients (uracil-tegafur plus leucovorin in 2, S-1 [tegafur/5-chloro-2,4-dihydroxypyridine/potassium oxonate] in 3, capecitabine in 1, and capecitabine in 1), and intravenous 5-FU plus leucovorin was provided to 11. Twenty patients received irinotecan, eight received oxaliplatin, and one received bevacizumab. Irinotecan has been commonly used since 1999 in Japan, and most of the patients who experienced recurrence after 1999 benefited from irinotecan. The group that developed recurrence until 1998 ($n = 19$) had significantly worse survival than those after 1999 ($n = 25$) (median survival time, 23 months vs. 55 months, $P = .004$).

Univariate Analysis of Survival

Factors Related to Primary Lesion

The results of univariate analysis of survival are listed in Table 1. The presence of metastatic lymph nodes was a significant predictor of worse outcome after second liver resection ($P = .03$). The location of the primary colorectal cancer and the histology of the primary lesion did not influence survival.

Factors Related to First Hepatectomy

Patients with metachronous liver metastases had a significantly better median survival time after second hepatectomy (60 vs. 32 months, $P = .009$). The patients who received blood transfusions during the first hepatectomy had significantly worse survival ($P = .049$). The number of tumors, size of the largest tumor, bilobar involvement, extent of hepatectomy, and serum carcinoembryonic antigen level were not prognostic factors. In terms of microscopic findings, invasions of the portal vein or hepatic vein, and a positive surgical margin tended to be associated with poor survival, but the difference was marginal ($P = .07$ and $.07$, respectively). Bile duct invasion was not a prognostic factor.

Factors Related to Second Hepatectomy

The 5-year survival was significantly better for patients with a disease-free interval of more than 6 months between the first hepatectomy and recurrence, as compared with patients with a disease-free interval of less than 6 months (49% vs. 22%, $P = .02$). Patients who had less than four nodules had significantly better survival than those with four or more (45% vs. 18%, $P = .001$). The size of the largest lesion at the second operation influenced survival, but not to a significant degree ($P = .09$). Similar to the first hepatectomy, patients who received blood transfusions showed significantly worse survival ($P = .03$), and bilobar involvement, extent of hepatectomy, and serum carcinoembryonic antigen level were not prognostic factors. Patients who had undergone resection of extrahepatic disease before second hepatectomy did not show worse survival. With respect to the microscopic features of the recurrent metastatic disease, a surgical margin, invasions of the portal vein or hepatic vein, and bile duct invasion had no statistically significant influence on survival.

Multivariate Analysis of Survival

Multivariate analysis identified three independent risk factors: synchronous first hepatectomy, four or

TABLE 1. Univariate analysis related to survival

Prognostic factor	No. of Patients	5-Year survival rate of second hepatectomy (%)	<i>P</i> value
Demographics			
Age			
< 60 y	56	43	.95
≥ 60 y	55	38	
Sex			
Male	74	38	.64
Female	27	46	
Primary lesion			
Location			
Colon	75	36	.17
Rectum	36	52	
Lymph nodes			
Negative	21	74	.03
Positive	90	33	
First hepatectomy			
Number of lesions			
< 4	90	43	.33
≥ 4	21	33	
Size			
< 5 cm	87	42	.45
≥ 5 cm	24	37	
Timing with primary			
Metachronous	53	51	.009
Synchronous	58	30	
Distribution			
Unilobar	68	44	.25
Bilobar	43	36	
Resection			
Minor	93	38	.92
Major	18	53	
CEA before first hepatectomy			
< 50 ng/dL	89	42	.31
≥ 50 ng/dL	22	37	
Blood loss			
< 1000 mL	91	35	.27
≥ 1000 mL	20	57	
Blood transfusion			
No	94	41	.049
Yes	17	35	
Surgical margin			
No	88	45	.07
Yes	23	29	
Vessel invasion			
No	89	46	.07
Yes	22	23	
Bile duct invasion			
No	72	36	.1
Yes	39	50	
Second hepatectomy			
Interval between first hepatectomy and recurrence			
< 6 mo	79	49	.02
≥ 6 mo	36	22	
Extrahepatic disease before second hepatectomy			
No	100	39	.31
Yes	11	54	
Number of lesions			
< 4	93	45	.001
≥ 4	18	18	
Size			
< 5 cm	100	44	.09
≥ 5 cm	11	16	

TABLE 1. Continued

Prognostic factor	No. of Patients	5-Year survival rate of second hepatectomy (%)	P value
Distribution			
Unilobar	68	45	.11
Bilobar	43	34	
Resection			
Minor	96	41	.67
Major	15	44	
CEA before second hepatectomy			
< 50 ng/dL	89	42	.31
> 50 ng/dL	22	37	
Blood loss			
< 1000 mL	73	40	.77
> 1000 mL	38	42	
Blood transfusion			
No	89	43	.03
Yes	22	29	
Surgical margin			
No	90	45	.16
Yes	21	22	
Vessel invasion			
No	75	36	.17
Yes	36	52	
Bile duct invasion			
No	71	43	.95
Yes	40	35	

TABLE 2. Multivariate analysis with Cox proportional hazard model

Prognostic factor	Relative risk	95% Confidence interval	P value
Synchronous timing of first hepatectomy	1.85	1.10-3.11	.02
Presence of vessel invasion at first hepatectomy	1.79	1.00-3.19	.049
Number of lesions at second hepatectomy ≥ 4	1.94	1.10-3.41	.022

more lesions at second hepatectomy, and invasion of the portal vein or hepatic vein at first hepatectomy (Table 2). Any of the variables related to microscopic findings—information that could only be obtained after the second hepatectomy—were not statistically significant prognostic factors.

All three risk factors identified in the multivariate analysis were based on information obtained before the second hepatectomy. Therefore, we tried to group patients according to risk factors. Thirty-four patients had no risk factors, 53 had one factor, 22 had two factors, and 2 had three factors. Survival expectancies at 5 years for patients with no risk factors, one or two risk factors, and three risk factors were 62%, 31%, and 0%, respectively, and these differences were statistically significant ($P = .001$) (Fig. 2). Two patients with three risk factors developed recurrence

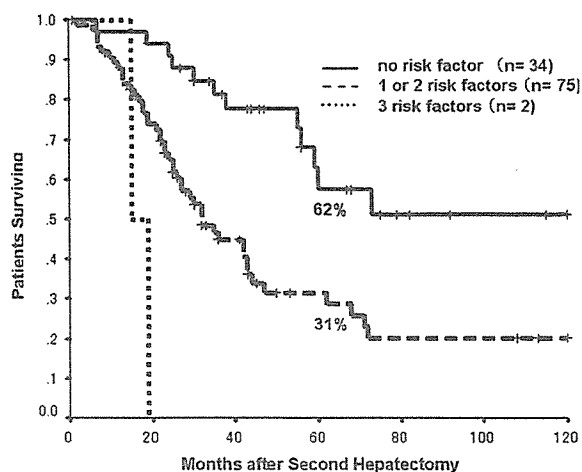


FIG. 2. Overall survival according to groups divided by number of risk factors identified in current study.

within 6 months and died at 15 months and 19 months, respectively, after the second hepatectomy.

DISCUSSION

The only potentially curative treatment for patients with liver-isolated colorectal metastases is surgical resection. However, most cannot be considered candidates for surgery for reasons such as very large tumor, unfavorable tumor location, multinodularity, or inadequate hepatic reserve. Nevertheless, because of its impact on survival, surgical resection is the treatment of choice when it is feasible. Improvements in surgical techniques and perioperative management have made surgical resection more feasible, with a mortality rate of less than 3%.^{2-4,8} For patients with recurrent colorectal liver metastases, second hepatic resection has been performed more frequently during the past decade.^{6,9-22} The results of previous series involving more than 20 patients are listed in Table 3. Five-year survival rates of 38% to 51% have been reported for first hepatic resections,^{1-5,23} and similar 5-year survival rates, ranging from 21% to 49%, can be achieved after second hepatic resection for well-selected patients. In fact, morbidity and mortality after second hepatic resection are almost comparable to those after initial hepatic resection. The median survival and 5-year survival rate in the present series were 43 months and 41%, respectively. Because conventional chemotherapy alone cannot achieve such favorable results, a second hepatectomy has become the treatment of choice for recurrent liver metastases from colorectal cancer.

TABLE 3. Reports of second hepatectomy

Author	Year	No. Patients	Mortality (%)	Morbidity (%)	5-Year survival	MST (mo)
Fong et al. ⁹	1994	25	0	28	NR	30
Nordlinger et al. ¹⁰	1994	116	.9	25	33 ^a	NR
Que and Nagorney ¹¹	1994	21	5	NR	43 ^b	41
Fernandez-Trigo et al. ¹²	1995	170	NR	19	32	34
Riesener et al. ¹³	1996	25	0	20	24 ^a	NR
Adam et al. ⁶	1997	64	0	20	26	46
Tuttle et al. ¹⁴	1997	23	0	22	32	40
Yamamoto et al. ¹⁵	1999	75	0	11	31	31
Muratore et al. ¹⁶	2001	29	3.4	10	35 ^a	NR
Suzuki et al. ¹⁷	2001	26	0	33	32	31
Petrowsky et al. ¹⁸	2002	126	1.6	28	34	37
Takahashi et al. ¹⁹	2003	22	0	18	49 ^a	23
Tanaka et al. ²⁰	2004	26	0	30	48 ^c	NR
Sugawara et al. ²¹	2005	27	0	22	49	41
Pessaux et al. ²²	2006	42	0	14	21	25

MST, median survival time; NR, not reported.

^a Three-year survival.

^b Four-year survival.

^c Five-year disease-free survival.

Recently, systemic chemotherapy has led to marked improvements in median overall survival and progression-free survival.²⁴⁻²⁶ These benefits are most pronounced with regimens containing irinotecan or oxaliplatin in combination with 5-FU plus leucovorin; median overall survival durations consistently approach 20 months, and some are as high as 24 months. Some patients experience early repeat recurrence within 6 months after second hepatectomy, and most of the disease is in an unresectable state when repeat recurrence is detected. In our series, 27 patients developed repeat recurrence within 6 months. Two patients underwent additional surgery, and the others received systemic chemotherapy, with a median survival time of 15 months. Considering these results, because their median survival was worse than that of patients who received systemic chemotherapy, the patients must have already had systemic disease at the time of surgery. Interestingly, we found that the patients who developed recurrence after 1999, when we started chemotherapy with irinotecan, had much better survival than those before 1998. This result seems mainly attributable to progress in chemotherapy, although diagnostic modality and perioperative management have been improved during these periods, and such improvements may have influenced survival. Now that we are in an era of effective chemotherapy, the indications for second liver resection need to be reconsidered. To improve the results of second hepatectomy, it is necessary to identify patients whose disease is likely to develop early repeat recurrence and who therefore should receive systemic chemotherapy.

Several studies have tried to identify factors predictive of a favorable outcome after repeat hepatectomy. To date, three reports have identified independent prognostic factors by multivariate analysis. Adam et al.⁶ showed that the disease-free interval between initial and second liver resections and a second liver resection with curative intent were independently associated with survival. In our study, univariate analysis showed that a disease-free interval of more than 6 months between the first hepatectomy and recurrence was a significant prognostic factor, although it did not reach statistical significance by multivariate analysis. Our multivariate analysis showed that synchronous first hepatectomy was an independently predictive factor. Petrowsky et al.¹⁸ showed that the presence of multiple lesions at repeat hepatectomy and a maximum tumor size exceeding 5 cm were independent prognostic factors after repeat hepatectomy. The third report, by Yamamoto et al.¹⁵ from our hospital in 1999, involved data from 90 repeat hepatectomies (second = 75; third = 12; fourth = 3). Multivariate analysis revealed two independent prognostic factors after the second hepatectomy: four or more tumors, and the presence of extrahepatic disease. The present study detected three independent prognostic factors: synchronous first hepatectomy, four or more lesions evident at the second hepatectomy, and invasions of the portal vein or hepatic vein at the first hepatectomy. Thus, only the number of lesions was a common predictor of outcome, whereas the other factors differed from those highlighted in the first study. We speculate that the reason for this difference was patient selection. In

the prior report, 12 of the 75 patients who underwent second hepatectomy had received their first hepatectomy at other hospitals. In the present series, all the patients had undergone both first and second hepatectomies at our hospital. This means that we had full access to pathologic data from both procedures, ruling out any possibility that the first resection had been an incomplete one, and had not been performed at a specialized center such as ours. Okano et al.²⁷ reported that portal vein invasion, hepatic vein invasion, neural invasion, and absence of macroscopic bile duct invasion were prognostic factors for poor outcome in patients undergoing initial hepatectomy. Similarly, we found that histopathologic evidence of invasions of the portal vein or hepatic vein at the first hepatectomy were associated with poor prognosis in patients undergoing a second hepatectomy. To date, to our knowledge, no previous report has indicated that pathological findings other than surgical margin can be predictive of survival after second hepatectomy. It is therefore suggested that not only adequate hepatic resection but also detailed examination by a specialized pathologist is important for more precise selection of patients for second hepatectomy.

All three independent risk factors we found to be important can be recognized before the second hepatectomy, thus permitting a prognosis to be estimated before patients undergo a second hepatectomy. We grouped the patients according to their risk factors. Survival expectancies at 5 years for patients with no risk factors, with one or two, and with three risk factors were 62%, 31%, and 0%, respectively. Considering these results, second hepatectomy will most benefit patients with no risk factors. In addition, no further treatments are needed for those patients. Patients with one or two of these risk factors may require adjuvant therapy after a second hepatectomy to improve survival. There is not much evidence of the efficacy of chemotherapy after hepatectomy, even now. So far, no evidence of improved overall survival has been shown, but the tested regimens included only fluorouracil, floxuridine, and leucovorin, and did not include irinotecan or oxaliplatin.²⁸⁻³⁰ A clinical trial comparing progression-free interval in patients undergoing surgical resection and/or ablation for hepatic metastases from colorectal cancer treated with adjuvant therapy comprising oxaliplatin and capecitabine versus without hepatic arterial infusion of floxuridine was conducted by National Surgical Adjuvant Breast and Bowel Project (NSABP-C09). This year, we are going to start a comparative trial to evaluate the efficacy of adjuvant

chemotherapy with oxaliplatin added to the simplified bimonthly 5-FU and leucovorin regimen³¹ as compared with surgery alone in patients undergoing curative hepatectomy. These results will permit us to determine the strategy to take with patient treatment after hepatectomy.

Generally, neoadjuvant chemotherapy for the patients with hepatic metastases is the strategy for initially unresectable tumors. Adam et al.³² showed the results of neoadjuvant chemotherapy in 701 patients with initially unresectable colorectal liver metastases. Ninety-five cases (13.5%) were found to be resectable, and patients underwent a potentially curative resection with a 5-year survival rate of 35%. Tanaka et al.³³ studied neoadjuvant chemotherapy for 48 patients with five or more bilobar hepatic metastases. They found that 25 patients with neoadjuvant chemotherapy had a better 5-year survival rate than 23 patients who did not receive neoadjuvant chemotherapy (39 vs. 21%, $P = .039$). Multivariate analysis showed that neoadjuvant chemotherapy was an independent predictor of survival. Adam et al.⁶ have adopted neoadjuvant chemotherapy for recurrent liver metastases before second hepatectomy, except in patients with small and solitary disease without concomitant extrahepatic disease.

Neoadjuvant chemotherapy before hepatectomy carries a risk of missing the opportunity for resection in patients whose tumors are initially resectable if tumor progression subsequently occurs during the course of chemotherapy. On the other hand, immediate resection carries a risk of missing occult metastases in the liver or at other sites. It was pointed out that the risk of missing the opportunity for resection could be avoided by frequent evaluation and the use of effective currently available chemotherapy regimens. Allen et al.,³⁴ in a study of neoadjuvant chemotherapy for patients with synchronous liver metastases, reported that none of those tumors became unresectable during the course of chemotherapy. Leonard et al.³⁵ commented that the role of neoadjuvant chemotherapy in patients with resectable liver metastases was not confirmed, and well-designed prospective trials were needed. One clinical trial was conducted to evaluate the feasibility and risks of the preoperative chemotherapy with oxaliplatin, 5-FU, and leucovorin and surgery for resectable colorectal liver metastases by the European Organization for Research and Treatment of Cancer.³⁶ The trial had been closed, and the interim results were that 93% of the patients receiving preoperative chemotherapy underwent surgery, and their surgery-related mortality and morbidity were

low. The results on survival will be available in 2006. In our institution, the policy for liver metastases is immediate resection when the metastases are found to be resectable, even if they have recurred for the second or third time. For patients with no risk factors, or with one or two of these risk factors, immediate surgery without neoadjuvant chemotherapy is appropriate considering our results. Although we cannot deny that hepatectomy is the best and most potentially curative treatment for recurrent hepatic metastases, neoadjuvant chemotherapy followed by surgery is likely to be preferable for patients who have all three risk factors, to achieve better outcome.

Yamamoto et al.¹⁵ showed that the presence of extrahepatic disease was independently associated with poor survival, but because our series included only three patients with concomitant extrahepatic metastases, we were unable to confirm this. All three patients had solitary lung metastasis; one underwent pulmonary resection concomitant with second hepatectomy, and the other two underwent the two procedures synchronously. The first two patients died after 7 and 19 months, respectively, and the third is alive, without recurrence, at 37 months. Thus, we think that the presence of pulmonary metastases does not contraindicate repeat hepatic resection if it is anticipated that surgical resection of lung disease will result in cure.

In conclusion, we have been able to identify three risk factors that predict poor survival in patients with recurrent liver metastases from colorectal cancer: (1) synchronous first hepatectomy, (2) four or more lesions present at the time of second hepatectomy, and (3) invasions of the portal vein or hepatic vein evident at the first hepatectomy. Second hepatectomy is beneficial for patients without any risk factors. Before second hepatectomy, we should consider the use of chemotherapy for patients with any of these risk factors—especially in patients with two or three factors—in the adjuvant or neoadjuvant setting to prolong survival. These results need to be confirmed and validated with another data set or by future prospective trials according to the scoring scheme we showed.

REFERENCES

- Scheele J, Stang R, Altendorf-Hofmann A, Paul M. Resection of colorectal liver metastases. *World J Surg* 1995; 19:59–71.
- Yamamoto J, Shimada K, Kosuge T, Yamasaki S, Sakamoto M, Fukuda H. Factors influencing survival of patients undergoing hepatectomy for colorectal metastases. *Br J Surg* 1999; 86:332–7.
- Minagawa M, Makuuchi M, Torzilli G, et al. Extension of the frontiers of surgical indications in the treatment of liver metastases from colorectal cancer: long-term results. *Ann Surg* 2000; 231:487–99.
- Choti MA, Sitzmann JV, Tiburi MF, et al. Trends in long-term survival following liver resection for hepatic colorectal metastases. *Ann Surg* 2002; 235:759–66.
- Adam R, Pascal G, Azoulay D, Tanaka K, Castaing D, Bismuth H. Liver resection for colorectal metastases: the third hepatectomy. *Ann Surg* 2003; 238:871–83; discussion 83–4.
- Adam R, Bismuth H, Castaing D, et al. Repeat hepatectomy for colorectal liver metastases. *Ann Surg* 1997; 225:51–60.
- Moriya Y, Sugihara K, Hojo K, Makuuchi M. Adjuvant hepatic intra-arterial chemotherapy after potentially curative hepatectomy for liver metastases from colorectal cancer: a pilot study. *Eur J Surg Oncol* 1991; 17:519–25.
- Fong Y, Cohen AM, Fortner JG, et al. Liver resection for colorectal metastases. *J Clin Oncol* 1997; 15:938–46.
- Fong Y, Blumgart LH, Cohen A, Fortner J, Brennan MF. Repeat hepatic resections for metastatic colorectal cancer. *Ann Surg* 1994; 220:657–62.
- Nordlinger B, Vaillant JC, Guiguet M, et al. Survival benefit of repeat liver resections for recurrent colorectal metastases: 143 cases. Association Francaise de Chirurgie. *J Clin Oncol* 1994; 12:1491–6.
- Que FG, Nagorney DM. Resection of "recurrent" colorectal metastases to the liver. *Br J Surg* 1994; 81:255–8.
- Fernandez-Trigo V, Shamsa F, Sugarbaker PH. Repeat liver resections from colorectal metastasis. Repeat Hepatic Metastases Registry. *Surgery* 1995; 117:296–304.
- Riesener KP, Kasperk R, Winkeltau G, Schumpelick V. Repeat resection of recurrent hepatic metastases—improvement in prognosis?. *Eur J Surg* 1996; 162:709–15.
- Tuttle TM, Curley SA, Roh MS. Repeat hepatic resection as effective treatment of recurrent colorectal liver metastases. *Ann Surg Oncol* 1997; 4:125–30.
- Yamamoto J, Kosuge T, Shimada K, Yamasaki S, Moriya Y, Sugihara K. Repeat liver resection for recurrent colorectal liver metastases. *Am J Surg* 1999; 178:275–81.
- Muratore A, Polastri R, Bouzari H, Vergara V, Ferrero A, Capussotti L. Repeat hepatectomy for colorectal liver metastases: a worthwhile operation?. *J Surg Oncol* 2001; 76:127–32.
- Suzuki S, Sakaguchi T, Yokoi Y, et al. Impact of repeat hepatectomy on recurrent colorectal liver metastases. *Surgery* 2001; 129:421–8.
- Petrowsky H, Gonen M, Jarnagin W, et al. Second liver resections are safe and effective treatment for recurrent hepatic metastases from colorectal cancer: a bi-institutional analysis. *Ann Surg* 2002; 235:863–71.
- Takahashi S, Inoue K, Konishi M, Nakagouri T, Kinoshita T. Prognostic factors for poor survival after repeat hepatectomy in patients with colorectal liver metastases. *Surgery* 2003; 133:627–34.
- Tanaka K, Shimada H, Ohta M, et al. Procedures of choice for resection of primary and recurrent liver metastases from colorectal cancer. *World J Surg* 2004; 28:482–7.
- Sugawara G, Isogai M, Kaneoka Y, Suzuki M, Yamaguchi A. Repeat hepatectomy for recurrent colorectal metastases. *Surg Today* 2005; 35:282–9.
- Pessaux P, Lermite E, Brehant O, Tuech JJ, Lorimier G, Arnaud JP. Repeat hepatectomy for recurrent colorectal liver metastases. *J Surg Oncol* 2006; 93:1–7.
- Kato T, Yasui K, Hirai T, et al. Therapeutic results for hepatic metastasis of colorectal cancer with special reference to effectiveness of hepatectomy: analysis of prognostic factors for 763 cases recorded at 18 institutions. *Dis Colon Rectum* 2003; 46(10 suppl):S22–31.

24. Simmonds PC. Palliative chemotherapy for advanced colorectal cancer: systematic review and meta-analysis. Colorectal Cancer Collaborative Group. *BMJ* 2000; 321:531-5.
25. Tournigand C, Andre T, Achille E, et al. FOLFIRI followed by FOLFOX6 or the reverse sequence in advanced colorectal cancer: a randomized GERCOR study. *J Clin Oncol* 2004; 22:229-37.
26. Goldberg RM, Sargent DJ, Morton RF, et al. A randomized controlled trial of fluorouracil plus leucovorin, irinotecan, and oxaliplatin combinations in patients with previously untreated metastatic colorectal cancer. *J Clin Oncol* 2004; 22:23-30.
27. Okano K, Yamamoto J, Moriya Y, et al. Macroscopic intrabiliary growth of liver metastases from colorectal cancer. *Surgery* 1999; 126:829-34.
28. Kemeny N, Huang Y, Cohen AM, et al. Hepatic arterial infusion of chemotherapy after resection of hepatic metastases from colorectal cancer. *N Engl J Med* 1999; 341:2039-48.
29. Kemeny M. Hepatic artery infusion of chemotherapy as a treatment for hepatic metastases from colorectal cancer. *Cancer J* 2002; 8(suppl 1):S82-8.
30. Kemeny N, Eid A, Stockman J, et al. Hepatic arterial infusion of floxuridine and dexamethasone plus high-dose Mitomycin C for patients with unresectable hepatic metastases from colorectal carcinoma. *J Surg Oncol* 2005; 91:97-101.
31. Maindrault-Gocbel F, Louvet C, Andre T, et al. Oxaliplatin added to the simplified bimonthly leucovorin and 5-fluorouracil regimen as second-line therapy for metastatic colorectal cancer (FOLFOX6). GERCOR. *Eur J Cancer* 1999; 35:1338-42.
32. Adam R, Avisar E, Ariche A, et al. Five-year survival following hepatic resection after neoadjuvant therapy for nonresectable colorectal [liver] metastasis. *Ann Surg Oncol* 2001; 8:347-53.
33. Tanaka K, Adam R, Shimada H, Azoulay D, Levi F, Bismuth H. Role of neoadjuvant chemotherapy in the treatment of multiple colorectal metastases to the liver. *Br J Surg* 2003; 90:963-9.
34. Allen PJ, Kemeny N, Jarnagin W, DeMatteo R, Blumgart L, Fong Y. Importance of response to neoadjuvant chemotherapy in patients undergoing resection of synchronous colorectal liver metastases. *J Gastrointest Surg* 2003; 7:109-15; discussion 16-7.
35. Leonard GD, Brenner B, Kemeny NE. Neoadjuvant chemotherapy before liver resection for patients with unresectable liver metastases from colorectal carcinoma. *J Clin Oncol* 2005; 23:2038-48.
36. Nordlinger B, Sorbye H, Debois M, et al. Feasibility and risks of pre-operative chemotherapy (CT) with FOLFOX 4 and surgery for resectable colorectal cancer liver metastases (LM). Interim results of the EORTC Intergroup randomized phase III study 40983 (abstract). *J Clin Oncol* 2005; 23(16 suppl):3528.

大腸癌肝転移の治療方針と成績

安野 正道 杉原 健一

消化器外科 2006年7月 第29巻第8号 通巻第360号

へるす出版

大腸癌肝転移の治療方針と成績

Treatment strategies for colorectal cancer liver metastases

安野 正道* 杉原 健一**
Masamichi Yasuno Kenichi Sugihara

●要旨●肝転移の治療方針を決めるには、肝に限局した病期なのか、全身的に腫瘍が転移している時期なのかを考慮することが大切である。遠隔転移が肝に限局し、切除可能な場合は、手術切除がもっとも効果的であるので肝切除を行う。一方、肝外にも転移巣が拡大していると考えられれば、化学療法を中心とする集学的治療を行う。しかし、実際には、微小転移病変の診断、腫瘍の悪性度の判断などが難しく、治療方針の決定は容易でないこともしばしばある。肝切除の適応、治療成績、肝切除時期（原発巣と同時切除か異時切除か）について述べた。

●Key words● 大腸癌肝転移、肝切除、異時性肝転移

はじめに

肝転移は、大腸癌においてもっとも高頻度にみられる転移形式である。同時性に10%、異時性に15%と合わせて大腸癌の約25%に合併する。無治療例の1年生存率は30%程度である。肝転移の治療は大腸癌切除後生存期間の改善にとって、大変重要である。有名な大腸癌血行性転移のカスケード理論¹⁾、すなわち「大腸癌の大部分の症例では、まず肝に血行性転移が成立し、ある程度の大きさになるとそこから肺に転移する。さらに、肺から全身に癌細胞が散布される」に従えば、肝に転移が限局している時期に肝転移巣をすべて切除できれば、根治が可能と考えられる。逆に、肝にとどまらずに全身へ癌細胞が散布されている時期の肝転移に対しては、肝切除だけでは不十分である。肝転移の治療方針を決めるには、肝に限局した病期なのか、全身的に腫瘍が転移している時期なのかを考慮することが大切である。遠隔転移が肝に限局し、切除可能な場合は、手術切除がもっとも効果的であるので肝切除を行う。一方、肝外にも転移巣が拡大していると考えら

れば、化学療法を中心とする集学的治療を行う。しかし、実際には、微小転移病変の診断、腫瘍の悪性度の判断などが難しく、治療方針の決定は容易でないこともしばしばある。

本稿では、肝転移治療について、肝切除の適応、治療成績、肝切除時期（原発巣と同時切除か異時切除か）を中心に、自験例と文献的報告からの知見を述べさせて頂く。

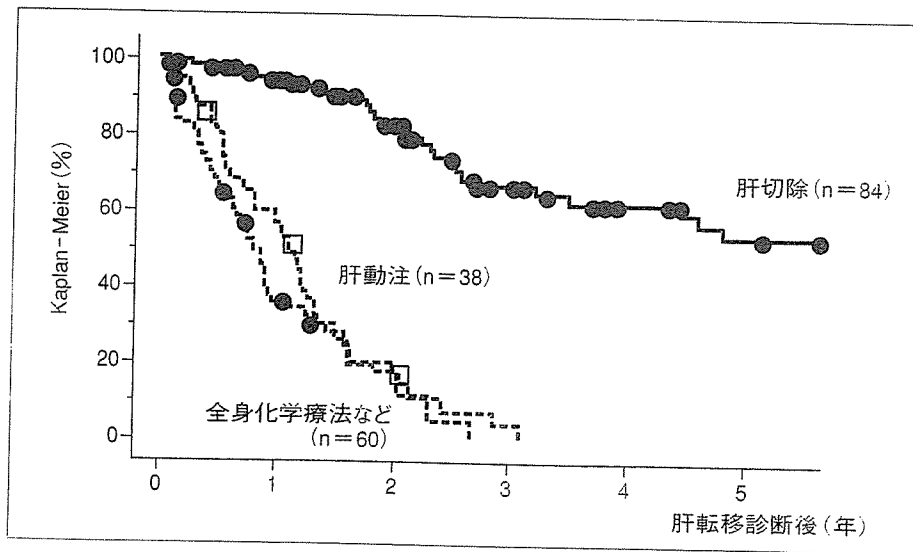
肝切除の治療成績

肝転移に対する肝局所治療効果は、肝切除、肝動注療法、全身化学療法の順である。図1に当科における治療別の生存曲線を示した。平成10年から4年間にわたり行われた厚生労働省がん助成金10-11「大腸がんの肝・肺転移例に対する治療法の確立に関する研究」班（主任研究者：加藤知行）で18施設から集積された大腸癌肝転移切除585症例の肝切除後3年生存率は52.8%で、5年生存率は39.2%であった²⁾。欧米の1990年以降の報告例では、肝切除後の5年生存率は、32~38%である^{3)~5)}。非切除例の50%生存期間は、進行度により異なるが6~16カ月である⁶⁾。

1980年以前は、単発肝転移例のみが肝切除の対象であったが、1980年代以降になると肝切除の適応が拡大

* 東京医科歯科大学大学院腫瘍外科学内講師

** 同教授



当科における大腸癌肝転移治療成績 (1992~2004)

され、肝転移巣が多発であっても、転移個数が4~5個程度までなら、肝切除が行われるようになった。集積された肝切除例の予後が解析され、多くの予後因子が報告されてきた。転移個数、分布(片葉か両葉)、最大径、肝門部リンパ節転移、脈管侵襲などの肝局所因子に加え、原発巣組織型や所属リンパ節転移、診断時期(同時性か異時性)、肝外病変の有無も予後因子として報告されている。しかし、報告ごとに予後因子としてのインパクトが異なり、現時点で肝切除の適応基準のコンセンサスは得られていない。安井らは厚生省がん研究・加藤班で集計された症例のうち、根治的肝切除が行われ、長期的経過観察が可能だった410例について、切除術式、手術時期、肝転移最大径、転移個数、同時・異時肝転移かなどを検討した。転移個数では4個以上のものが3個以下に比べ、肝転移最大径では4cm以上の症例が、それ未満の症例に比べて有意に不良であったという。

近年では、肝切除の適応は転移個数と大きさで決定する施設が多い。当科では、原則的には、①肝転移が肝に限局している、②十分な残肝機能を残して転移巣の完全切除が可能である、の条件が満たされる肝転移個数4個までを肝切除の適応としている⁷⁾。ただし、転移巣の数、大きさ、部位の正確な画像診断が大前提であることを強調したい。新しい『大腸癌取扱い規約』(第7版)で採用された肝転移の新分類は、肝転移最大径と個数の組み合わせからなる。H0H1H2H3に分類されて、H1は肝転移巣が4個以下かつ最大径5cm以下のもの、H3は肝転移巣5個以上かつ最大径が5cmを超えるもの、H2はH1、H3以外のもの、が定義で

ある。「大腸がんの肝・肺転移例に対する治療法の確立に関する研究」班(主任研究者:加藤知行)で集積された肝切除症例の生存曲線を、この新分類で示すと次のようになる。H1と比較して、H2とH3の予後は不良である。

他の手術以外の治療法と比べると、肝切除の治療効果は高いので、相当高度な肝転移に対しても、肝切除を行っている施設もある。肝外転移病変が同時にあっても、それが切除可能な、あるいは良好な制御が期待できる場合には(とくに肺)、肝切除によって、予後改善が期待できる症例もある⁹⁾。

肝切除後には残肝、肝外ともに再発が高率に起こる⁹⁾。肝切除後の残肝再発は、50%以上と高頻度である。残肝、肝外再発が各々30%、肝と肝外の両方の転移再発が30%に起こる。残肝再発に対して、再肝切除の成績が報告されてきた。初回肝切除と同様な適応、つまり、肝に転移が限局していて、十分な残肝機能を残して根治切除が可能であるなら、再肝切除により比較的良好的な予後が期待でき、再肝切除後の生存期間は、初回肝切除後の生存期間と同等であると報告されている¹⁰⁾。現在、残肝に出現した転移巣には、肝に限局している場合、積極的な再肝切除(時には3回以上)が行われている。

肝切除時期

同時性肝転移切除時期には、原発巣と同時に肝切除を行う同時切除と、原発巣切除後に、一定期間をおいて肝切除を行う異時切除の二つがある。同時切除派は、

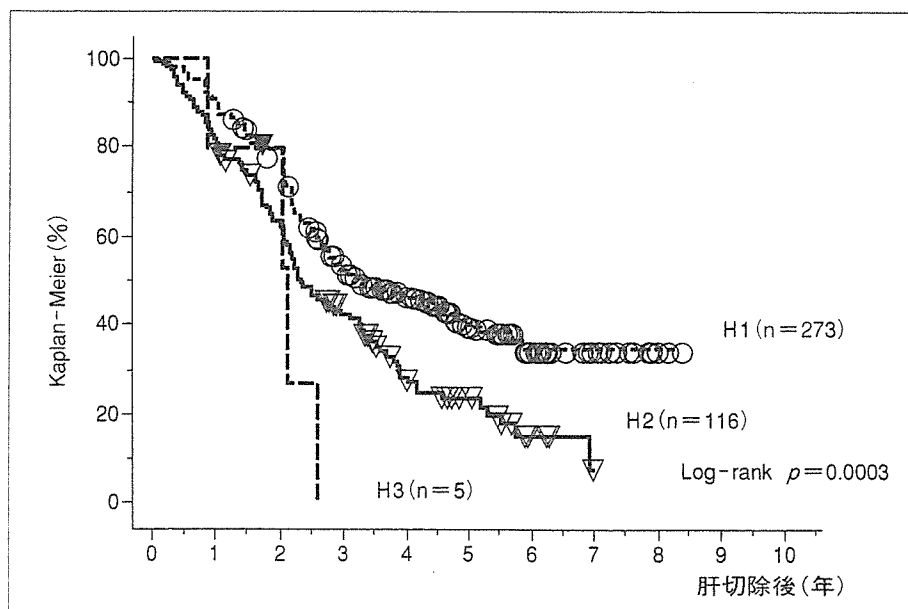


図2 肝転移新規約分類；肝転移診断後生存曲線

肝切除の待機中に、肝臓から2次的に肺を始めとする肝以外の全身の臓器へ転移を生じる可能性があると考えて、原発巣と同時に肝切除する。また、2期的切除より同時切除のほうが、1回の入院で済み、トータルの入院期間が短くなるメリットもあると考える。しかし、同時切除は原発巣切除に加え、肝切除も行うので、手術侵襲が大きくなり、術後合併症の頻度が高くなる可能性もある。

同時切除か異時切除かという議論のポイントは、当初、安全性から論じられ、近年では、同時性肝転移の悪性度という腫瘍学的側面から討論されている。しかし、結論はいまだ出ていない。この切除時期の問題は、重要である。文献的報告の歴史的な流れに沿って、切除時期に関する討論を述べたい。

1. 同時切除は術後合併症の危険を高めるか

大腸癌肝転移に対する肝切除が始められた頃の、1980年代の肝切除にかかわる合併症が多かった時期には、安全のため原発巣切除後に、2期的に肝転移巣を切除することが多かった。同時切除において、手術侵襲が大きいことや、肝切除のPringle操作の門脈血遮断で、腸管にうっ血浮腫をきたして、時には致死の合併症ともなる縫合不全率が高くなる危惧があった。Scheeleらは、28例の低位前方切除例を含む90例の同時切除例において、13例という高い頻度で縫合不全がみられて、そのうち2例が重篤な状態となって死亡したと報告した¹¹⁾。したがって、同時切除の場合は、部

分切除などの小さな術式のみが許容されると述べている。一方、Eliasらは、原発巣と肝転移の同時切除を行った53例—消化管の縫合箇所は76カ所、結腸・結腸19例、結腸・直腸9例、回腸・結腸5例、結腸・肛門4例(protective colostomy 4例造設)を含む—の縫合不全率を検討した¹²⁾。縫合不全は2カ所3%(小腸・小腸1例、結腸・結腸1例)にみられたのみで、肝切除を同時に行っても、縫合不全率は高くないと報告した。

2000年代に入ると、Martinら¹³⁾とLyassら¹⁴⁾の報告がある。Martinらは、同時性肝転移例に対して、原発巣と同時切除した136例と異時性切除を行った106例の術後合併症を比較した。同時性肝切除は、右側大腸癌、肝転移の数が少なく、最大径も小さい例が有意に多かったが、原発、肝切除をあわせた合併症率は、同時切除の49%に対し、異時切除の67%であった。合併症の重症度も重篤なものは少なく、肝、消化管の合併症の割合も同じパターンであった。また、区域切除以上の肝切除が行われた subgroup 症例で比較しても、有意に同時切除のほうに合併症が少なかったため、原発・肝同時切除は安全に行えると報告した。Lyassら¹⁴⁾も、原発巣の部位や肝転移程度にかかわらず、同時・異時切除で、合併症(25%程度)、出血量、入院期間は同等であったと報告している。手術手技と周術期管理が確立した現在、閉塞性大腸炎などの特別な合併症がなければ、原発巣と肝転移の同時切除は安全に行えるといつてよい。肝切除が技術的に安全に行われ