

μl or 5 $\mu\text{g}/5 \mu\text{l}$) or rhBMP-2 and ONO-4819 solution (3 $\mu\text{g}/3 \mu\text{l}$, 30 $\mu\text{g}/3 \mu\text{l}$, 300 $\mu\text{g}/3 \mu\text{l}$) and then fabricated into a disc (6 mm diameter, Fig. 2). In summary, 0, 3, 30, or 300 μg of ONO-4819 was mixed with the polymer plus 5 μg of rhBMP-2 and implanted into mice in each group (5 mice in each group and 1 implant/mouse). To examine the effects of ONO-4819 alone, 30 $\mu\text{g}/8 \mu\text{l}$ was added to the polymer without rhBMP-2. All procedures were carried out under sterile conditions. The implants were stored at -40°C in a freezer until required for implantation.

Experimental design

To examine the dose-dependent effects of the EP4 receptor agonist on ectopically induced bone formation by rhBMP-2, 50 mice were divided into 5 groups (10 mice per group). The mice were anesthetized by diethyl-ether gas inhalation, and the PLA–DX–PEG polymer discs prepared as described above were surgically implanted into the left dorsal muscle pouches (one pellet per animal) of the mice. In group 5, polymer discs containing 30 μg of ONO-4819, but no rhBMP-2, were implanted in the same manner.

1. 5 μg of rhBMP-2 per animal
2. 5 μg of rhBMP-2 and 3 μg ONO-4819 per animal
3. 5 μg of rhBMP-2 and 30 μg of ONO-4819 per animal
4. 5 μg of rhBMP-2 and 300 μg of ONO-4819 per animal
5. 30 μg of ONO-4819 per animal

At 1, 2, and 3 weeks after surgery, the body weight of each mouse was measured and recorded. Three weeks after surgery, the mice were sacrificed, and the implants were harvested and processed for histological analysis following morphological and radiological examination.

Radiological and histological analyses for rhBMP-2 induced ectopic bone

All harvested tissues were radiographed with a soft X-ray apparatus (Sofron Co., Ltd., Tokyo, Japan). The bone mineral content (BMC) (milligrams per ossicle) of each ossicle was measured by dual-energy X-ray absorptiometry (DXA) using a bone mineral analyzer (DCS-600EX, Aloka Co., Tokyo). The ossicles or tissue mass from each group was then fixed in neutralized 10% formalin, decalcified with K-CX (Fujisawa Pharmaceutical Co., Ltd. Japan), dehydrated in gradient ethanol series, and embedded in paraffin wax. Sections of 3 μm thickness were cut, stained with hematoxylin–eosin, and observed under a light microscope.

Bone metabolic markers in mice

To investigate the anabolic effects of ONO-4819 on systemic bone metabolism, an additional 60 mice were divided into 3 groups as follows: sham-operated mice that received sham operation and lacking implants (10 mice per group), group 1: 5 μg of rhBMP-2 per animal (5 mice per group) and group 3; 5 μg of rhBMP-2 and 30 μg of ONO-4819 per animal (5 mice per group). Blood samples were collected from mice of each group at 1, 2, and 3 weeks. The samples were stored at -80°C until biochemical analysis. Serum osteocalcin was measured by immunoradiometric assay (IRMA) using a commercial kit (Immutopics, Inc. San Clemente, CA) according to the manufacturer's instructions. Total alkaline phosphatase (ALP) activity, calcium (Ca), and phosphate (P) in serum were also measured in each group with commercially available kits.

Statistical analysis

Data are presented as mean \pm SE. The degree of significance was determined by post hoc testing using the




Fig. 2. PLA–DX–PEG polymer disc. Photograph of 6-mm-diameter PLA–DX–PEG polymer disc. The polymer has a hard sticky gel-like property at room temperature and softens when heated to 50°C .

Bonferroni method. An associated probability (P value) of <0.05 was considered significant.

Results

Body weight changes in animals

In our previous experiments, mice that received systemic injection of an excessive dose (100 $\mu\text{g}/\text{kg}$) of ONO-4819 every 8 h for 3 weeks showed a significant decline in body weight gain. In the current experiments, no significant difference in body weight gain was noted among the groups that received implants with or without local release of ONO-4819 (Fig. 3).

Radiological and histological evaluations

Pieces of hard tissue were harvested from the implantation sites of mice from groups 1, 2, 3, and 4 at 3 weeks after implantation. In group 5 (ONO-4819, 30 μg without BMP-2), no evidence of hard tissue formation was found at the implantation sites. On soft X-ray radiograms, the calcified samples retrieved from the mice revealed a trabecular network encased within a shell-shaped bone layer (Fig. 4). Histological sections of these samples showed normal characteristics of bone with trabeculae and hematopoietic marrow in the inter-trabecular space, findings that were also common to ossicles from groups 1, 2, 3, and 4. (Fig. 5) Radiological images indicated that the ossicles from group 3 (rhBMP-2, 5 μg + ONO-4819, 30 μg) and 4 (rhBMP-2, 5 μg + ONO-4819, 300 μg) were larger than those observed from control group 1 (rhBMP-2, 5 μg without ONO-4819).

On DXA analysis, the bone mineral content (BMC) of the ossicles containing ONO-4819 increased in a dose-dependent manner (3, 30, and 300 μg groups were 9.36 ± 1.89 mg, 14.21 ± 1.27 mg, and 18.75 ± 2.31 mg, respectively) Ossicles from group 1 mice (without ONO-4819) had a BMC of 6.52 ± 0.80 mg. In terms of BMC, the values of groups 3 and 4 were significantly higher than those of group 1. The mean BMC value of group 4 (BMP-2, 5 μg + ONO-4819, 300 μg) ossicles was approximately 3 times higher than that of the control group (Fig. 6).

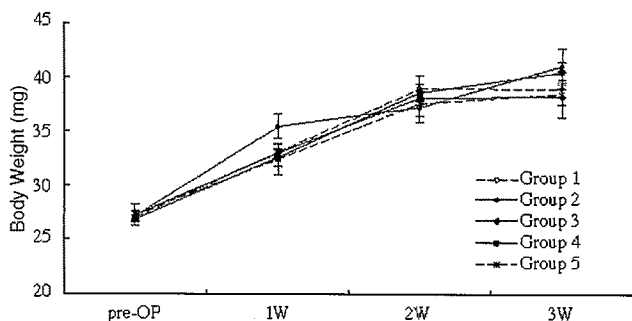


Fig. 3. Body weight. No significant difference in body weight was noted among the groups with implants with or without ONO-4819.

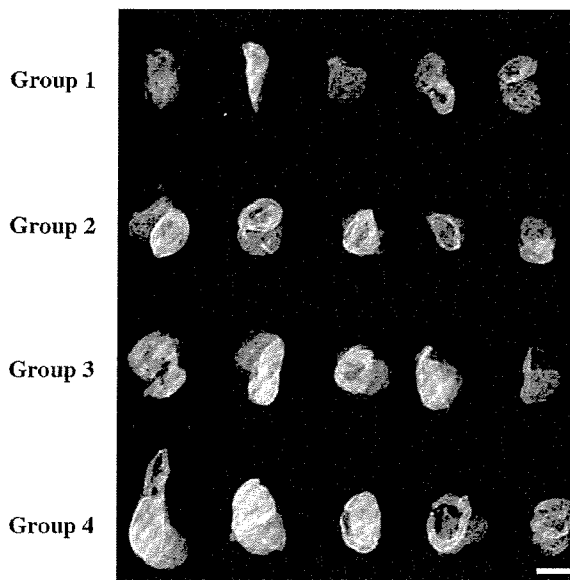


Fig. 4. Radiographic findings. Soft X-ray photograph of the ossicles harvested at 3 weeks after implantation (bar = 5 mm). A typical implant from each group is shown (groups 1, 2, 3, and 4). Both the radio-opaque areas and radiological densities of the ossicles on the radiogram were larger in groups 3 and 4 than in control group 1.

Serum osteocalcin and ALP activity assay

At 1 week, both serum osteocalcin (299.8 ± 24.4 ng/ml) and ALP activity (495.2 ± 32.0 IU/l) levels significantly increased in group 3 compared to the sham-operated animals (osteocalcin 208.6 ± 25.6 ng/ml, ALP activity 356.0 ± 39.8 IU/l). At 2 weeks, serum ALP activity (439.0 ± 76.8 IU/l) levels had increased significantly when compared to the sham-operated animals (ALP activity 313.2 ± 12.1 IU/l) (Fig. 7A). However, there were no significant differences among the groups at 3 weeks after implantation (Fig. 7B). In addition, there was no significant increase in serum calcium and phosphate level among them at any time point (data not shown). No significant changes in serum osteocalcin and ALP levels from the baseline were recorded in the groups that received implants containing ONO-4819.

Discussion

Based on these data, EP4A was examined for its ability to enhance BMP-induced bone formation and improve rhBMP-2 performance. In our previous study, systemic subcutaneous injections of the EP4A (ONO-4819) for 3 weeks increased bone mass induced by rhBMP-2 and caused a decline in body weight gain in the experimental animals [13]. To achieve the anabolic action and avoid the systemic adverse effect, low doses of the drug were added to the degradable polymer carrying the rhBMP-2 and implanted into the host mice. In this study, in a very encouraging response, ONO-4819 significantly increased the BMP-induced bone mass in dose-dependent manner

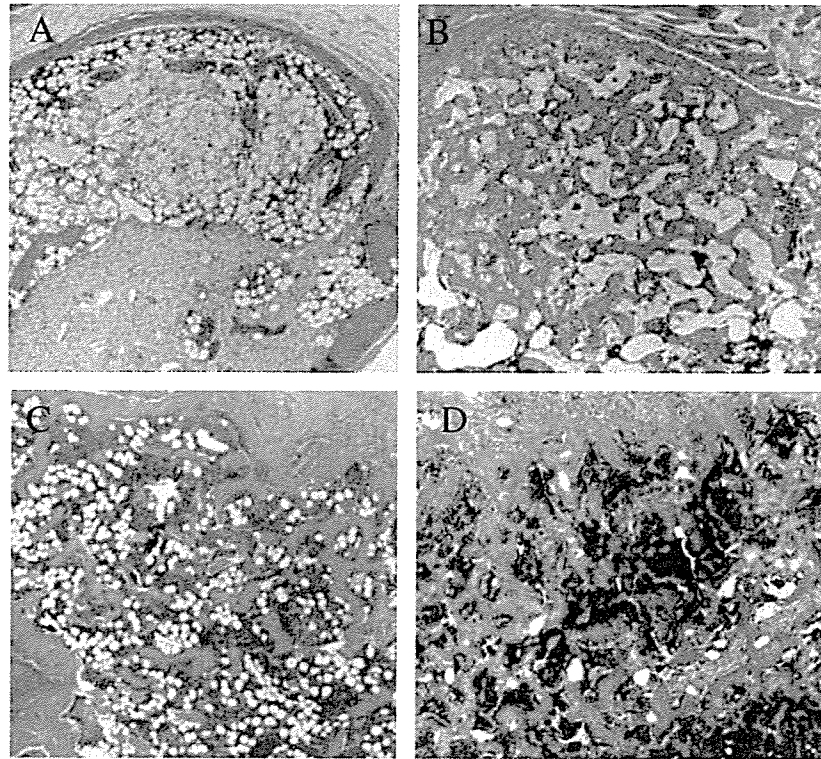


Fig. 5. Histology. Histological sections of the ossicles at 3 weeks after implantation are shown (hematoxylin–eosin stain; original magnification $\times 40$). (A) group 1: 5 μg of rhBMP-2, (B) group 2: 5 μg of rhBMP-2 and 3 μg of ONO-4819, (C) group 3: 5 μg of rhBMP-2 and 30 μg of ONO-4819, (D) group 4: 5 μg of rhBMP-2 and 300 μg of ONO-4819. New bone formation with hematopoietic marrow and bony trabeculae was visible in the rhBMP-2-induced ossicles. In groups 3 and 4, there were visible increases in the number and thickness of bony trabeculae when compared to the ossicles from group 1.

without significant body weight loss. The total dose of ONO-4819 required for a doubling of the BMP-induced bone mass was reduced when compared to the dose required using consecutive systemic administration (3 injections/day for 3 weeks) of the drug.

Enhanced bone formation by systemic administration of the EP4A over an experimental period of 3 weeks was essentially reproduced by the local release of the agent over the first week following implantation. This is the period when young mesenchymal cells most likely migrate, proliferate, and infiltrate the BMP/polymer composite implants before new bone formation gets underway

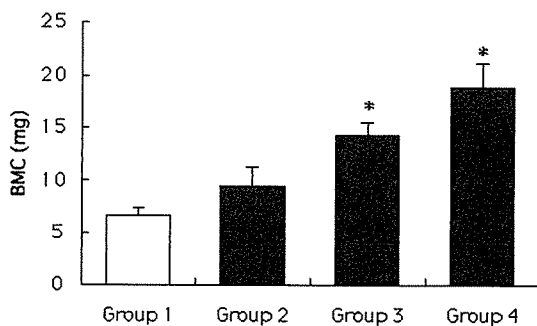


Fig. 6. Bone mineral content. The bone mineral content (BMC) of the ossicles at 3 weeks after implantation. BMC of ossicles was dose-dependently higher in groups 2, 3, and 4 than those in the group 1. Data expressed as mean \pm SE. *Significantly different from controls ($P < 0.05$).

[7,9,10]. It is possible that these young mesenchymal cells were responsible for the bone formation enhanced by EP4A. Therefore, a low dose of the EP4A, ONO-4819, delivered locally and concurrently with rhBMP enhanced new bone formation and significantly increased bone mass. The effective period of local release of the EP4A is not greater than 2 weeks based on the degradation rate of the polymer [9,10]. Therefore, one possible explanation for the bone mass increased by EP4A is that EP4A works first in osteoblast precursors with a potential for chondro-osseous differentiation in the early phase of the bone-forming reaction. In the previous study, due to identifying the time phase when ONO-4819 exerts its pharmacological effects, EP4A was systemically administered for 1 week over pre (–1–0 week), initial (0–1 week), middle (1–2 week), or late (2–3 week) phase, respectively. The anabolic effects of EP4A were seen in mice that received EP4A exclusively in the initial phase. This result might also indicate that EP4A and BMP work cooperatively to stimulate osteoblastic differentiation in its early stage at the interface to the BMP-retaining pellets. Previous *in vitro* studies support our consideration. Suda et al. reported that EP2/EP4 seems to be involved in osteoblastic differentiation, and EP1/EP3 is likely to be associated with their proliferation [35]. Weinreb et al. described that PGE₂ stimulates osteoblastic differentiation through an anabolic effect in rat bone marrow cultures mediated by activation of EP4, probably

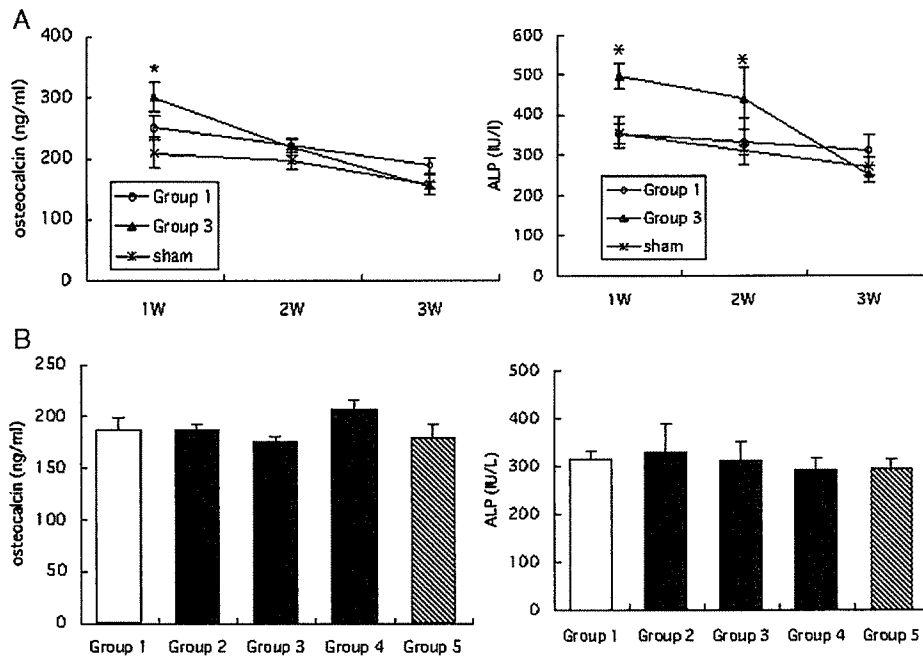


Fig. 7. Serum osteocalcin and ALP. Serum osteocalcin and ALP levels. (A) Serum osteocalcin and total ALP activity from group 3 with rhBMP-2 and ONO-4819 pellets were significantly increased compared to the sham group at 1 week. Total ALP activity from group 3 with rhBMP-2 and ONO-4819 pellets was significantly increased compared to the sham group at 2 weeks. (B) There were no significant differences in serum osteocalcin and ALP levels among the groups at 3 weeks after implantation.

by recruiting noncommitted osteogenic precursors [36,37]. Yoshida et al. described that PGE₂ induced the expression of core-binding factor alpha-1 (Runx2/Cbfa1) and enhanced the formation of mineralized nodules in a culture of bone marrow cells from wild-type mice, both of which were absent in a culture of cells from EP4 knockout mice. EP4 activation increased the number of Runx2 positive cells [30]. EP4 exerts this effect by inducing osteoblast differentiation. On the other hand, several studies indicate that EP4 is essential for PGE₂-induced bone resorption. Suzawa et al. described that, in mouse calvaria cultures, EP4A markedly stimulated bone resorption, and in calvaria culture from EP4 knockout mouse, a marked reduction in bone resorption to PGE₂ was found. EP4A induced cAMP production and the expression of osteoclast differentiation factor mRNA in osteoblastic cells [27]. Stimulation of osteoclastogenesis in cocultures of osteoblasts and spleen cells in response to PGE₂ is markedly decreased when the osteoblasts are derived from cells lacking the EP4 receptor [26–29]. These *in vitro* studies indicate that PGE₂-EP4 signaling works first in osteoblast precursors to induce osteoblast for bone formation and then works in mature osteoblasts to induce osteoclasts on newly formed bone. Further studies are required to elucidate the detailed mechanism of action of the EP4 receptor agonist in *in vitro* systems using less differentiated osteogenic cells.

The anabolic effect of PGE₂ on bone was exhibited through the activation of EP2 or EP4 and consequent elevation of intracellular cAMP level [23]. In this respect, the action of an EP4 agonist may be similar to that of PTH,

PDE-4, which also promotes bone formation and intercellular cAMP accumulation. Daily subcutaneous injection of parathyroid hormones (PTH) is known to enhance systemic bone formation, and daily systemic injection of phosphodiesterase-4 (PDE-4)-selective inhibitor, rolipram, can enhance BMP-2-dependent ectopic new bone formation in mice [11,38]. Although the detailed mechanisms of cAMP signal on bone formation have been unclear, these results might indicate that cAMP functionally has a key role in the regulation of the BMP action in osteoblast differentiation, and further studies are required.

Another possible mechanism of the anabolic effect of EP4A on the BMP-induced bone formation comes from studies involving cyclooxygenase-2 (COX-2). Zhang et al. showed the complementary effect of BMP-2 in a bone marrow cell culture from COX-2 knockout mice and suggested that BMP-2 is a target gene for PGE₂-induced bone formation [39]. Chikazu et al. reported that BMP-2 transcriptionally induces COX-2 expression, which in turn regulates, via the Runx2 binding site, production of PGE₂ and promotion of osteoblastic differentiation [40]. These results indicate that BMP and PGE₂ might have complementary or cooperative anabolic effects on mesenchymal cells to stimulate the early phase of osteoblastic differentiation.

Potent bone anabolic activity of EP4A is expected from clinical application for fractures and bone defects in patients. Development of a more effective way of exposing responding cells and tissues to EP4A is likely to be needed for cost effectiveness, clinical efficacy, and long-term safety.

In cases with a longer fracture healing time, such as in humans, a carrier might be necessary for the sustained release of EP4A to be effective. The property of this polymer would allow retention of rhBMP-2 for a period that is significant to elicit new bone formation and thereby provide a scaffold for further bone growth. Retention of the proteins at the implantation site for a sufficient period to promote progenitor cell migration and cell proliferation has been shown to enhance osteoinductive activity. Our results show that local administration of ONO-4819 using PLA–DX–PEG polymer can mimic the local bone anabolic effect of PGE₂ without an excessive dose. The ability to deliver a molecule so that it will induce a specific biologic effect is critical to the success of pharmacological agent therapy.

In conclusion, a new EP4 receptor agonist compound (ONO-4819) can enhance the bone-inducing activity of rhBMP-2 when administered using a local polymer-based carrier with no apparent systemic adverse effects. This compound may be a useful tool for enhancing the performance of rhBMP-2. This could have a significant impact on the costs associated with using this therapeutic cytokine for bone regeneration and repair in clinical practice. Further safety checks are required before ONO-4819 can be used for this purpose.

Acknowledgments

This work was supported in part by a Grant-in-Aid from the Ministry of Education, Culture, Sports, Science and Technology of Japan (Project Grant No. 12137203) and by grants from the Ministry of Health, Labor and Welfare of Japan.

References

- [1] Urist MR. Bone: formation by autoinduction. *Science* 1965;150:893–9.
- [2] Wozney JM, Rosen V, Celeste AJ, Mitsock LM, Whitters MJ, Kriz RW, et al. Novel regulators of bone formation: molecular clones and activities. *Science* 1988;242:1528–34.
- [3] Boden SD, Zdeblick TA, Sandhu HS, Heim SE. The use of rhBMP-2 in interbody fusion cages. Definitive evidence of osteoinduction in humans: a preliminary report. *Spine* 2000;25:376–81.
- [4] Boden SD, Kang J, Sandhu H, Heller JG. Use of recombinant human bone morphogenetic protein-2 to achieve posterolateral lumbar spine fusion in humans: a prospective, randomized clinical pilot trial: 2002 Volvo Award in clinical studies. *Spine* 2002;27:2662–73.
- [5] Burkus JK, Gomet MF, Dickman CA, Zdeblick TA. Anterior lumbar interbody fusion using rhBMP-2 with tapered interbody cages. *J Spinal Disord Tech* 2002;15:337–49.
- [6] Johnsson R, Stromqvist B, Aspenberg P. Randomized radiostereometric study comparing osteogenic protein-1 (BMP-7) and autograft bone in human noninstrumented posterolateral lumbar fusion. *Spine* 2002;27:2654–61.
- [7] Miyamoto S, Takaoka K, Okada T, Yoshikawa H, Hashimoto J, Suzuki S, et al. Evaluation of polylactic acid homopolymers as carriers for bone morphogenetic protein. *Clin Orthop* 1992;278:274–85.
- [8] Murakami N, Saito N, Horiuchi H, Okada T, Nozaki K, Takaoka K. Repair of segmental defects in rabbit humeri with titanium fiber mesh cylinders containing recombinant human bone morphogenetic protein-2 (rhBMP-2) and a synthetic polymer. *J Biomed Mater Res* 2002;62:169–74.
- [9] Saito N, Okada T, Horiuchi H, Murakami N, Takahashi J, Nawata M, et al. A biodegradable polymer as a cytokine delivery system for inducing bone formation. *Nat Biotechnol* 2001;19:332–5.
- [10] Saito N, Okada T, Horiuchi H, Ota H, Takahashi J, Murakami N, et al. Local bone formation by injection of recombinant human bone morphogenetic protein-2 contained in polymer carriers. *Bone* 2003;32:381–6.
- [11] Horiuchi H, Saito N, Kinoshita T, Wakabayashi S, Yotsumoto N, Takaoka K. Effect of phosphodiesterase inhibitor-4, rolipram, on new bone formations by recombinant human bone morphogenetic protein-2. *Bone* 2002;30:589–93.
- [12] Kinoshita T, Kobayashi S, Ebara S, Yoshimura Y, Horiuchi H, Tsutsumimoto T, et al. Phosphodiesterase inhibitors, pentoxifylline and rolipram, increase bone mass mainly by promoting bone formation in normal mice. *Bone* 2000;27:811–7.
- [13] Sasaoka R, Terai H, Toyoda H, Imai Y, Sugama R, Takaoka K. A prostanoïd receptor EP4 agonist enhances ectopic bone formation induced by recombinant human bone morphogenetic protein-2. *Biochem Biophys Res Commun* 2004;318:704–9.
- [14] Bergmann P, Schoutens A. Prostaglandins and bone. *Bone* 1995;16:485–8.
- [15] Kawaguchi H, Pilbeam CC, Harrison JR, Raisz LG. The role of prostaglandins in the regulation of bone metabolism. *Clin Orthop* 1995;313:36–46.
- [16] Raisz LG, Vanderhoek JY, Simmons HA, Kream BE, Nicolaou KC. Prostaglandin synthesis by fetal rat bone in vitro: evidence for a role of prostacyclin. *Prostaglandins* 1979;17:905–14.
- [17] Jee WSS, Ueno K, Deng YP, Woodbury DM. The effects of prostaglandin E2 in growing rats: increased metaphyseal hard tissue and cortico-endosteal bone formation. *Calcif Tissue Int* 1985;37:148–57.
- [18] Sone K, Tashiro M, Fujinaga T, Tomomasa T, Tokugawa K, Kuroume T. Long-term low-dose prostaglandin E1 administration. *J Pediatr* 1980;97:866–7.
- [19] Yang RS, Liu TK, Lin-Shiau SY. Increased bone growth by local prostaglandin E2 in rats. *Calcif Tissue Int* 1993;52:57–61.
- [20] Coleman RA, Kennedy I, Sheldrick RL. New evidence with selective agonists and antagonists for the subclassification of PGE2-sensitive (EP) receptors. *Adv Prostaglandin Thromboxane Leukotriene Res* 1987;17:467–70.
- [21] Coleman RA, Smith WL, Narumia S. Classification of prostanoid receptors: properties distribution, and structure of the receptors and their subtypes. *Pharmacol Rev* 1994;46:205–29.
- [22] Hizaki H, Segi E, Sugimoto Y, Hirose M, Saji T, Ushikubi F, et al. Abortive expansion of the cumulus and impaired fertility in mice lacking the prostaglandin E receptor subtype EP(2). *Proc Natl Acad Sci U S A* 1999;96:10501–6.
- [23] Narumiya S, Sugimoto Y, Ushikubi F. Prostanoid receptors: structures, properties, and functions. *Physiology* 1999;79:1193–226.
- [24] Segi E, Sugimoto Y, Yamasaki A, Aze Y, Oida H, Nishimura T, et al. Patent ductus arteriosus and neonatal death in prostaglandin receptor EP4-deficient mice. *Biochem Biophys Res Commun* 1998;246:7–12.
- [25] Ushikubi F, Segi E, Sugimoto Y, Murata T, Matsuoka T, Kobayashi T, et al. Impaired febrile response in mice lacking the prostaglandin E receptor subtype EP3. *Nature* 1998;395:281–4.
- [26] Sakuma Y, Tanaka K, Suda M, Yasoda A, Natsui K, Tanaka I, et al. Crucial involvement of the EP4 subtype of prostaglandin E receptor in osteoclast formation by proinflammatory cytokines and lipopolysaccharide. *J Bone Miner Res* 2000;15:218–27.
- [27] Suzawa T, Miyaura C, Inada M, Maruyama T, Sugimoto Y, Ushikubi F, et al. The role of prostaglandin E receptor subtypes (EP1, EP2, EP3, and EP4) in bone resorption: an analysis using specific agonists for the respective EPs. *Endocrinology* 2000;14:1554–9.

- [28] Miyaura C, Inada M, Suzawa T, Sugimoto Y, Ushikubi F, Ichikawa A. Impaired bone resorption to prostaglandin E2 in prostaglandin E receptor EP4-knockout mice. *J Biol Chem* 2000;275:19819–23.
- [29] Li X, Pilbeam CC, Pan L, Breyer RM, Raisz LG. Effects of prostaglandin E2 on gene expression in primary osteoblastic cells from prostaglandin receptor knockout mice. *Bone* 2002;30:567–73.
- [30] Yoshida K, Oida H, Kobayashi T, Maruyama T, Tanaka M, Katayama T, et al. Stimulation of bone formation and prevention of bone loss by prostaglandin E EP4 receptor activation. *Proc Natl Acad Sci U S A* 2002;99:4580–5.
- [31] Machwate M, Harada S, Leu CT, Seedor G, Labelle M, Gallant M, et al. Prostaglandin receptor EP (4) mediates the bone anabolic effects of PGE (2). *Mol Pharmacol* 2001;60:36–41.
- [32] Shamir D, Keila S, Weinreb M. A selective EP4 receptor antagonist abrogates the stimulation of osteoblast recruitment from bone marrow stromal cells by prostaglandin E2 in vivo and in vitro. *Bone* 2004;34:157–62.
- [33] Tanaka M, Sakai A, Uchida S, Tanaka S, Nagashima M, Katayama T, et al. Prostaglandin E2 receptor (EP4) selective agonist (ONO-4819.CD) accelerates bone repair of femoral cortex after drill-hole injury associated with local upregulation of bone turnover in mature rats. *Bone* 2004;34:940–8.
- [34] Murakami N, Saito N, Takahashi J, Ota H, Horiuchi H, Nawata M, et al. Repair of a proximal femoral bone defect in dogs using a porous surfaced prosthesis in combination with recombinant BMP-2 and a synthetic polymer carrier. *Biomaterials* 2003;24:2153–9.
- [35] Suda M, Tanaka K, Natsui K, Usui T, Tanaka I, Fukushima M, et al. Prostaglandin E receptor subtypes in mouse osteoblastic cell line. *Endocrinology* 1996;137:1698–705.
- [36] Weinreb M, Grosskopf A, Shir N. The anabolic effect of PGE2 in rat bone marrow cultures is mediated via the EP4 receptor subtype. *Am J Physiol* 1999;276:376–83.
- [37] Shamir D, Keila S, Weinreb M. A selective EP4 receptor antagonist abrogates the stimulation of osteoblast recruitment from bone marrow stromal cells by prostaglandin E2 in vivo and in vitro. *Bone* 2004;34:157–62.
- [38] Neer RM, Arnaud CD, Zanchetta JR, Prince R, Gaich GA, Reginster JY, et al. Effect of parathyroid hormone (1–34) on fractures and bone mineral density in postmenopausal women with osteoporosis. *N Engl J Med* 2001;44:1434–41.
- [39] Zhang X, Schwarz EM, Young DA, Puzas JE, Rosier RN, O’Keefe RJ. Cyclooxygenase-2 regulates mesenchymal cell differentiation into the osteoblast lineage and is critically involved in bone repair. *J Clin Invest* 2002;109:1405–15.
- [40] Chikazu D, Li X, Kawaguchi H, Sakuma Y, Voznesensky OS, Adams DJ, et al. Bone morphogenetic protein 2 induces cyclo-oxygenase 2 in osteoblasts via a Cbfa1 binding site: role in effects of bone morphogenetic protein 2 in vitro and in vivo. *J Bone Miner Res* 2002;17:1430–40.

Experimental Spinal Fusion With Recombinant Human Bone Morphogenetic Protein-2 Delivered by a Synthetic Polymer and β -Tricalcium Phosphate in a Rabbit Model

Takashi Namikawa, MD,* Hidetomi Terai, MD, PhD,* Eisuke Suzuki, MD, PhD,*
Masatoshi Hoshino, MD,* Hiromitsu Toyoda, MD,* Hiroaki Nakamura, MD, PhD,*
Shimpei Miyamoto, MD, PhD,* Naoyuki Takahashi, PhD,† Tadashi Ninomiya, PhD,† and
Kunio Takaoka, MD, PhD*

Experimental Spinal Fusion With Recombinant Human Bone Morphogenetic Protein-2 Delivered by a Synthetic Polymer and β -Tricalcium Phosphate in a Rabbit Model

Takashi Namikawa, MD,* Hidetomi Terai, MD, PhD,* Eisuke Suzuki, MD, PhD,* Masatoshi Hoshino, MD,* Hiromitsu Toyoda, MD,* Hiroaki Nakamura, MD, PhD,* Shimpei Miyamoto, MD, PhD,* Naoyuki Takahashi, PhD,† Tadashi Ninomiya, PhD,† and Kunio Takaoka, MD, PhD*

Study Design. An experimental animal study to achieve posterolateral intertransverse process spine fusion with recombinant bone morphogenetic protein in combination with a new delivery system.

Objective. To evaluate the efficacy of a new synthetic biodegradable bone-inducing material containing recombinant human bone morphogenetic protein-2 (rhBMP-2) as a bone-graft substitute for posterolateral intertransverse process fusion in a rabbit model.

Summary of Background Data. rhBMP-2, a powerful bone-inducing cytokine, has been used as a bone graft substitute in combination with animal-derived collagen to achieve spinal fusion in animal models. However, the minimum dose of rhBMP-2 required to obtain solid posterolateral intertransverse process fusion was high on the basis of previous reports (>100 μ g in rabbit models). To improve the efficacy, performance of rhBMP-2, and the safety of the delivery system for this protein, a more sophisticated system is required.

Methods. To fabricate one implant for one-side L4-L5 intertransverse process fusion, β -tricalcium phosphate (β -TCP) powder (300 μ g), a polymer gel (PLA-DX-PEG block copolymer, 300 μ g) and rhBMP-2 (7.5, 15, or 30 μ g) were mixed and manually shaped to resemble a rod. Through a posterolateral approach, two implants were placed on both sides (1 per side) by surgery so as to bridge the transverse processes of adult New Zealand white rabbits ($n = 27$). In control animals, implants without rhBMP or autogenous cortico-cancellous bone chips from the iliac

crest were placed in a similar location. The lumbar vertebrae were recovered 6 weeks after surgery. The posterolateral fusion was examined by manual palpation, radiography, biomechanical testing, and histology.

Results. Rabbits that received 15 or 30 μ g of rhBMP-2 showed consistent fusion. However, solid fusion was seen in 2 of 5 rabbits with autografting and rabbits that received 7.5 μ g of rhBMP-2. Fusion was not observed in the rabbits that did not receive rhBMP-2.

Conclusions. Consistent spinal fusion was obtained by implanting a biodegradable bone-inducing implant composed of β -TCP, PLA-DX-PEG, and rhBMP-2 within a period of 6 weeks. The rhBMP-2 doses required for the spinal fusion were significantly lower than those reported previously.

Key words: animal model, bone induction, posterolateral lumbar spine fusion, recombinant human bone morphogenetic protein-2. **Spine 2005;30:1717-1722**

Anterior or posterior fusion with autogenous bone grafting is a routine method for the treatment of spinal disorders associated with spinal instability resulting from degenerative changes, tumor resection, or trauma to the spine. To restore permanent stability of the spine, local new bone formation bridging the neighboring unstable vertebrae is essential. Autogenous iliac bone grafting is commonly used to promote bone formation. However, autogenous bone grafting is limited by some issues that remained unsolved. These are physical or cosmetic morbidities such as acute and chronic pain or dysesthesia, the potential risk for wound infection, extensive skin scarring, and deformity at the donor site.^{1,2} In addition, the limited available mass of graft bone is also a disadvantage. To overcome these issues, new methods or materials that can substitute for the autogenous bone grafts have been desired. Allogeneic bone graft or banked bone is one of the alternatives that have been considered. However, banked bone has less osteogenic potential than autograft, and there is a potential risk for immunologic reaction from hosts and disease transfer to host with this material.^{3,4} Biomaterials such as hydroxyapatite and bioactive ceramics also have been tested as bone-graft substitutes to avoid the potential risks arising from the use of allografts. Unfortunately, materials with osteoconductive potential but no osteoinductive capacity cannot substitute for autograft. Therefore, new materials

From the * Department of Orthopaedic Surgery, Osaka City University Graduate School of Medicine, Osaka, Japan; †Division of Hard Tissue Research, Institute for Oral Science, Matsumoto Dental University, Nagano, Japan

Acknowledgment date: August 23, 2004. First revision date: September 2, 2004. Acceptance date: September 3, 2004.

Supported in part by a grant-in-aid from the Ministry of Education, Culture, Sports, Science and Technology of Japan (project Grants 16790853 and 16109009).

The legal regulatory status of the device(s)/drug(s) that is/are the subject of this manuscript is not applicable in my country. The device(s)/drug(s) that is/are the subject of this manuscript is/are not FDA-approved for this indication and is/are not commercially available in the United States.

Federal funds were received in support of this work. No benefits in any form have been or will be received from a commercial party related directly or indirectly to the subject of this manuscript.

Address correspondence and requests for reprints to Hidetomi Terai, MD, Department of Orthopaedic Surgery, Graduate School of Medicine, 1-4-3 Asahi-machi Abeno-ku, Osaka City, Osaka, 545-8585, Japan.

with a potent osteoinductive capacity are required to avoid the disadvantages of autograft and to secure enhanced new bone formation for solid spinal fusion.

To manufacture an osteoinductive artificial bone graft substitute, cytokines retaining osteoinductive activity (bone morphogenetic proteins, BMPs) have been combined with biocompatible implant materials and used to obtain spinal fusion in experimental animals or in limited number of human cases.⁵⁻¹⁵ To elicit the BMP-induced bone formation, a carrier material that delivers BMP slowly to the target cells is essential. As a carrier material, animal-derived collagen has been used routinely both in animal experiments and in clinical settings despite the potential risks for immunologic reaction in the host and transfer of diseases such as bovine spongiform encephalopathy (BSE).^{16,17} To avoid those risks, we synthesized biodegradable polymers which work more effectively as the carrier for BMP-2 in *in vivo* conditions than bovine-derived collagen.^{18,19} By use of this BMP delivery system, critical size defects in the long bones of rabbits and dogs were repaired successfully. New bone formation was achieved with these new porous solid biomaterials, which remained unresorbed in hosts.^{20,21}

In this study, we attempted to achieve posterolateral intertransverse process spine fusion in the rabbit model by use of a biodegradable polymer and β -TCP composite as a delivery system for BMP. In this system, a successful outcome would be bone formation and the complete resorption of the carrier materials at the implanted sites.

Materials and Methods

rhBMP-2. rhBMP-2 was produced at Genetics Institute (Cambridge, MA) and donated to us through Astellas Pharma Inc. (Ibaraki, Japan).

PLA-DX-PEG Polymer. Poly-D,L-lactic acid with a random insertion of *p*-dioxanone/polyethylene glycol block copolymer (PLA-DX-PEG, MW; 12,400, LA/DX/EO molar ratio; 42:14:44), was provided by Taki Chemical (Kakogawa, Japan). The chemical formula of the PLA-DX-PEG is shown in Figure 1. We have reported that this polymer worked effectively as a carrier for rhBMP in previous studies. Details of the physicochemical characteristics and efficacy as a carrier material for rhBMP-2 have been reported elsewhere.^{18,19} The minimal efficacious content of rhBMP-2 in the synthetic polymer required to elicit new bone formation in rabbits was approximately 0.02%.²⁰

β -TCP Powder. β -TCP powder (less than 100 μ m in diameter of particles) was manufactured and provided to us by Olympus Biomaterial (Tokyo, Japan).

Preparation of New Bone Graft Substitute Implants. To prepare one implant (Figure 2A) to bridge L5 and L6 transverse

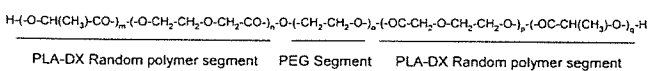


Figure 1. Structural formula of PLA-DX-PEG. The subscripts m, n, o, p, q represent variable number of units.

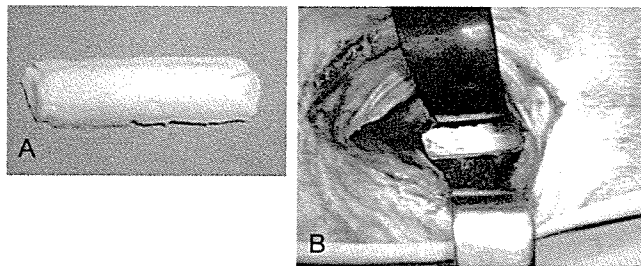


Figure 2. A, Prepared β -TCP dough implant. B, β -TCP dough was placed on the L5-L6 intertransverse region.

processes on one side, 300 mg of β -TCP powder, 300 mg of PLA-DX-PEG, and 3 dosages of rhBMP (7.5, 15, or 30 μ g) were mixed and stirred with a metal rod at 50°C for several minutes. The resultant dough was then cooled and fabricated by hand to resemble a rod. The hardened rods were stored at -30°C until implantation. As control implants, 300 mg of β -TCP powder and 300 mg of PLA-DX-PEG without rhBMP-2 was prepared in the same manner.

Surgery and Experimental Protocols. Twenty-seven New Zealand white rabbits (age, 1-2 years-old; weight, 3.5-4.5 kg) were divided randomly into five groups depending on the material to be implanted into the intertransverse process space. Before surgery, the animals were anesthetized with an intramuscular injection of ketamine (30 mg/kg) and xylazine (10 mg/kg). Cefazolin (100 mg) was administered subcutaneously as a prophylactic antibiotic. Each rabbit underwent surgery for a single level posterolateral intertransverse process fusion at L5-L6.⁷ A dorsal midline skin incision was made, followed by two paramedian fascial incisions. The intermuscular plane between the multifidus and longissimus muscles was retracted to expose the transverse processes of L5 and L6 and the intertransverse membrane. An electric-driven burr (Stryker, Kalamazoo, MI) was used to decorticate posterior cortex of the respective transverse process, and one of the implant or transplant materials listed in Table 1 was implanted (Figure 2B). The wounds were then closed with 3-0 absorbable and 3-0 nylon sutures. Cefazolin (100-mg once daily) was administered to the respective animal subcutaneously for 3 days after surgery. The animals were killed by overdose of anesthetics at 6 weeks after surgery, and the L4-L7 lumbar spines were harvested and processed for further examination. This protocol was approved by the Institutional Committee for Animal Care and Experiments of Osaka City University Medical School.

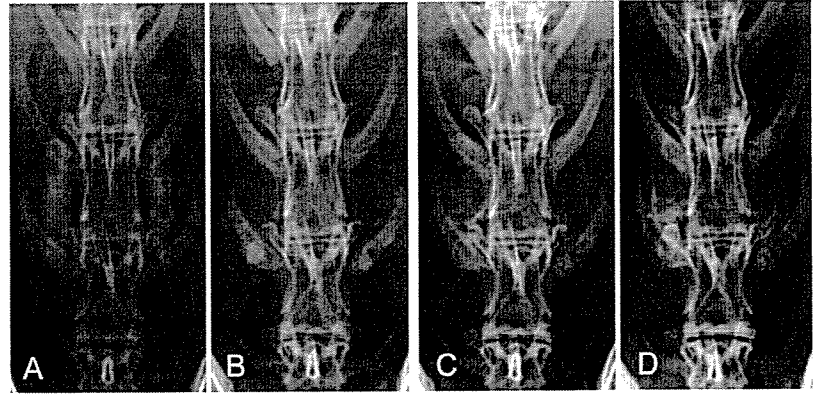
Radiographic Evaluation. The L5-L6 spines from each group animals were examined by posteroanterior plain radio-

Table 1. Implant Assignment

Group	rhBMP-2 (μ g)	β -TCP (mg)	PLA-DX-PEG (mg)	Concentration of rhBMP-2 (wt%)	n
BMP 30	30	300	300	0.005	5
BMP 15	15	300	300	0.0025	6*
BMP 7.5	7.5	300	300	0.00125	5
BMP 0	0	300	300	0	6*
Autogenous bone	Autogenous iliac bone graft (1-1.5 g)				5

* Each one is for histological evaluation.

Figure 3. Representative posteroanterior radiographs of rabbit spines in the BMP 30 group, immediately after surgery (A), at 2 weeks (B), at 4 weeks (C), and at 6 weeks (D). In the radiograph, a remarkable fusion mass is visible between the L5–L6 transverse process at 6 weeks.



graphs and computed tomographic (CT) scans (GE Yokogawa Medical System, Tokyo, Japan) sequentially at 2, 4, and 6 weeks after surgery. CT images of 2-mm slice thickness were used to construct three-dimensional images. From the harvested lumbar spine samples, soft tissues were removed, and plain radiographs and CT images were taken again. A radiologic evaluation for intertransverse process fusion was made by three observers in a blinded fashion. Fusion was graded as solid when two of the three observers agreed that the presence and location of new bone formation were consistent with a successful fusion outcome.

Manual Palpation. The harvested lumbar spines were manually palpated by flexion and extension at the fusion level and comparison with the adjacent level. Each motion segment was graded as solid fusion or not solid.

Biomechanical Testing. Biomechanical testing to evaluate the solidity of the L5–L6 fusion site was performed by a three-point flexion-bending test using a materials testing machine (Instron 5882, Instron, Boston, MA). Three-point bending tests were performed with a 30-mm intersupport distance and a 1 mm/minute head speed. The bending moment at 1.5-mm middle-span deflection was determined from the moment-deflection curves.

Histologic Examination. The harvested specimens were fixed in 10% formalin in neutral buffer solution and decalcified in 10% formic acid solution, dehydrated in a gradient ethanol series, and embedded in paraffin. Sections of 4- μ m thickness at the intertransverse process region were cut in a sagittal plane, stained with hematoxylin and eosin, and observed under a light

microscope to examine for bony fusion between the newly formed bone and the original transverse processes.

Statistical Analysis. Comparisons of biomechanical testing of spines in each group were made using one-way analysis of variance. The post hoc Scedge test was performed to determine significant differences between groups. Significance for all tests was defined as $P < 0.05$.

■ Results

Radiographic Evaluation

An opaque shadow of β -TCP was noted at the operated site on radiographs immediately after surgery. Radiographs at 6 weeks showed homogeneous calcified shadows between the transverse processes in all animals of the BMP15, BMP30, and in part of the BMP7.5 groups. (Figures 3–5) Representative three-dimensional CT images of each group are shown in Figure 6. Fusion assessments in three-dimensional CT were difficult because the images tend to overestimate the fusion mass. Results of the evaluation from plain radiographs and three-dimensional CT are shown in Table 2.

Manual Palpation

In all samples of the BMP 15 and BMP 30 groups, bony hard masses at the intertransverse process were palpable, and the passive motion between the vertebrae was significantly restricted when compared with that in control samples. Two of the five samples from the BMP 7.5 and autogenous bone groups, respectively, were evaluated as

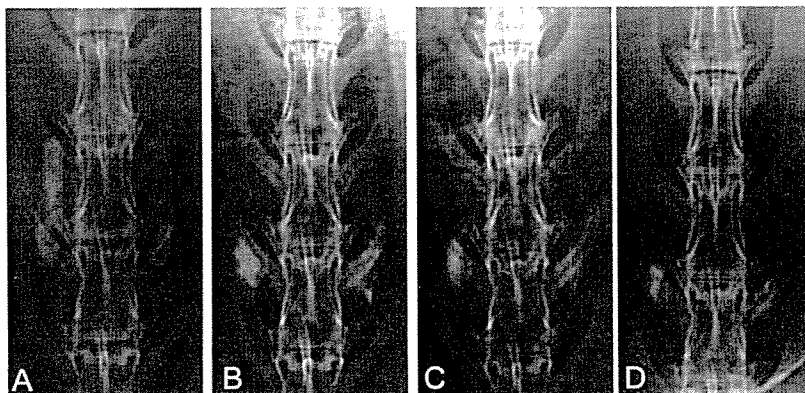


Figure 4. Representative posteroanterior radiographs of rabbit spines in the BMP 0 group, immediately after surgery (A), at 2 weeks (B), at 4 weeks (C), and at 6 weeks (D). In the radiograph, no fusion mass between the L5–L6 transverse process is visible.

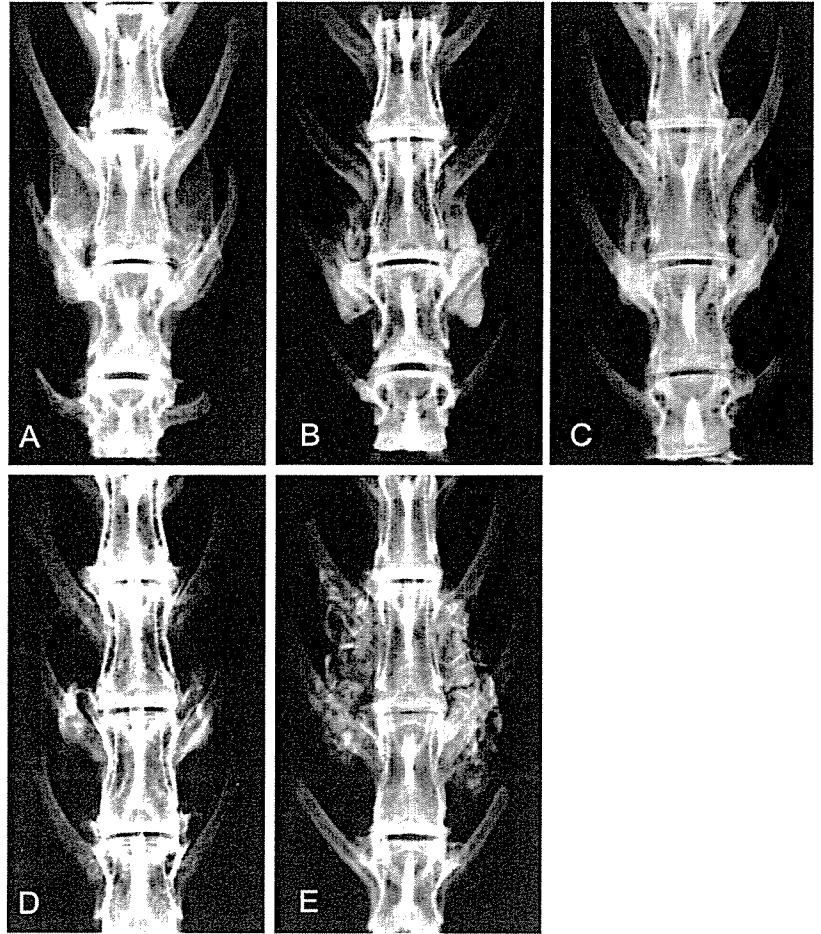


Figure 5. Harvested lumbar spine 6 weeks after surgery. BMP30 (A), BMP15 (B), BMP7.5 (C), BMP0 (D), autogenous bone (E).

solid fusion outcomes. In contrast, none of the samples from the BMP 0 groups achieved solid fusion (Table 3).

Biomechanical Testing

The results from biomechanical testing in each of the experimental groups are shown in Figure 7. The bending

moment at 1.5-mm middle-span deflection of the BMP 15 and BMP 30 groups were significantly larger than the BMP 0 group. The mean values in the BMP30 and BMP15 groups were higher than those from the autogenous bone group and the control BMP 0 group.

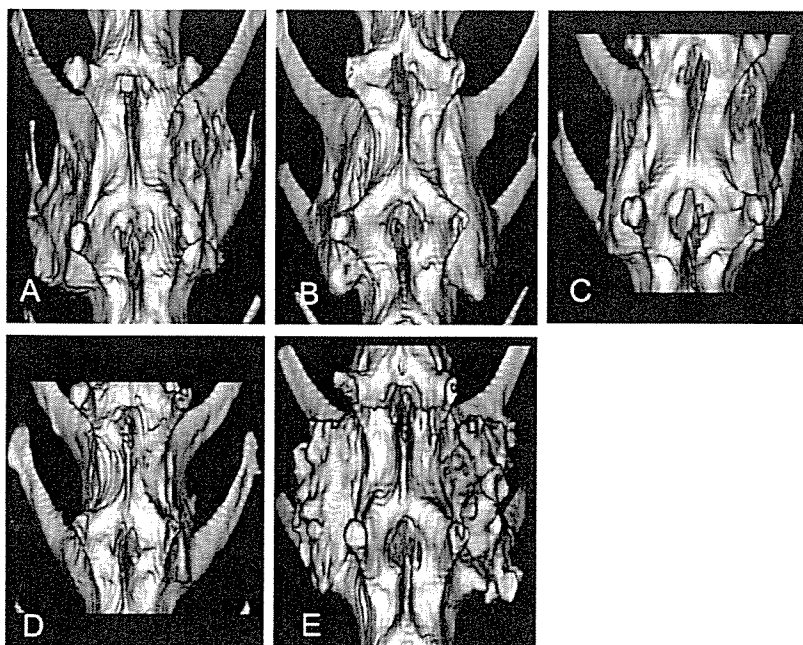


Figure 6. Three-dimensional-CT at 6 weeks after surgery. BMP30 (A), BMP15 (B), BMP7.5 (C), BMP0 (D), autogenous bone (E).

Table 2. Fusion Rate in Radiological Assessments

Group	Plain X-p	Three-Dimensional CT
BMP 30	5/5	5/5
BMP 15	5/5	5/5
BMP 7.5	4/5	4/5
BMP 0	0/5	0/5
Autogenous bone	5/5	5/5

Histologic Examination

Lower magnification views of sagittal sections (hematoxylin and eosin staining) of fusion mass in animals that received rhBMP-2 showed bone mass with peripheral cortical bone bridging the transverse processes. Higher magnification of the bridging bone mass revealed woven bone and hematopoietic marrow. Tiny remnants of the β -TCP powder were also recognized. However, the intertransverse region sampled in a spine that did not receive rhBMP-2 revealed fibrous tissue and remnants of β -TCP with no evidence of new bone formation (Figure 8).

Discussion

The present study was designed to test a synthetic and absorbable bone-graft substitute with osteoinductive ability equivalent or superior to the autogenous bone graft. The test was conducted in a critical bone defect model wherein the successful outcome was a solid posterolateral intertransverse process fusion. The results in this study were satisfactory, and in all animals with β -TCP (300 mg)/PLA-DX-PEG (300 mg) composite implants with 15 or 30 μ g of rhBMP-2, solid spinal fusion was obtained in 6 weeks. In the autogenous bone graft group, new bone formation was consistently recognized on radiographs, but in some specimens retrieved from the rabbits, failure of fusion was noted during biomechanical tests. It is interesting to note that in some clinical cases, the pseudarthrosis rate of posterolateral spine fusion has ranged from 5 to 35%.^{22,23} These results are encouraging and point to the need for further clinical testing of this synthetic composite implant. The avoidance of additional surgery to harvest graft bone and thereby eliminate donor site morbidities is a potential key benefit of this approach.

In considering the practical application of the rhBMP retaining implants, one of the remaining issues is the extremely high dose of rhBMP required to elicit new bone, especially in humans. Typically, several milligrams of rhBMP are necessary for one level spinal fusion, and this fact results in a high cost of the BMP-retaining im-

Table 3. Fusion Rate in Manual Palpation

Group	Solid Fusion
BMP 30	5/5
BMP 15	5/5
BMP 7.5	2/5
BMP 0	0/5
Autogenous bone	2/5

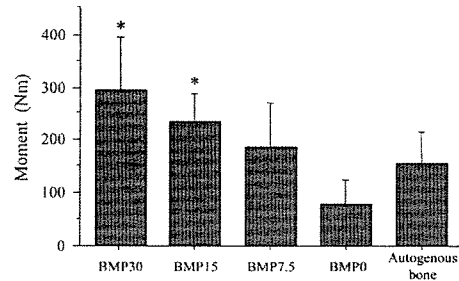
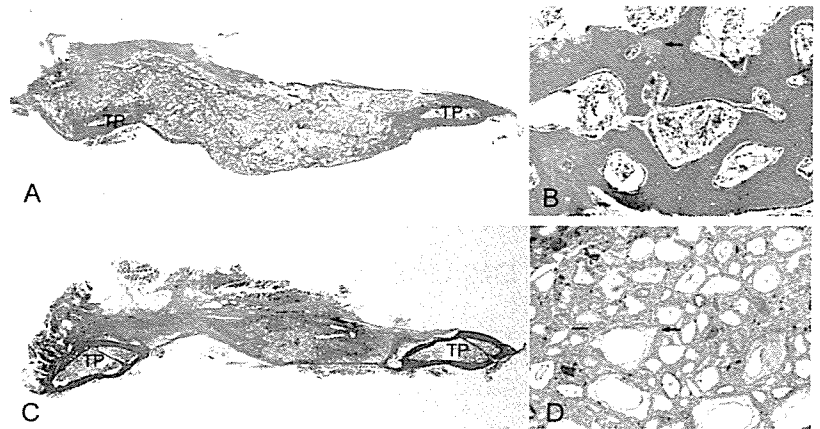


Figure 7. Results of three-point flexion bending tests for each specimen. These results indicate the fusion sites of BMP 30 and BMP 15 groups are stiffer than BMP 0 group. *, statistically significant difference from BMP 0 group.

plant.⁶ To reduce the cost, a more effective method to deliver efficacious but lower doses of rhBMP-2 would be desired. In previous experimental studies of the rabbit posterolateral intertransverse process spine fusion model, >100 μ g of rhBMP-2 were required to achieve the solid one-level spine fusion in 5 or 6 weeks. This was accomplished by the use of either animal-derived collagen sheets, hydroxyapatite with collagen, an open cell polylactic acid polymer, or sintered bovine bone as the delivery system for rhBMP-2.^{5,10,12-15} Interestingly, in this study, the minimal effective dose of rhBMP-2 was significantly lower (15–30 μ g) than the amounts used in previous studies. Those prior experiments were not reproduced in this study; therefore, a direct comparison of the minimal effective dose of rhBMP is difficult. However, our results suggest an advantage of this new delivery system to reduce the effective dose of rhBMP for spinal fusion. The use of β -TCP powder to construct the bone-inducing implants provides three advantages; 1) the addition of the β -TCP powder to the “sticky” PLA-DX-PEG resulted in a dough-like material with easy handling and molding characteristics, 2) a volume expansion of the implant by addition of β -TCP powder, and 3) resorption of the β -TCP powder by osteoclasts recruited during the BMP-induced bone formation phase and disappears after establishment of spinal fusion. In our previous study in mice, it was noted that the β -TCP granules coated with the rhBMP-2-retaining polymer (PLA-DX-PEG) elicited ectopic new bone in situ at 3 weeks. β -TCP encased within the ectopic ossicles was resorbed by a large population of osteoclasts attached on the surface.²⁴ As expected in the current study, the β -TCP powder was almost completely resorbed and replaced by new bone with marrow on histologic findings at 6 weeks after surgery.

In summary, a new bone-inducing and biodegradable implant was produced by combining three synthetic materials (PLA-DX-PEG, rhBMP-2, and β -TCP). Posterolateral intertransverse process fusion was successfully achieved in a rabbit model with this implant in 6 weeks. The fusion rate appeared to exceed that obtained by autogenous bone grafting. These data provide support for the use of this new biomaterial as a substitute for autogenous bone grafting. The avoidance of the need for and

Figure 8. Hematoxylin and eosin stained sagittal section of L5–L6 intertransverse region in BMP 15 (A,B) and BMP 0 (C,D) group. New bone formation between the L5–L6 transverse process (TP), the cortical rim around fusion mass, and tiny residual β -TCP (arrow) was seen in BMP 15 group. The specimen from the group that did not receive rhBMP-2 showed no new bone formation between the L5–L6 transverse process (A and C, $\times 0.5$, B and D, $\times 10$).



risks associated with surgery for graft material procurement is an additional benefit. Additional preclinical study involving nonhuman primates will be required to evaluate the utility and safety of this implant for spine fusion.

Key Points

- The efficacy of the β -TCP/PLA-DX-PEG composite that contained low doses of rhBMP-2 was evaluated in a New Zealand White rabbit posterolateral lumbar intertransverse process fusion model.
- Rabbits that received 15 or 30 μ g of rhBMP-2 on each side, which is a significantly lower efficacious dose than previously reported, achieved solid fusion within 6 weeks in all experimental animals.
- This new synthetic biodegradable bone-inducing material could reduce the dose of rhBMP-2 required to achieve solid fusion with no residual trace of the implant.
- The current study demonstrated the potential of the new material as a substitute for autogenous bone graft material in spine fusion. This material obviates the need for bone graft procurement and thereby reduces the risk of morbidity often associated with this surgery.

References

1. Arrington ED, Smith WJ, Chambers HG, et al. Complications of iliac crest bone graft harvesting. *Clin Orthop* 1996;300–9.
2. Kurz LT, Garfin SR, Booth RE Jr. Harvesting autogenous iliac bone grafts. A review of complications and techniques. *Spine* 1989;14:1324–31.
3. Buck BE, Malinin TI, Brown MD. Bone transplantation and human immunodeficiency virus. An estimate of risk of acquired immunodeficiency syndrome (AIDS). *Clin Orthop* 1989;129–36.
4. Leads from the MMWR. Transmission of HIV through bone transplantation: case report and public health recommendations. *JAMA* 1988;260:2487–8.
5. Akamaru T, Suh D, Boden SD, et al. Simple carrier matrix modifications can enhance delivery of recombinant human bone morphogenetic protein-2 for posterolateral spine fusion. *Spine* 2003;28:429–34.
6. Boden SD, Kang J, Sandhu H, et al. Use of recombinant human bone morphogenetic protein-2 to achieve posterolateral lumbar spine fusion in humans: a prospective, randomized clinical pilot trial: 2002 Volvo Award in clinical studies. *Spine* 2002;27:2662–73.
7. Boden SD, Schimandle JH, Hutton WC. An experimental lumbar intertransverse process spinal fusion model. Radiographic, histologic, and biomechanical healing characteristics. *Spine* 1995;20:412–20.
8. David SM, Gruber HE, Meyer RA Jr, et al. Lumbar spinal fusion using recombinant human bone morphogenetic protein in the canine. A comparison of three dosages and two carriers. *Spine* 1999;24:1973–9.
9. Grauer JN, Patel TC, Erulkar JS, et al. 2000 Young Investigator Research Award winner. Evaluation of OP-1 as a graft substitute for intertransverse process lumbar fusion. *Spine* 2001;26:127–33.
10. Itoh H, Ebara S, Kamimura M, et al. Experimental spinal fusion with use of recombinant human bone morphogenetic protein 2. *Spine* 1999;24:1402–5.
11. Johnsson R, Stromqvist B, Aspenberg P. Randomized radiostereometric study comparing osteogenic protein-1 (BMP-7) and autograft bone in human noninstrumented posterolateral lumbar fusion: 2002 Volvo award in clinical studies. *Spine* 2002;27:2654–61.
12. Konishi S, Nakamura H, Seki M, et al. Hydroxyapatite granule graft combined with recombinant human bone morphogenetic protein-2 for solid lumbar fusion. *J Spinal Disord Tech* 2002;15:237–44.
13. Minamide A, Kawakami M, Hashizume H, et al. Evaluation of carriers of bone morphogenetic protein for spinal fusion. *Spine* 2001;26:933–9.
14. Sandhu HS, Kanim LE, Kabo JM, et al. Effective doses of recombinant human bone morphogenetic protein-2 in experimental spinal fusion. *Spine* 1996;21:2115–22.
15. Schimandle JH, Boden SD, Hutton WC. Experimental spinal fusion with recombinant human bone morphogenetic protein-2. *Spine* 1995;20:1326–37.
16. Butler D. Last chance to stop and think on risks of xenotransplants. *Nature* 1998;391:320–4.
17. DeLustro F, Dasch J, Keefe J, et al. Immune responses to allogeneic and xenogeneic implants of collagen and collagen derivatives. *Clin Orthop* 1990;263–79.
18. Saito N, Okada T, Horiuchi H, et al. A biodegradable polymer as a cytokine delivery system for inducing bone formation. *Nat Biotechnol* 2001;19:332–5.
19. Saito N, Takaoka K. New synthetic biodegradable polymers as BMP carriers for bone tissue engineering. *Biomaterials* 2003;24:2287–93.
20. Murakami N, Saito N, Horiuchi H, et al. Repair of segmental defects in rabbit humeri with titanium fiber mesh cylinders containing recombinant human bone morphogenetic protein-2 (rhBMP-2) and a synthetic polymer. *J Biomed Mater Res* 2002;62:169–74.
21. Murakami N, Saito N, Takahashi J, et al. Repair of a proximal femoral bone defect in dogs using a porous surfaced prosthesis in combination with recombinant BMP-2 and a synthetic polymer carrier. *Biomaterials* 2003;24:2153–9.
22. DePalma AF, Rothman RH. The nature of pseudarthrosis. *Clin Orthop* 1968;59:113–8.
23. Steinmann JC, Herkowitz HN. Pseudarthrosis of the spine. *Clin Orthop* 1992;80–90.
24. Matsushita N, Terai H, Okada T, et al. A new bone-inducing biodegradable porous beta-tricalcium phosphate. *J Biomed Mater Res* 2004;70A:450–8.

Repair of an intercalated long bone defect with a synthetic biodegradable bone-inducing implant

Masahiro Yoneda^a, Hidetomi Terai^{a,*}, Yuuki Imai^a, Takao Okada^b, Kazutoshi Nozaki^c, Hikaru Inoue^d, Shimpei Miyamoto^a, Kunio Takaoka^a

^aDepartment of Orthopaedic Surgery, Osaka City University School of Medicine, 1-4-3 Asahi-machi, Abeno-ku, Osaka 545-8585, Japan

^bResearch Department, R&D Division, Taki Chemical Co., LTD., 64-1 Nishiwaki, Befu-cho, Kakogawa-shi, Hyogo 675-0125, Japan

^cApplied Pharmacology Laboratories, Institute for Drug Discovery Research, Yamanouchi Pharmaceutical Co., Ltd., 21 Miyukiqaoka, Tsukuba, Ibaraki 305-8585, Japan

^dOlympus Co., Ltd., 2-3 Kuboyamacho, Hachioji city, Tokyo 192-8512, Japan

Received 1 August 2004; accepted 23 January 2005

Abstract

Recombinant human bone morphogenetic protein (rhBMP)-2 in a block copolymer composed of poly-D,L-lactic acid with randomly inserted *p*-dioxanone and polyethylene glycol (PLA-DX-PEG) as a carrier and porous β -tricalcium phosphate (β -TCP) blocks were used to generate a new fully absorbable osteogenic biomaterial. The bone regenerability of the rhBMP-2/PLA-DX-PEG/ β -TCP composite was studied in a critical-sized rabbit bone defect model. In an initial study, a composite of PLA-DX-PEG (250 mg) and β -TCP (300 mg) loaded with or without rhBMP2 (50 μ g) was implanted into a 1.5 cm intercalated bone defect created in a rabbit femur. Defects were assessed by biweekly radiography until 8 weeks postoperatively. The bony union of the defect was recognized only in the BMP-loaded group. To obtain further data on biomechanical and remodeling properties, another BMP-loaded composites group was made and observed up to 24 weeks. All defects were completely repaired without residual traces of implants. Anatomical and mechanical properties of the repaired bone examined by histology, 3-dimensional CT (3D-CT) and mechanical testing were essentially equivalent to the nonoperated-on femur at 24 weeks. These experimental results indicate that fully absorbable rhBMP-2/PLA-DX-PEG/ β -TCP is a promising composite having osteogenicity efficient enough for repairing large bone defects.

© 2005 Elsevier Ltd. All rights reserved.

Keywords: BMP (bone morphogenetic protein); Bone tissue engineering; Biodegradation; Osteoconduction; Drug delivery; Calcium phosphate

1. Introduction

The long history of orthopedic practice has confirmed the efficacy of autogenous bone grafting, but significant problems such as donor site morbidity and the limited supply associated with autogenous bone harvesting remain. To overcome these problems, a variety of osteoconductive biomaterials, e.g., ceramics and titanium alloys, have been considered as bone graft substitutes [1,2]. Experience to date with osteoconductive

biomaterials suggests that these can be made in greater quantities, would improve biomechanical strength, and present no concerns with immunogenicity [3]. These osteoconductive biomaterials are already efficacious in repairing unloaded bone cavities or small bone defects where an efficient osteogenic cell supply can be anticipated. Repairing large loaded bone defects using osteoconductive biomaterials alone remains a challenge, however, because osteogenic cells are not likely to be recruited without osteoinductivity in the center of large defects, and the lack of absorbability presents an obstacle to remodeling necessary to withstand repetitive mechanical loading. These considerations led us to conclude that biomaterials used to repair large bone

*Corresponding author. Tel.: +81 6 6645 3851;

fax: +81 6 6646 6260.

E-mail address: hterai@med.osaka-cu.ac.jp (H. Terai).

defects should be completely biodegradable and have good osteoconduction and osteoinduction.

Among biodegradable and osteoconductive biomaterials such as synthetic porous polymers (poly[L-lactide-co-glycolide] copolymer (PLGA)) and tricalcium phosphates, porous beta-tricalcium phosphate (β -TCP) has proved most popular in current orthopedic surgery. Porous β -TCP has interconnected pores, which aid in infiltrating osteogenic cells, and is strong enough to maintain implant shape during bone formation [4]. β -TCP, as well as natural bone matrix, is mainly absorbed by cells positive for tartrate-resistant acid phosphatase (TRAP) and is replaced by newly formed bone. Reports have also confirmed its osteoconductivity and degradability at orthotopic sites [5].

Osteoinductivity is currently added to biomaterials three main ways: (1) applying cultured osteogenic cells from autologous bone marrow (cell-based), (2) applying osteoinductive cytokines (cytokine-based), and (3) applying osteoinductive genes [6–8]. We used the cytokine-based approach because of its promising clinical application since several human osteoinductive cytokines have been produced by recombinant techniques [9].

Bone morphogenetic proteins (BMPs) are biologically active osteoinductive cytokines with significant clinical potential, but the lack of a delivery system enabling full osteoinduction has precluded their wider implementation in clinical therapeutics [10]. Ideal delivery should be synthetic to avoid the disease transmission possible with allogenic materials. Current carrier materials for BMPs, such as collagen sponges and hydroxyapatite, show successful bone formation *in vivo*, but require a high BMP dose because of their inability to retain BMPs [11,12]. Another requirement for ideal delivery is thus controlled BMP release enabling the amount of BMPs required for bone repair to be reduced by ensuring effective BMP retention in reactive cells. For this, we developed a synthetic block copolymer composed of poly-D,L-lactic acid with randomly inserted *p*-dioxanone and polyethylene glycol (PLA-DX-PEG), reported to deliver BMPs effectively [13–15].

To this end, we used porous β -TCP and recombinant human BMP-2 (rhBMP-2) with PLA-DX-PEG to generate a new, fully absorbable osteogenic biomaterial for repairing loaded large bone defects. We evaluated the efficacy of rhBMP-2/PLA-DX-PEG/ β -TCP composite in bone induction and degradability using a critical-sized intercalated rabbit bone defect model.

2. Materials and methods

2.1. Materials

Porous β -TCP cylinders of OSferion[®] 6 mm in diameter, 5 mm high, and weighing approximately

100 mg were manufactured and donated (Olympus Biomaterials Co., Ltd., Tokyo, Japan) for the purpose of these studies. Pores were 100–400 μ m in size, porosity was 75%, and the sintering was at 1050° [4]. rhBMP-2 produced at the Genetics Institute (Cambridge, MA) and donated through Yamanouchi Pharmaceutical Co., Ltd. (Ibaraki, Japan), was dissolved in a buffer of 5 mM glutamic acid, 2.5% glycine, 0.5% sucrose, and 0.01% Tween 80 at a concentration of 1 μ g/ μ l. As a rhBMP-2 delivery system, a block copolymer of poly-D,L-lactic acid with randomly inserted *p*-dioxanone and polyethylene glycol (PLA-DX-PEG; MW 9,600; PLA/DX/PEG molar ratio 43/14/43) was synthesized and provided by Taki Chemical Co., Ltd. (Kakogawa, Japan). The physicochemical properties and efficacy of the rhBMP-2 carrier material are detailed elsewhere [13–15]. We determined the minimal optimal rhBMP-2 content in the synthetic polymer required to elicit new bone formation to be approximately 0.02% (wt/wt) in rabbits from previous experiments [16–18].

2.2. Preparation of implants

To combine polymer and rhBMP-2, 250 mg of polymer was dissolved in 3 ml of distilled acetone and 50 μ g of rhBMP in 0.01N HCl was mixed in a glass vial. Three porous β -TCP cylinders were then submerged in the mixed solution and placed in a vacuum for a few seconds to replace air in β -TCP cylinder pores with solvent. Acetone was then removed with a centrifuge evaporator. The glass vials were shaken several times during evaporation to thoroughly impregnate cylinders with the rhBMP-2 delivery material. Treated porous β -TCP cylinders were coated with the rhBMP-2/PLA-DX-PEG composite (50 μ g of rhBMP2, 250 mg of PLA-DX-PEG, and 300 mg of β -TCP (3 cylinders) for each defect). Implants were kept in a freezer at -30°C until use. Control implants were β -TCP cylinders coated with PLA-DX-PEG without rhBMP-2 prepared the same way as above.

2.3. Scanning electron microscopy (SEM)

The surface of porous β -TCP blocks was observed by scanning electron microscopy (SEM; Hitachi 4700SI) to ensure that the pore surface was coated by rhBMP-2/PLA-DX-PEG homogeneously (Fig. 1).

2.4. Animals and operative procedures

Of 24 Japanese white rabbits 3 months old purchased from Japan SLC Co., Ltd. (Shizuoka, Japan), 15 were used in Study 1 and 9 in Study 2. All experiments were conducted strictly observing institutional guidelines for the care and use of laboratory animals.




Fig. 1. Macroscopic aspect of β -TCP cylinders: images at left are axial and side views of the β -TCP cylinder, and at right are SEM micrographs of the β -TCP cylinder coated with PLA-DX-PEG $\times 3000$ (above) and the noncoated control ($\times 3000$, below). The β -TCP cylinder consists of $1\mu\text{m}$ sintered β -TCP granules with $100\text{--}400\mu\text{m}$ interconnected pores. The surface of β -TCP granules in the experimental group is uniformly covered by a thin polymer layer.

Rabbits were anesthetized using an intramuscular injection of ketamine (60mg/kg body weight) before surgery. Under sterile conditions, the mid-shaft of the femur was exposed through a lateral longitudinal skin incision and thigh muscles divided. A 1.5cm long section of the diaphysis was removed together with the periosteum using a cutting saw and the bone defect either filled with prepared implants or left as is [19]. Femurs were then fixed with external fixators for up to 8 weeks postoperatively.

2.5. Experimental design

2.5.1. Effects of rhBMP-2/PLA-DX-PEG/ β -TCP on bone defect repair (Study 1)

Fifteen rabbits were divided into 3 groups of 5 each based on implants received, i.e., (1) $50\mu\text{g}$ of rhBMP2, 250mg of PLA-DX-PEG, and 300mg of β -TCP; (2) no rhBMP2 but the same amounts PLA-DX-PEG and β -TCP; and (3) no implant (defect controls). Femurs were assessed every 2 weeks using X-ray radiography, and bone formation was evaluated as shown in X-ray photographs below. All animals were euthanized by anesthesia overdose at 8 weeks and femurs in the first group collected and stored at -30°C until mechanical testing in Study 2. β -TCP alone was not assessed in this study because PLA-DX-PEG alone only negligibly affected β -TCP osteoconductivity and degradability in previous studies [20].

2.5.2. Mechanical and remodeling properties of the repaired bone by rhBMP-2/PLA-DX-PEG/ β -TCP with long-term observation (Study 2)

Five rabbits underwent the same implants as group (1) in Study 1, i.e., $50\mu\text{g}$ of rhBMP2, 250mg of PLA-

DX-PEG, and 300mg of β -TCP, and external fixators were removed at 8 weeks postoperatively and observed for 24 weeks until animals were euthanized as described above. Femurs were collected to examine bone mineral density, then mechanically tested together with the 5 specimens in Study 1. Four other rabbits undergoing implants of $50\mu\text{g}$ of rhBMP2, 250mg of PLA-DX-PEG, and 300mg of β -TCP were euthanized (1 each) at 2, 4, 8, and 24 weeks postoperatively for histological examination.

2.6. X-ray analysis

New bone formation was evaluated by measuring the ratio of recognizable occupying callus to the defect in length because it is difficult to distinguish newly formed bone from β -TCP due to its radiopacity in the central portion of the defect [21].

2.7. Dual-energy X-ray absorptiometry analysis

Femurs harvested 24 weeks after surgery in Study 2 were examined via dual-energy X-ray absorptiometry (DXA) (DCS-600EX-III; Aloka Co., Ltd., Tokyo, Japan) using an analysis program designed for small animals. Bone mineral content (BMC) and area of new bone were measured and bone mineral density (BMD) calculated as $\text{BMC}/\text{bone area}$. Nonoperated-on femurs harvested from animals euthanized at 24 weeks were used as controls.

2.8. Mechanical testing

Five regenerated femurs each, harvested at 8 weeks in Study 1 and at 24 weeks, were used in 3-point bending mechanical testing with an apparatus designed for this purpose (Maruto Testing Machine Co., Tokyo, Japan). Nonoperated-on femurs harvested from animals euthanized at 24 weeks were used as controls. Other femurs implanted without rhBMP-2 in Study 1 showed no union, and hence were not mechanically tested. Maximum bending strength was measured.

2.9. Histological examination

For histological examination, samples were decalcified in 10% formic acid, dehydrated in a gradient ethanol series, mounted in paraffin, sectioned $4\mu\text{m}$ thick, and stained with hematoxylin-eosin. To observe bone resorption, specimens were stained with tartrate-resistant acid phosphatase (TRAP). Briefly, deparaffinized sections were placed in a TRAP-staining solution consisting of acetate buffer (pH 5.0) 50mM sodium tartrate, 25mg/ml Naphthol-AS MX phosphate (Sigma Chemical Co., MO, USA), and 0.5mg/ml

fast red violet salt (Sigma Chemical Co.) and incubated at 37 °C for 120 min. After the solution was removed by washing, specimens were counterstained with hematoxylin and observed under light microscopy.

2.10. Computed tomography (CT) scanning images

Computed tomography (CT) data on harvested distal femurs at 24 weeks was collected with a helical CT (GE Yokogawa, Tokyo, Japan) and images were reconstructed using 3-dimensional image reconstruction software (Aze, Tokyo, Japan).

2.11. Statistical analysis

Student's *t*-test was used to determine statistical significance, with $P < 0.05$ considered significant.

3. Results

3.1. Defect repair effect of rhBMP-2/PLA-DX-PEG/ β -TCP (Study 1)

Representative radiology of bone defects at 2, 4, and 8 weeks after surgery (Fig. 2) demonstrated opaque calcified shadows bridging both ends of defects as early as 2 weeks in the group implanted with β -TCP combined with rhBMP-2 and polymer. Calcification became more evident at 4 weeks, and newly formed bone connecting both ends of defects appeared to have been remodeled into cortical bone with a bone marrow cavity. The BMP-loaded group showed a time-dependent increase in callus of nearly 100% at 6 weeks, but the group with β -TCP and polymer without rhBMP-2 showed only small amounts of newly formed bone formation—less than 20%. No bone formation was recognized in the control group (Fig. 3).

3.2. Mechanical and remodeling properties of the repaired bone by rhBMP-2/PLA-DX-PEG/ β -TCP with long-term observation (Study 2)

Femurs in this group were stable and enabled free movement in caged animals until their sacrifice at 24 weeks. Radiology of femurs harvested 24 weeks after surgery showed complete regeneration of the intercalated defect. The 3D CT image and frontal tomographic image of regenerated femurs showed that normal femur anatomy had been restored with cortical bone with no residual evidence of implanted β -TCP cylinder blocks (Fig. 4).

3.2.1. Dual-energy X-ray absorptiometry analysis

Bone mineral density of femurs regenerated by biodegradable bone-inducing implants at 24 weeks was 350 mg/cm², essentially equal to control (normal) levels. No significance was seen between experimental and control groups.

3.2.2. Biomechanical properties of repaired bone

The 3-point bending test of femurs regenerated by biodegradable bone-inducing implants at 8 weeks showed significantly lower stiffness (160 N/m) than

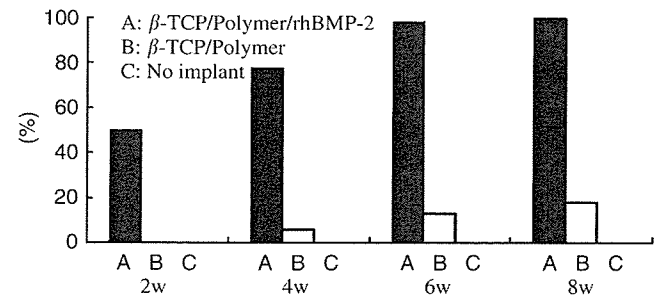


Fig. 3. BMP-loaded group promoting a time-dependent increase in callus (nearly 100% at 6 weeks). The group of β -TCP and polymer without rhBMP-2 promoted only negligible new bone formation—less than 20%. No bone formed in the control group.

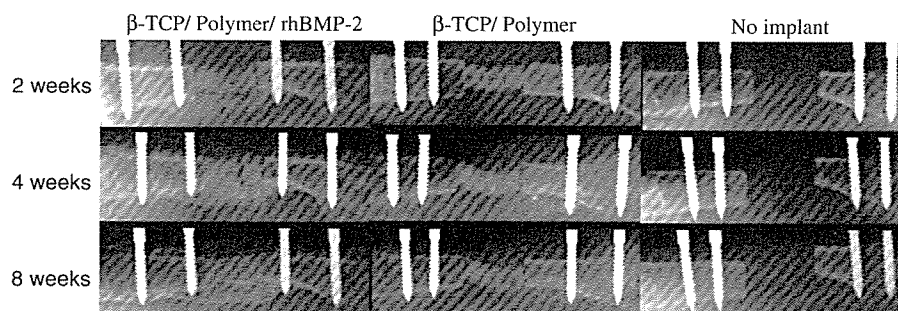


Fig. 2. Representative femur radiographs. From left, implanted with β -TCP with PLA-DX-PEG and rhBMP-2, β -TCP with PLA-DX-PEG without rhBMP-2, and critical size bone defect without implantation (sham surgery). Sequential radiographs show bone repair at 2, 4, and 8 weeks after implantation in the experimental group.

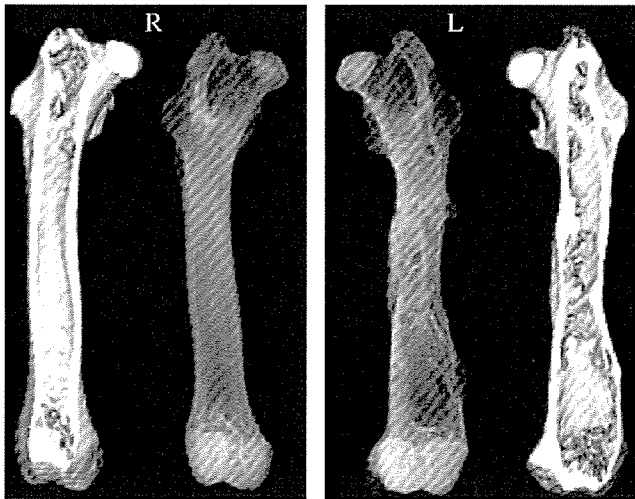


Fig. 4. Soft X-ray and 3D CT images of femurs 24 weeks after surgery. The repaired defect with biodegradable bone-inducing implants is shown at right (L). Images at left are of the counterpart femur in the control rabbit (R). The external fixator was removed 8 weeks after surgery. Note that β -TCP was absorbed and cortical walls remodeled anatomically with the marrow cavity.

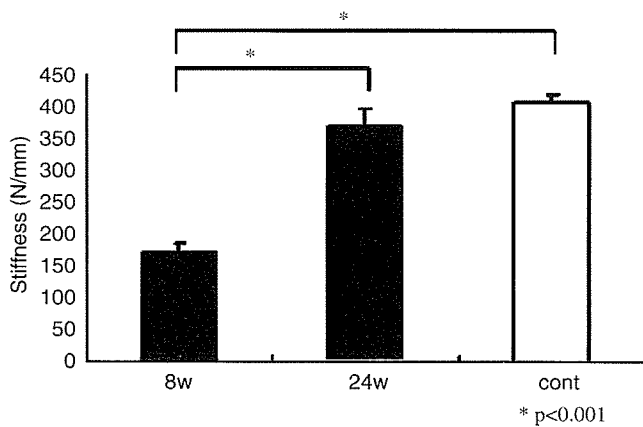


Fig. 5. Results of 3-point bending tests at 8 and 24 weeks after surgery (bar chart). (*: significant difference, $p < 0.001$).

controls (400 N/m, nonsurgical femurs 24 weeks after surgery). Stiffness increased at 24 weeks (370 N/m) and was essentially equal to control (normal) levels (Fig. 5).

3.2.3. Histological findings

In histological sections from defect sites 2 weeks postoperatively, fibrous tissue and a thin layer of bone running parallel to the long axis and encasing implants were seen in the experimental group. A femur from the experimental group at 4 weeks with increased bone mass connected to β -TCP implants and fibrous tissue was observed. Regenerated cortical bone had united with ends of the original cortex of the femur. In sections from the experimental group 8 weeks postoperatively, bone occupying defects had remodeled to where cortical bone and hematopoietic marrow-like tissue were clearly visible (Fig. 6). On the β -TCP surface at 4 weeks, large numbers of TRAP-positive multinucleated cells (osteoclasts) appeared (Fig. 7). In sections of regenerated defects at 24 weeks, cortical bone was remodeled to lamellar bone connected to original ends of the femur. Marrow tissue was also completely restored and no remnants of β -TCP implants were visible (Fig. 8).

4. Discussion

Our experimental results indicated successful regeneration of a critical intercalated bone defect in femur implantation using porous β -TCP with rhBMP-2 and a synthetic PLA-DX-PEG block copolymer as its delivery system. This approach clearly demonstrated that combining these synthetic materials and recombinant protein repaired large defects. The osteogenic potential of composite implants has yet to be compared critically, however.

The rhBMP-2 dose and rhBMP-2 concentration in polymer we used was determined based on previous study of critical bone defect repair in rabbits in which 1.5 cm of an intercalated bone defect in the humerus was




Fig. 6. Typical histological sections at 4 weeks (left, HE staining $\times 40$) and 8 weeks (right, HE staining $\times 40$). Abundant bone formed around β -TCP but not the outside of the femur in sections of specimens at 4 weeks. Cortical and bone marrow-like tissue clearly identified at 8 weeks.

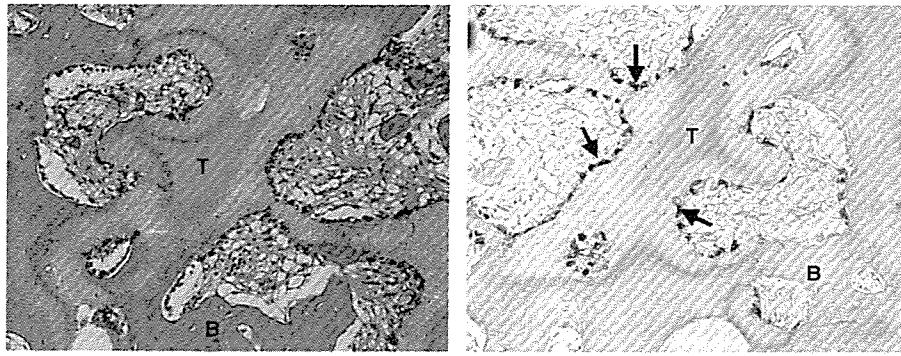


Fig. 7. Histological section of decalcified specimens harvested at 4 weeks and stained with HE (left, $\times 40$) and tartrate-resistant acid phosphatase (TRAP) (right, $\times 40$). β -TCP blocks coated with PLA-DX-PEG and rhBMP-2 are surrounded by abundant TRAP-positive multinucleated osteoclasts (arrows, stained red). (B = bone, T = β -TCP).

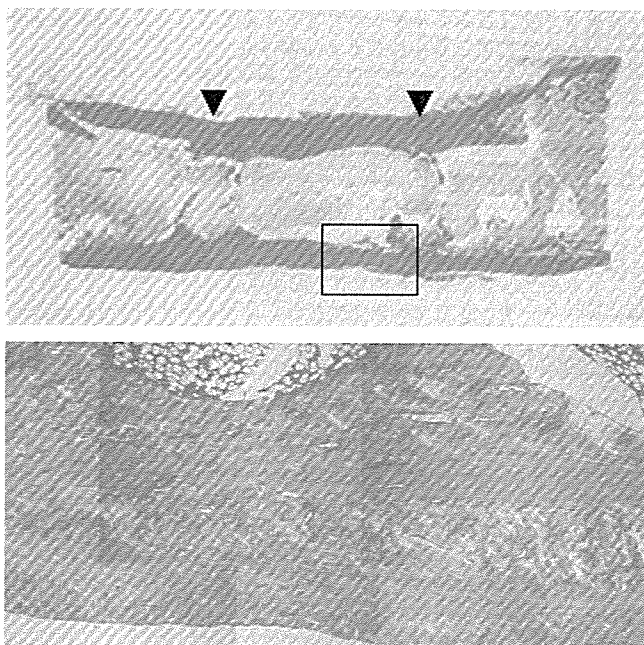


Fig. 8. Images of sagittal histological section at 24 weeks. Cortical walls were repaired completely. Arrowheads indicate fixator pin insertion locations. Polarized magnified image of junction between original and repaired bone (rectangle) (below). Randomly arrayed collagen in the repaired cortical wall contrasts with the more ordered layers of collagen in the original cortical wall.

successfully repaired by filling the defect with titanium mesh cylinders impregnated with a delivery system containing rhBMP-2 [17]. Titanium cylinders were not resorbed in repaired bone. Sustained permanent release of metal ions from the implant could increase the potential risk of allergic reactions or carcinogenesis, especially in infants. For these reasons, we replaced titanium in the present study with biodegradable material. As expected, β -TCP was completely resorbed and replaced by host bone within 24 weeks with no apparent adverse events from resorbed β -TCP.

The successful regeneration of the critical bone defect may be due in part to the porosity of β -TCP cylinders having 100–400 μm pores, which may enable rhBMP to accumulate locally within pores to where osteogenesis is initiated [22–25]. An appropriate local rhBMP concentration in pores would in turn enable successful invasion and ingrowth of mesenchymal cells in the implant and subsequent differentiation into osteoblasts. Additionally, the porosity of β -TCP appeared to be crucial to its rapid degradation in host animals, facilitating contact with host cells and resulting clearly in large numbers of osteoclasts contacting β -TCP [26]. The ability of these cells to permeate and resorb the β -TCP mass likely contributed to the relatively rapid replacement of implants by bone and marrow in our study. Although the location of BMP receptors on the surface of osteoclasts was reported previously [27], the effect of rhBMP-2 on osteoclastic differentiation remains to be clarified, requiring further study to determine the potential action of BMP on osteoclasts to explain the increased recruitment of osteoclasts in new bone induced by rhBMP2. Biodegradable osteoconductive β -TCP combined with a BMP delivery system is replaced by fully integrated biomechanically competent bone, eliminating one of the major limitations of other osteoconductive biomaterials.

The newly formed bone repairing the defect was remodeled to restore the normal anatomy of the original bone with concurrent resorption of β -TCP in 8 weeks. This means that BMP-induced new bone could remodel to adapt to the local biomechanical environment. Osteoconductive material must disappear to generate the physiological biomechanical environment and restore the original anatomy. Our results suggest that absorbable β -TCP is suitable as an ideal bone graft substitute.

The physicochemical properties and degradation profiles of polymer used in this study have been reported elsewhere [13–15]. A detailed safety check for clinical use of the polymer is currently in process. No systemic or local adverse effects have been noted to date.

The optimal content of rhBMP-2 in the carrier required to elicit new bone formation depends on the animal host [16–18], and a higher dose of rhBMP-2 is required in highly evolved animal species. Determining the optimal clinical dose thus requires additional experiments in primates.

5. Conclusion

A new absorbable bone graft substitute with osteogenic capacity was made by combining 3 artificial materials—porous β -TCP, rhBMP-2, and a PLA-DX-PEG delivery system. The capacity of this composite implant to regenerate bone is satisfactory. The composite implant was completely absorbed and replaced by newly formed bone, then remodeled into the femur to restore the natural anatomy. Although further safety checks and clinical trials are required, the practical use of this implant to promote bone regeneration is without doubt a realistic possibility.

Acknowledgements

This work was supported in part by a Grant-in-Aid from the Ministry of Education, Culture, Sports, Science and Technology of Japan (Project Grant No.12137203) and by grants from the Ministry of Health, Labor and Welfare of Japan.

References

- [1] Bauer TW, Muschler GF. Bone graft materials. An overview of the basic science. *Clin Orthop* 2000;371:10–27.
- [2] Greenwald AS, Boden SD, Goldberg VM, Khan Y, Laurencin CT, Rosier RN. Bone-graft substitutes: fact, fictions & applications. *J Bone Joint Surg Am* 2001;83(Suppl 2):98–103.
- [3] Hoogendoorn HA, Renooij W, Akkermans LMA, Visser DDS, Wittebol P. Long-term study of large ceramic implants in dog femora. *Clin Orthop* 1984;187:281–8.
- [4] Ozawa M. Experimental study on bone conductivity and absorbability of the pure β -TCP. *J Jpn Soc Biomater* 1995;13:167–75.
- [5] Debruijn JD, Bovell YP, Davies JE, Vanblitterswijk CA. Osteoclastic resorption of calcium phosphate is potentiated in postosteogenic culture conditions. *J Biomed Mater Res* 1994;28-1:105–12.
- [6] Dong J, Kojima H, Uemura T, Kikuchi M, Tateishi T, Tanaka J. In vivo evaluation of a novel porous hydroxyapatite to sustain osteogenesis of transplanted bone marrow-derived osteoblastic cells. *J Biomed Mater Res* 2001;57-2:208–16.
- [7] Lieberman JR, Daluiski A, Einhorn TA. The role of growth factors in the repair of bone. Biology and clinical application. *J Bone Jt Surg Am* 2002;84-A6:1032–44.
- [8] Baltzer AWA, Lattermann C, Whalen JD, Wooley P, Weiss K, Grimm M, Ghivizzani SC, Robbins PD, Evans CH. Genetic enhancement of fracture repair: healing of an experimental segmental defect by adenoviral transfer of the BMP-2 gene. *Gene Therapy* 2000;7-9:734–9.
- [9] Wang EA, Rosen V, D'Alessandro JS, Bauduy M, Cordes P, Harada T, Israel DI. Recombinant human bone morphogenetic protein induces bone formation. *Proc Natl Acad Sci USA* 1990;87:2220–4.
- [10] Takaoka K, Nakahara H, Yoshikawa H, Masuhara K, Tsuda T, Ono K. Ectopic Bone Induction on and in porous hydroxyapatite combined with collagen and bone morphogenetic protein. *Clin Orthop* 1988;234:250–4.
- [11] Zabka AG, Pluhar GE, Edwards RB, Manley PA, Hayashi K, Heiner JP, Kalscheur VL, Seeherman HJ, Markel MD. Histo-morphometric description of allograft bone remodeling and union in a canine segmental femoral defect model: a comparison of rhBMP-2, cancellous bone graft, and absorbable collagen sponge. *J Orthop Res* 2001;19-2:318–27.
- [12] Jeppsson C, Bostrom M, Aspenberg P. Intraosseous BMP implants in rabbits—Inhibitory effect on bone formation. *Acta Orthop Scand* 1999;70-1:77–83.
- [13] Saito N, Okada T, Toba S, Miyamoto S, Takaoka K. New synthetic absorbable polymers as BMP carriers: plastic properties of poly-D,L-lactic acid-polyethylene glycol block copolymers. *J Biomed Mater Res* 1999;47-1:104–10.
- [14] Saito N, Okada T, Horiuchi H, Murakami N, Takahashi J, Nawata M, Ota H, Nozaki K, Takaoka K. A biodegradable polymer as a cytokine delivery system for inducing bone formation. *Nat Biotechnol* 2001;19-4:332–5.
- [15] Saito N, Okada T, Horiuchi H, Murakami N, Takahashi J, Nawata M, Ota H, Miyamoto S, Nozaki K, Takaoka K. Biodegradable poly-D,L-lactic acid-polyethylene glycol block copolymers as a BMP delivery system for inducing bone. *J Bone Jt Surg Am* 2001;83-A(Suppl 1-Pt 2):S92–8.
- [16] Saito N, Okada T, Horiuchi H, Ota H, Takahashi J, Murakami N, Nawata M, Kojima S, Nozaki K, Takaoka K. Local bone formation by injection of recombinant human bone morphogenetic protein-2 contained in polymer carriers. *Bone* 2003;32-4:381–6.
- [17] Murakami N, Saito N, Horiuchi H, Okada T, Nozaki K, Takaoka K. Repair of segmental defects in rabbit humeri with titanium fiber mesh cylinders containing recombinant human bone morphogenetic protein-2 (rhBMP-2) and a synthetic polymer. *J Biomed Mater Res* 2002;62-2:169–74.
- [18] Murakami N, Saito N, Takahashi J, Ota H, Horiuchi H, Nawata M, Okada T, Nozaki K, Takaoka K. Repair of a proximal femoral bone defect in dogs using a porous surfaced prosthesis in combination with recombinant BMP-2 and a synthetic polymer carrier. *Biomaterials* 2003;24-13:2153–9.
- [19] Crigel MH, Balligand M. Critical size defect model on the femur in rabbits. *Vet Comp Orthop Traumatol* 2002;3:158–63.
- [20] Matsushita N, Terai H, Okada T, Nozaki K, Inoue H, Miyamoto S, Takaoka K. A new bone-inducing biodegradable porous beta-tricalcium phosphate. *J Biomed Mater Res* 2004;70A-3:450–8.
- [21] Kirkerhead CA, Gerhart TN, Schelling SH, Hennig GE, Wang E, Holtrop ME. Long-term healing of bone using recombinant human bone morphogenetic protein 2. *Clin Orthop* 1995;318:222–30.
- [22] Urist MR, Lietze A, Dawson E. β -tricalcium phosphate delivery system for bone morphogenetic protein. *Clin Orthop* 1983;187:277–80.
- [23] Urist MR, Nilsson O, Rasmussen J, Hirota W, Lovell T, Schmalzreid T, Finerman GA. Bone regeneration under the influence of a bone morphogenetic protein (BMP) beta tricalcium phosphate (TCP) composite in skull trephine defects in dogs. *Clin Orthop* 1987;214:295–304.
- [24] Laffargue P, Hildebrand HF, Rtaimate M, Frayssinet P, Amoureux JP, Marchandise X. Evaluation of human recombinant bone morphogenetic protein-2-loaded tricalcium phosphate implants in rabbits' bone defects. *Bone* 1999;25-2(Suppl):55S–8S.