

amount of protein such as tissue-leakage proteins derived from malignant solid tumor. We believe that a multi-dimensional analysis system is needed before MS analysis for plasma biomarker discovery, which is the primary aim in clinical plasma proteome projects.

Conclusion

Though recent advances in proteomic analysis are conspicuous, nevertheless current research has not yet achieved the final clinical goal of producing specific biomarkers for the early detection and discovery of new molecular targets for individualized therapy. The target molecules to be detected in proteomic investigations, must be sufficiently abundant to be clinically useful. It is necessary to further improve our techniques concerning sensitivity and wide dynamic range sufficiently to analyze human plasma proteins. We believe that the remaining problems will be resolved within a few years, and that a fundamental revolution in both early detection and therapeutic strategy will occur in the near future.

References

1. Wilkins MR, Sanchez JC, Williams KL, et al. Current challenges and future applications for protein maps and post-translational vector maps in proteome projects. *Electrophoresis* 1996; **17**: 830–8.
2. O'Farrell PH. High resolutional two-dimensional electrophoresis of proteins. *J Biol Chem* 1975; **250**: 4007–21.
3. Franzen B, Linder S, Okuzawa K, et al. Nonenzymatic extraction of cells from clinical tumor material for analysis of gene expression by two-dimensional polyacrylamide gel electrophoresis. *Electrophoresis* 1993; **14**: 1045–53.
4. Hirano T, Franzen B, Uryu K, et al. Detection of polypeptides associated with the histopathological differentiation of primary lung carcinoma. *Br J Cancer* 1995; **72**: 840–8.
5. Hirano T, Auer G, Maeda M, et al. Human tissue distribution of TA02, which is homologous with a new type of aspartic proteinase, napsin A. *Jpn J Cancer Res* 2000; **91**: 1015–21.
6. Hirano T, Gong Y, Yoshida K, et al. Usefulness of TA02 (napsin A) to distinguish primary lung adenocarcinoma from metastatic lung adenocarcinoma. *Lung Cancer* 2003; **41**: 155–62.
7. Brasch F, Ochs M, Kahne T, et al. Involvement of napsin A in the C- and N-terminal processing of surfactant protein B in type-II pneumocytes of the human lung. *J Biol Chem* 2003; **278**: 49006–14.
8. Ueno T, Linder S, Na CL, et al. Processing of pulmonary surfactant protein B by napsin and cathepsin H. *J Biol Chem* 2004; **279**: 16178–84.
9. Oh JM, Brichory F, Puravs E, et al. A database of protein expression in lung cancer. *Proteomics* 2001; **1**: 1303–19.
10. Chen G, Gharib TG, Huang CC, et al. Proteomic analysis of lung adenocarcinoma: identification of a highly expressed set of proteins in tumors. *Clin Cancer Res* 2002; **8**: 2298–305.
11. Chen G, Gharib TG, Wang H, et al. Protein profiles associated with survival in lung adenocarcinoma. *Proc Natl Acad Sci USA* 2003; **100**: 13537–42.
12. Petricoin EF, Ardekani AM, Hitt BA, et al. Use of proteomic patterns in serum to identify ovarian cancer. *Lancet* 2002; **359**: 572–7.
13. Petricoin EF 3rd, Ornstein DK, Paweletz CP, et al. Serum proteomic patterns for detection of prostate cancer. *J Natl Cancer Inst* 2002; **94**: 1576–8.
14. Zheng Y, Xu Y, Ye B, et al. Prostate carcinoma tissue proteomics for biomarker discovery. *Cancer* 2003; **98**: 2576–82.
15. Rosty C, Christa L, Kuzdzal S, et al. Identification of hepatocarcinoma-intestine-pancreas/pancreatitis-associated protein I as a biomarker for pancreatic ductal adenocarcinoma by protein biochip technology. *Cancer Res* 2002; **62**: 1868–75.
16. Hu Y, Zhang S, Yu J, et al. SELDI-TOF-MS: the proteomics and bioinformatics approaches in the diagnosis of breast cancer. *Breast* 2005; **14**: 250–5.
17. Schwegler EE, Gazares L, Steel LF, et al. SELDI-TOF MS profiling of serum for detection of the progression of chronic hepatitis C to hepatocellular carcinoma. *Hepatology* 2005; **41**: 634–42.
18. Baggerly KA, Morris JS, Edmonson SR, et al. Signal in noise: evaluating reported reproducibility of serum proteomic tests for ovarian cancer. *J Natl Cancer Inst* 2005; **97**: 307–9.
19. Ransohoff DF. Lessons from controversy: ovarian cancer screening and serum proteomics. *J Natl Cancer Inst* 2005; **97**: 315–9.
20. Yanagisawa K, Shyr Y, Xu BJ, et al. Proteomic patterns of tumour subsets in non-small-cell lung cancer. *Lancet* 2003; **362**: 433–9.
21. Tyan YC, Wu HY, Lai WW, et al. Proteomic profiling of human pleural effusion using two-dimensional nano liquid chromatography tandem mass spectrometry. *J Proteome Res* 2005; **4**: 1274–86.
22. Fujii K, Nakano T, Kanazawa M, et al. Clinical-scale high-throughput human plasma proteome analysis: lung adenocarcinoma. *Proteomics* 2005; **5**: 1150–9.

Surgery for Bronchioloalveolar Carcinoma and "Very Early" Adenocarcinoma: An Evolving Standard of Care?

Valerie W. Rusch, MD,* Ryosuke Tsuchiya, MD, PhD,† Masahiro Tsuboi, MD,‡ Harvey I. Pass, MD,§
Dominique Grunenwald, MD,|| and Peter Goldstraw, FRCS¶

Abstract: Lobectomy and mediastinal lymph node dissection is the standard surgical management of early stage non-small cell lung cancer (NSCLC) because more limited resections have been associated with a higher risk of local recurrence. Nevertheless, recent lung cancer screening studies have led to the detection of an increasing number of "very early" NSCLC (defined as less than 2 cm in size) and of good-prognosis histologic subtypes, bronchioloalveolar carcinoma (BAC), and adenocarcinoma (AC), mixed subtypes that are potentially appropriate for sublobar resection. The precise indications for sublobar resection remain unclear and are the subject of ongoing clinical trials, but it seems that very early, peripherally located, node-negative AC of a predominantly BAC pattern may be adequately treated in this manner. Multifocal AC and BAC, either synchronous or metachronous, are also effectively treated by complete resection, using limited resections whenever possible. The pneumonic form of BAC, the rarest variant of this disease spectrum, continues to have a poor prognosis despite complete resection. Very limited experience suggests that lung transplantation leads to prolonged survival in highly selected patients with this histologic subtype. To improve our management of very early AC, much more information is needed about the molecular abnormalities of AC and their relationship to clinical outcomes.

(*J Thorac Oncol.* 2006;1: S27–S31)

During the past decade, thoracic surgeons have been confronted with demographic and pathological shifts in the group of non-small cell lung cancers (NSCLC) that are potentially resectable.¹ In many countries, adenocarcinoma (AC) has become the most common NSCLC histology. The proportion of women with lung cancer has increased dramatically; in some institutions, half of all patients are female. The number of patients who have never smoked or who have minimal past tobacco exposure is also increasing, especially

in North America, because of tobacco control efforts. The widespread use of computed tomography (CT) for lung cancer screening has also led to increased detection of "very early" NSCLC, generally defined as tumors that are 2 cm or less in size, which are usually ACs of mixed subtype or bronchioloalveolar carcinomas (BAC) and which tend to have an indolent clinical behavior.

These epidemiologic shifts have led thoracic surgeons to reexamine the accepted tenets of surgical management of early-stage NSCLC. As part of the November 2004 symposium on BAC, which is the subject of this supplement, a group of thoracic surgeons were asked to review the current management of BAC and very early ACs, focusing especially on the role of sublobar resection. This paper summarizes the discussions held at the symposium and provides updated information on relevant clinical trials.

PATHOLOGICAL CLASSIFICATION OF AC: RELEVANCE TO SURGICAL MANAGEMENT

BAC has long been recognized as a distinct form of AC associated with a favorable prognosis. In 1989, the North American Lung Cancer Study Group (LCSG) reviewed 1635 patients who had undergone resection of AC, 235 of whom had BAC. Resectable BAC occurred more frequently in never-smokers, was diagnosed at an earlier disease stage, and was associated with a better survival rate than invasive AC.² During the last 40 years, improved understanding of the pathology of lung AC has prompted substantial changes in the histologic subclassification by the World Health Organization (WHO), which are summarized by Travis et al.³ in their report from the pathology panel of this symposium (Table 1). From 1967 to 1999, multiple subcategories were added to reflect increasing knowledge about the histologic heterogeneity of AC. Significant changes in the 1999 WHO classification included the addition of atypical adenomatous hyperplasia (AAH) as a preinvasive lesion for lung AC, and the requirement that all BACs demonstrate pure lepidic growth without invasion of stroma, blood vessels, or pleura. In 2004, AC mixed subtype was moved to the top of the list of subcategories in recognition that this is now the most common subtype.⁴

In 1995, Noguchi proposed a six-tier histologic subclassification (types A through F) for small ACs of the lung, recognizing the excellent prognosis associated with BACs (with a purely lepidic growth pattern), the adverse prognostic

*Memorial Sloan-Kettering Cancer Center, New York, New York; †National Cancer Center Hospital, Tokyo, Japan; ‡Tokyo Medical University, Tokyo, Japan; §New York University Medical Center, New York, New York; ||Hôpital Tenon, Paris, France; and ¶Royal Brompton Hospital, London, United Kingdom.

Address for correspondence: Valerie W. Rusch, M.D., Memorial Sloan-Kettering Cancer Center, 1275 York Avenue, New York, NY 10021; E-mail: ruschv@mskcc.org

Copyright © 2006 by the International Association for the Study of Lung Cancer

ISSN: 1556-0864/06/01-09-027

TABLE 1. History of Lung Adenocarcinoma Subclassification According to the World Health Organization

1967	Bronchogenic Acinar Papillary
1981	Bronchioloalveolar Acinar adenocarcinoma Papillary adenocarcinoma Bronchioloalveolar carcinoma Solid carcinoma with mucus formation
1999	Acinar Papillary Bronchioloalveolar carcinoma Nonmucinous Mucinous Mixed mucinous and nonmucinous Solid adenocarcinoma with mucin Adenocarcinoma with mixed subtypes Variants Well-differentiated fetal adenocarcinoma Mucinous (colloid) adenocarcinoma Mucinous cystadenocarcinoma Signet-ring adenocarcinoma Clear-cell adenocarcinoma
2004	Adenocarcinoma, mixed subtype Acinar adenocarcinoma Papillary adenocarcinoma Bronchioloalveolar carcinoma Nonmucinous Mucinous Mixed nonmucinous and mucinous or indeterminate Solid adenocarcinoma with mucin production Fetal adenocarcinoma Mucinous (colloid) adenocarcinoma Mucinous cystadenocarcinoma Signet-ring adenocarcinoma Clear-cell adenocarcinoma

From Travis WD, Garg K, Franklin WA, et al. Evolving concepts in the pathology and CT imaging of lung adenocarcinoma and bronchioloalveolar carcinoma. *J Clin Oncol* 2005;23:3279–3287. Used with permission.

importance of central fibrosis in BACs, and the pathologic heterogeneity of invasive ACs (Table 2).⁵ Although the 2004 WHO classification is the internationally accepted system, Noguchi deserves credit for an early attempt to refine the classification and to correlate it with clinical outcomes. As discussed below, the Noguchi system is still used by Japanese investigators to select patients for sublobar resection in ongoing clinical trials. More recently, Noguchi showed that these histologic subtypes have corresponding molecular abnormalities.⁶ Areas of histologic types A, B, and C extracted by microdissection from resected ACs were examined by multiplex PCR-LOH and were found to have a progressive rise in the incidence of allelic losses. Deletions of 3p, 17p, 18q, and 22q increased significantly from types A to C, consistent with a model of malignant progression.

Several Japanese studies now confirm that the histologic subtype correlates with CT findings and clinical out-

TABLE 2. Noguchi's Histology Typing of Small Adenocarcinoma of the Lung

Type	Description
A	Localized bronchioloalveolar carcinoma
B	Localized bronchioloalveolar carcinoma with foci of collapse of alveolar structure
C	Localized bronchioloalveolar carcinoma with foci of active fibroblastic proliferation
D	Poorly differentiated adenocarcinoma
E	Tubular adenocarcinoma
F	Papillary adenocarcinoma with compressive and destructive growth

From Noguchi M, Morikawa A, Kawasaki M, et al. Small adenocarcinoma of the lung. Histologic characteristics and prognosis. *Cancer* 1995;75:2844–2852. Used with permission.

come.^{3,7 19} The results of Kodama exemplify these investigations (Table 3). Taken as a whole, these studies suggest that: 1) pure ground-glass opacities (GGO) on CT usually represent BAC without any areas of invasive AC, whereas lesions that show both GGO and solid components on CT (part solid, part nonsolid) are mixtures of BAC and invasive ACs; and 2) small (less than 2 cm in size) tumors with >50% GGO are associated with a 100% chance of being node negative, have an excellent chance of long-term survival after treatment, and probably can be managed by limited resection rather than lobectomy. However, the appropriateness of limited resection for part solid/part nonsolid lesions is unclear and is the subject of clinical trials in Japan. Tumors that are more than 50% GGO on CT seem to have a better prognosis and may potentially be managed by sublobar resection, but preoperative high-resolution CT and intraoperative frozen-section analysis still do not always accurately identify tumors that have a poorer prognosis. Our uncertainties with respect to the optimal surgical management of these lesions reflect the highly variable presentation and behavior of lung ACs, the limitations of CT findings in predicting pathologic findings, and our lack of knowledge of the histologic and molecular features that predict a poor prognosis.

TABLE 3. Prognosis in Relationship to Appearance (% GGO)

	GGO < 50%	GGO > 50%	p
Patients	52	52	—
Size	13.7	12.3	0.09
Node involvement	8	0	0.01
% local resection	50%	70%	0.001
Relapse	9	0	—
DFS	72%	100%	—

GGO, ground-glass opacity; DFS, disease-free survival. Adapted from Kodama K, Higashiyama M, Yokouchi H. Prognostic value of ground-glass opacity found in small lung adenocarcinoma on high-resolution CT scanning. *Lung Cancer* 2001;33:17–25. Used with permission.

RELATIONSHIP OF TUMOR SIZE TO TUMOR STAGE: SURGICAL IMPLICATIONS

In NSCLC, the size of the primary tumor is known to correlate with the likelihood of lymph node metastases and, therefore, to influence consideration of sublobar resection. The frequency of nodal disease in very early NSCLC has been studied extensively.²⁰⁻³² Although lymph node involvement is relatively uncommon in small AC, approximately 10% of tumors that are 1 cm or smaller and 20% of tumors that are 1 to 2 cm in size have nodal metastases (Tables 4 and 5). Relative to AC, squamous cell carcinomas less than 2 cm in size seem to be associated with a lower risk of nodal disease.²⁰ These findings complicate the selection of patients for limited pulmonary resection because we do not fully understand which patients with very early lung AC may have disease in the intralobar lymphatics or regional nodes. A better understanding of the molecular features in early AC and their relationship to clinical outcome is needed to allow accurate decisions about the use of sublobar resection.

LOBECTOMY VERSUS SUBLOBAR RESECTION: CURRENT KNOWLEDGE AND INVESTIGATIONS

A prospective randomized multicenter trial reported by the LCSG in 1995 established lobectomy as the standard approach to resection for T1N0 NSCLC (LCSG trial 821). Sublobar resection, either wedge resection or segmentectomy, for carefully selected patients who had thorough intraoperative evaluation of the extent of the primary tumor and of the N1 and N2 lymph nodes, was associated with a tripling of the local recurrence rate and a 30% increase in the overall death rate. Within the T1 stage category, tumor size did not seem to influence the risk of recurrence, but the numbers of patients who had tumors less than 2 cm in size were small.³³ The increasing incidence of very early NSCLC seen in thoracic surgical practice, primarily via CT screening for lung cancer,¹ has reopened the debate about the use of sublobar resection. This debate is especially relevant to BAC and to some AC of mixed subtype because of their indolent clinical behavior and known propensity for multifocality. Patients with these AC histologic subtypes often have synchronous or metachronous primary tumors that are best managed by resection. Preservation of lung function through the proper

TABLE 4. Prevalence of Nodal Disease in Solid Nodules <2 cm in Size

	n	% Positive Nodes	% N2
Naruke (1993) ²³	287	40	50
Asamura (1996) ²⁴	174	20	60
Konaka (1998) ²⁵	171	17.5	66
Takizawa (1998) ²⁶	157	17	NS
Sugi (1998) ²⁷	115	19	66
Wu (2001) ²⁸	136	22	NS
Okada (2003) ²⁹	265	18	55
Nonaka (2003) ³⁰	46	28	70
Average		23	

NS, not stated.

TABLE 5. Prevalence of Nodal Disease in Solid Nodules 1 cm or Less in Size

	n	Patients with Positive Nodes (%)
Naruke (1993) ²³	20	8 (16)
Oda (1998) ³¹	22	0 (0)
Konaka (1998) ²⁵	19	0 (0)
Ohta (2001) ²⁰	11	4 (4)
Miller (2002) ³²	100	7 (7)
Average		9

use of limited resection can be a critical aspect of achieving prolonged survival and maintaining patients' functional capacity.³⁴⁻³⁶ Several retrospective studies and prospective clinical trials suggest that the sublobar resection may be an appropriate operation for very early AC.^{11,13,37-40} The parameters that currently seem to allow proper selection of patients for limited resection include tumor size (less than 2 cm and especially 1 cm or less) in combination with tumor histology (BAC or AC, mixed subtype with 50% or greater BAC component or AC, Noguchi types A or B), peripheral tumor location, and absence of N1 or N2 disease based on thorough intraoperative staging. The presence of GGO or of part solid, part nonsolid appearance on CT reflects these tumor characteristics. In ways that are not yet fully understood (aside from the presence of EGFR mutations in some tumors), these clinical and pathologic features represent tumors that most likely have an indolent biological behavior. The adequacy of wedge resection versus anatomical resection via segmentectomy remains undefined, although segmentectomy has been favored in Japanese studies because it provides an optimal deep margin of resection and removes the local lymphatic bed associated with the primary tumor.³⁹

Japanese investigators have sought to confirm these selection criteria for sublobar resection through prospective multicenter clinical trials. JCOG trial 0201 (Figure 1), reported at the 2006 meeting of the American Society of Clinical Oncology (ASCO), enrolled patients with clinical

JCOG 0201: Standardization of "peripheral early stage lung cancer" diagnosed by HRCT

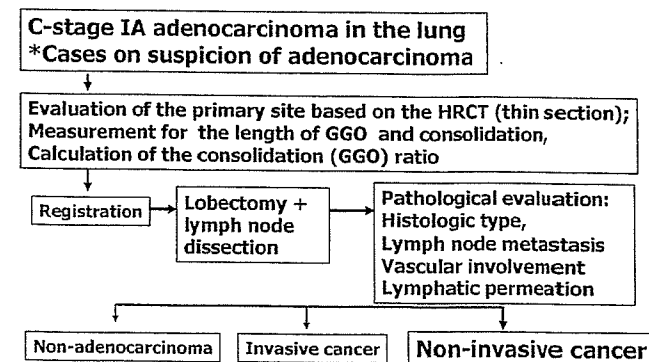


FIGURE 1. Schema for JCOG 0201 trial.

stage IA AC.⁴¹ The primary endpoint was to determine the specificity of high-resolution CT (HRCT) in diagnosing non-invasive AC, using the final pathologic findings as the reference standard. A pathological noninvasive AC was defined as a tumor with no lymph node metastases or lymphatic or vascular invasion. Preoperative evaluation included HRCT to assess the presence of GGO and to calculate the ratio of GGO to solid component of the tumor. Patients then underwent lobectomy and mediastinal lymph node dissection. Final pathological findings were compared with the HRCT features to determine whether the CT could be used to select patients appropriately for sublobar resection. Of the 811 patients enrolled, 545 eligible patients had undergone lobectomy and central data review at the time of the ASCO presentation. Comparison of the CT with the pathological findings showed that HRCT had a specificity of 98.3% but a sensitivity of only 24.7% for the diagnosis of noninvasive AC.

The results of JCOG 0201 have been utilized to develop two new prospective trials. Patients found to have AC 2cm or less in size that are predominantly GGO by HRCT (solid component less than 25% of entire tumor) will be entered on a single arm Phase II trial testing the use of wedge resection for these highly curable indolent tumors. Patients found to have AC 2cm or less in size that have a larger solid component on HRCT (more than 25% but less than 100% of the entire tumor) will be eligible for a prospective randomized comparing lobectomy to limited resection (Figure 2). These trials might also help define which tumors do not require lymph node dissection or sampling, although this is not a planned study endpoint. At the current time lymph node sampling or systematic nodal dissection (SND) remains a key part of accurate tumor staging.⁴²

In North America, the Cancer and Leukemia Group B (CALGB), in collaboration with the American College of Surgeons Oncology Group (ACOSOG), is planning a prospective randomized trial comparing lobectomy versus limited resection (wedge or segmentectomy) for patients with AC 2 cm or less in size. This trial does not incorporate the nuanced radiological and histologic selection criteria used in Japanese studies, depending instead on simple size criteria

and the basic diagnosis of AC. Designed to reproduce the LCSG 821 trial, but with a focus on smaller tumors, the CALGB trial uses intraoperative assessment of tumor size, tumor location, and nodal involvement, followed by randomization to lobectomy or limited resection. Because of the large numbers of patients and long follow-up time required to identify a survival difference between these two resectional approaches, results from this trial will probably not be available for about 8 years.

MANAGEMENT OF THE PNEUMONIC FORM OF BAC: RESECTION, SYSTEMIC THERAPY, OR TRANSPLANTATION?

Most BAC or AC, mixed subtype present as either a single nodule or as multiple lung nodules (synchronous or metachronous) that behave in an indolent manner and are best managed surgically.^{34,36,43} The least common variant of this BAC-AC disease spectrum is generally termed the pneumonic form because it presents as a progressive lobar consolidation with mucinous AC filling the alveolar spaces. Resection does not seem to alter the very poor prognosis of this disease, which inevitably progresses to consolidation of both lungs and death from respiratory failure.^{34,43} Systemic therapy has also been relatively ineffective in this disease. Thus, most surgeons are reluctant to consider pulmonary resection for this biologically aggressive form of AC. Lung transplantation has been suggested as a potential treatment option. First reported by Zorn et al., lung transplantation in nine patients (single lung in two and bilateral transplants in seven patients) was associated with a poor outcome.^{44,45} Only two patients survived long term, whereas the other patients experienced cancer recurrence in the transplanted lungs. More recently, the Toronto group reported their experience with transplantation in 29 patients.⁴⁶ Five-year survival was 51%, and recurrence developed in 13 of the transplanted lungs. Although transplantation was performed for advanced multifocal BAC, it is not entirely clear how many of these patients truly had the pneumonic form of mucinous AC. Thus, lung transplantation potentially remains an option for selected patients, but it is associated with a significant risk of recurrent disease and requires further study.

SUMMARY

Lobectomy and lymph node sampling or systematic nodal dissection remain the standard surgical treatment for patients with early stage NSCLC. However, limited resection may be an appropriate option for patients with very early AC and BAC based on tumor size, location, and relative proportion of BAC to AC. Very small BAC are probably appropriately treated by limited resection. Accurate criteria for selecting patients for limited pulmonary resection await the results of ongoing clinical trials and an improved understanding of NSCLC biology in relationship to clinical outcome.

REFERENCES

1. Read WL, Page NC, Tierney RM, et al. The epidemiology of bronchioloalveolar carcinoma over the past two decades: analysis of the SEER database. *Lung Cancer* 2004;45:137-142.
2. Grover FL, Piantadosi S. The Lung Cancer Study Group. Recurrence and survival following resection of bronchioloalveolar carcinoma of the

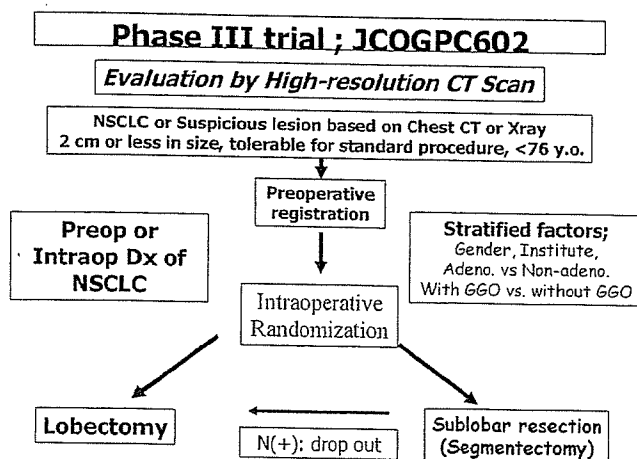


FIGURE 2. Schema for JCOGPC 602 trial.

- lung - the Lung Cancer Study Group experience. *Ann Surg* 1989;209:779-790.
3. Travis WD, Garg K, Franklin WA, et al. Evolving concepts in the pathology and CT imaging of lung adenocarcinoma and bronchioloalveolar carcinoma. *J Clin Oncol* 2005;23:3279-3287.
 4. Travis WD, Brambilla E, Müller-Hermelink HK, Harris CC, eds. World Health Organization Classification of Tumours: Pathology and Genetics of Tumours of the Lung, Pleura, Thymus and Heart. Lyon, France: IARC Press, 2004.
 5. Noguchi M, Morikawa A, Kawasaki M, et al. Small adenocarcinoma of the lung. Histologic characteristics and prognosis. *Cancer* 1995;75:2844-2852.
 6. Aoyagi Y, Yokose T, Minami Y, et al. Accumulation of losses of heterozygosity and multistep carcinogenesis in pulmonary adenocarcinoma. *Cancer Res* 2001;61:7950-7954.
 7. Kodama K, Higashiyama M, Yokouchi H, et al. Natural history of pure ground-glass opacity after long-term follow-up of more than 2 years. *Ann Thorac Surg* 2002;73:386-393.
 8. Nakata M, Sawada S, Saeki H, et al. Prospective study of thoracoscopic limited resection for ground-glass opacity selected by computed tomography. *Ann Thorac Surg* 2003;75:1601-1606.
 9. Shimizu K, Yamada K, Saito H, et al. Surgically curable peripheral lung carcinoma. Correlation of thin-section CT findings with histologic prognostic factors and survival. *Chest* 2005;127:871-878.
 10. Ohde Y, Nagai K, Yoshida J, et al. The proportion of consolidation to ground-glass opacity on high resolution CT is a good predictor for distinguishing the population of non-invasive peripheral adenocarcinoma. *Lung Cancer* 2003;42:303-310.
 11. Nakamura H, Saji H, Ogata A, et al. Lung cancer patients showing pure ground-glass opacity on computed tomography are good candidates for wedge resection. *Lung Cancer* 2004;44:61-68.
 12. Asamura H, Suzuki A, Watanabe S-I, et al. A clinicopathological study of resected subcentimeter lung cancers: a favorable prognosis for ground glass opacity lesions. *Ann Thorac Surg* 2003;76:1016-1022.
 13. Watanabe S-I, Watanabe T, Arai K, et al. Results of wedge resection for focal bronchioloalveolar carcinoma showing pure ground-glass attenuation on computed tomography. *Ann Thorac Surg* 2002;73:1071-1075.
 14. Kodama K, Higashiyama M, Yokouchi H, et al. Prognostic value of ground-glass opacity found in small lung adenocarcinoma on high-resolution CT scanning. *Lung Cancer* 2001;33:17-25.
 15. Matsuguma H, Yokoi K, Anraku M, et al. Proportion of ground-glass opacity on high-resolution computer tomography in clinical T1 N0 M0 adenocarcinoma of the lung: A predictor of lymph node metastasis. *J Thorac Cardiovasc Surg* 2002;124:278-284.
 16. Takashima S, Maruyama Y, Hasegawa M, et al. Prognostic significance of high-resolution CT findings in small peripheral adenocarcinoma of the lung: A retrospective study on 64 patients. *Lung Cancer* 2002;36:289-295.
 17. Okada M, Nishio W, Sakamoto T, et al. Correlation between computed tomographic findings, bronchioloalveolar carcinoma component, and biologic behavior of small-sized lung adenocarcinomas. *J Thorac Cardiovasc Surg* 2004;127:857-861.
 18. Suzuki K, Asamura H, Kusumoto M, et al. "Early" peripheral lung cancer: Prognostic significance of ground glass opacity on thin-section computed tomographic scan. *Ann Thorac Surg* 2002;74:1635-1639.
 19. Higashiyama M, Kodama K, Yokouchi H, et al. Prognostic value of bronchiolo-alveolar carcinoma component of small lung adenocarcinoma. *Ann Thorac Surg* 1999;68:2069-2073.
 20. Ohta Y, Oda M, Wu J, et al. Can tumor size be a guide for limited surgical intervention in patients with peripheral non-small cell lung cancer? Assessments from the point of view of nodal micrometastasis. *J Thorac Cardiovasc Surg* 2001;122:900-906.
 21. Ikeda N, Maeda J, Yashima K, et al. A clinicopathological study of resected adenocarcinoma 2 cm or less in diameter. *Ann Thorac Surg* 2004;78:1011-1016.
 22. Sakurai H, Dobashi Y, Mizutani E, et al. Bronchioloalveolar carcinoma of the lung 3 centimeters or less in diameter: A prognostic assessment. *Ann Thorac Surg* 2004;78:1728-1733.
 23. Naruke T. Significance of lymph node metastases in lung cancer. *Sem Thorac Cardiovasc Surg* 1993;5:210-218.
 24. Asamura H, Nakayama H, Kondo H, et al. Lymph node involvement, recurrence, and prognosis in resected small, peripheral, non-small cell lung carcinomas: Are these carcinomas candidates for video-assisted lobectomy? *J Thorac Cardiovasc Surg* 1996;111:1125-1134.
 25. Konaka C, Ikeda N, Hiyoshi T, et al. Peripheral non-small cell lung cancers 2.0 cm or less in diameter: Proposed criteria for limited pulmonary resection based upon clinicopathological presentation. *Lung Cancer* 1998;21:185-191.
 26. Takizawa T, Terashima M, Koike T, et al. Lymph node metastasis in small peripheral adenocarcinoma of the lung. *J Thorac Cardiovasc Surg* 1998;116:276-280.
 27. Sugi K, Nawata K, Fujita N, et al. Systematic lymph node dissection for clinically diagnosed peripheral non-small cell lung cancer less than 2 cm in diameter. *World J Surg* 1998;22:290-295.
 28. Wu J, Ohta Y, Minato H, et al. Nodal occult metastasis in patients with peripheral lung adenocarcinoma of 2.0 cm or less in diameter. *Ann Thorac Surg* 2001;71:1772-1778.
 29. Okada M, Sakamoto T, Nishio W, et al. Characteristics and prognosis of patients after resection of nonsmall cell lung carcinoma measuring 2 cm or less in greatest dimension. *Cancer* 2003;98:535-541.
 30. Nonaka M, Kadokura M, Yamamoto S, et al. Tumor dimension and prognosis in surgically treated lung cancer for intentional limited resection. *Am J Clin Oncol* 2003;26:499-503.
 31. Oda M, Watanabe Y, Shimizu J, et al. Extent of mediastinal node metastasis in clinical stage I non-small cell lung cancer: The role of systematic nodal dissection. *Lung Cancer* 1998;22:23-30.
 32. Miller DL, Rowland CM, Deschamps C, et al. Surgical treatment of non-small cell lung cancer 1 cm or less in diameter. *Ann Thorac Surg* 2002;73:1545-1551.
 33. Ginsberg RJ, Rubinstein LV. Randomized trial of lobectomy versus limited resection for T1N0 non-small cell lung cancer. Lung Cancer Study Group. *Ann Thorac Surg* 1995;60:615-622.
 34. Ebricht MJ, Zakowski MF, Martin J, et al. Clinical pattern and pathologic stage but not histologic features predict outcome for bronchioloalveolar carcinoma. *Ann Thorac Surg* 2002;74:1640-1647.
 35. Roberts PF, Stranicka M, Lara PN, et al. Resection of multifocal non-small cell lung cancer when the bronchioloalveolar subtype is involved. *J Thorac Cardiovasc Surg* 2003;126:1597-1602.
 36. Battafarano RJ, Meyers BF, Gurthrie TJ, et al. Surgical resection of multifocal non-small cell lung cancer is associated with prolonged survival. *Ann Thorac Surg* 2002;74:988-994.
 37. Okada M, Yoshikawa K, Hata T, et al. Is segmentectomy with lymph node assessment an alternative to lobectomy for non-small cell lung cancer of 2 cm or smaller? *Ann Thorac Surg* 2001;71:956-961.
 38. Koike T, Yamato Y, Yoshiya K, et al. Intentional limited pulmonary resection for peripheral T1N0M0 small-sized lung cancer. *J Thorac Cardiovasc Surg* 2003;125:924-928.
 39. Yoshikawa K, Tsubota N, Kodama K, et al. Prospective study of extended segmentectomy for small lung tumors: The final report. *Ann Thorac Surg* 2002;73:1055-1059.
 40. Watanabe T, Okada A, Imakiire T, et al. Intentional limited resection for small peripheral lung cancer based on intraoperative pathologic exploration. *Jpn J Thorac Cardiovasc Surg* 2005;53:29-35.
 41. Suzuki K, Koike T, Shibusa T, et al. Evaluation of radiologic diagnosis in peripheral clinical IA lung cancers - a prospective study for radiological diagnosis of peripheral early lung cancer (JCOG 0201). *J Clin Oncol* 2006;24:419s.
 42. Goldstraw P. Report on the international workshop on intrathoracic staging. London, October 1996. *Lung Cancer* 1997;18:107-111.
 43. Regnard JF, Santelmo N, Romdhani N, et al. Bronchioloalveolar lung carcinoma. Results of surgical treatment and prognostic factors. *Chest* 1998;114:45-50.
 44. Garver Jr. RI, Zorn GL, Wu X, et al. Recurrence of bronchioloalveolar carcinoma in transplanted lungs. *N Engl J Med* 1999;340:1071-1074.
 45. Zorn GL, McGiffin DC, Young KR, et al. Pulmonary transplantation for advanced bronchioloalveolar carcinoma. *J Thorac Cardiovasc Surg* 2003;125:45-48.
 46. de Perrot M, Chernenko S, Waddell TK, et al. Role of lung transplantation in the treatment of bronchogenic carcinomas for patients with end-stage pulmonary disease. *J Clin Oncol* 2004;22:4351-4356.

REVIEW ARTICLE

Tatsuo Ohira · Yasuhiro Suga · Yoshitaka Nagatsuka
Jitsuo Usuda · Masahiro Tsuboi · Takashi Hirano
Norihiko Ikeda · Harubumi Kato

Early-stage lung cancer: diagnosis and treatment

Received: December 12, 2005

Key words Lung cancer · Early-stage

Introduction

The lung cancer death rate is increasing throughout the world due to increases in numbers of the elderly, increased environmental pollution, and lack of detection in early stages. At our institution, the 5-year survival rate has gradually improved over the past five decades. These results could be due to improvements in therapeutic procedures, including surgery, chemotherapy, radiotherapy, laser therapy, and immunotherapy. Furthermore, the improvement in survival in Japan may be partially due to mass screening for lung cancer mandated by the Health Insurance Act of 1987. The therapeutic results for lung cancer are unsatisfactory. The 5-year survivals of lung cancer patients according to the Japanese Lung Cancer Registry, are shown in Fig. 1.¹ Good results were obtained only in stage I, but in other stages the results were still disappointing. Thus, in order to reduce deaths from lung cancer, it is necessary to detect and treat early-stage lung cancer.

However, there are various problems in the treatment of early-stage lung cancer. Early-stage lung cancers are classified into two categories according to the location of the tumor: central type and peripheral type, and the treatment of each type has specific problems.

In Japan, the criteria of early-stage lung cancer were first proposed about 30 years ago, in 1975. Peripheral-type early-stage lung cancer was defined as a tumor located in an

airway more peripheral than the subsegmental bronchi, with the longest dimension of the tumor being 2 cm or less and with no recognized lymph node or distant metastases. In central-type early-stage lung cancer, the tumor is located in a segmental bronchus. In central-type lesions, even if they are early-stage lung cancer, resection of a large volume of lung is generally necessary. This could be a significant factor for pulmonary dysfunction, especially in older patients. In addition, lung cancer, especially the early-stage central type, has a tendency to develop in multiple lesions. In such cases resection is not a valid option for the treatment of all lesions. Therefore, noninvasive therapeutic modalities were required. Laser therapy has been developed for central-type early lung cancer. For the diagnosis of early-stage central-type lung cancer, autofluorescence fiberscopes, bronchofiberscopic echograms, and optical coherence tomography (OCT) have been developed.

As stated above, the improvement of survival in Japan may be partially due to mass lung cancer screening mandated by the Health Insurance Act of 1987. Mass screening for lung cancer by chest computed tomography (CT) was begun in Japan 10 years ago and is now being used in the United States and Europe. Because large numbers of tiny peripheral lung shadows were detected in many of the CT screening pilot trials,^{2,3} it is important to establish an internationally accepted definition of peripheral-type early-stage lung cancer.

Therapeutic guidelines for central-type early-stage lung cancer

In Japan, the therapeutic guidelines for lung cancer were established according to evidence-based medicine, with the support of the Ministry of Health, Labor, and Welfare in 2002. In these guidelines, surgical resection and photodynamic therapy (PDT) are recommended for the treatment of central-type early-stage lung cancer.⁴

T. Ohira (✉) · Y. Suga · Y. Nagatsuka · J. Usuda · M. Tsuboi ·
T. Hirano · H. Kato
Department of Thoracic Surgery, Tokyo Medical University,
6-7-1 Nishi-shinjuku, Shinjuku-ku, Tokyo 160-0023, Japan
Tel. +81-3-3342-6111; Fax +81-3-3342-6154
e-mail: tatsuo@rd5.so_net.ne.jp

N. Ikeda
Department of Thoracic Surgery, International University of Health
and Welfare, Tokyo, Japan

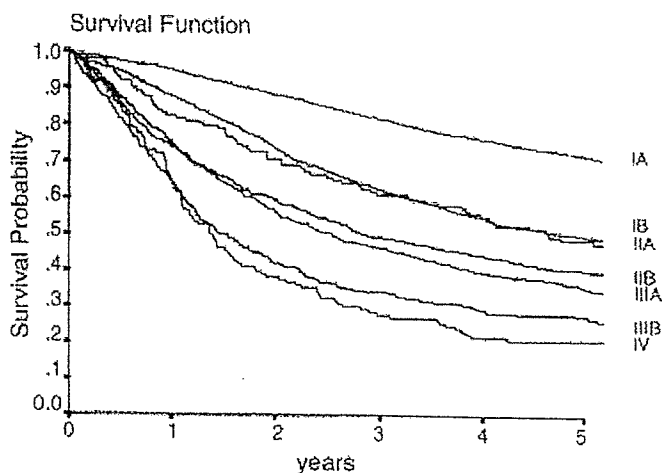


Fig. 1. Survival curves according to clinical (c)-stage. The 5-year survival rates according to c-stage were as follows: 72.1% for IA ($n = 2423$), 49.9% for IB ($n = 1542$), 48.7% for IIA ($n = 150$), 40.6% for IIB ($n = 746$), 35.8% for IIIA ($n = 1270$), 28.0% for IIIB ($n = 366$), and 20.8% for IV ($n = 147$). There was a significant difference in survival between stages IA and IB ($P = 0.0000$), between stages IIA and IIB ($P = 0.0458$), between stages IIB and IIIA ($P = 0.0439$), and between stages IIIA and IIIB ($P = 0.0000$). There was no difference in survival between stages IB and IIA ($P = 0.4969$) or between stages IIIB and IV ($P = 0.1577$).

Autofluorescence bronchoscopes (AFBs)

Central-type early-stage lung cancer can be cured by noninvasive endoscopic treatment, such as PDT, which has advantages for patients with poor pulmonary reserve; however, the detection of carcinoma in situ (CIS) is a challenge for bronchoscopists. Such lesions show only subtle changes in the bronchial mucosa,⁵ and Woolner⁶ reported that 60% of CIS lesions showed no macroscopically abnormal findings. This is particularly true with slightly edematous or superficial mucosal changes that can easily be missed, even by experienced bronchoscopists, because they are only a few millimeters thick. Autofluorescence diagnosis is a powerful method to detect macroscopically subtle lesions of the bronchus. Autofluorescence bronchoscopes (AFBs) have been used in leading facilities throughout the world, and the sensitivity for detection of intraepithelial lesions was reported to be 1.5 to 6 times higher than that of conventional white-light bronchoscopy.

Endobronchial ultrasonography (EBUS)

In order to decide indications for PDT, knowledge of the depth of the bronchial tumor is important. Previously, we assessed depth of tumor invasion by the shape of the tumor and loss of bronchus folds. Endobronchial ultrasonography (EBUS) can image the bronchial wall structure in order to assess the depth of bronchial tumor invasion.

Malignant tissues are imaged as hypoechoic areas, and tumor invasion of the cartilage layer is clearly detected. The bronchial wall structure can be imaged as six distinct layers.

The cartilage layer is easily identified and can be used to evaluate bronchial wall invasion.

Optical coherence tomography (OCT)

Optical coherence tomography (OCT) is a new modality to detect early-stage lung cancer. OCT can obtain high-resolution, cross-sectional microscopic images of tissue, potentially enabling an optical biopsy to substitute for conventional excisional biopsy. We sought to investigate the capability of OCT to image the microstructure of normal and abnormal bronchial tissue. To assess the depth of bronchial tumor invasion, OCT imaging of the bronchial wall structure was clearer than EBUS, but OCT could detect only the surface of the bronchus.

The OCT system we used was produced by Light Lab Imaging (Boston, MA, USA) and Pentax (Tokyo, Japan). We inserted the OCT catheter via the working channel of the bronchoscope to evaluate the bronchial lumen. The catheter delivers a radial OCT beam and scans circumferentially to generate a transluminal image. In central-type lung cancers, the tumors showed unevenly distributed high backscattering areas and resultant loss of the normal layer structure. We believe that OCT will be able to detect nuclear structure and be used for diagnosis similarly to biopsy in the future.⁷

Possibility of limited resection by video-assisted thoracoscopic surgery (VATS)

The standard therapeutic procedure for peripheral-type early-stage lung cancer is believed to be lobectomy with mediastinal lymph node dissection. However the question has been raised whether lobectomy is really needed for tiny tumors, particularly those less than 1 cm in greatest dimension. There are several reports on limited resection of small lung cancers.^{8,9} Some of these results showed satisfactory 5-year survival rates. Clinical trials to clarify the possibility of limited resection are needed for particularly small lung cancers showing ground-glass opacity (GGO), or ground-glass attenuation (GGA). Most of such lesions showed no lymph node metastases, and a 5-year survival of 100% was obtained in patients with such cases who underwent resection. Wedge resection of small lung cancers by VATS without lymph node dissection is one type of minimally invasive surgery. If some types of lung cancer could be shown to be resected by VATS without any increase in local recurrence, this method could become a future standard treatment for peripheral small lung cancers.

Rate of lymph node metastasis of peripheral small nodular cancers

In the past 5 years, 983 patients with lung cancer underwent surgery at our institution. Among them, a total of 159 pa-

tients were studied (Table 1). The tumor size was classified into three categories: 1 cm or less, 1 to 1.5 cm, and 1.5 to 2 cm (47, 49, and 63 patients, respectively). There were 147 pathological N0 patients; lymph node metastasis was recognized in 12 patients (7.5%); this was N1 in 3, and N2 in 9. Table 2 shows the rate of lymph node involvement according to tumor size. In patients with tumors of 1 cm or less, 98% showed no lymph node involvement; however, even in these tiny tumors, 2% showed N2 disease. In tumors between 1 and 1.5 cm, 94% showed no metastasis, but 6% were either N1 or N2. In tumors between 1.5 and 2 cm, lymph node involvement was recognized in 13%.

In this study, the percentages of GGO in tumors were extensively analyzed. We divided tumors into two categories according to how much of the lesion consisted of GGO findings. According to these criteria, 44 tumors showed more than 50% GGO and 115 showed less than 50% GGO. Tumors with a GGO ratio of more than 50% showed no lymph node metastases. On the contrary, all node-positive tumors showed a GGO ratio of less than 50% (Table 3). The relationship between percent GGO area on High Resolution Computed Tomography (HRCT) and the Noguchi classification¹⁰ is shown in Table 4.

Twenty-five of the 44 tumors (57%) showing a GGO component of more than 50% on HRCT were Noguchi type A and B. Seventeen of the 71 tumors (24%) of type C showed more than 50% GGO, and the remaining 54 type C tumors (76%) showed less than 50% GGO. Fifty-three of

the 55 (96%) type D, E, and F tumors showed less than 50% GGO. A good correlation between the CT findings and the Noguchi classification was recognized.

The relationship between representative clinicopathological factors and the percent GGO area is shown in Table 5. According to the χ^2 test, the percent GGO area was related to tumor size ($P = 0.0135$) and pathological stage ($P = 0.04$). In particular, a significant relationship with percent GGO was obtained for pathological features including the Noguchi classification ($P = 0.0001$), vascular invasion, and lymphatic invasion.

The overall 5-year survival rate of the patients studied was 88.0%, but it was 96.7% in those with tumors less than 1 cm in diameter, 81.6% in those with tumors between 1 and 1.5 cm, and 84.4% in those with tumors between 1.5 and 2 cm.

The 5-year survival rate was also analyzed according to percent GGO in the lesion. In patients with more than 50% GGO, a 100% 5-year survival rate was obtained, but those with less than 50% GGO had an 83.9% 5-year survival rate.

According to the Noguchi classification, a 5-year survival rate of 100% was obtained in types A and B, with 5-year survivals of 97.4% in type C, 67.1% in types D, E, and F, respectively, which was significantly lower than the results for types A and B and C.

Table 1. Patient characteristics

Characteristics	
Age (years)	
Average	63
Minimum	40
Maximum	84
Sex	
Male	67
Female	92
Smoking habit	
Non-smoker	89
Smoker	70
Operative procedure	
Lobectomy	112
Segmentectomy	20
Wedge resection	27

Table 2. Tumor size and nodal status

Tumor size	N0	N1	N2
1.0 cm or less ($n = 47$)	46	0	1
1.0-1.5 cm ($n = 49$)	46	1	2
1.5-2.0 cm ($n = 63$)	55	2	6

Table 3. GGO area and TN status

GGO%	$T \leq 1$ cm	$1 < T \leq 5$ cm	$1.5 < T \leq 2$ cm
More than 50%	18	16	10
Less than or equal to 50%	29 (1)	33 (3)	53 (8)
			115 (12)

Numbers in parentheses are numbers of node-positive tumors

Future surgical procedures for peripheral early-stage lung cancer

Tumors with 100% GGO findings on CT images could indicate suitability for limited surgical resection by VATS. Lesions showing between 50% and 100% GGO may also be indicated for limited resection in tumors less than 2 cm in

Table 4. GGO area and Noguchi classification

GGO%	A, B	C	D, E, F
More than 50%	25	17	2
Less than or equal to 50%	8	54	53
			115

Table 5. Relationship between prognostic factors and percent GGO on HRCT

Prognostic factor	χ^2	P value
Sex	0.162	0.687
Tumor size	8.616	0.0135
Pathological stage: I or II-IV	4.168	0.0412
Noguchi classification: A, B, C or D, E, F	14.442	0.0001
Vascular invasion	6.76	0.0093
Lymphatic invasion	5.326	0.0206

diameter, and also, perhaps, in lesions showing between 10% and 50% GGO findings with a tumor size less than 1 cm in diameter. Evaluation of limited resection for small peripheral nodules was reported previously by several researchers.^{8,9,11} However, different opinions concerning the modalities used have been reported.^{12,13} There are still controversies concerning limited resection of peripheral small lung cancers. A randomized clinical trial by the Lung Cancer Study Group (LCSG) demonstrated the disadvantages of limited resection for T1N0 tumors in relation to lobectomy.¹³ Therefore, clinical evidence of the usefulness of limited resection for peripheral early-stage lung cancers should be established. The features of peripheral lung cancers suitable for limited resection without lymph node dissection should be clarified. This will make it possible to determine the optimal CT findings for limited resection.

In our experience, even if the primary lesion was less than 1 cm in size, nodal involvement was confirmed histologically in some patients. Prognostic factors may depend not solely on tumor size but also on the percent GGO area. It is necessary to clarify the findings of CT images of noninvasive cancer by a clinical multicenter study.

Low-dose CT screening for lung cancer

Helical (spiral) CT imaging in the early 1990s provided a promising test for the detection of smaller nodules in the lungs, compared with traditional chest radiography, as images of the chest could be obtained in less than 20s at a low dose of radiation. It is generally accepted that low-dose CT screening leads to early diagnosis of lung cancer in a high percentage of cases. Based on this evidence, annual CT screening provides for detecting the disease at earlier and presumably more commonly curable stages. The Early Lung Cancer Action Project (ELCAP) showed the great superiority of CT imaging over chest radiographic imaging in identifying cancerous "nodules" in the lungs.^{14,15}

Adjuvant chemotherapy for early-stage lung cancer

Recently, some reports have shown significant survival results with adjuvant chemotherapy. The Japan Lung Cancer Research Group (JLCRG) conducted a randomized phase III trial of adjuvant chemotherapy with and without uracil plus tegafur (UFT) after complete surgical resection for stage I adenocarcinoma patients. Subgroup analysis of 263 stage IB patients showed a highly significant result for the UFT arm (5-year survival, 84.9% versus 73.5%; $P = 0.005$).¹⁶

Conclusions

Good results have been obtained in early-stage lung cancer treatments. Photodynamic therapy (PDT) is suitable for central-type early-stage lung cancer. VATS is a good indica-

tion for peripheral-type early lung cancer. Recently, less invasive therapies, such as stereotactic radiation therapy,¹⁷ charged-particle therapy,¹⁸ and microwave coagulation therapy¹⁹ have shown promising results. PDT could be a good modality for peripheral lung cancer, too.²⁰ The important thing is to find the early-stage lung cancers.

References

- Goya T, Asamura H, Yoshimura H, et al (2005) The Japanese Joint Committee of the Lung Cancer Registry. Prognosis of 6644 resected non-small cell lung cancers in Japan: a Japanese Lung Cancer Registry Study. *Lung Cancer* 50:227-234
- Kaneko M, Eguchi K, Ohmatsu H, et al (1996) Peripheral lung cancer: screening and detection with low-dose spiral CT versus radiography. *Radiology* 201:798-802
- Sone S, Takashima S, Li F, et al (1998) Mass screening for lung cancer with mobile spiral computed tomography scanner. *Lancet* 351:1242-1245
- Furuse K, Fukuoka M, Kato H, et al (1993) A prospective phase II study on photodynamic therapy with photofrin II for centrally located early-stage lung cancer. The Japan Lung Cancer Photodynamic Therapy Study Group. *J Clin Oncol* 11:1852-1857
- Ikeda N, Hiyoshi T, Kakihana M, et al (2003) Histopathological evaluation of fluorescence bronchoscopy using resected lungs in cases of lung cancer. *Lung Cancer* 41:303-309
- Woolner LB, Fontana RS, Cortese DA, et al (1984) Roentgenographically occult lung cancer: pathologic findings and frequency of multicentricity during a 10-year period. *Mayo Clin Proc* 59:453-466
- Tsuboi M, Hayashi A, Ikeda N, et al (2005) Optical coherence tomography in the diagnosis of bronchial lesions. *Lung Cancer* 49:387-394
- Jensik R, Faber L, Kittle C (1979) Segmental resection for bronchogenic carcinoma. *Ann Thorac Surg* 28:475-483
- Kodama K, Doi O, Higashiyama M, et al (1997) Intentional limited resection for selected patients with T1 N0 M0 non-small-cell lung cancer: a single-institution study. *J Thorac Cardiovasc Surg* 114:347-353
- Noguchi M, Morikawa A, Kawasaki M, et al (1995) Small adenocarcinoma of the lung. Histologic characteristics and prognosis. *Cancer* 15:2844-2852
- Watanabe S, Watanabe T, Arai K, et al (2002) Results of wedge resection for focal bronchioloalveolar carcinoma showing pure groundglass attenuation on computed tomography. *Ann Thorac Surg* 73:1071-1075
- Miller D, Rowland C, Deschamps C, et al (2002) Surgical treatment of non-small cell lung cancer 1 cm or less in diameter. *Ann Thorac Surg* 73:1545-1550
- Ginsberg R, Rubinstein L (1995) Randomized trial of lobectomy versus limited resection for T1 N0 non-small cell lung cancer. Lung Cancer Study Group. *Ann Thorac Surg* 60:615-622
- Henschke CI, Shaham D, Yankelevitz DF, et al (2005) CT screening for lung cancer: past and ongoing studies. *Semin Thorac Cardiovasc Surg* 17:99-106
- Wisnivesky JP, Mushlin AI, Sichertman N, et al (2003) The cost-effectiveness of low-dose CT screening for lung cancer: preliminary results of baseline screening. *Chest* 124:614-621
- Kato H, Ichinose Y, Ohta M, et al (2004) Japan Lung Cancer Research Group on Postsurgical Adjuvant Chemotherapy. A randomized trial of adjuvant chemotherapy with uracil-tegafur for adenocarcinoma of the lung. *N Engl J Med* 350:1713-1721
- Onishi H, Araki T, Shirato H, et al (2004) Stereotactic hypofractionated high-dose irradiation for stage I nonsmall cell lung carcinoma. *Cancer* 101:1623-1631
- Miyamoto T, Yamamoto N, Nishimura H, et al (2003) Carbon ion radiotherapy for stage I non-small cell lung cancer. *Radiation Oncol* 66:127-140
- Furukawa K, Miura T, Kato Y, et al (2005) Microwave coagulation therapy in canine peripheral lung tissue. *J Surg Res* 123:245-250
- Okunaka T, Kato H, Tsutsui H, et al (2004) Photodynamic therapy for peripheral lung cancer. *Lung Cancer* 43:77-82

7196 General Poster Session (Board #U5), Sun, 8:00 AM - 12:00 PM

Prognostic value of blood levels of vascular endothelial growth factor (VEGF) and basic fibroblast growth factor (bFGF) in advanced non-small cell lung cancer (NSCLC) patients. *V. Alberola, C. Camps, R. Sirera, L. Llobat, A. Blasco, M. J. Safont, J. Garde, M. Taron, J. J. Sanchez, R. Rosell; Hospital Arnau de Vilanova, Valencia, Spain; Hospital General de Valencia, Valencia, Spain; Hospital Germans Trias i Pujol, Badalona, Spain; Universidad Autonoma de Madrid, Madrid, Spain*

Background: VEGF and bFGF are among the most important angiogenic factors. We have explored these angiogenesis mediators in plasma and its prognostic significance in advanced NSCLC. **Methods:** Were enrolled 451 patients with advanced NSCLC, stages IIIB and IV and treated with cisplatin and docetaxel. Blood was collected before chemotherapy. Plasma VEGF and bFGF levels were assessed by commercial ELISA (sensitivity 5 pg/ml). In parallel plasma from 32 age and gender-matched controls was used. **Results:** Median age was 61 years (35–82) and 84% were males. 99% had performance status 0–1. 84% were in stage IV and 16% in stage IIIB. The histological subtypes were: 32% squamous cell carcinoma, 50% adenocarcinoma, 14% anaplastic large cell, and 4% undifferentiated. 41% of the patients received second line chemotherapy. 1% achieved complete response (CR), 36% partial response (PR), 35% had stable disease (SD) and 28% progressive disease (PD). Patient's median plasma levels of VEGF (20 pg/ml, [6–203]) differ significantly ($p = 0.04$) from controls (14 pg/ml, [7–53]), but in contrast bFGF levels were not different, 14 pg/ml [5–960] vs 10 pg/ml [6–278] respectively. There were not differences in patients according to histology, site of metastasis and ECOG; however we could observe a tendency with stage for both factors: bFGF 9 pg/ml [5–24] in stage IIIB vs 15 pg/ml [6–960], $p = 0.071$ and VEGF 17 pg/ml [6–145] in IIIB vs 21 pg/ml [6–203] in IV, $p = 0.086$. It could not be observed any differences in response to therapy for both angiogenic factors; CR+PR patients presented median VEGF of 18 pg/ml [6–71] and bFGF 11 pg/ml [6–960] vs 20 pg/ml of VEGF [6–203] and 15 pg/ml of bFGF [5–395] in the SD+PD group. In the multivariate analysis we could not find that VEGF and bFGF plasma levels were predictors for time to progression (TTP) and overall survival (OS). **Conclusions:** VEGF but not bFGF levels in patients are significantly higher in patients than in controls. In our cohort of patients with advanced NSCLC we have not found any relationship between serum VEGF and bFGF levels with stage, histology, response, site of metastasis, TTP and OS.

7198 General Poster Session (Board #U7), Sun, 8:00 AM - 12:00 PM

Elevated osteopontin (OPN) plasma levels are highly prognostic in advanced non-small cell lung cancer (NSCLC): Analysis of SWOG S0003. *P. C. Mack, M. W. Redman, K. Chansky, S. K. Williamson, N. Farneth, P. N. Lara Jr, Q. Le, P. H. Gumerlock, J. J. Crowley, D. R. Gandara; UC Davis Cancer Center, Sacramento, CA; Southwest Oncology Group Statistical Center, Seattle, WA; SWOG Statistical Center, Seattle, WA; University of Kansas Medical Center, Kansas City, KS; Stanford University, Stanford, CA*

Background: OPN is a secreted glycoprotein with a diverse array of functions, including induction of uPA & increased cell migration. OPN has been shown to be elevated in a number of tumor types, & its downregulation reduces tumorigenicity & metastasis in tumor models. High levels have also been associated with tumor hypoxia/angiogenesis, as are vascular endothelial growth factor (VEGF) & plasminogen activator inhibitor (PAI-1). We hypothesized that secreted levels of these biomarkers would correlate with clinical outcome after treatment. **Methods:** Plasma concentrations of OPN, VEGF & PAI-1 were measured by ELISA in 160 NSCLC patients enrolled on the Southwest Oncology Group (SWOG) trial S0003 (paclitaxel/carboplatin ± the hypoxic cytotoxin tirapazamine). Post-treatment plasma samples were available in 56 patients. **Results:** Baseline OPN plasma levels correlated significantly with patient overall survival (OS). High interpatient variability was observed, with levels ranging from undetectable to 2560 ng/ml, (median: 606.5 ng/ml). When dichotomized, median OS was 11 months for patients below median OPN levels & 7 months for those above ($p = 0.004$). Survival decreases with increasing OPN concentration. Furthermore, OPN levels correlated with response rate (RR) (median responders: 497; median non-responders: 698 ng/ml. Wilcoxon rank-sum $p = 0.03$). No association between baseline levels of either VEGF or PAI-1 with RR or OS was observed. However, plasma levels of both PAI-1 & VEGF were significantly inter-related & trended together ($p < 0.0001$), & both decreased significantly after treatment ($p = 0.0004$ & 0.04 , respectively). Median decrease: OPN: 17%, PAI: 44%, VEGF: 42%. No significant differences were observed between study arms, suggesting that OPN is prognostic in NSCLC, but not predictive for response to tirapazamine. **Conclusions:** 1) There is a great need for development of tumor biomarkers which can be serially assessed pre- & post-therapy. 2) High OPN plasma levels were significantly associated with reduced RR & OS for patients on this trial. OPN is a strong candidate for inclusion in a panel of prognostic (& perhaps predictive) markers for NSCLC. Supported by the Hope Foundation & R01-CA107228.

7197 General Poster Session (Board #U6), Sun, 8:00 AM - 12:00 PM

The influence of tumor size, histological differentiation and smoking history in patients with completely resected stage I adenocarcinoma of the lung. *M. Tsuboi, H. Kato, Y. Ichinose, M. Ohta, E. Hata, N. Tsubota, H. Tada, H. Wada, N. Hamajima, M. Ohta, the Japan Lung Cancer Research Group on Postsurgic; Tokyo Medical University, Tokyo, Japan; National Kyushu Cancer Center, Fukuoka, Japan; National Okinawa Hospital, Okinawa, Japan; Mitsui Memorial Hospital, Tokyo, Japan; Hyogo Medical Center, Akashi, Japan; Osaka City General Hospital, Osaka, Japan; Kyoto University, Kyoto, Japan; Nagoya University, Nagoya, Japan*

Background: To test the hypothesis that patients with completely resected p-stage I adenocarcinoma [Ad.] of the lung contain a favorable subgroup of patients with well differentiated histology and tumor 2.0 cm or less in greatest dimension, we analyzed the results of the JLCRG trial (a randomized prospective trial of adjuvant chemotherapy with Uraclil-Tegafu for stage I adenocarcinoma of the lung) by tumor size, smoking history, degree of histological differentiation and more. **Methods:** Patients were randomized to receive either oral uracil-tegafu (250 mg of tegafu m^2/day) for 2 years postoperatively or no adjuvant treatment. Multivariate analyses and interactions with the Cox proportional-hazards model were used to estimate the simultaneous effects of prognostic factors on survival. **Results:** The 5-year survival rate of the 412 patients with tumor 2cm or less in size was 89.8% (95% confidence interval [CI]: 86.8 to 92.8) versus 84.4% (95% CI: 81.3–87.4) for the 569 patients with tumor more than 2cm in size (median follow-up 72 months, $p = 0.002$). Although univariate analysis demonstrated improved survival for the patients with no smoking history and female gender, the selected covariates by multivariate analysis were as follows: age (hazard ratio [HR] for patients aged 70 years or more, 2.25; 95% CI: 1.58 to 3.14, $p < 0.0001$), tumor size (HR for more than 2cm in size, 1.55; 95% CI: 1.10 to 2.21, $p = 0.012$), histological differentiation (HR for moderate and poor differentiation, 1.75, 95% CI: 1.25 to 2.47, $p = 0.001$), and treatment group (HR for the uracil-tegafu group, 0.68; 95% CI: 0.49 to 0.94, $p = 0.02$). For these prognostic factors, there was only one significant interaction between tumor size and the adjuvant treatment. **Conclusions:** 1) Patients with completely resected stage I Ad. of the lung contain a favorable subgroup of patients with aged less than 70 years, well differentiated histology, and a maximum tumor dimension of 2.0 cm or less. 2) Adjuvant chemotherapy with oral uracil-tegafu should also be considered for stage I Ad. patients more than 2 cm in tumor size. 3) 2cm in tumor size might be a good benchmark candidate of the description of T factor to facilitate treatment strategies and revisions of the TNM staging system.

7199 General Poster Session (Board #U8), Sun, 8:00 AM - 12:00 PM

The relationship between RASSF1A aberrant methylation and survival in small sized lung adenocarcinoma. *K. Miyajima, T. Ohira, J. Usuda, H. Saji, M. Tsuboi, T. Hirano, H. Kato, M. Suzuki, S. Toyooka, A. F. Gazdar; Tokyo Medical University, Tokyo, Japan; University of Texas Southwestern Medical Center, Dallas, TX*

Background: Aberrant methylation of CpG islands in promoter regions of tumor cells is one of the major mechanisms for silencing of tumor suppressor genes. The RAS association domain family 1A (RASSF1A) gene was isolated from the 3p21.3 region homozygously deleted in lung cancer cell lines, and it was shown to be inactivated by hypermethylation of the promoter region in lung cancers. In this study, we investigated the clinicopathological significances of RASSF1A methylation in the development and/or progression of small-sized (less than 2.0cm) lung adenocarcinoma. It is important to identify a marker for high-risk early stage patients who should benefit from new investigational adjuvant therapies. **Methods:** Surgically resected specimens from 77 cases of small-sized primary lung adenocarcinoma. We determined the frequency of aberrant promoter methylation of the RASSF1A genes in small-sized adenocarcinoma. Aberrant promoter methylation was examined using methylation-specific PCR (MSP). **Results:** Twenty-five of 77 (32.5%) tumors showed RASSF1A methylation. RASSF1A methylation was dominantly detected in smoker ($P < 0.03$). There was no significant correlation of RASSF1A methylation with gender, age, T stage, N stage and pathological stage. RASSF1A methylation correlated with adverse survival by univariate analysis ($P < 0.005$) as well as multivariate analysis ($P = 0.0062$; RR 4.251; 95% C.I., 1.507–11.993). Furthermore, RASSF1A promoter hypermethylation in resected stage I small-sized lung adenocarcinoma was associated with impaired patient survival ($P < 0.01$). **Conclusions:** Aberrant promoter methylation of the RASSF1A was present in 25 of 77 (32.5%) of small-sized lung adenocarcinoma by MSP assay. These results indicated that epigenetic inactivation of RASSF1A plays an important role in the progression of small-sized lung adenocarcinoma, and that RASSF1A hypermethylation appears to be a useful molecular marker for the prognosis of patients with small-sized and stage I lung adenocarcinoma. RASSF1A is a potential tumor suppressor gene that undergoes epigenetic inactivation in lung adenocarcinoma through hypermethylation of its promoter region. RASSF1A methylation was significantly related to unfavorable prognosis in small-sized lung adenocarcinoma.