

## *Editorial*

# Oxidative stress and apoptosis in hepatitis C: the core issue

Article on page 257

### **Hepatitis C virus core protein inhibits deoxycholic acid-mediated apoptosis despite generating mitochondrial reactive oxygen species**

HARA Y, HINO K, OKUDA M, et al.

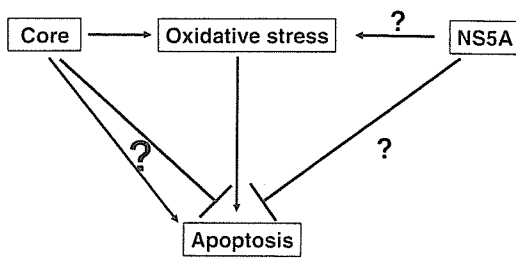
Extra- as well as intracellular stimuli elicit a wide range of responses, such as cell proliferation, differentiation, survival and apoptosis, via the regulation of intracellular signaling. Recent studies have revealed that stress-responsive signal transduction pathways are stringently regulated by the intracellular redox state.<sup>1</sup> The redox state of the cell is determined by the delicate balance between the levels of oxidizing and reducing equivalents, including reactive oxygen species (ROS) and endogenous antioxidants. The production of ROS, a representative of oxidative stress, fluctuates in response to alterations in both external and internal environments and, in turn, triggers specific signaling cascades, such as mitogen-activated protein kinases, which determine cell survival or death. Thus, ROS are profoundly involved in cell death or apoptosis.

In the liver, ROS are also key cytotoxic and signaling mediators in the pathophysiology of liver diseases, including viral hepatitis, in which hepatocytes and resident and infiltrating phagocytes can generate ROS. While ROS are able to cause cell death through massive lipid peroxidation, they also act to modulate signal transduction pathways by affecting redox-sensitive enzymes, transcription factors, and organelles, including mitochondria and endoplasmic reticulum. ROS, thus, directly regulate apoptotic and necrotic cell death.<sup>2</sup> In addition, ROS have indirect effects on the pathophysiology of cell death by supporting protease activity via inactivation of antiproteases.

In hepatitis C virus (HCV) infection, both ROS and apoptosis are closely involved in the process of progressive liver diseases from chronic hepatitis to cirrhosis and hepatocellular carcinoma (HCC).<sup>3–7</sup> ROS are assumed to play a major role in the pathogenesis of chronic hepatitis, which is characterized by continual

cell death followed by regeneration. In this condition, the viral proteins of HCV, the core and nonstructural (NS) 5A proteins, have been shown to play a role in inducing ROS as well as in modulating apoptosis of hepatocytes.

The HCV genome comprises the genes of four structural proteins and six nonstructural proteins, and at least two of these viral proteins have been reported to cause oxidative stress in cells. The core protein, a structural protein, has been found to have various actions, including the induction of oxidative stress and the accumulation of lipids, in experimental studies using cultured cells and transgenic mice.<sup>7,8</sup> Experiments using mice transgenic for the core gene showed increased ROS production, increased intrahepatic catalase activity, a decreased intrahepatic glutathione (GSH) level, and a decreased GSH/GSH-GSSG (dimeric oxidized glutathione) ratio, indicating inhibition of antioxidation effects, although there was neither an increase in the serum alanine aminotransferase (ALT) level nor a histological finding of hepatitis.<sup>7</sup> Increased levels of intrahepatic peroxide lipids in the core gene transgenic mice with aging, compared with levels in control mice, also indicate an increase in oxidative stress. One possible mechanism underlying oxidative stress induction by the core protein is mitochondrial damage. Morphological abnormalities of the mitochondria have been observed in core gene transgenic mouse liver,<sup>7</sup> and increased ROS production caused by damage to the mitochondrial electron transport system has been noted in core protein-expressing cells.<sup>8</sup> Mitochondrial DNA, which has no protective proteins such as histone, is susceptible to damage by ROS. Mitochondrial DNA damage in the core gene transgenic mice appeared when they were as young as 3 months old. This mitochondrial damage disrupts the synthesis of proteins constituting the electron transport system complex and might also increase oxidative stress caused by damage to the electron transport system.



**Fig. 1.** Relationships among oxidative stress, apoptosis, and HCV proteins

A study using a cell culture system demonstrated that the NS5A protein also causes oxidative stress. NS5A induces the endoplasmic reticulum to release calcium by causing stress to the endoplasmic reticulum, and this release leads to increased ROS production in the mitochondria.<sup>9</sup> Although the effect of NS5A has not yet been confirmed by other study groups, HCV has the direct action of increasing intracellular ROS production via its proteins, separate from the induction of oxidative stress as a result of inflammation caused by viral infection (Fig. 1). A report that oxidative stress is also observed in HCV carriers with a normal ALT level<sup>10</sup> indicates that it is induced directly, without any mediating inflammatory reactions being necessary.

In contrast to the production of ROS by the core protein, which is now quite evident, the role of HCV core protein in apoptosis is rather controversial. Regarding the HCV-induced apoptotic mechanism, the HCV core protein may have a regulatory function in modulating apoptosis, either by enhancing or inhibiting it. In particular, the core protein exhibits both proapoptotic and antiapoptotic actions, depending on experimental conditions and the type of cells used,<sup>11-14</sup> whereas both the NS3 and the NS5A proteins have antiapoptotic effects (Fig. 1).<sup>15</sup> Modulation of apoptosis may involve binding of the core protein to the intracellular signal transducing portion of death receptors such as TNF- $\alpha$ , Fas, or lymphotoxin- $\alpha\beta$ . Thus, HCV proteins may modulate hepatocyte apoptosis by indirect rather than by direct mechanisms. The real role of the core protein in the apoptotic process is, thus, not defined yet.

In the current issue of *Journal of Gastroenterology*, Hara et al.<sup>16</sup> tried to elucidate this core issue of HCV pathogenesis by separating the two properties of the HCV core protein with cultured cells, Huh-7 and HeLa. They confirmed that the core protein induced ROS, which was followed by activation of the scavenging system and insults to the cellular DNA, as shown previously.<sup>6</sup> In the study by Hara et al.,<sup>16</sup> the core protein inhibited the proapoptotic action of deoxycholic acid (DCA), which is known to cause both ROS production and apoptosis. Thus, the core protein seems to act to

oppose the proapoptotic function of ROS, which ROS are also induced by the core protein itself. Such apparently opposing actions of the core protein, the production of ROS and the inhibition of apoptosis, might well explain the mode of hepatocarcinogenesis in HCV infection: hepatocytes with ROS-induced DNA damage may evade apoptosis by another effect of the core protein that inhibits apoptosis. Such a mechanism, similar to one previously postulated by other researchers,<sup>3</sup> in which both ROS production and mitogen-activated protein kinase activation are ascribed to the core protein, may clarify how cells with DNA damage can survive and develop into buds of HCC. Regrettably, the current study was done using DCA as an agent to induce both apoptosis and ROS, making it difficult to interpret the authentic role of the core protein in the execution of such biological functions. As noted above, the effect of the core protein in apoptosis varies depending on the system used. Therefore, further studies using different systems may be necessary to bring a conclusion to the core issue of HCV-induced pathogenesis associated with the multipotential HCV core protein.

Kazuhiko Koike, MD, PhD

Department of Infectious Diseases, Internal Medicine, Graduate School of Medicine, University of Tokyo, 7-3-1 Hongo, Bunkyo-ku, Tokyo 113-8655, Japan

## References

- Schattenberg JM, Singh R, Wang Y, Lefkowitz JH, Rigoli RM, Scherer PE, et al. JNK1 but not JNK2 promotes the development of steatohepatitis in mice. *Hepatology* 2006;43:163-72.
- Rahman I, Biswas SK, Jimenez LA, Torres M, Forman HJ. Glutathione, stress responses, and redox signaling in lung inflammation. *Antioxid Redox Signal* 2005;7:42-59.
- Koike K. Molecular basis of hepatitis C virus-associated hepatocarcinogenesis: lessons from animal model studies. *Clin Gastroenterol Hepatol* 2005;3:S132-5.
- Tanikawa K. Pathogenesis and treatment of hepatitis C virus-related liver diseases. *Hepatobiliary Pancreat Dis Int* 2004;3:17-20.
- Farinati F, Cardin R, De Maria N, Della Libera G, Marafin C, Lecis E, et al. Iron storage, lipid peroxidation and glutathione turnover in chronic anti-HCV positive hepatitis. *J Hepatol* 1995; 22:449-56.
- Kitase A, Hino K, Furutani T, Okuda M, Gondo T, Hidaka I, et al. In situ detection of oxidized n-3 polyunsaturated fatty acids in chronic hepatitis C: correlation with hepatic steatosis. *J Gastroenterol* 2005;40:617-24.
- Moriya K, Nakagawa K, Santa T, Shintani Y, Fujie H, Miyoshi H, et al. Oxidative stress in the absence of inflammation in a mouse model for hepatitis C virus-associated hepatocellular carcinogenesis. *Cancer Res* 2001;61:4365-70.
- Okuda M, Li K, Beard MR, Showalter LA, Scholle F, Lemon SM, et al. Mitochondrial injury, oxidative stress, and antioxidant gene expression are induced by hepatitis C virus core protein. *Gastroenterology* 2002;122:366-75.
- Gong G, Waris G, Tanveer R, Siddiqui A. Human hepatitis C virus NS5A protein alters intracellular calcium levels, induces

- oxidative stress, and activates STAT-3 and NF- $\kappa$ B. *Proc Natl Sci U S A* 2001;98:9599–604.
10. Vendemiale G, Grattagliano I, Portincasa P, Serviddio G, Palasciamo G, Altomare E. Oxidative stress in symptom-free HCV carriers: relation with ALT flare-up. *Eur J Clin Invest* 2001;31:54–63.
  11. Ruggieri A, Harada T, Matsuura Y, Miyamura T. Sensitization to Fas-mediated apoptosis by hepatitis C virus core protein. *Virology* 1997;229:68–76.
  12. Ray RB, Meyer K, Steele R, Shrivastava A, Aggarwal BB, Ray R. Inhibition of tumor necrosis factor (TNF- $\alpha$ )-mediated apoptosis by hepatitis C virus core protein. *J Biol Chem* 1998;273:2256–9.
  13. Zhu N, Khoshnan A, Schneider R, Matsumoto M, Dennert G, Ware C, et al. Hepatitis C virus core protein binds to the cytoplasmic domain of tumor necrosis factor (TNF) receptor 1 and enhances TNF-induced apoptosis. *J Virol* 1998;72:3691–7.
  14. Marusawa H, Hijikata M, Chiba T, Shimotohno K. Hepatitis C virus core protein inhibits Fas- and tumor necrosis factor  $\alpha$ -mediated apoptosis via NF- $\kappa$ B activation. *J Virol* 1999;73:4713–20.
  15. Macdonald A, Harris M. Hepatitis C virus NS5A: tales of a promiscuous protein. *J Gen Virol* 2004;85:2485–502.
  16. Hara Y, Hino K, Okuda M, Furutani T, Hidaka I, Yamaguchi Y, et al. Hepatitis C virus core protein inhibits deoxycholic acid-mediated apoptosis despite generating mitochondrial reactive oxygen species. *J Gastroenterol* 2006;41:257–68.



RAPID COMMUNICATION

## Risk factors for retinopathy associated with interferon $\alpha$ -2b and ribavirin combination therapy in patients with chronic hepatitis C

Chiaki Okuse, Hiroshi Yotsuyanagi, Yoshihiko Nagase, Yuhtaro Kobayashi, Kiyomi Yasuda, Kazuhiko Koike, Shiro Iino, Michihiro Suzuki, Fumio Itoh

Chiaki Okuse, Yoshihiko Nagase, Yuhtaro Kobayashi, Michihiro Suzuki, Fumio Itoh, Division of Gastroenterology and Hepatology, Department of Internal Medicine, St. Marianna University School of Medicine, Kawasaki, Kanagawa, 216-8511, Japan  
Hiroshi Yotsuyanagi, Kazuhiko Koike, Department of Infectious Diseases, Internal Medicine, Faculty of Medicine, University of Tokyo, 7-3-1, Hongo, Bunkyo, Tokyo 113-8655, Japan  
Kiyomi Yasuda, Shiro Iino, Center for Liver Diseases, Kiyokawa Hospital, Minamiasagaya, Sugunami, Tokyo, 166-0004, Japan  
Correspondence to: Dr. Hiroshi Yotsuyanagi, Department of Infectious Diseases, Internal Medicine, Faculty of Medicine, University of Tokyo, 7-3-1, Hongo, Bunkyo, Tokyo 113-8655, Japan. hyotsu-tyk@umin.ac.jp  
Telephone: +81-3-58008720 Fax: +81-3-58008796  
Received: 2006-01-13 Accepted: 2006-02-18

**CONCLUSION:** Retinopathy associated with combination therapy of interferon  $\alpha$ -2b and ribavirin tends to develop in patients with hypertension.

© 2006 The WJG Press. All rights reserved.

**Key words:** Retinopathy; Ribavirin; Chronic hepatitis C; Interferon

Okuse C, Yotsuyanagi H, Nagase Y, Kobayashi Y, Yasuda K, Koike K, Iino S, Suzuki M, Itoh F. Risk factors for retinopathy associated with interferon  $\alpha$ -2b and ribavirin combination therapy in patients with chronic hepatitis C. *World J Gastroenterol* 2006; 12(23): 3756-3759

<http://www.wjgnet.com/1007-9327/12/3756.asp>

### Abstract

**AIM:** To elucidate the frequency and risk factors for retinopathy in patients with chronic hepatitis C who are treated by interferon-ribavirin combination therapy.

**METHODS:** We prospectively analyzed 73 patients with histologically confirmed chronic hepatitis C, who underwent combination therapy for 24 wk. Optic fundi were examined before, and 2, 4, 12 and 24 wk after the start of combination therapy.

**RESULTS:** Fourteen patients (19%) developed retinopathy, which was initially diagnosed by the appearance of a cotton wool spot in 12 patients. Retinal hemorrhage was observed in 5 patients. No patient complained of visual disturbance. Retinopathy disappeared in 9 patients (64%) despite the continuation of combination therapy. However, retinopathy persisted in 5 patients with retinal hemorrhage. A comparison of the clinical background between the groups with and without retinopathy showed no significant differences in age, gender, viral genotype, RNA level, white blood cell count, platelet count, prothrombin time, complications by diabetes mellitus or hypertension, or pretreatment arteriosclerotic changes in the optic fundi. However, multiple logistic regression analysis revealed that complication by hypertension was observed with a high frequency in the group with retinopathy ( $P = 0.004$ , OR = 245.918, 95% CI = 5.6-10786.2).

### INTRODUCTION

Chronic hepatitis C, which affects more than 170 million people in the world<sup>[1]</sup>, may eventually lead to cirrhosis and/or hepatocellular carcinoma. The main treatment for this intractable disease is interferon administration. Published guidelines recommend interferon-ribavirin combination therapy as a first-line treatment<sup>[2]</sup>. Interferon is also used in the treatment of other viral and neoplastic diseases.

Various adverse effects have been reported due to use of interferon<sup>[3]</sup>. An influenza-like syndrome, characterized by fever, chills, myalgias, arthralgias, and headache, is the most common adverse effect. Toxicities of the central nervous, hematopoietic, gastrointestinal, urinary, cardiovascular, musculoskeletal and endocrine systems have also been described. However, ocular toxicity was not reported before the use of interferon for chronic hepatitis<sup>[3]</sup>.

After the introduction of interferon for the treatment of hepatitis, retinal complications have been reported. Hayakawa *et al* showed that 17 of 43 patients developed retinopathy during interferon monotherapy. They also showed that the prevalence of retinopathy was higher in patients with diabetes<sup>[4]</sup>. Subsequently, several papers have shown that a substantial proportion of patients undergoing interferon monotherapy develop retinopathy<sup>[5-7]</sup>. However, the prevalence of retinopathy is variable, which is

presumably attributed to the difference in the treatment regimen and/or background of patients.

As mentioned above, interferon-ribavirin combination therapy has become the standard treatment for chronic hepatitis C. Results from recent studies have suggested that the prevalence of retinopathy associated with combination therapy may be higher than that associated with interferon monotherapy, which should be further investigated<sup>[8-10]</sup>.

In spite of the high prevalence, risk factors for interferon-associated retinopathy are still unclear. Diabetes mellitus and the patients' age were reported to be possible risk factors for retinopathy associated with interferon monotherapy<sup>[4]</sup>. In interferon-ribavirin combination therapy, diabetes, hypertension<sup>[8]</sup>, and response to treatment<sup>[10]</sup> were considered possible risk factors. However, the results are not conclusive because of the small number of patients examined.

The aim of the present study is to elucidate the prevalence and risk factors for retinopathy associated with interferon-ribavirin combination therapy.

## MATERIALS AND METHODS

### Patients

Seventy-three consecutive patients with histologically confirmed chronic hepatitis C (47 males and 26 females; median age, 53.4 years; ranges 26-73 years) were enrolled in this study from 2002 to 2004. The clinical backgrounds of the enrolled patients are shown in Table 1. All patients were treated with recombinant interferon  $\alpha$ -2b (Intron A, Schering-Plough, Kenilworth, NJ, USA) and ribavirin (Rebetol; Schering-Plough, Kenilworth, NJ, USA) combination therapy. All the patients were treated daily with interferon  $\alpha$ -2b at 6 MU for 2 wk followed by three times a wk treatment with interferon  $\alpha$ -2b at 6 MU for 22 wk in combination with ribavirin. Ribavirin was given orally twice a day at a total daily dose of 600 mg for patients who weighed 60 kg or less and 800 mg for the remaining patients who weighed more than 60 kg for 24 wk.

All patients were assessed to determine the safety, tolerance, and efficacy of the treatment at the end of wk 1, 2, 4, and every 4 wk during the treatment. After the treatment was completed, patients were followed up on wk 4, 8, 12, and 24. The primary end point was indicated by a sustained loss of detectable HCV-RNA at 24 wk after the treatment.

### Methods

Optic fundi were examined before, and 2, 4, 12 and 24 wk after the start of combination therapy. Ophthalmological examinations were carried out before the start of treatment and 2, 4, 12 and 24 wk after the start of treatment until the completion of treatment or until the retinopathy disappeared. Fundus photographs were taken for documentation and comparison when retinal abnormalities were detected.

Informed consent was obtained from each patient. The study protocol conformed to the ethical guidelines of the 1975 Declaration of Helsinki and was approved by the Ethics Committees of our institutions.

**Table 1 Profiles and initial laboratory data of patients with and without retinopathy during IFN-ribavirin combination therapy<sup>1</sup>**

	Total	Retinopathy (+)	Retinopathy (-)
<b>Patients</b>			
Number	73	14	59
Age (yr)	53.4 ± 10.9	56.3 ± 10.5	52.8 ± 10.6
Gender (M/F)	47/26	10/4	37/22
Hypertension (Yes/No) <sup>a</sup>	15/58	5/8	10/49
Diabetes mellitus (Yes/No)	2/71	1/13	1/58
<b>Peripheral blood count</b>			
Platelet count ( $\times 10^3/\text{mm}^3$ )	15.3 ± 6.0	12.5 ± 10.5	15.9 ± 38.6
White blood cell ( $\times 10^3/\text{mm}^3$ )	46.9 ± 12.6	46.5 ± 13.0	48.6 ± 10.9
Hemoglobin (g/dL)	14.0 ± 1.3	14.0 ± 1.0	14.0 ± 1.4
Prothrombin time (%)	90.2 ± 13.3	87.1 ± 13.3	90.8 ± 13.3
ALT (IU/L)	109.4 ± 78.2	104.1 ± 41.0	110.4 ± 83.6
<b>Viral factors</b>			
Genotype (type 1/type 2) <sup>2</sup>	45/26	33/24	12/2
Viral load (kcopies/mL)	592.3 ± 271.2	505.6 ± 309.1	607.5 ± 271.2
Pretreatment/Arteriosclerotic changes in optic fundi (Yes/No)	12/61	7/7	5/54
Response to therapy (SVR/non-SVR)	38/35	5/9	33/26

<sup>1</sup> Data are expressed as mean ± SD.

<sup>2</sup> Genotype could not be determined in 2 patients.

<sup>a</sup>  $P = 0.004$

## RESULTS

Before the start of the combination therapy, one patient had scars from laser coagulation of a previous interferon-associated retinopathy and another patient had retinal central vein occlusion. Arteriosclerotic changes of the optic fundi were observed in 12 patients.

After the start of interferon-ribavirin combination therapy, 14 out of 73 patients (19%) developed retinopathy. The clinical profiles and laboratory data of the patients with and without retinopathy are shown in Table 1.

We compared the characteristics of patients who developed retinopathy and those who did not. The two groups showed no statistical differences in age, gender, subtype of virus, RNA level, white blood cell count, platelet count, prothrombin time before treatment or prevalence of pretreatment fundic arteriosclerotic changes. The patients with retinopathy were more frequently complicated by hypertension ( $P = 0.004$ ) (Table 1).

Logistic regression analysis of factors affecting retinopathy was also carried out. Hypertension was found to be a factor for predicting retinopathy (Table 2).

Table 3 shows the optic fundi findings of the 14 patients with retinopathy. Retinopathy was initially diagnosed by the appearance of a cotton wool spot in 12 patients. In three of the 12 patients, retinal hemorrhage was also observed simultaneously or sequentially. Two of the 14 patients who developed retinopathy were diagnosed by retinal hemorrhage without a cotton wool spot. No patient complained of the visual disturbance.

**Table 2** Logistic regression analysis of factors associated with retinopathy

Factor	P	Odds ratio	95% confidence interval
Sex	0.68	1.699	0.1-21.0
Age	0.203	1.099	1.0-1.3
Genotype	0.776	1.621	0.1-45.5
Levels of HCV RNA	0.114	1.006	0.99-1.0
Hypertension	0.004	246.32	5.5-10977.8
Diabetes mellitus	0.211	0.122	0.1-3.3
Abnormal findings in pretreatment optic fundi	0.904	1.192	0.1-20.3
Platelet	0.059	1.391	1.0-1.9
Prothrombin time	0.747	0.982	0.9-1.1
ALT	0.992	1	0.98-1.0
WBC	0.964	1.027	0.4-2.9
Response to therapy (SVR or non-SVR)	0.123	0.016	0.0-3.1

Retinopathy disappeared in 9 of the 14 patients despite the continuation of combination therapy. However, it continued in three patients with retinal hemorrhage and two without retinal hemorrhage.

Ocular manifestations other than retinopathy (e.g., ocular pain, a mild watery eye and conjunctivitis) were not observed in any patients.

## DISCUSSION

Interferon associated retinopathy was first recognized in 1990 when Ikebe and associates reported a 39-year-old patient who developed retinal hemorrhages and cotton wool spots following intravenous administration of interferon<sup>[11]</sup>.

The exact mechanism of interferon-induced-retinopathy is not known but is presumably related to the disturbance in retinal microcirculation<sup>[12]</sup>. Therefore, preexisting arteriosclerosis that affects microcirculation may promote interferon-induced retinopathy.

Our study shows that hypertension is a more frequent complication in patients with interferon-induced-retinopathy. Chronic hypertension is associated with the thickening of the walls of the arteries and small arterioles<sup>[13]</sup>. Therefore, systemic hypertension predisposes patients to interferon-induced-retinopathy. The fact that hypertensive retinopathy induces the formation of flame-shaped hemorrhages and white cotton wool spots, which are also seen in interferon-induced-retinopathy, implies that systemic hypertension and interferon-induced-retinopathy may be related each other.

Statistical analysis did not indicate pretreatment optic fundic changes or diabetes as predictive factors of retinopathy. This may be attributed to the following reasons: (1) pretreatment changes in the optic fundi as a predictive factor are included in hypertension; and (2) the number of patients with diabetes is too small. Regardless of these reasons, systemic hypertension is an important risk factor for interferon-related retinopathy.

The frequencies of interferon-induced retinopathy associated with interferon monotherapy and interferon-

**Table 3** Optic fundi findings of patients with retinopathy

No	Age	Sex	Underlying disease	Optic fundi before treatment	Optic fundi after treatment			
			Hyper tension	H	S	Cotton wool spot	Retinal hemorrhage	
1	38	M	+	+	0	0	4 wk-	4 wk-
2	52	M	+	-	1	0	4-12 wk	-
3	40	M	-	-	0	0	6-36 wk	-
4	62	F	-	-	0	0	4-36 wk	-
5	61	M	+	-	0	0	12 wk-	-
6	58	M	-	-	1	1	12 wk-	-
7	73	M	-	-	2	2	4-28 wk	-
8	65	F	+	-	0	0	24-36 wk	-
9	59	F	+	-	2	2	2 wk-	4-24 wk
10	40	M	-	-	0	0	4-20 wk	-
11	62	F	-	-	1	2	2 wk-	4 wk-
12	65	M	-	-	1	1	2-24 wk	-
13	40	M	-	-	0	0	-	8-16 wk
14	40	M	-	-	0	0	-	2-4 wk

on-ribavirin combination therapy are reported to be 24%-58%<sup>[4,7,14,15]</sup> and 16%-64%<sup>[8-10,16]</sup>, respectively. The frequency in the present study (20%) was lower than that in previous reports. Furthermore, the ocular side effects of ribavirin, which include a mild watery eye and conjunctivitis, were not seen in this study. Therefore, the frequency of induced retinopathy associated with combination therapy may be considered as high as that associated with interferon monotherapy.

Retinopathy developed by 12 wk in most (13/14, 93%) of the patients after the start of combination therapy and disappeared in majority (10/14, 71%) of the patients during the 4-8 wk period, in which the patients were receiving the treatment. This suggests that treatment can be continued despite the development of retinopathy in many patients. However, two patients who developed cotton wool spots early in the therapy (2 wk) thereafter suffered from retinal hemorrhage in a prolonged manner. Therefore, patients who develop cotton wool spots early in the therapy should be carefully monitored. However, as reported in previous studies<sup>[4,8,17]</sup>, most of the patients with retinopathy in this study were asymptomatic. Therefore, combination therapy may be continued in most patients.

The fact that retinopathy occurred more frequently in patients with hypertension, suggests that these patients should be carefully monitored. With periodic examination of the optic fundi, major bleeding that causes visual symptoms may be prevented or detected at an early stage. Therefore, patients who undergo interferon-ribavirin combination therapy, particularly those with hypertension, should undergo periodic examination of the optic fundi. To conclude, retinopathy associated with combination therapy of interferon  $\alpha$ -2b and ribavirin tends to develop in patients with hypertension.

## REFERENCES

- Hepatitis C-global prevalence (update). *Wkly Epidemiol Rec* 1999; 74: 425-427

- 2 **Strader DB**, Wright T, Thomas DL, Seeff LB. Diagnosis, management, and treatment of hepatitis C. *Hepatology* 2004; **39**: 1147-1171
- 3 **Quesada JR**, Talpaz M, Rios A, Kurzrock R, Gutterman JU. Clinical toxicity of interferons in cancer patients: a review. *J Clin Oncol* 1986; **4**: 234-243
- 4 **Hayasaka S**, Fujii M, Yamamoto Y, Noda S, Kurome H, Sasaki M. Retinopathy and subconjunctival haemorrhage in patients with chronic viral hepatitis receiving interferon alfa. *Br J Ophthalmol* 1995; **79**: 150-152
- 5 **Sugano S**, Suzuki T, Watanabe M, Ohe K, Ishii K, Okajima T. Retinal complications and plasma C5a levels during interferon alpha therapy for chronic hepatitis C. *Am J Gastroenterol* 1998; **93**: 2441-2444
- 6 **Kawano T**, Shigehira M, Uto H, Nakama T, Kato J, Hayashi K, Maruyama T, Kuribayashi T, Chuman T, Futami T, Tsubouchi H. Retinal complications during interferon therapy for chronic hepatitis C. *Am J Gastroenterol* 1996; **91**: 309-313
- 7 **Saito H**, Ebinuma H, Nagata H, Inagaki Y, Saito Y, Wakabayashi K, Takagi T, Nakamura M, Katsura H, Oguchi Y, Ishii H. Interferon-associated retinopathy in a uniform regimen of natural interferon-alpha therapy for chronic hepatitis C. *Liver* 2001; **21**: 192-197
- 8 **Cuthbertson FM**, Davies M, McKibbin M. Is screening for interferon retinopathy in hepatitis C justified? *Br J Ophthalmol* 2004; **88**: 1518-1520
- 9 **Schulman JA**, Liang C, Kooragayala LM, King J. Posterior segment complications in patients with hepatitis C treated with interferon and ribavirin. *Ophthalmology* 2003; **110**: 437-442
- 10 **Jain K**, Lam WC, Waheeb S, Thai Q, Heathcote J. Retinopathy in chronic hepatitis C patients during interferon treatment with ribavirin. *Br J Ophthalmol* 2001; **85**: 1171-1173
- 11 **Ikebe T**, Nakatsuka K and Goto M. A case of retinopathy induced by intravenous administration of interferon. *Folia Ophthalmol Jpn (Ganka-Kiyo)* 1990; **41**: 2291-2296 (in Japanese)
- 12 **Guyer DR**, Yannuzzi LA, Chang S, Shields JA, Green WR. *Rerina-Vitreous-Macula*. 1st ed. Philadelphia: W.B. Saunders, 1999: 864
- 13 **Sharrett AR**, Hubbard LD, Cooper LS, Sorlie PD, Brothers RJ, Nieto FJ, Pinsky JL, Klein R. Retinal arteriolar diameters and elevated blood pressure: the Atherosclerosis Risk in Communities Study. *Am J Epidemiol* 1999; **150**: 263-270
- 14 **Hejny C**, Sternberg P, Lawson DH, Greiner K, Aaberg TM Jr. Retinopathy associated with high-dose interferon alfa-2b therapy. *Am J Ophthalmol* 2001; **131**: 782-787
- 15 **Kadayifcilar S**, Boyacioglu S, Kart H, Gursoy M, Aydin P. Ocular complications with high-dose interferon alpha in chronic active hepatitis. *Eye* 1999; **13** ( Pt 2): 241-246
- 16 **Chisholm JA**, Williams G, Spence E, Parks S, Keating D, Gavin M, Mills PR. Retinal toxicity during pegylated alpha-interferon therapy for chronic hepatitis C: a multifocal electroretinogram investigation. *Aliment Pharmacol Ther* 2005; **21**: 723-732
- 17 **Guyer DR**, Tiedeman J, Yannuzzi LA, Slakter JS, Parke D, Kelley J, Tang RA, Marmor M, Abrams G, Miller JW. Interferon-associated retinopathy. *Arch Ophthalmol* 1993; **111**: 350-356

S- Editor Pan BR E-Editor Liu Y

Kazuhiko Koike

## Antiviral treatment of hepatitis C: present status and future prospects

Received: June 7, 2006

**Abstract** Hepatitis C virus (HCV) infection is a major cause of chronic hepatitis. A substantial proportion of patients with chronic hepatitis C eventually develop hepatocellular carcinoma (HCC), which is one of the leading causes of death worldwide. Therefore, efficient antiviral treatments for HCV have long been needed. A recently developed combination therapy of pegylated interferon and ribavirin has dramatically improved the outcome of antiviral therapy for HCV infection. In genotype 1b HCV infection, 48 weeks of the combination therapy achieved eradication of the virus in 50% of patients, and in genotype 2 HCV infection, 24 weeks of the therapy resulted in viral eradication in 80%–90% of patients. By this eradication, an improvement in the hepatic fibrosis, an inhibition of HCC development, and an improvement in life expectancy were attained. Patients who did not respond to the combination therapy may be treated with long-term interferon monotherapy, which is not intended to eradicate HCV, but will lower the serum alanine aminotransferase (ALT) level. Thus, the treatment for HCV infection has progressed significantly, but therapies with new modalities, such as inhibitors of viral protease or RNA polymerase, are still being awaited.

**Key words** Hepatitis C · Interferon · Treatment

### Introduction

Hepatitis viruses mainly infect the liver, causing hepatic diseases in humans. To date, five types of hepatitis virus, B, A, D, E, and C, have been found, in this order, and sub-

jected to medical treatment. Hepatitis C virus (HCV) and hepatitis B virus (HBV) infections can develop into persistence, while hepatitis A virus and hepatitis E virus cause only transient infection. In Japan, chronic hepatitis caused by HCV infection currently poses the greatest problem because of the large number of patients affected and the high rate of patient mortality from complications, particularly hepatocellular carcinoma (HCC).<sup>1</sup>

### Chronic hepatitis C

It is estimated that there are approximately 170 million HCV carriers or patients with persistent HCV worldwide, and approximately 1.8 million patients in Japan. HCV infection occurs when blood contaminated with HCV enters the body directly. The infection routes include blood transfusion with HCV-contaminated blood products obtained a long time ago, sharing of needles among drug abusers, and the use of inappropriately disinfected acupuncture needles and tattoo needles, among others.<sup>2</sup> People undergoing folk remedies and hair-removal treatments should also be regarded as susceptible to HCV infection if these are invasive practices and nondisposable devices are used.

The problem with HCV infection resides in the very high rate of general HCV infections which are becoming chronic (approximately 70%). However, in the case of HCV infection via blood transfusion, the rate of reaching chronicity has been reported to reach 80%, probably because of a high virus load.

### Virus markers of HCV infection required for the treatment of hepatitis

Some virus markers of HCV infection are available, as described below. Figure 1 shows a progress observation flowchart for anti-HCV antibody-positive patients obtained using these virus markers.

K. Koike (✉)  
Department of Infectious Diseases, Internal Medicine, Graduate School of Medicine, University of Tokyo, 7-3-1 Hongo, Bunkyo-ku, Tokyo 113-8655, Japan  
Tel. +81-3-5800-8800; Fax +81-3-5800-8799  
e-mail: kkoike-ky@umin.ac.jp



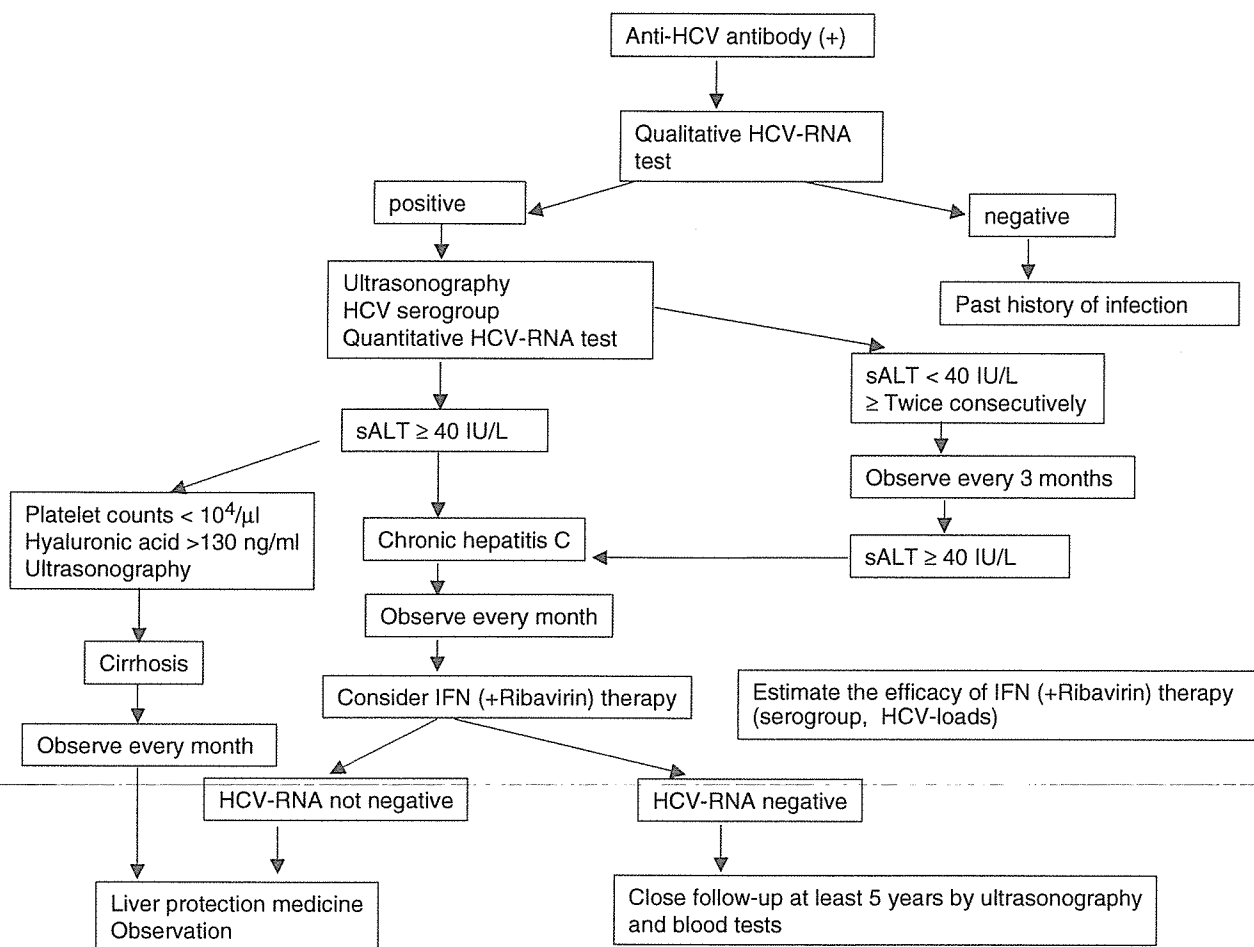


Fig. 1. Progress observation flow chart for anti-HCV antibody-positive patients. HCV, hepatitis C virus; ALT, alanine aminotransferase; IFN, interferon

### Anti-HCV antibody

Anti-HCV antibody of low titer is frequently detected using sensitive HCV kits currently available in Japan. Patients with low anti-HCV antibody titers mostly have a history of remote HCV infection, while those with high titers generally have an ongoing infection. Hence, patients who test positive for anti-HCV antibodies are not necessarily infected with HCV at present. When the antibody titer is found to be low, a history of infection (i.e., currently cured) should be suspected. To verify this, a sensitive qualitative HCV-RNA measurement is required (reverse transcriptase-polymerase chain reaction (RT-PCR) method).

Meanwhile, it should be noted that during the early stage of HCV infection (2–3 months from the initial HCV exposure), patients do not test positive for anti-HCV antibody (window period).

### HCV-RNA

To confirm the presence of HCV, we use an HCV-RNA assay by RT-PCR. There are two types of RT-PCR assay,

a qualitative one and a quantitative one. However, the latter has a relatively low sensitivity. Therefore, the qualitative RT-PCR assay is used to monitor the presence or absence of HCV, and hence the efficiency of an antiviral drug. For an estimation of the efficacy of antiviral treatment with interferon (IFN), a quantitative RT-PCR assay must be used.

### Genotypes and serogroups of HCV

Many genotypes of HCV have been identified (i.e., there are HCV groups whose gene or genomic sequences differ to some extent). HCV genotypes are clinically important because the efficacy of IFN therapy varies depending on the HCV genotype. In Japan, the majority of HCV patients have HCV genotypes 1 or 2. Because the HCV genotype is determined on the basis of restriction fragment length polymorphism (RFLP) by PCR assay, the determination procedure is somewhat complicated. In order to determine the responsiveness of patients with chronic hepatitis C to IFN therapy easily (rapidly and accurately), serogroup (SG) identification by enzyme immunoassay is useful.<sup>3</sup> Patients

are classified as SG-1 (corresponding to HCV genotype 1) or SG-2 (corresponding to HCV genotype 2). Many patients classified as SG-1 are resistant to IFN, whereas many patients classified as SG-2 are generally responsive to IFN therapy.

### Natural course of HCV infection

HCV patients commonly develop "acute hepatitis" 2 or 3 months after the initial exposure. However, many patients are unaware of this development because they have minor subjective symptoms and hardly exhibit jaundice. About 20% to 30% of patients exhibiting acute hepatitis recover spontaneously from the disease, but acute hepatitis develops into chronic hepatitis in the remaining 70% to 80% of patients (hepatitis persisting for more than 6 months is defined as chronic hepatitis). In general, these patients enter an "inactive phase" of hepatitis C, which persists for more than 10–15 years. The serum alanine aminotransferase (ALT) level, which indicates the extent of hepatocytic damage, is within the normal range during the inactive phase, but viral replication continues even during this period (Fig. 2).

Chronic hepatitis C frequently enters the "active phase" after an inactive phase of 10–15 years; however, this period varies greatly depending on the individual. In the active phase, the serum ALT level becomes approximately 2–3 times higher than the normal level. The problem with chronic hepatitis C is that it does not resolve spontaneously once it enters the active phase. If chronic hepatitis is left untreated, the risk of progression to cirrhosis increases without the patient realizing it. Thus, hepatitis C is characterized by its gradual but steady progression.<sup>4</sup>

With the progression to cirrhosis, there is an increasing risk of developing HCC. This risk has been reported to have an annual rate of 5% to 7%.<sup>5</sup> Ideally, HCV-infected patients should have the disease diagnosed during the inactive phase of chronic hepatitis so that, upon transition to the

active phase, the patients can start receiving antiviral therapy for HCV.

### Treatment of HCV infection

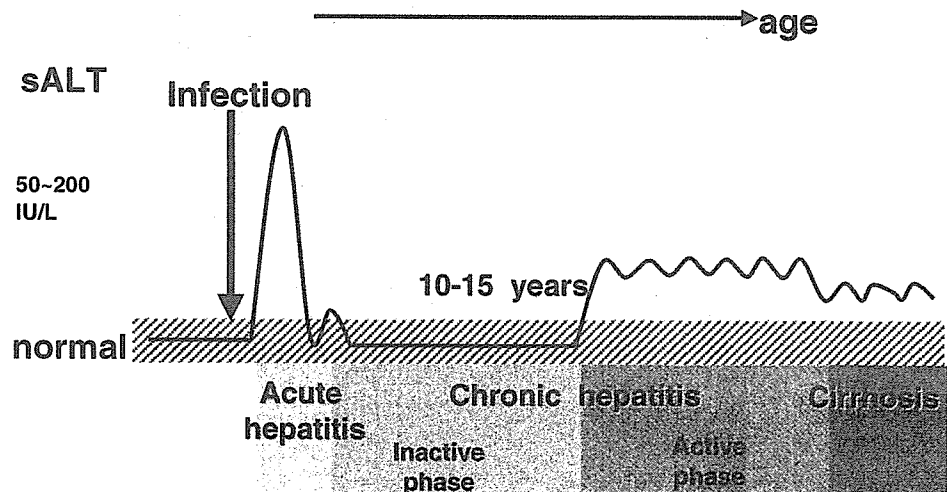
HCV infection is treated using mainly IFN preparations. These IFN preparations are outlined below in their order of development.

#### IFN monotherapy

IFN monotherapy was first introduced for the treatment of chronic hepatitis C. In Japan, the treatment of chronic hepatitis C generally starts with the daily administration of 6–10 million units of IFN for 2–4 weeks, followed by administration three times weekly for 6 months. In Europe and the USA, 3 million units of IFN are administered three times weekly from the start, and this is continued for a year. The efficacy of the therapy is evaluated after 6 months of IFN treatment. If an HCV-RNA test is negative by a qualitative RT-PCR assay at this time, it indicates that the patient obtained a sustained virological response (SVR) and is considered to be practically free of HCV.

IFN monotherapy had conventionally been used for non-A/non-B hepatitis from around 1985, prior to the discovery of HCV. A nationwide survey carried out by a research group supported by the former Ministry of Health and Welfare in 1995 showed that the overall SVR rate following IFN monotherapy for chronic hepatitis C (the administration of 6–10 million units per day) for 6 months was approximately 30%. SVR rates at facilities across Japan were nearly equal to this value. However, among patients with HCV genotype 1, who accounted for approximately 70% of all Japanese patients infected with HCV, and particularly those with a high viral load (defined as HCV-RNA >100 KIU/ml in Japan), a SVR was obtained in only 2% to 7% of cases; i.e., the efficacy of treatment by IFN

**Fig. 2.** Natural course of HCV-infected patients. Approximately 70% of acutely HCV-infected people develop persistent infection. After 10–15 years of the inactive phase, most chronic hepatitis C patients move into the active phase. One-third of chronic hepatitis C patients are assumed to develop cirrhosis. *sALT*, serum alanine aminotransferase



monotherapy was low. These patients with HCV genotype 1 at a high viral load have what is called “intractable hepatitis C.”

IFN therapy in combination with ribavirin

IFN is also administered in combination with ribavirin, an antiviral drug. In Japan, the use of ribavirin was approved in December 2001. Ribavirin (600–800mg daily, divided into two doses) is taken orally throughout the period of IFN injections. Ribavirin is a synthesized nucleic acid derivative and, when administered in combination with IFN, shows an increased antiviral activity.

In clinical studies of IFN therapy in combination with ribavirin conducted in Japan, a SVR rate of approximately 20% was obtained even in patients with HCV genotype 1 at a high viral load, i.e., “intractable hepatitis C,” and who were less responsive to IFN monotherapy. Because patients on IFN monotherapy used as the control showed a SVR rate of only 2.3%, the concomitant use of ribavirin contributed to an approximately 10-fold increase in antiviral activity.<sup>6</sup>

The efficacy of IFN therapy in combination with ribavirin after its inclusion in the health insurance program is very similar to that found in a clinical study in Japan. However, the adverse effects of this combinational therapy have generally been more severe than those observed during the clinical study period. The drop-out rates of patients who could not complete the combinational therapy were as high as 15%–20%, and this led to a decrease in SVR rate calculated on intention-to-treat (ITT). In other words, the

number of patients who dropped out of the treatment is added to the denominator. Adverse drug reactions that reduce the quality of life (QOL), such as hemolytic anemia, severe malaise, anorexia, and taste disorders, are frequently observed, particularly in many elderly patients. Indications for IFN therapy in combination with ribavirin should be considered carefully for patients aged 65 years or older.

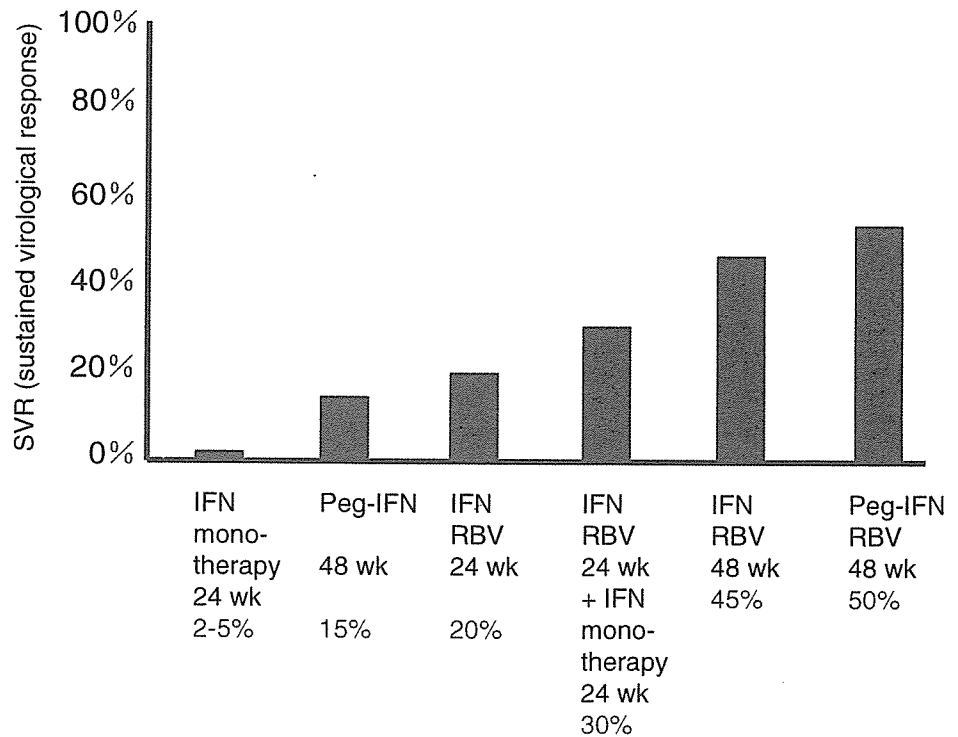
Long-term interferon therapy

In cases of long-term IFN therapy, IFN is administered two or three times a week for a period of 2 years or more. The purpose of this therapy is not the eradication of HCV, but the normalization of serum ALT levels and eventually the suppression of HCC development. This is a promising therapy for patients who cannot be treated with ribavirin because of its adverse effects, or for those who were not able to continue with the combination therapy of IFN and ribavirin.

PEG-IFN therapy in combination with ribavirin

PEG-IFN is an interferon molecule covalently bonded to polyethylene glycol (PEG), which shows a sustained release. PEG-IFN characteristically requires subcutaneous administration only once weekly, as compared with the conventional type of IFN which requires administration three times a week. PEG-IFN therapy alone has a higher efficacy than the conventional IFN monotherapy, but it has been demonstrated that PEG-IFN therapy used in combination with ribavirin shows an even higher efficacy<sup>7,8</sup> (Fig. 3).

**Fig. 3.** Changes in anti-HCV therapy, including interferon for intractable (genotype 1b, high viral loads) chronic hepatitis C patients. After the introduction of IFN monotherapy for chronic hepatitis C, the efficacy of IFN therapy has gradually increased with the addition of ribavirin, the introduction of pegylated IFN, and an extension of the duration of therapy. *IFN*, interferon; *RBV*, ribavirin



PEG-IFN therapy in combination with ribavirin is expected to increase the SVR rate to approximately 50% even in patients infected with HCV genotype 1 at a high viral load, and to approximately 60% in all patients infected with HCV. The efficacy in those infected with genotype 2 HCV reaches 80%–90%. In Japan, treatment with PEG-IFN  $\alpha$ -2a (Pegasys) alone was approved in December 2003. The combined use of PEG-IFN  $\alpha$ -2b (PegIntron) and ribavirin (Rebetol) was also approved in December 2004. These treatments with PEG-IFN are generally administered for 48 consecutive weeks. Continuation of the treatments for 48 consecutive weeks is important, although it may be necessary to decrease the dose owing to adverse drug effects.

The adverse effects of PEG-IFN therapy in combination with ribavirin are almost the same as those of conventional IFN therapy. However, such adverse effects are generally minor (for example, fever), and the therapy requires administration only once per week, thereby improving the patient's QOL. Because there is the possibility of drug accumulation in the body and an associated exacerbation of adverse effects owing to the sustained-release formulation, very careful observation of patients is required. There have been reports of other problematic adverse effects of this combinational therapy compared with those of the conventional IFN preparation, e.g., decreased counts of leukocytes, and particularly of neutrophils. Some patients exhibit severe thrombocytopenia. It is mandatory to confirm neutrophil count immediately before every administration.

It is currently specified that PEG-IFN therapy used in combination with ribavirin is the best choice in the treatment of intractable hepatitis C of genotype 1 at a high viral load. This combinational therapy is thus administered first. It has recently been suggested that an extended administration period of 72 weeks for PEG-IFN therapy in combination with ribavirin proves effective in patients who are slow in showing a SVR.

---

### **Efficacy of antiviral therapy and its effect on patient prognosis**

The following points have been reported in the literature: in patients in whom HCV was eradicated mainly by IFN monotherapy, hepatic fibrosis is improved,<sup>9</sup> the development of HCC is inhibited,<sup>10</sup> and life expectancy is also improved.<sup>11</sup> It has thus been indicated that if the eradication of HCV can be achieved, chronic hepatitis C prognosis is improved. It has also been reported that in patients in whom serum ALT level was normalized (even if this was transient), despite the failure to eradicate HCV (cases referred to as a biochemical response (BR)), the development of HCC was delayed in the short term. However, because no improvement in fibrosis was observed, it will probably be impossible in the long term to block the development of HCC. It has also been demonstrated that when curative treatment is carried out even after the development of HCC, subsequent IFN-based treatment could inhibit the recurrence of HCC.

---

### **Treatment of hepatitis C patients who do not respond sufficiently to IFN**

#### **Liver-protection therapy**

Liver-protection therapy aims to delay the progression of chronic hepatitis by controlling inflammation in patients in whom HCV could not be eradicated. An ursodeoxycholic acid preparation (Urso) and a glycyrrhizin preparation (Stronger Neo Minophagen C) are used in combination as a liver-protection therapy. These drugs inhibit hepatic inflammation and decrease serum ALT level, but they do not decrease HCV load. It was reported that Stronger Neo Minophagen C delays the progression of chronic hepatitis and the onset of HCC.<sup>12</sup> The ursodeoxycholic acid preparation decreases serum ALT level, but its action of delaying the progression of chronic hepatitis has not yet been verified.

Hepatitis C generally progresses slowly and is less likely to aggravate rapidly, unlike hepatitis B, which may aggravate very rapidly, and progresses steadily. Liver-protection therapy, which retards the progression of the disease by controlling inflammation, can therefore be considered significant in hepatitis C. This therapy is applied mainly when it is impossible to use IFN due to its adverse effects, or when patients do not respond sufficiently to IFN therapy, including in combination with ribavirin. Liver-protection therapy is also administered as a temporary measure until a therapy in combination with IFN is started.

#### **Phlebotomy**

Iron deficiency leads to a decrease in serum ALT level, and its use as a therapy for chronic hepatitis C has begun to be appreciated. This is based on the observation that reactive oxygen species (ROS) production increases in hepatitis C patients, which leads to the development of liver disease and eventually HCC. Because intrahepatic iron plays an important role in ROS production (Fenton reaction), phlebotomy is designed to suppress ROS production by inducing intrahepatic iron deficiency. In fact, decreasing the serum ferritin level (an indicator of iron store) to 10 ng/ml or lower leads to a significant decrease in serum ALT level.<sup>13</sup> This is a promising therapy for patients who do not respond sufficiently to IFN therapy, or who are unable to receive it and do not respond to the above-mentioned liver-protection therapy either.

---

### **Conclusions**

An overview of the current status of research on the progression of chronic hepatitis C and the treatment methods available has been presented and discussed in terms of the effects and limits of these methods. The early detection of HCV infection makes it possible to apply antiviral therapy at the appropriate time. It is particularly worth noting that

it has become possible for antiviral therapies to eradicate viruses in a majority of HCV patients, and to suppress and control the progression of HCV infection (or acute hepatitis C) to chronic hepatitis and subsequently to HCC. However, the limits of the current IFN-based therapies have also become evident. Specific antiviral drugs targeting HCV enzymes (including viral proteases, helicase, and RNA polymerase) have recently been developed. The development of one antiviral drug has advanced to phase II clinical trials as of 2006.

---

## References

1. Saito I, Miyamura T, Ohbayashi A, Harada H, Katayama T, Kikuchi S, et al. Hepatitis C virus infection is associated with the development of hepatocellular carcinoma. *Proc Natl Acad Sci USA* 1990;87:6547-9.
2. Kiyosawa K, Sodeyama T, Tanaka E, Gibo Y, Yoshizawa K, Nakano Y, et al. Interrelationship of blood transfusion, non-A, non-B hepatitis and hepatocellular carcinoma: analysis by detection of antibody to hepatitis C virus. *Hepatology* 1990;12:671-5.
3. Tanaka T, Tsukiyama-Kohara K, Yamaguchi K, Yagi S, Tanaka S, Hasegawa A, et al. Significance of specific antibody assay for genotyping of hepatitis C virus. *Hepatology* 1994;19:1347-53.
4. Koike K. Hepatitis viruses update. *Intern Med* 2001;40:173-5.
5. Ikeda K, Saitoh S, Suzuki Y, Kobayashi M, Tsubota A, Koida I, et al. Disease progression and hepatocellular carcinogenesis in patients with chronic viral hepatitis: a prospective observation of 2215 patients. *J Hepatol* 1998;28:930-8.
6. Tsubota A, Arase Y, Suzuki F, Suzuki Y, Akuta N, Hosaka T, et al. High-dose interferon alpha-2b induction therapy in combination with ribavirin for Japanese patients infected with hepatitis C virus genotype 1b with a high baseline viral load. *J Gastroenterol* 2004;39:155-61.
7. Fried MW, Shiffman ML, Reddy KR, Smith C, Marinos G, Goncales FL Jr, et al. Peginterferon alfa-2a plus ribavirin for chronic hepatitis C virus infection. *N Engl J Med* 2002;347:975-82.
8. Manns MP, McHutchison JG, Gordon SC, Rustgi VK, Shiffman M, Reindollar R, et al. Peginterferon alfa-2b plus ribavirin compared with interferon alfa-2b plus ribavirin for initial treatment of chronic hepatitis C: a randomized trial. *Lancet* 2001;358:958-65.
9. Sobesky R, Mathurin P, Charlotte F, Moussalli J, Olivi M, Vidaud M, et al. Modeling the impact of interferon alfa treatment on liver fibrosis progression in chronic hepatitis C: a dynamic view. The Multivirc Group. *Gastroenterology* 1999;116:3783-6.
10. Nishiguchi S, Kuroki T, Nakatani S, Morimoto H, Takeda T, Nakajima S, et al. Randomized trial of effects of interferon-alpha on incidence of hepatocellular carcinoma in chronic active hepatitis C with cirrhosis. *Lancet* 1995;346:1051-5.
11. Okanoue T, Itoh Y, Minami M, Sakamoto S, Yasui K, Sakamoto M, et al. Interferon therapy lowers the rate of progression to hepatocellular carcinoma in chronic hepatitis C, but not significantly in an advanced stage: a retrospective study in 1148 patients. *Viral Hepatitis Therapy Study Group. J Hepatol* 1999;30:653-9.
12. Arase Y, Ikeda K, Murashima N, Chayama K, Tsubota A, Koida I, et al. The long-term efficacy of glycyrrhizin in chronic hepatitis C patients. *Cancer* 1997;79:1494-500.
13. Kato J, Kobune M, Nakamura T, Kuroiwa G, Takada K, Takimoto R, et al. Normalization of elevated hepatic 8-hydroxy-2'-deoxyguanosine levels in chronic hepatitis C patients by phlebotomy and low iron diet. *Cancer Res* 2001;61:8697-702.

## Molecular epidemiology of hepatitis A virus in metropolitan areas in Japan

HIDEAKI TAKAHASHI<sup>1</sup>, HIROSHI YOTSUYANAGI<sup>1,3</sup>, KIYOMI YASUDA<sup>4</sup>, TOMOHIKO KOIBUCHI<sup>5</sup>, MICHIIRO SUZUKI<sup>1</sup>, TOMOHIRO KATO<sup>2</sup>, TETSUYA NAKAMURA<sup>5</sup>, AIKICHI IWAMOTO<sup>5</sup>, KUSUKI NISHIOKA<sup>2</sup>, SHIRO IINO<sup>1,4</sup>, KAZUHIKO KOIKE<sup>3</sup>, and FUMIO ITOH<sup>1</sup>

<sup>1</sup>Department of Internal Medicine, Division of Gastroenterology and Hepatology, Institute of Medical Science, St. Marianna University, Kawasaki, Japan

<sup>2</sup>Division of Molecular Immunology, Institute of Medical Science, St. Marianna University, Kawasaki, Japan

<sup>3</sup>Department of Infectious Diseases, Faculty of Medicine, University of Tokyo, 7-3-1 Hongo, Bunkyo, Tokyo 113-8655, Japan

<sup>4</sup>Center for Liver Diseases, Seizankai Kiyokawa Hospital, Tokyo, Japan

<sup>5</sup>Department of Internal Medicine, Division of Infectious Diseases and Immunology, Institute of Medical Science, University of Tokyo, Tokyo, Japan

**Background.** Transmission routes of hepatitis A virus (HAV) in Japan have changed. The present study investigated changes of transmission routes in relation to genetic drift. **Methods.** All 60 patients who were admitted between 1993 and 2003 with a diagnosis of hepatitis A were retrospectively analyzed. Nucleotide sequences of the VP1/2A region of the HAV recovered from their sera were determined. **Results.** The suspected transmission routes were household contact, 19 (31%); food or waterborne, 16 (27%); homosexual activity, 11 (18%); international travel, 4 (7%); and unknown 10 (17%). The 11 patients presumably infected through homosexual activity were found exclusively in 1998 and 1999. The proportion of patients exposed through homosexual behavior and household contact was higher in those 2 years than in other years. Nucleotide sequences could be determined for 58 patients. Fifty-seven of the 58 sequences belonged to genotype IA HAV, with less than 10% nucleotide diversity. Of the 27 sequences isolated during 1998 and 1999, 25 had an identical nucleotide sequence regardless of the suspected transmission route. In contrast, sequences obtained in the other years differed from one another. A phylogenetic tree constructed from sequences recovered from patients without a history of travel abroad showed several clusters. **Conclusions.** Our results suggest that (1) HAV acquired through homosexual activity may be transmitted to nonhomosexual individuals; (2) hepatitis A in metropolitan areas in Japan is caused mainly by sporadic infection with genotype IA HAV; and (3) several subtypes of genotype IA HAV are endemic in Japan.

**Key words:** hepatitis A virus, epidemiology, transmission route, sexuality, Japan

### Introduction

Hepatitis A virus (HAV) is one of the major causes of viral hepatitis and a worldwide problem. The annual incidence of hepatitis A is 1.5 million cases of clinical disease, and the true incidence, including subclinical disease, may be much higher.<sup>1</sup> Fulminant hepatic failure is a complication for some patients with clinical disease.<sup>2</sup> Therefore, preventing the spread of HAV is an important issue.

Good sanitation and a sterilized water supply are essential for the prevention of hepatitis A. In developing countries with a high incidence of hepatitis A, the main transmission route of hepatitis A is the fecal–oral route caused by poor sanitation, which increases the chance of ingesting contaminated food or water.<sup>2,3</sup> In contrast, in developed countries with good sanitation and a sterilized water supply, such as North America, Western Europe, Australia, and New Zealand, the incidence of hepatitis A is low and transmission is caused by personal contact with an infected person, homosexual activity, or transfusion of contaminated blood products, in addition to ingestion of contaminated food or water.<sup>2–5</sup>

The incidence of hepatitis A in Japan has markedly decreased recently. National surveillance of HAV in Japan has shown that more than 90% of people over 65 but fewer than 10% of people under 34 are positive for anti-HAV.<sup>6</sup> The difference can probably be attributed to changes in sanitation. If this hypothesis is true, then the transmission route of HAV in Japan may have changed with time. Studying changes in HAV transmission routes in Japan may therefore elucidate the influence of sanitation on transmission routes.

Molecular epidemiological approaches may also be useful for studying transmission routes. Studies from European countries have shown that several clusters of viral strains from various genotypes prevail in those countries.<sup>7,8</sup> The heterogeneity of isolated strains

Received: July 10, 2006 / August 3, 2006

Reprint requests to: H. Yotsuyanagi

None of the authors has a potential conflict of interest.

suggests multiple transmission routes. Information on transmission routes is, however, not available in these reports. Sequential molecular epidemiological studies linked to transmission routes may elucidate native strains in Japan and provide new information for the control of this disease.

The aim of this study was to understand both clinical and molecular epidemiology of HAV infection in Japan.

## Methods

### Patients

Sixty patients admitted to our institutions between 1993 and 2003 who were diagnosed with hepatitis A were analyzed retrospectively. The patients comprised 39 men (65%) and 21 women (35%), and their median age was 34.0 years (range, 22–55 years). The diagnosis of hepatitis A was based on a high titer serum IgM anti-HA level with acute liver injury. Coinfection with hepatitis B virus, hepatitis C virus, or other hepatotropic viruses was excluded by serological testing. Serum samples were available from all patients on admission. Fifty-eight of the 60 samples were positive for HAV RNA by reverse transcription (RT)-nested polymerase chain reaction (PCR) with the protocol outlined below. None of the 58 patients had fulminant hepatic failure. Intrahepatic cholestasis was a complication in one patient. The other 57 patients underwent a noncomplicated and self-limited clinical course.

Informed consent was obtained from each patient. The study protocol conformed to the ethical guidelines of the 1975 Declaration of Helsinki and was approved by the ethics committees of our institutions.

### Detection of hepatitis A viral RNA in serum

RNA was extracted from sera using the acid guanidinium-phenol-chloroform method.<sup>9</sup> In brief, 100 µl of sample was mixed with 300 µl of solution D (guanidinium solution), 60 µl of chloroform, and 40 µl of NaOAc (pH 5.2) and precipitated with 1 ml of ethanol. The RNA pellet was washed twice with 70% ethanol and dissolved in 25 µl of RNase-free distilled water.

For reverse transcription, 1 µl of RNA solution, extracted from 100 µl of sera using the acid guanidinium-phenol-chloroform method and dissolved in 25 µl of RNase-free distilled water, was heat-denatured at 68°C for 10 min. It was chilled rapidly on ice and mixed with 4 µl of 1.5 mM MgCl<sub>2</sub> solution, 2 µl of 10× RNA PCR buffer (100 mM Tris-HCl, pH 8.3; 500 mM KCl), 8.5 µl of RNase-free distilled H<sub>2</sub>O, 2 µl of dNTP mixture (10 mM dATP, dCTP, dGTP, dTTP), 1 µl of random 9-

mers (5'-NNNNNNNNN-3'), 0.5 µl of RNase inhibitor (Takara-Shuzo, Kyoto, Japan), and 1 µl of reverse transcriptase (Takara-Shuzo). After incubation at 30°C for 10 min, reverse transcription reaction was carried out at 42°C for 30 min, followed by inactivation at 95°C for 5 min.

In the first PCR, 5 µl of the 20 µl cDNA solution was used. The first PCR was performed in 50 µl of reaction mixture containing 1.0 µM each of outer sense primer (5'-GGTTTCTATTTCAGATTGCAAATTA-3' nt. 2891–2914) and antisense primer (5'-AGTAAAACTCCAGCATCCATTTC-3' nt. 3398–3375), 200 µM of each dNTP, 5 µl of 10× PCR buffer (100 mM Tris-HCl, pH 8.3; 500 mM KCl; 15 mM MgCl<sub>2</sub>; 0.01% (w/v) gelatin), and 2.5 U of *Ex Taq* polymerase (Takara) with proofreading activity. The amplification conditions were 94°C for 16 min followed by 40 cycles of 94°C for 1 min, 50°C for 1 min, and 72°C for 1 min.

One microliter of the first PCR product was used for the second PCR. The reaction mixture contained 1.0 µM each of inner sense primer (5'-TTGCAAATTACAATCATTCTG-3' nt. 2905–2925) and inner antisense primer (5'-TTCAAGAGTCCACACACTTCT-3' nt. 3377–3367), 5 µl of 10× PCR buffer, 35 µl of RNase-free dH<sub>2</sub>O, 5 µl of dNTP mixture (2 mM dATP, dCTP, dGTP, dTTP), and 0.5 µl of amplitaq gold (Roche Diagnostics, Branchburg, NJ, USA). The amplification conditions for the second PCR were the same as those of the first PCR. The second PCR products were analyzed by 2% agarose gel electrophoresis, stained with ethidium bromide, and visualized by UV transillumination. Standard precautions to avoid contamination were taken during PCR, with a negative control serum included in each run.

### Sequencing of PCR products

Amplification products were purified on Wizard PCR Preps DNA purification resin (Promega, Madison, WI, USA), and sequenced bidirectionally with the Dye Terminator Cycle Sequencing Ready Reaction kit (PE Applied Biosystems, Foster City, CA, USA) using the above PCR primers. Sequencing was performed on an automated DNA sequencer ABI 377 (PE Applied Biosystems).

The nucleotide sequences of HAV isolates from the patients were compared with those of seven reference HAV strains retrieved from the DDBJ/EMBL/GenBank databases, representing each of the seven major genotypes (I–VII). Phylogenetic trees were constructed with the Mega program version 2.1 using the Kimura two-parameter matrix and the neighbor-joining method.<sup>10</sup> To confirm the reliability of the phylogenetic tree analysis, bootstrap resampling and reconstruction were carried out 500 times.

*Statistical analysis*

Data were analyzed by a  $\chi$ -squared test. *P* values less than 0.05 were regarded as statistically significant.

**Results**

*Transmission routes*

Table 1 shows the numbers of patients and transmission routes. An epidemic of hepatitis A among homosexuals was reported in metropolitan areas in Japan between 1998 and 1999.<sup>11,12</sup> Our results showed that more patients were admitted during that period. The increase was caused not only by patients involved in homosexual activity but also by individuals without that risk factor.

The suspected transmission routes for the patients were as follows: household contact, 19 (31%); food or water, 16 (27%); homosexual activity, 11 (18%); international travel, 4 (7%); and unknown, 10 (17%). In 1998 and 1999, the suspected transmission routes were as follows: household contact, 13 (45%); homosexual activity, 11 (38%); food or water, 1 (3%); international travel, 1 (3%); and unknown, 3 (11%). The proportion of cases associated with homosexuality and household contact was higher in those 2 years than in the other years (homosexuality-associated, *P* = 0.0006; household contact-associated, *P* = 0.034). Figure 1 shows the time of onset for all patients over the 2 years. The times of

onset for those 2 years were from July 1998 to July 1999 for homosexual patients and from February 1998 to September 1999 for nonhomosexual patients. After excluding two patients with different sequences, the onset of nonhomosexual patients varied from August 1998 to September 1999. The periods of transmission were similar between homosexual and nonhomosexual groups.

*Sequence analysis of HAV RNA*

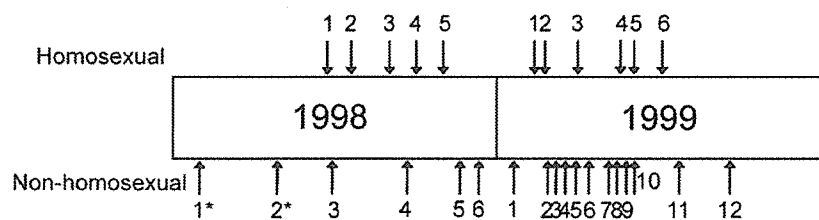
The sequence between nucleotides 3024 and 3191 of the VP1/2A region was determined for the 58 patients. Many nucleotide sequences were closely related to HAS-15, a representative HAV genotype IA strain. Twenty-five of the 27 viral sequences recovered during 1998–1999 were identical. This sequence is identical to IMSTU, which is prevalent among homosexuals in metropolitan areas.<sup>12</sup> As shown in Table 2, all sequences except one showed more than 90% identity with the reference sequences.

We then performed a phylogenetic analysis of the region between nucleotides 3024 and 3191 and classified the virus strains (Fig. 2). Bootstrap analysis to evaluate the statistical reliability of the phylogenetic tree revealed 500/500 (100%) reliability. All strains belonged to genotype IA, except for one that belonged to genotype IIIA. The patient harboring the genotype IIIA virus had a history of travel to Africa 1 month before admission.

**Table 1.** Numbers of patients and routes of transmission

	1993–1997	1998–1999	2000–2004	Total
Household contact	4 (29%)	13 (45%)*	2 (12%)	19 (31%)
Food or waterborne	4 (29%)	1 (3%)	11 (64%)	16 (27%)
Homosexual activity	0	11 (38%)**	0	11 (18%)
Foreign travel	1 (7%)	1 (3%)	2 (12%)	4 (7%)
Unknown	5 (35%)	3 (11%)	2 (12%)	10 (17%)
Total	14	29	17	60

\**P* = 0.034, \*\**P* = 0.0006;  $\chi$ -squared test

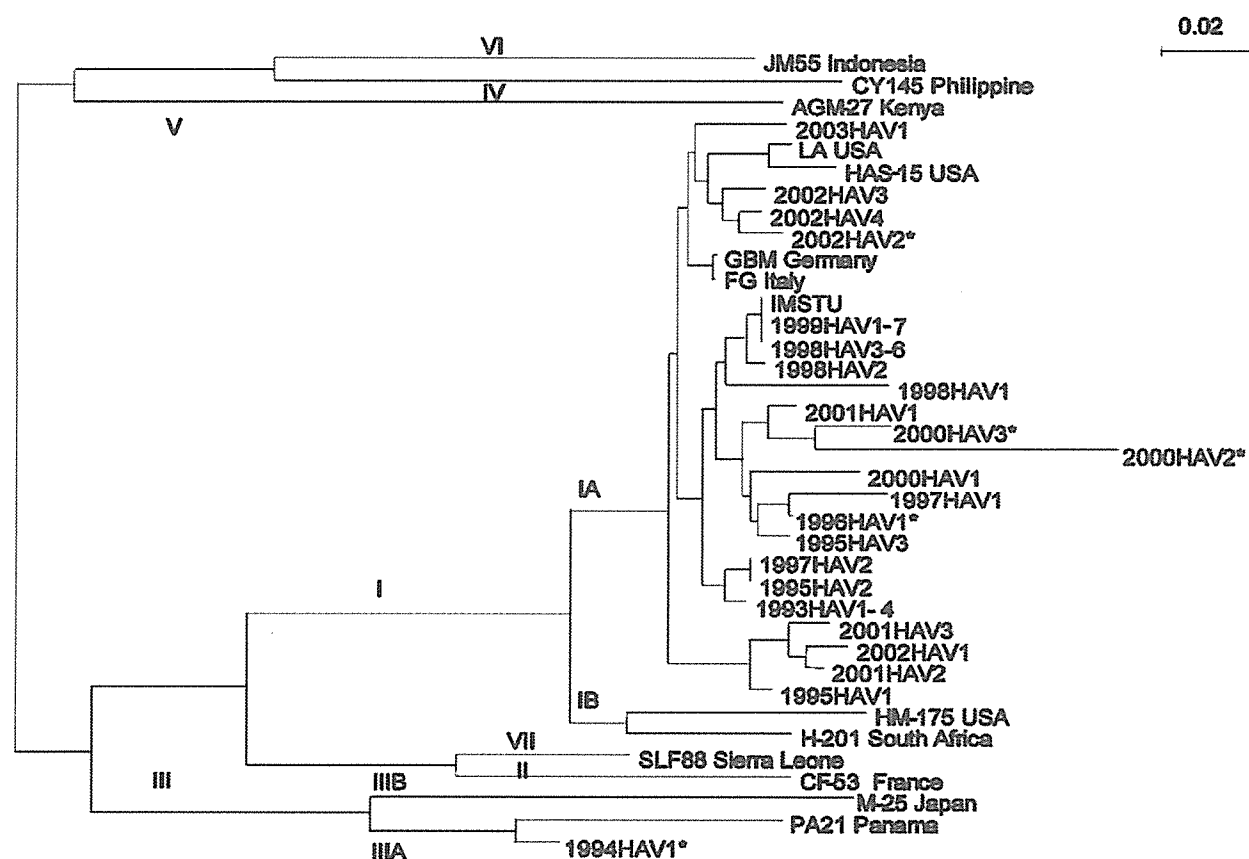


**Fig. 1.** Time of first visit of patients with hepatitis A in 1998 and 1999. Arrows in the upper part show the times of visit of homosexual patients. Arrows in the lower part show those of nonhomosexual patients. All except two (cases 1 and 2) had the same sequences. The period of transmission was similar for homosexual and nonhomosexual groups. \* shows the sequences that were different



**Table 2.** Homology with recovered sequences and representative strains (HAS-15 and IMSTU)

	Homology with IMSTU		Homology with HAS-15		
	Nucleic acid	Amino acid	Nucleic acid	Amino acid	
HAS-15	95.7	98.2	IMSTU	95.7	98.2
1993	97.6	100	1993	94.4	98.2
1994	77.1	89.1	1994	73.8	87.3
1995	95.7–98.8	98.2–100	1995	93.8–94.4	96.4–98.2
1996	97.6	100	1996	94.4	98.0
1997	95.7–98.8	96.4–100	1997	92.4–94.4	94.5–98.2
1998	95.7–100	98.2–100	1998	93.7–95.7	96.4–98.2
1999	100	100	1999	95.7	98.2
2000	90.4–95.7	92.7–98.2	2000	86.8–92.4	90.9–96.4
2001	93.7–97.6	96.4	2001	92.4–94.4	94.5–98.2
2002	93.1–96.3	100	2002	92.4–96.3	94.5–98.2
2003	96.7	100	2003	95.0	98.2



**Fig. 2.** A phylogenetic tree constructed for RNA sequences located in the VP1/2A region of hepatitis A virus (HAV) genomes reported previously. Accession numbers are shown for the isolates that have been deposited in the DDBJ/EMBL/GenBank databases. Many nucleotide sequences were close to that of HAS-15, a representative HAV genotype IA strain. Twenty-five of 27 viral sequences recovered during 1998–1999 were identical to IMSTU. \*shows the sequences that were acquired abroad

## Discussion

In this study, the most frequent transmission route was personal contact, which is also the case in the

United States ([www.cdc.gov/ncidod/diseases/hepatitis/resource/PDFs/hep\\_surveillance\\_60.pdf](http://www.cdc.gov/ncidod/diseases/hepatitis/resource/PDFs/hep_surveillance_60.pdf)). The next most frequent cause was contaminated food, which is different from the United States. Additionally, the

proportion of patients whose hepatitis was caused by contaminated food was highest in recent years. As mentioned above, anti-HAV prevalence, which may reflect poor sanitation, has decreased in Japan. Therefore, the high incidence of hepatitis A with food/water as a transmission route may not result from poor sanitation. The reason for the high percentage is presumably related to diet. Japanese people often eat raw fish or shellfish, which increases the chances of transmission. Indeed an outbreak caused by eating raw oysters has been reported.<sup>13</sup> In other words, the transmission routes of HAV in Japan are different from those in other developed countries irrespective of improved sanitation.

The molecular epidemiological study showed interesting results. The sequences recovered in the years other than 1998 and 1999 were heterogeneous (Fig. 1). Furthermore, the phylogenetic analysis showed several clusters of genotype IA HAV strains, after excluding cases presumably acquired abroad. This suggests that several subgroups of genotype IA HAV strains are endemic in Japan and cause sporadic hepatitis. A large-scale epidemiological study may be useful for testing this hypothesis.

In contrast, an epidemic caused by homosexual activity was observed in 1998 and 1999.<sup>11,12</sup> The same nucleotide sequences were detected among patients for more than 1 year (Fig. 1), which suggests that the same strain was transmitted secondarily. Among 24 patients whose sera harbored the same HAV sequences in this period, 11 were presumably infected through homosexual activity. Among the other patients, four were infected through close person-to-person contact (heterosexual activity, familial transmission, or transmission in day-care facilities), while the other four had no relevant history. These findings suggest that homosexual persons can transmit HAV to nonhomosexual persons through close contact or heterosexual activity.

It is interesting that 24 separate sequences in 1998 and 1999 were identical to the IMSTU recovered from ten patients in another institution. A serum sample recovered 2 months before the epidemic had a similar sequence, with 99.4% homology. Because a homosexual patient may have sexual contact with multiple partners within that community, the 34 patients may have been infected by the same strain. Therefore, our results suggest that the rate of mutation in this region of 168 base pairs is probably very low. A previous study has shown that the mutation rate of HAV within a person is very low;<sup>14</sup> our results are consistent with that observation.

A previous report has shown that sequences recovered in Japan in the early 1990s are variable and belong to multiple genotypes.<sup>14</sup> Our results are contrary to those of that study. This suggests that improvements in sanitation decrease both the number of patients

and viral heterogeneity. The endemicity in low-HAV-prevalence countries may be caused by highly related viral strains. A report from the United States showing that most patients infected in a community-wide outbreak were infected by the same strain supports this hypothesis.<sup>15</sup>

In developed countries, a substantial number of patients with hepatitis A acquired HAV through homosexual activity ([www.cdc.gov/ncidod/diseases/hepatitis/h96surve.htm](http://www.cdc.gov/ncidod/diseases/hepatitis/h96surve.htm)). Recent studies using PCR analysis have shown that the fecal excretion of HAV continues even after recovery,<sup>16</sup> which suggests that hepatitis A patients may transmit the virus even after recovery. This is in accordance with the fact that positivity for anti-HAV among homosexual people is very high.<sup>17-19</sup> Therefore, people who engage in homosexual activity should be considered for HAV vaccination regardless of human immunodeficiency virus coinfection.

To conclude, recent hepatitis A in metropolitan areas is caused predominantly by sporadic infection by genotype IA HAV. Homosexual activity may cause an HAV epidemic among not only homosexuals but also heterosexuals, and involve homogeneous viral strains.

*Acknowledgments.* We thank Ms. Mie Kanke for her excellent technical assistance. This study was supported in part by a Grant-in-Aid from the Ministry of Health, Labour and Welfare, Japan.

## References

1. Hepatitis A vaccines. *Wkly Epidemiol Rec* 2000;75:38-44.
2. Cuthbert JA. Hepatitis A: old and new. *Clin Microbiol Rev* 2001;14:38-58.
3. Gust ID. Epidemiological patterns of hepatitis A in different parts of the world. *Vaccine* 1992;10 Suppl 1:S56-8.
4. Dentinger CM, Bower WA, Nainan OV, et al. An outbreak of hepatitis A associated with green onions. *J Infect Dis* 2001;183:1273-6.
5. Hepatitis A among persons with hemophilia who received clotting factor concentrate—United States, September–December 1995. *MMWR Morb Mortal Wkly Rep* 1996;45:29-32.
6. Kiyohara T, Satoh T, Yamamoto H, Totsuka A, Moritsugu Y. The latest seroepidemiological pattern of hepatitis A in Japan. *Jpn J Med Sci Biol* 1997;50:123-31.
7. Bruisten SM, van Steenberghe JE, Pijl AS, Niesters HG, van Doornum GJ, Coutinho RA. Molecular epidemiology of hepatitis A virus in Amsterdam, the Netherlands. *J Med Virol* 2001;63:88-95.
8. Tallo T, Norder H, Tefanova V, Ott K, Ustina V, Prukk T, et al. Sequential changes in hepatitis A virus genotype distribution in Estonia during 1994 to 2001. *J Med Virol* 2003;70:187-93.
9. Chomczynski P, Sacchi N. Single-step method of RNA isolation by acid guanidinium thiocyanate-phenol-chloroform extraction. *Anal Biochem* 1987;162:156-9.
10. Sugita S, Yoshioka Y, Itamura S, Kanegae Y, Oguchi K, Gojibori T, et al. Molecular evolution of hemagglutinin genes of H1N1 swine and human influenza A viruses. *J Mol Evol* 1991;32:16-23.
11. Baba M, Oka H, Asayama M, Yoshinaga S, Yamashita H, Tachikawa N, et al. Acute hepatitis outbreak in Tokyo caused by

- hepatitis A virus of common origin transmitted through oral and sexual routes. *Jpn J Infect Dis* 2000;53:127-9.
12. Ishida T, Nakamura T, Ajisawa A, Negishi M, Kashiya T, Takechi A, et al. Outbreak of hepatitis A virus infection among HIV-1 seropositive men who had sex with men. *Jpn J Infect Dis* 1999;52:131-2.
  13. Ohara H, Naruto H, Watanabe W, Ebisawa I. An outbreak of hepatitis A caused by consumption of raw oysters. *J Hyg (Lond)* 1983;91:163-5.
  14. Robertson BH, Jansen RW, Khanna B, Totsuka A, Nainan OV, Siegl G, et al. Genetic relatedness of hepatitis A virus strains recovered from different geographical regions. *J Gen Virol* 1992; 73(Pt 6):1365-77.
  15. Robertson BH, Averhoff F, Cromeans TL, Han X, Khoprasert B, Nainan OV, et al. Genetic relatedness of hepatitis A virus isolates during a community-wide outbreak. *J Med Virol* 2000;62:144-50.
  16. Yotsuyanagi H, Koike K, Yasuda K, Moriya K, Shintani Y, Fujie H, et al. Prolonged fecal excretion of hepatitis A virus in adult patients with hepatitis A as determined by polymerase chain reaction. *Hepatology* 1996;24:10-3.
  17. Villano SA, Nelson KE, Vlahov D, Purcell RH, Saah AJ, Thomas DL. Hepatitis A among homosexual men and injection drug users: more evidence for vaccination. *Clin Infect Dis* 1997;25:726-8.
  18. Diamond C, Thiede H, Perdue T, Secura GM, Valleroy L, Mackellar D, et al. Viral hepatitis among young men who have sex with men: prevalence of infection, risk behaviors, and vaccination. *Sex Transm Dis* 2003;30:425-32.
  19. Koff RS. Seroepidemiology of hepatitis A in the United States. *J Infect Dis* 1995;171 Suppl 1:S19-23.

## Original Article

## Prevalence of coinfection with human immunodeficiency virus and hepatitis C virus in Japan

Kazuhiko Koike,<sup>1</sup> Kunihisa Tsukada,<sup>1</sup> Hiroshi Yotsuyanagi,<sup>1</sup> Kyoji Moriya,<sup>1</sup> Yoshimi Kikuchi,<sup>2</sup> Shinichi Oka<sup>1</sup> and Satoshi Kimura<sup>2</sup><sup>1</sup>Department of Internal Medicine, Graduate School of Medicine, University of Tokyo, Tokyo and <sup>2</sup>AIDS Clinical Center, International Medical Center of Japan, Tokyo, Japan

People with human immunodeficiency virus (HIV) infection are frequently infected with hepatitis C virus (HCV), because of the common transmission routes. Since the dissemination of hyperactive antiretrovirus therapy (HAART), the morbidity and mortality associated with HIV infection have declined. However, the reduction in mortality due to opportunistic infection has made HCV-associated liver diseases the leading cause of mortality in Western countries. A similar situation is assumed in Japan, but the status of coinfection with HIV and HCV is unclear. We conducted a nationwide survey to determine the prevalence of coinfection with HIV and HCV by dis-

tributing a questionnaire to the hospitals in the HIV/AIDS Network of Japan. Among 4877 patients reported to be HIV-positive, 935 (19.2%) were also positive for the anti-HCV antibody. Most (84.1%) of the patients coinfecting with HIV and HCV were recipients of blood products. These data, for the first time, show the current status of coinfection with HIV and HCV in Japan. A detailed analysis of the progression and severity of liver diseases in the coinfecting patients is expected.

**Key words:** coinfection, hepatitis C, HIV, liver disease

## INTRODUCTION

HEPATITIS C VIRUS (HCV) infection and human immunodeficiency virus (HIV) infection are major public health problems worldwide. In the USA, the estimated prevalence of the anti-HCV antibody is 1.8%, with 2.7 million people having HCV-RNA detected in their blood, indicative of ongoing HCV infection.<sup>1</sup> The prevalence of HIV is <1%, and the virus is estimated to have infected approximately 800 000 people.<sup>2</sup> Because of the common transmission routes, that is, parenteral ones, many people with HIV infection are also infected with HCV.<sup>3</sup> Before the introduction of hyperactive antiretroviral treatment (HAART) in 1996, most people with HIV infection died of HIV-associated opportunistic infections such as *Pneumocystis carinii* (currently called *P. jirovecii*) pneumonia and cytomegaloviral infection. Since the dissemination of HAART, the morbidity and mortality associated with HIV infection have

declined. However, the reduction in mortality due to opportunistic infection has made patients coinfecting with HIV and HCV faced with the menace of progressive liver diseases due to HCV infection in the United States and Europe.<sup>4,5</sup>

Coinfection with HIV has been shown to increase the HCV load in HCV infection,<sup>6</sup> being a negative prognostic factor for clearance of HCV in anti-HCV therapy using interferon.<sup>7,8</sup> It also accelerates the development of cirrhosis and, eventually, hepatocellular carcinoma. Although still controversial, coinfection with HIV and HCV yields a more rapid progression to acquired immunodeficiency syndrome (AIDS) in some cases.<sup>9,10</sup> Importantly, coinfection with HIV and HCV will increase the morbidity and mortality of HIV-infected patients also in Japan, where the prevalence of HIV infection is increasing in a linear fashion, exceptionally among developed countries.<sup>11</sup> There are more than 10 000 HIV-positive people in Japan as of the end of 2004, according to the AIDS National Survey in Japan,<sup>12</sup> and approximately 1.8 million chronic HCV carriers, according to the estimation by the Ministry of Health, Labor and Welfare (MHLW) of Japan. However, unfortunately, the prevalence of coinfection with HIV and HCV in Japan has been unclarified to date. Therefore, we conducted a nationwide study by distributing an

Correspondence: Professor Kazuhiko Koike, Department of Infectious Diseases, Internal Medicine, Graduate School of Medicine, University of Tokyo, 7-3-1 Hongo, Bunkyo-ku, Tokyo 113-8655, Japan. Email: kkoike-iky@umin.ac.jp

Received 7 August 2006; revision 22 August 2006; accepted 29 August 2006.