

- Horster M (1977) Nephron function and perinatal homeostasis. *Ann Rech Vet* **8**: 468–482.
- Jensh RP, Brent RL (1988) The effects of prenatal X irradiation on the appearance of reflexes and physiologic markers in the neonatal rat. *Radiat Res* **116**: 416–426.
- Koizumi M, Nishimura N, Enami T *et al.* (2002) Comparative toxicity study of 3-aminophenol in newborn and young rats. *J Toxicol Sci* **27**: 411–421.
- Koizumi M, Noda A, Ito Y *et al.* (2003) Higher susceptibility of newborn than young rats to 3-methylphenol. *J Toxicol Sci* **28**: 59–70.
- Koizumi M, Yamamoto Y, Ito Y *et al.* (2001) Comparative study of toxicity of 4-nitrophenol and 2,4-dinitrophenol in newborn and young rats. *J Toxicol Sci* **26**: 299–311.
- Landrigan PJ, Kimmel CA, Correa A, Eskenazi B (2004) Children's health and the environment: Public health issues and challenges for risk assessment. *Environ Health Perspect* **112**: 257–265.
- Matsui M, Watanabe HK (1982) Developmental alteration of hepatic UDP-glucuronosyltransferase and sulphotransferase towards androsterone and 4-nitrophenol in Wistar rats. *Biochem J* **204**: 441–447.
- MHLW (2001a) 2-tert-Butylphenol (88-18-6). In: Ministry of Health, Labor and Welfare (ed). *Toxicity Testing Reports of Environmental Chemicals*, Vol. 8. Chemical Investigation Promoting Council, Tokyo, pp. 208–218.
- MHLW (2001b) 2,4-Di-tert-butylphenol (96-76-4). In: Ministry of Health, Labor and Welfare (ed). *Toxicity Testing Reports of Environmental Chemicals*, Vol. 8. Chemical Investigation Promoting Council, Tokyo, pp. 372–386.
- NAS (National Academy of Sciences) (1993) *Pesticides in the Diets of Infants and Children*. National Academy Press, Washington, DC.
- New Chemical Index (2001) *Shin Kagaku Index*. [New Chemical Index.] The Chemical Daily Co., Ltd, Tokyo. (In Japanese).
- NIHS (1994) *Glossary of Terms for Toxicity Testing*. Biological Safety Research Center, National Institute of Health Sciences, Tokyo. (In Japanese).
- OECD (2004) Draft guidance document on reproductive toxicity testing and assessment, OECD environment, health and safety publications series on testing and assessment No. 43. November 10, 2004 (1st Version).
- Scheuplein R, Charnley G, Dourson M (2002) Differential sensitivity of children and adults to chemical toxicity. I. Biological basis. *Regul Toxicol Pharmacol* **35**: 429–447.
- Shafer TJ, Meyer DA, Crofton KM (2005) Developmental neurotoxicity of pyrethroid insecticides: Critical review and future research needs. *Environ Health Perspect* **113**: 123–136.
- Sheehan DM, Gaylor DW (1990) Analysis of the adequacy of safety factors. *Teratology* **41**: 590–591.
- Steel RD (1959) A multiple comparison rank sum test: Treatment versus control. *Biometrics* **15**: 560–572.
- Takahashi M, Ogata H, Izumi H *et al.* (2004) Comparative toxicity study of 2,4,6-trinitrophenol (picric acid) in newborn and young rats. *Cong Anom* **44**: 204–214.
- Zheng Q, Olivier K, Won YK, Pope CN (2000) Comparative cholinergic neurotoxicity of oral chlorpyrifos exposures in preweanling and adult rats. *Toxicol Sci* **55**: 124–132.



## In utero and lactational exposure to 2,3,7,8-tetrachlorodibenzo-*p*-dioxin (TCDD) affects tooth development in rhesus monkeys

Iku Yasuda<sup>a</sup>, Mineo Yasuda<sup>b, \*</sup>, Hiroshi Sumida<sup>c</sup>, Hideshi Tsusaki<sup>d</sup>, Akihiro Arima<sup>d</sup>,  
Toshio Ihara<sup>d</sup>, Shunichiro Kubota<sup>e</sup>, Kazuo Asaoka<sup>f</sup>,  
Kazuhiro Tsuga<sup>a</sup>, Yasumasa Akagawa<sup>a</sup>

<sup>a</sup> Department of Advanced Prosthodontics, Division of Cervico-Gnathostomatology, Programs for Applied Biomedicine, Graduate School of Biomedical Sciences, Hiroshima University, Hiroshima 734-8553, Japan

<sup>b</sup> Department of Clinical Engineering, Faculty of Health Sciences, Hiroshima International University, Hiroshima 724-0695, Japan

<sup>c</sup> Department of Clinical Radiology, Faculty of Health Sciences, Hiroshima International University, Hiroshima 724-0695, Japan

<sup>d</sup> Drug Safety Research Laboratories, Shin Nippon Biomedical Laboratories Ltd., Kagoshima 891-1394, Japan

<sup>e</sup> Department of Life Science, Graduate School of Arts and Sciences, The University of Tokyo, Tokyo 153-8902, Japan

<sup>f</sup> Primate Research Institute, Kyoto University, Aichi 484-8506, Japan

Received 26 October 2004; received in revised form 3 December 2004; accepted 20 December 2004

Available online 18 March 2005

### Abstract

We thought to validate the current tolerable daily intake (TDI) value for dioxin (4 pg/kg) in Japan. Pregnant rhesus monkeys received an initial dose of 2,3,7,8-tetrachlorodibenzo-*p*-dioxin (TCDD; 0, 30, or 300 ng/kg subcutaneously) on day 20 of gestation; the dams received additional injection of 5% of the initial dose every 30 days until day 90 after delivery. The teeth of stillborn, postnatally dead, and surviving offspring (now approximately 4 years old) were evaluated. None of the offspring in the 0 and 30 ng/kg groups ( $n = 17$  and 15, respectively) had tooth abnormalities, whereas 10 of 17 in the 300 ng/kg had them. These findings suggest the lowest-observed adverse-effect level (LOAEL) for TCDD in the rhesus monkey is between 30 and 300 ng/kg, and probably is close to that for rodents (86 ng/kg) on which the current TDI was based. It is reasonable to conclude that the current TDI needs no immediate modification.

© 2005 Elsevier Inc. All rights reserved.

**Keywords:** Dioxin; TCDD; Tooth; Rhesus monkey; Primate; TDI; Developmental toxicity; LOAEL

### 1. Introduction

Dioxins are ubiquitous environmental pollutants. Although contamination levels are decreasing [1], the adverse effects of dioxins, especially their reproductive and developmental toxicities, still attract much public concern, and regulatory agencies worldwide are seeking to define a reasonable permissible intake level. In Japan, the current tolerable daily intake (TDI) of dioxin and dioxin-related compounds has been set at 4 pg toxic equivalent (TEQ)/kg/day [2]. This value was calculated from the lowest-observed adverse-effect

level (LOAEL) in experimental animals, mostly rodents. A single oral dose of 200 ng/kg of 2,3,7,8-tetrachlorodibenzo-*p*-dioxin (TCDD) to pregnant rats on day 15 of gestation resulted in abnormalities of reproductive organs in the offspring [3]. The maternal body burden at this dose was measured to be 86 ng/kg. To attain this body burden level, human daily intake was calculated to be 43.6 pg/kg/day. An uncertainty factor of 10 was applied to this value, and the human TDI of 4 pg/kg was established. However, great differences between the biological half-life of TCDD in humans and rodents have called into question the validity of this calculation. To obtain a more reliable LOAEL for dioxins, in 1999 we initiated a long-term developmental toxicity study in rhesus monkeys.

\* Corresponding author. Tel.: +81 829 36 0224; fax: +81 829 36 0224.  
E-mail address: [mineoyas@ck9.so-net.ne.jp](mailto:mineoyas@ck9.so-net.ne.jp) (M. Yasuda).

In rodents, the teeth are known targets of the developmental toxicity of dioxin; in utero and lactational TCDD exposure affects incisor and molar development in rats [4]. Tooth abnormalities also occurred among human populations accidentally exposed to dioxins [5] or polychlorinated biphenyls (PCBs) and polychlorinated dibenzofurans (PCDF) [6,7]. During our monkey experiment, some offspring were stillborn or died neonatally. These animals provided us with a unique opportunity to study tooth development in primate offspring exposed to TCDD in utero and while nursing. Macroscopic observation revealed tooth abnormalities in the offspring from mothers exposed to a relatively high dose of TCDD (300 ng/kg on day 20 of gestation and 15 ng/kg every 30 days during pregnancy) [8]. This finding prompted us to examine surviving offspring radiographically, and we found that tooth abnormalities occurred at a high frequency in the high-dose group. These offspring are still alive and growing, and various studies are in progress. This report describes the dental findings obtained as of April 2004.

## 2. Materials and methods

### 2.1. Animals

Colony bred adult female rhesus monkeys (age, 3–10 years; weight, 4–7 kg) were purchased from China National Scientific Instruments & Materials Import/Export Corporation (Beijing, China). Details of breeding conditions are given elsewhere [9]. Briefly, the animals were housed in stainless-steel cages (68 cm × 70 cm × 77 cm), and received approximately 144 g of solid diet (Harlan Tekland, Harlan Sprague Dawley Inc., Indianapolis, IN, USA) daily. The rooms were maintained at  $26 \pm 2^\circ\text{C}$  and  $50 \pm 10\%$  relative humidity and on a 12-h light cycle (lights on, 06:00–18:00 h). Female monkeys were allowed to cohabit with males on days 12, 13, and 14 of the menstrual cycle. When copulation was confirmed visually, the median day of the mating period (day 13 of the menstrual cycle) was designated as day 0 of gestation (GD 0). On GD 18 or 19, pregnancy was confirmed by ultrasonography (SSD-2000, Aloka Co. Ltd., Tokyo, Japan) of animals anesthetized by an intramuscular injection of 5% ketamine hydrochloride (5–10 mg/kg, Sigma-Aldrich Corporation, St. Louis, MO, USA). Pregnant monkeys were divided into three groups, each consisting of approximately 20 animals. During gestation, all dams were observed for general condition at least once daily and they were weighed once every 20 days.

The dams were allowed to deliver naturally. The day on which delivery was detected was designated as postnatal day 0 (PND 0). Delivered offspring were examined macroscopically, and allowed to cohabit with their mothers for approximately 1 year. The offspring were weighed once every 10 days until PND 90, once every 20 days until PND 150, and once every 30 days thereafter. The animals were reared in the monkey facility of Shin Nippon Biomedical Laboratories

Ltd. (SNBL, Kagoshima, Japan) and were treated humanely according to the guidelines of animal experiments for SNBL. Animal excreta and carcasses were handled with extreme care, and all waste was burned in an incinerator equipped with an afterburner held at  $>800^\circ\text{C}$ .

### 2.2. Chemicals and administration

TCDD (lot number 110899, purity  $>98\%$  as determined by gas chromatography, Wellington Laboratories Inc., Guelph, Ontario, Canada) was dissolved in a mixture of toluene/dimethylsulfoxide (DMSO; 1:2, v/v) at a concentration of 300 ng/ml. The solution was prepared by Kanto Kagaku Co. Ltd. (Tokyo, Japan) and final concentrations were confirmed by gas chromatography. Confirmed pregnant female monkeys received TCDD subcutaneously into the back region on GD 20 at an initial dose of 30 or 300 ng/kg. This route was selected to avoid uncertainty of absorption by oral administration. The dosing volume was 0.1 ml/kg for the lower-dose group and 1 ml/kg for the higher-dose group. Controls received the vehicle in a volume of 1 ml/kg. To maintain the desired body burden, dams received 5% of the initial dose (i.e., 1.5 or 15 ng/kg) every 30 days during pregnancy and lactation until PND 90. For the maintenance dosing, a TCDD solution at a concentration of 30 ng/ml was prepared, and animals in the lower-dose group received 0.05 ml/kg in each injection whereas those in the higher-dose group received 0.5 ml/kg. The total dose administered to the higher-dose group was 405 ng/kg ( $300 + 15 \times 7$  for dams with gestation length less than 170 days) or 420 ng/kg ( $300 + 15 \times 8$  for dams with gestation length 170 days or more) and that to the lower-dose group was 40.5 or 42 ng/kg. The lower-dose level was set at about one-third of the LOAEL body burden in rodents (86 ng/kg) and the higher one at about three times the LOAEL. The maintenance-dosing schedule was set according to the assumption that the biological half-life of TCDD in rhesus monkeys is approximately 1 year [10].

### 2.3. Macroscopic observation

Stillborn fetuses and offspring that died by PND 100 were necropsied, and the upper and lower jaws were dissected for detailed observation. Macroscopic observation was made under a dissecting microscope (SZX12, Olympus Corporation, Tokyo, Japan). Photographs were taken using a digital camera (C-4040, Olympus). Surviving offspring were anesthetized by intramuscular injection of ketamine at 10 mg/kg into the thigh before intraoral examination, and photographs were taken using an intraoral digital camera (Crystal Cam II, GC Co. Ltd., Tokyo, Japan).

### 2.4. Radiographic observation

Conventional intraoral radiographs were taken using a portable X-ray apparatus (KX-60, Asahi Roentgen Ind. Co.

Table 1  
Pregnancy outcome and postnatal mortality

Dose of TCDD	No. of dams	No. of abortions	No. of stillbirths	No. of live births	No. of early postnatal deaths <sup>a</sup>	Gestation length (days)	Birth weight (g)
Control	23	2	3	18	1	161.8 ± 7.8	426.1 ± 58.6
30 ng/kg	20	0	5	15	0	163.8 ± 5.9	426.8 ± 56.9
300 ng/kg	20	1	3	16	2	164.9 ± 9.7	402.7 ± 62.1
300 ng/kg <sup>b</sup>	9	5	1	3	0	165.0 ± 3.0	466.0 ± 87.1

<sup>a</sup> Death by PND 100.

<sup>b</sup> Additional group.

Ltd., Kyoto, Japan) with a charge-coupled device (CCD; Gen-dex Visualix, Dentsply International Inc., York, PA).

### 2.5. Statistical analysis

All the data were analyzed using JMP5.1.1J (SAS Institute Japan, Tokyo, Japan). Analysis of variance was used to compare measurement data, such as length of gestation and body weight. The incidence of tooth abnormalities was compared by using Fischer's exact probability test. A statistically significant difference was confirmed at  $P < 0.05$ .

## 3. Results

### 3.1. Pregnancy outcomes

TCDD administration apparently had no effect on maternal health. Pregnancy outcomes are summarized in Table 1. Abortions, stillbirths, and early postnatal deaths occurred at fairly high frequencies in the TCDD-treated groups as well as the control group. The prenatal and early postnatal mortality rate of the offspring was higher in the 300 ng/kg group (41%) than in the control group (26%), but the difference was not statistically significant ( $P > 0.1$ ). In an attempt to increase the number of surviving offspring in the 300 ng/kg group, we added nine dams to the group approximately 2 years after the initiation of the experiment. However, only two surviving offspring were added due to a high incidence of abortions. There were no significant differences in the average length of gestation and average birth weight among the three groups.

### 3.2. Dental findings

#### 3.2.1. Dentition in normal rhesus monkeys

The number and types of teeth of the rhesus monkey are similar to those of humans. The number of deciduous and permanent teeth is 20 and 32, respectively. Fig. 1 illustrates outlines of these teeth and the code for designation of each tooth used in Tables 2 and 3. Neonatal monkeys usually have no erupted teeth. The central incisors erupt during the first postnatal month. The approximate ages of eruption of deciduous teeth are 0.5 month for the central incisors, 1 month for the lateral incisors, 2 months for the canines, 2.5 months for the first molars, 5 months for the second molars in the lower jaw, and 7 months for the second molars in the upper jaw. Those of permanent teeth are 2.5 years for the central incisors, 2.7 years for the lateral incisors, 3.5 years for the canines and the first premolars, 2.7 years for the second premolars, 1.5 years for the first molars, 3.5 years for the second molars, and 5.5 years for the third molars [11]. During this study, we found that there were fairly large inter-individual variations for the age of eruption of teeth.

#### 3.2.2. Dental findings in stillborn offspring and those that died postnatally

The incidences of tooth abnormalities are given in Table 4. During the early stage of this study, some carcasses from stillbirths and postnatal deaths were discarded inadvertently; therefore, the numbers of specimens in Table 4 are smaller than the total numbers of stillbirths and live births in Table 1. Stillborn fetuses from the control group had no erupted teeth in either the upper or lower jaw (Fig. 2A and E). However, conventional radiographs clearly revealed the presence of 20

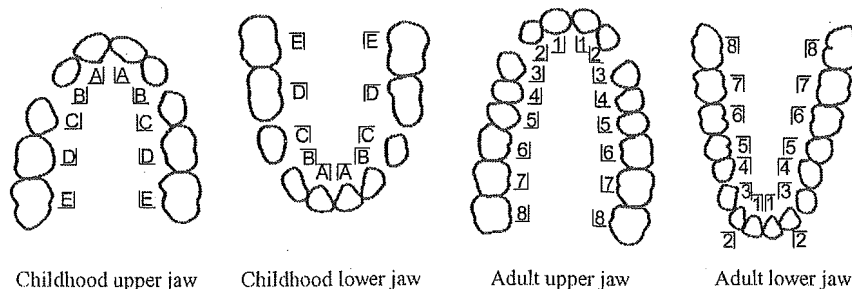


Fig. 1. Diagram illustrating outlines of rhesus teeth seen from the occlusal plane and the code for designation used in Tables 2 and 3. (A–E) Deciduous teeth: (A) central incisor, (B) lateral incisor, (C) canine, (D) first molar, (E) second molar. (1–8) Permanent teeth: (1) central incisor, (2) lateral incisor, (3) canine, (4) first premolar, (5) second premolar, (6) first molar, (7) second molar, (8) third molar. (UR) Upper right, (UL) upper left, (LR) lower right, (LL) lower left.

Table 2  
Tooth abnormalities detected in stillbirths and early postnatal deaths in the 300 ng/kg group

Offspring no.	Sex	Death categories	Age <sup>a</sup>	Abnormal findings
34 <sup>b</sup>	♂	Abortion	GD 128	–
37 <sup>c</sup>	♂	Stillbirth	GD 164	<u>A</u> <u>A</u> <u>D</u> <u>A</u> <u>A</u> precocious eruption, dysplasia <u>B</u> missing
40 <sup>c</sup>	♀	Early postnatal death	PND 26	<u>B</u> precocious eruption, incomplete calcification <u>A</u> <u>A</u> missing
43 <sup>d</sup>	♂	Stillbirth	GD 176	–
57 <sup>d</sup>	♂	Early postnatal death	PND 1	<u>B</u> <u>A</u> <u>A</u> <u>B</u> <u>A</u> <u>A</u> precocious eruption, incomplete calcification
103 <sup>d</sup>	♀	Stillbirth	GD 173	–

(–) No abnormalities were detected.

<sup>a</sup> GD: gestation days; PND: postnatal days.

<sup>b</sup> Total dose of TCDD administered to the dams: 345 ng/kg.

<sup>c</sup> Total dose of TCDD administered to the dams: 360 ng/kg.

<sup>d</sup> Total dose of TCDD administered to the dams: 375 ng/kg.

Table 3  
Tooth abnormalities detected in surviving offspring in the 300 ng/kg group

Offspring no.	Sex	Age <sup>a</sup> at observation	Abnormal findings
31 <sup>b</sup>	♀	941, 1041, 1122, 1430	<u>5</u> <u>4</u> <u>2</u> <u>2</u> <u>4</u> missing, <u>1</u> <u>5</u> cone-shaped, <u>5</u> <u>1</u> maldirected
33 <sup>c</sup>	♂	960, 1060, 1449	–
35 <sup>c</sup>	♀	936, 1036, 1425	–
39 <sup>b</sup>	♂	921, 1021, 1102, 1410	<u>5</u> <u>4</u> <u>2</u> <u>2</u> <u>4</u> <u>5</u> missing
42 <sup>c</sup>	♀	926, 1026, 1415	<u>5</u> <u>1</u> <u>5</u> missing, <u>4</u> cone-shaped
44 <sup>c</sup>	♂	926, 1026, 1415	<u>5</u> <u>4</u> <u>4</u> <u>5</u> maldirected
60 <sup>c</sup>	♂	899, 999, 1080, 1388	<u>5</u> <u>4</u> <u>2</u> <u>2</u> <u>4</u> <u>5</u> <u>5</u> <u>1</u> <u>5</u> missing
66 <sup>b</sup>	♂	849, 949, 1030, 1338	<u>5</u> <u>2</u> <u>1</u> <u>2</u> <u>1</u> <u>1</u> missing, <u>4</u> <u>5</u> cone-shaped, maldirected, <u>5</u> <u>4</u> <u>4</u> <u>5</u> maldirected
102 <sup>c</sup>	♂	177, 278	–
106 <sup>c</sup>	♀	198, 299, 380, 688	<u>A</u> <u>A</u> <u>4</u> <u>1</u> <u>2</u> <u>4</u> missing
109 <sup>c</sup>	♀	189, 290, 679	–

(–) No abnormalities were detected.

<sup>a</sup> Postnatal days.

<sup>b</sup> Total dose of TCDD administered to the dams: 420 ng/kg.

<sup>c</sup> Total dose of TCDD administered to the dams: 405 ng/kg.

well-formed deciduous teeth (Fig. 3A and E). Each tooth could be identified by its characteristic shape and size.

Dental examination of the dead offspring revealed tooth abnormalities only in the 300 ng/kg group. Three of the five animals had tooth abnormalities such as precocious eruption, dysplasia, incomplete calcification, and missing teeth. Although the incidence of tooth abnormalities in the 300 ng/kg group was high (60%), it did not differ significantly from the control incidence (0%;  $P > 0.1$ ), perhaps because of the small sample size. Descriptions of offspring with tooth abnormalities follow, and representative macro-

scopic photographs and conventional radiographs are shown in Figs. 2 and 3, respectively. Abnormal findings are summarized in Table 2.

*Offspring No. 37* was stillborn on GD 164. The deciduous upper central incisors and left first molar had erupted precociously (Fig. 2B). The erupted teeth were irregular in shapes and apparently were destroyed. X-ray examination revealed incomplete calcification in the erupted teeth, and the deciduous upper left lateral incisor was missing (Fig. 3B). The deciduous lower central incisors also had erupted precociously; these teeth were dark brown (Fig. 2F) and their

Table 4  
Incidence of tooth abnormalities

Group	Stillbirths and early postnatal deaths		Surviving offspring	
	No. of offspring	No. of offspring with tooth abnormalities (%)	No. of offspring	No. of offspring with tooth abnormalities (%)
Control	4	0 (0)	13	0 (0)
30 ng/kg	5	0 (0)	13	0 (0)
300 ng/kg	5	3 (60)	8	6 (75) <sup>b</sup>
300 ng/kg <sup>a</sup>	1	0 (0)	3	1 (33)

<sup>a</sup> Additional group.

<sup>b</sup> Significantly different from the control group ( $P < 0.01$ ).

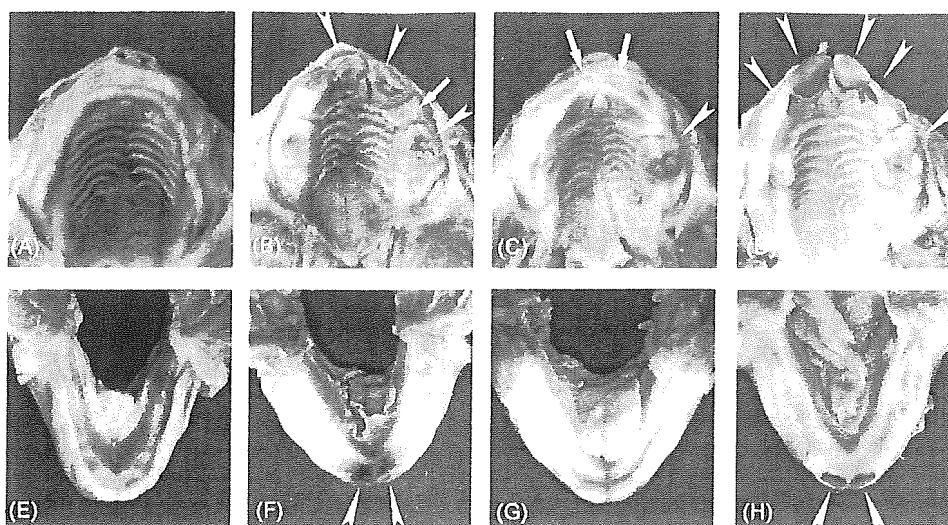


Fig. 2. Macroscopic photographs of jaws from a control offspring (A and E) and from offspring in the 300 ng/kg group with tooth abnormalities (B–D, F–H), which were stillborn or died early postnatally. Upper jaws (A–D) and lower jaws (E–H). Arrowheads indicate precocious eruption. Arrows point the location of missing teeth detected by X-ray. Offspring numbers and ages: (A and E) No. 10, GD 146; (B and F) No. 37, GD 164; (C and G) No. 40, PND 26; (D and H) No. 57, PND 1.

calcification seemed slightly retarded (Fig. 3F) as compared with that of a control animal stillborn at an earlier gestational age (Fig. 3E, No. 10: stillborn on GD 146).

*Offspring No. 40* died postnatally on PND 26. The deciduous upper left first molar had erupted precociously (Fig. 2C). The four cusps were discernible macroscopically but were unclear in the radiograph (Fig. 3C), indicating retarded calcification of the tooth. X-ray examination revealed that both the deciduous upper central incisors were missing. A slight deviation of the anterior nasal septum to the left was noted (Fig. 3C). The lower teeth were still in the gum, and no abnormality was detected radiographically (Fig. 3G).

*Offspring No. 57* died when a neonate, on PND 1. The bilateral deciduous upper central and lateral incisors, upper left first molar (Fig. 2D), and bilateral lower central incisors (Fig. 2H) had erupted precociously. The lower incisors were dark brown. X-ray examination revealed retarded calcification in these precociously erupted teeth (Fig. 3D and H).

### 3.2.3. Dental findings in surviving offspring

The incidences of tooth abnormalities in the surviving offspring are given in Table 4. The incidence in the 300 ng/kg group (total, 70%) was significantly higher than that in the control group (0%;  $P < 0.01$ ). Representative macroscopic

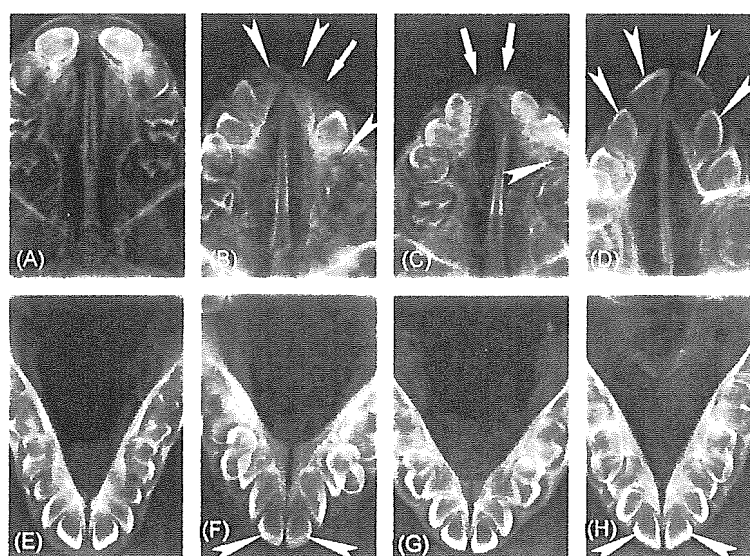


Fig. 3. Conventional radiographs of jaws shown in Fig. 2. Radiographs are arranged corresponding to Fig. 2. Upper jaws (A–D) and lower jaws (E–H). Arrowheads and arrows indicate precocious eruption and missing teeth, respectively. Offspring numbers: (A and E) No. 10; (B and F) No. 37; (C and G) No. 40; (D and H) No. 57.

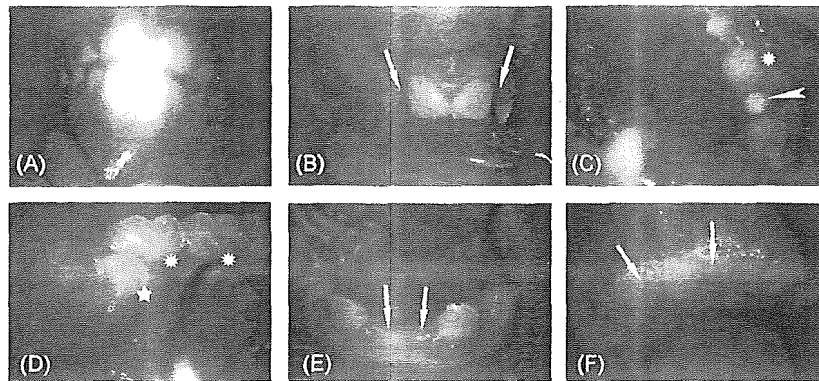


Fig. 4. Macroscopic photographs of surviving offspring in the control group (A) and 300 ng/kg group with tooth abnormalities (B–F). Arrows: missing; arrowhead: cone-shaped; star: maldirected; asterisks: remaining deciduous teeth. Offspring numbers and ages: (A) No. 1, PND 1438; (B and C) No. 31, PND 1430; (D) No. 44, PND 1415; (E) No. 66; PND 1338; (F) No. 106, PND 688. (A) Upper and lower incisors; (B) upper incisors; (C) upper left molars; (D) lower right molars; (E) lower incisors; (F) upper incisors.

and radiographic photographs are shown in Figs. 4 and 5, respectively. Abnormal findings are summarized in Table 3.

**3.2.3.1. Offspring observed between approximately PND 800 and PND 1400.** In the vehicle-treated group, offspring were at the stage of losing the deciduous teeth during the period of PND 800–PND 1400. In the majority of animals, the permanent central and lateral incisors and the first molars had erupted. By conventional radiography, all the permanent teeth except for the third molars were detectable. Descriptions of a control animal and the monkeys from the 300 ng/kg group with tooth abnormalities follow.

*Offspring No. 1* is a control animal. Fig. 4A shows the central upper and lower jaws on PND 1438. The permanent

central incisors had erupted. Fig. 5A is a radiograph of the anterior upper jaw taken on PND 1049. The midline is approximated by the left border of the picture. The deciduous central incisor had been lost and the permanent central incisor had erupted. The deciduous lateral incisor still remained but was being pushed up by the growing permanent incisor. The permanent canine was discernible deep to the long root of the deciduous canine on the distal side of the root of the permanent lateral incisor. The canine could be easily identified by the pointed shape of the crown. Fig. 5B shows the upper left molars radiographed on PND 1438. The deciduous first molar had been lost and the first premolar had erupted. The crown of the deciduous second molar remained posterior to the permanent first premolar, and it was being pushed up by the perma-

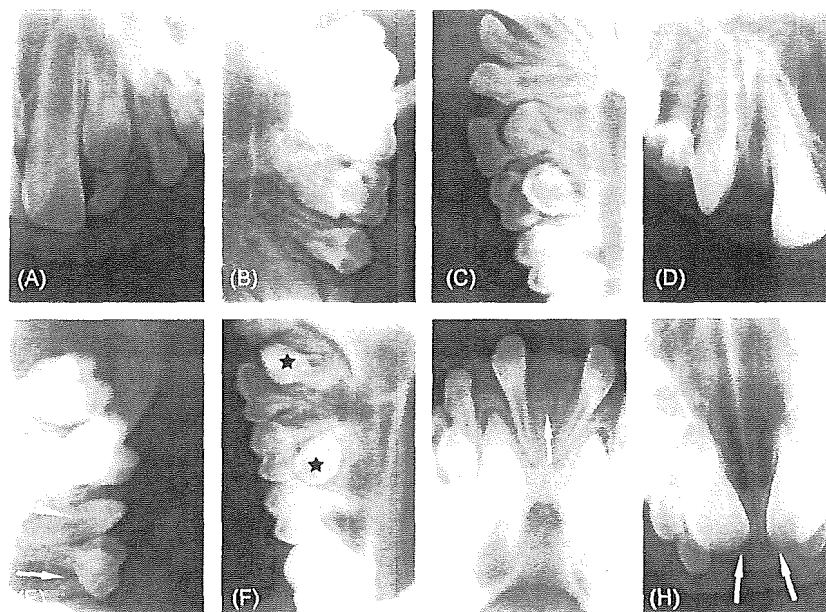


Fig. 5. Conventional radiographs of surviving offspring in the control group (A–C) and 300 ng/kg group with tooth abnormalities (D–H). Arrows: missing; arrowhead: cone-shaped; stars: maldirected. Offspring numbers and ages: (A) No. 1, PND 1049; (B and C) No. 1, PND 1438; (D and E) No. 31, PND 1430; (F) No. 44, PND 1415; (G) No. 66, PND 1338; (H) No. 106, PND 688. (A) Upper left incisors and canine; (B) upper left molars; (C) lower right molars; (D) upper right incisor and canine; (E) upper left molars; (F) lower left molars; (G) lower incisors; (H) upper incisors.

nent second premolar. The permanent first and second molars had erupted, but the third molar could not be seen clearly. Fig. 5C shows the lower right lateral incisor, canine, and molars on PND 1438. The lateral incisor and canine were permanent teeth, but the deciduous first and second molars still remained, being pushed up by the growing permanent first and second premolars. The permanent first molar had erupted.

Offspring No. 31–66 are members of the 300 ng/kg group.

*Offspring No. 31* was observed macroscopically on PND 1430. It was found that both the upper permanent lateral incisors were missing (Fig. 4B, arrows). The upper left second premolar had erupted but its crown was small and cone-shaped (Fig. 4C, arrowhead). These defects were confirmed by radiography (Fig. 5D, arrow; Fig. 5E arrowhead). Radiographs taken on PND 1430 showed that the upper left deciduous first molar remained, and no permanent first premolar was found between the roots of the deciduous first molar (Fig. 5E, arrow); therefore, a missing permanent first premolar was diagnosed. Similar findings from the upper right side led to diagnosis of missing first and second premolars on this side. In the lower jaw, the right second premolar had erupted, but its crown was on the lingual side of the alveolar gum. Radiographically, the axis of the second premolar was inclined in a lingual and distal direction.

*Offspring No. 39* was examined radiographically on PND 1410. The upper permanent lateral incisors and the first and second premolars were missing bilaterally.

*Offspring No. 42* had an upper left first premolar that was cone-shaped, and the upper second premolars were missing bilaterally according to observation on PND 1415.

*Offspring No. 44* had a lower right first premolar that was inclined in a lingual and mesial direction, and it had erupted on the lingual side of the alveolar gum (PND 1415; Fig. 4D, star). Because of this maldirection, the deciduous first molar still remained. Similarly, the lower right second premolar was maldirected, and the deciduous first and second molar also remained (Fig. 4D, asterisks). The lower left first premolar had not erupted, but a radiograph showed that the first and second premolar were maldirected (Fig. 5F, stars) and the deciduous first and second molars remained.

*Offspring No. 60* was evaluated macroscopically and radiographically on PND 1388. These studies indicated that both lateral incisors and both first and second premolars were missing from the upper jaw. In addition, both second premolars were missing from the lower jaw.

*Offspring No. 66* had an upper jaw from which the bilateral permanent lateral incisors and the right second premolars were missing, and the left first and second premolars were cone-shaped. In the lower jaw, the permanent central incisors were found to be absent on PND 1338 (Fig. 4E, arrows). The remaining permanent incisors were close to the canines, and there was a wide space between the two incisors (Fig. 5G, arrow), indicating that the incisors were lateral ones. The upper left first and second premolars had been erupted by PND 1338, but were cone-shaped and maldirected. The lower first and second premolars were also maldirected bilaterally.

*3.2.3.2. Offspring observed between approximately PND 200 and PND 700.* The two surviving offspring that were added to the 300 ng/kg group were approximately PND 200 at the time of their first radiographic examination. They were followed until approximately PND 700. Only one of these animals, *Offspring No. 106*, had obvious tooth abnormalities. This animal had a wide space between the small incisors in the upper jaw; this defect first was observed on PND 198, and was confirmed on PND 688 (Fig. 4F, arrows). Radiographs taken on PND 688 showed the growing permanent central incisors and a wide median gap between the remaining deciduous teeth (Fig. 5H, arrows), indicating that the deciduous central incisors were missing. In addition, the upper bilateral first premolars and the left permanent lateral incisor were missing.

#### 4. Discussion

The results of the present study clearly showed that prenatal and lactational exposure to TCDD with an initial dose of 300 ng/kg and a maintenance dose of 15 ng/kg affected tooth development in rhesus monkeys. The exposure began on GD 20, when the rhesus embryo is at the stage of primitive streak formation, corresponding to Carnegie stage 8 in the human embryo [12], and no tooth germs are present. In humans, the dental lamina, the earliest indication of teeth, appears by the 6th week of development [13]. The human embryo at 6 weeks after fertilization (Carnegie stage 17) corresponds to the rhesus embryo at 5 weeks after fertilization [14]. The human permanent tooth bud first appears around 10 weeks after fertilization, which corresponds to approximately 8 weeks after fertilization in the rhesus.

According to our observations, the 20 deciduous teeth had been well shaped by the time of delivery in the control offspring. Although the last maintenance injection of TCDD was done on PND 90, the offspring was considered to be exposed to TCDD via milk until weaning, approximately 1 year after birth. Even after weaning, TCDD that had accumulated in the various tissues gradually was released into the blood and could have affected developing permanent teeth. Hence, it is reasonable to assume that deciduous as well as permanent teeth were exposed to TCDD throughout the critical period of development and that the observed tooth abnormalities were associated with TCDD exposure.

Unfortunately, some of the carcasses from the stillbirths and postnatal deaths were discarded, and therefore, unavailable for dental examination. However, all the dental abnormalities we identified were noted after the disposal, and we feel that no bias was introduced into the sampling of the specimens. The incidences of tooth abnormalities among stillbirths and early postnatal deaths did not differ significantly between the control (0%) and 300 ng/kg (60%) groups, probably because of the small sample size. However, the difference among the surviving offspring is statistically significant and we, therefore, reasonably consider that



all the observed tooth abnormalities are due to TCDD exposure.

Developmental studies with TCDD in the rhesus monkey have been performed for more than 25 years and by several groups [15–19]. The main finding in these studies was abortions, and tooth abnormalities were not reported. However, one dioxin-related compound, 3,4,5,3',4',5'-hexachlorinated biphenyl (Aloclor 1242) has been reported to affect tooth development in rhesus monkeys [20]. These animals had cystic periodontal lesions around the unerupted molars 13 months after consumption of food containing 400 ppm Aloclor 1242 for 40 days, suggesting that dioxins might affect developing teeth in primates.

TCDD affects tooth development in rodents. A single oral dose of 1 µg/kg to pregnant rats on GD 15 disturbed post-natal molar development in the offspring [21]. Lactational exposure through maternal intraperitoneal administration of TCDD to rats at a dose level of 1000 µg/kg on PND 1 also affected molar development in the offspring [22,23]. In addition, growing incisors in rats were sensitive to continuous exposure to TCDD for 20 weeks beginning from 10 weeks of age [24].

Human epidemiological studies have been conducted to examine possible association between dioxin exposure and tooth abnormalities. In Finland, 102 6–7-year-old children who were breast-fed for an average of 10.5 months were studied. Milk samples were collected when the children were 4 weeks old, and the concentrations of dioxins and furans were determined. The total exposure to dioxins was calculated from the concentrations in milk and the duration of breast-feeding. The frequency and severity of hypomineralization of teeth correlated with the total exposure [25].

Follow-up studies after accidental exposure to dioxins also have indicated that the teeth are targets of developmental toxicity of these toxicants. High frequencies of delayed eruption and missing permanent teeth occurred among children with fetal Yusho or Yuchen (oil disease), which occurred in 1968 in Japan and in 1979 in Taiwan after ingestion of rice oil, contaminated with PCBs and PCDFs [6,7]. In addition, examination of 48 people exposed to dioxins because of the notorious accident in Seveso, Italy, in 1976 revealed a high incidence of developmental defects of enamel and missing permanent teeth [5]. These subjects had been younger than 9.5 years at the time of the accident and were examined for tooth abnormalities 25 years afterward. Plasma collected in 1976 had TCDD concentrations that ranged from 23 to 26,000 ng/kg in serum lipid. Subjects with higher serum-TCDD levels had developmental dental defects more often than those with lower TCDD levels.

In the present study, we found positional differences among teeth as manifestations of the sensitivity to the developmental toxicity of TCDD. Even before eruption, each tooth can be easily identified in light of the position of the canine, which is large and has a characteristically pointed crown. The canines were not affected in any of our monkeys; the vulnerable teeth were the central and lateral incisors, de-

ciduous first molars, and the first and second premolars. In the patients with Yusho, the most frequent missing tooth was the lower premolar, followed by the lower lateral incisor [6]. In humans, the lateral incisor and the second premolar are considered to have a regressing tendency in the process of evolution [26], and these teeth are missing relatively frequently in the general population. This intrinsic regressive tendency might be exacerbated by exogenous toxicants, resulting in positional differences in sensitivity.

It is well known that interactions between the ectoderm covering the first branchial arch and the mesenchyme derived from the neural crest are important in tooth morphogenesis. Several signal molecules and their receptors have been identified [27]. TCDD is a potent modulator of epithelial cell growth and differentiation [28], and most of its toxic effects are mediated by the aryl hydrocarbon receptor (AhR) [29]. For example cleft palate induction by TCDD was completely abolished in AhR knockout mice [30]. In mouse tooth buds, AhR is expressed in secretory odontoblasts and ameloblasts [23], suggesting the pathway via AhR as a mediator of dental toxicity of TCDD. One candidate for the pathway of TCDD action on tooth morphogenesis involves epidermal growth factor (EGF) and the EGF receptor (EGFR). TCDD added to cultured embryonic mouse mandibular molar tooth germs induced depolarization of ameloblasts and disturbed morphogenesis [31]. EGF added to the TCDD-containing medium suppressed the adverse effects of TCDD. The effect of TCDD was less dramatic on tooth germs from EGFR knockout mice [31]. Although no study has assayed expression of EGF or EGFR during tooth morphogenesis in rhesus embryos, these findings suggest that the EGF–EGFR signaling system may work in tooth development in the rhesus monkey as well as the mouse and that disturbance of this system by TCDD results in dysmorphogenesis of rhesus teeth.

In addition to altered epithelial–mesenchymal interaction, excessive apoptosis may be involved in the pathogenesis of tooth defects. TCDD added to organ culture of mouse molar tooth germs did not affect cell proliferation but increased apoptosis in the epithelium, resulting in defective molar [32]. In the process of cleft palate induction in mice by TCDD, excessive apoptosis was observed in the epithelium covering the palatal processes and in the palatal mesenchyme [33]. It is plausible that apoptosis induced by TCDD played a role in induction of tooth defects in the present experiment. Cleft palate was not detected in the present study. Probably the dose levels were too low to induce cleft palate in the rhesus monkey. In the sensitive C57 BL strain of mice, the LOAEL level for induction of cleft palate was reported to be 3000 ng/kg/day by oral administration during the period of organogenesis [34]. Detailed examinations of possible target organs of developmental toxicity of TCDD including the urinary, reproductive, and immune systems are in progress.

Our examination of the surviving offspring until the age of approximately 4 years revealed tooth defects only in the 300 ng/kg group. By macroscopic observation with the digital

camera, we could not detect mineralization defects reported in humans [5,25]. Because the permanent molars are still developing in 4-year-old rhesus monkeys, detailed further observation may reveal some subtle abnormalities, such as enamel defects in the offspring currently diagnosed as normal in the 30 and 300 ng/kg groups. Blood samples taken from pregnant and lactational mothers and milk samples await analyses for TCDD concentrations. Although the dosing schedule in the present study was set to keep the body burden at 30 or 300 ng/kg, the actual maternal body burden should be assessed after the autopsy of the mothers and analyses for TCDD, because the TCDD half-life in rhesus monkeys has shown fairly large inter-individual variations [10]. Plasma samples taken at intervals from the offspring are also waiting for TCDD analyses. Assuming that the actual body burden was not much different from the programmed one, the LOAEL body burden for the developmental toxicity of TCDD in rhesus monkeys is considered to be somewhere between 30 and 300 ng/kg and is probably on the order of 86 ng/kg, the value used to set the current TDI in Japan. In 2002, a panel of experts surveyed various data in the literature and concluded that no urgent change was necessary in the current TDI of 4 pgTEQ/kg/day [35]. The results of our present study support this conclusion. However, we should wait to draw a definite conclusion until the measurement of the actual body burden of the dams and detailed examinations of various organs of the offspring.

### Acknowledgements

This study was supported by Health Labour Sciences Research Grants for Research on Chemical Risk from the Ministry of Health Labour and Welfare of Japan. The authors thank Prof. Keiji Tanimoto, Department of Oral and Maxillofacial Radiology, Graduate School of Biomedical Sciences, Hiroshima University for his valuable suggestions for dental radiography.

### References

- [1] Hays SM, Aylward LL. Dioxin risks in perspective; past, present, and future. *Regul Toxicol Pharmacol* 2003;37:170–1.
- [2] Environmental Health Committee of the Central Environment Council, Living Environment Council and Food Sanitation Investigation Council. Memorandum on tolerable daily intake (TDI) of dioxin and related compounds (Japan). Tokyo: Environmental Agency and Ministry of Health and Welfare, Japan; 1999.
- [3] Gray Jr LE, Ostby JS, Kelce WR. A dose–response analysis of the reproductive effects of a single gestational dose of 2,3,7,8-tetrachlorodibenzo-*p*-dioxin in male Long Evans hooded rat offspring. *Toxicol Appl Pharmacol* 1997;146:11–20.
- [4] Mietinen HM, Alaluusua S, Tuomisto J, Viluksela M. Effect of in utero and lactational 2,3,7,8-tetrachlorodibenzo-*p*-dioxin exposure on rat molar development. *Toxicol Appl Pharmacol* 2002;184:57–66.
- [5] Alaluusua S, Calderara P, Gerthoux PM, et al. Developmental dental aberrations after the dioxin accident in Seveso. *Environ Health Perspect* 2004;112:1313–8.
- [6] Fukuyama H, Anan Y, Akamine A, Aono M. Alteration in stomatological findings of patients with Yusho (PCB poisoning) in the general examination. *Fukuoka Acta Med* 1979;70:187–98.
- [7] Lan S-J, Yen Y-Y, Ko Y-C, Chen E-R. Growth and development of permanent teeth germ of transplacental Yu-Cheng babies in Taiwan. *Bull Environ Contam Toxicol* 1989;42:931–4.
- [8] Yasuda I, Yasuda M, Sumida H, et al. Effect of in utero and lactational exposure to 2,3,7,8-tetrachlorodibenzo-*p*-dioxin on tooth development in rhesus monkeys. *Organohalogen Compd* 2003;64:431–4.
- [9] Ihara T, Oneda S, Yamamoto T, et al. An embryotoxic/teratogenic potential and abortifacient effect study of interferon alfacon-1 (Infergen®) via subcutaneous administration to rhesus monkeys. *Cong Anom* 1999;39:223–42.
- [10] Bowman RE, Schantz SL, Weerasinghe NCA, Gross ML, Barsotti DA. Chronic dietary intake of 2,3,7,8-tetrachlorodibenzo-*p*-dioxin (TCDD) at 5 or 25 parts per trillion in the monkey: TCDD kinetics and dose–effect estimate of reproductive toxicity. *Chemosphere* 1989;18:243–52.
- [11] Tajima Y, editor. Biological characteristic data of experimental animals. Tokyo: Soft Science; 1989.
- [12] Heuser CH, Streeter GL. Development of the macaque embryo. *Contrib Embryol Carneg Inst* 1941;29:15–55.
- [13] Sadler TW. Langman's medical embryology. 9th ed. Philadelphia: Lippincott Williams & Wilkins; 2004.
- [14] Gibnau AAM, Geijsberts GM. Developmental stages in the rhesus monkey (*Macaca mulatta*). *Adv Anat Embryol Cell Biol* 1981;68:1–84.
- [15] Allen JR, Barsotti DA, Van Miller JP, Abrahamson LJ, Lalich JJ. Morphological changes in monkeys consuming a diet containing low levels of 2,3,7,8-tetrachlorodibenzo-*p*-dioxin. *Food Cosmet Toxicol* 1977;15:401–10.
- [16] Allen JR, Barsotti DA, Lambrecht LK, Van Miller JP. Reproductive effects of halogenated aromatic hydrocarbons on nonhuman primates. *Ann NY Acad Sci* 1979;320:419–25.
- [17] Barsotti DA, Abrahamson LJ, Allen JR. Hormonal alterations in female rhesus monkeys fed a diet containing 2,3,7,8-tetrachlorodibenzo-*p*-dioxin. *Bull Environ Contam Toxicol* 1979;21:463–9.
- [18] Schantz SL, Barsotti DA, Allen JR. Toxicological effects produced in nonhuman primates chronically exposed to fifty parts per trillion 2,3,7,8-tetrachlorodibenzo-*p*-dioxin (TCDD). *Toxicol Appl Pharmacol* 1979;48(Pt 2):A180.
- [19] McNulty W-P. Fetotoxicity of 2,3,7,8-tetrachlorodibenzo-*p*-dioxin (TCDD) for rhesus macaques (*Macaca mulatta*). *Am J Primatol* 1984;6:41–7.
- [20] McNulty W-P. Toxicity and fetotoxicity of TCDD, TCDF and PCB isomers in rhesus macaques (*Macaca mulatta*). *Environ Health Perspect* 1985;60:77–88.
- [21] Kattainen H, Tuukkanen J, Simanainen U, et al. In utero/lactational 2,3,7,8-tetrachlorodibenzo-*p*-dioxin exposure impairs molar tooth development in rats. *Toxicol Appl Pharmacol* 2001;174:216–24.
- [22] Lukinmaa P-J, Sahlberg C, Leppäniemi A, et al. Arrest of rat molar tooth development by lactational exposure to 2,3,7,8-tetrachlorodibenzo-*p*-dioxin. *Toxicol Appl Pharmacol* 2001;173:38–47.
- [23] Gao Y, Sahlberg C, Kiukkonen A, et al. Lactational exposure of Han/Wistar rats to 2,3,7,8-tetrachlorodibenzo-*p*-dioxin interferes with enamel maturation and retards dentin mineralization. *J Dent Res* 2004;83:139–44.
- [24] Kiukkonen A, Viluksela M, Sahlberg C, et al. Response of the incisor teeth to 2,3,7,8-tetrachlorodibenzo-*p*-dioxin in a dioxin-resistant and a dioxin-sensitive rat strain. *Toxicol Sci* 2002;69:482–9.
- [25] Alaluusua S, Lukinmaa P-L, Koskimies M, et al. Developmental dental defects associated with long breast feeding. *Eur J Oral Sci* 1996;104:493–7.

- [26] Sakai T. Regression of human teeth. *J Jpn Assoc Dental Sci* 1978;31:978–84.
- [27] Thesleff I. Developmental biology and building a tooth. *Quintessence Int* 2003;34:613–20.
- [28] Osborne R, Greenlee WF. 2,3,7,8-tetrachlorodibenzo-*p*-dioxin (TCDD) enhances terminal differentiation of cultured human epidermal cells. *Toxicol Appl Pharmacol* 1985;77:434–43.
- [29] Mimura J, Fujii-Kuriyama Y. Regulatory roles of AhR. *Environ Sci* 2002;9:71–81.
- [30] Mimura J, Yamashita K, Nakamura K, et al. Loss of teratogenic response to 2,3,7,8-tetrachlorodibenzo-*p*-dioxin in mice lacking the Ah (dioxin) receptor. *Genes Cells* 1997;2:645–54.
- [31] Partanen A-M, Alaluusua S, Miettinen PJ, et al. Epidermal growth factor receptor as a mediator of developmental toxicity of dioxin in mouse embryonic teeth. *Lab Invest* 1998;78:1473–81.
- [32] Partanen A-M, Kiukkonen A, Sahlberg C, et al. Developmental toxicity of dioxin to mouse embryonic teeth in vitro: arrest of tooth morphogenesis involves stimulation of apoptotic program in the dental epithelium. *Toxicol Appl Pharmacol* 2004;194:24–33.
- [33] Takagi TN, Matsui KA, Yamashita K, Ohmori H, Yasuda M. Pathogenesis of cleft palate in mouse embryos exposed to 2,3,7,8-tetrachlorodibenzo-*p*-dioxin (TCDD). *Teratog Carcinog Mutagen* 2000;20:73–86.
- [34] Courtney KD, Moore JA. Teratology studies with 2,4,5-trichlorophenoxyacetic acid and 2,3,7,8-tetrachlorodibenzo-*p*-dioxin. *Toxicol Appl Pharmacol* 1971;20:396–4031.
- [35] Working Group for Assessment of Effects of Dioxin on Health. Report of the working group for assessment of effects of dioxin on health. Tokyo: Ministry of Health Labour and Welfare of Japan; 2002.

## Testes of rhesus monkeys exposed in utero and lactational period to 2,3,7,8-tetrachlorodibenzo-p-dioxin

Hiroshi Sumida<sup>1</sup>, Mineo Yasuda<sup>1</sup>, Akihiro Arima<sup>2</sup>, Toshio Fukusato<sup>3</sup>, Shunichiro Kubota<sup>4</sup>

<sup>1</sup>Department of Clinical Radiology, Faculty of Health Sciences, Hiroshima International University

<sup>2</sup>Safety Research Facility, Shin Nippon Biomedical Laboratories, Ltd

<sup>3</sup>Department of Pathology, Teikyo University School of Medicine

<sup>4</sup>Department of Life Sciences, Graduate School of Arts and Sciences, The University of Tokyo

### Introduction

Recently, the relationship between reduction of sperm number in human and environmental contamination of dioxin and dioxin related compounds has been investigated. The current tolerable daily intake (TDI) of dioxin and dioxin related compounds has been set at 4 pg TEQ/kg/day in Japan. This value was calculated from the lowest-observed-adverse-effect level (LOAEL) in experimental animals, mostly rodents. Gray *et al.*<sup>1</sup> reported that a single oral dose of 200 ng/kg of 2,3,7,8-tetrachlorodibenzo-*p*-dioxin (TCDD) to pregnant rats on day 15 of gestation resulted in abnormalities of reproductive organs in the female offspring. The maternal body burden at day of treatment was 97 ng/kg and it was 76 ng/kg at day 21 of gestation. Thus, the maternal body burden at LOAEL was estimated to be the mean of both values, approximately 86 ng/kg. To attain this body burden level, human daily intake was calculated to be 43.6 pg/kg/day. This value was divided by an uncertainty factor of 10, and then the human TDI was established as described above. By TCDD exposure to pregnant rats at the LOAEL<sup>2</sup>, as well as at lower level<sup>3</sup>, reduction of sperm number in offspring has been reported. However, due to great differences in the biological half life of TCDD between human and rodents, the validity of LOAEL in human is questioned. To obtain more reliable LOAEL in the second generation, we initiated a long-term study in rhesus monkeys in 1999. Previously, we reported renal dysgenesis<sup>4</sup> and abnormal development of teeth<sup>5, 6</sup> in young of the TCDD exposed group. In this study, we examined effects of TCDD exposure in utero and lactational periods to development of the testes in young of rhesus monkeys.

### Materials and Methods

Adult rhesus monkeys were mated, and females with confirmation of pregnancy by ultrasonography were given TCDD subcutaneously on day 20 of gestation at an initial dose level of 30 ng/kg (low dose group) or 300 ng/kg (high dose group). Controls received the vehicle. The lower dose level was set at about one third of the LOAEL body burden in rodents, and the higher one at about three times of the LOAEL. For maintenance of a certain body burden, 5% of the initial dose was given to dams every 30 days during pregnancy and lactation until 90 days after delivery. After weaning of the first newborn (F1a), the mothers were mated again, and TCDD was similarly treated but at an initial dose level of 20 ng/kg (low dose group) or 200 ng/kg (high dose group) on this time by consideration as TCDD accumulation in the maternal body. Maintenance treatment for second newborn (F1b) was same as F1a. In this study, totally ten postnatally died young (F1a and F1b aged 365 to 1297 days) and seven F1b sacrificed at the age about 850 days were autopsied. Testes were fixed in Bouin's fixative, and thin sections were routinely prepared for microscopic observations. In the cases where young died postnatally, the area of the seminiferous tubules was measured from the microphotograph.

### Results and Discussion

In control testes of young that died postnatally, the seminiferous tubules and epithelium were well developed, but spermatogenesis was not recognized at the present age (Fig. 1a). In controls, the area of seminiferous tubules occupied about 58% of the testis tissue (Fig.2). On the other hand, the testes of young that died postnatally in the TCDD exposure group were severely edematous (Fig. 1b, c, d). The seminiferous tubules were compressed by the loosely expanded connective tissue. Thus, the area of the seminiferous tubules was significantly decreased compared with that of controls (Fig.2) The area of the seminiferous tubules of high dose group was about half of controls. In one case in the high dose group, a severely fibrous atrophic testis was recognized (Fig. 1d). In this case,

most part of the seminiferous tubules was replaced by the fibrous scar tissue. Diameter of the remaining seminiferous tubules varied greatly, and the lumen of some seminiferous tubules was obscure.

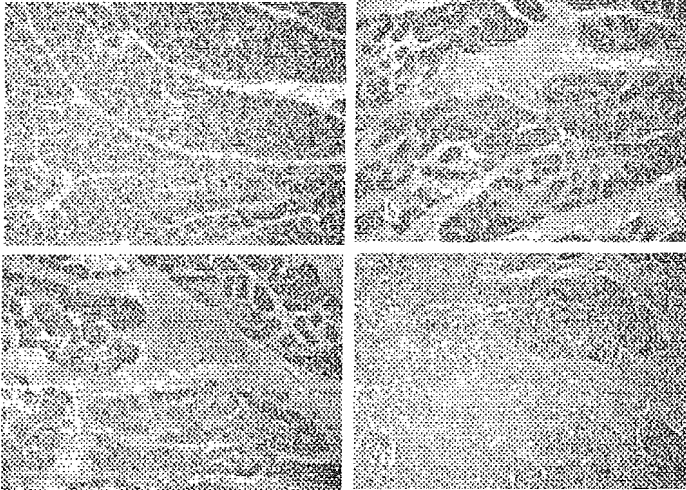


Fig 1  
a: control, b low dose group, c and d high dose group

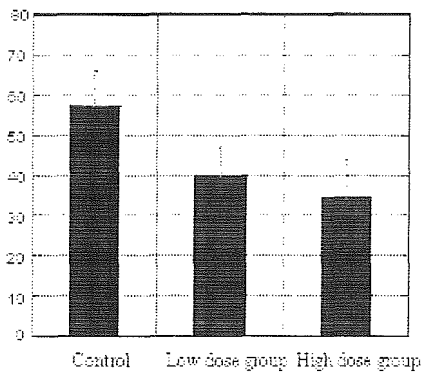


Fig.2 Area of the seminiferous tubules (%)

The histological findings of testes in sacrificed cases were similar with those of young that died postnatally (Fig.3). Some testes of the TCDD exposure group were edematous, like as shown in Fig.3. The level of edema varied among the testes, and it did not depend on dose level. In controls, the seminiferous epithelium was well developed and mature, and the spermatocytes were recognized, but spermatogenesis was not seen at the present age(Fig. 4). In TCDD exposure group, maturity level of the seminiferous epithelium was low, although level of maturity retardation did not depend on dose level.




Fig 3 The testes in sacrificed group  
a: control, b: low dose group




Fig. 4 High power micrograph of the testis tissue in sacrificed group.  
a: control, b: low dose group, arrows: spermatocytes

It should not be concluded that these histological changes are absolutely due to effect of TCDD. However, developing testes of primates might be more sensitive to TCDD than those of rodents. The results of the present study suggest necessity to re-examine the validity of LOAEL in human.

#### Acknowledgements

This study was supported by Health Labour Sciences Research Grants for Research on Food and Chemical Safety from the Ministry of Health Labour and Welfare of Japan.

#### References

1. Gray L.E., Jr., Wolf C., Mann P. and Ostby J.S. (1997) *Toxicol. Appl. Pharmacol.* 146: 237-244.
2. Gray L.E., Jr., Ostby J.S. and Kelce W.R. (1997) *Toxicol. Appl. Pharmacol.* 146: 11-20.
3. Faqi A.S., Dalsenter P.R., Merker H.J. and Chahoud I. (1998) *Toxicol. Appl. Pharmacol.* 150: 383-392.
4. Sumida H., Tsusaki H., Inoue M. and Yasuda M. (2003) *Organohalogen Compounds* 64: 374-377.
5. Yasuda I., Yasuda M., Sumida H., Tsusaki H., Inouye M., Tsuga K. and Akagawa Y. (2003) *Organohalogen Compounds* 64, 431-434.
6. Yasuda I., Yasuda M., Sumida H., Tsusaki H., Arima A., Ihara T., Kubota S., Asaoka, K., Tsuga K. and Akagawa Y. (2005) *Reprod. Toxicol.* 20: 21-30.

## EFFECTS OF TCDD IN UTERO ON REPRODUCTIVE DEVELOPMENT OF RHESUS MONKEY OFFSPRING

Shunichiro Kubota<sup>1</sup>, Toshio Fukusato<sup>2</sup>, Hiroshi Sumida<sup>3</sup>, Kazuo Asaoka<sup>4</sup>, Nobuo Murata<sup>5</sup>, Akihiro Arima<sup>6</sup>, Mineo Yasuda<sup>3</sup>

<sup>1</sup>Dept of Life Sciences, Graduate School of Arts and Sciences, The University of Tokyo

<sup>2</sup>Department of Pathology, Teikyo University School of Medicine

<sup>3</sup>Department of Clinical Radiology, Hiroshima International University

<sup>4</sup>Primate Research Institute, Kyoto University

<sup>5</sup>Department of Surgery, Mizonokuchi Hospital, Teikyo University School of Medicine

<sup>6</sup>Drug Safety Research Laboratories, Shin Nippon Biomedical Laboratories

### Introduction

*In utero* and lactational exposure to 2,3,7,8-tetrachlorodibenzo-*p*-dioxin (TCDD) results in wide variety of effects including developmental abnormality in the reproductive organs, immunological dysfunction, teratogenicity and carcinogenesis<sup>1-7</sup>. It was reported that a single oral dose of 200 ng/kg of TCDD to pregnant rats resulted in abnormalities of reproductive organs in the female offspring<sup>3</sup>. The maternal body burden at LOAEL was estimated as approximately 86 ng/kg. To attain this body burden level, human daily intake was calculated to be 43.6 pg/kg/day. This value was divided by an uncertainty factor of 10, and the tolerable daily intake (TDI) of dioxin and dioxin related compounds was determined at 4 pg TEQ/kg/day in Japan in 1998. Considering the pronounced difference between species observed in some previous studies, it is necessary to obtain more reliable LOAEL. Therefore, we started the present study in 1999 to clarify effects of low dose TCDD on development of the reproductive organs, in non-human primate after subcutaneous administration of TCDD into rhesus monkeys during pregnancy and lactation. During the course of the present study, we found abnormal protein expression in liver and brain<sup>8</sup>, and liver injury<sup>9</sup> in F0 monkeys exposed to TCDD, and abnormal development of teeth<sup>10</sup> in F1 monkeys exposed to TCDD. In this study, we examined effects of TCDD exposure *in utero* and lactational periods on development of the reproductive organs in F1 rhesus monkeys.

### Materials and Methods

Adult rhesus monkeys were mated, and females with confirmation of pregnancy by

ultrasonography were given TCDD subcutaneously on day 20 of gestation at an initial

dose level of 30 ng/kg or 300 ng/kg group. The lower dose level was set at about one third of the LOAEL body burden in rodents, and the higher one at about three times of the LOAEL. For maintenance of a certain body burden, 5% of the initial dose was given to dams every 30 days during pregnancy and lactation until 90 days after delivery. Twelve control F1 monkeys, 11 F1 monkeys of 30 ng/kg group, and 8 F1 monkeys of 300 ng/kg group were studied concerning developmental abnormality in the reproductive organs based on body weights, anogenital distance, testicular descent, and size of testis and penis. CA125 concentrations in peripheral blood in F0 female monkeys were assayed using EIA kit to evaluate the status of endometriosis.

### Results and Discussion

Menses was observed in 5 out of 8 control female monkeys, 3 out of 5 female monkeys of 30ng/kg TCDD group and 3 out of 3 female monkeys of 300ng/kg TCDD group. Body weights and anogenital distance were measured, and the data are summarized in Table 1. There were no significant differences among control group, 30ng/kg TCDD group, and 300ng/kg TCDD group. As TCDD is known to cause endometriosis, serum CA125 concentrations in female monkeys were measured. The mean levels of CA 125 in control group, 30ng/kg group and 300ng/kg group were 17.3±12.3 U/ml (n=12), 12.3±2.8 U/ml (n=13) and 15.5±9.5 U/ml (n=14), respectively. There was no significant

## TOX - Impact of Dioxin-like Chemicals on Reproduction and Development

difference among three groups.

As shown in Table 2, testicular descent was observed in 3 out of 4 male controls, 4 out of 6 male monkeys of 30ng/kg TCDD group, and 4 out of 5 male monkeys of 300ng/kg TCDD group. The size of testis and penis is summarized in Table 2. At this point there was no significant differences among controls, 30ng/kg TCDD group, and 300ng/kg TCDD group. Considering the size of testis and penis we speculated that it was difficult to evaluate the function of sperm in terms of the number and motility of the sperm. We continue to observe F1 monkeys and will evaluate the number and motility of the sperm in a year or two years.

### Acknowledgements

This study was supported by Health Labour Sciences Research Grants for Research on Food and Chemical Safety from the Ministry of Health Labour and Welfare of Japan.

### References

1. Colborn, T., vom Saal, F.S. and Soto, A.M. (1993) Environ. Health. Perspect. 101: 378-384.
2. Birnbaum, L.S. (1994) Environ. Health. Perspect. 102:157-167.
3. Gray L.E., Jr., Wolf C., Mann P. and Ostby J.S. (1997) Toxicol. Appl. Pharmacol. 146: 237-244.
4. Gray L.E., Jr., Ostby J.S. and Kelce W.R. (1997) Toxicol. Appl. Pharmacol. 146: 11-20.
5. Faqi A.S., Dalsenter P.R., Merker H.J. and Chahoud I. (1998) Toxicol. Appl. Pharmacol. 150: 383-392.
6. Sweeney, M.H. and Mocarelli, P. (2000) Food Addit. Contam. 17:303-316.
7. Signorini, S., Gerthoux, P.M., Dassi, C., Cazzaniga, M., Brambilla, P., Vincoli, N. and Mocarelli, P. (2000) Andrologia 32:263-270.
8. Ohta, M., Akema, S., Tsuzuki, M., Korenaga, T., Fukusato, T., Asaoka, T., Murata, N., Nomizu, M., Arima, A., and Kubota, S.(2004) Organohalogen Compounds 66:3299-3304.
9. Korenaga, T., Kubota, S., Ohta, M., Asaoka, K., Murata, N., Nomizu, M., Arima, A., and Fukusato, T. (2004) Organohalogen Compounds 66:3315-3320.
10. Yasuda, I., Yasuda, M., Sumida, H., Tsusaki, H., Arima, A., Ihara, T., Kubota, S., Asaoka, K., Tsuga, K., and Akagawa, Y. (2005) Reproductive Toxicology 20:21-30.

Table 1 Effects of TCDD *in utero* on body weight, menses and anogenital distance of

Female monkey offspring

Control group

Animal number	Body weights (kg)	Anogenital distance (mm) From anus To clitoris To vaginal orifice	Menses	Days after birth On January 12, 2005



TOX - Impact of Dioxin-like Chemicals on Reproduction and Development

1	4.1	42.4	19.9	+	1709
2	3.8	39.0	16.5	-	1700
6	4.4	40.8	17.7	+	1684
7	3.8	42.0	20.7	+	1711
11	3.9	42.2	19.5	-	1697
12	3.4	38.7	19.2	+	1687
46	2.6	29.9	15.5	-	1677
63	4.1	37.8	22.7	+	1651

30ng/kg TCDD group

Animal number	Body weights (kg)	Anogenital distance (mm)		Menses	Days after birth On January 12, 2005
		From anus			
		To clitoris	To vaginal orifice		
18	3.2	32.3	17.6	-	1692
21	4.2	33.2	17.9	+	1696
30	3.9	35.6	22.7	+	1680
59	4.0	38.6	27.2	+	1669
65	3.9	43.2	25.0	-	1612

300ng/kg TCDD group

Animal number	Body weights (kg)	Anogenital distance (mm)		Menses	Days after birth On January 12, 2005
		From anus			
		To clitoris	To vaginal orifice		
31	3.9	30.6	17.6	+	1701
35	4.1	35.3	17.3	+	1696
42	4.0	37.4	19.8	+	1686

Table 2 Effects of TCDD *in utero* on body weight, testicular descent and size of testis and penis of male monkey offspring

Control group

Animal number	BW (kg)	Size of testis and penis (mm)			Testicular descent	Days after birth On January 12, 2005
		Testis(rt)	Testis(lt)	Penis		
4	3.5	8.8x13.9	7.4x12.1	24.4	-	1695
13	5.2	18.4x30.5	19.5x30.6	34.5	+	1697
62	3.8	12.3x20.2	11.4x20.6	25.6	+	1651
64	4.9	18.8x25.8	18.1x27.8	31.0	+	1655

30ng/kg TCDD group

Animal number	BW (kg)	Size of testis and penis (mm)			Testicular descent	Days after birth On January 12, 2005
		Testis(rt)	Testis(lt)	Penis		
19	4.1	12.5x19.9	13.7x23.6	29.3	+	1705

TOX - Impact of Dioxin-like Chemicals on Reproduction and Development

22	3.9	10.1x16.1	9.5x14.9	23.2	-	1688
25	4.8	20.3x31.0	18.4x27.4	34.0	+	1693
27	4.7	26.1x37.6	26.3x39.0	38.9	+	1670
47	4.1	16.8x27.0	14.7x23.1	36.4	+	1677
53	4.1	8.8x14.6	8.4x15.1	17.9	-	1669

300ng/kg TCDD group

Animal number	BW (kg)	Size of testis and penis (mm)			Testicular descent	Days after birth On January 12, 2005
		Testis(rt)	Testis(lt)	Penis		
33	3.9	9.3x17.5	10.3x20.9	17.8	+	1719
39	4.8	25.4x41.8	27.3x39.6	41.8	+	1681
44	4.4	21.1x40.8	22.5x35.0	31.3	+	1686
60	3.1	11.8x18.4	10.3x18.0	23.2	+	1661
66	3.6	9.0x16.7	8.9x17.6	29.6	-	1611

## Prenatal and lactational exposure to 2,3,7,8-tetrachlorodibenzo-p-dioxin (TCDD) impairs renal development in offspring of rhesus monkeys

Toshio Fukusato<sup>1</sup>, Tatsumi Korenaga<sup>1</sup>, Mari Ohta<sup>2</sup>, Kazuo Asaoka<sup>3</sup>, Hiroshi Sumida<sup>4</sup>, Mineo Yasuda<sup>4</sup>, Akihiro Arima<sup>5</sup>, Suzuko Toida<sup>6</sup>, Nobuo Murata<sup>6</sup>, Shunichiro Kubota<sup>2</sup>

<sup>1</sup>Teikyo University School Of Medicine

<sup>2</sup>Graduate school of Arts and Sciences, The University of Tokyo

<sup>3</sup>Primate Research Institute, Kyoto University

<sup>4</sup>Faculty of Health Sciences, Hiroshima International University

<sup>5</sup>Shin Nippon Biomedical Laboratories, Ltd.

<sup>6</sup>Teikyo University School of Medicine, Mizonokuchi Hospital

### Introduction

Exposure to 2,3,7,8-tetrachlorodibenzo-p-dioxin (TCDD) results in wide variety of effects including immunological dysfunction, teratogenicity and carcinogenesis<sup>1-4</sup>. In utero and lactational exposure to TCDD induces developmental abnormality in the brain and reproductive tissue of female offspring<sup>5, 6</sup>. Renal involvement by TCDD toxicity has been reported in rodents, horses, and cats<sup>7</sup>. Prenatal exposure to a high dose of TCDD is known to induce hydronephrosis in the mouse<sup>8</sup>. Considering the pronounced difference between species observed in some previous studies, effects of low dose of TCDD on development of the kidney in non-human primate were investigated in the present study after subcutaneous administration of TCDD into rhesus monkeys during pregnancy and lactation. The results showed a peculiar form of interstitial and peripelvic fibrosis with tubular and glomerular dysgenesis in the kidney of rhesus monkey offspring.

### Materials and Methods

TCDD was purchased from Wellington Laboratories Inc., Guelph, Ontario, Canada) and was dissolved in a mixture of toluene/dimethylsulfoxide (DMSO;1:2, v/v) at Kanto Kagaku Co., Ltd. (Tokyo, Japan). Final concentrations were confirmed by gas chromatography. Colony bred adult female rhesus monkeys (age, 3-10 years; weight, 4-7kg) were purchased from China National Scientific Instruments & Materials Import/Export Corporation (Beijing, China).

TCDD (0, 30, 300ng/kg of body weight) was subcutaneously administrated to pregnant female monkeys on gestation day 20 (GD20), followed by injection with 5% of the initial dose every 30 days during pregnancy and lactation until GD90. Offspring that died by postnatal day (PND) 1100 were necropsied and examined macroscopically and histopathologically. Electron microscopic observation was also done. Renal tissue specimens were examined with quantitative image analysis (Win Roof, Mitani Corporation, Fukui, Japan) for fibrosis after picosirius red stain. Immunohistochemical staining was performed on paraffin-embedded renal tissues using MAX-PO kitt (DakoCytomation, Glostrup, Denmark) and anti-vimentin (DakoCytomation), anti-alpha-smooth muscle actin (SMA) (DakoCytomation), anti-lymphocyte common antigen (LCA)(DakoCytomation) antibodies.

### Results and Discussion

Numbers of dams in each group (0, 30, 300ng/kg) were 23, 20, and 20, respectively; live births, 18, 15, and 16; postnatal deaths, 6, 3, and 9. The cause of postnatal death included pneumonia in one monkey and renal failure in two. Renal interstitial and peripelvic fibrosis with or without atrophic papilla (Figure 1,2) was found in 5 (56%) of 9 offspring of dams exposed to relatively high dose of TCDD (300ng/kg), which were alive until PND1 to 465. The renal lesion was associated with renal tubular damage and function failure. Tubular and glomerular dysgenesis was also indicated. Electron microscopic observation showed interstitial collagen deposition and loss of renal tubuli. Quantitative image analysis disclosed significant increase in sirius-red positive areas within the renal cortex, medulla, and hilus. An immunohistochemical study revealed predominant proliferation of vimentin-positive fibroblasts, not SMA-positive myofibroblast, in these lesions. LCA-positive lymphocyte infiltration was minimal. No remarkable abnormalities were detected in the kidneys of 6 offspring of controls and 3 offspring of dams exposed to

relatively low dose (30ng/kg) of TCDD.

Although it has been reported that low doses of TCDD cause myocardial fibrosis in marmosets<sup>9</sup>, severe renal fibrosis found in offspring of rhesus monkey in the present study might not be directly induced by TCDD transferred from dams into offspring via placental blood or breast milk<sup>10</sup>. But it might be rather a secondary change which might follow abnormal renal differentiation including dysgenesis or loss of nephrons because it is known that TCDD induces hydronephrosis without severe fibrosis in offspring of mice and, in addition, both renal dysgenesis and hydronephrosis without severe fibrosis is evident in kidneys of transgenic mouse models with developmental anomaly<sup>11-13</sup>. This study is ongoing. We will be able to examine renal changes in still alive offspring in the near future.

In conclusions, this is the first report that describes a peculiar form of renal interstitial and peripelvic fibrosis with nephron dysgenesis developed in offspring of rhesus monkeys exposed during prenatal and lactational period to TCDD. The renal lesions developed exclusively in offspring of dams exposed to relatively high dose (300ng/kg) of TCDD.

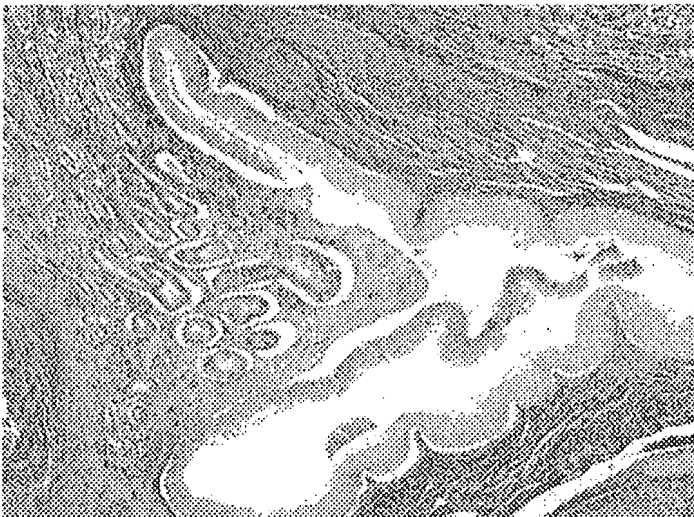

Figure 1. Interstitial and pericalyceal fibrosis with atrophic papilla in the kidney of rhesus monkey offspring.

