



FIGURE 1. Opening site of a waste pipe from a raccoon cote to a shallow drain in the macaque/bear area. The insert photograph at the upper right corner shows the opening of the waste pipe in the raccoon cote. Directions of water flow are indicated by arrows.

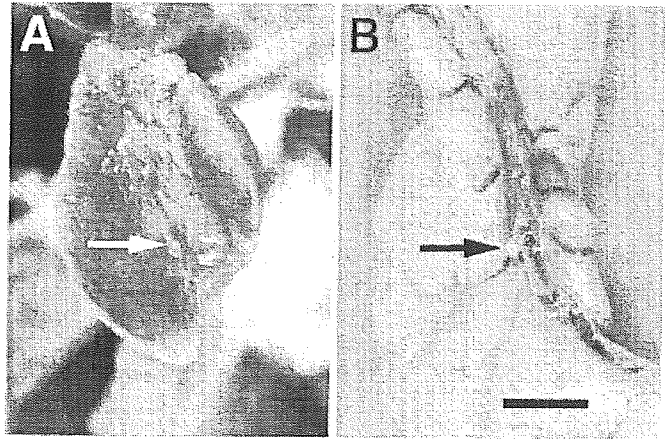


FIGURE 2. Military nodules found on the serosal surface of the accessory lobe of the lungs (A) and the ileum (B) from a macaque with ascarid larva migrans. Bar = 6 mm.

tological analyses found multifocal malacia with hemorrhages and gliosis in the cerebrum and 2 encapsulated ascarid larvae of approximately 60  $\mu\text{m}$  maximum width in the cerebrum and the lung. Histological sections and paraffin blocks of the cerebrum ( $n = 2$ ) and other tissues ( $n = 4$ ) of previous cases were provided by other laboratories. The additional cases also showed multifocal malacia in the cerebrum of 2 animals, but no parasites were detected in any tissues.

After histological detection of ascarid larvae in macaques showing neurological diseases, parasitological surveys were performed on raccoons and bears. Raccoons and bears were treated regularly (at least annually) with anthelmintic drugs. We found no evidence of infection in raccoons with *B. procyonis* at fecal examination, and caretakers of raccoons had never noticed expulsion of adult ascarids from any individuals after anthelmintic treatments in the past. Intensive examination of the soil from 13 points in the raccoon cote and the sewage drain could not detect any parasite eggs. As sentinel animals for detecting ascarid egg contamination of the cote, 2 young rabbits (*O. cuniculus*) were placed there for 1.5 mo from June 2001 to July 2001. These rabbits did not develop clinical symptoms, and no larvae were recovered from them by artificial tissue digestion of the whole muscles, viscera, and brains. On the contrary, all bears were constantly infected with *B. transfuga*, and several mature adults were recovered after every annual anthelmintic treatment. Soil examination of the macaque/bear enclosure from 8 sites, however, yielded few ascarid eggs (i.e., 2 *Baylisascaris* eggs from 150 g of soil from only 1 site). Then, formalin-preserved tissue samples were re-examined macroscopically. Three white military nodules were found on the serosal surface of the lungs and posterior ileum of 1 affected macaque (Fig. 2). Two encapsulated larvae were collected from the lungs (Fig. 3). However, no larvae were found in a military nodule on the serosal surface of the ileum, and the center of this nodule was calcified. An isolated larva showed morphology typical of *Baylisascaris* larvae and measured 1.38 mm long and 64  $\mu\text{m}$  wide, with a 0.21-mm-long esophagus. As described previously (Sato et al., 2004), the larvae of *B. procyonis* and *B. transfuga* resemble each other, and it is hard to distinguish the species based on morphological examination of the isolated parasite. The pathogenicity of *B. procyonis* and *B. transfuga* as LM was distinct for both mice and jirds (Sato et al., 2004). The LM caused by a limited number of *B. procyonis* larvae was fatal for both laboratory hosts because of neural invasion of the parasite, but induction of fatal *B. transfuga* LM occurred only after oral inoculation of the hosts with a substantial number of eggs (Papini and Casarosa, 1994; Papini et al., 1996; Sato et al., 2004). Based on findings such as severe histological lesions in the cerebrum (multifocal malacia with hemorrhages and gliosis) and few encapsulated larvae in the viscera of the affected macaques, it seems more likely that the causative ascarid of fatal LM in this macaque colony was *B. procyonis* rather than *B. transfuga*.

Multiple polymerase chain reaction (PCR)-based technologies have

been applied successfully for the identification of protozoan and helminthic species of medical and veterinary importance, including ascarids (Anderson et al., 1995; Nadler and Hudspeth, 1998, 2000; Loreille et al., 2001; Zhu et al., 2001). Both the PCR amplification and the sequencing of particular regions of ribosomal RNA gene (rDNA) or mitochondrial DNA (mtDNA) are of great advantage to phylogeneticists, taxonomists, and other researchers in identifying the organisms, because their amplification from minute or highly degraded DNA samples is relatively easy as a result of the multicopy nature of the genes (Kocher et al., 1989; McManus and Bowles, 1996). The species-identification strategy described above was adapted to our macaque cases that had neural and visceral LM caused by *Baylisascaris* sp. with a limited number of larvae in the tissues, as seen on histological slides or in formalin-preserved materials.

We attempted to amplify 28S rDNA and cytochrome *c* oxidase subunit I (COI) and subunit II (COII) mtDNA sequences of 2 larvae collected from formalin-fixed tissues of an affected macaque. Before this attempt, we collected basic information about these segments of various ascarid species as follows: *B. procyonis* from raccoons kept in a wildlife park where LM caused by this ascarid was found in rabbits in 2000 (Sato et al., 2002); *B. transfuga* from American black bears kept in the safari-style zoo described here, an Asiatic black bear (*U. thibetanus*) shot in Aomori Prefecture (Japan), and a polar bear (*U. martimus*) kept in a zoological garden (Sato et al., 2004); *Ascaris suum* from pigs in a

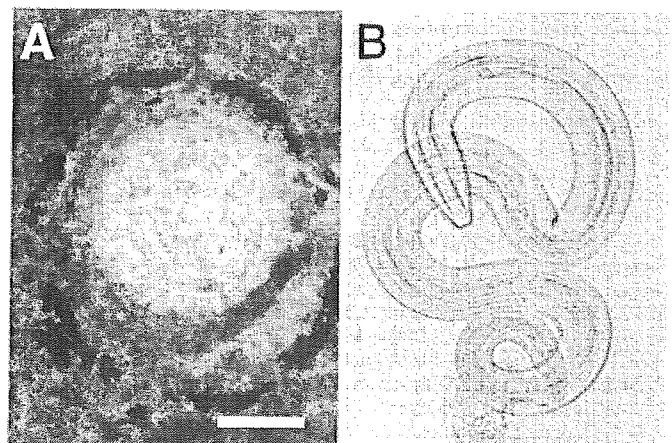


FIGURE 3. A pressed image of a pulmonary nodule (A) and an isolated larva (B) from an affected macaque. The larva has morphological features of *Baylisascaris*, but the species identification is difficult. Bar = 100  $\mu\text{m}$ .

TABLE I. Oligonucleotide primers used to amplify the 28S rDNA and cytochrome *c* oxidase subunit I (COI) and II (COII) mtDNA segments. The size of the polymerase chain reaction (PCR) product and the number of base differences between *Baylisascaris procyonis* and *B. transfuga* are indicated as well.

Primer name	Sequence	Size of PCR product (base pairs)	Number of base differences including in the PCR product*
28S rDNA			
Bp28S-F1	5'-GGGGCTATAGTCCAAAGAAGGTGCTA-3'	610 [F1-R1]	14
Bp28S-F2	5'-GCTGCATTCATCCGATCGG-3'	363 [F2-R1]	12
Bp28S-R1	5'-TCGGATAGGTGGTCAACGTTCCACA-3'		
COI mtDNA			
BpCoxI-F1	5'-TTTGGTCATCCTGAGGTTTATATT-3'	Unknown	Unknown
BpCoxI-R1	5'-ATGAAAATGTCTAACTACATAATAAGTATC-3'	Probably 423†	
COII mtDNA			
BpCoxII-F1	5'-ATTGTAGGCTTTTGTGGTGT-3'	528 [F1-R1]	33
BpCoxII-F2	5'-AGTCTTTGGATCAGTTGGAGTTGG-3'	302 [F2-R1]	12
BpCoxII-R1	5'-CACAAATCTCAGAACACTGACCATA-3'		

\* Based on reported sequences of 28S rDNA (U94753 and U94754) and COI mtDNA (AF179908 and AF179909) of *B. procyonis* and *B. transfuga*, respectively.

† Based on reported sequences of *Ascaris suum* (X54253), *Toxocara canis* (AF182297), and *T. cati* (AF181882).

local abattoir; *Toxascaris leonina* from cats kept in a veterinary school; *Toxocara canis* and *T. cati* from dogs and cats at a veterinary clinic; and *T. tanuki* from a raccoon dog shot in Aomori Prefecture. Larvae of *B. procyonis*, *B. transfuga* (polar bear origin), and *T. canis* were collected from Mongolian jirds (*Meriones unguiculatus*) inoculated orally with embryonated eggs as described previously (Sato et al., 2004).

Formalin-fixed adult ascarids were washed in running tap water overnight. Pieces of viscera and musculature were removed and minced on clean aluminum foil using a clean scalpel, put into 15-ml tubes, and washed several times with pure water. Frozen ascarids were cut into pieces with a clean scalpel. All parasite samples were collected in 1.5-ml Eppendorf tubes, and DNA was extracted with GenomicPrep<sup>®</sup> Cells and Tissue DNA Isolation Kit (Amersham Pharmacia Biotech, Piscataway, New Jersey) according to the instructions provided by the manufacturer. For formalin-fixed eggs and larvae, including 2 larvae collected from an affected macaque, intermittent ultrasonication at 60 C for 20 min was used to break their hard covers, cuticles, or egg shells according to the method described by Loreille et al. (2001). Because the parasite samples remained intact under a stereoscopic microscope even after 2 sonications, an additional sonication was performed after adding glass beads of 0.105–0.125 mm in diameter into the Eppendorf tubes containing the parasite samples. Amplification was performed in 50 µl of a solution containing 10 mM Tris-HCl (pH 8.3), 50 mM KCl, 1.5 mM MgCl<sub>2</sub>, each dNTP at 0.2 mM, each primer at 0.5 µM (Table I), parasite DNA, and 1.25 U of AmpliTaq Gold<sup>®</sup> polymerase (PE Applied Biosystems, Foster City, California). Each cycle of PCR consisted of denaturation for 45 sec at 94 C, hybridization for 1 min at 52 C (COI) or 55 C (COII and 28S rDNA), and extension for 45 sec at 72 C. This cycle was repeated 40 times, and another 40 cycles of the reaction were performed for larval materials. Amplified PCR products were analyzed by electrophoresis using 1.3% agarose gels and ultraviolet visualization after ethidium bromide staining. Amplicons of interest were semipurified with Montage<sup>®</sup> PCR Centrifugal Filter Devices (Millipore, Bedford, Massachusetts) and sequenced in both directions using the aforementioned primers on ABI PRISM<sup>®</sup> 377 (PE Applied Biosystems) by a commercial service (FASMAC, Atugi, Kanagawa, Japan). The DNA sequences were aligned using the CLUSTAL W multiple-alignment program (Thompson et al., 1994).

The pair of primers shown in Table I successfully amplified 610- and 363-base pair (bp) segments of 28S rDNA, a 423- or 420-bp segment of COI mtDNA, and 528- and 234-bp segments of COII mtDNA from all adult ascarids examined here by a single round (40 cycles) of PCR. A single round of PCR did not amplify a 610-bp segment of 28S rDNA and a 528-bp segment of COII for any larvae or eggs, but some amplification of a 363-bp segment of 28S rDNA, a 423- or 420-bp segment

of COI, and a 234-bp segment of COII for parts of these parasite materials was seen. Subsequent PCRs were conducted using 4 µl of the primary PCR products, and successful amplifications of the latter 3 DNA segments were obtained. Partial COI nucleotide sequences obtained here are available in the DDBJ/EMBL/GenBank databases (AB125694 through AB125700). As for the laboratory-prepared, formalin-fixed larvae, double sets of PCR were conducted to amplify the DNA of 2 larvae detected from formalin-preserved tissues of a macaque with ascarid LM (Fig. 3), and only a 420-bp segment of COI mtDNA was amplified successfully. However, the nucleotide sequence of the amplified COI segments of these 2 larvae were amplicons distinct from those of any ascarid parasites.

Initial attempts to amplify 5 sizes (234–610 bp) of segments of 28S rDNA or of COI and COII mtDNA by a single round (40 cycles) of PCR using adult ascarids were absolutely successful, whereas only smaller sizes (234–423 bp) of segments were amplified by 2 rounds (40 cycles in each round) of PCR involving formalin-preserved ascarid larvae or viable eggs. A major cause of this difference could be the original amount of DNA template in each reaction tube for ascarid adults or nonadults. Different processing of ascarid adults and larvae or eggs might elucidate the difference between them regarding segment sizes of amplicons; to extract the DNA from the hardy, cuticle-surrounded larvae and shell-protected eggs, these materials were ultrasonicated 3 times at 60 C (three rounds of ultrasonication for 20 min each). Loreille et al. (2001) demonstrated that this method alone could successfully break the hard shell of ancient eggs of *Ascaris* sp. We could not break the coat of larvae and eggs by ultrasonication only, and we finally destroyed them by performing an additional ultrasonication with fine-glass beads added to the tube. Repeated and extended ultrasonication of the material might cause fragmentation of DNA. This extraction step should be modified to minimize DNA destruction; use of a high-speed mechanical shaker, which may assist the actions of glass beads to destroy the hard nematode cover, may be better than ultrasonication for this purpose.

In conclusion, the present study reports a second outbreak of *Baylisascaris* LM in animals in Japan following an outbreak of the disease in rabbits kept by a small wildlife park (Sato et al., 2000; Furuoka et al., 2003; Sato, Kamiya, and Furuoka, 2003). This outbreak was characterized by sporadic occurrences of macaques showing clinical and fatal neurological disorders in the colony kept by a safari-style zoo. The area potentially contaminated with *B. procyonis* eggs might have been very limited (i.e., around the opening of a sewage pipe from the raccoon cote and a shallow drain). Furthermore, visitors are forbidden to walk in this area, and they must pass the area by car. The approximately 30 animal caretakers and veterinarians working in this zoo were tested

hematologically and serologically with an enzyme-linked immunosorbent assay using the excretory/secretory antigens of *B. procyonis* larvae, which was prepared following the method described by Boyce et al. (1988). None of the workers exhibited positive serological reactions to *B. procyonis* or *T. canis* antigens.

We are grateful to Yoshihiko Saito, Sayuri Murakami, Kazuaki Koide, Yukiko Koide, Noriko Kawai, and Naoko Nakamura for their cooperation and for providing ascarid adults. The present work was supported in part by Grants-in-Aid (13460137 and 15390134) from the Japan Society for the Promotion of Science.

#### LITERATURE CITED

- ANDERSON, T. J. C., M. E. ROMERO-ABAL, AND J. JAENIKE. 1995. Mitochondrial DNA and *Ascaris* microepidemiology: The composition of parasite populations from individual hosts, families, and villages. *Parasitology* **110**: 221–229.
- ASAKAWA, M., T. KURACHI, AND THE WILDLIFE ECOLOGICAL SOCIETY. 1999. Parasitic helminths of raccoons in Hokkaido, Japan. *Japanese Journal of Zoo and Wildlife Medicine* **4**: 101–103.
- BOYCE, W. M., B. A. BRANSTETTER, AND K. R. KAZACOS. 1988. In vitro culture of *Baylisascaris procyonis* and initial analysis of larval excretory–secretory antigens. *Proceedings of the Helminthological Society of Washington* **55**: 15–18.
- CONRATHS, F. J., C. BAUER, J. CSEKE, AND H. LAUBE. 1996. Arbeitssplatzbedingte Infektionen des Menschen mit dem Waschbärspulwurm *Baylisascaris procyonis*. *Arbeitsmedizin, Sozialmedizin und Umweltmedizin* **31**: 13–17. [In German with English summary.]
- FURUOKA, H., H. SATO, M. KUBO, S. OWAKI, Y. KOBAYASHI, T. MATSUI, AND H. KAMIYA. 2003. Neuropathological observation of rabbits (*Oryctolagus cuniculus*) affected with raccoon roundworm (*Baylisascaris procyonis*) larva migrans in Japan. *Journal of Veterinary Medical Science* **65**: 695–699.
- GAVIN, P. J., K. R. KAZACOS, T. Q. TAN, W. B. BRINKMAN, S. E. BYRD, A. T. DAVIS, M. B. METS, AND S. T. SHULMAN. 2002. Neural larva migrans caused by the raccoon roundworm *Baylisascaris procyonis*. *Pediatric Infectious Disease Journal* **21**: 971–975.
- GOLDBERG, M. A., K. R. KAZACOS, W. M. BOYCE, E. AI, AND B. KATZ. 1993. Diffuse unilateral subacute neuroretinitis: Morphometric, serologic, and epidemiologic support for *Baylisascaris* as a causative agent. *Ophthalmology* **100**: 1695–1701.
- KAZACOS, K. R. 1997. Visceral, ocular, and neural larva migrans. In *Pathology of infectious diseases*, Vol. II, D. H. Connor, F. W. Chandler, D. A. Schwartz, H. J. Manz, and E. E. Lack (eds.), Appleton and Lange, Stamford, Connecticut, p. 1459–1473.
- . 2001. *Baylisascaris procyonis* and related species. In *Parasitic diseases of wild mammals*, 2nd ed, W. M. Samuel, M. J. Pybus, and A. A. Kocan (eds.), Iowa State University Press, Ames, Iowa, p. 301–341.
- , L. A. RAYMOND, E. A. KAZACOS, AND W. A. VESTRE. 1985. The raccoon ascarid: A probable cause of human ocular larva migrans. *Ophthalmology* **92**: 1735–1744.
- , P. J. GAVIN, S. T. SHULMAN, T. Q. TAN, S. I. GERBER, W. A. KENNEDY, W. J. MURRAY, AND L. MASCOLA. 2002. Raccoon roundworm encephalitis: Chicago, Illinois, and Los Angeles, California, 2000. *MMWR* **50**: 1153–1155.
- KAWANAKA, M., K., SAKAMOTO, AND H. SUGIYAMA. 2001. Raccoon and raccoon roundworm (*Baylisascaris procyonis*) surveillance in Japan. *Rinsho-Kiseichugaku* **12**: 121–125. [In Japanese.]
- KOCHER, T. D., W. K. THOMAS, A. MEYER, S. V. EDWARDS, S. PÄÄBO, E. X. VILLABLANCA, AND A. C. WILSON. 1989. Dynamics of mitochondrial DNA evolution in animals: Amplification and sequencing with conserved primers. *Proceedings of the National Academy of Sciences of the United States of America* **86**: 6196–6200.
- KÜCHLE, M., H. L. J. KNORR, S. MEDENBLIK-FRYSCH, A. WEBER, AND C. BAUER. 1993. Diffuse unilateral subacute neuroretinitis syndrome in a German most likely caused by the raccoon roundworm, *Baylisascaris procyonis*. *Graefes Archive for Clinical and Experimental Ophthalmology* **231**: 48–51.
- LOREILLE, O., E. ROUMAT, O. VERNEAU, F. BOUCHET, AND C. HANNI. 2001. Ancient DNA from *Ascaris*: Extraction amplification and sequences from eggs collected in coprolites. *International Journal for Parasitology* **31**: 1101–1106.
- MCMANUS, D. P., AND J. BOWLES. 1996. Molecular genetic approaches to parasite identification: their value in diagnostic parasitology and systematics. *International Journal for Parasitology* **26**: 687–704.
- METS, M. B., A. G. NOBLE, S. BASTI, P. GAVIN, A. T. DAVIS, S. T. SHULMAN, AND K. R. KAZACOS. 2003. Eye findings of diffuse unilateral subacute neuroretinitis and multiple choroidal infiltrates associated with neural larva migrans due to *Baylisascaris procyonis*. *American Journal of Ophthalmology* **135**: 888–890.
- MIYASHITA, M. 1993. Prevalence of *Baylisascaris procyonis* in raccoons in Japan and experimental infections of the worm to laboratory animals. *Seikatsu-Eisei* **37**: 137–151. [In Japanese with English summary.]
- NADLER, S. A., AND D. S. S. HUDSPETH. 1998. Ribosomal DNA and phylogeny of the Ascaridoidea (Nematoda: Secernentea): Implications for morphological evolution and classification. *Molecular Phylogenetics and Evolution* **10**: 221–236.
- , AND ———. 2000. Phylogeny of the Ascaridoidea (Nematoda: Ascaridida) based on three genes and morphology: Hypotheses of structural and sequence evolution. *Journal of Parasitology* **86**: 380–393.
- PAPINI, R., AND L. CASAROSA. 1994. A report on the pathology of *Baylisascaris transfuga* (Ascarididae: Nematoda) for mice. *Revue de Médecine Vétérinaire* **145**: 949–952.
- , S. DEMI, AND G. D. CRÖCE. 1996. Observations on the migratory behavior of *Baylisascaris transfuga* larvae in rabbits. *Revue de Médecine Vétérinaire* **147**: 893–896.
- ROWLEY, H. A., R. M. UHT, K. R. KAZACOS, J. SAKANARI, W. V. WHEATON, A. J. BARKOVICH, AND A. W. BOLLEN. 2000. Radiologic–pathologic findings in raccoon roundworm (*Baylisascaris procyonis*) encephalitis. *American Journal of Neuroradiology* **21**: 415–420.
- SATO, H., H. FURUOKA, AND H. KAMIYA. 2002. First outbreak of *Baylisascaris procyonis* larva migrans in rabbits in Japan. *Parasitology International* **51**: 105–108.
- , H. KAMIYA, AND H. FURUOKA. 2003. Epidemiological aspects of the first outbreak of *Baylisascaris procyonis* larva migrans in rabbits in Japan. *Journal of Veterinary Medical Science* **65**: 453–457.
- , K. MATSUI, H. KAMIYA, T. ISHIKAWA, S. OKABAYASHI, N. KISHI, AND Y. UNE. 2003. *Pterygodermatites nycticebi* (Nematoda: Ric-tulariidae): Accidental detection of encapsulated third-stage larvae in the tissue of a white-fronted marmoset. *Journal of Parasitology* **89**: 1163–1166.
- , ———, A. OSANAI, H. KAMIYA, N. AKAO, S. OWAKI, AND H. FURUOKA. 2004. Larva migrans by *Baylisascaris transfuga*: Fatal neurological diseases in Mongolian jirds, but not in mice. *Journal of Parasitology* **90**: 774–781.
- THOMPSON, J. D., D. G. HIGGINS, AND T. J. GIBSON. 1994. CLUSTRAL W: Improving the sensitivity of progressive multiple-sequence alignment through sequence weighting, positions-specific gap penalties, and weight matrix choice. *Nucleic Acids Research* **22**: 4673–4680.
- ZHU, X. Q., R. B. GASSER, N. B. CHILTON, AND D. E. JACOBS. 2001. Molecular approaches for studying ascaridoid nematodes with zoonotic potential, with an emphasis on *Taxocara* species. *Journal of Helminthology* **75**: 101–108.



## *Toxocara canis*: Search for a potential drug amongst $\beta$ -carboline alkaloids—in vitro and mouse studies

Tadaaki Satou <sup>a,\*</sup>, Akiko Horiuchi <sup>a</sup>, Nobuaki Akao <sup>b</sup>, Kazuo Koike <sup>a</sup>,  
Koichiro Fujita <sup>b</sup>, Tamotsu Nikaido <sup>a</sup>

<sup>a</sup> Department of Pharmacognosy, Faculty of Pharmaceutical Sciences, Toho University, 2-2-1 Miyama, Funabashi, Chiba 274-8510, Japan

<sup>b</sup> Section of Environmental Parasitology, Division of Public Health, Graduate School of Tokyo Medical and Dental University, 1-5-45 Yushima Bunkyo-ku, Tokyo 113-8519, Japan

Received 7 October 2004; received in revised form 7 February 2005; accepted 11 February 2005

Available online 19 March 2005

### Abstract

The goal of this study was to search for new treatments for *Toxocara canis* using both in vitro and in vivo experiments. We specifically looked for a treatment for *T. canis* larva migrans, and examined  $\beta$ -carboline alkaloids (17 compounds) with various structural modifications, both in in vitro and in vivo experiments. In the in vitro experiments, screening for nematocidal activity on the *T. canis* second stage larvae, cytotoxic activity, and immune activity in the host were undertaken. Compound 17 was selected, as it exhibited nematocidal activity for *T. canis* larvae and did not have any cytotoxic or immunosuppressive activity in the host. The effectiveness of compound 17 was then examined using *T. canis* larvae infected mice in in vivo experiments. To evaluate the anthelmintic effect, the relative mobility value for the larvae was examined in addition to the number of larvae in the brain, skeletal muscle, and liver. Compound 17 was also examined in both free and liposome-entrapped (LE) forms. Polyethylene glycol (PEG)-LE compound 17 showed an anthelmintic effect in which the number of larvae in the brain was decreased compared free albendazole. PEG-LE compound 17 also effectively suppressed the mobility of the larva in brain and skeletal muscle. The experimental procedure employed assisted in the discovery of this potential candidate and is a promising approach for finding alternative therapeutic regimens for *T. canis* larva migrans.

© 2005 Elsevier Inc. All rights reserved.

**Keywords:**  $\beta$ -Carboline; *Toxocara canis*; Liposome; Chemotherapy

### 1. Introduction

An effective drug that can be used to treat the human infections caused by *Toxocara canis* is still needed. The aim of our previous research was to search for new drugs in vitro that could be used for treatment of *T. canis* larva migrans infection (Satou et al., 2002, 2003). Using the method developed by one of us (Koike,

2003), we isolated and synthesized 17 different  $\beta$ -carboline alkaloids from *Picrasma quassioides* and *Ailanthus altissima* (Simaroubaceae).

In this study, we examined  $\beta$ -carboline alkaloids both in in vitro (nematocidal, cytotoxic, and immune activities) and in vivo experiments. The in vitro evaluation of potential efficacy considered the effects on both the parasite and the host while the in vivo experiment was based on the concept that effects on both the parasite and host need to be considered. In the in vivo experiment, to increase the absorption of potentially poorly bioavailable compounds, liposome-entrapped (LE)

\* Corresponding author. Fax: +81 47 472 1404.

E-mail address: [satou@phar.toho-u.ac.jp](mailto:satou@phar.toho-u.ac.jp) (T. Satou).

forms were prepared and their effects were compared with those of the free drug. Liposomes are recognized as foreign bodies and are broken down after incorporation into the mononuclear phagocytic system (MPS) by macrophages.

Although the absorption of albendazole by the tissues has been shown to increase after administration in liposomes (Wen et al., 1996). To bypass the MPS uptake, we added polyethylene glycol (PEG) to the liposome (Hreckova and Velebny, 2001; Velebny et al., 2000).

The mobility of the *T. canis* larvae was evaluated by using the scoring method developed by Kiuchi et al. (1987). For the in vivo experiment, we modified this method to obtain an improved score.

## 2. Materials and methods

### 2.1. Test compounds

The compounds shown in Fig. 1 were isolated from *P. quassioides* and *A. altissima* (Simaroubaceae) and synthesized as described by Koike (2003). These compounds were mostly side-chain substituted  $\beta$ -carboline alkaloids, with compound 7 being a dimer, and compound 14 and compound 15 having halogenated substituents.

### 2.2. Preparation of *T. canis* larvae

*Toxocara canis* adult worms were collected from naturally infected puppies by using an anthelmintic

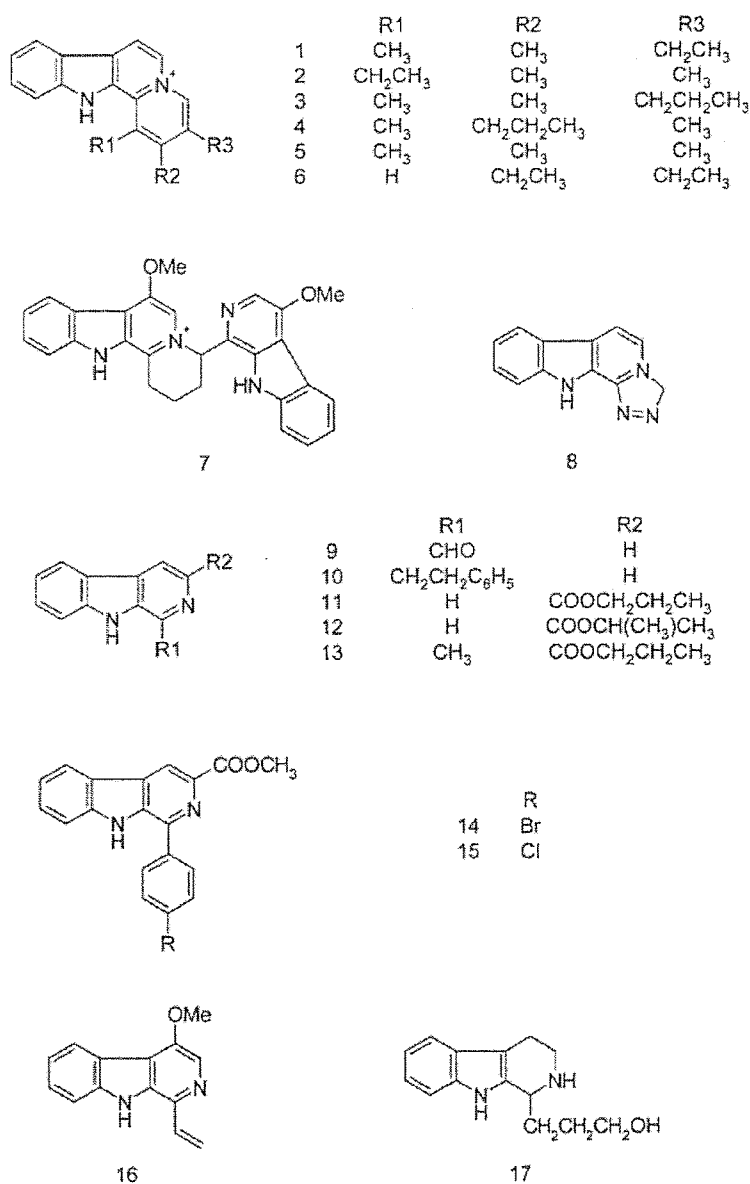


Fig. 1. The structures of 17 kinds of  $\beta$ -carboline alkaloids isolated from *P. quassioides* or *A. altissima* or synthesized.

(milbemycin A, Sankyo). Eggs removed from the uterus were developed into the larva-containing eggs after culturing for 1 month at 28 °C. By using a 50% sodium hypochlorite solution (antiformin, Wako), the protein cover of the eggs was dissolved (Oshima, 1961), and the hatched *T. canis* larvae were collected. These second stage larvae can be kept alive for about 2 years when maintained at 37 °C in an Eagle MEM1 medium (Nissui) at pH 7.0 (Kiuchi et al., 1987).

### 2.3. Nematocidal activity test

A microplate was used to initially culture the *T. canis* second stage larvae for 2 h (50 larvae/well) in Eagle MEM1 medium. The larvae were then maintained at 37 °C for 72 h with 0.01 or 0.1 mg/ml of the test substances.

Larval mobility after exposure to the test compound was evaluated by a scoring system originally developed by Kiuchi et al. (1987).

The activity was evaluated in vitro, and the scoring methodology is shown in Table 1.

### 2.4. Cytotoxic activity tests

The mouse macrophage cell line J774.1 and human acute myeloid leukemia cell line HL-60 culture cells were used (Riken Bioresource Center, Cell Bank, Japan). Cells were cultured in RPMI1640 medium (Gibco) supplemented with 10% fetal bovine serum (FBS, Sankou Junyaku), 100 U/ml crystal potassium penicillin G (Meiji), and 100 µg/ml streptomycin sulfate (Meiji). The test compounds (Fig. 1) were administered at 0.01 or 0.1 mg/ml. The cultured J774.1 cell line ( $1 \times 10^6$  cells/ml) was used to measure the survival rate after 48 h (preincubation for 2 h). The cultured cell line HL-60 ( $3 \times 10^4$  cells/ml) was used to measure the proliferation ratio after 72 h (preincubation for about 24 h). The measurement of the cytotoxic activity was carried out using a modified 3-(4,5-dimethylthiazol-2-yl)-2,5-diphenyl-tetrazolium bromide (MTT, Sigma) reduction assay (Sargent and Taylor, 1989). Briefly, after termination of the cell culture, 10 µl of 5 mg/ml MTT in PBS was added to each well and the plate was incubated in 5% CO<sub>2</sub>/air for 4 h at 37 °C. The plate

was read on a microplate reader at 550 nm. Cytotoxicity was determined by averaging results from three assays. These activities were evaluated against control (culture without test substances) survival rates.

### 2.5. Immune activity test

Compound effects on the immune system was evaluated by analyzing the nitric oxide (NO) generation rate in J774.1 cells. The NO generation rate was estimated by measuring NO<sub>2</sub><sup>-</sup> generation, which almost increases in parallel. NO<sub>2</sub><sup>-</sup> generation was measured using a method previously described (Cunha et al., 1993). Briefly, J774.1 cells were washed and resuspended in the cultured medium (200 µl at  $1 \times 10^6$  cells/ml), and placed in each well of a 96-well flat-bottomed plate. They were incubated in 5% CO<sub>2</sub>/air for 2 h at 37 °C. After incubation, the medium was replaced by a medium containing 10 ng/ml lipopolysaccharide (LPS, Sigma, Japan) and recombinant murine interferon-gamma (IFN-γ, Funakoshi). Samples were then added to the wells. Absorbance at 550 nm was measured after 48 h incubation using isovolume Griess reagent [1% sulfanilamide (Sigma) and 0.1% *N*-(1-naphthyl) ethylenediamine dihydrochloride (Sigma) in 2.5% phosphoric acid (Wako)], and compared to that of the control (culture without test substances). The average absorbance from three assays was used to determine the NO<sub>2</sub><sup>-</sup> generation rate.

### 2.6. *Toxocara canis* infected mice

For the experiments, we used 5-week-old male BALB/c mice (Nippon Bio-Supp. Center) that weighed 20–22 g. All mice were given a standard commercial diet with free access to water and maintained on a cycle of 14 h light to 10 h dark at a room temperature of 23 °C.

Mice were anesthetized with diethyl ether (Wako Chemical, Japan) and orally infected with 300 containing invasive larva using a glass probe coated with silicon. Four mice were used in each experimental group. The laboratory animals were handled according to the animal Ethics regulations of Tokyo Medical and Dental University.

Based on the paper by Hrcakova and Velebny (2001), the drug was administered during the 28th through the 36th day of infection, and autopsies were performed on the 50th day.

### 2.7. Preparation of samples for intraperitoneal dosing

Free compounds and PEG-LE compounds were administered into the peritoneal cavity of the mice.

The reagents used for liposomepreparation were 3-*sn*-phosphatidylcholine [from hydrogenated egg yolk, lecithin (Wako Chemical, Japan)], polyethylene glycol-cholesterol [MW: 5000, PEG-Chol, (NOF, Japan)]. And

Table 1

Criteria for evaluating the effect of drugs on larvae

State of larva	Score ( <i>n</i> )
Moving using the whole body	3
Moving with only a part of the body during the observation	2
Immobile but not dead	1
Dead	0

Mobility index (MI) =  $\sum n N_n / \sum N_n$ , where  $N_n$ : number of larvae with the score of  $n$ .

Relative mobility (RM) =  $MI_{\text{sample}} / MI_{\text{control}} \times 100$ .

albendazole (Sigma, Japan) was used as positive control. Each compound was prepared using the following proportions by weight, lecithin:PEG-Chol:sample = 10:13.6:25. After using organic solvent to dissolve these mixtures, a thin film was formed by evaporation of the solvent. Phosphate-buffered saline (PBS) was added to the thin film, followed by sonication using an ultrasonic cleaner. Prepared PEG-LE compounds were given two times/day intraperitoneally (50 mg/kg/day).

### 2.8. Design of necropsy studies

The brains of the mice were taken out, and interposed between two slides to count the larvae. The larvae in the liver and skeletal muscle were collected by using artificial digestive juice treatment [2.5 g pepsin (Wako Chemical, Japan), 3.5 ml hydrochloric acid (Wako Chemical, Japan), and 500 ml water] and by centrifugation (2500 rpm, 5 min).

The examination for larvae was done immediately after the necropsy, since there was the possibility as the mobility of the larvae might decrease and/or the larvae might die after some time.

### 2.9. Evaluation method for larva mobility in the in vivo experiment

Larval mobility after compound administration was evaluated by a scoring system developed by Kiuchi et al. (1987) and is generally used in in vitro experiments. We were able to modify and improve this scoring method so that it could also be used to evaluate the mobility of larvae in in vivo experiments as shown in Table 2.

### 2.10. Calculation of the proportion of eosinophilic leukocytes

The Hinkelman method was used to stain eosinophils (Hino, 1963). Ten microliters of blood was obtained from the tip of the mouse tail for evaluation of eosinophils and suspended in 100  $\mu$ l of Hinkelman solution [eosin yellow (Merck) 0.05 g, phenol (Wako) 0.5 ml, formalin (Wako) 0.5 ml, and purified water 100 ml]. The blood sample ( $n = 4$ ) was stained for 30 min. Using a

phase contrast microscope (CK-2, Olympus), the proportion of leukocytes (over 200) that were eosinophils was calculated by using a counting chamber.

## 3. Results

### 3.1. In vitro experiment

For the in vitro experiment, if a compound exhibited nematocidal activity and did not show cytotoxic or immunosuppressive activities, it was considered to be acceptable for further testing and development (Satou et al., 2002, 2003).

Albendazole (AZ), thiabendazole (TZ), and  $\beta$ -carboline alkaloids 1–17 were examined in nematocidal activity tests against *T. canis* second stage larvae. As shown in Fig. 2, there was nematocidal activity with relative mobility (RM) values under 80 for both AZ and TZ and for compounds 1 ( $1.0 \pm 1.3$ ), 2 ( $1.9 \pm 0.0$ ), 3 ( $25.5 \pm 6.8$ ), 4 ( $21.7 \pm 20.0$ ), 5 ( $24.4 \pm 2.5$ ), 6 ( $34.6 \pm 1.8$ ), 9 ( $4.5 \pm 3.9$ ), 10 ( $68.9 \pm 3.0$ ), 11 ( $2.8 \pm 3.9$ ), 12 ( $25.0 \pm 7.6$ ), 16 ( $13.4 \pm 1.6$ ), and 17 ( $13.3 \pm 1.0$ ). Highest nematocidal activity was seen for compounds 1, 2, 9, and 11.

Those compounds that had exhibited high nematocidal activity were chosen for further study, in a cytotoxic activity test performed in vitro.

The compounds 1–6, 9–12, 16, and 17 at concentrations of 0.1 mg/ml, were examined for the cytotoxic activity in the cultured cell J774.1 after activation by LPS and IFN- $\gamma$ . As shown in Fig. 3, only compound 17 ( $83.8 \pm 24.0$ ) did not exhibit cytotoxicity at the 0.1 mg/ml concentration.

As the cytotoxicity for compound 17 was low ( $83.8 \pm 24.0$ ) at concentrations where anti-nematode activity for *T. canis* second stage larvae was high, an additional series of experiments designed were per-

Table 2  
Evaluation method for larva mobility in the in vivo experiment

State of larva	Score ( $n$ )
Moving using the whole body	3
Moving with only a part of the body during the observation, or immobile but not dead	1.5
Dead	0

Mobility index (MI) =  $\sum nNn / \sum Nn$ , where  $Nn$  number of larvae with the score of  $n$ .

Relative mobility (MI) =  $MI_{\text{sample}} / MI_{\text{control}} \times 100$ .

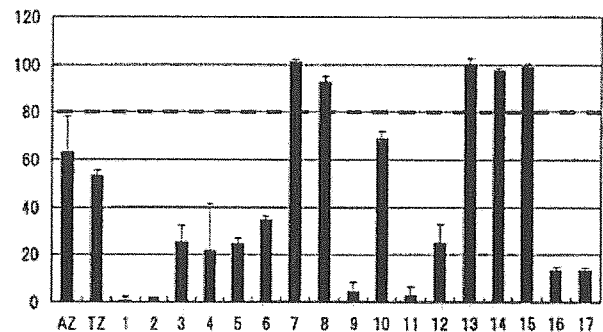


Fig. 2. Anti-nematode activity against *T. canis* second stage larvae for each compound was examined at concentrations of 0.1 mg/ml (the average of the relative mobility (RM) value  $\pm$  SD from four assays). The value of the control (the medium) was set at 100. AZ, albendazole; TZ, thiabendazole.



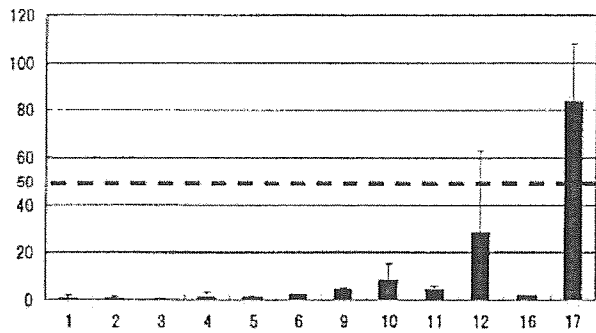


Fig. 3. The cytotoxic activity for cultured cell J774.1 for each compound at a concentration of 0.1 mg/ml (the average of the survival rate  $\pm$  SD from three assays). The value of the control (the medium) was set at 100.

Table 3

Immune activity for the cells for cultured cells J774.1 at a 0.1 mg/ml concentration of compound 17 (mean value  $\pm$  SD of NO<sub>2</sub><sup>-</sup> production rate) and cytotoxic activity for cultured cells HL-60 (mean value  $\pm$  SD of the cell proliferation rate)

	The mean value $\pm$ SD of NO <sub>2</sub> <sup>-</sup> production rate (%) (culture cells J774.1) (n = 4)	The mean value $\pm$ SD of the cell proliferation rate (%) (culture cells HL-60) (n = 4)
17	83.7 $\pm$ 1.2	44.9 $\pm$ 2.3

formed to further examine the properties of this compound.

First the effect of compound 17 in the cultured cell J774.1 was examined for activation of NO production. We then looked at compound 17's cytotoxic activity in HL-60 cell. As seen in Table 3, the NO production rate by the cultured J774.1 cell line was 83.7  $\pm$  1.2%, indicating that it was not effective. The cell proliferation rate in the cultured cell HL-60 was observed to remain at 44.9  $\pm$  2.3%.

### 3.2. In vivo experiment using infected mice

*Toxocara canis* eggs with encapsulated larvae were administered orally to BALB/c mice and the effectiveness of compound 17 after an intraperitoneal administration was examined. A high anthelmintic effect in *T. canis* larva infected mice has been reported when using a PEG-LE formulation of benzimidazole carbamates (albendazole, etc.) (Dvoroznakova et al., 1997; Hrcakova and Velebny, 2001; Velebny et al., 1997, 2000). Since the compounds work to the larvae more, the administration of both free and PEG-LE (liposome-entrapped) compound 17 were examined. In studies to confirm compound 17's effectiveness in toxocarasis, we found that it was effective in the in vitro experiment. However, the number of larvae seen in the brain and skeletal muscle during the administration of free compound 17 was not altered and was similar to control (Fig. 4). When

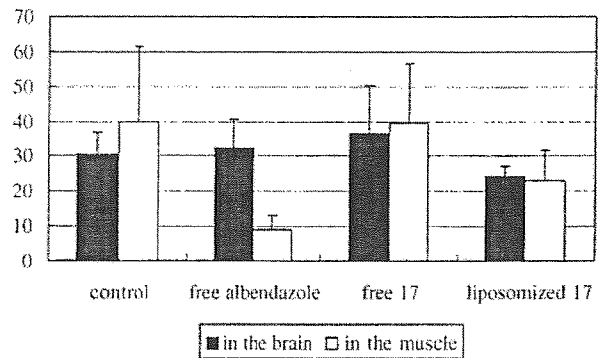


Fig. 4. Average larvae's numbers  $\pm$  SD for the *T. canis* second stage larvae infected mouse in the brain (■) and the skeletal muscle (□) after an intracelical injection of 50 mg/kg/day for each of the compounds. The vertical bars indicate the infectious larvae's number (n = 4).

compound 17 was formulated in liposomes, number in both the brain (24.3  $\pm$  3.0) and the skeletal muscle (23.3  $\pm$  8.4) decreased as compared to control.

A mobility score was used to evaluate the mobility of the larva in the brain and skeletal muscle, after measurement of the number of tissue larvae.

As seen in Fig. 5, brain mobility values for the free compound 17 (77.0  $\pm$  12.4) and liposomal compound 17 (72.2  $\pm$  5.7) were equivalent to that seen for free albendazole (72.2  $\pm$  5.7). In addition, liposomal compound 17 was equally effective in both the skeletal muscle (78.3  $\pm$  25.9) and the brain.

The time-dependent change in the proportion of circulating eosinophil was measured. This is an important index of parasitic infection, as there is no rise in the value with noninfection. From the start of the infection there was an increase of about 40% in the eosinophil number in all leukocyte counts, which lasted until around the 14th day, after which there was a decrease that was related to the administration of the drug. The proportion of eosinophils to total leukocytes on the 42nd day after the infection is shown in Fig. 6. There

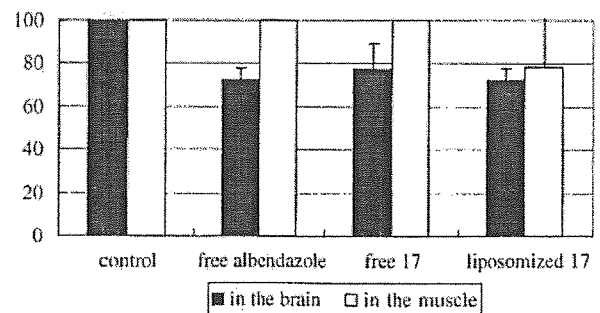


Fig. 5. Mean RM value of the larvae  $\pm$  SD for the *T. canis* second stage larvae infected mice isolated from the brain (■) and the skeletal muscle (□) after an intraperitoneal injection of 50 mg/kg/day of each compound. The vertical bars show the average RM value of the larvae (n = 4).



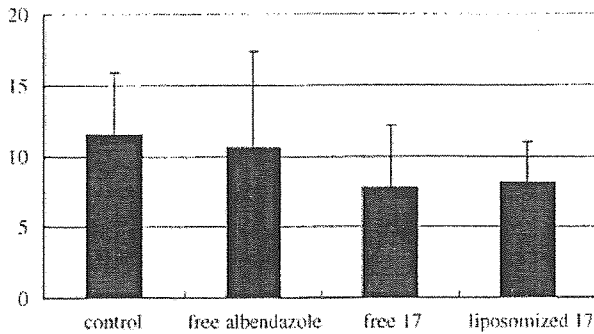


Fig. 6. The proportion of the eosinophils to the total leukocyte number in the infected mouse in the 42nd day from the infection after intracelical administration of 50 mg/kg/day of each chemical compound in the *T. canis* second stage larvae infected mouse. The vertical bar indicates the eosinophil proportion  $\pm$  SD ( $n = 4$ ).

was a decrease of the proportion of the number of eosinophils with both the free compound 17 ( $7.8 \pm 4.4$ ) and the liposomized compound 17 ( $8.1 \pm 29$ ) administrations. This was correlated with the decrease in the larvae number.

#### 4. Conclusions

The data suggest that of all of the  $\beta$ -carboline alkaloid compounds tested, compound 17 is the one with the greatest potential as a drug for the treatment of toxocariasis. However, compound 17 was not particularly effective in the in vivo experiment for larval numbers and mobility.

Based on consistent results ranging from the in vitro experiment (nematocidal activity test with *T. canis* second stage larvae, cytotoxic activity test with cultured J774.1 and HL-60, immune activity test with activated J774.1) to the in vivo experiment (antiparasitic experiment in the *T. canis* infected mouse), the data show there is a correlation between the in vitro and in vivo experiments.

#### References

- Cunha, F.Q., Assreuy, J., Xu, D., Charles, I., Liew, F.Y., Moncada, S., 1993. Repeated induction of nitric oxide synthase and leishmanicidal activity in murine macrophages. *European Journal of Immunology* 23, 1385–1388.
- Dvoroznakova, E., Boroskova, Z., Dubinsky, P., Velebny, S., Tomasovicova, O., Machnicka, B., 1997. Proliferative response of T and B lymphocytes of two mouse strains treated for experimental larval toxocarosis. *Helminthologia* 34, 121–126.
- Hino, S., 1963. History of Hinkelman's solution and problems in its use in acidophil counting. *Rinsho byori*. *Japanese Journal of Clinical Pathology* 11, 261–262.
- Hrekova, G., Velebny, S., 2001. Treatment of *Toxocara canis* infections in mice with liposome-incorporated benzimidazole carbamates and immunomodulator glucan. *Journal of Helminthology* 75, 141–146.
- Kiuchi, F., Miyashita, N., Tsuda, Y., Kondo, K., Yoshimura, H., 1987. Studies on crude drugs effective on visceral larva migrans. I. Identification of larvicidal principles in betel nuts. *Chemical and Pharmaceutical Bulletin* 35, 2880–2886.
- Koike, K., 2003. Study on the biologically active natural products of Simaroubaceous plants. *Natural Medicines* 57, 157–162.
- Oshima, T., 1961. Standardization of techniques for infecting mice with *Toxocara canis* and observation on the normal migration routes of the larvae. *Journal of Parasitology* 47, 652–656.
- Sargent, J.M., Taylor, C.G., 1989. Appraisal of the MTT assay as a rapid test of chemosensitivity in acute myeloid leukaemia. *British Journal of Cancer* 60, 206–210.
- Satou, T., Akao, N., Matsushashi, R., Koike, K., Fujita, K., Nikaido, T., 2002. Inhibitory effect of isoquinoline alkaloids on movement of second-stage larvae of *Toxocara canis*. *Biological and Pharmaceutical Bulletin* 25, 1651–1654.
- Satou, T., Akao, N., Koike, K., Watanabe, I., Fujita, K., Nikaido, T., 2003. A new method for identifying potential remedies for larva migrans using crude drug extracts (I), (II). *Natural Medicines* 57 (7–11), 23–26.
- Velebny, S., Tomasovicova, O., Hrekova, G., Dubinsky, P., 1997. *Toxocara canis* in mice: are liposomes and immunomodulator able to enhance the larvicidal effect of the anthelmintic? *Helminthologia* 34, 147–153.
- Velebny, S., Hrekova, G., Tomasovicova, O., 2000. *Toxocara canis* in mice: effect of stabilized liposomes on the larvicidal efficacy of fenbendazole and albendazole. *Helminthologia* 37, 195–198.
- Wen, H., New, R.R., Muhmut, M., Wang, J.H., Wang, Y.H., Zhang, J.H., Shao, Y.M., Craig, P.S., 1996. Pharmacology and efficacy of liposome-entrapped albendazole in experimental secondary alveolar echinococcosis and effect of co-administration with cimetidine. *Parasitology* 113, 111–121.

---

CLINICAL INVESTIGATION

---

## Following the Migration of a *Toxocara* Larva in the Retina by Optical Coherence Tomography and Fluorescein Angiography

Takashi Suzuki<sup>1</sup>, Takeshi Joko<sup>1</sup>, Nobuaki Akao<sup>2</sup>, and Yuichi Ohashi<sup>1</sup>

<sup>1</sup>Department of Ophthalmology, Ehime University School of Medicine, Ehime, Japan;

<sup>2</sup>Section of Environmental Parasitology, Graduate School of Tokyo Medical and Dental University, Tokyo, Japan

---

### Abstract

**Background:** The *Toxocara* larva is known to migrate across the retina, but the layer in which it migrates and its effect on the retina has been unknown.

**Case:** An ocular *Toxocara* infection was diagnosed by an immunological test on a vitreous sample from a patient with a retinal lesion that had migrated. Optical coherence tomography (OCT) and fluorescein angiography (FA) were used in this investigation.

**Observations:** Many small lesions were first detected in the peripheral retina, and vitrectomy was performed because of vitreous haze. Two peripapillary lesions were found during the vitrectomy. OCT of one lesion demonstrated a highly reflective mass located in the nerve fiber layer, and FA showed dye leakage from the lesion as well as hyperfluorescence of the disc. Three weeks later, another lesion was found in the macular area, and OCT and FA findings were the same as for the first lesions. Fluorescein leakage was also observed along the presumed path of the migrating larva.

**Conclusions:** The movement of the lesion from the peripapillary area to the macular area suggested that a *Toxocara* larva had migrated across the retina. OCT images indicated that the larva moved in the nerve fiber layer, and FA showed that it caused severe inflammation along its pathway. *Jpn J Ophthalmol* 2005;49:159-161 © Japanese Ophthalmological Society 2005

**Key Words:** fluorescein angiography, migration, ocular toxocariasis, optical coherence tomography, *Toxocara* larva

---

### Introduction

The *Toxocara* larva commonly migrates across the retina,<sup>1,2</sup> but in which retinal layer the larva migrates has not been clearly determined. We report a case of antibody-confirmed toxocariasis in which the migration was followed by optical coherence tomography (OCT) and fluorescein angiography (FA).

### Case Report

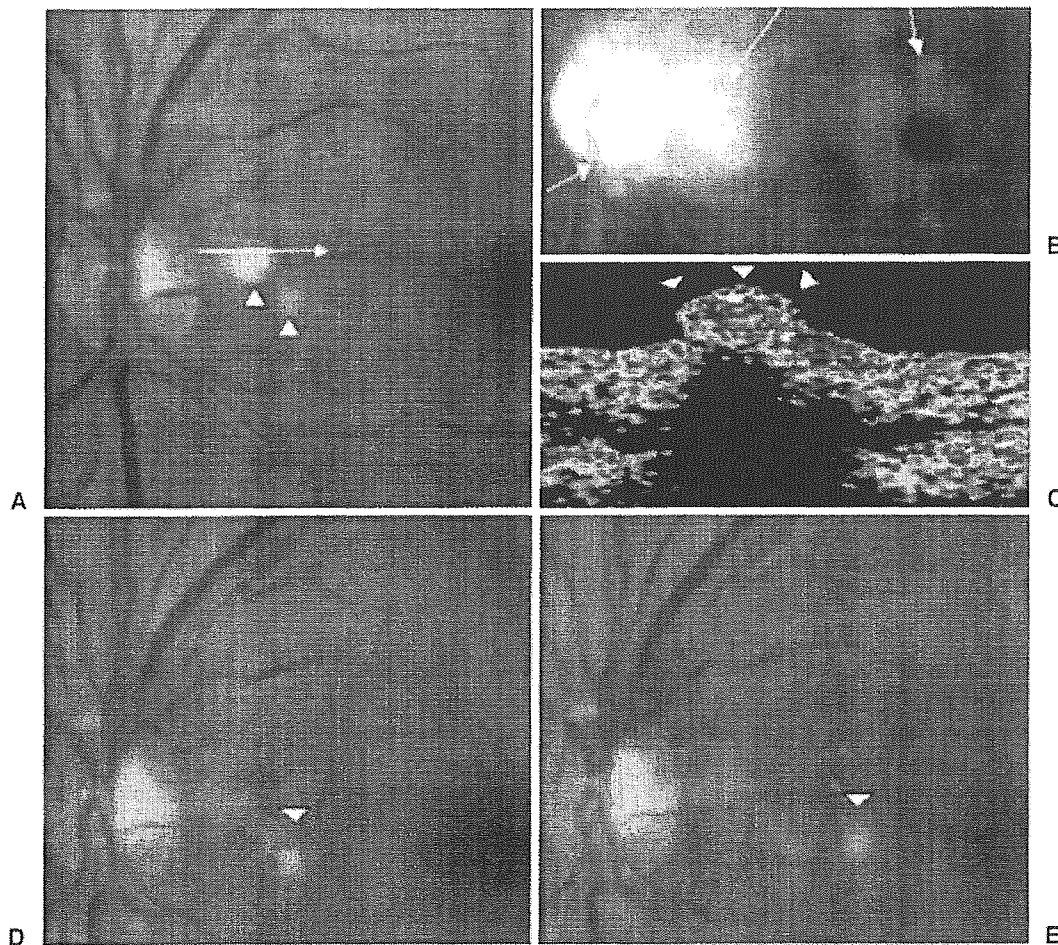
A 51-year-old man complained of blurred vision in the left eye. Ophthalmoscopy demonstrated lesions in the peripheral retina of the left eye, and the best-corrected visual acuity was 20/20 OS. Many white masses were present in the superior peripheral retina, with cells in the vitreous. Ocular toxocariasis with peripheral granuloma was suspected, and the patient was treated with oral prednisone (30 mg daily, tapered over 2 months) and diethylcarbamazine (100 mg/day for 3 days, 300 mg/day for 3 days, followed by 300 mg/week for 8 weeks).

The vitreal turbulence increased, and endophthalmitis developed. Vitrectomy was recommended, and informed consent was obtained. Pars plana vitrectomy was performed with cryocoagulation of the peripheral lesions. Intraopera-

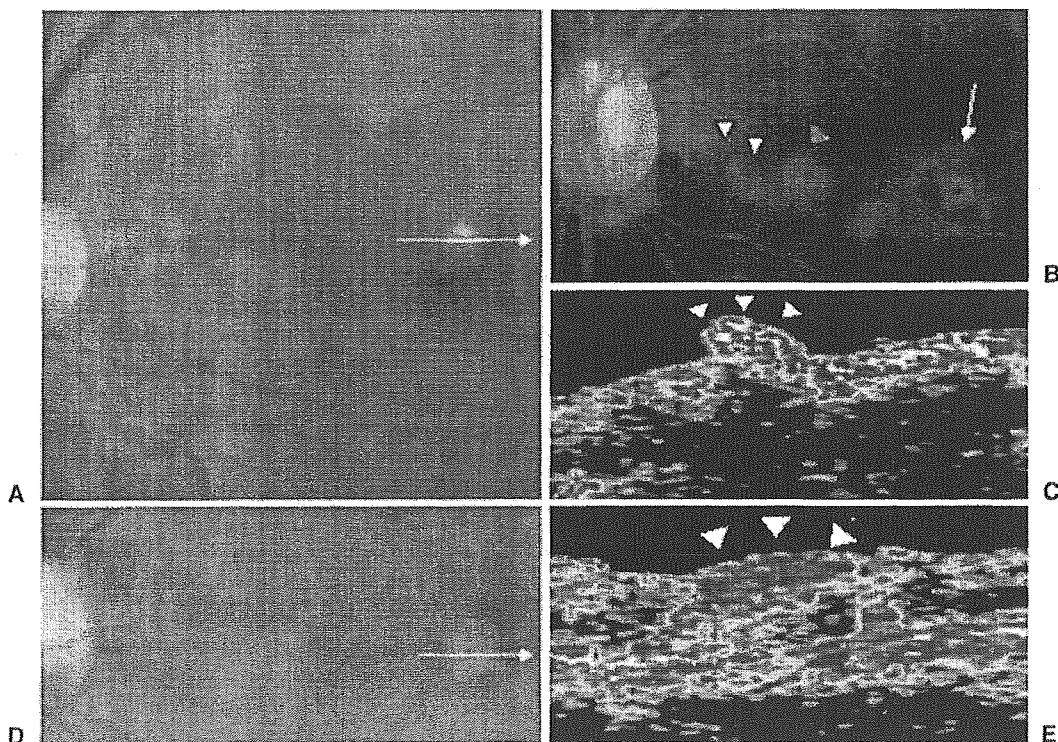
---

Received: July 20, 2004 / Accepted: October 27, 2004

Correspondence and reprint requests to: Takashi Suzuki, Department of Ophthalmology, Ehime University School of Medicine, Shit-sukawa, Shigenobu-cho, Onsen-gun, Ehime 791-0295, Japan  
e-mail: s-t-ishizuchi@orion.ocn.ne.jp



**Figure 1A-E.** Fundus photographs, fluorescein angiograms, and optical coherence tomography (OCT) images before and after the migration of a *Toxocara* larva. **A** Fundus photograph before migration showing two yellowish white lesions (*arrowheads*) with slight papillary hyperemia. The *arrow* points to the location and indicates the direction of the OCT scan. **B** Late-phase fluorescein angiogram showing dye leakage at the lesion, optic disc, and macula. The optic disc is hyperfluorescent (*arrows*). **C** OCT image of the nasal lesion. A hyperreflective mass can be seen protruding into the vitreous (*arrowheads*); the retina is thickened. **D** Fundus photograph 1 week after the migration: the nasal lesion has coalesced with the temporal lesion. **E** Fundus photograph 2 weeks after the migration: the lesion is now one disc diameter away from the optic disc.



**Figure 2A-E.** Fundus photographs, fluorescein angiograms, and OCT images after the migration. **A** Fundus photograph taken 3 weeks after the migration showing a yellowish white lesion in the upper foveal area of the macula. The direction of the OCT scan is shown by the *arrow*. **B** Late-phase fluorescein angiogram 3 weeks after the migration. There is dye leakage from the lesion, the macula (*arrow*) and along the track of migration (*white arrowheads*). Window defects are seen at the site of the photocoagulation (*green arrowhead*). **C** Three weeks after the migration, OCT shows a highly reflective protrusion on the retinal surface (*arrowheads*), with thickened retina. **D** Fundus photograph at 6 months after the migration. The scars of healed lesions can be seen at the fovea in the macular region. The direction of the OCT scan is shown by the *arrow*. **E** OCT image 6 months after the migration. A highly reflective mass (*arrowheads*) is seen in the retina.

tively, two yellowish white lesions were detected near the optic disc with slight papillary hyperemia (Fig. 1A).

Vitreous samples were collected, and an enzyme-linked immunosorbent assay showed a strong positive reaction to the larval antigen of *Toxocara canis*.

Postoperatively, the vitreous cleared, and OCT of one of the peripapillary lesions showed a highly reflective mass protruding from the thickened retina into the vitreous (Fig. 1C). FA demonstrated dye leakage from the mass and the macula, with a hyperfluorescent optic disc (Fig. 1B). This result indicated that the inflammation extended from the mass to the macula and to the optic disc.

The peripapillary lesions coalesced in a week and began spreading toward the macula (Fig. 1D). In 2 weeks, the lesion was one disc diameter from the optic disc (Fig. 1E). It was photocoagulated with an argon laser (Argon Green with 200mW of power; spot size, 50 $\mu$ m; and duration, 0.3 s), but, the lesion continued to migrate to the superior foveal area. It stopped moving at 3 weeks (Fig. 2A). The patient's visual acuity was 20/100, and OCT showed that the migrating larva remained in the same intraretinal layer (Fig. 2C). FA showed dye leakage from the lesion and along the trail of migration (Fig. 2B).

With time, the size of the lesion decreased, and the inflammation subsided at the optic disc. There was still dye leakage along the trail of the migration. Without further management, the lesion healed 6 months later (Fig. 2D), and the patient's visual acuity improved to 20/50. OCT showed hyperreflection at the site of the lesion with the disappearance of the protrusion, but the retina was still thickened (Fig. 2E).

### Comments

Migration of the *Toxocara* larva has been reported but without details on the intraretinal pathway.<sup>1,2</sup> In our patient, the OCT images obtained before and after the migration showed that the protruding lesions were highly reflective on the retinal surface, more specifically from the nerve fiber layer to the internal limiting membrane. FA showed dye leakage along the track of the migration and from the macular area, with a hyperfluorescent optic disc. Ophthal-

moscopy demonstrated that the lesions were probably in the nerve fiber layer. These findings indicate that the *Toxocara* larva most likely migrated in the nerve fiber layer and caused the inflammation to the optic disc and macula.

In a case of posterior pole *Toxocara* granuloma, Higashide et al.<sup>3</sup> demonstrated by OCT that the granuloma was located in the subretinal space and resembled choroidal neovascularization. In our patient, the OCT image did not show any granuloma, perhaps because the larva was migrating. Takayanagi et al.<sup>4</sup> found that in an experimental model, migrating *Toxocara* larvae did not cause any granuloma to form.<sup>4</sup> Perhaps the pathology of a lesion migrating in the retinal surface is quite different from that of a subretinal lesion; thus, the experimental model might correspond to our case.

The peripapillary lesion appeared concurrently with the development of apparent endophthalmitis. However, because of the vitreous haze, we were not able to observe the fundus in detail when the lesion migrated to the peripapillary area, and thus we could not determine whether the larva had migrated from the peripheral retina or from elsewhere. The endophthalmitis apparently developed while the larva migrated in the retina. This finding indicates that the migration of the *Toxocara* larva caused the inflammation of the retina.

In conclusion, our case showed that a *Toxocara* larva in the nerve fiber layer can migrate and cause severe inflammatory reactions in the optic disc and macula. The anthelmintic drug and steroids were ineffective in stopping the migration or in reducing the retinal and papillary inflammation.

### References

1. Sorr EM. Meandering ocular toxocariasis. *Retina* 1984;4:90-96.
2. Shields JA. Ocular toxocariasis. A review. *Surv Ophthalmol* 1984; 28:361-381.
3. Higashide T, Akao N, Shirao E, Shirao Y. Optical coherence tomographic and angiographic findings of a case with subretinal *Toxocara* granuloma. *Am J Ophthalmol* 2003;136:188-190.
4. Takayanagi TH, Akao N, Suzuki R, Tomoda M, Tsukidate S, Fujita K. New animal model for human ocular toxocariasis: ophthalmoscopic observation. *Br J Ophthalmol* 1999;83:967-972.

## 旋尾線虫幼虫 Type-X による creeping eruption の 1 例\*

川瀬 正昭\*<sup>1</sup>・赤尾 信明\*<sup>2</sup>・名和 行文\*<sup>3</sup>・影井 昇\*<sup>4</sup>  
渡辺 直熙\*<sup>5</sup>・新村 真人\*<sup>6</sup>

**要 約** 77 歳，女性。1999 年 6 月 25 日，左膝蓋に癢痒を伴う紅色小丘疹を生じた。同丘疹が左大腿へ蛇行しながら移動した後，再び左下腿へ下行し線状紅斑を形成した。7 月 6 日に当科を受診し生検を行ったが虫体をとらえられず，さらに左下腿から左膝蓋を経由して左足背に移動して同部に 5 日間停滞した。その先端の浸潤の触れる紅色丘疹を 7 月 25 日に生検した。患者は 1999 年 3 月に生ホタルイカを摂食していた。病理組織像で真皮浅層に虫体断面がみられ，その形態学的特徴により旋尾線虫幼虫 Type-X と同定した。旋尾線虫幼虫の切片を用いた蛍光抗体間接法で抗体は陰性であったが，食道腺質部に加え筋組織に対しても陽性が認められた他の患者血清を用いての酵素抗体法 (IgG) では陽性であった。また，ドロレス顎口虫抽出抗原を用いた microplate ELISA 法にて IgG 抗体の陽性所見を得た。

**キーワード** 旋尾線虫幼虫 Type-X, creeping eruption, ホタルイカ, ドロレス顎口虫

川瀬正昭，他：臨皮 59：490-493，2005

### はじめに

最近，顎口虫以外の旋尾線虫亜目の幼虫による creeping eruption の報告が多くみられ，大部分がホタルイカの生食によって発症している。

今回，われわれは生検にて虫体を検出して，旋尾線虫幼虫 Type-X による creeping eruption と診断した 1 例を経験し，感染部位，ホタルイカを食べてから発症までの期間および体内生存期間，

creeping eruption での抗原および抗体について考察したので報告する。



### 症 例

患 者：77 歳，女性

主 訴：左下肢の癢痒を伴う線状紅斑

既往歴：1954 年に虫垂切除，1980 年には子宮頸癌手術（輸血施行），その後放射線照射治療，

\* Creeping eruption caused by a larva of the nematode suborder *Spirurina* Type-X

\*<sup>1</sup> Masaaki KAWASE：国立大蔵病院皮膚科（主任：川瀬 正昭） Department of Dermatology, National Okura Hospital, Tokyo, Japan (Chief: Dr M KAWASE)

\*<sup>2</sup> Nobuaki AKAO：東京医科歯科大学大学院国際環境寄生虫病学分野（主任：藤田紘一郎教授） Section of Environmental Parasitology, Division of Public Health, Graduate School, Tokyo Medical and Dental University, Tokyo, Japan (Director: Prof K FUJITA)

\*<sup>3</sup> Yukifumi NAWA：宮崎医科大学寄生虫学教室（主任：名和 行文教授） Department of Parasitology, Miyazaki Medical College, Miyazaki, Japan (Director: Prof Y NAWA)

\*<sup>4</sup> Noboru KAGEI：国立感染症研究所寄生動物部（主任：遠藤 卓郎部長） Department of Parasitology, National Institute of Infectious Diseases, Tokyo, Japan (Chief: Dr T ENDO)

\*<sup>5</sup> Naohiro WATANABE：東京慈恵会医科大学熱帯医学講座（主任：渡辺 直熙教授） Department of Tropical Medicine, The Jikei University School of Medicine, Tokyo, Japan (Director: Prof N WATANABE)

\*<sup>6</sup> Michihito NIIMURA：東京慈恵会医科大学皮膚科学講座（主任：新村 真人教授） Department of Dermatology, The Jikei University School of Medicine, Tokyo, Japan (Director: Prof M NIIMURA)

〔連絡先〕川瀬 正昭：東京慈恵会医科大学皮膚科学講座 (☎ 105-8461 東京都港区西新橋 3-25-8)



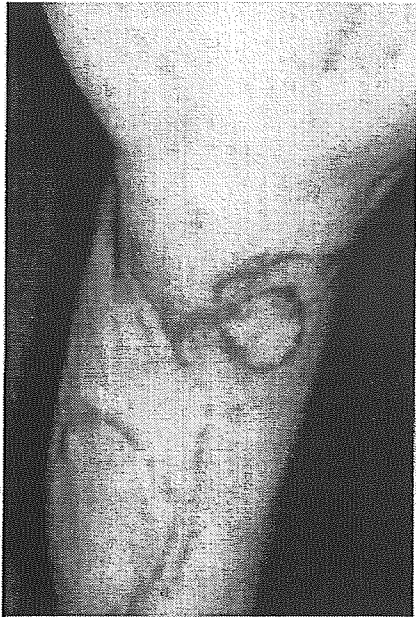

図1 臨床像  
左下肢の一部水疱を伴う線状紅斑

1981年に慢性C型肝炎, 1999年5月にNIDDM, 血糖コントロールのため1999年5月31日~6月28日まで内科に入院

家族歴: 特になし.

現病歴: 1999年6月25日に左膝蓋に癢痒を伴う紅斑小丘疹を生じた. 同丘疹が左大腿へ蛇行しながら移動した(1日約5cmずつ)後, 再び左下腿へ下行し線状紅斑を形成した. 7月6日に当科を受診し, 先端部の生検を行ったが虫体をとられず, さらに左下腿から左膝蓋を經由して左足背に移動し, 同部に5日間停滞した. その先端部を再び7月25日に生検した. 患者は1999年3月に生ホタルイカを摂食していた.

現症: 左下腿に幅約5mmの一部水疱を伴う浮腫性の蛇行性紅色線状皮疹を認めた(図1).

臨床検査所見: WBC 4,200/ $\mu$ l (Seg 67%, Eos 3%, Baso 1%, Lymph 22%), RBC 306 $\times$ 10<sup>4</sup>/ $\mu$ l, Hb 9.8 g/dl, Ht 28.5%, Plt 15.5 $\times$ 10<sup>4</sup>/ $\mu$ l, AST 64 IU/l, ALT 63 IU/l, LDH 307 IU/l, FBS 121 mg/dl, FRA 318  $\mu$ mol/l, HbA<sub>1c</sub> 5.2%

病理組織像: HE染色にて真皮浅層に3つの虫体断面を認める(図2). 断面の幅は100 $\mu$ mで薄い角皮下に一部融解がみられる筋細胞(poly-myarian-type)と連続切片の一部に非対称性双葉

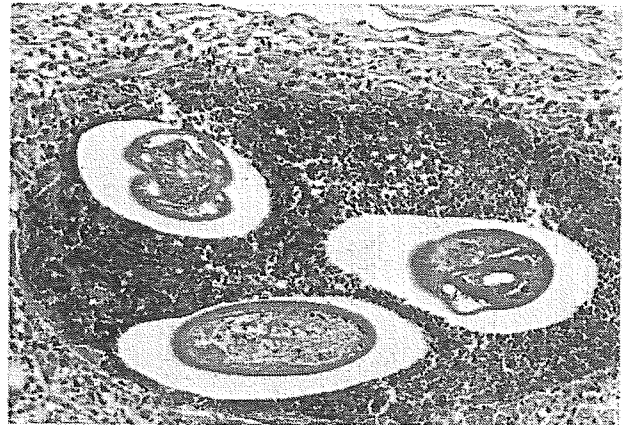


図2 病理組織像  
皮膚真皮内の幼虫断面

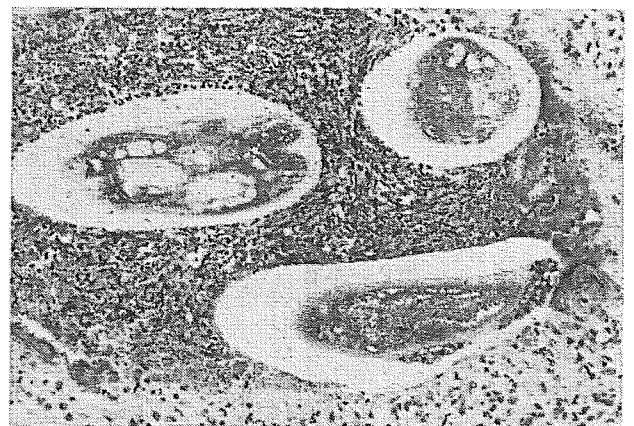


図3 病理組織像  
B血清による酵素抗体法(IgG)で陽性

状の側索があった. 虫体の周囲に好酸球浸潤がみられた. 以上の形態学的特徴から Hasegawa<sup>1)</sup>の提唱する旋尾線虫幼虫 Type-X とした<sup>2-4)</sup>.

放射線科受診時に定期的に血液検査を行っていたため, 患者の承諾を得てその血清を以下の3種類の検査に使用した. まずホタルイカに寄生する旋尾線虫の幼虫をJB-4樹脂に包埋し, この薄切切片を用いて蛍光抗体間接法を行ったが陰性であった. そこで次に本患者の虫体を含む病変部切片についてAおよびBの血清を用いて酵素抗体法(IgG)を施行した(A:本幼虫の食道腺質部に対する蛍光抗体間接法が陽性であった他の患者血清, B:食道腺質部に加え筋組織に対しても陽性が認められた他の患者血清). A血清では陰性であったがB血清では陽性であった(図3). また, 顎口虫は同じ旋尾線虫亜目<sup>2)</sup>であるので, 交差反応を

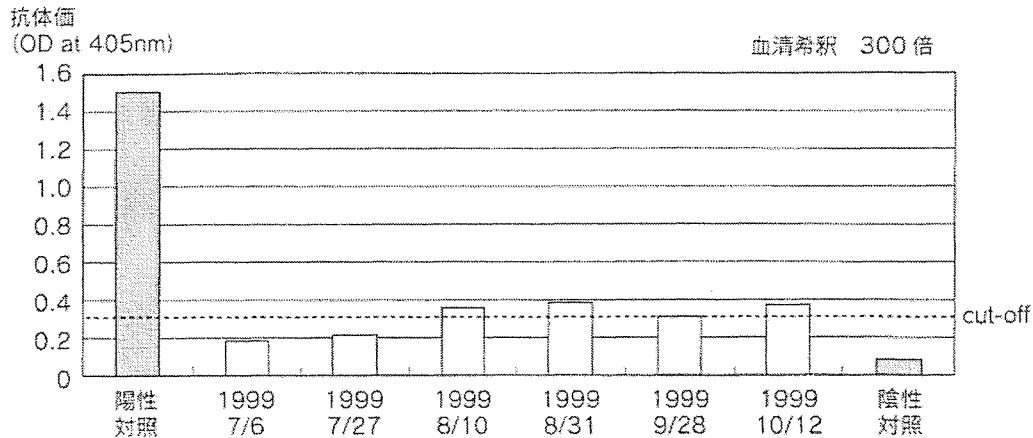


図4 ドロレス顎口虫抽出抗原に対する抗体価の推移

利用して、ドロレス顎口虫成虫の虫体抽出抗原を用いた microplate ELISA 法にて IgG 抗体価を測定したところ 1999 年 8 月 10 日分から陽性所見を得た (cut-off 値は複数の健常人の OD+3 SD とした。300 倍希釈では cut-off 値はおよそ 0.300) (図 4)。約 1 年後 (2000 年 6 月 6 日) の血清では陰性化した (データは示さず)。

治療および経過：2 回目の生検後は皮疹の再発はなく、軽度色素沈着を残して治癒した。

## 考 按

本症の 2002 年 12 月までの本邦報告例は 93 例で、そのうち皮膚爬行症は 50 例、眼移行は 1 例、腸閉塞は 42 例である。皮膚爬行症の発症部位としては、50 例中 45 例が軀幹 (腹部が多い) で、残り 5 例は下肢 4 例、手指 1 例であった。旋尾線虫幼虫がどのようにして皮膚に出現するかはいまだにはっきりしていない。腹部に出現する例では臍を中心として腹壁に現れ、左右いずれかの腹壁に広がっていくパターンが多い。本症例では膝部から発症しているの、鼠径部周辺から腹壁を出て皮膚の深部を移動しながら膝部に達したと思われる。また、血行性に門脈から肝臓に至り、肺から心臓に戻って大循環にのって膝部に達した可能性もある。

生ホタルイカを食べてから発症までの期間は、大滝ら<sup>9)</sup>は 2 日～1 か月までであるとしているが、本症例ではさらに長く約 3 か月を経て発症している。また虫体の体内生存期間に関しては、高橋ら<sup>9)</sup>は本症が出没を繰り返さないため、比較的早

期に死滅すると推測している。しかし、本症例では 27 日間皮膚爬行をしている。生ホタルイカを摂食してから約 4 か月間、虫体が生存したことになる。

本症の診断には通常患者血清を用いた蛍光抗体間接法が行われている。皮膚爬行症はまず治療を兼ねた生検において虫体の断片が得られれば形態から診断するが、虫体をとらえられないときは問診および特異的臨床症状 (爬行速度や水疱の有無など) と蛍光抗体間接法で診断する。岡沢ら<sup>9)</sup>は蛍光抗体間接法による旋尾線虫幼虫皮膚爬行症患者の血清抗体価の測定による診断法を確立した。それによると患者は血清抗体価が高く、健常人の値から区別できる。抗体が結合する抗原は幼虫の食道腺質部に局在すること、また顎口虫による皮膚爬行症患者の血清でも高い抗体価が得られるものの、抗原は筋層とクチクラ層にあり、旋尾線虫の場合と異なることから両者を区別できるとしている。

本症例では生検において旋尾線虫幼虫 Type-X であることが確認されたが、一般的に診断に用いられている蛍光抗体間接法では Type-X に対する抗体は陰性であった。病理組織像で筋組織が融解していたことや、現病歴で皮膚爬行先端部が同じ場所に 5 日間停滞していたことから、幼虫はその場所で死滅したと考えられる。虫体が死滅崩壊することによって食道腺質部の抗原性が失われたが、筋組織由来の抗原は残存して、患者の血清中には崩壊中に放出された幼虫の筋組織に対する抗体ができたと思われる。このため、幼虫は酵素抗



体法で B 血清でのみ陽性になったと考えられる。血清 B で染色された虫体の内容は、食道腺質部と思われる部位も膨化変性した筋組織由来の物質がつまっていたのではと推定した。また、ドロレス顎口虫抽出抗原を用いての ELISA 法で陽性となったのは、岡沢ら<sup>3)</sup>の報告から旋尾線虫の筋層には顎口虫との共通抗原が存在すると予測されることから、幼虫の筋組織に対する抗体と反応したためと考えられる。ただし、交差反応を利用しているため、本来のドロレス顎口虫症患者血清より抗体価が低い。また、旋尾線虫幼虫による腸閉塞患者血清中における蛍光抗体間接法での経時的に測定した報告<sup>7-12)</sup>では、陽性の時期はホタルイカ摂食から 2~6 週の間となっている。蛍光抗体間接法と異なり、ELISA 法で今回測定したのは幼虫の筋組織に対する抗体であり、幼虫が死滅したと推測された日より後に陽性となり、また測定できた 3 か月間と長期にわたって陽性であった。

特異的な抗原のない現段階では、蛍光抗体間接法は診断には大変有効な方法であるが、本症例や大滝ら<sup>13)</sup>の報告でも、実際に虫体が検出できて

も患者血清中の旋尾線虫出現に対する証拠抗体は陰性の場合もある。もし新鮮な虫体ではないため寄生虫の同定ができない場合は、虫体のみられた患者組織の切片を抗原として抗血清(既知抗体陽性患者血清)を反応させる酵素抗体法(IgG)も有用ではないかと考えた。

本論文の要旨は第 100 回日本皮膚科学会総会(2001 年 4 月, 東京)にて発表した。

## 文 献

- 1) Hasegawa H: Acta Med Biol 26: 79, 1978
- 2) 赤尾信明, 藤田紘一郎: 皮膚臨床 39: 843, 1997
- 3) 岡沢孝雄, 他: 北陸公衛誌 20: 71, 1993
- 4) Kagei N: Jpn J Parasitol 40: 437, 1991
- 5) 大滝倫子, 赤尾信明: 臨床病理 108(臨増): 258, 1998
- 6) 高橋伸也, 他: 皮膚臨床 34: 341, 1992
- 7) 守田万寿夫, 他: 日消誌 92: 26, 1994
- 8) 橋 良哉, 他: 日消誌 98: 1071, 2001
- 9) 江本拓也, 他: 臨放 47: 335, 2002
- 10) 古川浩一, 他: 新潟県厚生連医誌 9: 97, 1999
- 11) 長沼甲太郎, 他: 臨牀消化器内科 12: 1795, 1997
- 12) 青山 庄, 他: 内科 75: 717, 1995
- 13) 大滝倫子, 他: 西日皮膚 59: 598, 1997

## □文献紹介□

### 米国における水痘ワクチン接種実施後の水痘による死亡率の低下

米国において、1995 年から水痘のワクチン接種プログラムが施行された。この水痘ワクチン接種プログラムの効果を評価するため、水痘が直接死因または死亡に影響した要因と記載された死亡に関するデータを、1990 年から 2001 年の米国国立保健統計センターにおける複数の死因による死亡率データから解析した。水痘による死亡率は 1990 年から 98 年にかけて変動し、その後急激に低下した。1990 年から 94 年の期間に水痘に関連した死亡件数の平均は年間 145 件であったが、1999 年から 2001 年には年間 66 件に減少した。年齢群による死亡率は、1~4 歳の幼児が 92% 減と最も低下し、その他 50 歳未満の全年齢群で低下した。ワクチン接種プログラムのターゲットである 1 歳から 4 歳児の死亡率が低下しただけでなく他の年齢層でも死亡率が低下したのは、集団免疫効

果があったためと推測される。小児に対する水痘ワクチン接種プログラムを国家規模で施行したのは米国が世界で始めてであるが、小児だけでなく成人に対しても水痘関連死を減少させることができることが確認された。今後、他国においても水痘ワクチン接種プログラムが国家規模で展開されることが望まれる。

Huong Q Nguyen, et al: Decline in Mortality Due to Varicella after Implementation of Varicella Vaccination in the United States. N Engl J Med 352: 450, 2005

(慶應義塾大学 小野紀子)

症  
例

## 旋尾線虫幼虫による Creeping Disease

—自家製ホタルイカ沖漬けの生食により生じた1例—

芦田 敦子\* 河内 繁雄\* 斎田 俊明\*  
高本 雅哉\*\* 赤尾 信明\*\*\*

## 要 約

51歳, 男性。自家製のホタルイカの沖漬けを数日にわたって摂食した。その約2週間後, 右下腹部痛が出現し, さらに3日後, 右側腹部に周囲に手掌大の浮腫性紅斑を伴い, 表層に小水疱を伴う線状爬行疹が出現した。生検にて爬行疹先端部よりもさらに1cm程先の表皮直下に虫体断面を確認し, 旋尾線虫幼虫タイプXと同定した。また, 旋尾線虫タイプX幼虫の薄切切片を用いた酵素抗体法により, 血中特異抗体の上昇を確認した。旋尾線虫幼虫症には creeping disease を引き起こす皮膚爬行疹型と腸閉塞型があるが, 自験例は前者の特徴をよく示していた。本症は最近増加しており, 原因となるホタルイカの生食を慎むよう注意を喚起する必要がある。

キーワード: creeping disease, 旋尾線虫幼虫タイプX, ホタルイカ

## I. はじめに

creeping disease は寄生虫が皮内や皮下を遊走するため線状爬行疹を生じる疾患である。旋尾線虫幼虫症は, 1980年代後半よりそれまで多かった顎口虫症以外の新しい寄生虫症として報告が相次ぎ, 1992年にその原因がホタルイカの生食によることが判明した。今回我々は, ホタルイカの沖漬けを摂食後に発症した旋尾線虫幼虫による creeping disease を経験したので報告する。

## II. 症 例

患 者 51歳, 男性  
初 診 2003年5月26日  
主 訴 右側腹部の紅色皮疹

既往歴・家族歴 特記すべきことなし。

現病歴 5月21日, 右下腹部痛が出現し, 近医を受診した。24日より右側腹部に痒みのある紅色皮疹が出現し, 26日, 末梢血好酸球増多と腹部CTで皮下の炎症像を指摘され, 安曇総合病院皮膚科へ紹介された。初診時, 右側腹部に痒痒と熱感を伴った10×8cm大の環状の浮腫性紅斑を認め, その中心部には1cm大の硬結を触知した。虫刺症やライム病, creeping disease の初期などを疑い経過観察したところ, 27日より紅斑上に右側腹から背部へ向かって移動する線状疹が出現した。28日, 線状疹の先端部を切除した。問診により下腹部痛出現の2週間前に, 新潟の海産物店で購入した生のホタルイカにて自家製の「沖漬け」(醤油, みりん, 酒などに漬けたもの)を作

\* Atsuko ASHIDA, Shigeo KAWACHI & Toshiaki SAIDA, 信州大学, 皮膚科学教室 (主任: 斎田俊明教授)

\*\* Masaya TAKAMOTO, 同, 医学研究科移植免疫感染症学 (主任: 菅根一男教授)

\*\*\* Nobuaki AKAO, 東京医科歯科大学, 国際環境寄生虫学分野 (主任: 藤田紘一郎教授)

別刷請求先 芦田敦子: 信州大学医学部皮膚科 (〒390-8621 松本市旭 3-1-1)

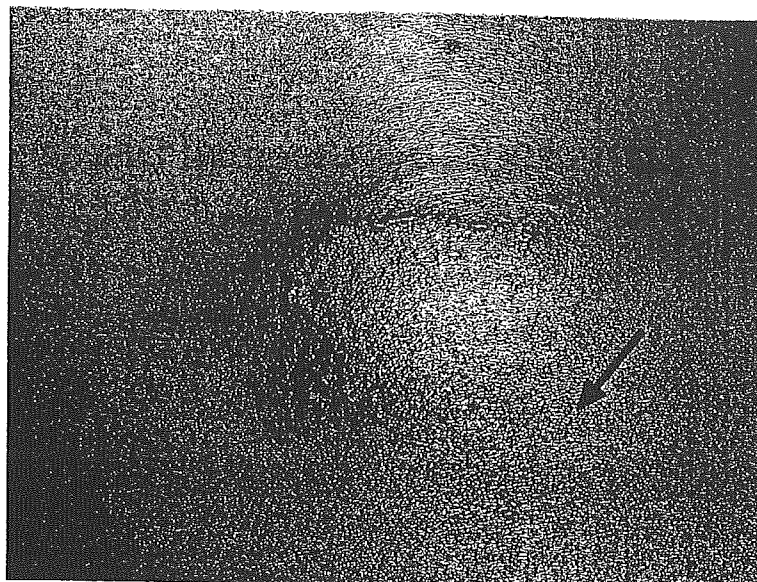
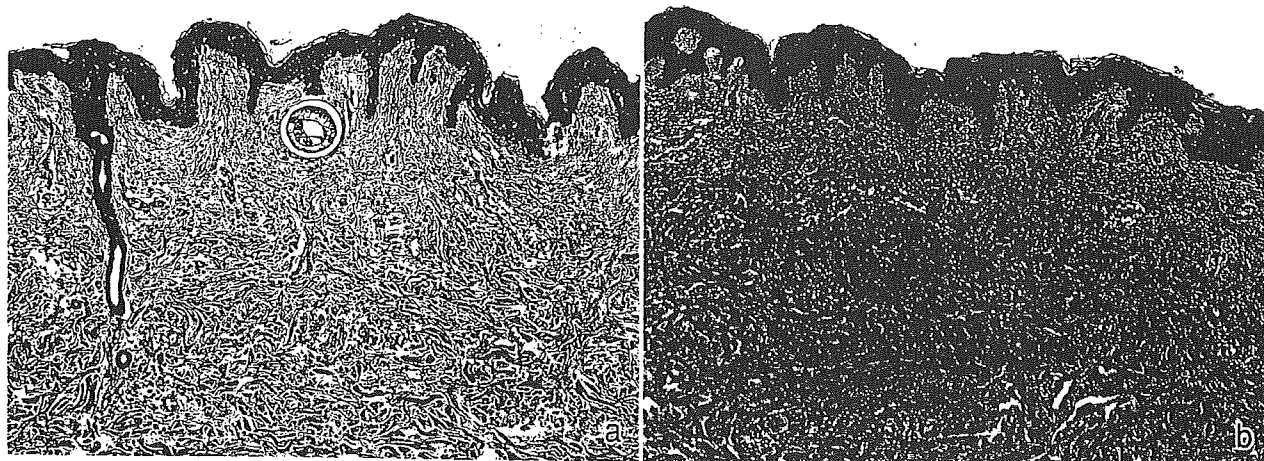
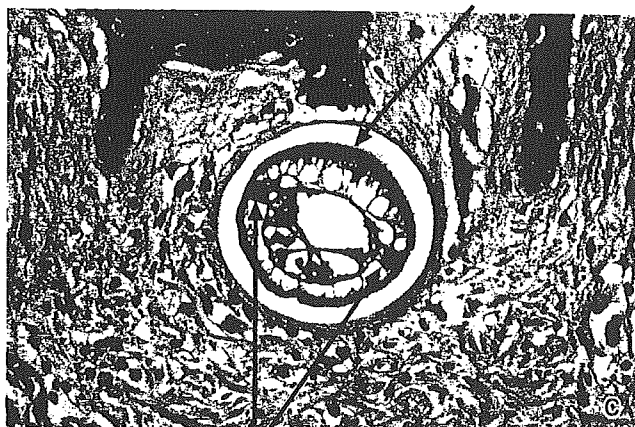


図1 臨床像：右側腹から背部にかけての小水疱を伴う線状爬行疹（矢印が生検部）



角皮



側索

図2 爬行疹先端部の病理組織像

- a：表皮直下に虫体の断面像が認められる。
- b：浸潤硬結を触れる紅斑部；虫体の通過部位を中心に，好酸球，リンパ球からなる炎症細胞が稠密に浸潤する。
- c：虫体断面像（強拡大）；角皮の表面に突起がなく，左右非対称の側索が消化管に接して突出する。

り、数日にわたって大量に摂食していた。また、前日にはマグロ、カツオの刺身を食べているが淡水魚は摂食していない。

**生検時現症** 右側腹部から背部にかけ、長さ約10 cmの釣り針状に蛇行する鮮紅色の線状皮疹を認める。線状疹の幅は約2 mmで硬く浸潤を触れ、その表層には線状に配列する小水疱を形成し、周囲には幅2~3 cmの浮腫性紅斑を伴っている(図1)。先端部では、肉眼で確認できる紅斑よりもさらに1 cm程前方まで軽度の浸潤硬結を触知した。

**初診時検査所見** 白血球数10690/mm<sup>3</sup>、好酸球27.3%、CRP 2.18 mg/dlと上昇を認めた。他には異常なし。

**病理組織学的所見** creeping diseaseと考え、線状皮疹の浸潤を触れる先端部を中心に長径4.5 cmの紡錘形に皮下まで切除した。皮疹先端よりやや先の部分に相当する表皮直下に虫体横断面が認められた(図2-a)。虫体周囲と真皮から皮下脂肪織までの血管周囲に好酸球、リンパ球からなる炎症細胞が浸潤する。浸潤硬結を触れる紅斑部では好酸球を多数混じた稠密な炎症細胞浸潤が認められ、特に虫体の通過部位と思われる部位には好酸球の集積が著明である(図2-b)。虫体の直径は99 μmで、角皮の表面に突起がなく、左右非対称の側索が消化管に接して突出しているなどの所見より、旋尾線虫幼虫タイプXと同定した(図2-c)。

**免疫血清学的所見** タイプX幼虫の薄切切片を抗原とした酵素抗体法による血中抗体検査では、患者血清(6月4日採取)200倍希釈まで陽性であった。

**経過** 虫体摘出後、ステロイド軟膏の外用により約1週間で皮疹は消退した。

### Ⅲ. 考 案

旋尾線虫幼虫は線虫類に属する寄生虫だがその成虫は確定されておらず、終宿主も不明である。人体への侵襲にはcreeping disease(皮膚爬行疹型)と腸閉塞型がある。本幼虫は形態学的に13種に分類されているが、タイプXが最も腸管への侵入性が高く、上記2病型の原因となることが多い<sup>1)</sup>。タイプX幼虫は体長0.5~1 cm、体幅80~100 μmで、ハタハタ、タラ、ホッケ、ホタルイカ、スルメイ

カなどの腸管に寄生しており、中でも内臓を取り出さずに生食されるホタルイカが原因となることが多い<sup>2)</sup>。本症の発症時期はホタルイカ漁解禁時期の3~8月に集中している。ちなみにホタルイカにはアニサキスの寄生は確認されていない。

これまで本邦における本幼虫によるcreeping diseaseの報告は調べた限り51例あり、次のような特徴が見出された。①潜伏期は数日~2週間前後である。②好発部位は体幹で、中でも腹部が最好発部位である。③臨床症状は掻痒を伴う紅斑から始まり、次に線状皮疹が出現する。移動性の線状皮疹が出現すれば診断は比較的容易であり、ホタルイカの摂食を確認すれば確定される。しかし、掻痒性紅斑のみの場合や、小水疱を形成するものの線状皮疹が明らかでない場合は初期診断が難しく、接触皮膚炎、帯状疱疹、虫刺症などとの鑑別が問題となる<sup>3)</sup>。自験例では初診時、マダニ咬傷に伴う慢性遊走性紅斑に類似していた。④本幼虫による爬行疹は、顎口虫症やマンソン孤虫症による爬行疹に比べ、1)線状皮疹が細く、鋭い印象がある、2)表層に小水疱を形成することが多い、3)移動が速い、などの特徴がある。これは虫体の体幅が1 mm以下と細いことや、表皮や真皮上層など皮膚の浅層部の爬行が多いためと考えられている。また、移動速度は1日2~7 cm、中には2時間で22 mm移動した例もある<sup>4)</sup>。したがって、虫体はすでに線状紅斑よりも先の部位に移動していることが多いので、切除する場合にはこの点を十分に考慮する必要がある。自験例では、爬行疹先端部付近を丹念に触診することで虫体の存在部位を推定することができた。病理組織学的に虫体周囲の炎症反応は虫体の通過部位のそれに比べ軽度であった。これも虫体の移動速度の速さを裏付ける所見と考えられた。

体内での移行経路については未だ解明されていないが、経口摂取された幼虫は腸壁を突き破り、腹腔から皮膚に侵入すると考えられている。摂取半日から数日後に腹痛、悪心などの消化器症状を伴うことがあるが程度は軽く一過性である。これに対し、腸閉塞型では上記と同時期に急性腹症として発症する。しかし腸壁に侵入して腸壁に炎症を持続させる幼虫と、貫通して皮膚に到達する幼

表 1 旋尾線虫幼虫による creeping disease  
20 例 (1997~2003 年) のまとめ

1. 消化器症状合併例	9/20 例 (45%)
2. 9%以上の好酸球上昇	9/13 例 (69%) (7 例:記載なし)
3. 虫体摘出例	12/20 例 (60%)
4. 虫体の存在部位	
表皮内	1 例
真皮上層	4 例
真皮中層	3 例
真皮下層~皮下	3 例
記載なし	1 例
5. 線状の小水疱形成	11/20 例 (55%)

虫が同じ種類かどうかはわかっていない。これまで腸閉塞型の中で皮膚症状を伴っていたのは 1 例のみである<sup>5)</sup>。

自験例を含め 1997 年以後に報告された皮膚爬行疹型 20 例について解析したところ、9 例 (45%) が消化器症状を伴っていた。9%以上の好酸球上昇を認めたのは記載のあった 13 例中 9 例 (69%) であった。また、この 9 例のうち 7 例に消化器症状が認められている (表 1)。皮膚爬行疹型では好酸球は正常か軽度上昇のことが多いが<sup>6)</sup>、腸閉塞型では高率かつ著明に好酸球が上昇する傾向がある。青山らは 10 例の腸閉塞型において、全例で好酸球が 8%以上であり、その半数は 20%以上を示したと報告している<sup>5)</sup>。自験例は白血球、好酸球とも上昇し、消化器症状もかなり強かった。皮膚爬行疹型でも炎症反応が強い場合は白血球増多や好酸球増多を呈するものと考えられる。

本症の診断はホタルイカの生食歴、線状爬行疹、虫体の摘出により確定されるが、虫体が検出されない場合はタイプ X 幼虫の薄切切片を抗原とした酵素抗体法が有用である<sup>7)</sup>。

治療は虫体の摘出だが、これまでの報告では切除範囲は様々である。大滝らは先端から正常部を含め 3~4 cm の切除が望ましいとしている<sup>2)</sup>。虫体摘出率は 60%だったが (表 1)、皮膚の浅い部位を移動する割には少ないという印象がある。これはやはり移動が速いためと考えられる。自験例では虫体が存在したのは線状皮膚疹の先端よりもさらに先で、視診上は正常皮膚であったが浸潤を触知した。蛇行して後戻りした症例も報告されてい

るが、その際も虫体存在部位は強く浸潤を触れたとの記載があり<sup>2)</sup>、先端周囲を広範囲に丹念に触診することが有用と思われる。また、皮下組織に虫体が存在することもあるため、先端周囲を大きく皮下脂肪層まで切除することが必要である。本症に有用な駆虫剤は今のところ存在しないが、摘出されなくても虫体は数週間で死滅するようである。

旋尾線虫幼虫は十分な加熱や冷凍で死滅することが確認されており、自験例は未冷凍のホタルイカを購入したと思われる。これまでホタルイカの沖漬けが原因となった報告は自験例以外に 1 例あるが<sup>8)</sup>、自家製か否かの記載はなかった。市販されている沖漬けはすべて冷凍処理してある。

1994 年に生ホタルイカの危険性がマスコミで大々的に取り上げられてからは出荷自粛が相次いだ。その後、ホタルイカの産地である富山県を中心に生食用は急速冷凍して出荷されるようになり、本症の報告は一時減少したが最近再び報告が増加している。理由として、ホタルイカの取扱業者が日本海沿岸各地に増加し、未冷凍の生ホタルイカが今なお市場に出回っていること、生食による危険が一般に広く知られていないことなどが考えられる。

1997 年と 2000 年に当時の厚生省は、生食用ホタルイカは冷凍済みならその旨を、未冷凍なら内臓除去する旨をラベル表示するよう、各都道府県に対し通達した。しかし、法的に罰則が科せられていないため、そのような表示のない商品が多数市場に出回っている。今後も行政による指導と一般消費者への注意の喚起が望まれる。

本論文の要旨は日皮学会第 153 回信州地方会において発表した。

(2004 年 9 月 24 日受理)

#### 又 献

- 1) Hasegawa H: Acta Med Biol, 26: 79-116, 1978
- 2) 大滝倫子, 赤尾信明: 臨床病理, 108: 258-263, 1998
- 3) 中野敏明ほか: 皮膚病診療, 21: 35-38, 1999
- 4) 藤平圭子ほか: 皮膚臨床, 94: 354-355, 1992
- 5) 青山 庄ほか: 日消誌, 93: 312-321, 1996
- 6) 松永 剛ほか: 皮膚医誌, 14: 30-32, 2001
- 7) 杉山 広ほか: Clin Parasitol, 13: 98-101, 2002
- 8) 諏訪部寿子ほか: 西口皮膚, 61: 67-69, 1999