

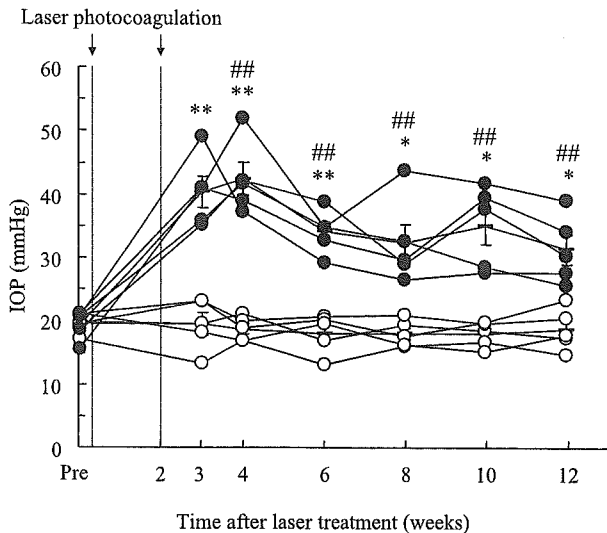Fig. 2. Time change in IOP in each right control eye (open circle) and left experimental glaucoma eye (closed circle) in Experiment 1. There was a significant interaction effect ( $p < 0.001$ ) between the group (treatment) and time on IOP using a mixed model followed both by a  $t$ -test with Bonferroni's correction ( $*p < 0.05$ ,  $**p < 0.01$  vs. right control eye) and by a paired Dunnett's multiple-comparison test ( $## p < 0.01$  vs. pre-laser treatment values).  $n = 5$ . Thick horizontal lines and vertical bars indicate mean  $\pm$  SE.

( $p > 0.05$ ) in the control eyes versus the pre-laser treatment value.

In Experiment 2, the baseline IOP before laser treatment was  $18.4 \pm 1.1$  mmHg ( $n = 6$ ) in the right eye and  $18.3 \pm 1.1$  mmHg ( $n = 6$ ) in the left eye. For the experimental glaucoma eyes, IOP was persistently elevated for 16 weeks, being statistically significant after 3, 4, 5, 6, 8, 10, 12, 14, and 16 weeks versus the IOP in the control eye or the pre-laser treatment value (Fig. 3).

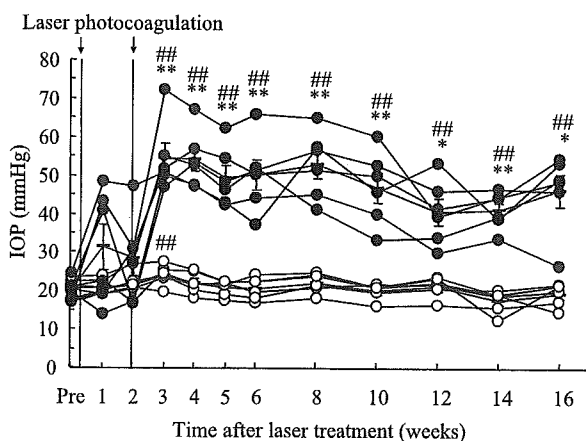


Fig. 3. Time change in IOP in each right control eye (open circle) and left experimental glaucoma eye (closed circle) in Experiment 2. There was a significant interaction effect ( $p < 0.001$ ) between group (treatment) and time on IOP using a mixed model followed both by a  $t$ -test with Bonferroni's correction ( $*p < 0.05$ ,  $**p < 0.01$  vs. right control eye) and by a paired Dunnett's multiple-comparison test ( $## p < 0.01$  vs. pre-laser treatment values).  $n = 6$ . Thick horizontal lines and vertical bars indicate mean  $\pm$  SE.

There was a significant interaction effect ( $p < 0.001$ ) between the group treatments and the time for IOP. In contrast, there were no significant changes in the control eyes, except for the IOP increase ( $p = 0.002$ ) after 3 weeks versus the pre-laser treatment value.

### 3.2. Fundus photography

Ocular fundus photographs taken of both the eyes of a single monkey (animal No. 1) 12 weeks after laser treatment are shown in Fig. 4. In comparison with the control eye (Fig. 4a), the experimental glaucoma eye (Fig. 4b) exhibited deepened and enlarged optic disc cupping, nerve fibre layer thinning, and peripapillary choroidal atrophy. These changes were seen in all laser-induced experimental glaucoma eyes of 11 monkeys.

### 3.3. Optic disc topography

Topographic images of the optic nerve head obtained using HRT for both the eyes of a single monkey (animal No. 1) 12 weeks after laser treatment in Experiment 1 are shown in Fig. 5. Mean values for the optic disc topographic parameters in the control and experimental glaucoma eyes of five monkeys are shown in Table 1. Seven of the eight global topographic parameters showed statistically significant differences between the two eyes, the exception being the disc area. Differences in the rim area and height variation contour were still significant ( $p < 0.0063$ ) after correcting the  $p$ -value by the number of comparisons, which totalled eight parameters.

Over the time course of changes in Experiment 2, baseline values were taken as the average of three measurements made at 1-week intervals before the laser treatment, and confirmed that there was no significant right-left difference in any of the HRT parameters examined. From the variation in the baseline data ( $n = 6$ ), changes greater than 4.6% for the rim area, 9.7% for the height variation contour, 10.6% for the rim volume, 10.5% for the mean RNFL thickness, 36.6% for the cup volume, 18.4% for the cup shape measure and 7.3% for the mean cup depth (% change vs. baseline value) would be detected with  $n = 6$  with a significance level ( $\alpha$ ) of 0.05 using the Dunnett's critical value for 10 groups of 2.6862 and statistical power ( $1 - \alpha$ ) of 0.8. The time course of the changes for the average of the HRT parameters in Experiment 2 is shown in Fig. 6. There were significant interaction effects between group treatments and time for all parameters except the disc area ( $p = 0.997$ ). For the experimental glaucoma eyes, all the HRT parameters except the disc area changed in a time-dependent manner, but almost plateaued 4 weeks after the laser treatment. In contrast, there were no significant changes ( $p > 0.05$ ) in the control eyes vs. the pre-laser treatment value. To determine the rate of change in individual eyes, the mean  $\pm$  3SD values including 99.6% distribution for individual

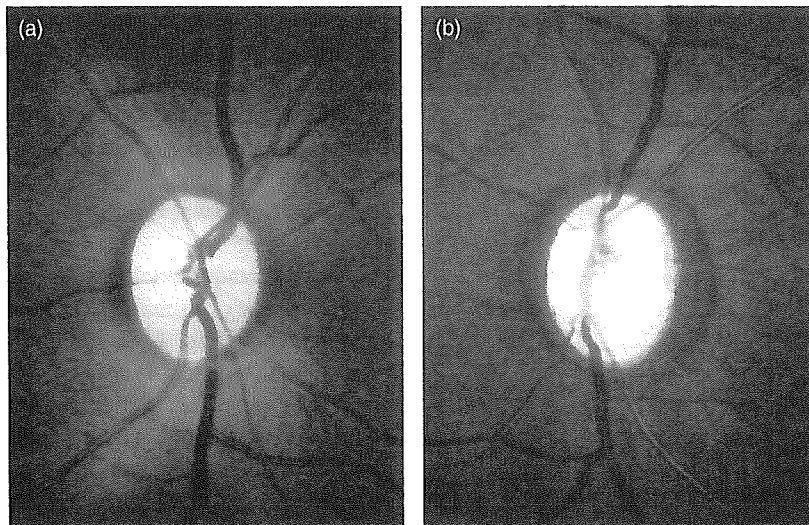


Fig. 4. Ocular fundus photographs of right control (a) and left experimental glaucoma eyes (b) of a representative monkey (Experiment 1). Deep optic disc cupping, nerve fibre layer thinning, and peripapillary choroidal atrophy were observed in the experimental glaucoma eye (B)

parameters obtained from three consecutive pre-laser values for each eye were used and the change was considered to be statistically significant for an individual parameter after laser treatment, when it exceeded its pre-laser mean  $\pm 3SD$  value for the measured and subsequent time points. For the control eye, there were no changes in any HRT parameter. Among the HRT parameters of the experimental glaucoma eyes, five of five eyes (excluding one eye of a monkey developing corneal cloudiness) changed in terms of rim area, rim volume, cup volume and mean cup depth after 3–4 weeks and in height variation contour after 10–12 weeks.

### 3.4. Retinal nerve fibre layer (RNFL) analysis

Typical retardation maps obtained using GDx FCC are shown in Fig. 7 for the control eye and the experimental glaucoma eye of a single monkey 12 weeks after laser treatment in Experiment 1. For the right control eye, the peripapillary thickness on the green concentric ellipse located 1.5 disc diameters away from the edge of the optic disc showed a double-hump pattern thicker in the superior and inferior quadrants than in the nasal and temporal quadrants (Fig. 7A). In the experimental glaucoma eye, this double-hump pattern had vanished due to diffuse thinning of

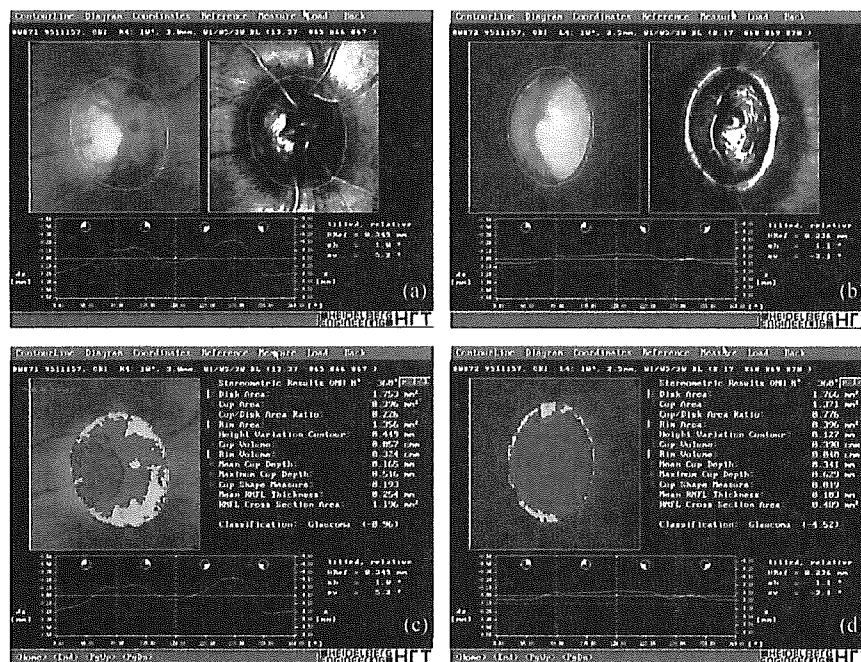


Fig. 5. Mean topographic images of optic nerve head obtained from HRT and stereometric results within the contour line in the right control eye (a and c) and left experimental glaucoma eye (b and d) of a representative monkey (Experiment 1).

Table 1  
Optic disc topographic parameters for control and experimental glaucoma eyes 12 weeks after laser treatment (Experiment 1)

Parameters	Control eye	Experimental glaucoma eye	p value
Disc area (mm <sup>2</sup> )	1.656 ± 0.055	1.611 ± 0.078	0.651
Rim area (mm <sup>2</sup> )	1.251 ± 0.178	0.484 ± 0.079	0.004
Cup volume (mm <sup>3</sup> )	0.055 ± 0.023	0.336 ± 0.096	0.043
Rim volume (mm <sup>3</sup> )	0.349 ± 0.083	0.060 ± 0.013	0.025
Mean cup depth (mm)	0.146 ± 0.016	0.334 ± 0.061	0.034
Cup shape measure	-0.182 ± 0.049	0.003 ± 0.030	0.012
Height variation contour (mm)	0.407 ± 0.034	0.164 ± 0.016	<0.001
Mean RNFL thickness (mm)	0.237 ± 0.041	0.122 ± 0.010	0.046

Data are expressed as mean ± SE for five animals. RNFL indicates retinal nerve fibre layer.

the RNFL (Fig. 7B). Mean values for the RNFL polarimetric parameters of the control and experimental glaucoma eyes of five monkeys are shown in Table 2. The experimental glaucoma eye had significantly lower values than did the control eye for all parameters except for the superior, temporal, nasal, and S+I. Differences in the RaIN, Ra(SN+IN) were still significant ( $p < 0.0063$ ) after correcting the p-value by the number of comparisons, eight parameters in total.

The time course of changes in the Ra(SN+IN) in both eyes of Experiment 2, which has shown good correlations with the histological RNFL thickness in five of five right control eyes in Experiment 1 (described below), was shown

for each eye in Fig. 8. These parameters declined in a time-dependent manner during the period in which there was persistent IOP elevation in the left experimental glaucoma eye (see Fig. 3).

### 3.5. Histological examination

For the experimental glaucoma eye (Fig. 9C) of a representative monkey in Experiment 1, histological abnormalities were seen in various regions compared with the control eye (Fig. 9A) 12 weeks after laser treatment. The optic nerve head (ONH) showed marked atrophy, with deep cupping of the optic disc and thickening of the fibrous tissue

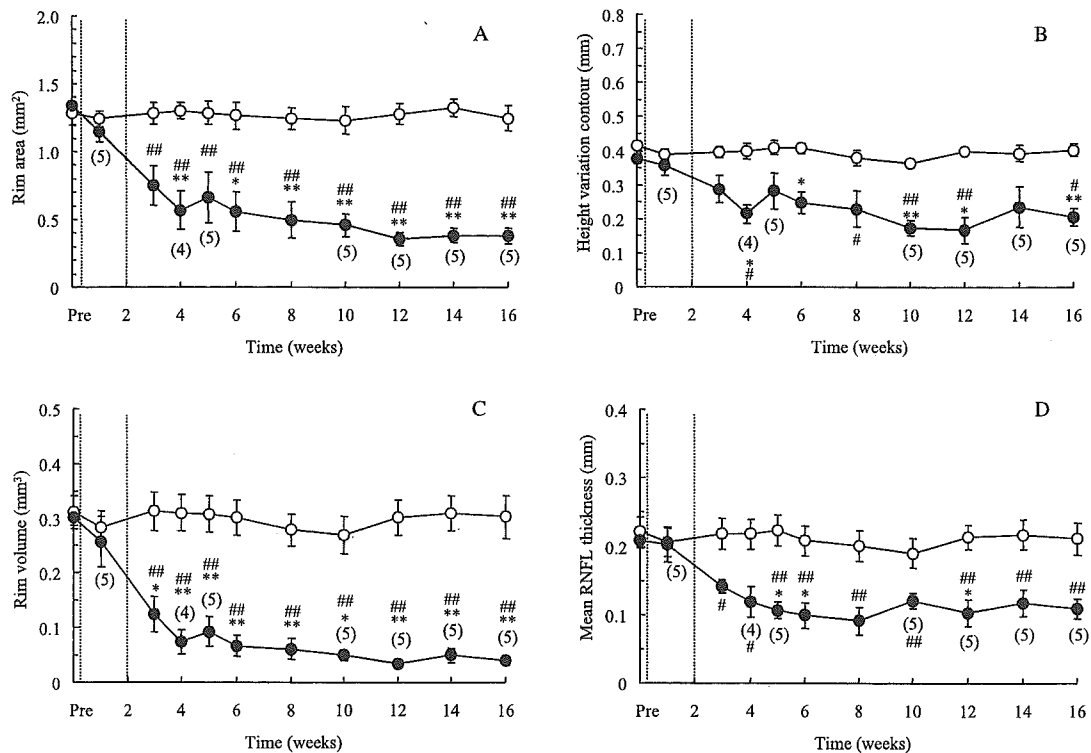


Fig. 6. Time-course of changes in the rim area (A), height variation contour (B), rim volume (C), mean RNFL thickness (D), cup volume (E), cup shape measure (F), mean cup depth (G), and disc area (H) measured using HRT in Experiment 2. Left experimental glaucoma eye, filled circle; right control eye, open circle. Data-points were derived from four to six eyes. There were significant interaction effects between group (treatment) and time on the rim area ( $p < 0.001$ ), height variation contour ( $p = 0.014$ ), rim volume ( $p < 0.001$ ), mean RNFL thickness ( $p < 0.001$ ), cup volume ( $p = 0.024$ ), cup shape measure ( $p < 0.001$ ), and mean cup depth ( $p = 0.003$ ), but not on disc area ( $p = 0.997$ ) using a mixed model followed both by a *t*-test with Bonferroni's correction ( $*p < 0.05$ ,  $**p < 0.01$  vs. right control eye) and by a paired Dunnett's multiple-comparison test ( $\# p < 0.05$ ,  $\#\# p < 0.01$  vs. pre-laser treatment values).

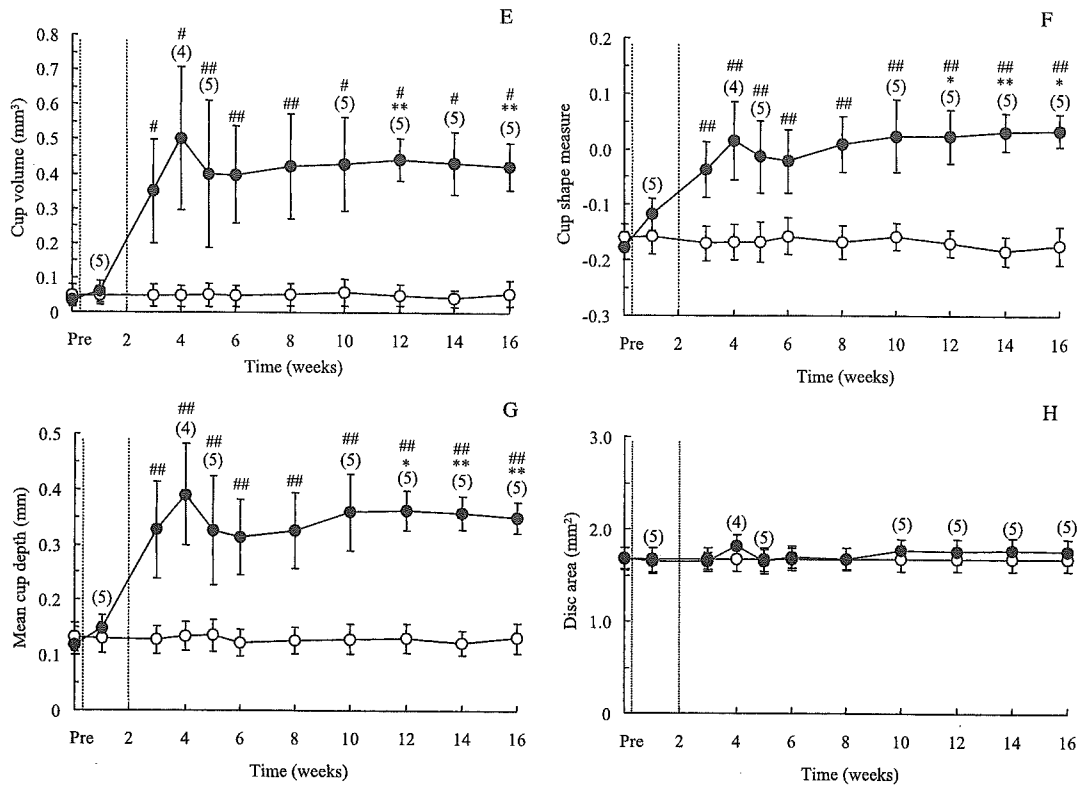


Fig. 6 (continued)

septa and an increased number of glial nuclei. A vertical section showed reduced RNFL thickness in the superior retinal portion (Fig. 9D) in comparison with that of the control eye (Fig. 9B).

In Experiment 1, mean values for the RNFL thickness in the superior quadrant 1.5 disc diameters from the edge of the optic disc determined from histological specimens taken 12 weeks after laser treatment were  $65 \pm 11 \mu\text{m}$  ( $n=5$ ) for the experimental glaucoma eyes and  $183 \pm 23 \mu\text{m}$  ( $n=5$ ) for the control eyes ( $p=0.002$ ) as also shown in Table 2. For the inferior quadrant, corresponding values were  $63 \pm 13 \mu\text{m}$  ( $n=5$ ) and  $210 \pm 26 \mu\text{m}$  ( $n=5$ ), respectively ( $p=0.001$ ).

In Experiment 2, values obtained from the histological specimens 16 weeks after the laser treatment were as

follows: for the superior quadrant,  $45 \pm 7.4 \mu\text{m}$  ( $n=6$ ) for the experimental glaucoma eyes and  $148 \pm 8.3 \mu\text{m}$  ( $n=6$ ) for the control eyes ( $p<0.001$ ); and for the inferior quadrant,  $49 \pm 11 \mu\text{m}$  ( $n=6$ ) for the experimental glaucoma eyes and  $152 \pm 11 \mu\text{m}$  ( $n=6$ ) for the control eyes ( $p<0.001$ ).

In Experiments 1 and 2, mean values for the vertical disc diameter determined from histological specimens taken 12 or 16 weeks after laser treatment were  $1338 \pm 53 \mu\text{m}$  ( $n=11$ ) for the experimental glaucoma eyes and  $1407 \pm 47 \mu\text{m}$  ( $n=11$ ) for the control eyes, and there was no significant difference in them ( $p=0.680$ ). Furthermore, the ratio of the disc diameter of the experimental glaucoma eyes to that of the control eyes was estimated from the ratio of the disc area

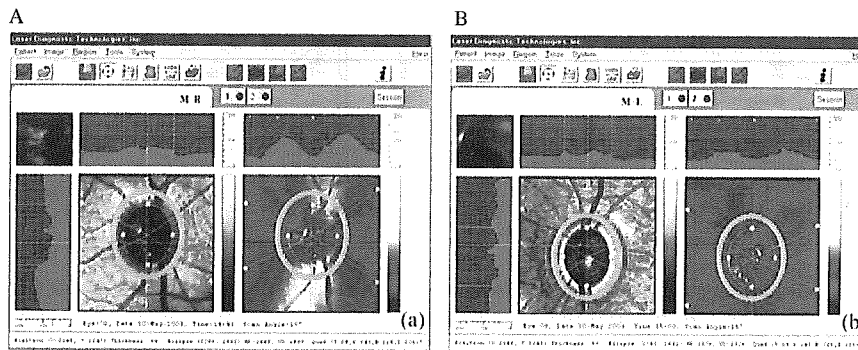


Fig. 7. Mean retardation maps for the right control eye (A) and the left experimental glaucoma eye (B) of a representative monkey (Experiment 1). The maps are colour-coded, light areas indicating high retardation and dark areas low retardation.

Table 2

Polarimetric retardation values for control and experimental glaucoma eyes 12 weeks after the laser treatment (Experiment 1)

	Control eye	Experimental glaucoma eye	% of control	p value
GDx parameters				
Superior	106.0±9.1	84.4±8.4	79.6±5.0	0.119
Temporal	64.2±6.7	60.0±9.8	91.5±5.7	0.734
Inferior	117.3±5.5	89.8±9.0	76.0±5.5	0.031
Nasal	69.6±5.1	66.6±7.9	94.4±4.9	0.757
S+I	223.3±14.3	174.3±17.3	77.6±4.7	0.060
RaSN	1.52±0.05	1.28±0.05	84.7±4.9	0.007
RaIN	1.70±0.07	1.36±0.04	80.5±4.0	0.004
Ra(SN+IN)	3.22±0.10	2.64±0.09	82.3±3.7	0.002
Histological mean RNFL thickness				
Superior	183.3±22.8	64.7±10.6	38.1±7.7	0.002
Inferior	210.0±26.3	62.6±13.0	32.1±8.5	0.001

Data are expressed as mean ± SE for five animals. % of control, value for left (experimental glaucoma) eye as a percentage of that for right (control) eye in same animal. RNFL indicates retinal nerve fibre layer. GDx parameters (Superior, mean thickness parameter in superior quadrant. Temporal, mean thickness parameter in temporal quadrant. Inferior, mean thickness parameter in inferior quadrant. Nasal, mean thickness parameter in nasal quadrant. S+I, sum of superior and inferior thickness parameters. RaSN, ratio of superior quadrant to nasal quadrant. RaIN, ratio of inferior quadrant to nasal quadrant. Ra(SN+IN), sum of RaSN and RaIN, histological mean RNFL thickness (µm) (Superior, histological mean thickness in superior quadrant 1.5 disc diameters away from the outer edge of the optic disc rim. Inferior, histological mean thickness in inferior quadrant 1.5 disc diameter away from the outer edge of the optic disc rim).

measured using the HRT before laser treatment and after 12 weeks in Experiment 1 and 16 weeks in Experiment 2. The ratio of the disc diameter thus estimated agreed well with that obtained from histological specimens and showed little

difference between before and after laser treatment for all 10 eyes except for one eye in Experiment 2, where the HRT parameters could not be obtained at 16 weeks because of the corneal opacity.

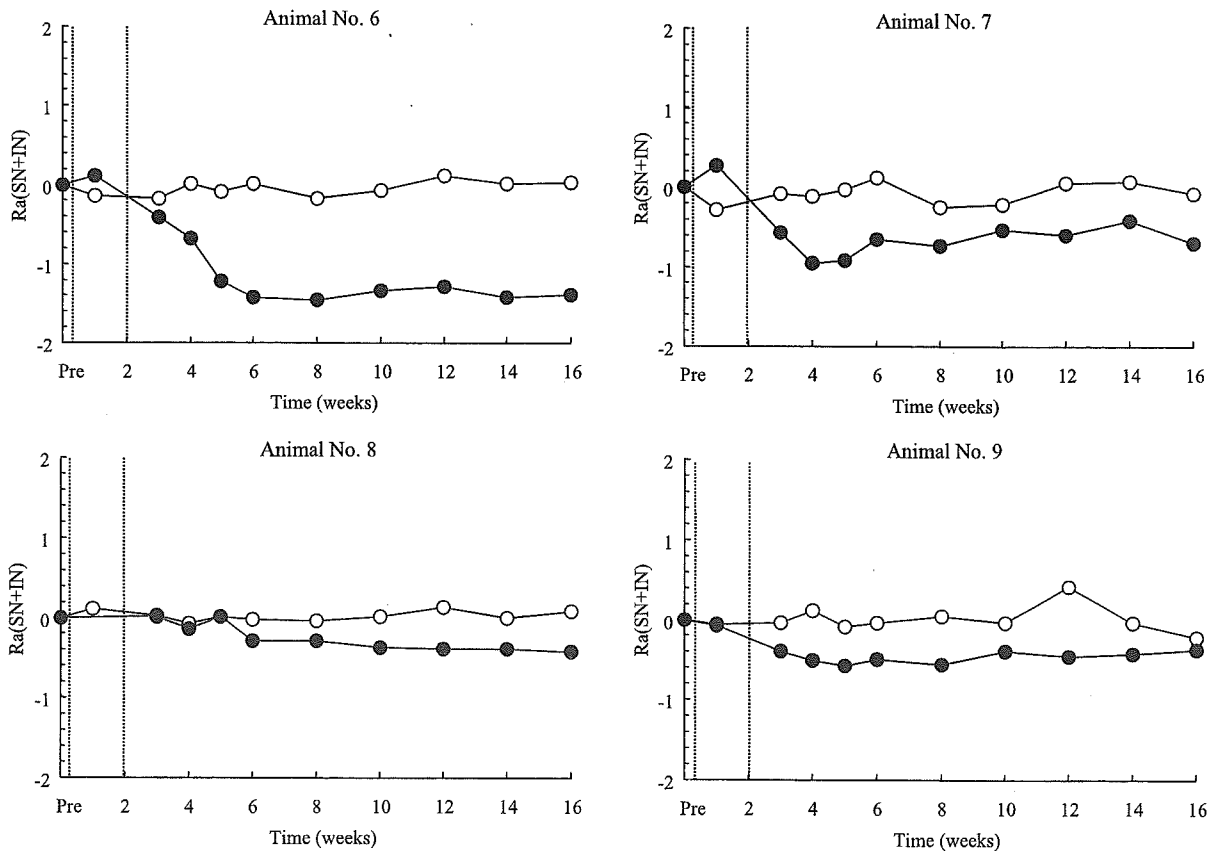


Fig. 8. Time-course of changes in Ra(SN+IN) in individual eyes (animals Nos. 6–11) measured using a GDx FCC in Experiment 2. Left experimental glaucoma eye, filled circle; right control eye, open circle. During the time course of changes, baseline values in each eye were taken as the average of three measurements made at 1-week intervals before the laser treatment. The changes from the baseline in each eye were plotted as delta values. One eye from animal No. 11 showed corneal clouding at 16 weeks after laser irradiation, and was excluded from our data Ra(SN+IN), sum of RaSN and RaIN, where RaIN and RaSN are ratio of superior quadrant to nasal quadrant and ratio of inferior quadrant to nasal quadrant, respectively.

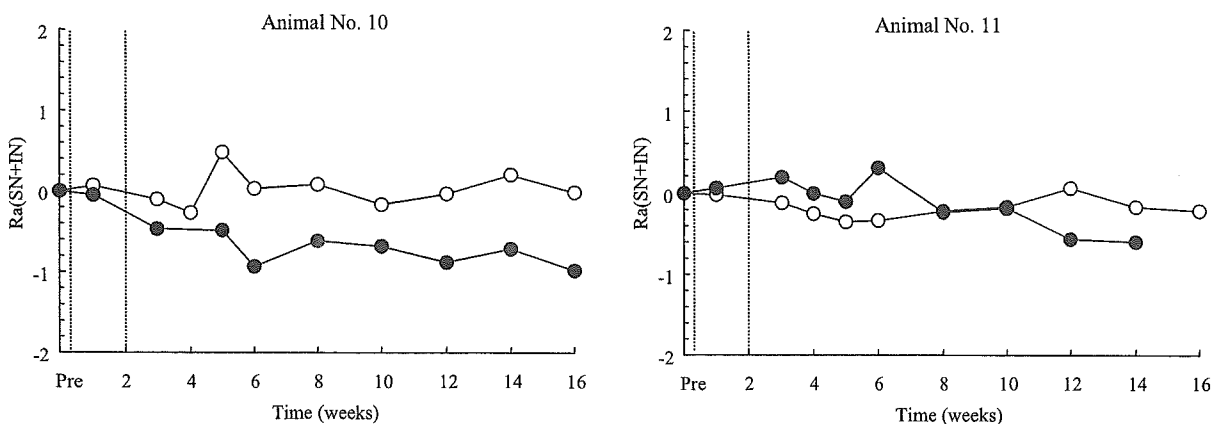


Fig. 8 (continued)

3.6. Correlations between GDx parameters and histological RNFL thickness for the control eyes in Experiment 1

Correlation coefficients between the GDx parameters and RNFL thickness values obtained from histological specimens in Experiment 1 were calculated for the

superior and inferior quadrants of each control eye from 1.5 to 2.1 disc diameters in 0.1 disc-diameter increments away from the outer edge of the optic disc rim (Table 3). For each of right control eye, the thickness parameter for the inferior quadrant as well as the RaIN and Ra(SN+IN) showed significant and high correlations with the

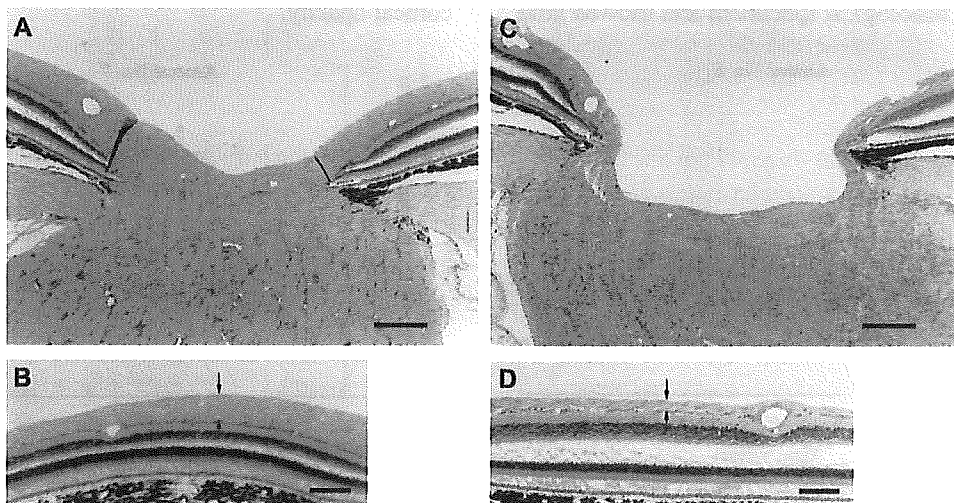


Fig. 9. Histological sections of left experimental glaucoma (C and D) and right control eyes (A and B) (Experiment 1). (A) Histological section of optic nerve head (ONH) shows normal morphology. (C) Histological section of ONH shows marked atrophy with deep cupping of the optic disc. Distance between arrows in B and D shows thickness of retinal nerve fibre layer. Each scale bar indicates 200  $\mu$ m.

Table 3

Pearson correlation coefficients between GDx parameters and values for RNFL thickness obtained from histological specimens of control eyes (Experiment 1)

Monkey No.	Superior	Inferior	S+I	RaSN	RaIN	Ra(SN+IN)
1	0.884 (0.019)	0.919 (0.003)	0.980 (<0.001)	0.902 (0.014)	0.969 (<0.001)	0.994 (<0.001)
2	0.881 (<0.001)	0.848 (0.016)	0.899 (0.006)	0.910 (0.004)	0.946 (0.001)	0.958 (<0.001)
3	-0.712 (0.073)	0.772 (0.042)	-0.500 (0.253)	0.668 (0.101)	0.912 (0.004)	0.851 (0.015)
4	0.960 (<0.001)	0.986 (<0.001)	0.986 (<0.001)	0.923 (0.003)	0.993 (<0.001)	0.979 (<0.001)
5	0.953 (<0.001)	0.971 (<0.001)	0.992 (<0.001)	0.988 (<0.001)	0.967 (<0.001)	0.992 (<0.001)

Values are given as the Pearson correlation coefficient for each control eye from five monkeys (*p* value). The GDx parameters and the values for RNFL thickness from histological specimens were measured at seven sites located between 1.5 and 2.1 disc diameters (in 0.1 disc-diameter increments) away from the outer edge of the optic disc rim, and their correlations were analysed. RNFL indicates retinal nerve fibre layer. Superior, mean thickness parameter in superior quadrant. Inferior, mean thickness parameter in inferior quadrant. S+I, sum of superior and inferior thickness parameters. RaSN, ratio of superior quadrant to nasal quadrant. RaIN, ratio of inferior quadrant to nasal quadrant. Ra(SN+IN), sum of RaSN and RaIN.

Table 4

Pearson correlation coefficients between HRT parameters and histological RNFL thickness at 1.5 disc diameters from the edge of the optic disc (Experiments 1 and 2)

Optic disc topographic parameters	Histological mean RNFL thickness	<i>p</i> value
Disc area	−0.216	0.347
Rim area	0.865	<0.001
Cup volume	−0.822	<0.001
Rim volume	0.871	<0.001
Mean cup depth	−0.833	<0.001
Cup shape measure	−0.856	<0.001
Height variation contour	0.850	<0.001
Mean RNFL thickness	0.812	<0.001

Values are given as the Pearson correlation coefficient (for 21 eyes from 11 monkeys). RNFL indicates the retinal nerve fibre layer.

histological RNFL thickness. On the other hand, the thickness parameter for the superior quadrant along with the S+I and RaSN did not show significant correlations with the histological RNFL thickness for one of the five eyes (animal No. 3), although they did for the other four. The same analysis was also tried for each of left experimental glaucoma eyes. However, the histological RNFL thickness and GDx parameters values obtained as above were all similar at all measurement sites in each eye because of severe glaucomatous damage and consequently correlation analyses in these eyes were abandoned.

### 3.7. Correlations between HRT parameters and histological RNFL thickness

Data obtained from 21 eyes of 11 monkeys in Experiments 1 and 2 were used for this analysis. Pearson's correlation coefficients between the HRT parameters and the histological mean RNFL thickness 1.5-disc diameters away from the edge of the optic disc are shown in Table 4 and Fig. 10. All HRT parameters except for the disc area showed highly significant correlations with the histological mean RNFL thickness. In particular, the rim area ( $r=0.865$ )

and rim volume ( $r=0.871$ ) showed higher correlations with the histological mean RNFL thickness than did the other parameters.

### 3.8. Correlations between HRT and GDx parameters

Pearson's correlation coefficients between the HRT and GDx parameters are shown in Table 5. There were 11 statistically significant correlations among the 16 parameter-pairs, between all optic topographic parameters except for the disc area and the thickness parameter (S+I) or ratio parameter [Ra(SN+IN)]. In particular, the ratio parameter showed higher correlations with the HRT parameters than did the thickness parameter.

## 4. Discussion

In this study, we used a scanning laser ophthalmoscope (Heidelberg Retina Tomograph: HRT) and a scanning laser polarimeter with a fixed corneal polarization compensator (GDx FCC) to examine the time course of changes in optic disc topography and in the thickness of the retinal nerve fibre layer (RNFL) that occurred in laser-induced experimental glaucoma monkeys. An increase in the IOP occurred early in the observation period and persisted for at least 12 or 16 weeks following laser application to the trabecular meshwork of the left eye of each monkey. Alongside this high elevation, there was a pronounced cupping of the optic nerve head and peripapillary choroidal atrophy as previously reported (Pederson and Gaasterland, 1984; Fukuchi et al., 1992; Quigley and Pease, 1996; Jonas and Hayreh, 1999). In the present study, the mean IOP was  $35.4 \pm 2.5$  mmHg in the experimental glaucoma eyes versus  $17.9 \pm 1.3$  mmHg in the control eyes and  $43.2 \pm 3.8$  mmHg in the experimental glaucoma eyes versus  $18.9 \pm 1.1$  mmHg in the control eyes for Experiments 1 and 2, respectively. The elevated IOP level was never higher than those noted in other previous studies (Burgoyne et al, 1995, 2002; Quigley and Pease, 1996; Harwerth et al., 1997; Weber et al., 1998;

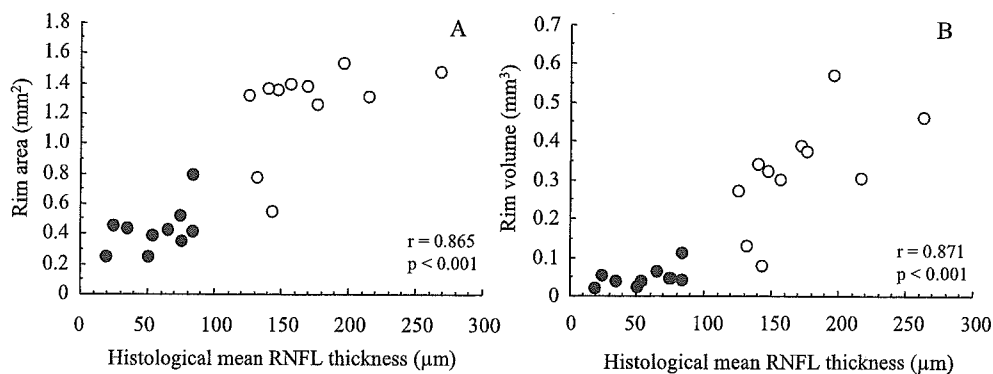


Fig. 10. Representative plots of histological mean RNFL thickness (at 1.5 disc diameters away from the edge of the optic nerve head) against the rim area (A) and rim volume (B) as measured using the HRT in 21 eyes from 11 monkeys (Experiments 1 and 2). Open and closed circles show data for right control and left experimental glaucoma eyes, respectively.

Table 5  
Pearson correlation coefficients between HRT and GDx parameters at 1.5 disc diameters from the edge of the optic disc (Experiments 1 and 2)

Optic disc topographic parameters	RNFL polarimetric parameters			
	S+I	p value	Ra(SN+IN)	p value
Disc area	0.242	0.290	-0.167	0.469
Rim area	0.551	0.010	0.842	<0.001
Cup volume	-0.325	0.150	-0.786	<0.001
Rim volume	0.498	0.022	0.777	<0.001
Mean cup depth	-0.376	0.094	-0.782	<0.001
Cup shape measure	-0.362	0.107	-0.848	<0.001
Height variation contour	0.486	0.026	0.796	<0.001
Mean RNFL thickness	0.454	0.039	0.761	<0.001

Values are given as the Pearson correlation coefficient (for 21 eyes from 11 monkeys). RNFL indicates retinal nerve fibre layer. S+I, sum of superior and inferior thickness parameters. Ra(SN+IN), sum of RaSN and RaIN. RaSN, ratio of superior quadrant to nasal quadrant. RaIN, ratio of inferior quadrant to nasal quadrant.

Yücel et al.; 1998, 1999, 2001; Hayreh et al., 1999) and it was rather lower in Experiment 1. For example, Yücel et al. (1998) reported  $39 \pm 14$  mmHg in the experimental glaucoma eyes, Burgoyne et al. (1995, 2002) reported 22–60 or 4–59 mmHg and Weber et al. (1998) reported  $48 \pm 15$  mmHg in the experimental glaucoma eyes.

For the HRT measurements, seven out of eight global optic disc parameters, the disc area being the exception, showed significant differences between the experimental glaucoma and control eyes. These results are consistent with a previous report by Yücel et al. (1998), in which topographic changes were detected in experimental glaucoma cynomolgus monkey eyes 10 months after laser treatment, and in which all HRT parameters except for the disc area showed a good correlation with the number of optic nerve axons. In the present study, changes in the HRT parameters rapidly occurred during the first 4 weeks after the laser treatment, with little change being observed thereafter. Several groups have reported longitudinal changes in the optic disc surface in experimental glaucoma monkeys (Pederson and Gaasterland, 1984; Shirakashi et al., 1992; Burgoyne et al., 1995, 2002; Quigley and Pease, 1996). Burgoyne et al. (2002) evaluated ONH surface changes in the laser-induced experimental glaucoma monkeys using confocal scanning laser tomography (TopSS), and found that clinically specific detection of the onset and progression of ONH surface changes was possible for each eye. They artificially adjusted the IOP to 10 mmHg to avoid any ONH surface changes not being attributed to histological damage but to tissue compliance when the ONH images were acquired. Another publication from this group (Burgoyne et al., 1995) reported that optic disc compliance

was increased 1–2 weeks after the IOP elevation in laser-induced experimental glaucoma monkeys. They assumed that early changes in the optic disc surface were unlikely to be due to axon loss alone, but rather to compliance of the load-bearing connective tissues of ONH, and that late anteriorization detected in the chronic phase might be indicative of histological change. In the present study, changes in the ONH surface were detected 2 weeks after laser-treatment using HRT. Since we acquired the ONH images without IOP adjustment, the ONH surface changes could have been at least partly due to tissue compliance. Although late anteriorization is caused by lowering the reference plane for ONH structure analysis (Burgoyne et al., 2002), it was not observed here even in the monkey's eye that showed severe damage in the histological RNFL thickness. These discrepancies may be due to differences in the setting of the reference plane. We used 50  $\mu$ m posterior to the mean of the contour line heights between 350 and 356° on the contour line as a standard reference plane (HRT software ver. 2.01; Heidelberg Engineering) (Vihanninjoki et al., 2002). This area of the segment height is the lowest and is relatively stable until the late stage of glaucoma (Asawaphureekorn et al., 1996; Burk et al., 2000). On the other hand, Burgoyne et al. (2002) used as a reference plane 150  $\mu$ m posterior to the average magnitude of all elevation values outside the disc margin. This reference plane may be changed by thinning of the retina caused by a high IOP.

In this study, there was no significant difference in the vertical optic diameters measured in the histological specimens 12 and 16 weeks after the laser treatment between the experimental glaucoma and control eyes. Furthermore, the ratio of the disc diameter of experimental glaucoma eyes to that of the control eyes was estimated from the ratio of the disc area measured with HRT before laser treatment and after 12 weeks in Experiment 1 and 16 weeks in Experiment 2. The ratio of the disc diameter estimated after 12 or 16 weeks agreed well with that obtained for the histological specimens and showed little difference between before and after laser treatment for all examined eyes. These results are consistent with those obtained using the HRT, in which any changes in the disc area from the baseline were not observed at any post-laser time point. Similar results have been reported in previous studies using cynomolgus monkeys (Derick et al., 1994; Yücel et al., 1998). In contrast, Bellezza et al. (2003) found that the optic disc diameters measured for the histological specimens were enlarged in experimental glaucoma monkey's eyes between 4 and 15 weeks after the IOP elevation where normal fellow eyes ranged from 8 to 11 mmHg versus the high-experimental glaucoma eyes which ranged from 19 to 47 mmHg. They concluded that damage to the ONH connective tissues occurred early in young adult monkey eyes with the experimental glaucoma. Although we do not have a good explanation for this discrepancy, it may be partly due to differences in the



monkey species and age. We used 11 male cynomolgus monkeys aged between 5 and 6 years, and Derick et al. (1994) and Yücel et al. (1998) also used cynomolgus monkeys of unknown age, while more than half of the monkeys used by Bellezza et al. (2003) were rhesus monkeys aged between 6 and 11 years. We have observed a marked difference in the extent of IOP elevation or disc change after laser treatment in monkeys with different birthplaces or ages.

Together with the HRT results, we evaluated changes in the RNFL thickness using a GDx FCC, a nerve fibre analyser, which theoretically has less compliance than the ONH structure. The GDx device is a scanning laser polarimeter designed to measure the shift in polarization caused by the birefringence of RNFL tissue. In living eyes, however, there are two other birefringent structures, the cornea, and to a much smaller extent the lens. Recently, Weinreb et al. (2002) reported that there were individual differences in corneal birefringency using a prototype, modified GDx-N with fixed corneal polarization compensator in three cynomolgus monkeys (six eyes including two eyes with experimental glaucoma (two monkeys)). We also measured the macular in six monkeys (12 eyes) before laser irradiation, and confirmed that there were marked individual differences in corneal birefringency in monkeys. The use of GDx with variable corneal polarization compensator (GDx VCC) for the automatic correction of corneal refraction, which has recently become commercially available for clinical use, should facilitate more accurate evaluation of RNFL thickness as absolute values. However, as commercially available GDx VCC is an automatic-type product, it may not be directly applied in monkeys and was not commercially available when we planned the current experiment. Furthermore, the GDx VCC that Weinreb et al. used was a prototype, modified GDx-N for special use, and could not be generally utilized. Therefore, we used GDx FCC in the current study.

In Experiment 1, obvious changes in fundus photography and in the histological mean RNFL thickness of the superior and inferior quadrants 1.5 disc diameters away from the edge of the optic disc were seen in the experimental glaucoma eyes. However, the mean of the GDx thickness parameters for these eyes were significantly different from those of the control eyes only in the inferior and not superior, nasal or temporal quadrants. The reason for these discrepancies is probably variations in the corneal polarization axis among monkey eyes. On the other hand, the ratio parameters [RaSN, RaIN, and Ra(SN+IN)] were significantly decreased in the experimental glaucoma eyes compared to the control eyes, suggesting that these parameters may still partly represent the true change in the RNFL thickness being less affected by variations in the corneal polarization axis.

When we examined correlations between the histological mean RNFL thickness and GDx parameters obtained from the same quadrant of the same control eye (Table 3), we

found good, significant correlations for five out of five eyes tested in the case of the inferior thickness parameter, RaIN and Ra(SN+IN), and for four of five eyes in the case of the superior thickness parameter, S+I and RaSN (Table 3). These findings warranted a comparison of the changes with time in some of the GDx FCC parameters, as long as they are obtained from the same quadrant of the same monkey eye. Accordingly, we used Ra(SN+IN), which showed a good correlation with the histological RNFL thickness in individual eyes, for comparison of the changes with time in Experiment 2 and plotted the change from the baseline values in individual eyes. As shown in Fig. 8, the Ra(SN+IN) decreased alongside the IOP elevation, almost plateauing 8 weeks after the laser treatment.

As mentioned above, changes in the HRT parameters rapidly occurred during the first 4 weeks after the laser treatment, with little change being observed thereafter. This time lag may be partly attributed to the compliance of the optic disc, which is responsible for the changes in the HRT parameters detected earlier. GDx measures the RNFL thickness based on birefringence properties of its microtubules. Even if some changes in the thickness of the RNFL were induced by its compression due to an elevated IOP, retardation values would change little without a change in the number of microtubules. Thus, it seems that changes in the measured Ra(SN+IN) value from the baseline represented the histological loss of retinal nerve fibres. Although HRT parameters showed rapid changes during the first 4 weeks, there was little change during observation period between 4 and 16 weeks. However, we do not think the change stopped further progressing after 4 weeks. It should slowly and gradually go on after that, which could not be detected by HRT in 16-week period. If the experiment was carried out for 1 year, we would be able to detect further deterioration of HRT parameters.

Taken together with the results obtained with the HRT, histological ONH and RNFL changes caused by laser-induced IOP elevation are thought to be evident as early as 8 weeks in monkey eyes after the last laser treatment, at least under the present experimental conditions.

When we evaluated the correlation coefficients between the HRT parameters and histological mean RNFL thickness or GDx parameters [S+I and Ra(SN+IN)] 1.5 disc diameters away from the edge of the optic disc, we found that all HRT parameters except the disc area showed high and significant correlations with the histological mean RNFL thickness and the GDx ratio parameter [Ra(SN+IN)]. These findings confirm that the rim area and volume adequately reflect the histological RNFL thickness and that changes in the above GDx parameters also reflected the extent of ONH damage.

In conclusion, for laser-treated cynomolgus monkey eyes, we used HRT and GDx FCC to examine the time course of changes in optic disc topography and the RNFL thickness that occur alongside induced elevated IOP. Most of the changes in the ONH and RNFL took place within 8

weeks, and the HRT parameters except the disc area 12 weeks or later showed good correlations with the histological RNFL thickness.

## Acknowledgements

The authors thank Mr Fumio Nakazawa of Glaucoma Group, Research and Development Center, and Mr Tateki Goto of Biostatistics and Data Management Team, Clinical Development Center, Santen Pharmaceutical Co. Ltd for technical advice and statistical advice, respectively.

## References

- Asawaphureekorn, S., Zangwill, L., Weinreb, R.N., 1996. Ranked-segment distribution curve for interpretation of optic nerve topography. *J. Glaucoma* 5, 79–90.
- Bellezza, A.J., Rintalan, C.J., Thompson, H.W., Downs, J.C., Hart, R.T., Burgoyne, C.F., 2003. Deformation of the lamina cribrosa and anterior scleral canal wall in early experimental glaucoma. *Invest. Ophthalmol. Vis. Sci.* 44, 623–637.
- Burgoyne, C.F., Quigley, H.A., Thompson, H.W., Vitale, S., Varma, R., 1995. Early changes in optic disc compliance and surface position in experimental glaucoma. *Ophthalmology* 102, 1800–1809.
- Burgoyne, C.F., Mercante, D.E., Thompson, H.W., 2002. Change detection in regional and volumetric disc parameters using longitudinal confocal scanning laser tomography. *Ophthalmology* 109, 455–466.
- Burk, R.O., Vihanninjoki, K., Bartke, T., Tuulonen, A., Airaksinen, P.J., Volcker, H.E., Konig, J.M., 2000. Development of the standard reference plane for the Heidelberg retina tomograph. *Graefes Arch. Clin. Exp. Ophthalmol.* 238, 375–384.
- Chen, Y.Y., Chen, P.P., Xu, L., Ernst, P.K., Wang, L., Mills, R.P., 1998. Correlation of peripapillary nerve fiber layer thickness by scanning laser polarimetry with visual field defects in patients with glaucoma. *J. Glaucoma* 7, 312–316.
- Derick, R.J., Pasquale, L.R., Pease, M.E., Quigley, H.A., 1994. A clinical study of peripapillary crescents of the optic disc in chronic experimental glaucoma in monkey eyes. *Arch. Ophthalmol.* 112, 846–850.
- Essock, E.A., Sinai, M.J., Fechtner, R.D., Srinivasan, N., Bryant, F.D., 2000. Fourier analysis of nerve fiber layer measurements from scanning laser polarimetry in glaucoma: emphasizing shape characteristics of the 'double-hump' pattern. *J. Glaucoma* 9, 444–452.
- Fukuchi, T., Sawaguchi, S., Hara, H., Shirakashi, M., Iwata, K., 1992. Extracellular matrix changes of the optic nerve lamina cribrosa in monkey eyes with experimentally chronic glaucoma. *Graefes Arch. Clin. Exp. Ophthalmol.* 230, 421–427.
- Harwerth, R.S., Smith III, E.L., DeSantis, L., 1997. Experimental glaucoma: perimetric field defects and intraocular pressure. *J. Glaucoma* 6, 390–401.
- Hayreh, S.S., Pe'er, J., Zimmerman, M.B., 1999. Morphologic changes in chronic high-pressure experimental glaucoma in rhesus monkeys. *J. Glaucoma* 8, 56–71.
- Iester, M., Mikelberg, F.S., Courtright, P., Drance, S.M., 1997. Correlation between the visual field indices and Heidelberg retina tomograph parameters. *J. Glaucoma* 6, 78–82.
- Jonas, J.B., Hayreh, S.S., 1999. Localised retinal nerve fibre layer defects in chronic experimental high pressure glaucoma in rhesus monkeys. *Br. J. Ophthalmol.* 83, 1291–1295.
- Malinovsky, V.E., 1996. An overview of the heidelberg retina tomograph. *J. Am. Optom. Assoc.* 67, 457–467.
- Morgan, J.E., Waldock, A., Jeffery, G., Cowey, A., 1998. Retinal nerve fibre layer polarimetry: histological and clinical comparison. *Br. J. Ophthalmol.* 82, 684–690.
- Pederson, J.E., Gaasterland, D.E., 1984. Laser-induced primate glaucoma. I. Progression of cupping. *Arch. Ophthalmol.* 102, 1689–1692.
- Quigley, H.A., Hohman, R.M., 1983. Laser energy levels for trabecular meshwork damage in the primate eye. *Invest. Ophthalmol. Vis. Sci.* 24, 1305–1307.
- Quigley, H.A., Pease, M.E., 1996. Change in the optic disc and nerve fiber layer estimated with the glaucoma-scope in monkey eyes. *J. Glaucoma* 5, 106–116.
- Shirakashi, M., Nanba, K., Iwata, K., 1992. Changes in reversal of cupping in experimental glaucoma. Longitudinal study. *Ophthalmology* 99, 1104–1110.
- Vihanninjoki, K., Burk, R.O., Teesalu, P., Tuulonen, A., Airaksinen, P.J., 2002. Optic disc biomorphometry with the heidelberg retina tomograph at different reference levels. *Acta Ophthalmol. Scand.* 80, 47–53.
- Weber, A.J., Kaufman, P.L., Hubbard, W.C., 1998. Morphology of single ganglion cells in the glaucomatous primate retina. *Invest. Ophthalmol. Vis. Sci.* 39, 2304–2320.
- Weinreb, R.N., Dreher, A.W., Coleman, A., Quigley, H., Shaw, B., Reiter, K., 1990. Histopathologic validation of Fourier-ellipsometry measurements of retinal nerve fiber layer thickness. *Arch. Ophthalmol.* 108, 557–560.
- Weinreb, R.N., Lusky, M., Bartsch, D.U., Morsman, D., 1993. Effect of repetitive imaging on topographic measurements of the optic nerve head. *Arch. Ophthalmol.* 111, 636–638.
- Weinreb, R.N., Shakiba, S., Zangwill, L., 1995a. Scanning laser polarimetry to measure the nerve fiber layer of normal and glaucomatous eyes. *Am. J. Ophthalmol.* 119, 627–636.
- Weinreb, R.N., Shakiba, S., Sample, P.A., Shahrokni, S., van Horn, S., Garden, V.S., Asawaphureekorn, S., Zangwill, L., 1995b. Association between quantitative nerve fiber layer measurement and visual field loss in glaucoma. *Am. J. Ophthalmol.* 120, 732–738.
- Weinreb, R.N., Bowd, C., Zangwill, L.M., 2002. Scanning laser polarimetry in monkey eyes using variable corneal polarization compensation. *J. Glaucoma* 11, 378–384.
- Wollstein, G., Garway-Heath, D.F., Fontana, L., Hitchings, R.A., 2000. Identifying early glaucomatous changes: comparison between expert clinical assessment of optic disc photographs and confocal scanning ophthalmoscopy. *Ophthalmology* 107, 2272–2277.
- Xu, L., Chen, P.P., Chen, Y.Y., Takahashi, Y., Wang, L., Mills, R.P., 1998. Quantitative nerve fiber layer measurement using scanning laser polarimetry and modulation parameters in the detection of glaucoma. *J. Glaucoma* 7, 270–277.
- Yücel, Y.H., Gupta, N., Kalichman, M.W., Mizisin, A.P., Hare, W., de Souza Lima, M., Zangwill, L., Weinreb, R.N., 1998. Relationship of optic disc topography to optic nerve fiber number in glaucoma. *Arch. Ophthalmol.* 116, 493–497.
- Yücel, Y.H., Kalichman, M.W., Mizisin, A.P., Powell, H.C., Weinreb, R.N., 1999. Histomorphometric analysis of optic nerve changes in experimental glaucoma. *J. Glaucoma* 8, 38–45.
- Yücel, Y.H., Zhang, Q., Weinreb, R.N., Kaufman, P.L., Gupta, N., 2001. Atrophy of relay neurons in magno- and parvocellular layers in the lateral geniculate nucleus in experimental glaucoma. *Invest. Ophthalmol. Vis. Sci.* 42, 3216–3222.

## EXTENDED REPORT

# Optic disc topographic parameters measured in the normal cynomolgus monkey by confocal scanning laser tomography

T Taniguchi, M Shimazawa, M Araie, G Tomita, M Sasaoka, Y Kitazawa, H Hara

*Br J Ophthalmol* 2005;89:1058-1062. doi: 10.1136/bjo.2004.062513

See end of article for authors' affiliations

Correspondence to: Hideaki Hara, PhD, Department of Biofunctional Molecules, Gifu Pharmaceutical University, 5-6-1 Mitahara-higashi, Gifu 502-8585, Japan; hidehara@gifu-pu.ac.jp

Accepted for publication 1 February 2005

**Aim:** To study optic disc topographic parameters in normal cynomolgus monkeys by Heidelberg retina tomograph (HRT).

**Methods:** 12 optic disc topographic parameters were investigated in 36 normal eyes in 18 male monkeys. Mean (SD) and interocular differences were obtained for each parameter from three independent measurements made during a 1 week period. Correlations among the topographic parameters were analysed, too.

**Results:** No significant differences between right and left eyes were detected for any topographic parameters. Disc area, rim area, and height variation contour showed smaller right-left differences than other parameters. The coefficients of variation for rim area, height variation contour, rim volume, mean cup depth, maximum cup depth, mean retinal nerve fibre layer (RNFL) thickness, and RNFL cross section area were less than 10% (for rim area, less than 5%). Rim area and height variation contour showed relatively weak interrelations and neither showed a correlation with disc area.

**Conclusion:** For evaluating time related changes in the optic disc by HRT in monkeys, rim area and height variation contour might be useful parameters because coefficients of variation and right-left differences were lower than for other parameters and because these parameters showed weak interrelations and no correlation with disc area.

In cynomolgus and rhesus monkeys, the optic nerve head (ONH) resembles the human ONH in appearance and the pathophysiological changes that occur in experimental glaucoma resemble those in patients with glaucoma.<sup>1-4</sup> Hence, the monkey eye is a useful model for the study of glaucoma. Half the 30 or so reports on ONH morphology in monkeys have noted ONH changes in experimental glaucoma in cynomolgus or rhesus monkeys. Many ONH studies in glaucomatous monkeys have employed in traditional methodologies, such as fundus photography and histological analysis, and have revealed enlargement of the optic disc cup, localised retinal nerve fibre defects, and selective loss of ganglion cells with thinning of the nerve fibre layer in experimental glaucoma eyes.<sup>1-9</sup> On the other hand, Jonas and colleagues<sup>10</sup> used fundus photographs to evaluate the normal optic disc as a prerequisite for a proper understanding of experimentally induced optic nerve changes such as those associated with glaucomatous damage in rhesus monkeys. However, these methods do not provide a full quantitative evaluation because optic disc parameters obtained from fundus photographs are usually expressed in relative terms and, moreover, histological comparisons may be affected by tissue shrinkage.<sup>1-10</sup> In the clinical assessment of the optic disc from fundus photographs it is difficult to be objective; indeed, results vary particularly between different observers, even if they have adequate experience.<sup>11</sup> Furthermore, two dimensional analysis from fundus photographs may be unable to detect subtle changes in the progression of glaucoma, because glaucomatous changes in the optic disc are three dimensional.

By contrast, confocal scanning laser tomography allows us to obtain three dimensional images of the human optic disc.<sup>12-13</sup> This device has been used to make quantitative, objective measurements of ONH structures in humans with reasonable reproducibility and potential advantages over

other techniques.<sup>12-17</sup> Recently, this method has been used to study ONH structure in monkeys.<sup>18-22</sup> The monkey ONH was studied using a computerised digital image analyser, rather than confocal scanning laser tomography.<sup>23-26</sup> HRT (Heidelberg retina tomograph, Heidelberg Engineering), which operates on tomographic principles, is the most widely used optic nerve imaging tool in glaucoma clinics.<sup>12-14-17</sup> Yücel and colleagues<sup>21</sup> reported quantitative differences in the optic disc topographic parameters measured using HRT between the control fellow and experimental glaucoma eyes in cynomolgus monkeys. However, for a proper study of ONH changes in cynomolgus monkeys using HRT it is necessary to know the reproducibility of the measurements and also the variation in HRT parameters between individual normal monkeys. Further, the information about interocular differences (right-left differences) in normal monkeys is essential to use the fellow eye as a control for the experimental glaucoma eye. To our knowledge, however, appropriate data have yet to be published. We examined (a) the reproducibility of HRT measurements in a total of 36 eyes in 18 normal monkeys, (b) the interindividual variability and the right-left differences in each parameter, and (c) correlations among HRT parameters.

## MATERIALS AND METHODS

### Animals

Eighteen normal male cynomolgus monkeys (*Macaca fascicularis*) aged between 4.0 years and 5.5 years, weighing 4.0-

**Abbreviations:** CA, cup area; C/D, cup/disc area ratio; CSM, cup shape measure; CV, cup volume; DA, disc area; HRT, Heidelberg retina tomograph; HVC, height variation contour; IOP, intraocular pressure; MnCD, mean cup depth; MnRNFLT, mean RNFL thickness; MxCD, maximum cup depth; ONH, optic nerve head; RA, rim area; RCSA, RNFL cross section area; RNFL, retinal nerve fibre layer; RV, rim volume

5.0 kg were used. None of the eyes had been used in any other experiment, undergone any surgical procedure, or received any medical treatment. Monkeys were housed in an air conditioned room (24°C (SD 2°C), 60% (10%) humidity) and allowed food and water ad libitum. All investigations were in accordance with the ARVO statement for the use of animals in ophthalmic and vision research.

### Experimental protocol

Intraocular pressure (IOP) was measured using a calibrated pneumatonometer under ketamine anaesthesia (8.75–10 mg/kg, intramuscular: im), with local anaesthesia before any optic disc topographic images were taken. Optic disc topographic parameters were analysed using HRT (Heidelberg Engineering, Heidelberg, Germany) under ketamine (8.75–10 mg/kg, im) plus xylazine (0.5 mg/kg, im) anaesthesia. Before topographic image acquisition, the refractive index and corneal curvature radius were measured in each eye, then entered into the patient data submenu for the examined eye to allow correction of magnification effects on the images. The SD, which indicates the precision of the measurement process, was always less than 30 µm. The disc contour line was determined by an experienced operator while viewing fundus photographs. The following 12 optic disc topographic parameters were investigated: disc area (DA), cup area (CA), cup/disc area ratio (C/D), rim area (RA), height variation contour (HVC), cup volume (CV), rim volume (RV), mean cup depth (MnCD), maximum cup depth (MxCD), cup shape measure (CSM), mean retinal nerve fibre layer (RNFL) thickness (MnRNFLT), and RNFL cross section area (RCSA). The position of the reference plane was 50 µm posterior to the mean retinal height between 350 degrees and 356 degrees (temporal) along the operator drawn contour line delineating the optic disc margin. Topographic parameters were obtained three times over a 1 week period as independent measurements. The disc contour line was defined during the first measurement and this definition was transported to the topographic images obtained during the second and three measurements. Right-left differences in topographic parameters were calculated for each animal as the absolute difference between two eyes as previously described.<sup>27</sup> Measurements of HRT parameters and data analysis were each performed by an operator who was masked as to the purpose of this study.

### Statistical analysis

Correlations analyses were assessed using Pearson's correlation test. A Student's *t* test was used to compare topographic parameters between the right and left eyes.

### RESULTS

The fundus photographs showed no obvious retinal lesions, nerve fibre layer defects, or abnormalities of either the ONH or vascular structures in any of the eyes examined (fig 1A). Topographic images of the optic disc were obtained using HRT (figs 1B and 1C). The IOP values (mean (SD) *n* = 18) obtained for the right and left eyes were 20.7 (3.8) mm Hg and 20.0 (3.2) mm Hg, respectively. No statistically

significant correlations were observed between any topographic parameters and IOP (data not shown). The mean data of refraction in right and left eyes are shown in table 1. There was no significant difference between right and left eyes.

The mean (SD) values and right-left differences for each topographic parameter are shown in table 2. No statistically significant differences between the two eyes were found in all topographic parameters. Right-left differences were relatively large (>40% of mean value for right eye) for CA, C/D, and CV but relatively small (about 10% or <10% of mean for right eye) for DA, RA, and HVC. On the basis of data (mean (SD), and sample size) in table 2, we calculated the statistical power for detecting a 20% right-left difference in each parameter using a Student's *t* test. Statistical power was more than 80% for RA, HVC, MnRNFLT, and RCSA. Thus, under our experimental conditions, a statistically significant difference would be detected in several parameters with a fair degree of certainty if the difference between right and left eyes was about 20%.

Seven topographic parameters (RA, HVC, RV, MnCD, MxCD, MnRNFLT, and RCSA) had coefficient of variation less than 10% for both eyes, with the smallest coefficient of variation (<5%) in each eye being shown by RA (table 3). For CA, C/D, CV, and CSM, the coefficient of variation was more than 10% in each eye, with that for CV being the highest (30–40%).

Finally, correlations among HRT parameters were examined (on the basis of the mean of three independent measurements from each eye) using Pearson's correlation coefficient (table 4). CA, C/D, CV, RV, and MnCD displayed relatively strong interrelations (correlation coefficient more than 0.7), with significance being demonstrated for each eye, while DA, RA, HVC, and CSM exhibited relatively weak interrelations.

### DISCUSSION

In this study, we measured optic disc topographic parameters in normal monkey eyes by means of HRT. The mean values obtained for each HRT parameter in the right and left eyes are comparable to those obtained for control fellow eyes in the previous study of experimental glaucoma in cynomolgus monkeys.<sup>21</sup> Moreover, the coefficient of variation for parameters related to the optic disc cup (namely, CA, C/D, CV, and CSM) exceeded 10%, which is compatible with findings reported by others for humans.<sup>28</sup> By contrast, RA, HVC, RV, MnCD, MxCD, MnRNFLT, and RCSA each had coefficient of variation less than 10% for both eyes than those relating to the optic disc cup, suggesting that the values obtained for these parameters may be more reliable in monkeys. The coefficient of variation for RA was particularly low in this study and, interestingly, Tan and colleagues<sup>28</sup> noted that RA was the most reproducible parameter in humans. Previous reports have indicated that RA correlates well with the visual field and the degree of glaucomatous optic disc damage in humans.<sup>15–17</sup> These findings suggest that RA should be suited for the evaluation of glaucomatous changes using HRT in monkey eyes as well as in humans.

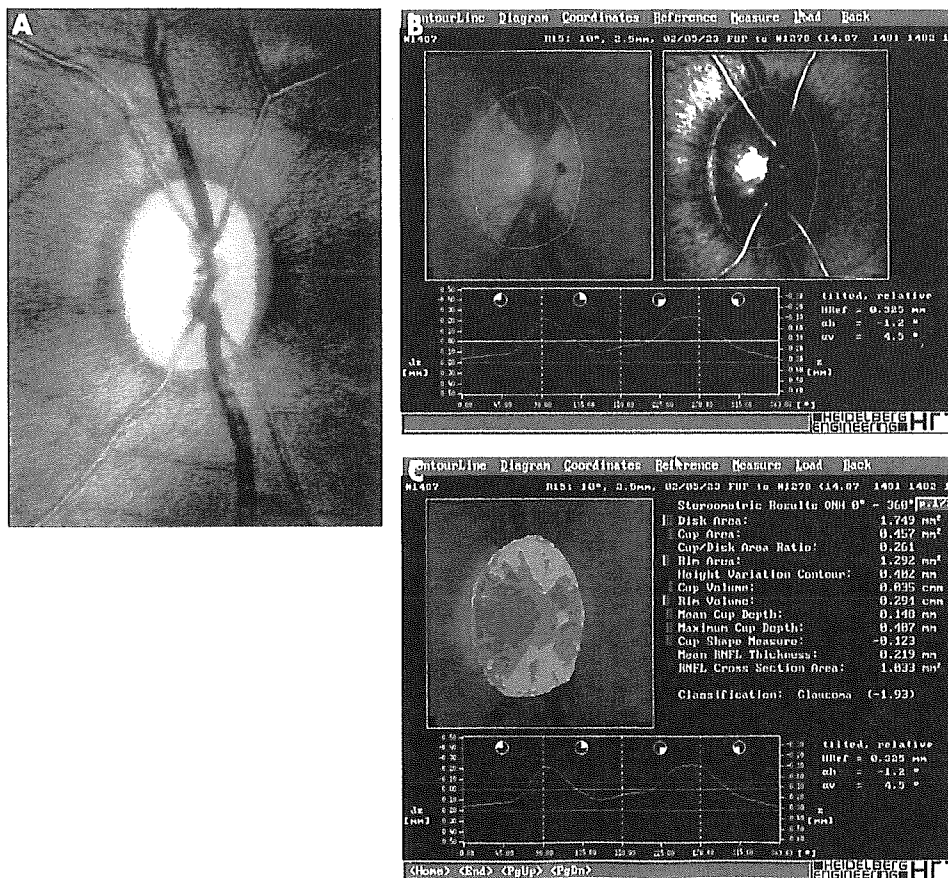
There are two ways to define the disc contour line for evaluating time related changes in HRT parameters. One is to transport the contour line obtained for the base HRT image to subsequent images, the other is to redefine the contour line for each image. Roff *et al* compared the data variability between these two methods.<sup>29</sup> Their results indicated that the use of transport led to a lower data variability than redefinition. When investigating the coefficient of variation, it is desirable to limit data variability, and so in this study we used the transport method to define the disc contour line.

Although previous reports have investigated right-left differences in HRT parameters in healthy human subjects,<sup>30–31</sup>

**Table 1** Refraction in normal cynomolgus monkey eyes

	Right eye	Left eye
	Mean (SD)	Mean (SD)
Refraction (dioptres)	1.01 (1.52)	1.27 (1.45)

No significant difference between right and left eyes.  
Each value represents mean (SD) for 18 eyes.



**Figure 1** Representative fundus photograph and mean topographic images of optic disc obtained from HRT in normal cynomolgus monkey eye. (A) Fundus photograph; (B) mean topographic images; (C) analysis results for topographic parameters.

there have been no such reports in normal monkeys (table 5). RV and MnRNFLT were significantly lower in the left eye.<sup>31</sup> MnRNFLT and RCSA were significantly lower in the right eye.<sup>30</sup> Although the reason for the discrepancy between these two reports is unclear, the age, sex ratio, and sample size were different between the two studies. By contrast, we observed no significant differences in HRT parameters between right and left eyes in monkeys that were all of one sex (male) and from a narrow age range, although the sample size was much smaller than in the previous reports on humans.<sup>30-31</sup> The values we obtained when we expressed right-left differences as a percentage of the mean value obtained for the right eye (R-L difference ratio) were lower (less than 20%) for RA, HVC, RV, MnCD, MxCD, CSM, MnRNFLT, and RCSA than for the other parameters.

Therefore, when evaluating longitudinal changes in HRT parameters in experimental glaucoma eyes (using non-treated fellow eyes as controls), these parameters, especially RA and HVC (each of which had an R-L difference ratio of about 10%), may be suitable parameters. By contrast, for CA, C/D, and CV, R-L difference ratios were greater than 40%, suggesting that these parameters are not suitable for this purpose.

Here, correlations among HRT parameters were investigated using Pearson's correlation coefficient, as described elsewhere.<sup>32-33</sup> CA, C/D, CV, and MnCD showed stronger interrelations than the other parameters, a result compatible with previous findings in normal humans.<sup>32</sup> This supports the optic disc structure of the monkey being comparable to that of humans. HRT parameters are determined following the

**Table 2** Optic disc topographic parameters in normal cynomolgus monkey eyes

Parameters	Right eye		Left eye		Right-left difference		As % of mean value for right eye
	Mean	SD	Mean	SD	Mean	SD	
Disc area (mm <sup>2</sup> )	1.62	0.24	1.62	0.24	0.08	0.06	4.9
Cup area (mm <sup>2</sup> )	0.30	0.29	0.31	0.24	0.14	0.18	46.7
Cup/disc area ratio	0.17	0.15	0.18	0.12	0.08	0.09	47.1
Rim area (mm <sup>2</sup> )	1.32	0.25	1.31	0.13	0.15	0.19	11.4
Height variation contour (mm)	0.40	0.05	0.39	0.05	0.04	0.03	10.0
Cup volume (mm <sup>3</sup> )	0.03	0.05	0.03	0.03	0.02	0.03	66.7
Rim volume (mm <sup>3</sup> )	0.33	0.10	0.31	0.06	0.06	0.07	18.2
Mean cup depth (mm)	0.13	0.05	0.12	0.04	0.02	0.02	15.4
Maximum cup depth (mm)	0.35	0.12	0.34	0.11	0.05	0.02	14.3
Cup shape measure	-0.17	0.06	-0.16	0.06	0.03	0.04	-17.6
Mean RNFL thickness (mm)	0.23	0.04	0.22	0.04	0.04	0.04	17.4
RNFL cross section area (mm <sup>2</sup> )	1.04	0.21	0.97	0.17	0.17	0.19	16.3

No significant differences between right and left eyes.

Each value represents mean (SD) for 18 eyes. RNFL, retinal nerve fibre layer.

Right-left difference was calculated using the absolute difference between right and left eyes for each animal.

**Table 3** Reproducibility of the optic topographic parameters measured using HRT

Parameters	Coefficient of variation			
	Right	SD	Left	SD
Cup area (mm <sup>2</sup> )	23.3	24.8	24.2	28.2
Cup/disc area ratio	23.4	24.9	24.1	28.0
Rim area (mm <sup>2</sup> )	3.4	3.4	3.1	2.3
Height variation contour (mm)	7.0	4.1	7.1	3.8
Cup volume (mm <sup>3</sup> )	30.7	28.7	40.9	47.3
Rim volume (mm <sup>3</sup> )	8.3	4.7	8.0	4.8
Mean cup depth (mm)	7.0	4.1	8.1	7.1
Maximum cup depth (mm)	6.0	4.0	5.8	5.8
Cup shape measure	12.6	6.3	13.1	11.1
Mean RNFL thickness (mm)	7.1	5.3	7.2	4.2
RNFL cross section area (mm <sup>2</sup> )	7.1	5.3	7.1	4.2

Coefficient of variation was obtained from measurement at three times over a 1 week period.  
 Disc area was defined in the first measurement, and transported to the second and third topographic images.  
 No significant differences between right and left eyes.  
 Each value represents mean (SD) for 18 eyes. RNFL, retinal nerve fibre layer

**Table 4** Correlations among HRT parameters

		CA	C/D	RA	HVC	CV	RV	MnCD	MxCD	CSM	MnRNFLT	RCSA
DA	right	0.57*	0.50*	0.31	0.32	0.48*	0.01	0.60**	0.43	0.64**	-0.10	0.26
	left	0.86**	0.81**	0.24	0.16	0.78**	-0.23	0.56*	0.42	0.42	-0.30	0.08
CA	right		0.99**	-0.61**	-0.13	0.94**	-0.70**	0.87**	0.74**	0.65**	-0.73**	-0.53*
	left		0.99**	-0.28	0.16	0.90**	-0.59**	0.72**	0.53*	0.64**	-0.48*	-0.17
C/D	right			-0.66**	-0.19	0.92**	-0.74**	0.89**	0.77**	0.64**	-0.74**	-0.56*
	left			-0.36	0.17	0.87**	-0.61**	0.77**	0.58*	0.67**	-0.47	-0.17
RA	right				0.46	-0.62**	0.81**	-0.43	-0.43	-0.13	0.74**	0.86**
	left				<-0.01	-0.24	0.69**	-0.32	-0.21	-0.43	0.36	0.48*
HVC	right					-0.07	0.54*	0.01	-0.02	0.15	0.52*	0.59**
	left					0.02	0.22	0.24	0.15	0.24	0.36	0.42
CV	right						-0.63**	0.79**	0.72**	0.48*	-0.74**	-0.57*
	left						-0.47*	0.79**	0.71**	0.32	-0.35	-0.07
RV	right							-0.55*	-0.47*	-0.44	0.89**	0.87**
	left							-0.25	-0.10	-0.59**	0.77**	0.72**
MnCD	right								0.94**	0.56*	-0.47*	-0.26
	left								0.94**	0.29	0.06	0.27
MxCD	right									0.27	-0.37	-0.23
	left									-0.04	0.18	0.35
CSM	right										-0.45	-0.19
	left										-0.45	-0.30
MnRNFLT	right											0.93**
	left											0.93**

Values are shown as the Pearson correlation coefficient for 18 animals. \*p<0.05, \*\*p<0.01 (Pearson's correlation test).  
 DA, disc area; CA, cup area; C/D, cup/disc area ratio; RA, rim area; HVC, height variation contour; CV, cup volume; RV, rim volume; MnCD, mean cup depth;  
 MxCD, maximum cup depth; CSM, cup shape measure; MnRNFLT, mean RNFL thickness; RCSA, RNFL cross section area; RNFL, retinal nerve fibre layer.

**Table 5** HRT parameters in normal human eyes of human in published studies

	Herman <i>et al</i> <sup>21</sup>		Ghergel <i>et al</i> <sup>20</sup>	
	154 (female), 728 (male)		80 (female), 77 (male)	
	Age range 35-70 years		Age range 14-77 years	
	Right	Left	Right	Left
Disc area (mm <sup>2</sup> )	1.83 (0.39)	1.81 (0.39)	1.92 (0.38)	1.90 (0.37)
Cup area (mm <sup>2</sup> )	0.44 (0.32)	0.44 (0.32)	0.49 (0.26)	0.47 (0.28)
Cup/disc area ratio	0.22 (0.13)	0.22 (0.13)	0.24 (0.10)	0.23 (0.11)
Rim area (mm <sup>2</sup> )	1.39 (0.27)	1.37 (0.27)	1.43 (0.28)	1.42 (0.25)
Cup volume (mm <sup>3</sup> )	NA	NA	0.12 (0.10)	0.11 (0.11)
Rim volume (mm <sup>3</sup> )	0.38 (0.13)	0.36 (0.12)	0.37 (0.12)	0.40 (0.13)
Maximum cup depth (mm)	NA	NA	0.66 (0.18)	0.69 (0.18)
Cup shape measure	NA	NA	-0.23 (0.07)	-0.24 (0.07)
Mean RNFL thickness (mm)	0.26 (0.07)	0.25 (0.07)	0.25 (0.06)	0.27 (0.06)
RNFL cross section area (mm <sup>2</sup> )	NA	NA	1.20 (0.32)	1.33 (0.32)

Each value represents mean (SD). RNFL, retinal nerve fibre layer.  
 NA, not available.  
 Data in table are derived from previous reports by Herman *et al*<sup>21</sup> and Ghergel *et al*<sup>20</sup> (see column headings).

drawing of contour lines to define DA. This procedure is to some extent observer dependent. Therefore, it is important to know which parameters are influenced by DA. In our study, DA correlated with CA, C/D, CV and MnCD (in both eyes), and CSM (in the right eye only). Further, for most of these parameters both the coefficient of variation and R-L difference ratio were relatively high. By contrast, RA, HVC, RV, MxCD, MnRNFLT, and RCSA seemed to be unaffected by DA in either eye. For these parameters, both the coefficient of variation (less than 10%) and the R-L difference ratio (less than 20%) were relatively low. These findings suggest that these parameters, especially RA and HVC may be more suitable than the other parameters for evaluating optic disc changes.

When evaluating HRT parameters in another non-human primate (for example, rhesus monkey) under our experimental conditions, our results (in particular, coefficient of variation) may be useful. However, as previous reports have indicated that the optic structures measured by HRT display racial differences,<sup>34, 35</sup> it is possible that the monkey optic disc structure also differs among the various kinds of monkeys.

In conclusion, we examined optic disc topographic parameters in normal eyes in male cynomolgus monkeys of similar ages. RA and HVC showed relatively low coefficient of variation values (less than 10%), low R-L difference ratios (about 10%), no correlation with DA in either eye, and relatively weak interrelations. These basic results may be useful when HRT is used in monkeys to evaluate optic disc changes in experimentally induced optic disc damage and also to evaluate the efficacy of potential treatments.

#### Authors' affiliations

**T Taniguchi, M Sasaoka**, Research and Development Center, Santen Pharmaceutical Co Ltd, Nara, Japan  
**M Shimazawa, H Hara**, Department of Biofunctional Molecules, Gifu Pharmaceutical University, Gifu, Japan  
**M Araie, G Tomita**, Department of Ophthalmology, University of Tokyo School of Medicine, Tokyo, Japan  
**Y Kitazawa**, Department of Ophthalmology, Gifu University School of Medicine, Gifu, Japan

#### REFERENCES

- 1 Gaasterland D, Kupfer C. Experimental glaucoma in the rhesus monkey. *Invest Ophthalmol Vis Sci* 1974;**13**:455-7.
- 2 Varma R, Quigley HA, Pease ME. Changes in optic disk characteristics and number of nerve fibers in experimental glaucoma. *Am J Ophthalmol* 1992;**114**:554-9.
- 3 Hayreh SS, Pe'er J, Zimmerman MB. Morphologic changes in chronic high-pressure experimental glaucoma in rhesus monkeys. *J Glaucoma* 1999;**8**:56-71.
- 4 Jonas JB, Hayreh SS. Localised retinal nerve fibre layer defects in chronic experimental high pressure glaucoma in rhesus monkeys. *Br J Ophthalmol* 1999;**83**:1291-5.
- 5 Quigley HA, Hohman RM, Addicks EM, et al. Blood vessels of the glaucomatous optic disc in experimental primate and human eyes. *Invest Ophthalmol Vis Sci* 1984;**25**:918-31.
- 6 Derick RJ, Pasquale LR, Pease ME, et al. A clinical study of peripapillary crescents of the optic disc in chronic experimental glaucoma in monkey eyes. *Arch Ophthalmol* 1994;**112**:846-50.
- 7 Hayreh SS, Jonas JB, Zimmerman MB. Parapapillary chorioretinal atrophy in chronic high-pressure experimental glaucoma in rhesus monkeys. *Invest Ophthalmol Vis Sci* 1998;**39**:2296-303.
- 8 Jonas JB, Hayreh SS. Optic disk morphology in experimental central retinal artery occlusion in rhesus monkeys. *Am J Ophthalmol* 1999;**127**:523-30.
- 9 Jonas JB, Hayreh SS. Influence of experimental chronic high-pressure glaucoma on age-related macular degeneration in rhesus monkeys. *Invest Ophthalmol Vis Sci* 2000;**41**:2972-7.
- 10 Jonas JB, Hayreh SS. Ophthalmoscopic appearance of the normal optic nerve head in rhesus monkeys. *Invest Ophthalmol Vis Sci* 2000;**41**:2978-83.
- 11 Varma R, Steinmann WC, Scott IU. Expert agreement in evaluating the optic disc for glaucoma. *Ophthalmology* 1992;**99**:215-21.
- 12 Malinovsky VE. An overview of the Heidelberg retina tomograph. *J Am Optom Assoc* 1996;**67**:457-67.
- 13 Ahn BS, Kee C. Ability of a confocal scanning laser ophthalmoscope (TopSS) to detect early glaucomatous visual field defect. *Br J Ophthalmol* 2000;**84**:852-5.
- 14 Azuara-Blanco A, Harris A, Cantor LB. Reproducibility of optic disk topographic measurements with the Topcon ImageNet and the Heidelberg retina tomograph. *Ophthalmologica* 1998;**212**:95-8.
- 15 Iester M, Mikelberg FS, Courtright P, et al. Correlation between the visual field indices and Heidelberg retina tomograph parameters. *J Glaucoma* 1997;**6**:78-82.
- 16 Eid TM, Spaeth GL, Katz LJ, et al. Quantitative estimation of retinal nerve fiber layer height in glaucoma and the relationship with optic nerve head topography and visual field. *J Glaucoma* 1997;**6**:221-30.
- 17 Lan YW, Henson DB, Kwartz AJ. The correlation between optic nerve head topographic measurements, peripapillary nerve fibre layer thickness, and visual field indices in glaucoma. *Br J Ophthalmol* 2003;**87**:1135-41.
- 18 Heickell AG, Bellezza AJ, Thompson HW, et al. Optic disc surface compliance testing using confocal scanning laser tomography in the normal monkey eye. *J Glaucoma* 2001;**10**:369-82.
- 19 Burgoyne CF, Mercante DE, Thompson HW. Change detection in regional and volumetric disc parameters using longitudinal confocal scanning laser tomography. *Ophthalmology* 2002;**109**:455-66.
- 20 Ervin JC, Lemij HG, Mills RP, et al. Clinician change detection viewing longitudinal stereophotographs compared to confocal scanning laser tomography in the LSU Experimental Glaucoma (LEG) Study. *Ophthalmology* 2002;**109**:467-81.
- 21 Yücel YH, Gupta N, Kalichman MW, et al. Relationship of optic disc topography to optic nerve fiber number in glaucoma. *Arch Ophthalmol* 1998;**116**:493-7.
- 22 Hare WA, WoldeMussie E, Weinreb RN, et al. Efficacy and safety of memantine treatment for reduction of changes associated with experimental glaucoma in monkey, II: Structural measures. *Invest Ophthalmol Vis Sci* 2004;**45**:2640-51.
- 23 Quigley HA, Pease ME. Change in the optic disc and nerve fiber layer estimated with the glaucoma-scope in monkey eyes. *J Glaucoma* 1996;**5**:106-16.
- 24 Shirakashi M, Abe H, Sawaguchi S, Iwata K. The relationship between deterioration and reversal of optic disc cupping in monkeys with chronic experimental high-pressure glaucoma. *Graefes Arch Clin Exp Ophthalmol* 1998;**236**:546-52.
- 25 Burgoyne CF, Varma R, Quigley HA, et al. Global and regional detection of induced optic disc change by digitized image analysis. *Arch Ophthalmol* 1994;**112**:261-8.
- 26 Burgoyne CF, Quigley HA, Thompson HW, et al. Measurement of optic disc compliance by digitized image analysis in the normal monkey eye. *Ophthalmology* 1995;**102**:1790-9.
- 27 Saruhan A, Orgul S, Kocak I, et al. Descriptive information of topographic parameters computed at the optic nerve head with the Heidelberg retina tomograph. *J Glaucoma* 1998;**7**:420-9.
- 28 Tan JC, Garway-Heath DF, Hitchings RA. Variability across the optic nerve head in scanning laser tomography. *Br J Ophthalmol* 2003;**87**:557-9.
- 29 Roff EJ, Hosking SL, Barnes DA. The influence of contour line size and location on the reproducibility of topographic measurement with the Heidelberg retina tomograph. *Ophthalmic Physiol Opt* 2001;**21**:173-81.
- 30 Gherghel D, Orgul S, Prunte C, et al. Interocular differences in optic disc topographic parameters in normal subjects. *Curr Eye Res* 2000;**20**:276-82.
- 31 Hermann MM, Theofylaktopoulos I, Bangard N, et al. Optic nerve head morphometry in healthy adults using confocal laser scanning tomography. *Br J Ophthalmol* 2004;**88**:761-5.
- 32 Nakamura H, Maeda T, Suzuki Y, et al. Scanning laser tomography to evaluate optic discs of normal eyes. *Jpn J Ophthalmol* 1999;**43**:410-14.
- 33 Durukan AH, Yücel I, Akar Y, et al. Assessment of optic nerve head topographic parameters with a confocal scanning laser ophthalmoscope. *Clin Experiment Ophthalmol* 2004;**32**:259-64.
- 34 Tsai CS, Zangwill L, Gonzalez C, et al. Ethnic differences in optic nerve head topography. *J Glaucoma* 1995;**4**:248-57.
- 35 Girkin CA, McGwin G Jr, McNeal SF, et al. Racial differences in the association between optic disc topography and early glaucoma. *Invest Ophthalmol Vis Sci* 2003;**44**:3382-7.

# Topical application of autologous serum for the treatment of late-onset aqueous oozing or point-leak through filtering bleb

H Matsuo, A Tomidokoro, G Tomita and M Araie

## Abstract

**Purpose** To evaluate the efficacy of topical autologous serum application to stop aqueous oozing or point-leak through filtering bleb after trabeculectomy.

**Patients and Methods** A total of 21 consecutive eyes with oozing and 21 eyes with a point-leak through a functional bleb after trabeculectomy with 5-fluorouracil or mitomycin C were enrolled in this randomized, case-control study. In eyes randomly assigned to the serum group, an antibiotic and the autologous serum, which was sterilely diluted to 20% with physiological saline, were topically applied four times a day for up to 12 weeks. In eyes assigned to the control group, the antibiotic alone was applied according to the same protocol. Intraocular pressure (IOP) and the presence of oozing or a point-leak were tested before and every 2 weeks after starting the treatments.

**Results** In the serum and control groups, oozing stopped in 62.5 and 0% of eyes, respectively ( $P=0.003$ ), and point-leaks stopped in 27.3 and 18.2%, respectively ( $P>0.9$ ). IOP significantly increased from  $10.0\pm 3.2$  (mean  $\pm$  standard deviation) to  $11.8\pm 3.3$  mmHg in eyes in which oozing stopped ( $P=0.066$ ), and from  $11.4\pm 2.7$  to  $15.4\pm 2.3$  mmHg in eyes in which a point-leak stopped ( $P=0.042$ ).

**Conclusions** Autologous serum application was significantly effective to stop aqueous oozing but not point-leaks. Stopping oozing or point-leaks was significantly associated with an increase in IOP.

Eye (2005) 19, 23–28. doi:10.1038/sj.eye.6701422  
Published online 9 July 2004

**Keywords:** trabeculectomy; oozing; point-leak; serum

## Introduction

The introduction of antimetabolic agents such as 5-fluorouracil (5-FU) or mitomycin C (MMC) has improved the success rate of controlling intraocular pressure (IOP) after trabeculectomy.<sup>1–6</sup> However, because avascular blebs with thin walls are more commonly obtained after trabeculectomy with antimetabolites,<sup>7–10</sup> bleb-related complications, such as hypotony due to a bleb leak, blebitis, and endophthalmitis, are increasing.<sup>11–15</sup>

Aqueous leakage from filtering blebs is not a rare condition after trabeculectomy with antimetabolites.<sup>1,2,4,10–12,14,16,17</sup> Previous studies revealed the prevalence of aqueous leakage as 1.4% after trabeculectomy with 5-FU<sup>17</sup> and 3.7% with MMC,<sup>17</sup> and the probability of aqueous leakage estimated with the life-table method was 4.2% at 6 years after surgery with 5-FU.<sup>18</sup> There are two types of aqueous leakage: point-leaks and oozing. The former is leakage with a visible aqueous stream from a leak point, and the latter is transconjunctival aqueous egress without a focal leak point.<sup>10</sup> We recently reported that the prevalence of point-leaks was 1.4% with 5-FU and 2.3% with MMC, and that of oozing was 13.8% with 5-FU and 10.9% with MMC.<sup>10</sup> Both are possible risk factors for bleb-related complications because oozing often indicates hyperpermeability and/or vulnerability of the bleb wall.<sup>7–10,19</sup> Several methods for repairing point-leaks have been reported, such as surgical repair,<sup>20–24</sup> subconjunctival autologous blood injection,<sup>25–27</sup>

Department of Ophthalmology  
University of Tokyo  
Graduate School of Medicine  
Bunkyo-ku Tokyo, Japan

Correspondence:  
A Tomidokoro, MD  
Department of Ophthalmology  
University of Tokyo  
Graduate School of Medicine  
7-3-1, Hongo  
Bunkyo-ku  
Tokyo 113-8655, Japan  
Tel: +81 3 3815 5411 (ext 33493)  
Fax: +81 3 3817 0798  
E-mail: tomidokoro-tyk@umin.ac.jp

Published online: 9 July 2004

None of the authors has any commercial or proprietary interest in materials described in this article.



and using tissue glue or fibrin.<sup>28–30</sup> There is no established method, however, to treat oozing.

Serum contains various cytokines or chemical mediators, such as vitamin A, epidermal growth factor, and transforming growth factor- $\beta$ .<sup>31–33</sup> Topical application of autologous serum is reported to be useful in the treatment of corneal diseases, such as severe dry eye,<sup>32</sup> persistent corneal epithelial defect,<sup>31</sup> and superior limbic keratoconjunctivitis.<sup>33</sup> Although the effects of serum on the conjunctiva have not been fully studied, vitamin A and epidermal growth factor are reported to have roles in maintaining the normal histology of the conjunctiva.<sup>34–36</sup> In the current study, the therapeutic efficacy of the topical application of autologous serum to treat aqueous leakage, including oozing and point-leaks, was prospectively evaluated in glaucoma patients who had undergone trabeculectomy with antimetabolites.

### Patients and methods

In consecutive patients who had a history of trabeculectomy with 5-FU or MMC and had a functioning bleb, the presence of point-leaks or oozing of aqueous through the bleb was tested as follows, in the outpatient clinic of the Department of Ophthalmology, University of Tokyo Graduate School of Medicine (Tokyo, Japan), from February 2000 to December 2000. A moistened sterile fluorescein strip was gently applied to the bleb surface and the presence of a spontaneous visible aqueous stream from a leak point (point-leak) was initially tested under cobalt blue slitlamp illumination. If no point-leak was found, the slitlamp observation was continued for 15 s to find oozing, which was identified as aqueous egress without apparent interruption of the conjunctival tissue or an aqueous stream on the bleb wall.<sup>10</sup>

In patients in whom point-leaks or oozing were found, the purpose of the study was explained and the advantage and disadvantage of treatment were discussed. In patients who gave a written informed consent, each eye was randomly assigned into the treatment group (serum group) or control group. In patients in the serum group, 40 ml of blood was obtained from the antebraclial vein and centrifuged for 5 min at 1500 r.p.m. According to the methods of Tsubota *et al*,<sup>31–33</sup> the serum was sterilely separated and diluted with physiological saline to a 20% concentration; the 20% serum solution was aliquoted into 5 ml bottles with ultraviolet light-filtering walls, since vitamin A is easily degraded by light, and patients were instructed to keep the bottles in a dark and cool place, such as a refrigerator, and to stock the rest of the bottles in a freezer until required. Both the 20% serum solution and an antibiotic

(0.3% ofloxacin, Tarivid<sup>TM</sup>, Santen Pharmaceutical Co. Ltd, Osaka, Japan) were topically applied with a 5-min interval into the eyes with point-leaks or oozing four times a day. In eyes of the control group, the antibiotic alone was topically applied four times a day.

The patients were instructed to visit the outpatient clinic every 2 weeks, and a slitlamp examination was performed with testing for point-leaks or oozing at every visit by a clinician masked to the treatment. If a point-leak or oozing was not found at two consecutive visits, the treatment protocol was discontinued, but the observation was continued every 2 weeks for the at least 8 weeks to check for the recurrence of oozing or point-leaks. If point-leaks or oozing did not stop, the protocol of treatment and observation was continued for 12 weeks. IOP was measured with an applanation tonometer at every visit. None of the eyes required intervention for signs of infection (blebitis or endophthalmitis) or problems relating to hypotony (hypotony maculopathy, shallow anterior chamber, etc). The study adhered to the tenets of the Declaration of Helsinki and the research protocol was approved by an Institutional Review Board.

### Results

Oozing was found in 21 eyes of 21 patients and a point-leak in another 21 eyes of 21 patients. There was no patient who had oozing and/or a point-leak in both eyes. Eight and 13 of the 21 eyes with oozing, and 11 and 10 of the 21 eyes with point-leaks, were assigned to the serum and control groups, respectively. Table 1 summarizes the patients' demographics; there was no significant difference between the serum and control groups ( $P > 0.1$ ,  $\chi^2$ , Fisher exact, or Mann-Whitney tests).

Of the 21 eyes with oozing, the oozing stopped in five of eight eyes (62.5%) in the serum group and none of 13 eyes (0%) in the control group, a statistically significant difference ( $P = 0.003$ , Fisher exact test). Of the 21 eyes with point-leaks, the point-leak stopped in three of 11 eyes (27.3%) in the serum group and two of 11 (18.2%) eyes in the control group, which was not significantly different ( $P > 0.9$ ). The proportion in whom oozing stopped was not statistically significantly higher than the proportion in whom point-leaks stopped in the serum group (62.5 vs 27.3%) and in the control group (27.3 vs 18.2%), respectively ( $P = 0.144$ , 0.178). In the current study, no case of recurrence of oozing or point-leak was observed at least 6 months after the determination of the stoppage of oozing or point-leak.

The changes in IOP associated with treatment in the eyes with oozing and point-leaks are shown in Tables 2 and 3, respectively. IOP before the treatment was IOP when oozing or point-leak was initially found. IOP

**Table 1** Patients' demographics when oozing or point-leak was initially found

Group	Oozing			Point-leak		
	Serum	Control	P	Serum	Control	P
Number of eyes	8	13		11	10	
Male/female	7/1	10/3	>0.99	6/5	9/1	0.15
Age (year)	58.9±12.5	57.4±16.4	0.91	57.2±18.8	56.9±12.2	0.92
<b>Diagnosis</b>						
POAG	7	11		10	7	
NTG	1	2		0	1	
PACG	0	0		0	0	
Secondary	0	0		1	2	
<b>Antimetabolites</b>						
MMC	6	11	0.62 <sup>a</sup>	8	6	0.66 <sup>a</sup>
5-FU	2	2		3	4	
Duration from surgery (month)	4.4±2.1	3.1±3.4	0.12 <sup>b</sup>	6.1±2.8	5.8±2.3	0.10 <sup>b</sup>
Concurrent IOP (mmHg)	10.8±3.4	10.8±3.3	0.74 <sup>b</sup>	11.3±2.7	9.3±3.5	0.89 <sup>b</sup>

Number of eyes or mean±standard deviation. Oozing and point-leak = eyes with oozing and point-leak, respectively. POAG = primary open-angle glaucoma, NTG = normal tension glaucoma, PACG = primary angle closure glaucoma, secondary = secondary glaucoma. P = P-value regarding the difference between the serum and control groups.

<sup>a</sup>By  $\chi^2$  test or Fisher exact test.

<sup>b</sup>By Mann-Whitney test.

**Table 2** Changes in intraocular pressure in eyes with oozing

	N	Pre (mmHg)	Post (mmHg)	P-value (pre vs post)
<b>All eyes</b>				
Oozing stopped	5	10.0±3.2	11.8±3.3	0.066
Oozing continued	16	11.0±3.3	9.8±3.6	0.042*
P-value (oozing stopped vs continued)		0.354	0.313	
<b>The serum group</b>				
Oozing stopped	5	10.0±3.2	11.8±3.3	0.066
Oozing continued	3	12.0±4.0	9.3±5.9	0.180
P-value (oozing stopped vs continued)		0.571	0.393	
<b>The control group</b>				
Oozing stopped	0	—	—	—
Oozing continued	13	10.8±3.3	9.8±3.3	0.092
P-value (oozing stopped vs continued)	—	—	—	—

Mean±standard deviation. N = number of eyes. P-value (pre vs post) = P-value regarding the difference between before and after the treatment (Wilcoxon signed rank test). P-value (oozing stopped vs continued) = P-value regarding the difference between eyes of which oozing stopped and those of which oozing continued (Mann-Whitney test). \*Significant difference (P < 0.05).

after the treatments was IOP when oozing or point-leak stopped or at the end of the 12-week treatment. Among the 21 eyes with oozing, IOP increased from 10.0±3.2 to 11.8±3.3 mmHg (P = 0.066, Wilcoxon signed rank test) in the five eyes in which oozing stopped, while the IOP significantly decreased from 11.0±3.3 to 9.8±3.6 mmHg (P = 0.042) in the 16 eyes in which oozing

continued. If the serum and control groups were separately analysed, similar tendencies were obtained (Table 2). Among the 21 eyes with point-leaks, the IOP significantly increased from 11.4±2.7 to 15.4±2.3 mmHg (P = 0.042) in the 5 eyes in which point-leaks stopped, but did not significantly change (P = 0.344) in the 16 eyes in which a point-leak continued. If the serum and control

**Table 3** Changes in intraocular pressure in eyes with a point-leak

	N	Pre (mmHg)	Post (mmHg)	P-value (pre vs post)
<i>All eyes</i>				
Leak stopped	5	11.4±2.7	15.4±2.3	0.042*
Leak continued	16	10.0±3.4	10.6±4.0	0.344
P-value (leak stopped vs continued)		0.313	0.006*	
<i>The serum group</i>				
Leak stopped	3	12.0±1.0	15.3±2.1	0.109
Leak continued	8	11.0±3.2	11.3±2.4	0.752
P-value (leak stopped vs continued)		0.630	0.024*	
<i>The control group</i>				
Leak stopped	2	10.5±5.0	15.5±3.5	0.180
Leak continued	8	9.0±3.5	10.0±5.2	0.336
P-value (leak stopped vs continued)		0.718	0.178	

Mean ± standard deviation. N = number of eyes. P-value (pre vs post) = P-value regarding the difference between before and after the treatment (Wilcoxon signed rank test). P-value (leak stopped vs continued) = P-value regarding the difference between eyes in which a point-leak stopped and those in which a point-leak continued (Mann-Whitney test). \*Significant difference (P < 0.05).

groups were separately analysed, similar tendencies were obtained (Table 3).

**Discussion**

This prospective study revealed that the topical application of autologous serum is significantly effective for stopping aqueous oozing, but not for curing point-leaks in eyes after trabeculectomy with 5-FU or MMC. The IOP significantly increased in eyes in which aqueous leakage including oozing and point-leak stopped, regardless of the treatments. No other complication was observed during autologous serum treatment.

Aqueous leakage through a filtering bleb is thought to be associated with several postoperative complications, including endophthalmitis.<sup>11-15</sup> In most of the previous reports, aqueous leakage was tested with the Seidel test to find point-leaks, but oozing was usually not reported. Our recent study, however, revealed that oozing is much more frequent than point-leaks.<sup>10</sup> Since the development of blebitis or endophthalmitis is not so frequent after trabeculectomy, it should be difficult to precisely determine the relative risks of oozing on these complications. According to Susanna *et al*,<sup>19</sup> however, point-leaks could be induced with digital massage on the upper lid in 15 of 47 eyes with filtering blebs that initially showed the negative Seidel test, and the induced point-leak was much more frequently observed in eyes with a transparent, avascular bleb, suggesting that oozing, which usually occurred in blebs with avascular walls,<sup>10</sup> may easily develop point-leaks. Moreover, as Lehmann *et al*.<sup>37</sup> suggested, the physical barrier function against bacteria should be impaired in the thin and avascular

bleb wall, with denuded epithelium, and in the underlying full thickness stromal damage.<sup>7</sup> Thus, eyes with oozing should have potential risks of developing point-leak- and bleb-related infections, and a method to treat oozing should be of clinical importance.

Eyes with bleb leaks generally show lower IOP than those without it. In our previous study,<sup>10</sup> IOPs were 11.9 ± 3.9, 9.8 ± 3.2, and 9.1 ± 2.2 mmHg (mean ± standard deviation) in eyes without oozing or point-leaks, those with oozing, and those with point-leaks, respectively, and the intergroup difference was significant (P < 0.001, Kruskal-Wallis test). Therefore, with a view to IOP control, bleb leaks may not be necessarily an adverse condition. In the current study, the IOP increased from 10.0 ± 3.2 to 11.8 ± 3.3 mmHg (P = 0.066) in eyes in which oozing stopped, and from 11.4 ± 2.7 to 15.4 ± 2.3 mmHg (P = 0.042) in eyes in which point-leaks stopped, while IOP decreased or did not change in eyes in which oozing or point-leaks continued. These results suggest that not only point-leaks but also oozing is associated with keeping IOP lower. Thus, an attempt to stop oozing may not be indicated in eyes in which the target IOP is low, although continuing careful observation is necessary. Conversely, an eye with oozing and consistent low IOP may be a good indication for autologous serum application.

According to Tsubota *et al*,<sup>31-33</sup> autologous serum prepared in the same manner as in the current study includes vitamin A, epidermal growth factor, and transforming factor-β1. They also reported that the migration speed of a confluent sheet of human corneal epithelial cells was significantly higher in medium containing 20% serum than in that without it.<sup>31</sup> Although

the influence of cytokines or other chemical mediators in serum on the conjunctiva is not so clear as that on the corneal tissues, several studies suggest that deficiency of vitamin A caused abnormal histology in the conjunctiva, such as decreased goblet cells and increased cellular stratification.<sup>34,35</sup> Also, another study found epidermal growth factor in the conjunctiva and tears of rats, but not in the cornea and aqueous humor.<sup>36</sup> Doyle *et al*<sup>38</sup> suggested that peribleb injection of transforming growth factor- $\beta$  contributes to healing bleb leaks created by stab incision of the bleb in rabbits. The current result that autologous serum application was significantly effective in stopping aqueous oozing also suggests that these substances may have beneficial effects on treating hyperpermeability of thin and avascular bleb walls, in which an irregular cell arrangement of the epithelial layer and a damaged basement membrane exist.<sup>7-9,13-15</sup> The 20% serum application, however, is not thought to be effective enough to close a leaking micro-hole responsible for a point-leak on the bleb wall.

The topical application used in the current study was formulated from the patient's own serum in a sterile manner, and was kept in a dark and cool place, such as a freezer and a refrigerator. The concentrations of vitamin A, epidermal growth factor, and transforming growth factor- $\beta$ 1 in 20% serum are reported to be stably maintained for 1 month in a refrigerator or 3 months in a freezer.<sup>31</sup> Although contamination of the serum solution was not assessed in the current study, a previous report found no bacterial or fungal positive cultures from the remaining serum prepared as in the current study and used in 12 cases with dry eyes in Sjögren's syndrome.<sup>32</sup> No eye participating in the current study developed infectious complications, such as conjunctivitis, blepharitis, blebitis, and an endophthalmitis during or after the current study. In the current study, although the recurrence of oozing was not seen during at least 6 months follow-up in eyes in which oozing was initially stopped with or without the treatment, it is still unclear whether the effect of autologous serum application on curing oozing is long-lasting or not. Therefore, the cost (or effort) effectiveness of this regimen should not be concluded here, and deserves further clinical studies with longer follow-up periods.

In conclusion, autologous serum application was significantly effective in stopping aqueous oozing but not point-leaks after trabeculectomy with 5-FU or MMC. Stopping oozing is expected to reduce the risk of future bleb-related complications, such as hypotony, hypotony maculopathy, blebitis, and endophthalmitis. However, it also has the possibility of aggravating IOP control at least in a part of cases. An eye concurrently having oozing and hypotony or a fairly low IOP is in our view an indication for treatment with autologous serum application. If an

eye without low IOP has oozing, careful observation of the bleb should be advocated rather than instantly starting the autologous serum application.

## References

- 1 Rockwood EJ, Parrish II RK, Heuer DK, Skuta GL, Hodapp E, Palmberg PF *et al*. Glaucoma filtering surgery with 5-fluorouracil. *Ophthalmology* 1987; **94**: 1071-1078.
- 2 The Fluorouracil Filtering Surgery Study Group. Five-year follow-up of the Fluorouracil Filtering Surgery Study. *Am J Ophthalmol* 1996; **121**: 349-366.
- 3 Kitazawa Y, Kawase K, Matsushita H, Minobe M. Trabeculectomy with mitomycin. A comparative study with fluorouracil. *Arch Ophthalmol* 1991; **109**: 1693-1698.
- 4 Liebmann JM, Ritch R, Marmor M, Nunez J, Wolner B. Initial 5-fluorouracil trabeculectomy in uncomplicated glaucoma. *Ophthalmology* 1991; **98**: 1036-1041.
- 5 Araie M, Shoji N, Shirato S, Nakano Y. Postoperative subconjunctival 5-fluorouracil injections and success probability of trabeculectomy in Japanese: results of 5-year follow-up. *Jpn J Ophthalmol* 1992; **36**: 158-168.
- 6 Cheung JC, Wright MM, Murali S, Pederson JE. Intermediate-term outcome of variable dose mitomycin C filtering surgery. *Ophthalmology* 1997; **104**: 143-149.
- 7 Shields MB, Scroggs MW, Sloop CM, Simmons RB. Clinical and histopathologic observations concerning hypotony after trabeculectomy with adjunctive mitomycin C. *Am J Ophthalmol* 1993; **116**: 673-683.
- 8 Mietz H, Brunner R, Addicks K. Histopathology of an avascular filtering bleb after trabeculectomy with mitomycin-C. *J Glaucoma* 1993; **2**: 266-270.
- 9 Nuyts RM, Felten PC, Pels E, Langerhorst CT, Geijssen HC, Grossniklaus HE *et al*. Histopathologic effects of mitomycin C after trabeculectomy in human glaucomatous eyes with persistent hypotony. *Am J Ophthalmol* 1994; **118**: 225-237.
- 10 Matsuo H, Tomidokoro A, Suzuki Y, Shirato S, Araie M. Late-onset transconjunctival oozing and point leak of aqueous humor from filtering bleb after trabeculectomy. *Am J Ophthalmol* 2002; **133**: 456-462.
- 11 Wolner B, Liebmann JM, Sassani JW, Ritch R, Speaker M, Marmor M. Late bleb-related endophthalmitis after trabeculectomy with adjunctive 5-fluorouracil. *Ophthalmology* 1991; **98**: 1053-1060.
- 12 Ticho U, Ophir A. Late complications after glaucoma filtering surgery with adjunctive 5-fluorouracil. *Am J Ophthalmol* 1993; **115**: 506-510.
- 13 Greenfield DS, Parrish II RK. Bleb rupture following filtering surgery with mitomycin-C: clinicopathologic correlations. *Ophthalmic Surg Lasers* 1996; **27**: 876-877.
- 14 Belyea DA, Dan JA, Stamper RL, Liebmann MF, Spencer WH. Late onset of sequential multifocal bleb leaks after glaucoma filtration surgery with 5-fluorouracil and mitomycin C. *Am J Ophthalmol* 1997; **124**: 40-45.
- 15 Sihota R, Dada T, Gupta SD, Sharma S, Arora R, Agarwal HC. Conjunctival dysfunction and mitomycin C-induced hypotony. *J Glaucoma* 2000; **9**: 392-397.
- 16 Katz GJ, Higginbotham EJ, Lichter PR, Skuta GL, Musch DC, Bergstrom TJ *et al*. Mitomycin C versus 5-fluorouracil in high-risk glaucoma filtering surgery. *Extended follow-up. Ophthalmology* 1995; **102**: 1263-1269.