

33. Taylor GI, Townsend P, Corlett R (1979) Superiority of the deep circumflex iliac vessels as the supply for free groin flaps. *Clinical work. Plast Reconstr Surg* 64:745-759
34. Salibian AH, Rappaport I, Allison G (1985) Functional oromandibular reconstruction with the microvascular composite groin flap. *Plast Reconstr Surg* 76:819-828
35. Teot L, Bosse JP, Mourfarrege R (1981) The scapular crest pedicled bone graft. *Int J Microsurg* 3:257-262
36. Swartz WM, Banis JC, Newton ED, et al. (1986) The osteocutaneous scapular flap for mandibular and maxillary reconstruction. *Plast Reconstr Surg* 77:530-545
37. Baker SR, Sullivan MJ (1988) Osteocutaneous free scapular flap for one-stage mandibular reconstruction. *Arch Otolaryngol Head Neck Surg* 114:267-277
38. Hidalgo DA (1989) Fibula free flap: a new method of mandible reconstruction. *Plast Reconstr Surg* 84:71-79
39. Flemming AF, Brough MD, Evans ND, et al. (1990) Mandibular reconstruction using vascularized fibula. *Br J Plast Surg* 43:403-409
40. Wei FC, Seah CS, Tsai YC, et al. (1994) Fibula osteoseptocutaneous flap for reconstruction of composite mandibular defects. *Plast Reconstr Surg* 93:294-304
41. Soutar DS, McGregor IA (1986) The radial forearm flap in intraoral reconstruction: the experience of 60 consecutive cases. *Plast Reconstr Surg* 78:1-8
42. Soutar DS, Widdowson WP (1986) Immediate reconstruction of the mandible using a vascularized segment of radius. *Head Neck Surg* 8:232-246
43. Thoma A, Allen M, Tadeson BH, et al. (1995) The fate of the osteotomized free radial forearm osteocutaneous flap in mandible reconstruction. *J Reconstr Microsurg* 11:215-219
44. Byars LT (1946) Subperiosteal mandibular resection with internal bar fixation. *Plast Reconstr Surg* 1:236-239
45. Freeman BS (1948) The use of vitallium plates to maintain function following resection of the mandible. *Plast Reconstr Surg* 3:73-78
46. Conley JJ (1951) The use of vitallium prostheses and implants in the reconstruction of the mandibular arch. *Plast Reconstr Surg* 8:150-162
47. Edgerton MT, Ward G, Sikes TE (1950) Fixation and plastic repair after partial mandibular resection. *Plast Reconstr Surg* 5:231
48. Healy MJ Jr, Sudbay JL, Niebel HH, et al. (1954) The use of acrylic implants in one-stage reconstruction of the mandible. *Surg Gynecol Obstet* 98:395-406
49. Phillips CM (1967) Primary and secondary reconstruction of the mandible after ablative surgery. Report of 24 cases using stainless steel prostheses. *Am J Surg* 114:601-604
50. Cordeiro PG, Hidalgo DA (1994) Soft-tissue coverage of mandibular reconstruction plates. *Head Neck* 16:112-115
51. Boyd JB, Mulholland RS, Davidson J, et al. (1995) The free flap and plate in oromandibular reconstruction: long-term review and indications. *Plast Reconstr Surg* 95:1018-1028
52. Vuillemin T, Raveh J, Sutter F (1988) Mandibular reconstruction with the titanium hollow screw reconstruction plate (THORP) system: evaluation of 62 cases. *Plast Reconstr Surg* 82:804-814
53. Irish JC, Gullane PJ, Gilbert RW, et al. (1995) Primary mandibular reconstruction with the titanium hollow screw reconstruction plate: evaluation of 51 cases. *Plast Reconstr Surg* 96:93-99
54. Ostrup LT, Fredrickson JM (1974) Distant transfer of a free, living bone graft by microvascular anastomoses. An experimental study. *Plast Reconstr Surg* 54:274-285
55. McCullough DW, Fredrickson JM (1973) Neovascularized rib grafts to reconstruct mandibular defects. *Can J Otolaryngol* 2:96-100
56. Schlenker JD, Indresano AT, Raine T, et al. (1980) A new flap in the dog containing a vascularized rib graft - the latissimus dorsi myoosteocutaneous flap. *J Surg Res* 29:172-183
57. Ohmori K, Harii K (1976) Free dorsalis pedis sensory flap to the hand, with microvascular anastomoses. *Plast Reconstr Surg* 58:546-554
58. Salibian AH, Rappaport I, Furnas DW, et al. (1980) Microvascular reconstruction of the mandible. *Am J Surg* 140:499-502
59. Rosen IB, Manktelow RT, Zuker RM, et al. (1985) Application of microvascular free osteocutaneous flaps in the management of post-radiation recurrent oral cancer. *Am J Surg* 150:474-479
60. Zuker RM, Manktelow RT (1986) The dorsalis pedis free flap: technique of elevation, foot closure, and flap application. *Plast Reconstr Surg* 77:93-104
61. Taylor GI, Watson N (1978) One-stage repair of compound leg defects with free, revascularized flaps of groin skin and iliac bone. *Plast Reconstr Surg* 61:494-506
62. Taylor GI (1982) Reconstruction of the mandible with free composite iliac bone grafts. *Ann Plast Surg* 9:361-376
63. Jewer DD, Boyd JB, Manktelow RT, et al. (1989) Orofacial and mandibular reconstruction with the iliac crest free flap: a review of 60 cases and a new method of classification. *Plast Reconstr Surg* 84:391-403
64. Urken ML, Vickery C, Weinberg H, et al. (1989) The internal oblique-iliac crest osseomyocutaneous microvascular free flap in head and neck reconstruction. *J Reconstr Microsurg* 5:203-214
65. Harii K, Yamada A, Nakatsuka T, et al. (1991) Reconstruction of the mandible with a vascularized iliac bone or osteocutaneous flap. *Jpn J Plast Reconstr Surg* 34:47-58
66. Frodel JL Jr, Funk GF, Capper DT, et al. (1993) Osseointegrated implants: a comparative study of bone thickness in four vascularized bone flaps. *Plast Reconstr Surg* 92:449-455
67. Gilbert A, Teot L (1982) The free scapular flap. *Plast Reconstr Surg* 69:601-604
68. dos Santos LF (1984) The vascular anatomy and dissection of the free scapular flap. *Plast Reconstr Surg* 73:599-604
69. Granick MS, Newton ED, Hanna DC (1986) Scapular free flap for repair of massive lower facial composite defects. *Head Neck Surg* 8:436-441
70. Nakatsuka T, Harii K, Yamada A, et al. (1996) Surgical treatment of mandibular osteoradionecrosis: versatility of the scapular osteocutaneous flap. *Scand J Plast Reconstr Surg Hand Surg* 30:291-298
71. Coleman JJ 3rd, Sultan MR (1991) The bipedicled osteocutaneous scapula flap: a new subscapular system free flap. *Plast Reconstr Surg* 87:682-692
72. Coskunfirat OK (1999) Free vascularized fibula transfer: who was first? *Plast Reconstr Surg* 104:1202-1203
73. Taylor GI, Miller GD, Ham FJ (1975) The free vascularized bone graft. A clinical extension of microvascular techniques. *Plast Reconstr Surg* 55:533-544
74. Ueba Y, Fujikawa S (1983) Nine years' follow-up of a free vascularized fibular graft in neurofibromatosis: a case report and literature review. *Jpn J Orthop Trauma Surg* 26:595-600
75. O'Brien BM, Gumley GJ, Dooley BJ, et al. (1988) Folded free vascularized fibula transfer. *Plast Reconstr Surg* 82:311-318
76. Hidalgo DA, Rekow A (1995) A review of 60 consecutive fibula free flap mandible reconstructions. *Plast Reconstr Surg* 96:585-596
77. Soutar DS, Schecker LR, Tanner NS, et al. (1983) The radial forearm flap: a versatile method for intra-oral reconstruction. *Br J Plast Surg* 36:1-8
78. Thoma A, Khadaroo R, Grigenas O, et al. (1999) Oromandibular reconstruction with the radial-forearm osteocutaneous flap: experience with 60 consecutive cases. *Plast Reconstr Surg* 104:368-378
79. Weinzeig N, Jones NF, Shestak KC, et al. (1994) Oromandibular reconstruction using a keel-shaped modification of the radial forearm osteocutaneous flap. *Ann Plast Surg* 33:359-369
80. Butterworth M, Butler PE (2000) Radial forearm osteocutaneous flap for head and neck reconstruction. *Plast Reconstr Surg* 106:1425-1426
81. Takushima A (2002) Author reply to Harris PA and Butler PE. Radial forearm osteocutaneous flap for mandibular reconstruction. *Plast Reconstr Surg* 110:1196
82. Takushima A, Harii K, Asato H, et al. (2001) Mandibular reconstruction using microvascular free flaps: a statistical analysis of 178 cases. *Plast Reconstr Surg* 108:1555-1563
83. Moscoso JF, Keller J, Genden E, et al. (1994) Vascularized bone flaps in oromandibular reconstruction. A comparative anatomic study of bone stock from various donor sites to assess suitability for enosseous dental implants. *Arch Otolaryngol Head Neck Surg* 120:36-43
84. David DJ, Tan E, Katsaros J, et al. (1988) Mandibular reconstruction with vascularized iliac crest: a 10-year experience. *Plast Reconstr Surg* 82:792-803
85. Cordeiro PG, Disa JJ, Hidalgo DA, et al. (1999) Reconstruction of the mandible with osseous free flaps: a 10-year experience with 150 consecutive patients. *Plast Reconstr Surg* 104:1314-1320

Revisional Operations Improve Results of Neurovascular Free Muscle Transfer for Treatment of Facial Paralysis

Akihiko Takushima, M.D., Kiyonori Harii, M.D., Hirotaka Asato, M.D., and Akira Momosawa, M.D.

Tokyo, Japan

Background: Neurovascular free muscle transfer is currently the mainstay for smile reconstruction. However, problems such as excessive muscle bulk and dislocation of the transferred muscle attachment have been described. Furthermore, dynamic movements of the transferred muscle are sometimes too strong or too weak, resulting in facial asymmetry. In these cases, secondary revisional operations for the transferred muscle are required after neurovascular free muscle transfer. This report describes revisional operative procedures in detail and examines the extent of improvement of the smile by comparing preoperative and postoperative results.

Methods: Of 468 patients in whom neurovascular free muscle transfer was performed between 1977 and 2000, a total of 183 received revisional operations for the transferred muscle. Operations included revision of muscle attachment in 129 patients, debulking of the cheek in 114 patients, and fascia graft in 21 patients.

Results: Evaluation with the grading scale was performed in 117 of the 183 patients. Grading improved in 59 patients and worsened in seven patients. The remaining 51 patients displayed no change in grading. Differences between preoperative and postoperative grading were compared statisti-

cally, and revisional operations improved the grading score.

Conclusions: Revisional operations are effective and important as secondary operations after neurovascular free muscle transfer. However, care must be taken not to damage the neurovascular pedicles. (*Plast. Reconstr. Surg.* 116: 371, 2005.)

The goal of facial reconstruction in long-standing facial paralysis is to achieve symmetry at rest, during voluntary motion, and during expression of emotion. Although all areas of the face, eyebrows, eyelids, mouth, and cheeks may require attention, one of the most important functions is the ability to smile voluntarily and thus facilitate emotional communication.¹ Numerous reconstructive procedures, including nerve transfer² and local muscle transfer,³ have been developed to achieve a natural-looking smile. Neurovascular free muscle transfer is now the mainstay for smile reconstruction.^{4,5} Since the introduction of neurovascular free muscle transfer by Harii et al.,⁶ problems such as excessive muscle bulk and dislocation of muscle attachment have been described. To solve the problem of excessive muscle bulk, Manktelow and Zuker⁷ refined use of the gracilis muscle by identifying independent neuromuscular units within the graci-

From the Department of Plastic and Reconstructive Surgery, School of Medicine, Kyorin University, and the Department of Plastic and Reconstructive Surgery, Graduate School of Medicine, University of Tokyo. Received for publication February 27, 2004; revised November 17, 2004.

Presented at the 13th International Congress of the International Confederation for Plastic, Reconstructive and Aesthetic Surgery, in Sydney, Australia, August 10 to 15, 2003.

DOI: 10.1097/01.PRS.0000169687.94376.78

lis. Dellon and Mackinnon^{8,9} also used a small, segmentally innervated portion of the latissimus dorsi muscle.

Fixation of transferred muscle on both the nasolabial and malar sides also represents an important factor for acquiring maximum excursion. Asato et al.¹⁰ used a disposable stapler to create a stable muscle end for accurate muscle fixation in the nasolabial fold line. Bartlett¹¹ reported that superior fixation was achieved using zygomatic arch periosteum and the superficial layer of deep temporal fascia. With such technical refinements, smiles acquired using neurovascular free muscle have improved. However, some cases still show unnatural smiling because of dislocation of muscle attachment (particularly in the nasolabial fold) or excessive bulk of the cheek resulting from the volume of transferred muscle. Furthermore, dynamic movement of transferred muscle is sometimes too strong or too weak, resulting in facial asymmetry.

In these cases, secondary revisional operations are required after neurovascular free muscle transfer. However, no reports have yet described revisional operations in detail, with only brief notions by Terzis and Noah,⁴ in which revision and debulking of free muscle were performed in 26 percent of patients, and O'Brien et al.,¹² in which release, debulking, and reinsertion of muscle were performed as secondary procedures. The present report describes revisional operative procedures in detail and analyzes the extent of improvement to the smile by comparing preoperative and postoperative results.

PATIENTS AND METHODS

Patient Profiles

Between 1977 and 2000, neurovascular free muscle transfer was performed in 468 patients with longstanding facial paralysis. Of these, 183 patients (39.1 percent) have received revisional operations to the transferred muscle, with one revisional operation in 128 patients, two in 39 patients, three in 10 patients, and four in six patients. Operations included revision of attachment, debulking of cheek, and fascia graft (Table I). Revision of muscle attachment was performed from either a nasolabial fold incision ($n = 92$) or a preauricular incision ($n = 37$). Debulking of cheek protrusion was performed by debulking transferred muscle with subcutaneous fat tissue from a

TABLE I
Revisional Operations

Type of Operation	No. of Patients
Revision of attachment	
Nasolabial fold incision	92
Preauricular incision	37
Debulking of the cheek	
Muscle debulking	100
Liposuction	14
Fascia transfer	21

preauricular or nasolabial incision ($n = 100$) or by liposuction of buccal subcutaneous fat ($n = 14$). Fascia graft was performed for muscle elongation or lower lip suspension ($n = 21$).

Evaluation

The grading scales⁵ shown in Table II are used to evaluate the results of neurovascular free muscle transfer. These were applied to revisional operations by comparing results before and after revisional operations in 117 patients. When several revisional operations were performed, results were evaluated after all revisional operations. Grading scores were statistically compared between those obtained preoperatively and postoperatively using the McNemar test.

TABLE II
Evaluation Criteria

Grade	Description
5	Symmetric balance and good facial tone at rest Sufficient muscle power upon voluntary contraction Synchronous and natural expression upon emotional facial movements, especially upon smiling EMG demonstrating relatively high amplitudes with full interference patterns and high evoked potential obtained upon stimulation of the contralateral facial nerve
4	Symmetric balance and good facial tone at rest Active muscle contraction acquired but not sufficiently synchronous (too strong or slightly weak) EMG demonstrating good interference patterns and evoked potentials Results well accepted by the patients
3	Symmetric balance and good facial tone at rest Insufficient contraction of the muscle Low volitional EMG spikes with discrete interference patterns
2	Reduced symmetric balance upon smiling No effective contraction of the muscle EMG with no interference patterns
1	No correction Electrically silent EMG
0	No follow-up

Operative Procedures

Revision of attachment (nasolabial end). When neurovascular muscle is transferred to the cheek pocket, the proximal muscle end is fixed to the lateral aspect of the atrophied orbicularis oris muscle to create symmetrical nasolabial folds on smiling. However, asymmetry sometimes occurs, typically because of dislocation of muscle attachment to the superolateral side. Under such conditions, muscle attachment on the nasolabial fold is revised.

A skin incision is made on the nasolabial fold line, taking particular care to avoid damaging the donor nerve where it crosses through the upper lip. Dissection from the skin incision to the superolateral buccal side enables exposure of the dislocated end of the transferred muscle. In most cases in which the muscle end is dislocated, dynamic movement of the transferred muscle is clinically weak. The muscle end is then pulled down to the mid lower side and again fixed to the lateral edge of the orbicularis oris muscle. Dermis and epithelium are sutured layer to layer when the nasolabial fold on the normal side is not deep. However, when the nasolabial fold on the normal side is deep, as is often seen in elderly patients, two skin strips beside the incision line are deepithelialized by approximately 5 mm on each side. Denuded skin on the buccal side is then turned upside-down and the upper surfaces of denuded skin on both sides are sutured (Fig. 1). With this manipulation, buccal skin just lateral to the nasolabial line protrudes slightly

anteriorly, facilitating a natural-looking nasolabial fold.

Revision of attachment (zygomatic end). In neurovascular free muscle transfer procedures, the distal muscle end is fixed around the zygomatic arch. When facial paralysis is complete, part of the soft tissue on the zygoma is resected, and transferred muscle is fixed to the periosteum of the arch for rigid fixation.^{13,14} However, this procedure cannot be sufficiently performed in patients with incomplete paralysis, given the possibility of damaging residual facial nerve function. Transferred muscle is thus fixed to soft tissue on the zygomatic arch, which tends to loosen in the direction of the nasolabial fold. Under such conditions, muscle attachment in the zygomatic end should be pulled up again. The zygomatic muscle end is also pulled up again when muscle power is weak both electromyographically and clinically.

The preauricular incision for muscle transfer is therefore reused to expose the zygomatic muscle end. The upper surface of the muscle is dissected lateral to the nasolabial fold. If dissection is stopped halfway at the middle of the cheek, dimples or wrinkles on the buccal skin may become conspicuous. Because the muscle is placed with neurovascular bundles on the undersurface, dissection of the upper surface of the muscle can be performed safely. In two-stage methods combining free muscle transfer with cross-face nerve grafting, however, nerve suture between the cross-face nerve and the motor nerve of the transferred muscle is usu-

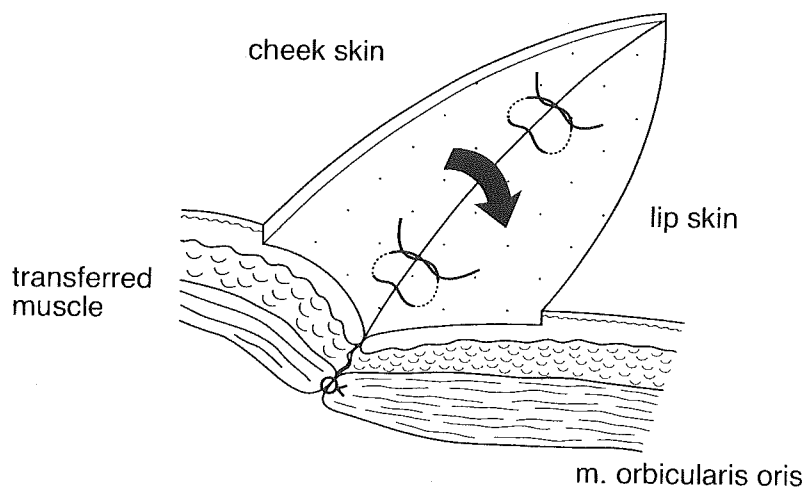


FIG. 1. Schema for revision of attachment (nasolabial end). Skin tissue on both sides of the incision is denuded to approximately 5 mm wide. Denuded skin on the buccal side is then turned upside-down and the upper surfaces of the denuded skin on both sides are sutured to create a nasolabial fold.

ally performed around the preauricular region. Dissecting the undersurface of the transferred muscle in this region to shorten the muscle is then difficult and risky. Conversely, when one-stage methods using the latissimus dorsi muscle⁵ are used, dissection of the muscle undersurface can be safely performed half-way to nasolabial fixation, because the neurovascular hilus is around the nasolabial region. Dissected muscle is then pulled superolaterally and again sutured to firm tissue over the zygoma.

Debulking the cheek. Because the paralyzed cheek is depressed as a result of facial muscle atrophy, symmetry in both cheeks is usually achieved after neurovascular muscle transfer. However, excessive muscle bulk is sometimes evident, requiring debulking of muscle volume. When bulkiness is severe, the upper surface of the transferred muscle is dissected from a preauricular incision, a nasolabial incision, or both. Transferred muscle and some of the subcutaneous fatty tissue above the muscle are then resected to leave a suitable volume. As noted above, the neurovascular bundles are on the undersurface of the muscle, so debulking of the upper surface can be safely performed.

When excess bulk in the cheek is not severe, liposuction of subcutaneous fat tissue without muscle debulking is usually sufficient to obtain symmetry of cheek contour. The suction cannula is inserted from the scar of the preauricular incision for liposuction on the zygomatic half of the transferred muscle. For liposuction on the nasolabial half of the muscle, a small wound is applied on the nasolabial fold line or beneath the chin.

Fascia graft. When asymmetry in the lower lip is evident, fascia grafting proves effective. After a skin incision is made on the nasolabial fold line, the nasolabial end of the muscle is dissected without damaging the neurovascular pedicles. A fascia strip 1 to 2 cm in width is harvested from the lateral thigh. This is then passed through the lower lip and fixed to the orbicularis oris muscle at the center of the lower lip, and the other end of the fascia is fixed to the nasolabial end of the muscle so that the lower lip is elevated with contraction of the transferred muscle (Fig. 2).

Fascia grafting is again effective when contraction of the transferred muscle is too strong and tight. After making a skin incision on the nasolabial fold line, a fascia strip is interposed between the lateral edge of the orbicularis oris

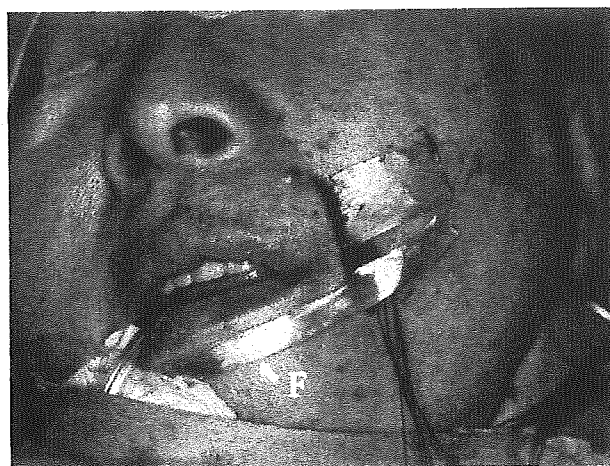

FIG. 2. Fascia is grafted when asymmetry in the lower lip is evident. A fascia (F) is passed through the lower lip and fixed to the orbicularis oris muscle at the center of the lower lip, whereas the other end of the fascia is fixed to the nasolabial end of the muscle so that the lower lip is elevated with contraction of the transferred muscle.

muscle and the transferred muscle, effectively elongating the muscle and reducing its contractile power.

RESULTS

Comparisons between preoperative and postoperative results on the 117 patients who could be followed-up for at least 1 year are shown in Table III. Grade was improved in 59 patients, unchanged in 51 patients, and worsened in seven patients. The two patients with a preoperative grade of 2 were unchanged postoperatively. Of the 22 patients with a preoperative grade of 3, improvement to grade 4 was observed in 15 (68 percent), but seven patients (32 percent) were unchanged. Of the 66 patients with a preoperative grade of 4, improve-

TABLE III
Change of the Grading Scale before and after Revisional Operations

Scale of Pre-Operation (No. of Patients)	Scale of Post-Operation	No. of Patients		
		Worsened	Unchanged	Improved
Grade 2 (2)	Grade 2		2	
Grade 3 (22)	Grade 3		7	
	Grade 4			15
Grade 4 (66)	Grade 2	2		
	Grade 3	4		
	Grade 4		16	
	Grade 5			44
Grade 5 (27)	Grade 4	1		
	Grade 5		26	
Total 117		7	51	59

McNemar test revealed that the revisional operations improved the grading scores ($p < 0.01$).

ment to grade 5 was seen in 44 patients (67 percent), whereas 16 patients (24 percent) were unchanged, four patients (6 percent) worsened to grade 3, and two patients (3 percent) worsened to grade 2. In these two patients with worsening to grade 2, nerves innervating the transferred muscle appear to have been damaged during revisional operations. Twenty-seven patients who had already scored 5 (at the top end of the scale) underwent revisional operations for further improvement. Of the 27 patients with a preoperative grade 5, one patient worsened to grade 4 (4 percent) postoperatively, whereas 26 patients (96 percent) were unchanged. Statistical analysis using the McNemar test revealed that the revisional operations improved the grading scores (McNemar test, $p < 0.01$).

CASE REPORTS

Case 1

A 44-year-old man presented with irreversible Bell's palsy on the right side that had begun approximately 5 years earlier. A one-stage method using latissimus dorsi muscle was performed for smile reconstruction, with gold plate lid-loading in the paralyzed upper eyelid as an ancillary procedure. Thoracodorsal vessels were anastomosed to the right facial vessels and the thoracodorsal nerve was passed through the upper lid and sutured to the contralateral branch of the facial nerve. Two years postoperatively, clinical muscle movement on smiling was noticed but was considered insufficient, showing a grade of 4, although electromyography revealed high-amplitude action potentials with good interference patterns. Because excessive muscle bulk was also evident, a revisional operation was planned. The nasolabial fold line was incised and the thoracodorsal nerve exposed to avoid accidental damage. The dislocated nasolabial muscle end was then exposed, and dissection on the transferred muscle was undertaken on the superolateral side without damaging the vascular pedicles. Redundant muscle with overlying buccal subcutaneous fat was debulked to improve symmetry of cheek contour on the contralateral side. Skin strips approximately 5 mm in width on both labial and buccal sides were deepithelialized to create denuded flaps, and dermis of the buccal flap was turned over the dermis of the labial side to create the nasolabial fold. Three years after the revisional operation, near-natural movements on smiling were obtained and cheek contour was symmetrical. Grading had improved from 4 to 5 (Fig. 3).

Case 2

A 45-year-old man experienced complete facial paralysis on the right side resulting from longstanding Bell's palsy starting 9 years earlier. In the first operation, a cross-face nerve graft using a sural nerve segment was placed through the upper lip with gold plate lid-loading, which was resected because of exposure 4 months later. At 10 months after cross-face nerve graft, neurovascular free gracilis muscle was transferred, with concomitant transfer of temporal muscle to the eyelids for eye closure and juxta-brow skin excision for brow

lift. By 2 years postoperatively, muscle movement on smiling was good. However, asymmetry of the cheek caused by excessive bulk of the transferred muscle was evident with a grade of 4. In the revisional operation, vascular pedicles of the gracilis muscle that were anastomosed to the superficial temporal vessels were first dissected from the preauricular incision. The upper surface of the transferred muscle was then dissected, followed by reduction of muscle bulk. Protrusion of the transferred muscle during smiling was marked before the revisional operation but had disappeared by 3 years after the revisional operation, with improvement to grade 5 (Fig. 4).

Case 3

A 45-year-old woman presented with a 2-year history of complete irreversible Bell's palsy on the right side. Latissimus dorsi muscle was transferred for smile reconstruction and the ptotic eyebrow was lifted using an endoscope. Transferred muscle contraction was first recognized 6 months after neurovascular free muscle transfer. At 2 years postoperatively, the reconstructed cheek was bulky because of transferred muscle volume, although muscle contraction was good and the grade was 5. Because bulkiness of the cheek was slight, liposuction was scheduled for cheek reduction. Liposuction was performed through two small stab incisions placed on the preauricula and nasolabial fold line. One year after revisional operation, cheek contours on both sides were symmetrical without worsened movement of transferred muscle. The grade remained at 5 (Fig. 5).

Case 4

A 53-year-old man presented with facial palsy caused by Bell's palsy on the left side that had started 3 years previously. Latissimus dorsi muscle was transferred with juxta-brow skin excision for brow lift and temporal muscle transfer to the eyelids for eye closure. As of 1 year postoperatively, muscle movement was recognized. However, contractile power was insufficient, particularly in the lower lip, and the grade was 4. Fascia transfer was therefore planned for lower lip elevation. In the revisional operation, the nasolabial fold line was first incised and the fascia was transferred through a tunnel created in the lower lip. Both ends were fixed to the orbicularis oris muscle near the center of the lower lip and the edge of the transferred muscle. Finally, the nasolabial fold was created as indicated in Figure 1. By 1 year after fascia transfer, facial contours had improved and a grade of 5 was achieved (Fig. 6).

DISCUSSION

Since neurovascular free muscle transfer was developed as a new operative procedure for facial reanimation,⁶ one key concern has been which muscle should be selected as a donor to achieve a natural-looking smile with sufficient excursion of transferred muscle. For this purpose, many types of muscles have been selected, including gracilis,⁶ pectoralis minor,¹⁵ abductor hallucis,¹⁶ rectus abdominis,¹⁷ and latissimus dorsi.⁸ In addition to seeking a novel muscle, refinements of operative procedure have been also developed.¹³ To avoid cheek bulkiness caused by volume of the transferred

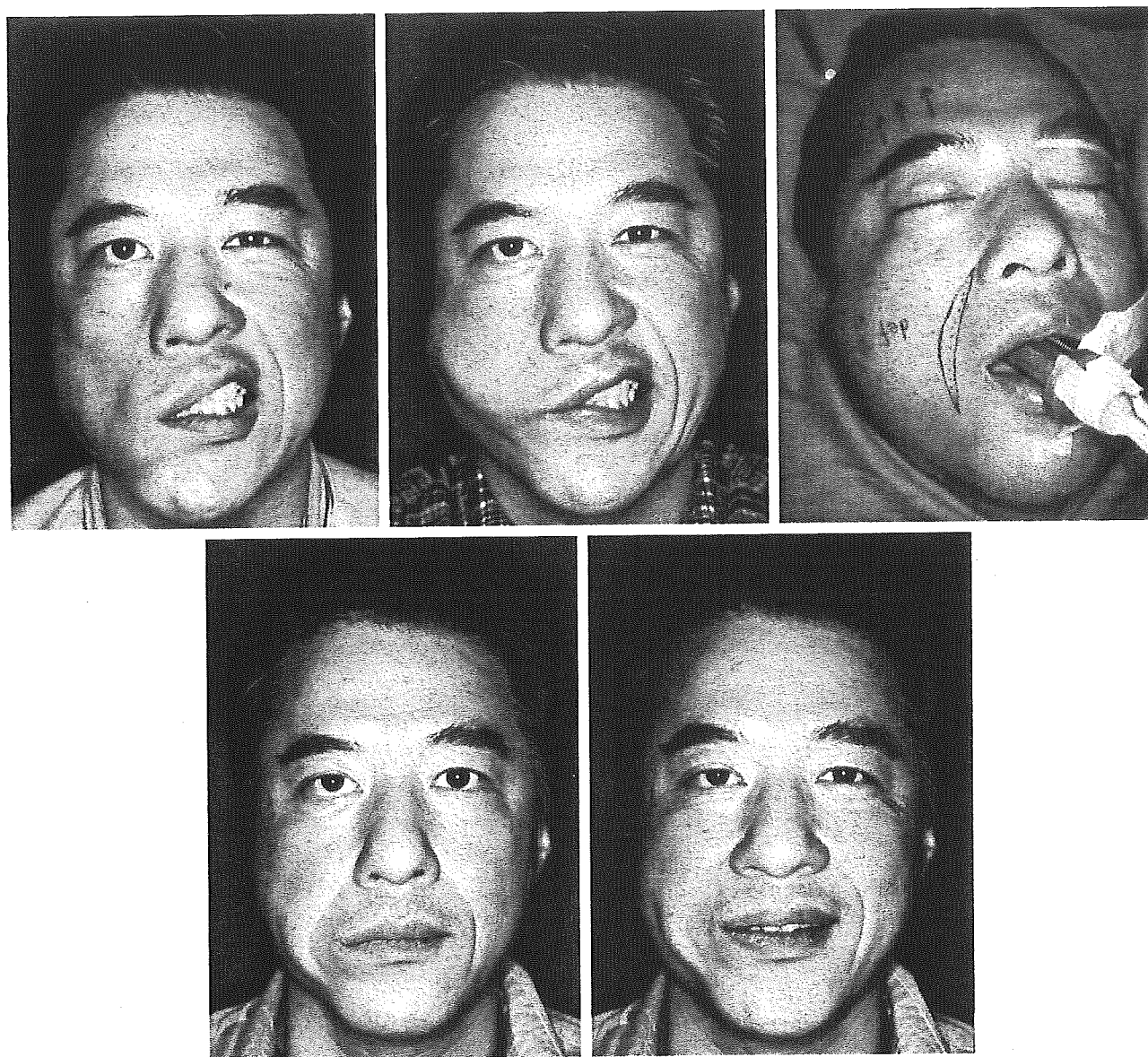


FIG. 3. A 44-year-old man with irreversible Bell's palsy on the right side. (*Above, left*) Preoperative appearance on smiling. (*Above, center*) Two years after latissimus dorsi transfer. Dislocation of the nasolabial end of the transferred muscle and cheek bulk because of muscle volume are evident. (*Above, right*) The dislocated nasolabial end was reattached to create a new nasolabial fold and redundant muscle volume was debulked. (*Below*) Appearance 3 years after revisional operation. The grade has improved from 4 to 5.

muscle, segmental use of the gracilis⁷ and latissimus dorsi⁹ muscles has been proposed. The reason why muscle bulkiness represents a problem is that estimating how much transferred muscle will prove atrophic is very difficult. According to Guelinckx et al.,¹⁸ a major portion of decreases in muscle mass and impairments in force arise from tenotomy and repair. However, muscle atrophy caused by denervation should also be considered.⁴ According to Frey, approximately double the muscle volume necessary to be replaced has to be planned,¹⁹

based on experimental results.²⁰ Because Frey used the two-stage method combining the free muscle transfer with cross-face nerve grafting, this rough formula is not applicable to all operative methods like the one-stage method. This is because the extent of muscle atrophy depends on the period of denervation, the number of nerve sutures, and the speed of axon recovery. Determining the amount of muscle to be transferred to obtain symmetry of facial contour with the desired dynamic results thus remains very difficult. Consequently, mus-

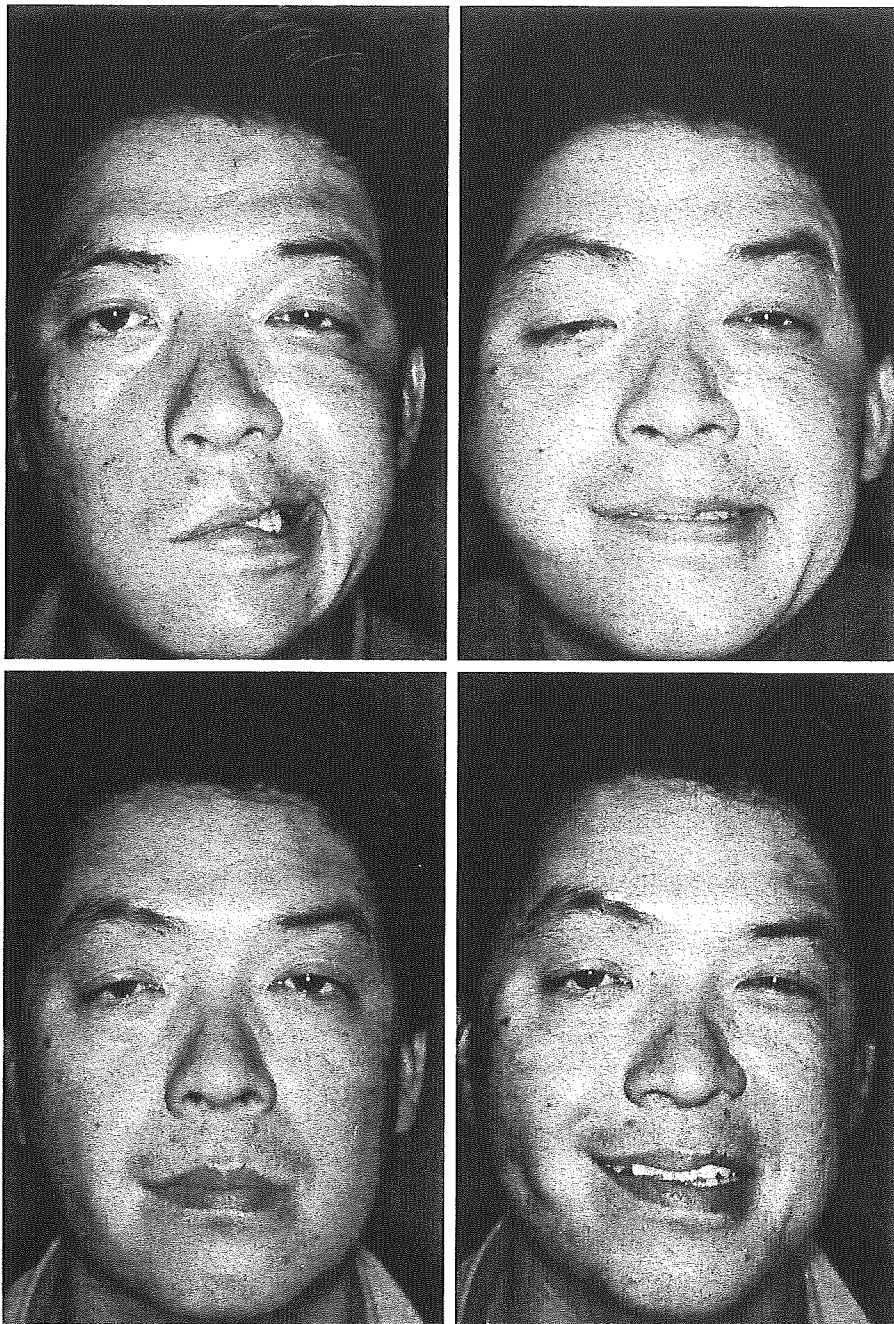


FIG. 4. A 45-year-old man with established facial paralysis on the right side caused by Bell's palsy. (*Above, left*) Preoperative appearance on smiling. (*Above, right*) Appearance 2 years after gracilis muscle transfer, which was performed 10 months after cross-face nerve graft. (*Below*) Appearance 3 years after a revisional operation. Grading has improved from 4 to 5.

cle debulking for cheek contour is required in many cases.

Besides volume of the transferred muscle, tension of transferred muscle has not yet been well delineated. Some surgeons suggest fixing the muscle under original muscle resting tension,¹⁹ whereas others suggest fixing the muscle under sufficient tension to keep the angles

of the mouth either symmetrical in the operative paralyzed state¹⁵ or slightly overcorrected for the deformity.¹² Harii et al. also described fixing the muscle end, giving proper tension to the muscle segment.⁵ However, muscle contraction after innervation can be too weak or strong, resulting in the need for revisional operations. Furthermore, when muscle is fixed

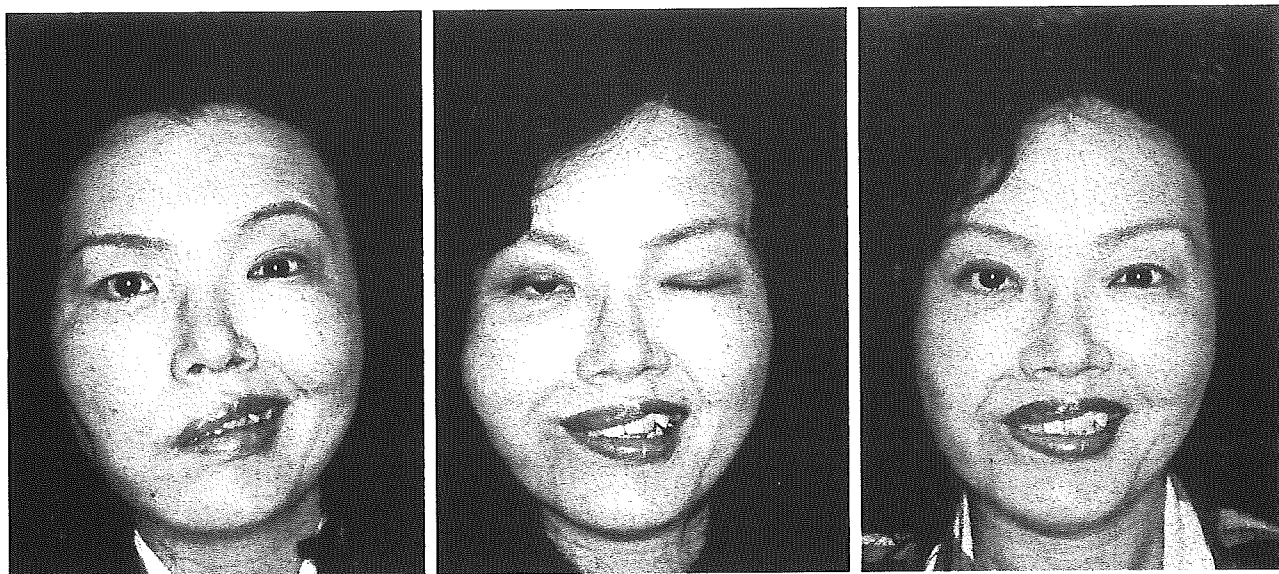

FIG. 5. A 45-year-old woman presented with irreversible Bell's palsy on the right side. (*Left*) Preoperative appearance on smiling. (*Center*) Appearance 2 years postoperatively. Muscle movement was sufficient, showing a grade of 5, with slight asymmetry of cheek contour. (*Right*) Appearance 1 year after liposuction of subcutaneous cheek fat. The grade is unchanged, although cheek contour is improved.

under relatively strong tension, suture sites sometimes break and slip out of place because of the fragility of the muscle end, although a pull-out suspension suture is placed for resting tension to the muscle for 2 weeks, and a device that staples the muscle end to a secure anchoring is used.¹⁰ This results in malpositioning of the newly created nasolabial fold or masking of muscle contraction as if distance of the transferred muscle excursion is small. Restoring the muscle end is then required in revisional operations.

Although several situations that require revisional operations have been detected, these symptoms are not independent of each other, but are closely related. For example, when the nasolabial muscle end is dislocated, muscle weakness is often noticed along with asymmetry of the nasolabial fold line. Also, when the zygomatic muscle end is dislocated, both overbulking of the cheek and muscle weakness are noticed. Revisional operations should therefore be selected depending on the condition of the individual patient.

In this series, revisional operations were limited to revision of attachments, debulking of the cheek, and fascia graft, as these operations are directly associated with neurovascular free muscle transfer. However, minor operations other than these are often performed simultaneously or separately to neurovascular muscle transfer. Neurectomy of the mandibular

branch or myectomy of the depressor muscle of the lower lip on the nonparalyzed side is effective for improving symmetry of the lower lip on smiling. Lipoinjection to the deformed cheek is also effective for aesthetic improvement. However, these techniques were not evaluated in this series, as they are not directly associated with neurovascular free muscle transfer.

The effect of revisional operations was evaluated using the grading scale that was originally developed to evaluate smiling results after neurovascular free muscle transfer. This scale is therefore not suitable for evaluating the results of the revisional operation itself. For example, when a revisional operation is performed on patients whose score was already grade 5 (at the top end of the scale), scoring improvement cannot be achieved, even though improvements might be apparent following revisional operations. This is because no grade is higher than grade 5. In our series, 26 of the 27 patients with a preoperative grade of 5 displayed no change in score postoperatively. However, among these 26 patients, clinical improvements that could not be elucidated using our grading scale might be achieved. Nevertheless, revisional operations improved the results in 59 of the 117 patients who could be evaluated preoperatively and postoperatively using our grading scale, and statistical analysis using the McNemar test revealed that revisional op-

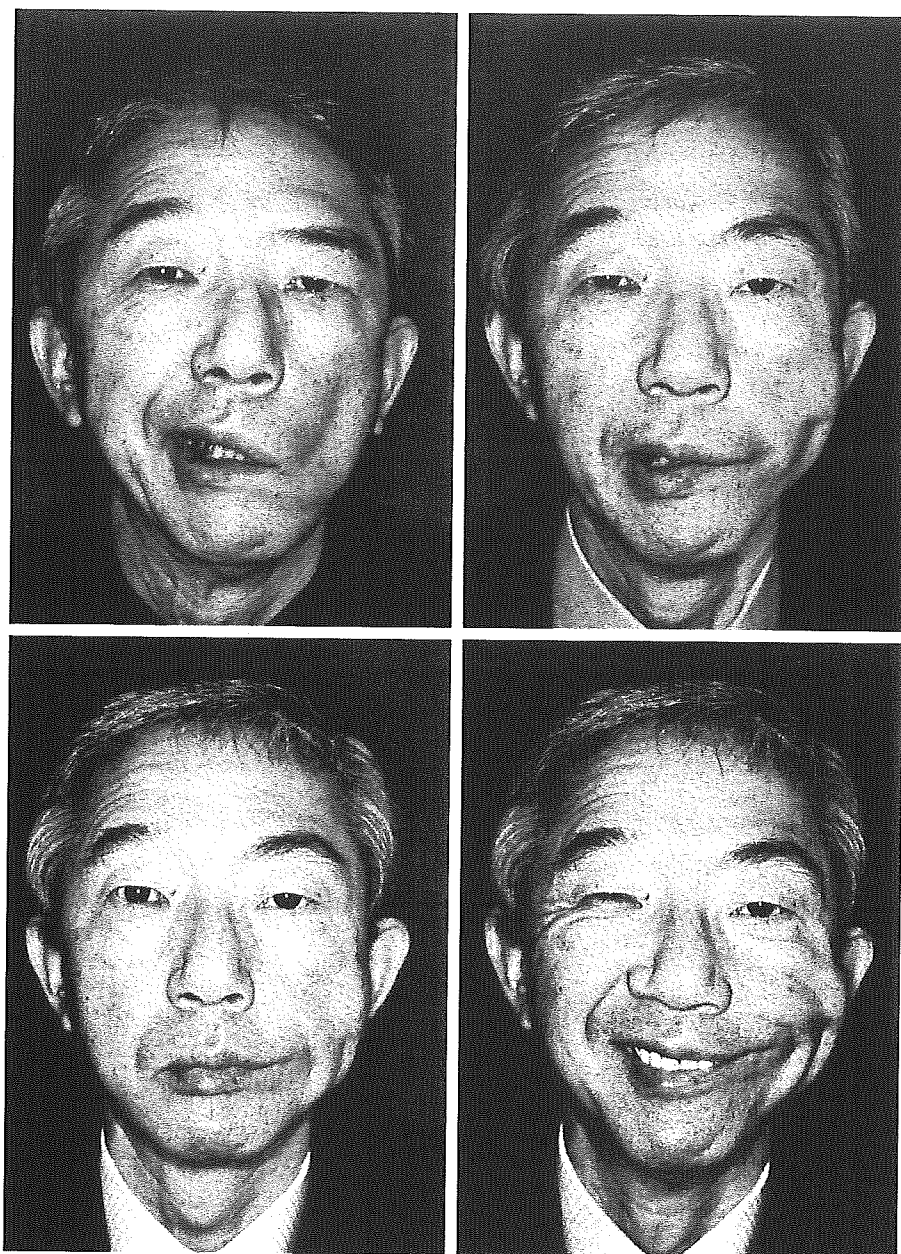


FIG. 6. A 53-year-old man presented with facial palsy caused by irreversible Bell's palsy on the left side. (*Above, left*) Preoperative appearance on smiling. (*Above, right*) Appearance 1 year after one-stage smile reconstruction using latissimus dorsi muscle. Contractile power was insufficient, particularly in the lower lip, with a grade of 4. (*Below*) Appearance 1 year after fascia transfer. The grade has improved to 5.

erations improved the grading score. Revisional operations can therefore prove effective and important as secondary interventions after neurovascular free muscle transfer.

However, development of transferred muscle function itself after revisional operations remains suspicious. Do muscle fibers increase in number and muscle power following stretching of dislocated muscle in revisional operations? Muscle length reduction and tenotomy

are well known to impair muscle function.^{21,22} As noted before, Guelinckx et al. insist that the major portion of decreased muscle mass and impairments in force arise from tenotomy and repair.¹⁸ However, little is known regarding muscle force and power after muscle stretching, although morphologic changes have been reported in a stretched avian model.^{23,24} According to Alway et al.,²⁵ muscle stretch resulted in enlargement of the anterior latissi-

mus dorsi muscle and an increase in the number of muscle fibers in adult quails. However, no studies regarding practical measurements of muscle power and force or changes to excursion length in stretched muscle models have been reported. In our series, electromyographic improvements were not clearly seen in any patient who displayed improved grade. The main cause for the improved grade is thus attributed to more conspicuous movement of transferred muscle caused by increased muscle tension following revisional operations.

CONCLUSIONS

Problems after neurovascular free muscle transfer for treatment of facial paralysis include excessive muscle bulk and dislocation of muscle attachment. Muscle contractions that are too strong or too weak also represent a problem. The present study revealed that revisional operations for the already transferred muscle are effective for achieving symmetrical facial contours and a near-natural smile.

Akihiko Takushima, M.D.

Department of Plastic and Reconstructive Surgery
Kyorin University School of Medicine
6-20-2, Shinkawa, Mitaka-shi
Tokyo 181-8611, Japan
takushima-pla@umin.ac.jp

REFERENCES

1. Manktelow, R. T. Free muscle transplantation for facial paralysis. *Clin. Plast. Surg.* 11: 215, 1984.
2. Conley, J., and Baker, D. C. Hypoglossal-facial nerve anastomosis for reinnervation of the paralyzed face. *Plast. Reconstr. Surg.* 63: 63, 1979.
3. Baker, D. C., and Conley, J. Regional muscle transposition for rehabilitation of the paralyzed face. *Clin. Plast. Surg.* 6: 317, 1979.
4. Terzis, J., and Noah, M. Analysis of 100 cases of free-muscle transplantation for facial paralysis. *Plast. Reconstr. Surg.* 99: 1905, 1997.
5. Harii, K., Asato, H., Yoshimura, K., et al. One-stage transfer of the latissimus dorsi muscle for reanimation of a paralyzed face: A new alternative. *Plast. Reconstr. Surg.* 102: 941, 1998.
6. Harii, K., Ohmori, K., and Torii, S. Free gracilis muscle transplantation, with microneurovascular anastomoses for the treatment of facial paralysis: A preliminary report. *Plast. Reconstr. Surg.* 57: 133, 1976.
7. Manktelow, R. T., and Zuker, R. M. Muscle transplantation by fascicular territory. *Plast. Reconstr. Surg.* 73: 751, 1984.
8. Dellon, A. L., and Mackinnon, S. E. Segmentally innervated latissimus dorsi muscle: Microsurgical transfer for facial reanimation. *J. Reconstr. Microsurg.* 2: 7, 1985.
9. Mackinnon, S. E., and Dellon, A. L. Technical considerations of the latissimus dorsi muscle flap: A segmentally innervated muscle transfer for facial reanimation. *Microsurgery* 9: 36, 1988.
10. Asato, H., Harii, K., Nakatsuka, T., and Yoshimura, K. Use of the disposable stapler to insure proper fixation of a transferred muscle in treatment of facial paralysis. *J. Reconstr. Microsurg.* 14: 199, 1998.
11. Bartlett, S. P. Smile reconstruction using the serratus anterior muscle. *Oper. Tech. Plast. Reconstr. Surg.* 6: 190, 1999.
12. O'Brien, B. M., Pederson, W. C., Khazanchi, R. K., et al. Results of management of facial palsy with microvascular free-muscle transfer. *Plast. Reconstr. Surg.* 86: 12, 1990.
13. Harii, K. Refined microneurovascular free muscle transplantation for reanimation of paralyzed face. *Microsurgery* 9: 169, 1988.
14. Harii, K. Microneurovascular free muscle transplantation. In L. R. Rubin (Ed.), *The Paralyzed Face*. St. Louis: Mosby, 1991. Pp. 178-200.
15. Harrison, D. H. The pectoralis minor vascularized muscle graft for the treatment of unilateral facial palsy. *Plast. Reconstr. Surg.* 75: 206, 1985.
16. Jiang, H., Guo, E. T., Ji, Z. L., Zhang, M. L., and Lu, V. One-stage microneurovascular free abductor hallucis muscle transplantation for reanimation of facial paralysis. *Plast. Reconstr. Surg.* 96: 78, 1995.
17. Hata, Y., Yano, K., Matsuka, K., et al. Treatment of chronic facial palsy by transplantation of the neurovascularized free rectus abdominis muscle. *Plast. Reconstr. Surg.* 86: 1178, 1990.
18. Guelinckx, P. J., Faulkner, J. A., and Essig, D. A. Neurovascular-anastomosed muscle grafts in rabbits: Functional deficits result from tendon repair. *Muscle Nerve* 11: 745, 1988.
19. Frey, M. Smile reconstruction using the gracilis muscle. *Oper. Tech. Plast. Reconstr. Surg.* 6: 180, 1999.
20. Frey, M., Giovanoli, P., and Meuli-Simmen, C. The qualification of different free muscle transplants to reconstruct mimic function: An experimental study in rabbits. *Plast. Reconstr. Surg.* 101: 1774, 1998.
21. Kadhiresan, V. A., Guelinckx, P. J., and Faulkner, J. A. Tenotomy and repair of latissimus dorsi muscles in rats: Implications for transposed muscle grafts. *J. Appl. Physiol.* 75: 1294, 1993.
22. Sancesario, G., Massa, R., Anzil, A. P., and Bernardi, G. Active muscle length reduction progressively damages soleus in hindlimb-suspended rabbits. *Muscle Nerve* 15: 1002, 1992.
23. Sola, O. M., Christensen, D. L., and Martin, A. W. Hypertrophy and hyperplasia of adult chicken anterior latissimus dorsi muscles following stretch with and without denervation. *Exp. Neurol.* 41: 76, 1973.
24. Kennedy, J. M., Eisenberg, B. R., Reid, S. K., Sweeney, L. J., and Zak, R. Nascent muscle fiber appearance in overloaded chicken slow-tonic muscle. *Am. J. Anat.* 181: 203, 1988.
25. Alway, S. E., Winchester, P. K., Davis, M. E., and Gonyea, W. J. Regionalized adaptations and muscle fiber proliferation in stretch-induced enlargement. *J. Appl. Physiol.* 66: 771, 1989.

REVIEW ARTICLE

Yuhei Yamamoto

Mid-facial reconstruction after maxillectomy

Received: May 26, 2005

Abstract Reconstruction following extensive resection of the maxilla has been a challenging problem in the field of head and neck cancer surgery. At our institutes, maxillectomy defects have been restored based on the principles of repair involving the important concept of maxillary buttress reconstruction. Reconstruction of the zygomaticomaxillary buttress (ZMB), including the orbital floor, is essential for prevention of the malpositioning of the eyeball in preservation of the orbital contents. ZMB reconstruction is also important to provide a good contour of malar prominence. Pterygomaxillary buttress (PMB) reconstruction provides sufficient support for the fitting of a dental prosthesis. In patients with extensive resection of buccal soft tissue, a PMB and nasomaxillary buttress (NMB) should be reconstructed to prevent superior and posterior deviation of the alar base and oral commissure. We advocate that critical assessment of skeletal defects, as well as associated soft-tissue defects, following various types of maxillectomies is essential for a rational approach to achieve satisfactory clinical results.

Key words Maxillary reconstruction · Vascularized composite autograft · Maxillary buttress

Introduction

With the development of vascularized composite autografts using microsurgical techniques, reconstruction of extensive maxillary defects has been achieved to a high level of functional and esthetic results.^{1–11} In this article, the therapeutic concept of maxillary buttress reconstruction in mid-facial reconstruction after oncologic resection of the maxilla, at the Hokkaido University Hospital, is introduced.

Y. Yamamoto (✉)

Department of Plastic and Reconstructive Surgery, Graduate School of Medicine, Hokkaido University, Kita 14 Nishi 7, Kita-ku, Sapporo 060-8638, Japan
Tel. +81-11-716-1161; Fax +81-11-709-6574
e-mail: yu-h1@med.hokudai.ac.jp

Maxillary buttresses in reconstruction of maxillary skeletal defects

The important role of buttress reconstruction in the surgical management of maxillary skeletal defects has been addressed.⁵ The midfacial structure consists of three principal maxillary buttresses, the zygomaticomaxillary (ZMB), pterygomaxillary (PMB), and nasomaxillary buttresses (NMB).

The ZMB extends from frontal process of the maxilla along the inferior ridge of the orbit to the zygomatic process of the frontal bone and laterally to the zygomatic arch. The PMB extends from the alveolar ridge anterior to the pterygoid plate of the sphenoid bone. The NMB extends from the anterior maxillary alveolus along the pyriform aperture to the nasal process of the maxilla (Fig. 1). Restoration of these buttresses is an important approach to obtain the most effective reconstruction of complex maxillectomy skeletal defects.¹

Three categories of maxillectomy defects

Maxillectomy defects have been classified into three categories based on the assessment of anatomic sites of resection.¹⁰

Category I includes limited maxillectomy and subtotal maxillectomy defects (Fig. 2a). In this category, the anterior and/or medial walls of the lower maxilla, including the palate, are mainly removed, with preservation of the orbital inferior ridge and floor. According to the buttress concept, the PMB and partial NMB are ablated.

Category II includes orbitomaxillectomy and orbitozygomaticomaxillectomy defects (Fig. 2b). In this category, the anterior and medial walls of the upper maxilla, including the orbital contents (orbital exenteration) are mainly removed, with preservation of the palate. The malar region, including the zygomatic arch, is occasionally resected in orbitozygomaticomaxillectomy defects. According to the buttress concept, the ZMB and partial NMB are ablated.

Category III includes total maxillectomy and extended total maxillectomy defects (Fig. 2c). In this category, the maxilla is completely removed without preservation of the orbital inferior ridge, the floor, or the palate. The orbital contents (orbital exenteration), malar region, including the zygomatic arch, and/or facial skin and/or mimetic muscle are occasionally resected in extended total maxillectomy defects. According to the buttress concept, the ZMB, PMB, and NMB are ablated.

Concepts underlying the surgical management of maxillectomy defects

Reconstruction of both skeletal and soft-tissue maxillectomy defects is ideal; however, various factors affect the choice of reconstructive method. The patient's age,

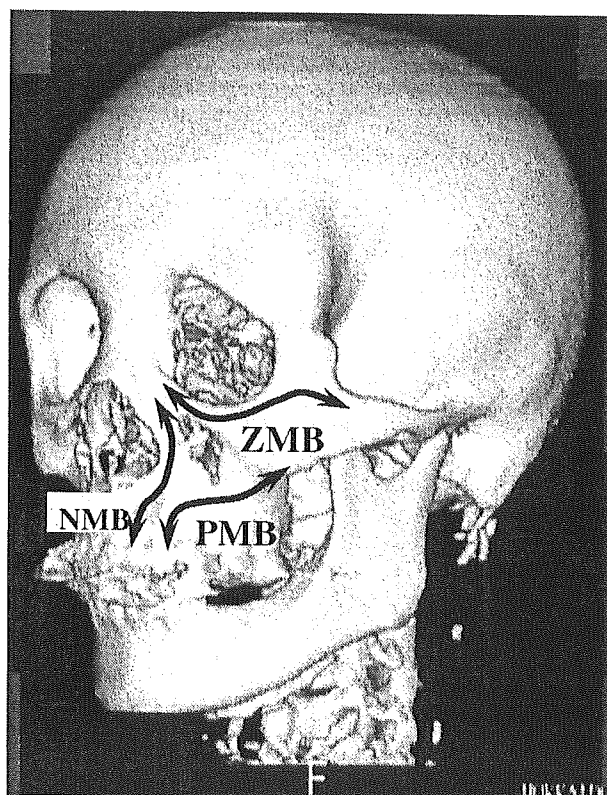
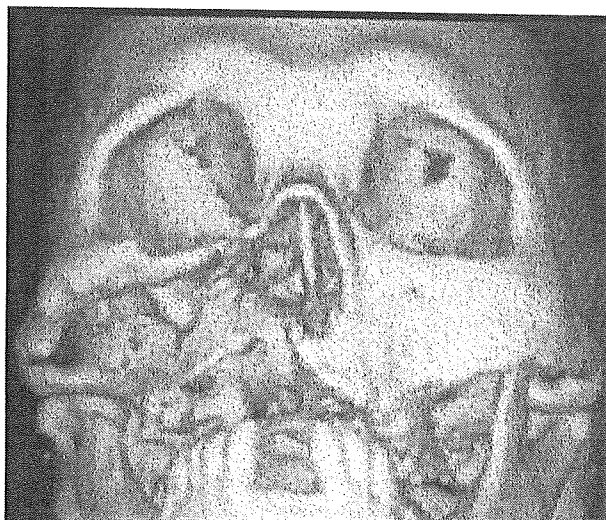
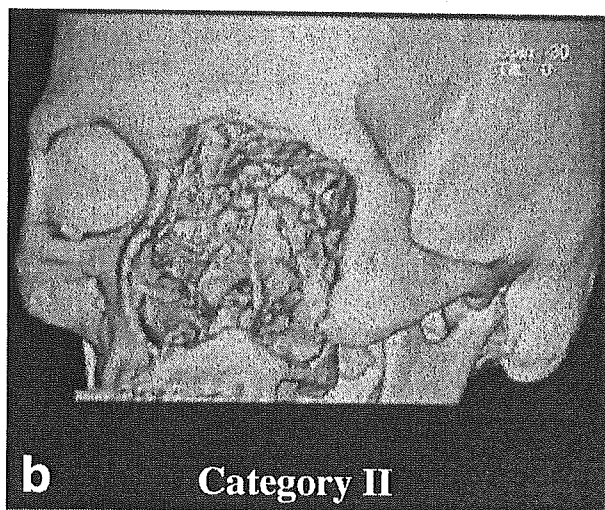


Fig. 1. Maxillary buttresses in the reconstruction of maxillary skeletal defects. *ZMB*, zygomaticomaxillary buttress; *PMB*, pterygomaxillary buttress; *NMB*, nasomaxillary buttress

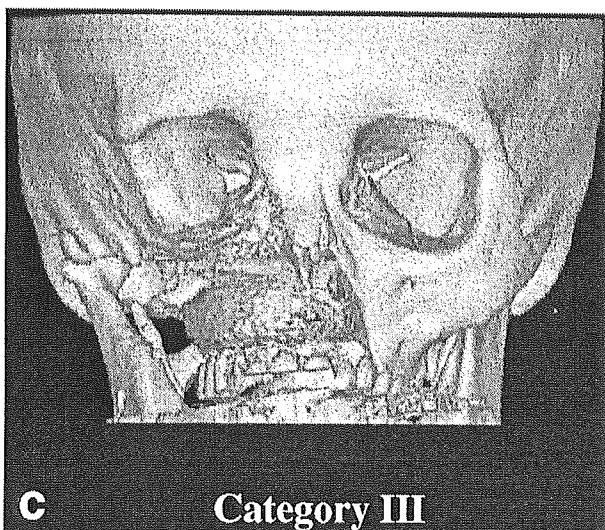
Fig. 2a-c. Three categories of maxillectomy defects shown in three-dimensional computed tomography (CT) scans. **a** Category I includes limited maxillectomy and subtotal maxillectomy defects. **b** Category II includes orbitomaxillectomy and orbitozygomaticomaxillectomy defects. **c** Category III includes total maxillectomy and extended total maxillectomy defects



a Category I



b Category II



c Category III

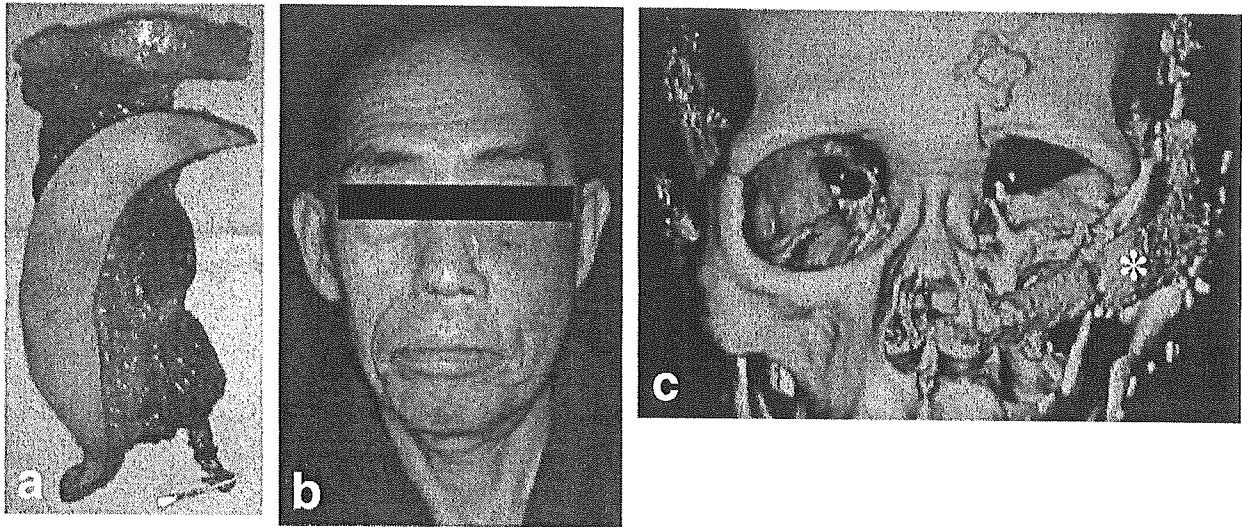


Fig. 3a-c. Reconstruction of the ZMB with vascularized costal cartilage combined with a rectus abdominis myocutaneous flap for a category I maxillary defect. **a** The rectus abdominis myocutaneous free flap combined with the eighth and ninth costal cartilage. The vascular pedicle of this composite graft is the deep inferior epigastric vascular

system and the eighth and ninth costal cartilages are supplied from the vascular connection between the eighth intercostal and deep epigastric vascular systems. **b** Postoperative frontal view. **c** Postoperative three-dimensional CT scan (asterisk, vascularized costal cartilage graft)

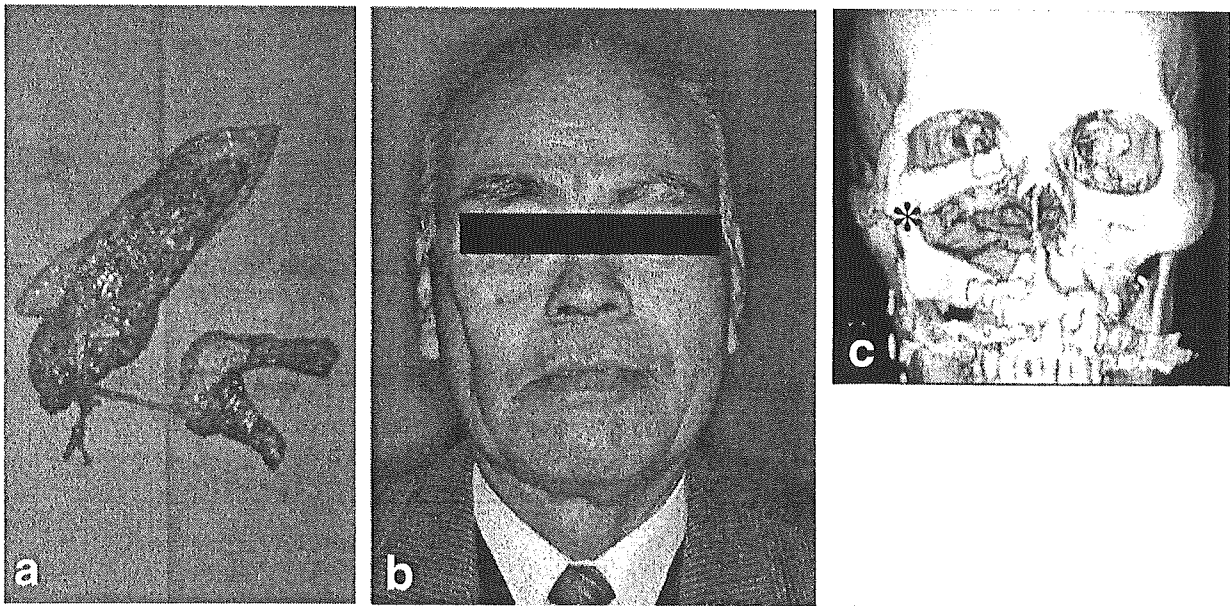


Fig. 4a-c. Reconstruction of two buttresses: the ZMB and PMB, with a latissimus dorsi myocutaneous flap combined with a V-shaped scapular bone for a category II maxillary defect. **a** The latissimus dorsi myocutaneous flap combined with V-shaped scapular bone. The vascular pedicle of this composite graft is the thoracodorsal vascular system

and the scapula is nourished by the angular branch. **b** Postoperative frontal view. **c** Postoperative three-dimensional CT scan. (asterisk, V-shaped scapular bone). The ZMB was reconstructed with the medial border of the scapula, and the PMB with the lateral border

associated diseases, degree of advanced carcinoma, and request for skeletal reconstruction from the surgical oncologist are important issues to be evaluated preoperatively. In the surgical restoration of maxillectomy defects, precise assessment and understanding of the mid-facial defects is the

first key point to approach effective maxillary reconstruction. The PMB is the main buttress to be reconstructed in category I maxillary defects. In a patient with extensive resection of buccal soft tissue, including mimetic muscle and skin, the NMB should be reconstructed to prevent superior

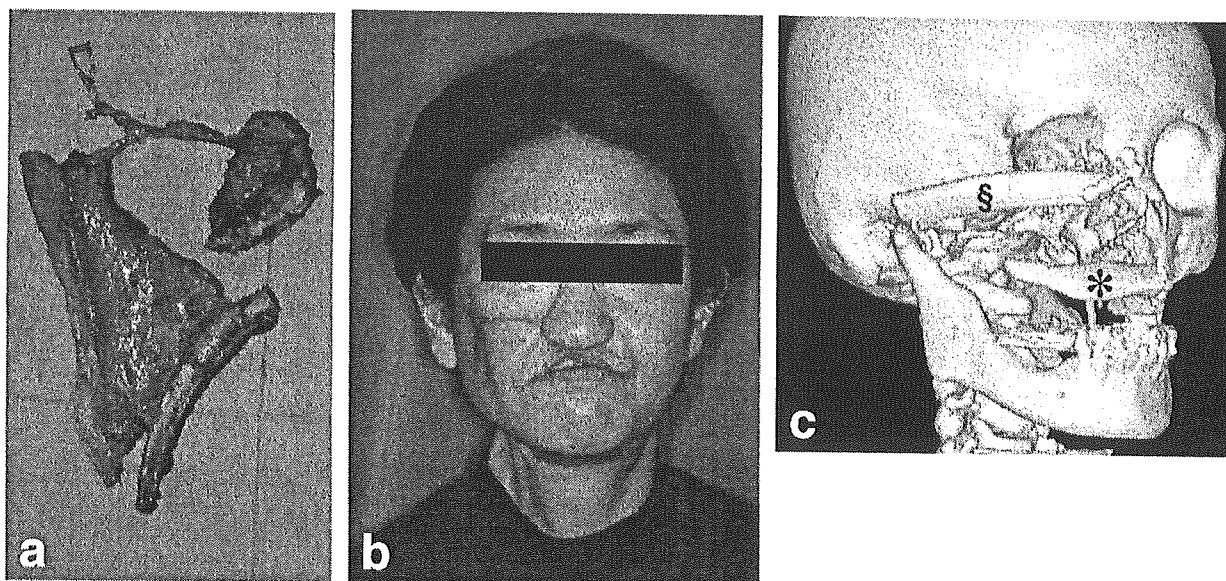


Fig. 5a-c. Reconstruction of three buttresses: the ZMB and PMB, and partial NMB, with the latissimus dorsi myocutaneous free flap, combined with V-shaped scapular bone and rib for a category III maxillary defect. **a** The latissimus dorsi myocutaneous flap combined with V-shaped scapular bone and eighth rib. The vascular pedicle of this composite graft is the thoracodorsal vascular system. The scapula is nourished by the angular branch, and the eighth rib is supplied from

the communicating perforators from the latissimus branch of the thoracodorsal to the eighth intercostal vascular system. **b** Postoperative frontal view. **c** Postoperative three-dimensional CT scan. (*asterisk*, V-shaped scapular bone, PMB reconstructed with the lateral border of the scapula, and partial NMB reconstructed with the medial border. \$, Vascularized rib grafted for restoration of the ZMB and zygomatic arch)

and posterior deviation of the alar base. The ZMB is the main buttress to be reconstructed in category II maxillary defects, especially those with extensive resection of the zygomatic process and arch. However, most category II defects do not require skeletal reconstruction. In category III maxillary defects, the ZMB and PMB are the main buttresses to be reconstructed. Reconstruction of all three buttresses is considered for patients with category III maxillary defects with extensive resection of the zygomatic process and arch and buccal soft tissue.

Reconstructive procedures using vascularized composite autografts

Several reconstructive techniques using vascularized composite autografts have been developed for maxillary reconstruction at our institutes.¹²⁻¹⁴

In the reconstruction of the ZMB, vascularized eighth and ninth costal cartilage, combined with a rectus abdominis myocutaneous flap, have been applied. The rectus abdominis myocutaneous flap combined with costal cartilage is a useful tool for the restoration of one buttress: the ZMB and a midfacial soft-tissue defect (Fig. 3).

In the reconstruction of the PMB, the lateral border of the scapula combined with a latissimus dorsi myocutaneous or scapular flap has been employed. We consider that the lateral border of the scapula is well tolerated for restoration

of the PMB because it has enough volume to provide reliable stability for the fitting of a dental prosthesis.

In the reconstruction of two buttresses, the latissimus dorsi myocutaneous or scapular flap, combined with a V-shaped scapular bone is a good indication. The medial border of the scapula is used for the ZMB restoration and lateral border for the PMB. The central space of the V-shaped scapular bone also allows for the placement of the bulk of the transferred flap (Fig. 4).

In the reconstruction of all three buttresses, the latissimus dorsi myocutaneous free flap combined with a V-shaped scapular bone and rib is a versatile technique to manage such complex skeletal defects (Fig. 5).

Acknowledgments The author would like to express his appreciation to Professor Satoshi Fukuda, MD, PhD, Department of Otolaryngology and Head and Neck Surgery, Graduate School of Medicine, Hokkaido University, for his valuable cooperation in head and neck cancer surgery.

References

1. Serafin D, Riefkohl R, Thomas I, et al. (1980) Vascularized rib-periosteal and osteocutaneous reconstruction of the maxilla and mandible: an assessment. *Plast Reconstr Surg* 66:718-727
2. Swartz WM, Banis JC, Newton ED, et al. (1986) The osteocutaneous scapular flap for mandibular and maxillary reconstruction. *Plast Reconstr Surg* 77:530-545

3. Granick MS, Ramasastry SS, Newton ED, et al. (1990) Reconstruction of complex maxillectomy defects with the scapular-free flap. *Head Neck* 12:377-385
4. Coleman JJ III, Sultan MR (1991) The bipedicle osteocutaneous scapula flap: a new subscapular system free flap. *Plast Reconstr Surg* 87:682-692
5. Yamamoto Y, Minakawa H, Kawashima K, et al. (1998) Role of buttress reconstruction in zygomaticomaxillary skeletal defects. *Plast Reconstr Surg* 101:943-950
6. Cordeiro PG, Santamaria E, Kraus DH, et al. (1998) Reconstruction of total maxillectomy defects with preservation of the orbital contents. *Plast Reconstr Surg* 102:1874-1884
7. Kyutoku S, Tsuji H, Inoue T, et al. (1999) Experience with the rectus abdominis myocutaneous flap with vascularized hard tissue for immediate orbitofacial reconstruction. *Plast Reconstr Surg* 103:395-402
8. Cordeiro PG, Santamaria E (2000) A classification system and algorithm for reconstruction of maxillectomy and midfacial defects. *Plast Reconstr Surg* 105:2331-2346
9. Kakibuchi M, Fujikawa M, Hosokawa K, et al. (2002) Functional reconstruction of maxilla with free latissimus dorsi-scapular osteomusculocutaneous flap. *Plast Reconstr Surg* 109:1238-1244
10. Yamamoto Y, Kawashima K, Sugihara T, et al. (2004) Surgical management of maxillectomy defects based on the concept of buttress reconstruction. *Head Neck* 26:247-256
11. Nakayama B, Hasegawa Y, Hyodo I, et al. (2004) Reconstruction using a three-dimensional orbitozygomatic skeletal model of titanium mesh plate and soft-tissue free flap transfer following total maxillectomy. *Plast Reconstr Surg* 109:1238-1244
12. Yamamoto Y, Sugihara T, Kuwahara H, et al. (1995) An anatomic study for the rectus abdominis myocutaneous flap combined with a vascularized rib. *Plast Reconstr Surg* 96:1336-1340
13. Yamamoto Y, Sugihara T, Kawashima K, et al. (1996) An anatomic study of the latissimus dorsi-rib flap: an extension of the subscapular combined flap. *Plast Reconstr Surg* 98:811-816
14. Yamamoto Y, Minakawa H, Kokubu I, et al. (1997) The rectus abdominis myocutaneous flap combined with vascularized costal cartilages in reconstructive craniofacial surgery. *Plast Reconstr Surg* 100:439-444

Arterial Blood Flow Changes after Free Tissue Transfer in Head and Neck Reconstruction

Mitsuru Sekido, M.D., Yuhei Yamamoto, M.D., Ph.D., and Tsuneki Sugihara, M.D., Ph.D.

Sapporo, Japan

Background: The authors measured pedicle arterial flow volume output using color Doppler ultrasonography in 23 patients after free tissue transfer in head and neck reconstruction.

Methods: Transferred flaps included six free jejunums, eight free radial forearm flaps, and four anterolateral thigh flaps. Flow volume output could be measured on all patients and was selectively measured in 17 patients with color Doppler ultrasonography on days 1, 4, 7, 14, 21, and 28 after surgery. The authors compared output change in different periods. In addition, they compared flow volume output on the first postoperative day in the different flaps and in the different recipient arteries and veins, and the effectiveness of irradiation in the different patients.

Results: Three of the 17 patients developed venous thrombosis. Flow volume output on the skin flaps increased gradually from day 1 to 7 after surgery and decreased gradually until day 28 in 14 patients without venous thrombosis. The free jejunum had more pedicle arterial blood flow than the skin flaps and it showed minimal flow volume output change. There were no significant differences among different recipient vessels or different skin flaps, or in the effectiveness of irradiation in the different patients. Three patients who developed venous thrombosis were salvaged by reanastomoses of the thrombosed vein.

Conclusions: Before reanastomosis, abnormal arterial waveform, decreasing flow volume output, and a lack of venous blood flow were observed in the patients who developed venous thrombosis. After reanastomoses, the output was significantly improved and the flaps survived completely in all three cases. The authors conclude that color Doppler ultrasonography is useful for detecting venous thromboses too. (*Plast. Reconstr. Surg.* 115: 1547, 2005.)

Free tissue transfer has become a popular and indispensable procedure in head and neck reconstruction that offers great advantages in head and neck reconstruction. Failure, however, results in disaster. The key to success for free tissue transfer is to get sufficient blood inflow and blood drainage in the transferred tissue. The main reasons for flap failure include vascular thrombosis, compression, and twisting. These causes can be recovered by reoperation if failure is discovered early. To find blood flow abnormalities, various methods have been reported. These methods include clinical observation of the flap temperature and color, pinprick test, laser Doppler flowmetry,¹ implantable Doppler probe,^{2,3} ultrasonic Doppler probe,⁴ Doppler ultrasound,⁵ and angiography. Color Doppler ultrasonography is widely used in cardiovascular surgery to assess the internal mammary artery blood flow.⁶ It is a simple, rapid, and noninvasive

From the Department of Plastic and Reconstructive Surgery, Hokkaido University Graduate School of Medicine. Received for publication December 11, 2003; revised May 21, 2004.

DOI: 10.1097/01.PRS.0000160273.17302.CE

method. There have been few reports about continuous blood flow monitoring after free tissue transfer over 1 week with color Doppler ultrasonography. In this study, we evaluated the flap arterial blood flow change after various kinds of free tissue transfer in head and neck reconstruction using color Doppler ultrasonography at various time points. In addition, we compare arterial blood flow in different recipient vessels, irradiated effects, and transferred tissue.

PATIENTS AND METHODS

Head and neck reconstruction with free tissue transfer was performed on 23 patients at the Department of Plastic and Reconstructive Surgery, Hokkaido University Hospital from September of 2001 to March of 2003. Patient ages ranged from 22 to 78 years (average, 57.7 years; median, 60 years). Fifteen were men and eight were women. Fourteen of the 23 patients received radiotherapy before surgery. The radiation dose ranged from 20 Gy to 65 Gy. Arterial anastomoses were performed under a surgical microscope in end-to-end fashion using 9-0 or 10-0 nylon. Venous anastomosis with internal jugular vein was performed in an end-to-side manner and the other venous anastomoses were performed in an end-to-end manner. The transferred free tissues and recipient vessels are shown in the tables (Tables I and II).

Flow volume output of the flap artery was measured using a color Doppler ultrasonography (Logiq 500, GE-Yokogawa Medical System, Tokyo, Japan). All measurements were made by the senior author, who performed microsurgery in every case and knows vessel locations very well. Locations of pedicle and recipient artery were recorded precisely before wound closure. Pedicle location and anastomosis were performed by identifying the recipient vessels with color Doppler ultrasonography. The recipient arteries were native branches of the carotid artery. It is not difficult to identify the

TABLE I
Types of Transferred Free Tissue

Free Flap	No. of Cases
Radial forearm	8
Jejunum	6
Anterolateral thigh	4
Rectus abdominis musculocutaneous	2
Other	3
Total	23

TABLE II
Recipient Arteries and Veins

	No. of Cases
Recipient artery	
Superior thyroid	11
Facial	6
Transverse cervical	4
Others	2
Total	23
Recipient vein	
Internal jugular*	14
Facial	4
External jugular	2
Retromandibular	2
Other	1
Total	23

* Internal jugular vein was anastomosed in an end-to-side manner.

superior thyroid artery, facial artery, and transverse cervical artery we used for microvascular anastomosis by knowing their relationship to internal and external carotid artery. In addition, the pedicle always runs in an unnatural course, differing from normal anatomy. It runs from the recipient artery to a transferred flap. Flap vein runs very close to flap artery or it is often anastomosed to the internal jugular vein. It can be found without difficulty by recognizing its location.

At least three measurements were taken and the mean value was used. Diameter of the flap artery ranged from 1.5 to 4.5 mm (average, 2.5 mm). Flow volume output of flap artery was measured in selected patients with the color Doppler ultrasonography on days 1, 4, 7, 14, 21, and 28 after surgery. We compared the changes in the flap arterial output on postoperative days to the output at postoperative day 1 for each patient. This was then considered to be the flow volume output ratio (output at days 4, 7, 14, 21, or 28 / output at day 1), which was compared and studied for the different postoperative days in each patient. In addition, we compared flow volume output itself on the first postoperative day for the different flaps and different recipient arteries and veins, and the effectiveness of irradiation in the different patients.

Statistical Analysis

The arterial flow volume output ratios for different days and in different patients were assessed by the Wilcoxon signed-rank test. No correction was made for the testing. Flow volume output itself at postoperative day 1 in different flaps and different recipient arteries and veins and the effectiveness of irradiation in

the different patients were assessed by Mann-Whitney *U* test. Statistical significance was set at $p < 0.05$ for both tests.

RESULTS

Flow volume output of each flap artery could be measured in all 23 patients. Flap arterial output ranged from 0 to 52.9 ml/minute. It could be measured continuously with color Doppler ultrasonography in 17 of 23 patients on days 1, 4, 7, 14, 21, and 28 after surgery. Continuous study was not done on six patients. Three of the 17 patients developed venous thrombosis, but they were salvaged by reanastomosis. All 23 flaps survived.

Changes in Time Course

The flow volume output ratio was assessed in 14 patients without venous thrombosis. The ratio increased gradually from days 1, 4, and 7 after surgery (Fig. 1). A significant difference ($p < 0.05$) was observed between ratios on day 1 and days 4, 7, 14, and 21 after surgery. The ratio decreased gradually after day 7. Significant difference was observed between the ratios at day 7 and day 28.

Differences in Recipient Arteries and Veins

Comparison of flow volume output at postoperative day 1 in the different recipient arteries was carried out. The flap arterial output for the superior thyroid artery, facial artery, and transverse cervical artery anastomoses showed no significant difference. Output for the different recipient veins at postoperative day 1 was compared in internal jugular vein, facial vein,

and external jugular vein anastomoses. There were no significant differences.

Effectiveness of Irradiation

Flow volume output at postoperative day 1 between patients with irradiation and those without irradiation showed no significant differences.

Differences in Transferred Tissue

The flow volume output at postoperative day 1 showed significant differences between the free jejunum and skin flaps (radial forearm and anterolateral thigh flaps) ($p < 0.05$). The free jejunum had more pedicle arterial blood flow than the skin flap. Output for the free jejunum was higher than for the skin flap at every time point and showed minimal changes (Fig. 2). We were able to measure the flow volume output in only three of the six free jejunum continuously, so we could not analyze it statistically regarding the time course change.

Flow Volume Output in the Flap with Venous Thromboses

Three of the 23 patients had venous thromboses, two had radial forearm flaps for tongue reconstruction and one had a rectus abdominis musculocutaneous flap for maxillary soft-tissue reconstruction. Flow volume output was measured immediately when venous congestion was suspected. Abnormal flap arterial waveform, decreasing flow volume output, and absence of venous blood flow was observed using color Doppler ultrasonography. Only the vein

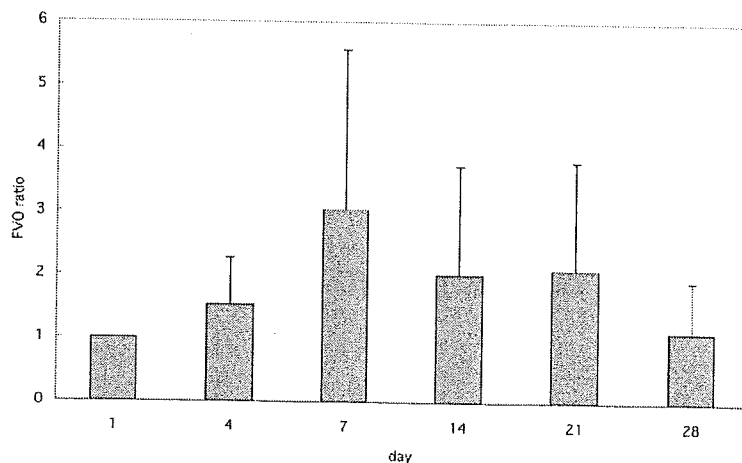


FIG. 1. Flow volume output (FVO) ratio after free flap transfer ($n = 14$). Error bars represent the standard deviations.

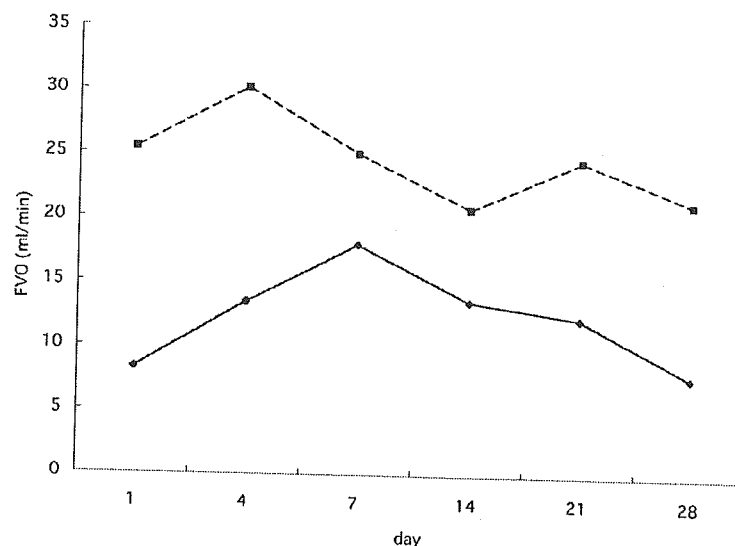


FIG. 2. Comparison of average arterial flow volume output (FVO) in skin flaps ($n = 11$; diamonds) and in free jejunum ($n = 3$; squares). Free jejunum has more pedicle arterial blood flow than the skin flap does.

was reanastomosed at day 1 in two patients and at day 2 in one patient. After reanastomoses, the output was significantly improved and the flap survived completely in all cases.

CASE REPORT

A 74-year-old man had venous thrombosis after free radial forearm flap transfer for tongue reconstruction. The recipient vessels were the facial artery and internal jugular vein. Venous anastomosis was performed in an end-to-side manner. Slight venous congestion was observed 1 day after surgery. The waveform of the flap artery indicated turbulence, with systolic antegrade and diastolic retrograde flow and decreased flow volume output (Fig. 3, above). At that time, venous blood flow was not detected by color Doppler ultrasonography. We suspected venous thrombosis, so we explored it in the operating room. Venous thrombosis was found, and only the vein was reanastomosed. The flap arterial waveform recovered immediately and the flow volume output increased significantly from 2.45 ml/minute to 7.92 ml/minute (Fig. 3, below). The flap survived completely.

DISCUSSION

Free tissue transfer with microvascular anastomosis has become a popular procedure. Obtaining adequate blood inflow and outflow is very important for flap survival. Therefore, attempts have been made to use various methods to monitor flap blood flow. Color Doppler ultrasonography is widely used in cardiovascular surgery to assess the internal mammary artery blood flow. In the field of plastic surgery, color Doppler ultrasonography has been used for preoperative assessment of transverse rectus abdominis musculocutaneous flaps and perfo-

rator vessels⁷ and assessment of artery and vein preoperatively.⁸ For blood flow measurement after microsurgery, Amerhauser et al. reported clinical and experimental study using color Doppler ultrasonography in 1993.⁹ They reported its precise measurement of blood flow in an experimental animal model. In addition, they monitored pedicle vessels after free tissue transfer in head and neck reconstruction accurately. Salmi et al. reported arterial blood flow changes in free muscle flap pedicle postoperatively from 2 weeks to 9 months with color Doppler ultrasonography.¹⁰ Color Doppler ultrasonography has also been used for monitoring buried free flap in the head and neck region.^{11,12} Hemodynamic changes after free flap transfer were reported in free skin flap for 1 week after surgery.^{13,14}

Zierler et al.¹⁵ studied the accuracy of blood flow measurement using color Doppler ultrasound in small vessels ranging from 1 to 3 mm in diameter. They reported an error of measured blood flow of 13 percent.

To minimize errors, at least three measurements were taken and the mean was used. In addition, angles of incidence of the Doppler line of sight were almost kept in every measurement. Angle, location, and direction of Doppler probe are relatively restricted in the neck region; therefore, it is not difficult to measure flow volume output in almost the same direction. The measured flow volume output is reproducible with minimal error.