

carcinoma was positive for IQGAP1. However, squamous cell carcinoma frequently showed membranous staining, whereas normal stratified squamous epithelium showed both cytoplasmic and membranous staining. This altered localization of IQGAP1 may relate to the dysfunction of cell adhesion or signal transduction during carcinogenesis in squamous cell carcinomas.

Concerning glandular cells, the cytoplasm of normal bronchial serous glands were specifically stained, whereas mucous glands were not. Well-differentiated adenocarcinoma frequently showed a cytoplasmic staining pattern, whereas moderately- or poorly-differentiated adenocarcinoma showed membranous staining or reduced expression. Thus, our findings are similar to gastric (15) and endometrial (16) cancer. This might result in a worse prognosis for patients with lung adenocarcinoma showing membranous or reduced staining patterns. An inverse correlation of membranous expression of IQGAP1 and either E-cadherin or  $\alpha$ -catenin (15,16) might explain some dedifferentiated features of cancer cells. Since the most common cause of death in this series of patients was distant metastasis, abnormal localization of IQGAP1 might play a role in local invasion and distant metastases.

In summary, the expression pattern of IQGAP1 in lung cancer was different according to histologic type, which may reflect the features of cancer cell origin. In adenocarcinoma, cytoplasmic staining was frequently observed in the well-differentiated type, and survival of patients with this type was better than those with membranous or reduced expression. Therefore, the expression pattern of IQGAP1 can predict survival in patients with lung adenocarcinoma.

#### Acknowledgements

This study was funded by grant no. 15591493 from the Ministry of Education, Science, Sports, and Culture in Japan.

#### References

1. Briggs M and Sacks D: IQGAP1 as signal integrator: Ca<sup>2+</sup>, calmodulin, Cdc42 and the cytoskeleton. *FEBS Lett* 542: 7-11, 2003.
2. Katata T, Irie K, Fukuhara A, *et al*: Involvement of nectin in the localization of IQGAP1 at the cell-cell adhesion sites through the actin cytoskeleton in Madin-Darby canine kidney cells. *Oncogene* 22: 2097-2109, 2003.
3. Zhang B, Chernoff J and Zheng Y: Interaction of Rac1 with GTPase-activating proteins and putative effectors. A comparison with Cdc42 and RhoA. *J Biol Chem* 273: 8776-8782, 1998.
4. Joyal J, Annan R, Ho Y, *et al*: Calmodulin modulates the interaction between IQGAP1 and Cdc42. Identification of IQGAP1 by nanoelectrospray tandem mass spectrometry. *J Biol Chem* 272: 15419-15425, 1997.
5. Li Z, Kim S, Higgins J, Brenner M and Sacks D: IQGAP1 and calmodulin modulate E-cadherin function. *J Biol Chem* 274: 37885-37892, 1999.
6. Kaibuchi K, Kuroda S, Fukata M and Nakagawa M: Regulation of cadherin-mediated cell-cell adhesion by the Rho family GTPases. *Curr Opin Cell Biol* 11: 591-596, 1999.
7. Clark E, Golub T, Lander E and Hynes R: Genomic analysis of metastasis reveals an essential role for RhoC. *Nature* 406: 532-535, 2000.
8. Nabeshima K, Shimao Y, Inoue T and Koono M: Immunohistochemical analysis of IQGAP1 expression in human colorectal carcinomas: its overexpression in carcinomas and association with invasion fronts. *Cancer Lett* 176: 101-109, 2002.
9. Travis D, Colby V, Corrin B, Shimosato Y and Brambilla E: *Histological typing of lung and pleural tumors*. 3rd edition. Springer, Heidelberg, pp25-47, 1999.
10. Mountain C: Revisions in the international system for staging lung cancer. *Chest* 111: 1710-1717, 1997.
11. Kikuno R, Nagase T, Waki M and Ohara O: HUGE: a database for human large proteins identified in the Kazusa cDNA sequencing project. *Nucleic Acids Res* 30: 166-168, 2002.
12. Mataraza J, Briggs M, Li Z, Frank R and Sacks D: Identification and characterization of the Cdc42-binding site of IQGAP1. *Biochem Biophys Res Commun* 305: 315-321, 2003.
13. Li Q and Stuenkel E: Calcium negatively modulates calmodulin interaction with IQGAP1. *Biochem Biophys Res Commun* 317: 787-795, 2004.
14. Mateer S, McDaniel A, Nicolas V, *et al*: The mechanism for regulation of the F-actin binding activity of IQGAP1 by calcium/calmodulin. *J Biol Chem* 277: 12324-12332, 2002.
15. Takemoto H, Doki Y, Shiozaki H, *et al*: Localization of IQGAP1 is inversely correlated with intercellular adhesion mediated by E-cadherin in gastric cancers. *Int J Cancer* 91: 783-788, 2001.
16. Miyamoto S, Baba H, Kuroda S, *et al*: Changes in E-cadherin associated with cytoplasmic molecules in well and poorly differentiated endometrial cancer. *Br J Cancer* 83: 1168-1175, 2000.

# Gefitinib in the adjuvant setting: safety results from a phase III study in patients with completely resected non-small cell lung cancer

Masahiro Tsuboi<sup>a</sup>, Harubumi Kato<sup>a</sup>, Kanji Nagai<sup>b</sup>, Ryosuke Tsuchiya<sup>c</sup>, Hiromi Wada<sup>d</sup>, Hirohito Tada<sup>e</sup>, Yukito Ichinose<sup>f</sup>, Masahiro Fukuoka<sup>g</sup> and Haiyi Jiang<sup>h</sup>

Standard therapy for stage I–IIIA non-small cell lung cancer (NSCLC) is surgery, although adjuvant therapies are required to prevent disease recurrence and improve patient survival. This is the first study that planned to administer adjuvant gefitinib (Iressa) 250 mg/day or placebo to randomized patients with completely resected NSCLC (stage IB–IIIA) 4–6 weeks following surgery, for 2 years, until recurrence/withdrawal. However, recruitment was stopped after the randomization of 38 patients, because interstitial lung disease (ILD)-type events were being increasingly reported in Japan in the advanced disease setting. Finally, the trial was halted. Safety data for 38 recruited patients (18 gefitinib and 20 placebo) showed no unexpected adverse drug reactions (ADRs), with the most common being grade 1/2 gastrointestinal and skin disorders in 12 and 16 patients receiving gefitinib and in five and six patients receiving placebo, respectively. Grade 3/4 ADRs occurred in four patients receiving gefitinib and one patient receiving placebo. ILD-type events were reported in one patient receiving gefitinib (concomitantly with other ILD-inducing drugs) who died and two patients receiving placebo. Eight patients receiving gefitinib withdrew due to ADRs compared with three patients receiving placebo. Adverse events associated with surgical complications were reported for six patients receiving

gefitinib and four patients receiving placebo. In the adjuvant setting there were no unexpected adverse events observed. Gefitinib had no impact on surgery-related complications when given within 4–6 weeks post-operatively. *Anti-Cancer Drugs* 16:1123–1128 © 2005 Lippincott Williams & Wilkins.

*Anti-Cancer Drugs* 2005, 16:1123–1128

**Keywords:** gefitinib, non-small cell lung cancer, phase III, safety

<sup>a</sup>Tokyo Medical University Hospital, Tokyo, Japan, <sup>b</sup>National Cancer Center Hospital East, Chiba, Japan, <sup>c</sup>National Cancer Center Hospital, Tokyo, Japan, <sup>d</sup>Kyoto University Faculty of Medicine, Kyoto, Japan, <sup>e</sup>Osaka City General Hospital, Osaka, Japan, <sup>f</sup>National Kyushu Cancer Center, Fukuoka, Japan, <sup>g</sup>Kinki University School of Medicine, Osaka, Japan and <sup>h</sup>AstraZeneca KK, Osaka, Japan.

**Sponsorship:** This trial was coordinated and supervised by the Study Coordinating Committee (principal investigators plus AstraZeneca personnel), and the Independent Data Monitoring Committee (lung cancer and statistical experts independent of AstraZeneca), with funding and organizational support from the trial sponsor AstraZeneca.

Correspondence to M. Tsuboi, Department of Surgery, Tokyo Medical University Hospital, 6-7-1 Nishi-Shinjuku, Shinjuku-ku, Tokyo 160-0023, Japan.  
Tel: +81-3-3342-6111; fax: +81-3-3349-0326;  
e-mail: mtsuboi@za2.so-net.ne.jp

Received 21 February 2005 Revised form accepted 3 August 2005

## Introduction

Non-small cell lung cancer (NSCLC) is generally not diagnosed until the disease is symptomatic, by which time more than two-thirds of patients are in the advanced stages of disease and have a poor prognosis [1]. Approximately 25% of patients with NSCLC are diagnosed when their disease is in the early stages; however, as many of these patients frequently have undetectable metastases, disease often recurs in distant sites [2]. Adjuvant therapies are therefore required to help prevent disease recurrence and as they will need to be given to patients post-operatively for a prolonged period, they should be well tolerated.

Although some clinical trials in NSCLC have shown a significant survival benefit with adjuvant uracil plus tegafur (UFT) and cisplatin-based chemotherapy [3–7], others have not observed a significant improvement in

survival [5,8,9]. At the time of commencing this study, there were no standard adjuvant treatment regimens for NSCLC.

Gefitinib (Iressa), an orally active epidermal growth factor receptor tyrosine kinase inhibitor (EGFR-TKI), was approved in Japan for the treatment of inoperable or recurrent NSCLC in 2002. Two large phase II trials, IDEAL (Iressa Dose Evaluation in Advanced Lung cancer) 1 and 2, observed objective responses and stable disease in more than 40% of pre-treated patients with NSCLC receiving 250 mg/day gefitinib, with the majority of adverse events (AEs) being mild to moderate gastrointestinal and skin disorders [10,11]. Gefitinib was not associated with the well-recognized AEs observed with cytotoxic chemotherapy (e.g. bone marrow depression, neurotoxicity, nephrotoxicity). The tolerability profile of gefitinib has been confirmed by data from the

Expanded Access Programme, through which more than 39 000 patients have received gefitinib 250 mg/day on a compassionate-use basis. Furthermore, a retrospective analysis of 9515 US patients who had received gefitinib for 1 year or more via the Expanded Access Programme showed a 1-year survival rate of 33% [12], which compares with the IDEAL studies [10,11]. Recently, Onn *et al.* observed efficacy (16% with objective responses and 45% with stable disease) and a low incidence of grade 3/4 AEs in Japanese patients with NSCLC, most of whom had been treated with second-line gefitinib or above (99% of patients) [13].

To date, there is no experience of using gefitinib in the post-operative adjuvant setting. This phase III trial was initially undertaken to compare survival rates in patients with completely resected stage IB–IIIA NSCLC who had been treated with adjuvant gefitinib 250 mg/day or placebo. However, in October 2002, recruitment was halted following high-profile media activity around reports of gefitinib-related interstitial lung disease (ILD)-type events in patients with advanced or metastatic NSCLC in Japan. In March 2003, the trial was halted because of an increased withdrawal rate. As enrollment could not be resumed until the prospective investigation into gefitinib-related ILD-type events in Japan was completed, the trial was closed. Consequently survival data are not available, although data from patients recruited to the study have been subsequently analyzed for safety.

## Methods

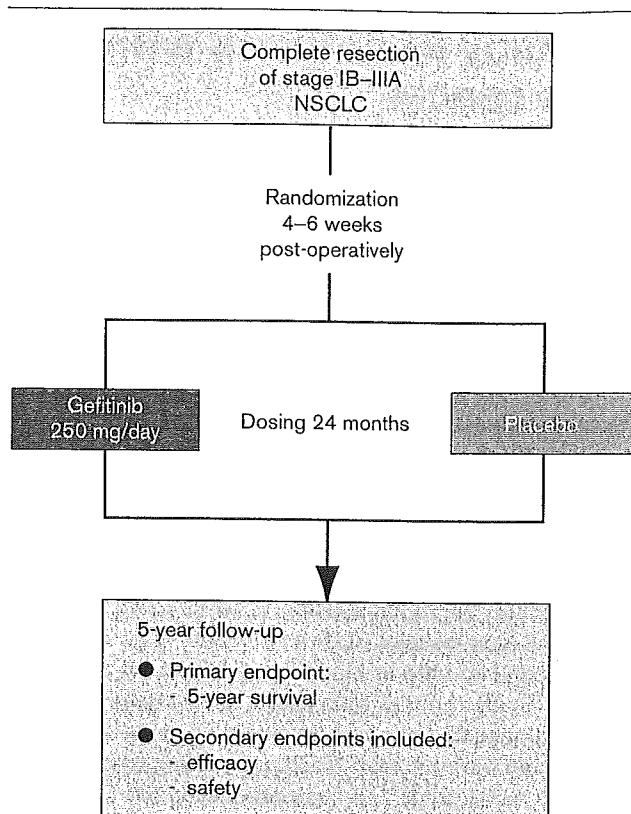
### Patients

Patients were eligible for inclusion in the trial if they had histologically confirmed NSCLC (post-operative stage IB–IIIA) that had been completely resected 4–6 weeks before the start of treatment. Patients were required to be 20–75 years of age, with a WHO performance status (PS) 0–1, no previous history of chemotherapy, radiotherapy or immunotherapy for NSCLC and no co-malignancies within the past 5 years. All patients gave written, informed consent to participate in the trial, which was conducted in accordance with the Declaration of Helsinki [14] and Good Clinical Practice guidelines.

### Study design

This randomized (1:1), double-blind, placebo-controlled, phase III multicenter survival study planned to recruit 670 patients (335 per group) and randomize them to receive either gefitinib (250 mg) or placebo (Fig. 1). Treatment was to be continued for 2 years, or until recurrence/secondary carcinoma or withdrawal criteria were met. An Independent Data Monitoring Committee (IDMC) was set up to assess the efficacy and safety of gefitinib post-operatively, and would advise whether the study should be continued, changed or discontinued.

Fig. 1



Trial design schema.

## Assessments

### Efficacy

Disease recurrence or secondary carcinogenesis were assessed using X-rays every 3 months during treatment and every 6 months during the follow-up period. Computed tomography (CT) scans were carried out 8 weeks after the first dose (where necessary, the pre-operative thoracoabdominal CT scan could be used), at week 48 during treatment, at week 104 after withdrawal/completion and every 52 weeks thereafter, unless disease recurrence was observed.

### Safety

AEs were to be recorded and coded using MedDRA (Medical Dictionary for Regulatory Activities) version 6.0, graded using National Cancer Institute Common Toxicity Criteria (NCI-CTC) version 2.0 and assigned causality by the investigators. AEs associated with post-operative complications were defined as events occurring within 90 days after surgery and were recorded without regard to causality. Treatment could be interrupted for up to 14 days, although the IDMC later recommended that drug interruption could be allowed for more than 14 days in cases where ILD-type events were suspected, but could not be confirmed, in order to ensure the safety of

patients who remained in the trial after recruitment was halted. Hematology, biochemistry and urinalysis were also measured at baseline and during the study.

### Role of the funding source

This trial was coordinated and supervised by the principal investigators, the IDMC and AstraZeneca personnel, with funding and organizational support from the trial sponsor AstraZeneca.

## Results

### Patients

Between August and October 2002, 38 patients were randomized into the trial – 18 received gefitinib and 20 received placebo. Patient demography was well balanced between the treatment arms, with the majority of patients having adenocarcinoma histology and WHO PS 1 (Table 1). When the trial was stopped, four patients in the gefitinib arm and 11 patients in the placebo arm were

still receiving treatment (Fig. 2). Of the 23 patients who withdrew, 13 did so because of AEs (10 in the gefitinib arm and three in the placebo arm), five were unwilling to continue with treatment (three in the gefitinib arm and two in the placebo arm), two had disease recurrence (both in the placebo arm) and three withdrew for other reasons (one patient in the gefitinib arm had incomplete recovery from surgery that was not drug related, and two patients in the placebo arm had pre-existing interstitial pneumonia and were withdrawn at the request of the sponsor).

### Efficacy

From the limited efficacy data, disease recurrence was not seen in patients receiving gefitinib at data cutoff. Three patients who received placebo (one with stage IB and two with stage IIB) experienced disease recurrence – two patients recurred during the trial and one patient recurred after the trial had stopped.

### ADRs

No unexpected ADRs were observed and, in general, the frequency of all ADRs was higher for gefitinib versus placebo (Table 2). The most common ADRs were mild to moderate grade 1/2 gastrointestinal and skin disorders. Grade 3/4 ADRs were seen in four patients in the gefitinib arm and one patient in the placebo arm (Table 3), all of whom had treatment withdrawn (the patient with grade 3 eczema had treatment withdrawn due to grade 2 impetigo).

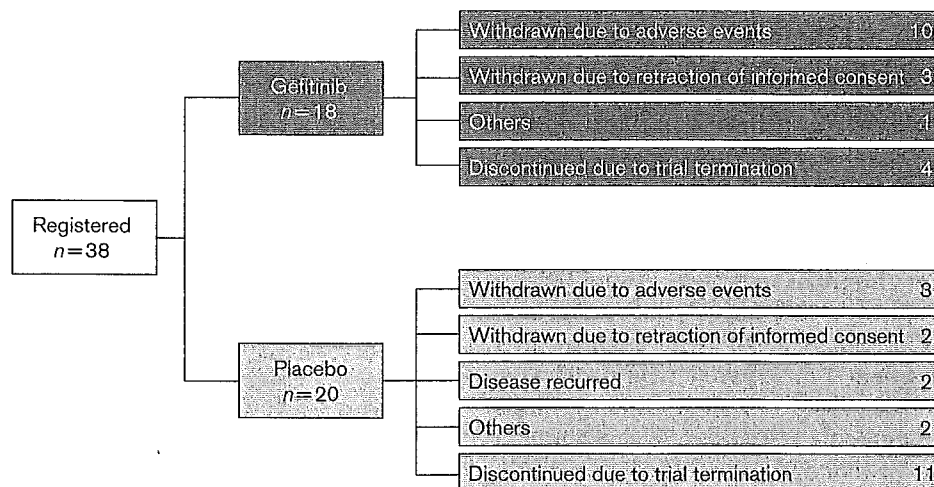
### Respiratory ADRs

The majority of respiratory ADRs were grade 1/2 and occurred within 1 month of treatment. In the gefitinib arm, two patients experienced cough (associated with post-operative complications), one patient had dyspnea,

Table 1 Patient demography

	Gefitinib 250 mg/day (n=18)	Placebo (n=20)
Sex [n (%)]		
male	14 (77.8)	15 (75.0)
female	4 (22.2)	5 (25.0)
Median age [years (range)]	64.0 (49–73)	62.5 (52–73)
WHO PS [n (%)]		
0	5 (27.8)	9 (45.0)
1	13 (72.2)	11 (55.0)
Histology [n (%)]		
squamous cell carcinoma	4 (22.2)	6 (30.0)
adenocarcinoma	14 (77.8)	14 (70.0)
Stage [n (%)]		
IB	7 (38.9)	8 (40.0)
IIA	2 (11.1)	1 (5.0)
IIB	3 (16.7)	5 (25.0)
IIIA	6 (33.3)	6 (30.0)

Fig. 2



Trial outcome.

Table 2 Common ADRs occurring in two or more patients

AE (MedDRA term) <sup>a</sup>	Gefitinib 250 mg/day (n=18)	Placebo (n=20)
Abnormal hepatic function	4	0
Acne	2	0
Anorexia	5	1
Cough	2 <sup>b</sup>	1
Diarrhea	9	2
Dry skin	3	0
Eczema	8	2
Elevated ALT/AST	2	0
Fatigue	2	0
Gastritis	3 <sup>b</sup>	0
Loose stools	4	0
Nausea	3	0
Rash	5	3
Sputum	0	2
Stomatitis	2	0

<sup>a</sup>A patient could have more than one AE.<sup>b</sup>All were associated with post-operative complications.

Table 3 Grade 3/4 ADRs

AE (MedDRA term)	Grade	Gefitinib 250 mg/day (n=18)	Placebo (n=20)
Abnormal hepatic function	3	1	0
Eczema	3	1	0
Elevated ALT	3	1	0
Neutropenia	3	0	1
Pneumonitis	4	1	0

and one patient experienced grade 4 ILD-type events (pneumonitis) 107 days after starting gefitinib and was withdrawn from the study. The patient with pneumonitis had taken concomitant shosaikoto, a Chinese herbal medicine, and loxoprofen, both of which have previously been shown to induce pneumonitis [15,16]. Twenty-one days later bacterial pneumonia related to methylprednisolone therapy was diagnosed, and the patient subsequently died 37 days later due to both pneumonitis and bacterial pneumonia. In the placebo arm, one patient who experienced cough and grade 1 pulmonary fibrosis had had interstitial changes on their chest X-ray at enrollment, and in a second patient, pre-existing non-specific interstitial pneumonia was exacerbated resulting in grade 1 ILD. In both patients, these conditions persisted following withdrawal of study drug.

#### Interruptions and withdrawals due to ADRs

ADRs requiring interruptions in therapy were similar between patients receiving gefitinib or placebo (Table 4) and were usually for less than 14 days, although four patients in the gefitinib arm required treatment to be interrupted for 14 days (including one patient whose treatment was interrupted for 20 days). The majority of ADRs leading to withdrawal were usually mild-to-moderate grade 1/2 in severity (Table 5). Grade 3 ADRs leading to withdrawal occurred in two patients receiving gefitinib (hepatic function abnormalities, elevated ALT)

Table 4 Exposure of patients to gefitinib

	Gefitinib 250 mg/day (n=18)	Placebo (n=20)
Median duration of treatment [days (range)]	86.5 (4-195)	144.0 (20-197)
Dosing period (n)		
< 60 days	6	2
60-120 days	9	4
≥ 120 days	3	14
No. dose interruptions (n)		
1	5	6
2	2	2
≥ 3	2	2

Table 5 ADRs leading to patient withdrawals

Adverse event (MedDRA term)	Grade	Gefitinib 250 mg/day (n=18)	Placebo (n=20)
Eczema	2	1	0
Elevated ALT/AST	2	1	0
	3	1	0
Hepatic function abnormalities	2	1	0
	3	1	0
ILD	1	0	1
Impetigo	2	1	0
Neutropenia	3	0	1
Paronychia	2	1	0
Pneumonitis	4	1	0
Pulmonary fibrosis	1	0	1

and in one patient receiving placebo (neutropenia), and grade 4 pneumonitis led to the withdrawal of one patient who was receiving gefitinib. Following withdrawal of gefitinib treatment, grade 3 abnormal hepatic function and elevated ALT resolved, and grade 3 neutropenia persisted.

#### AEs associated with post-operative complications

As there are no safety data regarding the use of gefitinib in the post-operative setting, AEs associated with the healing process were examined to provide preliminary safety data on the start of the dosing timing in the adjuvant setting for gefitinib. AEs related to post-operative complications were observed in six patients in the gefitinib arm and four patients in the placebo arm. In the gefitinib arm, the most frequent AEs were grade 1/2 cough (four patients) and gastritis (three patients), and in the placebo arm grade 1/2 pain (three patients). Grade 1 cough, grade 1 supraventricular arrhythmia and grade 2 dyspnea were also experienced by three out of four patients receiving placebo.

#### Discussion

This trial was designed to compare survival rates in patients with completely resected stage IB-IIIa NSCLC who had received adjuvant therapy with gefitinib 250 mg/day or placebo. However, incidences of ADRs of ILD-

type events in the advanced disease setting have been increasingly reported since gefitinib was launched in Japan, and new recruitment was put on hold on 23 October 2002 at the request of the Ministry of Health, Labor and Welfare. In order to evaluate the ILD and ensure the safety of the trial patients, two separate Co-ordination Committee and IDMC meetings (December 2002 and January 2003) were conducted to discuss the feasibility of continuing the study and management of the trial patients. Based on the updated information on ADRs of interstitial pneumonia, the committees concluded that the study could be continued because the possibility of risk did not exceed that of benefit to enrolled patients. The IDMC also suggested that top priority should be given to assure the safety of the patients receiving gefitinib, and that discontinuation should be considered if flu-like symptoms including difficulty in breathing, fever and coughing occurred.

A 'Supplemental Explanation Sheet and Informed Consent Form' was provided four times to enrolled patients, offered updated information and methods to assure and manage any safety issues, and confirmed the patients' willingness to continue participating in the study. In December 2002, AstraZeneca KK gave the principal investigators the option to suspend gefitinib treatment at once. With the extensive monitoring of the trial patients in terms of safety, there were still an increasing number of withdrawals. In addition, enrollment could not be resumed until the prospective investigation on gefitinib-related ILD was completed. Based on these facts, the sponsor finally decided to terminate the trial in March 2003.

The types of AEs reported in this trial were similar to that already reported in the large phase II IDEAL 1 and 2 trials for patients with locally advanced or metastatic NSCLC [10,11]. Three patients experienced ILD-type events – two in the placebo arm and one patient in the gefitinib arm (this patient was also taking two other medications known to induce ILD) [15,17]. It has generally been observed that a higher frequency of ILD-type events are reported in Japanese patients taking gefitinib compared with those in other south-east Asian countries and the rest of the world (1.6, 0.3, and 0.3%, respectively) [18]. The occurrence of ILD in Japanese patients and the reasons for such an ethnic stratification in ILD incidence following gefitinib treatment require further clarification.

The most common reason for withdrawal in both treatment arms was due to toxicity, with the majority of drug-related AEs being grade 1/2 in severity. In the advanced or metastatic disease setting, few patients who experience grade 1/2 drug-related AEs withdraw from treatment with gefitinib, and in IDEAL 1, which

recruited Japanese patients, two out of 103 patients who received gefitinib 250 mg/day withdrew from therapy due to ADRs [18]. Several factors may explain the high number of withdrawals (including withdrawal of treatment for less severe ADRs) reported in this trial data compared with previously reported studies. These reasons include the fact that patients with early-stage NSCLC may be less tolerant of AEs compared with patients with advanced NSCLC who have received prior chemotherapy. In contrast to the other studies, the impact of heavy media coverage surrounding gefitinib-related ILD cannot be ignored.

It has been suggested that the dosage and schedule of gefitinib used in this study may not best suit patients with completely resected NSCLC in terms of tolerability and a number of adjustments may need to be taken into consideration when planning an adjuvant study of gefitinib in the future. It is unlikely that the time frame of 4–6 weeks is too short before starting adjuvant treatment, as other adjuvant trials conducted in Japanese patients have used similar time frames [3,4]. It may be possible to lengthen the duration by which gefitinib could be interrupted for toxicity, since 14 days may be too short for patients recovering from AEs such as hepatic enzyme elevation, or to reduce the dose following toxicity to perhaps 250 mg every other day, although this would require further study into the efficacy of such an approach.

With no experience of using gefitinib in post-operative patients there was a concern that EGFR-TKIs might impact on surgery-related complications (especially on the healing process) due to their mode of action. In order to assess this, the trial was designed to allow a safety review of the first 60 patients. Due to the early termination of the study, we have only 38 patients' (18 on gefitinib) data for review; however, there does not seem to be any impact on surgery-related complications when gefitinib was administered within 4–6 weeks after surgery, as evidenced by a similar number of these AEs that occurred in both groups. This indicates that it may be feasible to administer gefitinib in the adjuvant setting within this time frame.

In conclusion, this is the first study to investigate the use of EGFR-TKIs as adjuvant therapy. Despite the absence of survival data, there were no unexpected AEs seen in the adjuvant setting compared with those already reported for patients with locally advanced or metastatic NSCLC. However, it was observed that there were more AEs leading to withdrawal in the gefitinib arm, even though the majority of AEs were grade 1/2 in severity, suggesting that a daily dose of gefitinib 250 mg may not best suit patients with completely resected NSCLC in terms of tolerability.

## Acknowledgements

The following individuals are the principle investigators and IDMC members: Tetsuya Mitsudomi, Aichi Cancer Center, Nagoya; Motoi Aoe, Okayama University School of Medicine, Okayama; Hideyuki Saeki, National Shikoku Cancer Center, Ehime; Katsuhiko Nakagawa, Osaka Prefectural Habikino Hospital, Osaka; Teruaki Koike, Niigata Cancer Center Hospital, Niigata; Chiaki Endo, Tohoku University School of Medicine, Sendai; Makoto Oda, Kanazawa University School of Medicine, Kanazawa; Kohei Yokoi, Tochigi Cancer Center, Tochigi; Toshihiko Iizasa, Chiba University School of Medicine, Chiba; Fumihiko Tanaka, Kyoto University Faculty of Medicine, Kyoto; Akihide Matsumura, National Kinki Chuo Hospital, Osaka; Ichiro Yoshino, Kyusyu University School of Medicine, Fukuoka; Nagahiro Saijo, National Cancer Center, Tokyo; Haruhiko Fukuda, National Cancer Center, Tokyo; Naoki Ishizuka, National Cancer Center, Tokyo; Tomoyuki Goya, Kyorin University Hospital, Tokyo; Ryuzo Ueda, Nagoya University School of Medicine, Nagoya. We thank Dr Carolyn Gray, from Complete Medical Communications, who provided medical writing support on behalf of AstraZeneca. Iressa is a trademark of the AstraZeneca group of companies

## References

- Ries LAG, Eisner MP, Kosary CL, Hankey BF, Miller BA, Clegg L, et al. *SEER cancer statistics review*; 2004. [http://seer.cancer.gov/csr/1975\\_2001/](http://seer.cancer.gov/csr/1975_2001/).
- Martini N, Bains MS, Burt ME, Zakowski MF, McCormack P, Rusch VW, et al. Incidence of local recurrence and second primary tumors in resected stage I lung cancer. *J Thorac Cardiovasc Surg* 1995; **109**:120-129.
- Kato H, Ichinose Y, Ohta M, Hata E, Tsubota N, Tada H, et al. A randomized trial of adjuvant chemotherapy with uracil-tegafur for adenocarcinoma of the lung. *N Engl J Med* 2004; **350**:1713-1721.
- Wada H, Hitomi S, Teramatsu T. Adjuvant chemotherapy after complete resection in non-small-cell lung cancer. West Japan Study Group for Lung Cancer Surgery. *J Clin Oncol* 1996; **14**:1048-1054.
- Non-Small Cell Lung Cancer Collaborative Group. Chemotherapy in non-small cell lung cancer: a meta-analysis using updated data on individual patients from 52 randomised clinical trials. *Br Med J* 1995; **311**:899-909.
- Tanaka F, Miyahara R, Ohtake Y, Yanagihara K, Fukuse T, Hitomi S, et al. Advantage of post-operative oral administration of UFT (tegafur and uracil) for completely resected p-stage I-IIIa non-small cell lung cancer (NSCLC). *Eur J Cardiothorac Surg* 1998; **14**:256-262.
- Arriagada R, Bergman B, Dunant A, Le Chevalier T, Pignon JP, Vansteenkiste J. Cisplatin-based adjuvant chemotherapy in patients with completely resected non-small-cell lung cancer. *N Engl J Med* 2004; **350**:351-360.
- Endo C, Saito Y, Iwanami H, Tsushima T, Imai T, Kawamura M, et al. A randomized trial of postoperative UFT therapy in p stage I, II non-small cell lung cancer: North-east Japan Study Group for Lung Cancer Surgery. *Lung Cancer* 2003; **40**:181-186.
- Wada H, Miyahara R, Tanaka F, Hitomi S. Postoperative adjuvant chemotherapy with PVM (Cisplatin + Vindesine + Mitomycin C) and UFT (Uracil + Tegafur) in resected stage I-II NSCLC (non-small cell lung cancer): a randomized clinical trial. West Japan Study Group for lung cancer surgery (WJSG). *Eur J Cardiothorac Surg* 1999; **15**:438-443.
- Fukuoka M, Yano S, Giaccone G, Tamura T, Nakagawa K, Douillard J-Y, et al. Multi-institutional randomized phase II trial of gefitinib for previously treated patients with advanced non-small-cell lung cancer. *J Clin Oncol* 2003; **21**:2237-2246.
- Kris MG, Natale RB, Herbst RS, Lynch Jr TJ, Prager D, Belani CP, et al. Efficacy of gefitinib, an inhibitor of the epidermal growth factor receptor tyrosine kinase, in symptomatic patients with non-small cell lung cancer. A randomized trial. *J Am Med Ass* 2003; **290**:2149-2158.
- Ochs J, Grous JJ, Warner KL. Final survival and safety results for 21,064 non-small-cell lung cancer (NSCLC) patients who received compassionate use gefitinib in a U.S. expanded access program (EAP). *Proc Am Soc Clin Oncol* 2004; **23**:628.
- Onn A, Tsuboi M, Thatcher N. Treatment of non-small-cell lung cancer: a perspective on the recent advances and the experience with gefitinib. *Br J Cancer* 2004; **91**(Suppl 2):S11-S17.
- World Medical Association. World Medical Association Declaration of Helsinki. Recommendations guiding physicians in biomedical research involving human subjects. *J Am Med Ass* 1997; **277**:925-926.
- Sato A, Toyoshima M, Kondo A, Ohta K, Sato H, Ohsumi A. Pneumonitis induced by the herbal medicine Sho-saiko-to in Japan. *Nihon Kyobu Shikkan Gakkai Zasshi* 1997; **35**:391-395.
- Tohyama M, Tamaki Y, Toyama M, Ishimine T, Miyazato A, Nakamoto A, et al. A case of loxoprofen-induced pneumonitis pathologically resembling hypersensitivity pneumonitis. *Nihon Koryu Gakkai Zasshi* 2002; **40**:123-128.
- Miyazaki E, Ando M, Ih K, Matsumoto T, Kaneda K, Tsuda T. [Pulmonary edema associated with the Chinese medicine shosaikoto]. *Nihon Koryu Gakkai Zasshi* 1998; **36**:776-780.
- Forsythe B, Faulkner K. Overview of the tolerability of gefitinib (IRESSA™) monotherapy. Clinical experience in non-small-cell lung cancer. *Drug Safety* 2004; **27**:1081-1092.

# Locally Recurrent Central-Type Early Stage Lung Cancer < 1.0 cm in Diameter After Complete Remission by Photodynamic Therapy\*

Kinya Furukawa, MD, PhD; Harubumi Kato, MD, PhD;  
Chimori Konaka, MD, PhD; Tetsuya Okunaka, MD, PhD;  
Jituo Usuda, MD, PhD; and Yoshiro Ebihara, MD, PhD

**Background:** It is well known that central-type early stage lung cancer < 1.0 cm in diameter shows almost 100% complete response (CR) to photodynamic therapy (PDT). However, we have encountered cases of local recurrence after CR of tumors with a surface diameter < 1.0 cm.

**Patients and methods:** Ninety-three patients with 114 lesions were followed up, and cases of recurrence after CR has been obtained with initial tumors that had a diameter < 1.0 cm were examined. We compared the cytologic findings of local recurrence after CR to the cytologic findings before PDT. The relationship between the cell features and the depth of bronchial tumor invasion before PDT and on recurrence was evaluated.

**Results:** The CR and 5-year survival rates of patients with lesions < 1.0 cm were 92.8% (77 of 83 patients) and 57.9%, respectively; meanwhile, in the group of patients with lesions  $\geq$  1.0 cm, CR and 5-year survival rates were 58.1% (18 of 31 patients) and 59.3%. There was a significant difference in efficacy between the two groups ( $p < 0.001$ ). Recurrences after CR were recognized in 9 of 77 lesions (11.7%) < 1.0 cm. When the recurrent tumor cells showed type I-II (low-to-moderate atypia) at the same site initially treated, CR could be obtained by a second PDT. Type III cells (high-grade atypia) showed the characteristics of tumor cells from deeper layers of the bronchial wall. Local recurrence at the same site may be caused by residual tumor cells from deep layers because of inadequate laser irradiation and penetration.

**Conclusions:** To reduce the recurrence rate, it is essential to accurately grasp the tumor extent and the depth of the bronchogenic carcinoma before performing PDT. Analysis of cell features of recurrent lesions after CR appears to be a useful source of information as to the depth of cancer invasion in the bronchial wall. (CHEST 2005; 128:3269-3275)

**Key words:** early stage lung cancer; occult lung cancer; photodynamic therapy; porfimer sodium

**Abbreviations:** AFB = autofluorescence bronchoscopy; CIS = carcinoma *in situ*; CR = complete remission; EBUS = endobronchial ultrasonography; ESLC = early stage lung cancer; PDT = photodynamic therapy; PR = partial remission

Lung cancer has a tendency to develop in older people, with a very poor prognosis. A total of 55,000 Japanese died from lung cancer in 2003, which made it the number-one cause of cancer death. Although diagnostic techniques such as high-resolution CT scan, video bronchoscopy, fluorescence bronchoscopy, and endobronchial ultrasonography (EBUS) have been developed recently, many

patients with newly detected lung cancer still have inoperable advanced cancer. Therefore, the detection of early stage lung cancer (ESLC) is considered essential to reduce the mortality rate. Meanwhile, even when ESLC is detected, some cases are inoperable because of cardiopulmonary dysfunction due to age. Endoscopic procedures that are minimally invasive and do not compromise pulmonary function

\*From the Department of Chest Surgery (Dr. Furukawa), Kasumigaura Hospital, Tokyo Medical University, Ibaraki; First Department of Surgery (Drs. Kato, Konaka, Usuda, and Ebihara), Second Department of Pathology, Tokyo Medical University, Tokyo; and Center for Respiratory Diseases (Dr. Okunaka), Sanno Hospital, Tokyo, Japan.  
Manuscript received February 12, 2005; revision accepted May 9, 2005.

Reproduction of this article is prohibited without written permission from the American College of Chest Physicians ([www.chestjournal.org/miso/reprints.shtml](http://www.chestjournal.org/miso/reprints.shtml)).

Correspondence to: Kinya Furukawa, MD, PhD, Department Chest Surgery, Tokyo Medical University, Kasumigaura Hospital, 3-20-1 Chuo, Ami-machi, Inashiki-gun, Ibaraki 300-0395, Japan; e-mail: k-furu@tokyo-med.ac.jp

are considered useful modalities for centrally located lung cancer. In particular, photodynamic therapy (PDT) is considered a useful and attractive modality for central-type ESLC.<sup>1-7</sup> Its action mechanism is considered to involve singlet oxygen, which is generated through photochemical reactions and causes degenerative necrosis of cells that have taken up the photosensitizer, *ie*, tumor cells.<sup>8</sup>

PDT using red laser light and a tumor-specific photosensitizer was established as a new therapeutic modality for central-type ESLC in 1982.<sup>1</sup> The length of longitudinal tumor extent was the only independent predictive factor for complete remission (CR), and 100% CR in lesions < 1.0 cm in diameter treated by PDT was reported.<sup>5</sup> However, we have encountered local recurrences after CR of tumor even in cases with a surface diameter < 1.0 cm. Therefore, we investigated the characteristics and cytomorphic features of primary lesions and recurrences after CR in patients with lesions < 1.0 cm in diameter.

## MATERIALS AND METHODS

### Patient Selection

A total number of 145 patients with 191 lesions of endoscopic ESLC underwent PDT from February 1980 to April 2001 in the Department of Tokyo Medical University. Of the 145 patients with 191 lesions, 93 patients with 114 lesions were followed up, and cases of recurrence after CR was obtained with initial tumors with a diameter < 1.0 cm were examined.

### Procedures of PDT and Follow-up

The depth of tumor invasion was judged by biopsy specimen and CT scan, and was also evaluated by bronchoscopic findings based on the diagnostic criteria of ESLC defined by the Japan Lung Cancer Society.<sup>9</sup> To determine tumor size, bronchoscopic biopsies of the proximal and distal sites of the lesion and bronchoscopic measurements using forceps were performed. PDT procedures were performed with the combination of porfimer sodium (Photofrin; Wyeth Japan K.K.; Tokyo, Japan) that is taken up selectively in tumor, and an argon gas laser system (model 770; Spectra-Physics; Mountain View, CA) or excimer dye laser (EDL-1; Hamamatsu Photonics; Hamamatsu, Japan). Laser irradiation was performed via a quartz fiber inserted through the biopsy channel of the endoscope at 48 h after the IV administration of 2.0 mg/kg of porfimer sodium. The total energy of the laser irradiation was 100 J/cm<sup>2</sup>, and energy levels in this range do not cause any heat degeneration or other adverse effects. The duration of irradiation required usually 10 to 20 min. Clean-up bronchoscopies to remove necrotic tissue produced by the PDT reaction were performed at 1, 3, and 7 days after PDT. Both cytologic and histologic examinations via fiberoptic bronchoscopy were performed at 1, 2, and 3 months, and thereafter at 3-month intervals in the first year and 6-month intervals after the second year until 5 years after PDT.

### Efficacy Evaluation

The antitumor effect of initial treatment was rated based on endoscopic measurement of tumor size using forceps, morpho-

logic observations, and histopathologic examination by biopsy, according to the general rules of the Japan Lung Cancer Society<sup>9</sup> and the Japan Society of Clinical Oncology.<sup>10</sup> The antitumor effect was rated at 1 month and 2 months after PDT. Antitumor effect was rated as CR (no demonstrable tumor microscopically by brushing and/or biopsy for a period of 4 weeks), partial remission (PR) [ $\geq 50\%$  reduction in tumor size], no change (< 50% reduction or < 25% increase in tumor size), progressive disease (> 25% increase in tumor size), or not evaluable.

### Evaluation of Cytomorphic Features of Local Recurrences

In the central-type ESLC < 1.0 cm in greatest dimension, we have compared the cytologic findings of local recurrence after CR to the cytologic findings before PDT using bronchial brushing specimen. Cytologic findings were classified into three cytologic morphotypes using the classification of cell features proposed by Konaka and coworkers,<sup>11</sup> which appears to yield information as to the depth of cancer invasion in the bronchial wall. The classification was described as follows: type I cell, low-grade atypia (resembling atypical squamous cell metaplasia); type II cell, moderate-grade atypia (resembling early stage squamous cell carcinoma); and type III cell, high-grade atypia (resembling invasive squamous cell carcinoma). The biopsy specimens before PDT and on recurrence, or resected materials, in cases of resection after recurrence, were examined histopathologically, and the depth of bronchial wall invasion was classified into three groups: grade 1, carcinoma *in situ* (CIS) or microinvasion; grade 2, extramucosal bronchial wall invasion; and grade 3, intracartilaginous to extracartilaginous invasion. The relationship between the cell features and the depth of bronchial tumor invasion before and after PDT was evaluated.

### Statistical Analysis

Statistical analysis were done using statistical software (Stat Flex for Windows, version 5.0; Artec; Osaka, Japan). The  $\chi^2$  test was used to compare the efficacy of PDT between lesions < 1.0 cm and > 1.0 cm in diameter. Differences between the survival rates of two groups in the Kaplan-Meier survival curves were analyzed using the log-rank test;  $p < 0.05$  was considered to indicate a statistically significant difference.

## RESULTS

### Results of PDT for Central-Type ESLC

A total of 93 patients with 114 lesions of central-type ESLC who underwent PDT were examined. Thirteen synchronous lesions in six cases, 15 metachronous lesions in six cases, and 5 synchronous/metachronous lesions in one case were observed. The evaluation of the efficacy of PDT is shown in Table 1. CRs and PRs were obtained in 75 patients with 95 lesions (83.3%) and in 18 patients with 19 lesions (16.7%) out of 93 patients with 114 lesions. Each lesion with PR was subsequently treated with other modalities, including surgery in 13 cases, chemotherapy in 5 cases, or radiotherapy in 1 case, and finally achieved 100% CR. Recurrences after CR were recognized in 12 of 95 lesions (12.6%). The 114 lesions were classified in two groups according to the

**Table 1—Results of PDT for Central-Type ESLC\***

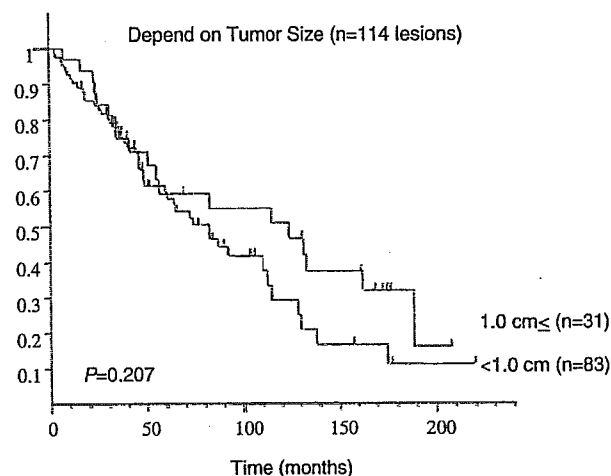
Tumor Size, cm	Lesions, No.	CR	PR	Recurrence After CRT
< 1.0	83	77 (92.8)	6 (7.2)	9 (11.7)
≥ 1.0	31	18 (58.1)	13 (41.9)	3 (16.7)
Total	114	95 (83.3)	19 (16.7)	12 (12.6)

\*Data are presented as No. (%) unless otherwise indicated.  
†p < 0.001.

maximum longitudinal tumor extent. Of these, 83 lesions (72.8%) were < 1.0 cm and 31 lesions (27.2%) were ≥ 1.0 cm in diameter. The CR and PR rates in the group of patients with lesions < 1.0 cm in maximum diameter were 92.8% (77 of 83 patients) and 7.2% (6 of 83 patients), respectively. Meanwhile, in the group of patients with lesions ≥ 1.0 cm in diameter, the CR and PR rates were 58.1% (18 of 31 patients) and 41.9% (13 of 31 patients), respectively. Neither no change nor partial disease were observed in these groups. There was a significant difference in efficacy between the two groups using the  $\chi^2$  test (p < 0.001). Recurrences after CR were recognized in 9 of 77 lesions (11.7%) in the group < 1.0 cm and 3 of 18 lesions (16.7%) in the group ≥ 1.0 cm in diameter. The overall 5-year survival rates of the two groups were 57.9% and 59.3%, respectively (Fig. 1). There was no significant difference between the two groups on the basis of the log-rank test (p = 0.207).

*Characteristics of Local Recurrence < 1.0 cm in Diameter After CR*

The information on nine patients with nine lesions in the group of patients with lesions < 1.0 cm in diameter who had recurrence after CR had been achieved by initial PDT are presented in Table 2. All patients with recurrence were male, and the age



**FIGURE 1.** The overall 5-year survival rates were 57.9% in the group of patients with tumors < 1.0 cm and 59.3% in the group with tumors ≥ 1.0 cm in diameter, respectively. There was no significant difference between the survival rates of two groups in the Kaplan-Meier curves on the basis of the log-rank test (p = 0.207).

distribution ranged from 64 to 71 years (average age, 67.6 years at the time of initial diagnosis). Evidences of local recurrence were found in nine patients with nine lesions at the site of the primary lesion. The recurrent lesions were located on the trachea in one patient, lobar bronchus in one patient, segmental bronchi in five patients, and subsegmental bronchi in two patients. The average diameter of the nine recurrent lesions was 0.46 cm. All lesions were squamous cell carcinoma, and endoscopic findings showed nodular type in two lesions and superficial type in seven lesions. The disease-free interval of these nine patients ranged from 3 to 18 months (average, 10 months).

Local recurrence at site corresponding to the

**Table 2—Recurrent Cases After PDT for Central-Type ESLC < 1.0 cm in Diameter\***

Case No.	Patient Age, yr	Lesion	Size, cm	BF Findings	CR, mo	Recurrence	Additional Treatment	Prognosis
1	66	Segmental bronchus rB <sup>3</sup>	0.3	Superficial	18	PM	PDT, OP (RUL)	Alive (24 mo)
2	64	Subsegmental bronchus IB <sup>3</sup> a-b	0.3	Superficial	13	PM	PDT, OP (LPn)	Dead (56 mo), other disease
3	69	Subsegmental rB <sup>10</sup> a-b	0.4	Superficial	10	PM	PDT Brachy	Alive (41 mo)
4	64	Segmental bronchus IB <sup>1+2</sup>	0.6	Nodular	5	SS (CIS)	PDT	Alive (24 mo)
5	66	Segmental bronchus rB <sup>1</sup>	0.5	Superficial	3	SS (CIS)		Dead (5 mo), other disease
6	69	Segmental bronchus IB <sup>1+2</sup>	0.4	Superficial	14	SS (CIS)	PDT	Alive (27 mo)
7	71	Trachea	0.3	Nodular	10	SS (CIS)	PDT	Alive (27 mo)
8	70	Lobar bronchus rMid.-low	0.9	Superficial	6	SS (intracartilage)	OP (RML)	Dead (56 mo), other disease
9	69	Segmental IB <sup>1+2</sup> B <sup>3</sup>	0.4	Superficial	11	SS (extracartilage)	Nd-YAG, radiation, OP	Alive (65 mo)

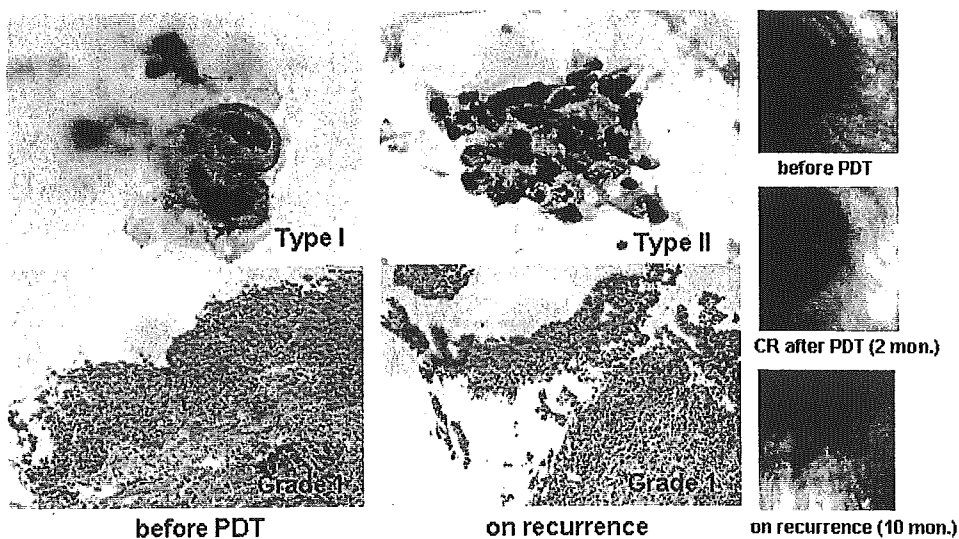
\*PM = peripheral margin initially treated; SS = same site initially treated; OP = operation; RML = right middle lobe; RUL = right upper lobe; LPn = left pneumonectomy; BF = bronchofiberscopic.

**Table 3—Cell Feature and Depth of Bronchial Invasion**

Case No.	Before PDT		Recurrence	
	Cytology (Brush) Type	Pathologic Grade	Cytology (Brush) Type	Pathologic Grade
4	I	1	I	1
5	I	1	I	1
6	I-II	1	I-II	1
7	I	1	II	1
8	I-II	1	II-III	3 (intracartilaginous invasion)
9	I	1	III	3 (extracartilaginous invasion)

peripheral margin of the lesion initially treated by PDT was observed in three patients (cases 1 to 3), while local recurrence at the same site as the initial tumor initially treated was observed in six patients (cases 4 to 9). The local recurrences at the site corresponding to the peripheral lesion were initially located in the subsegmental bronchus in two of three primary lesions. The patients with three local recurrences at the site corresponding to the peripheral margin underwent a second PDT session; however, CR was not obtained in any of these patients. Therefore, additional conventional surgery was performed in two patients and brachytherapy in one

patient. The pathologic examinations of two operated patients showed residual tumor at the peripheral site. Right upper lobectomy was performed for case 1, and the resected material revealed superficial tumor invasion peripheral to the right B<sup>3</sup>b. Left pneumonectomy was selected for case 2 (ipsilateral double cancer) because an ESLC was located at the bifurcation of left B<sup>3</sup>a-b and a malignant lymphoma was in left B<sup>6</sup>. This patient died due to malignant lymphoma at 56 months after the initial PDT session. Four patients (cases 4 to 7) with six local recurrences at the same site as the initial tumor local showed superficial tumor invasion (CIS), and a second PDT session was performed in three of four patients. CRs were again obtained in all three patients, who are presently disease free. One double cancer patient who had advanced stomach cancer underwent systemic chemotherapy without a second PDT but died 5 months after the initial PDT session. The pathologic examinations of the two other surgically treated patients (cases 8 and 9) revealed intracartilaginous invasion of the bronchial wall. One multiple lung cancer patient (case 8) who received right middle and lower lobectomy after local recurrence died of hemoptysis due to another advanced lung cancer at 56 months after the initial PDT session. At the last follow-up of the nine patients who had local recurrence after CR had been obtained by initial PDT in whom the original primary lesion had been < 1.0 cm



**FIGURE 2.** The cytopathologic and bronchoscopic findings in case 7. Bronchoscopic findings showed a small nodular tumor at the right side of the tracheal wall before PDT. Redness of the tracheal mucosa was observed on recurrence at 10 months after PDT. Cytologic findings before PDT were classified as type I because cell features showed a round shape and slight increase of nuclear chromatin but low-grade nuclear atypia. The biopsy specimen showed CIS (grade 1). Cytologic findings on recurrence were classified as type II because a sheet formation of polymorphic-shaped cells, increase of nuclear chromatin, and nuclear body were observed. Biopsy specimen on recurrence showed superficial tumor invasion (CIS) beneath the thin epithelial layer (grade 1). A second PDT was performed, and CR was again obtained in this patient.

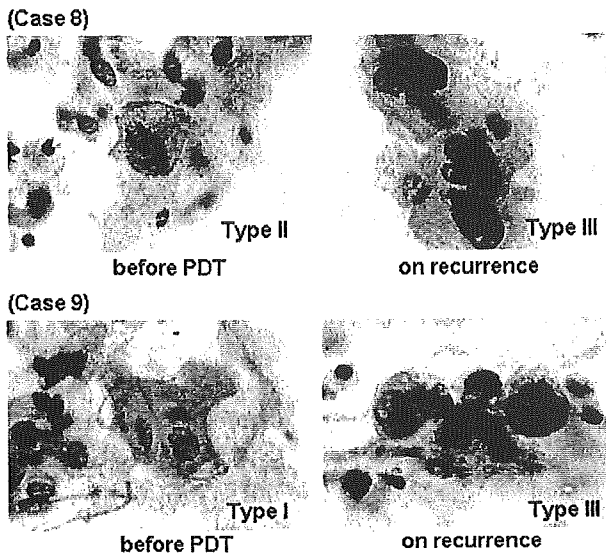


FIGURE 3. The findings of brushing cytology mainly observed in cases 8 and 9 before PDT and on recurrence after CR. Cytologic findings before PDT in case 8 were classified as type II because of a slight increase of nuclear chromatin. Cytologic findings before PDT in case 9 were classified as type I because of low-grade nuclear atypia. The findings of recurrent tumor cells in cases 8 and 9 were classified as type III because of severe increases of nuclear chromatin, high nuclear/cytoplasmic ratio, and high grade of nuclear atypia.

in diameter, three patients had died of other diseases and six patients were alive, and there were no deaths from the primary lesion.

#### *Evaluation of Cytomorphologic Features of Local Recurrences*

As mentioned above, local recurrence of the carcinoma at the same site as lesions < 1.0 cm in diameter initially treated successfully by PDT was observed in six out of nine locally recurrent patients (cases 4 to 9). A summary of the cell features and depth of bronchial wall invasion before PDT and after recurrence are shown in Table 3. The brushing cytology specimens before PDT mainly showed type I or II, and biopsy revealed grade 1 in all six cases. The majority of cell features in cases 4 to 7 showed type I or II, and the biopsy specimens showed grade 1 on recurrences. The cytopathologic and bronchoscopic findings of case 7 are shown Figure 2. Populations of type I and II cells were predominant in the recurrent lesions in these cases, which implied that the recurrent tumor was located in a superficial layer of bronchial wall. When the recurrent tumor cells showed type I-II (low-to-moderate atypia) local recurrence at the same site as the initial tumor initially treated, CR could be obtained by a second PDT. In cases 8 and 9, mainly type III cell features were observed in brushing cytology on recurrence (Fig 3).

These two cases underwent resection, and the resected specimens revealed intracartilaginous tumor invasion of bronchial wall (grade 3), which implied the residual tumor located in a deep layer of bronchial wall.

#### DISCUSSION

PDT for cancer using a combination of low-power laser irradiation and tumor specific photosensitizer was first applied clinically by Dougherty et al<sup>12</sup> in 1978 to the skin metastasis of breast cancer. Since then, we performed the first reported endoscopic clinical application of PDT in cooperation with Dougherty and coworkers.<sup>12</sup> In Japan, PDT using porfimer sodium, a tumor-specific photosensitizer and excimer dye laser, was recognized by the government; and from April 1996, hospitals could receive reimbursement for PDT of early stage carcinomas of the lung, esophagus, stomach, and cervix from the national health insurance system.

The best PDT candidates in lung cancer are cases with central-type ESLC because of their endoscopic accessibility; therefore, selection of patient is important to achieve CR. Nagamoto et al<sup>13</sup> demonstrated that no lymph node involvement was found in 59 cancers with a longitudinal extent of < 20 mm; in another study,<sup>14</sup> histology by serial block sectioning showed that there was no nodal involvement in any CIS cases. Nakamura et al<sup>15</sup> retrospectively analyzed resected cases of central-type ESLC to clarify the relation between the endoscopic findings and the histologic extent of tumor. They demonstrated a significant difference is the maximum dimension according to the depth of bronchial invasion between CIS and extramuscular invasion and CIS and invasion into or beyond the cartilaginous layer. Lesions with a maximum diameter < 1.0 cm have a high possibility of being CIS. Their preoperative bronchoscopic diagnosis of centrally located ESLC was correct in 74.0%. In another study, Akaogi et al<sup>16</sup> demonstrated that polypoid or nodular lesions < 1.0 cm and flatly spreading lesions < 1.5 cm in greatest dimension were limited to within the cartilaginous layer without regional lymph node involvement. Also, Furuse et al<sup>5</sup> demonstrated that the length of longitudinal tumor extent was the only independent predictive factor for CR by PDT, and that lesions < 1.0 cm in diameter showed 100% CR. According to these data, therapy for CR requires satisfaction of the following endoscopic conditions: (1) no evidence of lymph node metastasis; (2) the lesion is superficial with a maximum diameter of < 1.0 cm; (3) no invasion into or beyond the cartilaginous layer; (4) the histologic type is squamous cell carcinoma; and

(5) the lesion is located in a position that can be easily irradiated with the laser.

In this study, excellent efficacy with a significant difference of CR rate was seen in patients with lesions < 1.0 cm (92.8%) compared to  $\geq$  1.0 cm (58.1%) in diameter; however, the overall 5-year survival rate of the two groups showed no significant difference (57.9% vs 59.3%). This may be because it was possible to perform additional alternative modalities such as surgery, second PDT, and brachytherapy to achieve CR after failure of initial PDT or recurrence after PDT. Considering that the 5-year survival rate of pathologic stage Ia (T1N0M0) patients who underwent surgery is approximately 67.0%,<sup>17</sup> our data are favorable because the majority of the PDT group consisted of patients with advanced age and poor cardiopulmonary function. Therefore, we consider that PDT may be used as first-line therapy for central-type ESLC prior to surgery, especially in cases with poor cardiopulmonary function. Also, Edell et al<sup>18</sup> and Cortese et al<sup>19</sup> demonstrated that PDT is an alternative to surgical resection in the management of early superficial squamous cell carcinoma.

In this study, recurrence after CR was recognized in 9 of 77 lesions (11.7%) in the group of patients with lesions < 1.0 cm in diameter. Despite the average diameter of the nine initial lesions being relatively small (0.46 cm), recurrence was recognized in eight of nine lesions (88.9%) within 12 months. Therefore, intensive follow-up studies should be performed until 1 year after PDT even for small primary lesions. The reasons why recurrences after CR were observed in the lesions < 1.0 cm in diameter could be explained by inappropriate estimation of the peripheral margin in cases of local recurrence at the site corresponding to the peripheral margin and insufficient laser irradiation or miss estimation of tumor depth in the cases of local recurrence at the same site as the initial tumor.

From our experiences, to achieve CR with PDT for central-type ESLC, it appears that not only the analysis of cell features but also the comprehension of tumor extent to the peripheral site and tumor invasion to the bronchial wall are of considerable significance. Kurimoto et al<sup>20</sup> demonstrated that endobronchial EBUS was useful to determine the depth of tumor invasion into the bronchial wall, and the accuracy of EBUS from the histopathologic findings was 95.8%. The EBUS image at 20 MHz shows five layers in the cartilaginous portion of bronchial wall. The third to fifth layers are images of cartilage. Therefore, it is feasible to evaluate the depth of invasion using EBUS whether or not the tumor invades into or beyond the cartilaginous layer. In lesions with an intact third layer on EBUS, CR

could be achieved with PDT. Miyazu et al<sup>21</sup> demonstrated that the depth of tumor invasion estimated by EBUS was accurate by histopathologic findings after surgical resection. They found 5 of 14 lesions (35.7%) < 1.0 cm in diameter that showed extracartilaginous invasion on the EBUS image that was later confirmed histopathologically; also, 3 of 5 lesions appeared bronchoscopically superficial but were shown to be extracartilaginous by EBUS. The indications of PDT for centrally located ESLC with a longitudinal extension of < 1.0 cm are unquestionable; meanwhile, we should realize that even < 1.0 cm in diameter can have extracartilaginous invasion. To comprehend the surface extent of superficial tumor invasion in the bronchial lumen, autofluorescence bronchoscopy (AFB) is considered useful.<sup>22-25</sup> The green autofluorescence of the lesion was decreased because of the lack of endogenous fluorophors, thickening of the membrane, and increased microvasculature.<sup>26</sup> We sometimes encountered unexpected surface invasion by AFB.

It is essential to know the extent of the tumor and the depth of bronchogenic carcinoma accurately for the selection of treatment modality. Corresponding to the previous study by Konaka et al,<sup>11</sup> the analysis of cell features is a useful source of information to evaluate the depth of cancer invasion in the bronchial wall. In addition, we believe that it could be beneficial information when choosing the treatment modality, such as recurrence after CR by PDT demonstrated in our study. Additionally, we now perform EBUS and AFB to determine the indications of PDT in all patients who have ESLC for the purpose of achieving 100% CR and reduction of recurrence rate. A comparative study of PDT for the treatment of ESLC before and after the adoption of EBUS and AFB will enable accurate evaluation of the benefits of these new diagnostic tools in the near future.

**ACKNOWLEDGMENT:** The authors are indebted to Professor J. P. Barron of the International Medical Communications Center of Tokyo Medical University for his review of this article.

#### REFERENCES

- 1 Hayata Y, Kato H, Konaka C, et al. Hematoporphyrin derivative and laser photoradiation in the treatment of lung cancer. *Chest* 1982; 81:269-277
- 2 Kato H, Konaka C, Kawate N, et al. Five-year disease-free survival of a lung cancer patient treated only by photodynamic therapy. *Chest* 1986; 90:768-770
- 3 Edell ES, Cortese DA. Bronchoscopic phototherapy with hematoporphyrin derivative for treatment of localized bronchogenic carcinoma: a 5-year experience. *Mayo Clin Proc* 1987; 62:8-14
- 4 Edell ES, Cortese DA. Bronchoscopic localization and treatment of occult lung cancer. *Chest* 1989; 96:919-921
- 5 Furuse K, Fukuoka M, Kato H, et al. A prospective phase II

- study on photodynamic therapy with Photofrin II for centrally located early-stage lung cancer. *J Clin Oncol* 1993; 11:1852-1187
- 6 Kato H. Photodynamic therapy for lung cancer: a review of 19 years' experience. *J Photochem Photobiol* 1998; B42:96-99
  - 7 Kato H, Furukawa K, Sato M, et al. Phase II clinical study of photodynamic therapy using mono-L-aspartyl chlorin e6 and diode laser for early superficial squamous cell carcinoma of the lung. *Lung Cancer* 2003; 42:103-111
  - 8 Niedre M, Patterson MS, Wilson BC. Direct near-infrared luminescence detection of singlet oxygen generated by photodynamic therapy in cells *in vitro* and tissues *in vivo*. *Photochem Photobiol* 2002; 75:382-391
  - 9 General rules for clinical and pathological records of lung cancer. 4th ed. In: Japan Lung Cancer Society, eds. Tokyo, Japan: Kanehara and Company, 1995; 123-133
  - 10 Niiya H. Toxicity grading criteria of the Japan Clinical Oncology Group. *Int J Clin Oncol* 1997; 32:61-65
  - 11 Konaka C, Miura H, Ikeda N, et al. The characteristics of early bronchogenic carcinoma evaluated by cytomorphological features. *Lung Cancer* 2002; 38:267-271
  - 12 Dougherty TJ, Lawrence G, Kaufman JH, et al. Photoradiation in the treatment of recurrent breast carcinoma. *J Natl Cancer Inst* 1978; 62:231-237
  - 13 Nagamoto N, Saito Y, Ohta S, et al. Relationship of lymph node metastasis to primary tumor size and microscopic appearance of roentgenographically occult lung cancer. *Am J Surg Pathol* 1989; 13:1009-1013
  - 14 Nagamoto N, Saito Y, Sato M, et al. Clinicopathological analysis of 19 cases of isolated carcinoma in situ of the bronchus. *Am J Surg Pathol* 1993; 17:1234-1243
  - 15 Nakamura H, Kawasaki N, Hagiwara M, et al. Endoscopic evaluation of centrally located early squamous cell carcinoma of the lung. *Cancer* 2001; 91:1142-1147
  - 16 Akaogi E, Ogawa I, Mitsui K, et al. Endoscopic criteria of early squamous cell carcinoma of the bronchus. *Cancer* 1994; 74:3113-3117
  - 17 Mountain CF. Revisions in the international system for staging lung cancer. *Chest* 1997; 111:1710-1717
  - 18 Edell ES, Cortese DA. Photodynamic therapy in the management of early superficial squamous cell carcinoma as an alternative to surgical resection. *Chest* 1992; 102:1319-1322
  - 19 Cortese DA, Edell ES, Kinsey JH. Photodynamic therapy for early stage squamous cell carcinoma of the lung. *Mayo Clin Proc* 1997; 72:595-602
  - 20 Kurimoto N, Murayama M, Yoshioka S, et al. Assessment of usefulness of endobronchial ultrasonography in determination of depth of tracheobronchial tumor invasion. *Chest* 1999; 115:1500-1506
  - 21 Miyazu Y, Miyazawa T, Kurimoto N, et al. Endobronchial ultrasonography in the assessment of centrally located early-stage lung cancer before photodynamic therapy. *Am J Respir Crit Care Med* 2002; 165:832-837
  - 22 Lam S, Kennedy T, Unger M, et al. Localization of bronchial intraepithelial neoplastic lesions by fluorescence bronchoscopy. *Chest* 1998; 113:696-702
  - 23 Ikeda N, Hiyoshi T, Kakihana M, et al. Histopathological evaluation of fluorescence bronchoscopy using resected lungs in cases of lung cancer. *Lung Cancer* 2003; 41:303-309
  - 24 Sutedja TG, Codrington H, Risse EK, et al. Autofluorescence bronchoscopy improves staging of radiographically occult lung cancer and has an impact on therapeutic strategy. *Chest* 2001; 120:1327-1332
  - 25 Sutedja TG, Venmans BJ, Smit EF, et al. Fluorescence bronchoscopy for early detection of lung cancer: a clinical perspective. *Lung Cancer* 2001; 34:157-168
  - 26 Furukawa K, Ikeda N, Miura T, et al. Is autofluorescence bronchoscopy needed to diagnose early bronchogenic carcinoma? *J Bronchol* 2003; 10:64-69

# Quantitative Detection of Lung Cancer Cells by Fluorescence *In Situ* Hybridization\*

## Comparison With Conventional Cytology

Haruhiko Nakamura, MD, PhD; Idiris Aute, MD, PhD; Norihito Kawasaki, MD; Masahiko Taguchi, MD, PhD; Tatsuo Ohira, MD, PhD; and Harubumi Kato, MD, PhD, FCCP

**Study objective:** The aim of this study was to clarify whether fluorescence *in situ* hybridization (FISH) can diagnose lung cancer in various clinical specimens in comparison with conventional cytology.

**Design:** Prospective study.

**Setting:** University hospital in a metropolitan area.

**Patients:** Fifty consecutive patients with abnormal chest radiography or CT scan findings were enrolled. The patients included 32 men and 18 women, with an average age of 64 years. The final definitive diagnosis was made by histologic examination, as follows: 38 primary lung cancers (24 adenocarcinomas, 8 squamous cell carcinomas, 2 large cell carcinomas, and 4 small cell carcinomas); 1 metastatic renal cell carcinoma; and 11 benign lesions.

**Methods:** Four types of clinical specimens were analyzed. Cells obtained by transbronchial brushing and transbronchial fine-needle aspiration using a fiberoptic bronchoscope under fluoroscopy, CT scan-guided percutaneous needle biopsy, and bronchial washings. On every examination, duplicate slides were made for analyses of conventional cytology and FISH.

**Results:** Classifications according to conventional cytology were as follows: class I, 4 patients; class II, 15 patients; class IIIa, 3 patients; class IIIb, 5 patients; and class V, 23 patients. A classification higher than class IIIb was considered to be positive for cancer. For cytology, we found no false-positive cases and 11 false-negative cases. The specificity was 100%, and the sensitivity was 71.8%. By FISH, 34 cases showed aberrant copy numbers in either chromosome 3 or 17. We found no false-positive cases and five false-negative cases. The specificity was 100%, and the sensitivity was 87.1%.

**Conclusion:** The ability of FISH to detect aneusomic lung cancer cells is superior to conventional cytology for the diagnosis of lung cancer. (CHEST 2005; 128:906-911)

**Key words:** aneuploidy; aneusomy; cytology; fluorescence *in situ* hybridization; lung cancer

**Abbreviations:** BW = bronchial washing; FISH = fluorescence *in situ* hybridization; PN = percutaneous needle biopsy; SSC = standard saline citrate; TB = transbronchial brushing

Conventional cytology plays an important role for the diagnosis of lung cancer, especially in the examination of sputum and pleural effusions. In addition, cell specimens obtained by transbronchial brushing (TB)<sup>1</sup> and needle aspiration under fluoroscopy,<sup>2</sup> percutaneous needle biopsy (PN) under CT

scanning,<sup>3</sup> and bronchial washings (BWs)<sup>4</sup> provide important information for the differential diagnosis between benign and malignant disease. Cytologic diagnoses are made by experienced cytologists who can properly evaluate the morphologic features of malignant cells. However, this judgment is some-

\*From the Department of Chest Surgery (Drs. Nakamura, Kawasaki, and Taguchi), Atami Hospital, International University of Health and Welfare, Atami, Shizuoka, Japan; the Department of Thoracic Surgery (Dr. Aute), The First Affiliated Hospital, Xinjiang Medical University, Urumqi, People's Republic of China; and the Department of Surgery (Drs. Ohira and Kato), Tokyo Medical University, Tokyo, Japan. Supported by grant No. 15591493 from the Ministry of Education, Science, Sports, and Culture in Japan.

Manuscript received September 2, 2004; revision accepted January 13, 2005.

Reproduction of this article is prohibited without written permission from the American College of Chest Physicians ([www.chestjournal.org/misc/reprints.shtml](http://www.chestjournal.org/misc/reprints.shtml)).

Correspondence to: Haruhiko Nakamura, MD, PhD, Department of Chest Surgery, Atami Hospital, International University of Health and Welfare, 13-1 Higashikaigan-cho, Atami-city, Shizuoka, Japan 413-0012; e-mail: h.nakamura@iuhw.ac.jp

times difficult when the morphologic changes associated with malignancy are mild. Such cells are usually classified as class III, using the classification of Papanicolaou,<sup>5</sup> which is suggestive of, but not conclusive for, malignancy. This is an ambiguous judgment for clinical decision making. In addition, when one obtains a small number of cells from the lesion, the definitive diagnosis is even more difficult. These limitations of morphology-based conventional cytology have stimulated the search for more objective and quantitative methods for an accurate cytologic diagnosis of cancer.

Aneuploidy is the most common feature of many solid tumors, including lung cancer.<sup>6</sup> Solid tumors are characterized by complicated karyotypes by classic cytogenetics.<sup>7,8</sup> Chromosomal instability<sup>9,10</sup> may cause the uneven distribution of chromosomes during cell division.<sup>11,12</sup> Thus, malignant tumors can be diagnosed by detecting aneuploid, usually hyperdiploid, cells. A rapid and sensitive method for detecting aneusomy of a specific chromosome in an individual cell is fluorescence *in situ* hybridization (FISH). For this purpose, specific centromeric DNA probes enumerated the chromosomes. FISH was originally developed as a method to detect chromosomal aberrations,<sup>13</sup> and is now widely used for gene mapping,<sup>14</sup> the diagnosis of congenital diseases,<sup>15</sup> and detecting specific gene copy number changes in malignant cells.<sup>16-18</sup>

One advantage of FISH in detecting malignant cells is its objective and quantitative evaluation. However, the specificity and sensitivity of FISH in the diagnosis of lung cancer is unclear. We report the results of a prospective study comparing FISH with conventional cytology to detect lung cancer cells.

## MATERIALS AND METHODS

### Patients

Fifty consecutive patients who underwent cytologic examination for abnormal chest radiography or CT scan findings at Tokyo Medical University Hospital from July 2003 to January 2004 were enrolled in this prospective study. The patients included 32 men and 18 women, with an average age of 64 years. The final definitive diagnosis was made by histologic examination, as follows: 38 primary lung cancers (24 adenocarcinomas, 8 squamous cell carcinomas, 2 large cell carcinomas, and 4 small cell carcinomas); 1 metastatic renal cell carcinoma; and 11 benign lesions. All patients with lung cancer were staged according to the latest Union Internationale Centre le Cancer criteria.<sup>19</sup> Cases included 10 tumors in stage IA, 5 in stage IB, 1 in stage IIA, 3 in stage IIB, 10 in stage IIIA, 6 in stage IIIB, and 3 in stage IV (Table 1).

Cells gathered from lung lesions were independently analyzed by conventional cytology and FISH. Informed consent for the cytologic examinations and genetic analyses of the specimens were obtained from all patients.

**Table 1—Histology and Stage of Lung Cancer in This Series of Patients\***

Case	Age	Gender	Specimen	Histology	Stage
1	59	M	TB	Sq	cIIIA
2	42	F	PN	B	NA
3	43	M	TB	Ad	PIIIA
4	70	M	TB	Ad	CIIV
5	77	M	TB	Ad	PIA
6	73	M	PN	Ad	PIA
7	58	M	TN	Ad	PIA
8	71	M	BW	Ad	pIIIA
9	71	M	BW	La	pIB
10	66	F	TN	RCC	NA
11	65	F	TB	Sm	cIIIB
12	68	F	PN	Ad	pIA
13	69	F	BW	Ad	pIV
14	52	F	TB	Ad	pIIA
15	75	F	TN	Sq	pIA
16	37	M	PN	B	NA
17	64	M	PN	Ad	pIIB
18	58	F	TB	B	NA
19	73	F	PN	Ad	pIA
20	62	M	PN	B	NA
21	69	M	TB	B	NA
22	76	M	BW	La	cIIIB
23	76	M	PN	Ad	cIIIB
24	75	M	PN	Ad	pIB
25	65	M	BW	Sm	cIIIA
26	23	M	PN	B	NA
27	74	M	BW	Ad	cIV
28	72	F	PN	B	NA
29	80	M	TB	B	NA
30	56	M	BW	Ad	pIB
31	64	M	TB	B	NA
32	58	M	PN	Ad	cIIIA
33	72	F	PN	Ad	pIA
34	72	M	PN	Ad	cIIIA
35	66	F	TB	Sm	cIIIB
36	61	M	TB	Ad	pIIB
37	72	F	TB	Ad	pIB
38	52	M	PN	B	NA
39	64	M	TB	Ad	pIA
40	79	F	TB	Sq	cIB
41	39	M	TB	B	NA
42	78	M	BW	Sq	cIIIB
43	62	M	TB	Sq	cIIIA
44	57	M	TB	Sq	pIIIA
45	70	M	PN	Ad	pIA
46	55	F	PN	Ad	pIA
47	58	F	TN	Sq	cIIIB
48	66	F	TN	Ad	pIIB
49	62	M	BW	Sm	cIIIA
50	72	F	BW	Sq	cIIIA

\*M = male; F = female; TN = transbronchial needle biopsy; Ad = adenocarcinoma; Sq = squamous cell carcinoma; La = large cell carcinoma; Sm = small cell carcinoma; RCC = renal cell carcinoma; B = benign lesion; c = clinical stage; p = pathologic stage; NA = not applicable.

### Cell Samples

In this study, the following four types of cell specimens were analyzed: cells obtained by TB (n = 18) and transbronchial fine-needle aspiration (n = 5) using a fiberoptic bronchoscope

under fluoroscopy, CT scan-guided PN using the 19-gauge Tokyo Medical University Needle<sup>3</sup> (n = 17), and BWs (n = 10). On every examination, duplicate specimens were made for simultaneous analyses of conventional cytology and FISH.

For conventional cytology, cells were stained by the Papanicolaou method.<sup>5</sup> Diagnosis was made by cytologists in the Department of Pathology at Tokyo Medical University Hospital. The various classes in conventional cytology are defined as follows: class I, absence of atypical or abnormal cells; class II, atypical cytology but no evidence of malignancy; class III, cytology suggestive of, but not conclusive for, malignancy (IIIa, mild dysplasia; IIIb, advanced dysplasia); class IV, cytology strongly suggestive of malignancy; and class V, cytology conclusive for malignancy.<sup>5</sup>

#### FISH

For FISH, cells on glass slides were air-dried overnight and stored at -80°C until they were used. Direct fluorochrome-labeled centromeric probes were used for the enumeration of different chromosomes. Spectrum-orange-labeled or Spectrum-green-labeled probes for the respective centromeric regions of chromosomes 3 and 17 were purchased (Vysis Inc; Downers Grove, IL), and dual-color FISH was performed. Slides were denatured by incubation with 70% formamide (two times the standard saline citrate [SSC] solution) at 74°C for 2 min in a water bath. Then, slides were dehydrated through a graded ethanol system (70% for 2 min, 85% for 2 min, and 100% for 2 min). A hybridization solution (10 µL) was applied to each slide, which was coverslipped and sealed with rubber cement. The hybridization solution contained 1 µL each DNA probe in 70% formamide (two times the SSC solution), and 10% dextran sulfate solution (cot I DNA). After incubation for 16 h at 37°C in a humidified chamber, slides were washed (two times SSC solution) for 3 min at 74°C. A di-amidinophenylindole antifade solution (8 µL) was applied to each spot and coverslipped. The slides were observed under a fluorescence microscope that was connected to a cooled charge-coupled device camera and an image analyzer system (CytoVision; Applied Imaging, Ltd; Newcastle, UK).

FISH signal analysis was performed as follows. All cells in a fluorescence microscopy field, except for those with damaged or overlapped nuclei, were evaluated. One hundred cells were counted, and the numbers of each centromeric signal were recorded. If there were < 100 cells on the slide, as many cells as possible were counted. When the percentages of hyperdisomic cells (*ie*, more than three copies for at least one chromosome) were > 10%, we judged the lesion to be malignant.

#### Comparison of Conventional Cytology and FISH

FISH diagnoses were made without clinical information or the results of conventional cytology. The results of FISH analysis were not shown to the cytologists. Thus, both diagnoses were independently made in a blind fashion.

#### Statistical Analysis

Differences in the number of countable cells according to the histology of the lung lesions or the cell-gathering methods used were analyzed by the Kruskal-Wallis test. A *p* value of < 0.05 was considered to be significant.

## RESULTS

Cells countable for FISH analyses ranged from 5 to 100 (maximum). Cell counts according to the

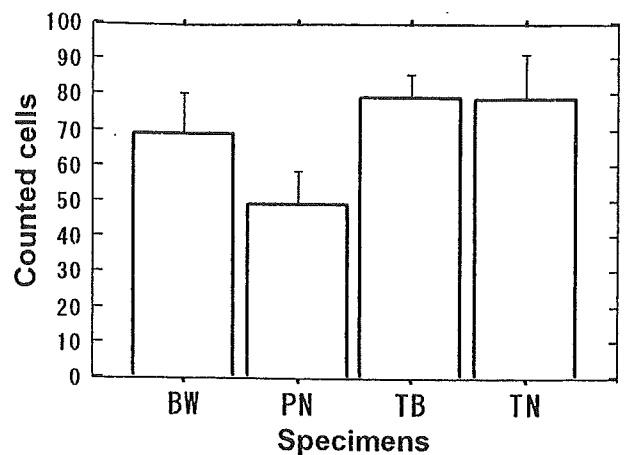


FIGURE 1. Countable cells according to the type of clinical specimen. Although cell counts obtained by PN were the lowest, no statistical significance was obtained by the Kruskal-Wallis test ( $p = 0.1117$ ). Error bars indicate standard error. TN = transbronchial fine-needle aspiration.

cell-gathering method did not differ significantly, but the fewest cells were obtained by PN (Fig 1). Although the fewest cells were obtained from small cell carcinomas, no significant difference was seen according to the histologic type of lung cancer (Fig 2).

The results of conventional cytology according to the Papanicolaou classification were as follows: class I, 4 cases; class II, 15 cases; class IIIa, 3 cases; class IIIb, 5 cases; and class V, 23 cases (Table 2). Twenty-eight cases showing a higher grade than class IIIb were considered to be positive for lung cancer. By cytology, we found no false-positive cases and 11

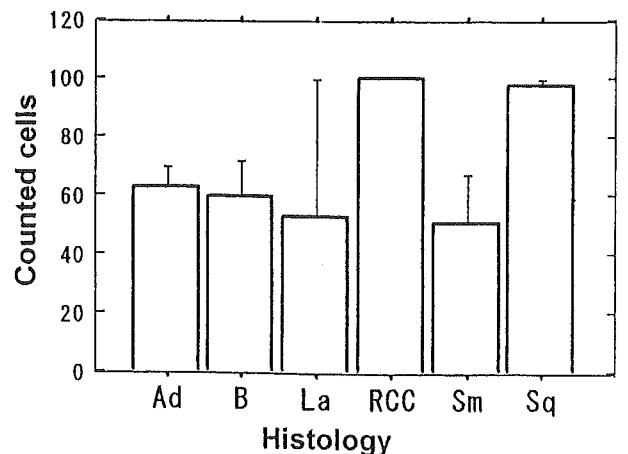


FIGURE 2. Countable cells according to histology. Although cell counts obtained from small cell lung cancer (Sm) were the lowest, no statistical significance was obtained by the Kruskal-Wallis test ( $p = 0.2369$ ). Error bars indicate SE. Ad = adenocarcinoma; B = benign lesion; La = large cell carcinoma; RCC = renal cell carcinoma; Sq = squamous cell carcinoma.

Table 2—Results of FISH and Conventional Cytology\*

Case	Countable Cells	Three Copies	Four Copies	Five Copies	Six Copies or More	Hyperdisomy, %	FISH	Cytology Stage
		C3/C17	C3/C17	C3/Ch17	C3/C17	C3/C17		
1	100	28/18	10/2	2/2	0/0	40/22	Positive	V
2	8	0/0	0/0	0/0	0/0	0/0	Negative	II
3	100	14/9	4/4	1/1	0/0	18/13	Positive	V
4	100	16/8	0/1	1/0	0/0	17/9	Positive	II†
5	52	2/0	1/0	0/0	0/0	3/0	Negative†	II†
6	100	9/0	1/3	1/0	0/0	10/3	Positive	IIIa†
7	44	7/3	0/0	1/0	0/0	18/7	Positive	II†
8	100	6/6	0/2	2/2	0/0	8/10	Positive	V
9	5	0/0	0/0	0/0	0/0	0/0	Negative†	I†
10	100	17/26	2/5	1/2	0/0	20/33	Positive	II†
11	100	38/37	9/2	3/0	1/0	51/39	Positive	V
12	17	2/3	2/1	1/0	0/0	29/29	Positive	V
13	79	5/11	5/3	4/1	0/0	18/19	Positive	IIIb
14	100	7/3	0/0	0/0	1/0	8/3	Negative†	II†
15	100	9/0	1/3	1/0	0/0	11/3	Positive	II†
16	42	0/1	0/0	0/0	0/0	0/2	Negative	II
17	100	22/16	2/11	3/5	0/1	27/33	Positive	V
18	100	2/0	0/0	0/0	0/0	2/0	Negative	I
19	26	5/8	0/0	0/0	0/0	19/31	Positive	IIIb
20	100	1/1	0/0	0/0	0/0	1/1	Negative	II
21	100	0/0	0/0	0/0	0/0	0/0	Negative	II
22	100	17/14	3/1	2/2	1/1	23/18	Positive	IIIb
23	5	1/1	0/0	0/0	0/0	20/20	Positive	IIIb
24	100	22/23	5/7	1/3	2/1	30/34	Positive	V
25	37	13/10	1/7	1/0	0/0	41/46	Positive	V
26	8	0/0	0/0	0/0	0/0	0/0	Negative	IIIa
27	43	1/1	0/0	0/0	0/0	2/2	Negative†	I†
28	100	0/0	0/0	0/0	0/0	0/0	Negative	I
29	44	0/0	0/1	0/0	0/0	0/2	Negative	II
30	100	8/6	1/1	0/1	0/0	9/8	Negative†	IIIb
31	100	2/0	0/0	0/0	0/0	2/0	Negative	II
32	8	2/3	1/1	1/0	0/0	50/50	Positive	V
33	21	4/5	1/0	0/0	0/0	24/24	Positive	V
34	57	27/31	5/2	2/1	0/1	60/61	Positive	V
35	40	10/9	2/3	4/0	0/2	40/35	Positive	V
36	100	15/15	1/4	1/1	0/0	17/20	Positive	V
37	38	2/4	0/0	0/0	0/0	5/11	Positive	V
38	23	0/1	0/0	0/0	0/0	0/4	Negative	II
39	45	9/9	1/4	2/1	0/0	27/31	Positive	V
40	79	14/12	1/1	1/0	0/0	20/16	Positive	V
41	30	0/1	0/0	0/0	0/0	0/3	Negative	II
42	100	17/6	3/1	0/1	0/0	20/8	Positive	V
43	100	19/18	3/6	4/1	2/0	28/25	Positive	II†
44	100	18/15	1/5	0/1	0/0	19/21	Positive	V
45	100	11/7	0/1	0/0	0/0	11/8	Positive	V
46	14	4/3	0/0	0/0	0/0	29/21	Positive	V
47	100	15/15	0/8	0/1	0/0	15/24	Positive	V
48	48	8/6	0/1	0/0	0/0	17/15	Positive	V
49	25	4/6	1/0	0/0	0/0	20/24	Positive	V
50	100	21/28	5/5	1/1	0/0	27/34	Positive	IIIa†

\*C3 = chromosome 3; C17 = chromosome 17.

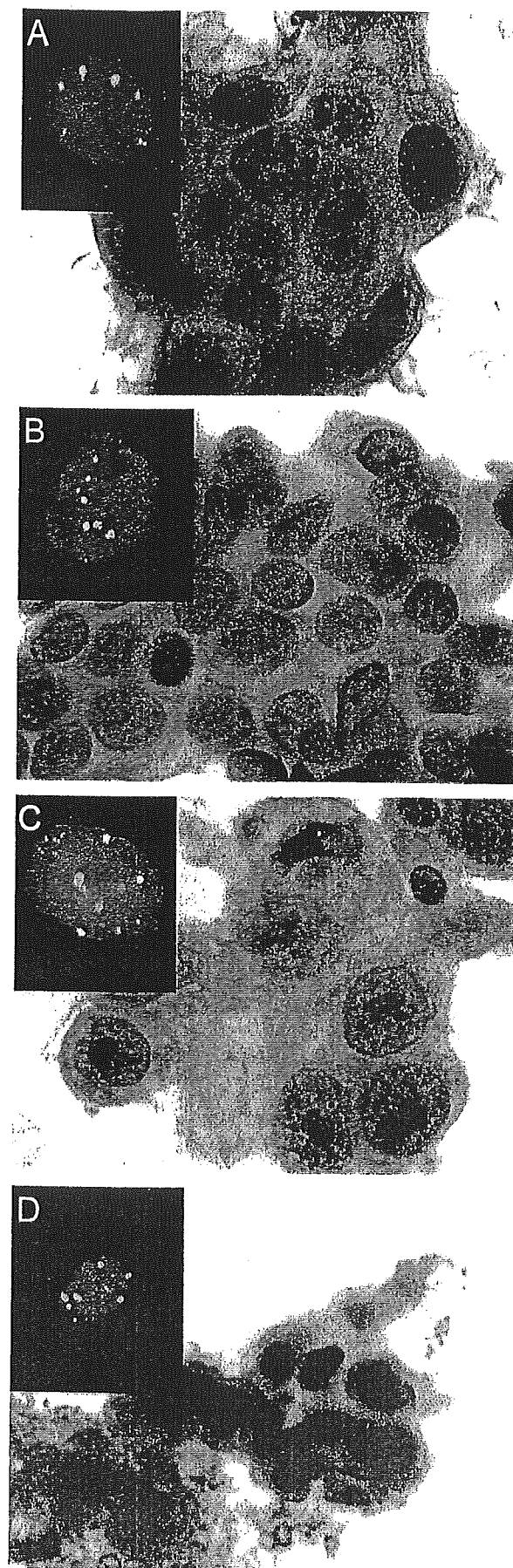
†False-negative result.

false-negative cases. Thus, by conventional cytology, specificity was 100%, and sensitivity was 71.8%.

In FISH analyses, 34 cases showed aberrant copy numbers in either chromosome 3 or 17. Representative findings of conventional cytology and FISH

are shown in Figure 3. We found no false-positive cases and five false-negative cases. For FISH analyses, specificity was 100%, and sensitivity was 87.1%.

Seven cases, including one with metastatic renal cell carcinoma, had negative cytology findings and



positive FISH findings. In these cases, the cytologic classifications were as follows: class II, five cases; and class IIIa, two cases. One case was cytology-positive and FISH-negative. In this case, the portion of aneusomic cells were observed to be 8 to 9%, which is just below the predetermined cutoff value.

#### DISCUSSION

We demonstrated here the usefulness of FISH analyses in diagnosing lung cancer using various clinical specimens. Similar results about the effectiveness of FISH analyses have been reported by several authors. Schenk et al<sup>20</sup> examined 23 patients with lung cancer by FISH with probes specific for chromosomes 3, 8, 11, 12, 17, and 18 for malignant effusions and primary tumors. In that study, chromosomal alterations always consisted of gains in chromosomal signal numbers, and all chromosomes were found to be aneusomic to a similar extent. According to this observation, we used only two probes in the present study, which were specific for chromosomes 3 and 17.

Recently, Sokolova et al<sup>21</sup> analyzed BW specimens from 48 patients with lung cancer by FISH using four probes (*ie*, centromeric region of chromosome 1, 5p15, 8q24 (*c-myc*), and 7p12 [epidermal growth factor receptor]). In that report, FISH detected 15 of 18 specimens that were falsely negative by cytology. The sensitivity of FISH for the detection of lung cancer was 82% compared with 54% sensitivity by conventional cytology. The same group<sup>22</sup> used a similar FISH probe set to show that significantly higher frequencies of abnormal cells were found in each of the 20 surgical specimens of non-small cell carcinoma (100%) and in the 3 sputum specimens (100%) from lung cancer patients. These probes detected a 4.8 to 7.3% rate of abnormal copy numbers in normal control specimens. In these retrospective studies, FISH detected lung cancer cells in touch preparations of resected tumors and BWs. Thus, we planned a prospective study to compare conventional cytology with FISH using various specimens from lung lesions.

In our study, we determined the cutoff value for the percentage of hyperdisomic cells to be 10%, be-

FIGURE 3. Hyperdisomic cells detected by FISH. Red signals are the centromeric region of chromosome 3, and green signals are the centromeric region of chromosome 17. Representative findings of conventional cytology (Papanicolaou stain, original  $\times 400$ ) and FISH in the same cases, as follows: *top left*, A: adenocarcinoma (case 39); *top right*, B: squamous cell carcinoma (case 1); *bottom left*, C: large cell carcinoma (case 24); and *bottom right*, D: small cell carcinoma (case 11).

cause we often count  $\leq 6\%$  hyperdisomic cells in normal cell specimens, probably due to counting sister chromatids as two copies. When we set the cutoff value at 10%, a specificity of 100% and a sensitivity of 87.1% were obtained by FISH, whereas the sensitivity of cytology was 71.8%. As a result, we successfully detected seven lung cancer cases that were cytology-negative. Among these cases, two were class IIIa that we could not diagnose as malignant based on morphologic features. FISH may provide decisive information for the detection of malignancies, especially cases with IIIa classification.

Although the sensitivity of FISH is superior to that of conventional cytology, there are some disadvantages to FISH analyses. First, we do not generate information about the histologic type of lung cancer since we cannot observe morphologic features. Second, FISH is expensive. Third, FISH signal counting under fluorescence microscopy is time-consuming. Thus, the present FISH assay system probably can play a complementary role to that of conventional cytology.

We had five cases that we could not correctly diagnose by FISH. There are two possible reasons for our false-negative FISH results. One would be the failure to obtain proper cell material from the lesion, resulting in the absence of cancer cells on the slide. The other would be that the cancer cells were near-diploid, such that we could not detect aneuploidy in two target chromosomes. We could probably detect more aneusomic cells using additional suitable probes for other chromosomes or chromosomal regions as reported by Romeo et al,<sup>22</sup> who successfully diagnosed 100% of lung cancer cases by FISH using a set of four probes. In our previous study,<sup>23</sup> chromosomal instability detected by FISH was associated with poor survival in patients with lung cancer. The finding of multiple chromosomal changes by FISH may be used as a prognostic factor and in the selection of patients for different therapeutic programs in the future.

In conclusion, FISH can detect lung cancer cells with aneuploidy in various clinical specimens. The sensitivity was superior to that of conventional cytology. FISH should be used in conjunction with conventional cytology.

#### REFERENCES

- 1 Muers M, Boddington M, Cole M, et al. Cytological sampling at fiberoptic bronchoscopy: comparison of catheter aspirates and brush biopsies. *Thorax* 1982; 37:457-461
- 2 Schenk D, Bryan C, Bower J, et al. Transbronchial needle aspiration in the diagnosis of bronchogenic carcinoma. *Chest* 1987; 92:83-85
- 3 Saji H, Nakamura H, Tsuchida T, et al. The incidence and the

- risk of pneumothorax and chest tube placement after percutaneous CT-guided lung biopsy: the angle of the needle trajectory is a novel predictor. *Chest* 2002; 121:1521-1526
- 4 Ng A, Horak G. Factors significant in the diagnostic accuracy of lung cytology in bronchial washing and sputum samples: I. Bronchial washings. *Acta Cytol* 1983; 27:391-396
- 5 Papanicolaou G. *Criteria of malignancy*. In: *Atlas of exfoliative cytology*. Cambridge, MA: Harvard University Press, 1954; 13-21
- 6 Choma D, Daures J-P, Quantin X, et al. Aneuploidy and prognosis of non-small-cell lung cancer: a meta-analysis of published data. *Br J Cancer* 2001; 85:14-22
- 7 Nowell P. The clonal evolution of tumor cell populations. *Science* 1976; 194:23-28
- 8 Hoglund M, Gisselsson D, Sall T, et al. Coping with complexity. Multivariate analysis of tumor karyotypes. *Cancer Genet Cytogenet* 2002; 135:103-109
- 9 Lengauer C, Kinzler K, Vogelstein B. Genetic instabilities in human cancers. *Nature* 1998; 396:643-649
- 10 Duesberg P, Rausch C, Rasnick D, et al. Genetic instability of cancer cells is proportional to their degree of aneuploidy. *Proc Natl Acad Sci U S A* 1998; 95:13692-13697
- 11 Cahill D, Lengauer C, Yu J, et al. Mutations of mitotic checkpoint genes in human cancers. *Nature* 1998; 392:300-303
- 12 Pihan G, Doxsey S. The mitotic machinery as a source of genetic instability in cancer. *Semin Cancer Biol* 1999; 9:289-302
- 13 Pinkel D, Straume T, Gray J. Cytogenetic analysis using quantitative, high-sensitivity, fluorescence hybridization. *Proc Natl Acad Sci U S A* 1986; 83:2934-2938
- 14 Gingrich J, Shadravan F, Lowry S. A fluorescence *in situ* hybridization map of human chromosome 21 consisting of 30 genetic and physical markers on the chromosome: localization of 137 additional YAC and cosmid clones with respect to this map. *Genomics* 1993; 17:98-105
- 15 Kuo W, Tenjin H, Segraves R, et al. Detection of aneuploidy involving chromosomes 13, 18, or 21, by fluorescence *in situ* hybridization (FISH) to interphase and metaphase amniocytes. *Am J Hum Genet* 1991; 49:112-119
- 16 Kallioniemi O, Kallioniemi A, Kurisu W, et al. ERBB2 amplification in breast cancer analyzed by fluorescence *in situ* hybridization. *Proc Natl Acad Sci U S A* 1992; 89:5321-5325
- 17 Gray J, Collins C, Henderson I, et al. Molecular cytogenetics of human breast cancer. *Cold Spring Harb Symp Quant Biol* 1994; 59:645-652
- 18 Hiraguri S, Godfrey T, Nakamura H, et al. Mechanisms of inactivation of E-cadherin in breast cancer cell lines. *Cancer Res* 1998; 58:1972-1977
- 19 Mountain C. Revisions in the International System for Staging Lung Cancer. *Chest* 1997; 111:1710-1717
- 20 Schenk T, Ackermann J, Brunner C, et al. Detection of chromosomal aneuploidy by interphase fluorescence *in situ* hybridization in bronchoscopically gained cells from lung cancer patients. *Chest* 1997; 111:1691-1696
- 21 Sokolova I, Bubendorf L, O'Hare A et al. A fluorescence *in situ* hybridization-based assay for improved detection of lung cancer cells in bronchial washing specimens. *Cancer* 2002; 96:306-315
- 22 Romeo M, Sokolova I, Morrison L, et al. Chromosomal abnormalities in non-small cell lung carcinomas and in bronchial epithelia of high-risk smokers detected by multi-target interphase fluorescence *in situ* hybridization. *J Mol Diagn* 2003; 5:103-112
- 23 Nakamura H, Saji H, Idris A, et al. Chromosomal instability detected by fluorescence *in situ* hybridization in surgical specimens of non-small cell lung cancer is associated with poor survival. *Clin Cancer Res* 2003; 9:2294-2299