

peritoneum than after laparotomy as determined by DTH in a murine model.^{18,19} All these findings suggest that postoperative systemic cell-mediated immune function is less impaired after laparoscopic surgery.

Several clinical studies on the effect of pneumoperitoneum on systemic T-lymphocyte subpopulations have also been reported. Vallina and Velasco showed that the ratio of T-helper lymphocytes to T-suppressor lymphocytes decreased after laparoscopic cholecystectomy,²⁰ while Brune et al. reported that T lymphocytes were stimulated after open cholecystectomy, but not after laparoscopic cholecystectomy.²¹ Brune et al. also showed that the Th1/Th2 balance was better preserved after laparoscopic cholecystectomy than after open cholecystectomy.²²

Clinically, the laparoscopic procedure is better than the open procedure from the standpoint of systemic cell-mediated immune response. Lacy et al. recently reported the results of a randomized clinical trial on laparoscopy-assisted colectomy and open colectomy, for stage III tumors, which showed that laparoscopic surgery contributed to earlier recovery and oral-intake times, shorter hospital stay, lower morbidity, and higher survival rate than open colectomy.² Our study also supports the usefulness of laparoscopic surgery as a less invasive alternative to open surgery.

There are few reports about cell-mediated immunity in the peritoneal cavity after surgical procedures. By analyzing rat PECs on the first day after the operative procedures, Gutt et al. showed that systemic CD4/8 was increased and peritoneal CD4/8 was decreased in both laparoscopic and open surgery groups, but the differences between the groups were not significant.¹¹ In our study analyzing T-lymphocyte populations in murine PECs over time, the percentages of CD3⁺, CD4⁺, and CD8⁺ T lymphocytes increased for a shorter period after laparotomy than after pneumoperitoneum, and the peritoneal CD4/8 ratio of POD 3 was less impaired after pneumoperitoneum than after laparotomy. The cause for these modifications in immunity in the peritoneal cavity after surgery remains unclear.

Peritoneal mesothelial cells are known to secrete several cytokines that regulate inflammation, wound healing, and tissue regeneration.^{23,24} Betjes et al. showed that mesothelial cells produced interleukin-8 by stimulating interleukin-1 and tumor necrosis factor- α .²⁵ These cytokines could induce T-lymphocyte migration to the intraperitoneal cavity in response to surgical stress. Laparotomy may result in a stronger stimulation of peritoneal mesothelial cells than pneumoperitoneum, which would explain the increased populations of T lymphocytes and NK cells in PECs after laparotomy.

In our previous studies, CO₂ pneumoperitoneum and laparotomy caused different morphologic changes in mesothelial cells, upregulated the intraperitoneal secre-

tion of hyaluronic acid, and increased the expression of adhesion molecules in peritoneal mesothelial cells.^{12,13,26} When CO₂ pneumoperitoneum or laparotomy is performed, different types of injuries to peritoneal mesothelial cells seem to occur in the peritoneal cavity because of the different temperature, moisture, and pressure exposures.

Barbul et al. and Fishel et al. investigated lymphocyte participation in wound healing in a rat model, and showed that helper T lymphocytes and cytotoxic T lymphocytes remained in the superficial and deep layers of the wound until POD 10, while the CD4/8 ratio in the wound was 2:1.^{27,28} Thus, changes in peritoneal lymphocyte populations after surgery may be associated not only with direct damage to peritoneal immune cells by operative procedures, but also with wound healing after surgery.

Surgical stress causes suppression of systemic NKCC,¹⁶ and NK cells play an important role in fighting bacterial and viral infections, and in surveillance against tumor cell growth and dissemination.^{29,30} Using a rat model, Sandoval et al. showed that CO₂ pneumoperitoneum does not lead to the systemic suppression of NK cell activity.¹⁷ Allendorf et al. showed that inoculated tumors in the backs of mice grew more remarkably after laparotomy than after pneumoperitoneum because of the suppression of NKCC in the circulating NK cells.³¹ In a study on cholecystectomy patients, Walker et al. showed that a open procedure resulted in a significant reduction of circulating NK cell subsets in comparison with laparoscopic procedure.³² Our results for splenic NKCC after the operative procedures were similar to theirs, although NKCC of peritoneal immune cells was very low both before and after surgery, and there was no difference in the NKCC of PECs between CO₂ pneumoperitoneum and laparotomy. It remains unclear whether the NKCC of peritoneal immune cells affects the progression of tumor cells disseminated intraperitoneally, and the importance of peritoneal NKCC after surgery for gastrointestinal cancer needs to be clarified.

In conclusion, the populations of T lymphocytes and NK cells in PECs were less impaired after CO₂ pneumoperitoneum than after laparotomy. Systemic NKCC was less suppressed after pneumoperitoneum than after laparotomy, but peritoneal NKCC after pneumoperitoneum was the same as that after laparotomy. Our data suggest that laparoscopic surgery is preferable to open surgery for abdominal malignancies because the cell-mediated immune response, including the peritoneal CD4/8 ratio and systemic NKCC, is less impaired as a result. However, the association between peritoneal metabolism and peritoneal immune response after surgery, and the interaction between systemic and peritoneal immune responses after surgery, need to be clarified.

References

1. Kitano S, Shiraishi N, Fujii K, Yasuda K, Inomata M, Adachi Y. A randomized controlled trial comparing open vs laparoscopy-assisted distal gastrectomy for the treatment of early gastric cancer: an interim report. *Surgery* 2002;131(suppl):s306-11.
2. Lacy AM, García-Valdecasas JC, Delgado S, Castells A, Taurá P, Piqué JM, et al. Laparoscopy-assisted colectomy versus open colectomy for treatment of nonmetastatic colon cancer: a randomized trial. *Lancet* 2002;359:2224-9.
3. McMahon AJ, Russell IT, Baxter J, Ross S, Anderson JR, Morran CG, et al. Laparoscopy versus minilaparotomy cholecystectomy: a randomised trial. *Lancet* 1993;343:135-8.
4. Dorrance HR, Oien K, O'Dwyer PJ. Effects of laparoscopy on intraperitoneal tumor growth and distant metastases in an animal model. *Surgery* 1999;126:35-40.
5. Schaeff B, Paolucci V, Thomopoulos J. Port site recurrences after laparoscopic surgery. *Dig Surg* 1998;15:124-34.
6. Wexner SD, Cohen SM. Port site metastases after laparoscopic colorectal surgery for cure of malignancy. *Br J Surg* 1995;82:295-8.
7. Allendorf JDF, Bessler M, Whelan RL, Trokel M, Laird DA, Terry MB, et al. Postoperative immune function varies inversely with the degree of surgical trauma in a murine model. *Surg Endosc* 1997;11:427-30.
8. Da Costa ML, Redmond HP, Bouchier-Hayes DJ. The effect of laparotomy and laparoscopy on the establishment of spontaneous tumor metastasis. *Surgery* 1998;124:516-25.
9. Trokel MJ, Bessler M, Treat MR, Whelan RL, Nowygrod R. Preservation of immune response after laparoscopy. *Surg Endosc* 1994;8:1385-8.
10. Evrard S, Falkenrodt A, Park A, Tasseti V, Mutter D, Marescaux J. Influence of CO₂ pneumoperitoneum on systemic and peritoneal cell-mediated immunity. *World J Surg* 1997;21:353-7.
11. Gutt CN, Hollander D, Brier CH, Kim ZG, Lorenz M. Influence of laparoscopy and laparotomy on systemic and peritoneal T lymphocytes in a rat model. *Int J Colorectal Dis* 2001;16:216-20.
12. Suematsu T, Hirabayashi Y, Shiraishi N, Adachi Y, Kitamura H, Kitano S. Morphology of the murine peritoneum after pneumoperitoneum vs laparotomy. *Surg Endosc* 2001;15:954-8.
13. Yamaguchi K, Hirabayashi Y, Suematsu T, Shiraishi N, Adachi Y, Kitano S. Hyaluronic acid secretion during carbon dioxide pneumoperitoneum and its association with port-site metastasis in a murine model. *Surg Endosc* 2001;15:59-62.
14. Suematsu T, Shiromizu A, Yamaguchi K, Shiraishi N, Adachi Y, Kitano S. Convenient murine pneumoperitoneal model for the study of laparoscopic cancer surgery. *Surg Laparosc Endosc* 1999;9:279-81.
15. Ishikawa K, Shimoda K, Shiraishi N, Adachi Y, Kitano S. Induction natural killer suppressive factor in murine peritoneal cavity by intraperitoneal bolus administration of high-dose cisplatin. *Int J Clin Oncol* 2000;5:48-53.
16. Pollock RE, Babcock GF, Romsdahl MM, Nishioka K. Surgical stress-mediated suppression of murine natural killer cell cytotoxicity. *Cancer Res* 1984;44:3388-91.
17. Sandoval BA, Robinson AV, Sulaiman TT, Shenk RR, Stellato TA. Open versus laparoscopic surgery: a comparison of natural antitumoral cellular immunity in a small animal model. *Am Surg* 1996;62:625-31.
18. Gitzelmann CA, Mendoza-Sagaon M, Talamini MA, Ahmad SA, Pegoli W Jr, Páidas CN. Cell-mediated immune response is better preserved by laparoscopy than laparotomy. *Surgery* 2000;127:65-71.
19. Gleason NR, Blanco I, Allendorf JDF, Lee SW, Zhai C, Bessler M, et al. Delayed-type hypersensitivity response is better preserved in mice following insufflation than after laparotomy. *Surg Endosc* 1999;13:1032-4.
20. Vallina VL, Velasco JM. The influence of laparoscopy on lymphocyte subpopulations in the surgical patient. *Surg Endosc* 1995;10:481-4.
21. Brune IB, Wilke W, Hensler T, Feussner H, Holzmann B, Siewert JR. Normal T lymphocyte and monocyte function after minimally invasive surgery. *Surg Endosc* 1998;12:1020-4.
22. Brune IB, Wilke W, Hensler T, Holzmann B, Siewert JR. Downregulation of T helper type 1 immune response and altered pro-inflammatory and anti-inflammatory T cell cytokine balance following conventional but not laparoscopic surgery. *Am J Surg* 1999;177:55-60.
23. Goodman RB, Wood RG, Martin TR, Hanson-Painton O, Kinasevitz GT. Cytokine-stimulated human mesothelial cells produce chemotactic activity for neutrophils including NAP-1/IL-8. *J Immunol* 1992;148:457-65.
24. Lanfrancone L, Boraschi D, Ghiara P, Falini F, Peri G, Mantovani A, et al. Human peritoneal mesothelial cells produce many cytokines (granulocyte colony-stimulating factor [CSF], granulocyte-macrophage-CSF, macrophage-CSF, interleukin-1 [IL-1], and IL-6) and are activated and stimulated to grow by IL-1. *Blood* 1992;80:2835-42.
25. Betjes MGH, Tuk CW, Struijk DG, Krediet RT, Arisz L, Hart M, et al. Interleukin-8 production by human peritoneal mesothelial cells in response to tumor necrosis factor-alpha, interleukin-1, and medium conditioned by macrophages cocultured with *Staphylococcus epidermidis*. *J Infect Dis* 1993;168:1202-10.
26. Tahara K, Fujii K, Yamaguchi K, Suematsu T, Shiraishi N, Kitano S. Increased expression of P-cadherin mRNA in the mouse peritoneum after carbon dioxide insufflation. *Surg Endosc* 2001;15:946-9.
27. Barbul A, Breslin RJ, Woodyard JP, Wasserkrug HL, Efron G. The effect of in vivo T helper and T suppressor lymphocyte depletion on wound healing. *Ann Surg* 1989;209:479-83.
28. Fishel RS, Barbul A, Beschoner WE, Wasserkrug HL, Efron G. Lymphocyte participation in wound healing. *Ann Surg* 1987;206:25-9.
29. Hanna N. Expression of metastatic potential of tumor cells in young nude mice is correlated with low levels of natural killer cell-mediated cytotoxicity. *Int J Cancer* 1980;26:675-80.
30. Hanna N. Inhibition of experimental tumor metastasis by selective activation of natural killer cells. *Cancer Res* 1982;42:1337-42.
31. Allendorf JDF, Bessler M, Horvath KD, Marvin MR, Laird DA, Whelan RL. Increased tumor establishment and growth after open vs laparoscopic surgery in mice may be related to differences in postoperative T-cell function. *Surg Endosc* 1999;13:233-5.
32. Walker CBJ, Bruce DM, Heys SD, Gough DB, Binnie NR, Eremin O. Minimal modulation of lymphocyte and natural killer cell subsets following minimal access surgery. *Am J Surg* 1999;177:48-54.



and Other Interventional Techniques

Current status of laparoscopic gastrectomy for cancer in Japan

S. Kitano, N. Shiraishi

Department of Surgery I, Oita University Faculty of Medicine, 1-1 Idaigaoka, Hasama-machi Oita 879-5593, Japan

Received: 7 March 2003/Accepted: 21 July 2003/Online publication: 29 December 2003

Abstract. Because of the increased incidence of early gastric cancer in Japan, minimally invasive laparoscopic approaches to gastric malignancies have been under development since 1991. Laparoscopic local resection of the stomach, i.e., laparoscopic wedge resection (LWR) and intragastric mucosal resection (IGMR), is used to treat mucosal cancer without lymph node metastasis. Laparoscopy-assisted distal gastrectomy (LADG) is used to treat early gastric cancer with risk factors for regional lymph node metastasis. A survey conducted by the Japan Society for Endoscopic Surgery showed that 1428 LWRs, 260 IGMRs, and 2600 LADGs were performed between 1991 and 2001 in departments of endoscopic surgery in Japan. Laparoscopic gastrectomy for gastric cancer is still under development in Japan. According to short-term results reported by a small group of surgeons, laparoscopic approaches to gastric cancer provide for minimal invasion, early recovery, and decreased morbidity and mortality. If the advantages can be confirmed in one or more multicenter randomized control studies of the long-term outcome of patients undergoing laparoscopic gastrectomy for gastric cancer, the procedure should come into wide acceptance and use.

Key words: Early gastric cancer — Laparoscopic wedge resection — Intragastric mucosal resection — Laparoscopy-assisted distal gastrectomy

The incidence of gastric cancer is high in Japan, and cases are managed routinely by surgery with systemic lymph node dissection. Detection of early gastric cancer has increased because of the development of diagnostic techniques such as endoscopy, biopsy, and endoscopic ultrasonography [17]. Because of the high incidence of early gastric cancer, minimal invasiveness is a consideration, and several new surgical procedures with minimal invasiveness have been developed. These include endoscopic mucosal resection (EMR) [20], laparoscopic surgery [7], and pylorus-preserving gastrectomy [22].

Correspondence to: S. Kitano

After the first laparoscopy-assisted distal gastrectomy (LADG) for early gastric cancer was performed in 1991 [7], laparoscopic gastrectomy began to be used by many surgeons around the world [5, 11]. In Japan, new laparoscopic procedures, such as laparoscopic wedge resection (LWR) and intragastric mucosal resection (IGMR), have been developed for the management of patients with early gastric cancer [14, 15]. Because of the improved outcome achieved with laparoscopic procedures for early gastric cancer, indications for laparoscopic procedures have been expanded from early to advanced gastric cancer.

Herein, we review the current indications for, techniques pertaining to, and outcomes of laparoscopic procedures for gastric cancer, including LWR, IGMR, and LADG in Japan.

I. Laparoscopic local resection of the stomach

Laparoscopic local resection of the stomach has been performed in Japan since 1994 for minimally invasive management of early gastric cancer. One technique is LWR, developed by Ohgami et al. [15], and the other is IGMR developed by Ohashi [14].

Indications

Pathologic examination of early gastric cancers reveals the presence of nodal metastasis in 2–3% of mucosal carcinomas and 15–20% of submucosal carcinomas [18, 26]. Lymphatic vessel invasion, histological tumor ulceration, and tumor diameter (> 30 mm) are independent factors predicting regional lymph node metastasis [24]. The data suggest that most early carcinomas are located only in the gastric wall and that local resection of the gastric wall is adequate for clearance. Theoretically, laparoscopic local resection can be applied to treat early gastric cancer that shows no risk factors for lymph node metastasis (Table 1). Ohgami et al. reported the following indications for LWR: (1) preoperative diagnosis of mucosal cancer, (2) diameter < 25 mm for

Table 1. Laparoscopic surgery for gastric cancer in Japan

	Laparoscopic local resection		Laparoscopic gastrectomy (LADG)
	IGMR	LWR	
Number of cases in Japan ^a (1991–2001)	260	1428	2600
Indication (in our department)	Early gastric cancer without risk of LN metastasis (1) Mucosal cancer: difficult to resect by EMR elevated type (< 25 mm) depressed type (< 15 mm) without ulceration (2) Location posterior (IGMR), except posterior (LWR)		Early gastric cancer with risk of LN metastasis (1) Mucosal cancer: elevated type (> 25 mm) depressed type (> 15 mm) with ulceration (2) Submucosal cancer with slight invasion
Complication rate in Japan ^a			
Intraoperative (%)	4.2	2.1	1.4
Postoperative (%)	6.5	4.6	9.7

^a From [8]

protruding type lesions, (3) diameter < 15 mm and UL (–) for depressed type lesions [15]. The procedure can be applied to a lesion located in any part of the stomach except the posterior wall. The indications for IGMR are nearly the same as those for LWR, but IGMR can be applied to a lesion located in any part of the stomach except the anterior wall. The accepted indications for IGMR are as follows: (1) mucosal carcinoma difficult to resect completely by EMR, (2) mucosal carcinoma of the elevated type (< 25 mm) or depressed type (< 15 mm), and (3) mucosal carcinoma located in any part of the stomach except the anterior wall [14].

Techniques

LWR. LWR is performed by the lesion-lifting method [15]. The cancerous lesion and the gastric wall around it are exposed endoscopically and laparoscopically. The abdominal wall and gastric wall near the lesion are pierced with a 12-G sheathed needle. A small metal rod with a fine wire is inserted into the stomach through the outer sheath, and the sheath is removed. The lesion is lifted by retracting the metal rod and resected with a wedge-shaped part of the stomach with the use of an endoscopic stapler. After the resected specimen is removed, the abdomen is closed.

The lesion must be removed with an adequately clear margin. To resect the lesion successfully, Altorjay et al. developed the modified lesion-lifting method called the double-lifting method [4].

IGMR. IGMR is performed as follows. Three trocars are placed in the gastric lumen, penetrating both the abdomen and stomach walls, under gastrofiberscopic and laparoscopic observation. These trocars fix the gastric wall to the abdominal wall with a balloon. After the laparoscope and two forceps are inserted into the stomach through the trocars, dots are placed to indicate the removal margin around the lesion, and mucosal resection is performed. Hemostasis is achieved by elec-

trocautery and laser. The resected specimen is extracted by gastrofiberscope. Each balloon is then deflated, and the trocars are pulled out. Each port in the stomach is sutured laparoscopically, and the abdomen is closed.

For IGMR, it is important to access the gastric lumen easily and get an optimal operative field. There are several new devices, such as the expandable sleeve [21], which can be used instead of forceps with a balloon, to provide the necessary easy access. Yamashita et al. used a Buess-type endoscope to resect the lesion with the full-thickness wall from the gastric lumen [25].

Evaluation and current status of laparoscopic local resection in Japan

After laparoscopic local resection was made possible, its use increased in the early 1990s. A survey of the Japan Society for Endoscopic Surgery, in which 1462 out of 2706 departments of endoscopic surgery responded (the response rate: 54%), revealed 1428 LWRs and 260 IGMRs were carried out between 1992 and 2001 in Japan [8] (Table 1). These data suggest that 20–30% of patients with early gastric cancer are treated by laparoscopic local resection in these departments.

There has been no study into the clinical advantages of laparoscopic local resection versus open local resection. A survey of the Japan Society for Endoscopic Surgery showed the incidence of intraoperative and postoperative complications for the last 10 years to be 2.1% and 4.6% after LWR, and 4.2% and 6.5% after IGMR, respectively [8]. The major intraoperative complications after LWR and IGMR are bleeding and gastric emptying, respectively. These do not seem to be a higher incidence of intraoperative or postoperative complications after laparoscopic procedures compared to the incidence with open procedures. Mortality rates following LWR and IGMR were both 0%.

According to the results of the survey, patients could ingest liquid on the second day, and solid food was started on the second or third postoperative day after LWR and IGMR. In our department, the time to PO

intake was two days after LWR or IGMR, and the average period of postoperative hospital stay was ~10 days. These data suggest early recovery after laparoscopic local resection.

There are few reports of survival and cancer recurrence after LWR and IGMR. Ohgami et al. reported two recurrences out of 111 cases treated by laparoscopic local resection [15]. In both cases, recurrence was diagnosed within 2 years after initial surgery, and the lesions were successfully treated by open gastrectomy and laser irradiation. So far, all patients in Ohgami's series have survived the 4- to 65-month follow-up period. Hiki reported that all 29 patients in his series have been recurrence-free for a follow-up period of 46 months.

We believe that both LWR and IGMR are curative and minimally invasive treatments applicable to early gastric cancer without lymph node metastasis, when the indication of these procedures is limited.

II. Laparoscopy-assisted distal gastrectomy (LADG)

Laparoscopy-assisted Billroth-I gastrectomy for early gastric cancer was first performed by Kitano et al. in 1991 [7], and the first totally laparoscopic Billroth-II gastrectomy was reported by Goh and Kum in 1992 [5]. Laparoscopic gastrectomy is still in the developmental phase around the world, whereas the use of LADG for early gastric cancer has increased significantly in Japan.

Indications

LADG was developed to treat early gastric cancer in which there is some risk of lymph node metastasis at the perigastric portion (n1) (Table 1). The guidelines for gastric cancer treatment of the Japanese Gastric Cancer Association give the indications for LADG as follows: (1) mucosal cancer without preoperatively diagnosed lymph node metastasis, (2) cancer with submucosal invasion and without preoperatively diagnosed lymph node metastasis [13]. It is sometimes difficult to diagnose lymph node metastasis preoperatively, and the rate of accuracy is very low. Therefore, in our department, the indication for LADG is determined by tumor size, depth of cancer, the presence of ulceration, and histologic type [19, 26]. Our present indications for LADG are as follows: (1) mucosal cancer of the elevated (> 25 mm) or depressed type (> 15 mm), (2) mucosal cancer with peptic ulcer, (3) remnant cancer after endoscopic mucosal resection, and (4) carcinoma with minimal submucosal invasion. These criteria account for 60% of patients with early-stage gastric carcinoma in our study series.

Technique

After the Hasson type cannula is placed at the subumbilical portion, four other ports are placed in the upper abdomen under laparoscopic observation. The greater omentum and gastrocolic ligament are dissected laparoscopically outside the epigastric arcade. The right

gastroepiploic vessels are cut at the pancreatic surface to facilitate dissection of lymph nodes at the subpyloric portion. The lesser curvature is dissected, and the left gastric vessels are divided after double ligation with clips. The left cardiac and superior gastric lymph nodes are dissected down to the distal portion of the stomach. The suprapyloric lymph nodes are also dissected after ligation of the right gastric artery. After complete laparoscopic mobilization of the lower two-thirds of the stomach, a 5-cm midline skin incision is placed just below the xiphoid. After transection of the duodenum through a small laparotomy, the distal two-thirds of the stomach containing the cancer is resected with an autostapler. The regional lymph nodes are completely dissected along with the distal portion of the stomach. Gastroduodenostomy is performed in the same way it is done in open surgery, via small laparotomy.

Evaluation and current status of laparoscopic gastrectomy in Japan

The survey of the Japan Society for Endoscopic Surgery showed that 2600 LADGs were performed from 1991 to 2001 in departments of endoscopic surgery in Japan [8] (Table 1). Since 1996, the use of LADG has rapidly increased, and 959 gastric cancers were treated by LADG in 2001. Because ~20,000 patients with early gastric cancer are estimated to be performed in Japan a year, LADG may amount to only 5% in gastrectomy for early cancer. Thus, LADG is still performed in only a limited number of hospitals in Japan, but the number has increased year by year. In a few hospitals, because of the improved outcome for patients receiving LADG, indications for LADG have expanded to include lymph node dissection (D2) [23].

The survey of the Japan Society for Endoscopic Surgery showed the mortality of LADG for the past 10 years to be 0% and also showed the LADG-associated incidence of intraoperative and postoperative complications to be 1.4% and 9.7%, respectively [8]. The major intraoperative complication is bleeding, and the major postoperative complications are gastric emptying, anastomotic leakage and wound infection. Maruyama et al. reported that the mortality and morbidity of open distal gastrectomy (ODG) with D1 lymph node dissection were 0.5% and 20.6% [12]. These data suggest that LADG is as safe as conventional ODG.

There are several reports of clinical advantages of LADG compared with ODG. Goh et al. reported that 10 of 16 surgeons in responses to questionnaires in a worldwide survey recognized the superiority of laparoscopic gastrectomy to open gastrectomy because of faster recovery, less pain, and better cosmesis [6]. We showed by retrospective study that there were several advantages to LADG in comparison to ODG, including less surgical trauma assessed by acute inflammatory index, better nutrition, less pain, rapid return of gastrointestinal function, and shorter hospital stay, with no decrease in operative curability [1]. We have shown in a small randomized study that there are some advantages including less pain and less impaired pulmonary func-

tion after LADG in comparison to ODG [9]. LADG is a better option than ODG with regard to patient's quality of life (QOL) [2]. Regarding the cost, our previous study showed that LADG is less expensive than conventional open gastrectomy (total hospital charges, ¥ 1336 × 10³ vs ¥ 1411 × 10³) because both the postoperative recovery period and the hospital stay are shorter (16.1 vs 20.5 days) [3]. But Rosin et al. pointed out problems with LADG, including complexity of the procedure and long operation time [16]. A multicenter randomized controlled trial is needed to confirm the clinical advantages of LADG.

In our series, 116 LADGs with regional lymph node dissection (D1) were performed over 10 years [10]. All patients, except one who died of cerebral bleeding, were alive without recurrence or port-site metastasis at the mean follow-up period of 45 months. Although there are no other data on survival and recurrence after LADG, we believe that LADG is a curative procedure. The lower complication rate and lower recurrence rate of LADG might be caused by not only the strict indications for LADG but also the improvement in technique on the instruments, such as laparoscope and laparoscopic coagulation shears, or surgical skill. Now, a few institutes in Japan have tried to treat advanced gastric cancer laparoscopically.

Conclusions

Laparoscopic gastrectomy for gastric cancer is still in the developmental phase in Japan. Since 1991, three laparoscopic procedures, LWR, IGMR, and LADG, have been used in Japan, and they have been widely accepted for the past 10 years. The indication for LWR and IGMR is mucosal cancer without risk of lymph node metastasis, and that for LADG is early gastric cancer with a risk of perigastric lymph node metastasis (n1). We believe that laparoscopic procedures are useful for the treatment of patients with early gastric cancer because of the minimal invasiveness, decrease in pain, and early recovery. If the advantages can be confirmed in one or more multicenter randomized control studies of the long-term outcome of patients undergoing laparoscopic gastrectomy for gastric cancer, the procedure will come into wide acceptance and use.

References

- Adachi Y, Shiraishi N, Shiromizu A, et al. (2000) Laparoscopy-assisted Billroth-I gastrectomy compared with conventional open gastrectomy. *Arch Surg* 135: 806-810
- Adachi Y, Suematsu T, Shiraishi N, et al. (1999) Quality of life after laparoscopy-assisted Billroth-I gastrectomy. *Ann Surg* 229: 49-54
- Adachi Y, Shiraishi N, Ikebe K, Aramaki M, Bandoh T, Kitano S Evaluation of the cost for laparoscopy-assisted Billroth I gastrectomy. *Surg Endosc* 15: 932-936
- Altörjay A, Szanto I, Garcia J, et al. (1996) Endoscope-assisted laparoscopic resection of the gastric wall (Hungarian). *Orv Hetil* 137: 2743-2745
- Goh P, Kum CK (1993) Laparoscopic Billroth II gastrectomy: a review. *Surg Oncol* 2: s13-18
- Goh PM, Alponat A, Mak K, et al. (1997) Early international results of laparoscopic gastrectomies. *Surg Endosc* 11: 650-652
- Kitano S, Iso Y, Moriyama M, et al. (1994) Laparoscopy-assisted Billroth I gastrectomy. *Surg Laparosc Endosc* 4: 146-148
- Kitano S, Bandoh T, Kawano K (2001) Endoscopic surgery in Japan. *Min Invas Ther & Allied Technol* 10: 215-9
- Kitano S, Shiraishi N, Fujii K, et al. (2002) A randomized controlled trial comparing an open versus a laparoscopy-assisted distal gastrectomy for the treatment of early gastric cancer: an interim report. *Surgery* 131: S306-311
- Kitano S, Shiraishi N, Kakisako K, et al. (2002) Laparoscopy-assisted Billroth I gastrectomy (LADG) for cancer: our 10 years' experience. *Surg Laparosc Endosc Percutan Tech* 12: 204-207
- Llorente J (1994) Laparoscopic gastric resection for gastric leiomyoma. *Surg Endosc* 8: 887-889
- Maruyama K, Sasako M, Kinoshita T, et al. (1998) Should systemic lymph node dissection be recommended for gastric cancer? *Eur J Cancer* 34: 1480-1483
- Nakajima T (2002) Gastric cancer treatment guidelines in Japan. *Gastric Cancer* 5: 1-5
- Ohashi S (1995) Laparoscopic intraluminal (intra-gastric) surgery for early gastric cancer. *Surg Endosc* 9: 169-171
- Ohgami M, Otani Y, Kumai K, et al. (1999) Curative laparoscopic surgery for early gastric cancer: five years experience. *World J Surg* 23: 187-192
- Rosin D, Brasesco O, Rosenthal RJ (2001) Laparoscopy for gastric tumors. *Surg Oncol Clin N Am* 10: 511-529
- Sano T, Okuyama Y, Kobori O, et al. (1990) Early gastric cancer: endoscopic diagnosis of depth of invasion. *Dig Dis Sci* 35: 1340-1344
- Sano T, Kobori O, Muto T (1992) Lymph node metastasis from early gastric cancer: endoscopic resection of tumor. *Br J Surg* 79: 241-244
- Shiraishi N, Adachi Y, Kitano S, et al. (1999) Indication for and outcome of laparoscopy-assisted Billroth-I gastrectomy. *Br J Surg* 86: 541-544
- Tada M, Shimada M, Murakami F (1984) Development of the strip-off biopsy. *Gastroenterol Endosc* 26: 833-839
- Taniguchi E, Ohashi S, Takiguchi S, et al. (2000) Laparoscopic intra-gastric surgery using a radically expandable sleeve. *Surg Endosc* 14: 505-507
- Uyama I, Sugioka A, Fujita J, et al. (1999) Purely laparoscopic pylorus-preserving gastrectomy with extraperigastric lymphadenectomy for early gastric cancer: a case and technical report. *Surg Laparosc Endosc Percutan Tech* 9: 418-422
- Uyama I, Sugioka A, Fujita J, et al. (1999) Completely laparoscopic extraperigastric lymph node dissection for gastric malignancies located in the middle or lower third of the stomach. *Gastric Cancer* 2: 186-190
- Yamao T, Shirao K, Ono H, et al. (1996) Risk factors for lymph node metastasis from intramucosal gastric carcinoma. *Cancer* 77: 602-606
- Yamashita Y, Maekawa T, Sakai T, et al. (1999) Transgastrostomal endoscopic surgery for early gastric carcinoma and submucosal tumor. *Surg Endosc* 13: 361-364
- Yasuda K, Shiraishi N, Suematsu T, et al. (1999) Rate of detection of lymph node metastasis is correlated with the depth of submucosal invasion in early stage gastric carcinoma. *Cancer* 85: 2119-2123



Increased peritoneal dissemination after laparotomy vs pneumoperitoneum in a mouse cecal cancer model

H. Takeuchi, M. Inomata, K. Fujii, S. Ishibashi, N. Shiraishi, S. Kitano

Department of Surgery I, Faculty of Medicine, Oita University, 1-1 Idaigaoka, Hasama-machi, Oita 879-5593, Japan

Received: 10 December 2003/Accepted: 17 June 2004/Online publication: 26 October 2004

Abstract

Background: The effect of carbon dioxide (CO₂) pneumoperitoneum on the liberation of cancer cells from the primary tumor is not clear. This study investigated the influence of laparotomy versus CO₂ pneumoperitoneum on the progression of colon cancer with serosal invasion in a mouse model.

Methods: Pieces of human colon adenocarcinoma (HT29) tumor were implanted in the cecal wall of 45 BALB/c nude mice. Each mouse underwent one of three procedures: laparotomy, CO₂ pneumoperitoneum, or anesthesia (control). Three weeks later, the size and weight of cecal tumors, the number of nodules, and the tumor volume score of peritoneal dissemination were examined. Another 45 mice were treated in the same way. The cecal tumor was resected on days 1, 3, or 5 after treatment. Total RNA was isolated from the resected tumors. The expression of E-cadherin and beta-1 integrin messenger RNA (mRNA) was examined by semiquantitative real-time reverse transcriptase-polymerase chain reaction assay.

Results: Significantly more nodules of peritoneal dissemination were found in the laparotomy group than in the control group ($p < 0.05$). The tumor volume score of peritoneal dissemination in the laparotomy group was significantly higher than in the other two groups ($p < 0.05$). The expression of E-cadherin mRNA at day 5 in the laparotomy group was significantly less than in the other two groups ($p < 0.05$). There were no differences in beta-1 integrin among three groups.

Conclusions: Peritoneal dissemination was more extensive after laparotomy than after CO₂ pneumoperitoneum in a mouse model of cecal cancer with serosal invasion. Decreased expression of E-cadherin mRNA in tumors after laparotomy, but not after CO₂ pneumoperitoneum, may be associated with the increase in peritoneal dissemination.

Key words: Pneumoperitoneum — Peritoneal dissemination — Murine model — Real-time RT-PCR
E-cadherin

Laparoscopic surgery has been applied to many patients with colorectal cancer [1, 12, 14, 22]. It is considered less invasive and less immunosuppressive than conventional open surgery [12, 14]. Recently, the indications for laparoscopic resection have been expanded to include not only the early stage, but also the advanced stage of malignancy. However, the influence of the laparoscopic procedure on the prognosis of patients with malignancy is unclear.

Peritoneal dissemination is an important prognostic factor in colorectal cancer. Surgery is indicated for advanced colorectal cancer with serosal invasion before peritoneal dissemination occurs. Therefore, several animal studies have investigated the effects of carbon dioxide (CO₂) pneumoperitoneum induced for laparoscopic surgery on port-site seeding and peritoneal dissemination [3, 9, 16]. Instrument manipulation and mechanical tumor spillage seem to play the major role in cancer seeding and dissemination in laparoscopic surgery [3, 17]. On the other hand, morphologic study using electron microscopy showed the typical changes of mesothelial cells after CO₂ pneumoperitoneum and laparotomy [18, 21], suggesting the direct influence of mesothelial cells on the adhesion molecules by these surgical procedures. It therefore is also critical to clarify the effect of CO₂ pneumoperitoneum and laparotomy on the liberation of cancer cells from primary tumor with serosal invasion but without peritoneal dissemination.

In the current study, we investigated and compared the influence of CO₂ pneumoperitoneum and that of laparotomy on the progression of colorectal cancer with serosal invasion in a nude mouse model from the viewpoint of adhesion molecules expression.

Correspondence to: H. Takeuchi

Table 1. Tumor volume score

Points	Nodule diameter
0	< 1 mm
1	≥1 to < 2 mm
2	≥2 to < 3 mm
3	≥3 to < 4 mm

Materials and methods

Male 7-week-old BALB/c nude mice were kept under standard laboratory conditions with free access to food and water before and after surgery. All procedures were performed according to the Guidelines for Animal Experimentation of Oita University. An HT29 human colon adenocarcinoma cell line was grown in RPMI 1640 medium (Gibco BRL; Life Technologies, Rockville, MD, USA) supplemented with 10% fetal bovine serum (Gibco BRL) and an antibiotic-antimycotic agent containing 100 IU/ml penicillin, 0.1 mg/ml streptomycin, and 2.5×10^4 mg amphotericin B (Gibco BRL). The cells were cultured in dishes in a 5% CO₂ atmosphere at 37°C.

Cecal cancer model

This study was performed with a modified cecal cancer model [6]. The mice were anesthetized with diethyl ether and inoculated with 0.1 ml of the tumor suspension (1×10^6 cells). Three weeks later, a subcutaneous tumor was resected aseptically from each mouse. Necrotic tissue in the resected tumor was cut away, and the remaining healthy tumor tissue was scissor-minced into 50-mg pieces in Hank's balanced salt solution. A second group of mice was anesthetized the same way, and tumor pieces were fixed on the serosal surface of the murine cecal wall.

Experiment 1

Tumor pieces were implanted in the cecal wall of 45 mice. Three weeks later, the mice were randomly divided into a laparotomy group ($n = 15$), a CO₂ pneumoperitoneum group ($n = 15$), and an anesthesia (control) group ($n = 15$). For the CO₂ pneumoperitoneum group, we used a convenient murine pneumoperitoneum model that we have described previously [19]. With the mice under anesthesia with diethyl ether, CO₂ pneumoperitoneum was created and maintained for 30 min with CO₂ insufflations at 5 mmHg.

Three weeks later, all the mice were killed using anesthesia overload. Cecal tumors were resected, and tumor size and weight were measured. Peritoneal dissemination was assessed by the number of nodules larger than 1 mm in diameter and by the tumor volume score (Table 1).

Experiment 2

Tumor pieces were implanted in the cecal wall of another 45 mice. Three weeks later, the mice were randomly divided into three groups the same as in the first experiment. The mice were treated as previously described and killed per each three groups on days 1 ($n = 5$), 3 ($n = 5$), or 5 ($n = 5$) after surgery. A tissue sample from the cecal tumor of each mouse was frozen immediately in liquid nitrogen and stored at -80°C until extraction of total RNA. Total RNA was isolated from the cecal tumors by the acid guanidinium thiocyanate-phenol-chloroform extraction procedure [4], complementary DNA (cDNA) was synthesized by reverse transcription from 2.5 µg of total RNA. A real-time polymerase chain reaction (PCR) assay was performed with a LightCycler (Roche Diagnostics, Mannheim, Germany) in a total volume of 20 µl, to which was added 2 µl of 10X reaction buffer (Taq polymerase, diethylnitrophenyl thiophosphates, magne-

Table 2. Primer sequences for the reverse transcriptase-polymerase chain reaction

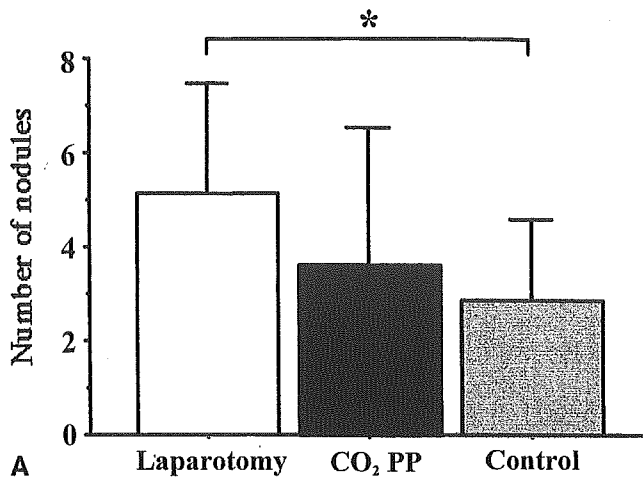
Molecule	Sequence (5'-3')
E-cadherin	Sense TCC CAT CAG CTG CCC AGA AA
	Antisense TGA CTC CTG TGT TCC TGT TA
Beta-1 integrin	Sense GTT ACA CGG CTG CTG GTG TT
	Antisense CTA CTG CTG ACT TAG GGA TC
GAPDH	Sense GGC AGA GAT GAT GAC CCT TTT GGC
	Antisense AAG GTG AAG GTC GGA GTC AAC G

GAPDH, glyceraldehyde phosphate dehydrogenase

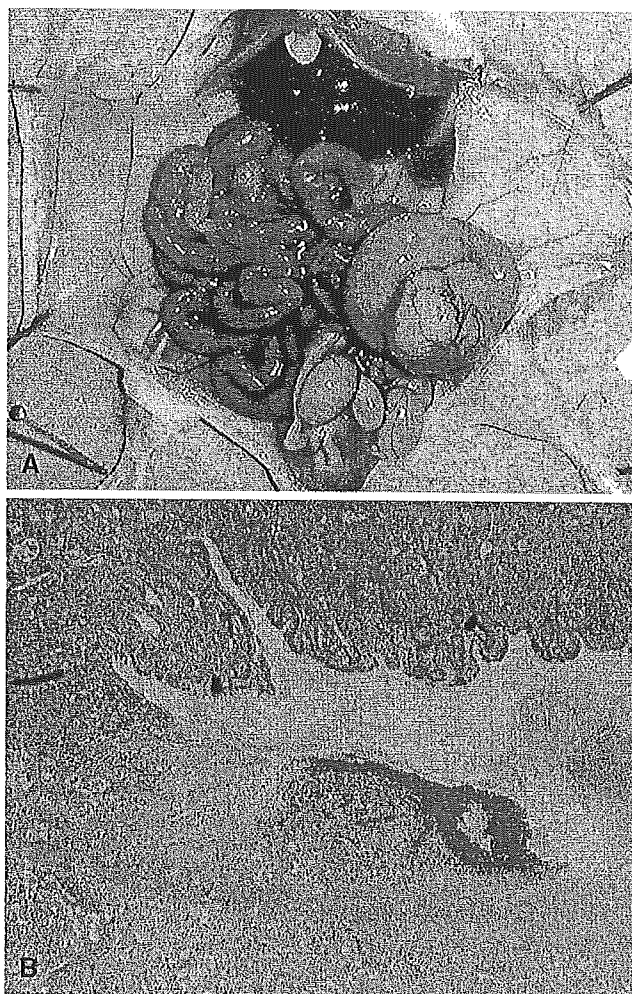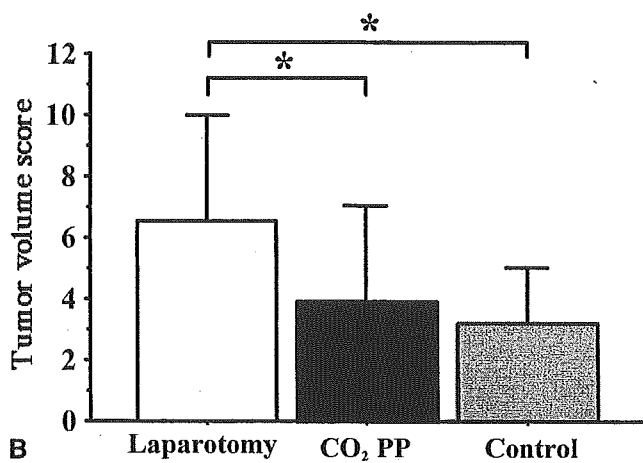


Fig. 1. **A** Photograph of an implanted cecal tumor. **B** Hematoxylin and eosin staining of an implanted cecal tumor. The implanted cecal tumor invaded to the mucosa from the serosa in 3 weeks.

sium chloride, SYBR Green; Roche Diagnostics), and 2 µl of cDNA. Magnesium chloride and each oligonucleotide primer (Table 2) were added to a final concentration of 4 mmol/l and 0.5 µmol/l, respectively. Real-time PCR was performed with an initial denaturation step of 10 min at 95°C, followed by 40 cycles of 15 s at 95°C, 10 s at annealing temperature (glyceraldehyde phosphate dehydrogenase 58°C; E-cadherin, 60°C; beta-1 integrin, 60°C), and product length (bp)/25 s at 72°C. At the end of each cycle, the fluorescence emitted by the SYBR Green was measured. The relative fluorescence of each messenger RNA (mRNA) was normalized to the fluorescence of GAPDH for semiquantification.



A



B

Fig. 2. a The number of nodules of peritoneal dissemination. b Tumor volume score of peritoneal dissemination. PP, pneumoperitoneum (* $p < 0.05$).

Table 3. Volume and weight of the cecal tumor

	Laparotomy	CO ₂ PP	Control	<i>p</i> value
Volume (mm ³)	890 ± 416	744 ± 341	752 ± 265	NS
Weight (mg)	985 ± 435	923 ± 435	903 ± 229	NS

CO₂ PP, carbon dioxide pneumoperitoneum; NS, not significant

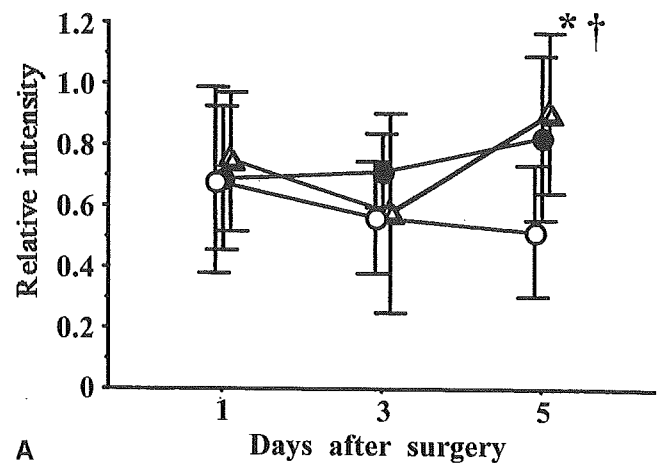
Statistical analysis

All data are expressed as the mean ± standard deviation. Statistical analysis was performed using the Mann-Whitney *U* test, and a *p* value less than 0.05 was considered statistically significant.

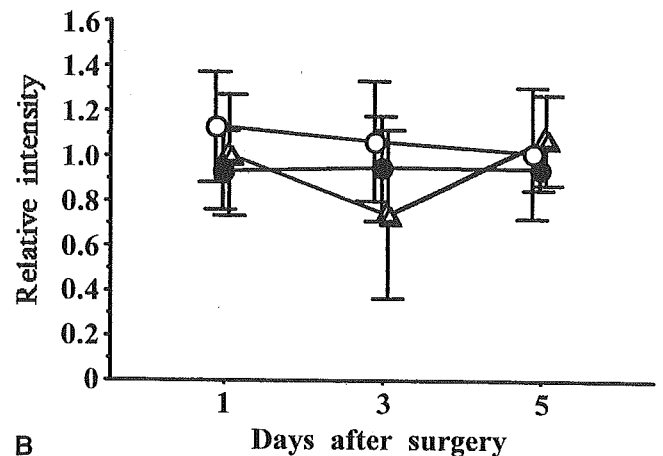
Results

We confirmed by histologic study that an implanted cecal tumor in this model invaded from the serosal layer to the mucosal layer in 3 weeks (Fig. 1a and b). After 3 weeks, peritoneal dissemination was identified macroscopically as a small nodule at the surface of the small intestine.

A significantly larger number of peritoneal dissemination nodules was observed in the laparotomy group



A



B

Fig. 3. Expression of E-cadherin (a) and beta-1 integrin (b) messenger RNA (mRNA) in mouse tumor in the three groups, as measured by real-time reverse transcriptase-polymerase chain reaction. The relative expression of each mRNA is normalized to the expression of glyceraldehyde phosphate dehydrogenase for semiquantification. ○ laparotomy, ●, CO₂ pneumoperitoneum, △ control. (* $p < 0.05$ laparotomy vs CO₂ pneumoperitoneum, † $p < 0.05$ laparotomy vs control).

(5.13 ± 12.33) than in the control group (2.87 ± 2.90) ($p < 0.05$) (Fig. 2a). The mean tumor volume score of peritoneal dissemination was significantly higher in the laparotomy group (6.53 ± 3.42) than in either the CO₂ pneumoperitoneum group (3.93 ± 13.04) or the control group (3.20 ± 1.82) ($p < 0.05$) (Fig. 2b). The volume and weight of the cecal tumor did not differ significantly among the three groups (Table 3).

The expressions of E-cadherin and beta-1 integrin mRNA on days 1, 3, and 5 after surgery are shown in Fig. 3. The expression of E-cadherin mRNA on day 5 in the laparotomy group was significantly depressed as compared with that in the CO₂ pneumoperitoneum and control groups (Fig. 3a). The expression of beta-1 integrin mRNA on each day did not differ significantly among the three groups (Fig. 3b).

Discussion

In this study, we found that peritoneal dissemination was more frequent after laparotomy than after CO₂

pneumoperitoneum in a nude mouse cecal implantation model. Our findings suggest that the increased peritoneal dissemination could result from the liberation of cells from the primary tumor. Several studies have demonstrated less impaired immunity after CO₂ pneumoperitoneum than after laparotomy [7]. Using nude mice, Volz et al. [21] showed the morphologic changes of mesothelial cells after surgical procedures, suggesting the possibility that these morphologic effects did not result from changed immunity by CO₂ pneumoperitoneum. Therefore, a nude mouse model was used in our study to clarify the direct effects of surgical procedures on the adhesion molecules of cancer cells.

There are three steps in the formation of peritoneal dissemination: liberation of cancer cells from the primary tumor, implantation to the peritoneum, and proliferation in the implanted area. Although we found several animal studies on the effect of CO₂ pneumoperitoneum on peritoneal implantation and proliferation [9, 16], no study was found that compared the liberation of cancer cells from the primary tumor after CO₂ pneumoperitoneum and after laparotomy. To examine the peritoneal implantation and proliferation after CO₂ pneumoperitoneum, an animal model with injection of cancer cells into the peritoneal cavity often is used [9, 16]. To study the liberation of cancer cells from the primary tumor after CO₂ pneumoperitoneum, we used the animal model with cecal cancer established previously by Furukawa et al. [6]. Using this animal model, cecal cancer with serosal invasion was identified in all mice 3 weeks after implantation of a tumor piece, and peritoneal dissemination also occurred in 42 of 45 mice 6 weeks after implantation.

The effect of CO₂ pneumoperitoneum on tumor growth and peritoneal dissemination still is controversial. Using a mouse model, Da Costa et al. [5] and Gitzelmann et al. [7] showed that subcutaneous tumor growth was greater after laparotomy than after CO₂ pneumoperitoneum. Bouvy et al. [2] used a rat model to show that tumor growth in the abdominal wall was greater after laparotomy than after CO₂ pneumoperitoneum. Using a rat model, Gutt et al. [8] showed that peritoneal tumor growth was greater after laparotomy than after CO₂ pneumoperitoneum. However, using a WAG rat model, Hubens et al. [10] found no significant difference between peritoneal tumor growth after CO₂ pneumoperitoneum and after laparotomy. In our study using nude mice, the size and weight of the cecal tumor in the CO₂ pneumoperitoneum group did not differ from that in the laparotomy group. Further study is necessary to clarify the factors influencing tumor growth after laparotomy, such as growth factors and immunity.

Several studies have investigated the effects of CO₂ pneumoperitoneum on port-site seeding and peritoneal dissemination. Le Moine et al. [15] reported that laparoscopic cecal resection significantly increased the incidence of a diffuse carcinomatosis, even when performed for locally noninvasive tumors, and emphasized the risk of increased peritoneal dissemination after laparoscopic surgery from manipulation of cancer cells in surgical procedures. Brundell et al. [3] and Texler et al. [20] also demonstrated by *in vitro* and *in vivo* experiments that

instrumental manipulation, mechanical tumor cell spillage, and local metabolism played the important role in port-site seeding of cancer cells after CO₂ pneumoperitoneum. On the other hand, morphologic studies with electron microscopy by Suematsu et al. [18] and Volz et al. [21] showed that peritoneal mesothelial cells were exfoliated and the basal membrane was exposed soon after surgical procedures. These changes were more intensive after laparotomy than after CO₂ pneumoperitoneum, suggesting that surgical procedures damage adhesion molecules of mesothelial cells. It is possible that adhesion molecules of cancer cells on the surface of the tumor also may be affected by surgical procedures. We showed in the current study that the tumor volume score of peritoneal dissemination in the laparotomy group was significantly higher than in either the CO₂ pneumoperitoneum group or the control group, possibly because of a decrease in E-cadherin cellular adhesion molecules.

E-cadherin is known as a main adhesion molecule for epithelial cell-cell interaction. Recent studies have shown that deletion of E-cadherin contributes to hematogenous metastasis and peritoneal dissemination of a tumor [11, 13, 23]. In the current study, the expression of E-cadherin mRNA was depressed on day 5 after laparotomy, as compared with the expression on day 5 after CO₂ pneumoperitoneum. Although the quantity and function of E-cadherin protein in the tumor were not measured in this study, the expression of E-cadherin mRNA was shown to be decreased on day 5 after laparotomy, as compared with expression on day 5 after CO₂ pneumoperitoneum. These data suppose the possibility that decreased E-cadherin in a tumor after laparotomy enables cancer cells to detach easily from the primary tumor and implant into the peritoneum.

In conclusion, we observed more extensive peritoneal dissemination after laparotomy than after CO₂ pneumoperitoneum in a mouse model of cecal cancer with serosal invasion. The decreased expression of E-cadherin mRNA in tumors after laparotomy but not after CO₂ pneumoperitoneum may be associated with the increase in peritoneal dissemination. Clinically, the long-term survival of patients who have undergone laparoscopic surgery for colon cancer is not clear, but our animal study suggests that laparoscopic surgery for colon cancer with serosal invasion is acceptable in terms of peritoneal dissemination.

Acknowledgments. The authors are grateful to Dr. T. Kubota and Dr. M. Watanabe, Department of Surgery, School of Medicine, Keio University, for technical advice. This study was supported in part by a Grant-in-Aid from the Ministry of Education, Science and Culture of Japan, account no. 15390401.

References

1. Adachi Y, Sato K, Shiraishi N, Kakisako K, Tanimura H, Kitano S (1998) Tumor size of colorectal cancer: indication for laparoscopic surgery. *Surg Laparosc Endosc* 8: 269-272
2. Bouvy ND, Marquet RL, Jeekel J, Bonjer HJ (1997) Laparoscopic surgery is associated with less tumour growth stimulation than

- conventional surgery: an experimental study. *Br J Surg* 84: 358–361
3. Brundell SM, Tucker K, Texler M, Brown B, Chatterson B, Hewett PJ (2002) Variables in the spread of tumor cells to trocars and port sites during operative laparoscopy. *Surg Endosc* 16: 1413–1419
 4. Chomczynski P, Sacchi N (1987) Single-step method of RNA isolation by acid guanidinium thiocyanate–phenol–chloroform extraction. *Anal Biochem* 162: 156–159
 5. Da Costa ML, Redmond HP, Finnegan N, Flynn M, Bouchier-Hayes D (1998) Laparotomy and laparoscopy differentially accelerate experimental flank tumour growth. *Br J Surg* 85: 1439–1442
 6. Furukawa T, Kubota T, Watanabe M, Kuo TH, Nishibori H, Kase S, Saikawa Y, Tanino H, Teramoto T, Ishibiki K (1993) A metastatic model of human colon cancer constructed using cecal implantation of cancer tissue in nude mice. *Surg Today* 23: 420–423
 7. Gitzelmann CA, Mendoza-Sagaon M, Talamini MA, Ahmad SA, Pegoli W Jr, Paidas CN (2000) Cell-mediated immune response is better preserved by laparoscopy than laparotomy. *Surgery* 127: 65–71
 8. Gutt CN, Riemer V, Kim ZG, Jacobi CA, Paolucci V, Lorenz M (1999) Impact of laparoscopic colonic resection on tumour growth and spread in an experimental model. *Br J Surg* 86: 1180–1184
 9. Hirabayashi Y, Yamaguchi K, Shiraishi N, Adachi Y, Kitamura H, Kitano S (2002) Development of port-site metastasis after pneumoperitoneum. *Surg Endosc* 16: 864–868
 10. Hubens G, Pauwels M, Hubens A, Vermeulen P, Van Marck E, Eyskens E (1996) The influence of a pneumoperitoneum on the peritoneal implantation of free intraperitoneal colon cancer cells. *Surg Endosc* 10: 809–812
 11. Jiang WG (1996) E-cadherin and its associated protein catenins, cancer invasion and metastasis. *Br J Surg* 83: 437–446
 12. Kakisako K, Sato K, Adachi Y, Shiraishi N, Miyahara M, Kitano S (2000) Laparoscopic colectomy for Dukes A colon cancer. *Surg Laparosc Endosc Percutan Tech* 10: 66–70
 13. Kinsella AR, Green B, Lepts GC, Hill CL, Bowie G, Taylor BA (1993) The role of the cell–cell adhesion molecule E-cadherin in large bowel tumour cell invasion and metastasis. *Br J Cancer* 67: 904–909
 14. Lacy AM, Garcia-Valdecasas JC, Delgado S, Castells A, Taura P, Pique JM, Visa J (2002) Laparoscopy-assisted colectomy versus open colectomy for treatment of non-metastatic colon cancer: a randomized trial. *Lancet* 359: 2224–2229
 15. Le Moine MC, Navarro F, Burgel JS, Pellegrin A, Khiari AR, Pourquier D, Fabre JM, Domergue J (1998) Experimental assessment of the risk of tumor recurrence after laparoscopic surgery. *Surgery* 123: 427–431
 16. Mutter D, Hajri A, Tassetti V, Solis-Caxaj C, Aprahamian M, Marescaux J (1999) Increased tumor growth and spread after laparoscopy vs laparotomy: influence of tumor manipulation in a rat model. *Surg Endosc* 13: 365–370
 17. Neuhaus SJ, Texler M, Hewett PJ, Watson DI (1998) Port-site metastases following laparoscopic surgery. *Br J Surg* 85: 735–741
 18. Suematsu T, Hirabayashi Y, Shiraishi N, Adachi Y, Kitamura H, Kitano S (2001) Morphology of the murine peritoneum after pneumoperitoneum vs laparotomy. *Surg Endosc* 15: 954–958
 19. Suematsu T, Shiromizu A, Yamaguchi K, Shiraishi N, Adachi Y, Kitano S (1999) Convenient murine pneumoperitoneal model for the study of laparoscopic cancer surgery. *Surg Laparosc Endosc Percutan Tech* 9: 279–281
 20. Texler ML, King G, Hewett PJ (1998) Tumour cell movement during heating and humidification of insufflating CO₂: an *in vitro* model. *Aust N Z J Surg* 68: 740–742
 21. Volz J, Koster S, Spacek Z, Paweletz N (1999) Characteristic alterations of the peritoneum after carbon dioxide pneumoperitoneum. *Surg Endosc* 13: 611–614
 22. Weeks JC, Nelson H, Gelber S, Sargent D, Schroeder G (2002) Short-term quality-of-life outcomes following laparoscopic-assisted colectomy vs open colectomy for colon cancer: a randomized trial. *JAMA* 287: 321–328
 23. Yonemura Y, Endou Y, Kimura K, Fushida S, Bandou E, Taniguchi K, Kinoshita K, Ninomiya I, Sugiyama K, Heizmann CW, Schafer BW, Sasaki T (2000) Inverse expression of S100A4 and E-cadherin is associated with metastatic potential in gastric cancer. *Clin Cancer Res* 6: 4234–4242

臨床応用レベルでの話題
悪性腫瘍への腹腔鏡下手術の現況

猪股 雅史 北野 正剛 白石 憲男

永 井 書 店

特集

新しい外科治療 現状と今後の展開

臨床応用レベルでの話題

悪性腫瘍への腹腔鏡下手術の現況

The current status of laparoscopic surgery for malignant diseases

猪股 雅史 北野 正剛** 白石 憲男*

INOMATA Masafumi

KITANO Seigo

SHIRAIISHI Norio

1987年に胆嚢摘出術に導入されて以来、腹腔鏡下手術は、胃癌・大腸癌・肝臓癌などの悪性疾患においても、低侵襲手術(Minimally invasive surgery)というカテゴリーを確立し、患者のQOLを重視する社会のニーズと相まって、この10数年で急速な普及をとげた。しかしながら各術式とも短期成績の評価から、その低侵襲性と安全性が明らかになったものの、進行癌に対する根治性や患者QOLなど長期成績については未だ明確でなく、EBMに基づいて適応が決定されているとは言い難い。

新たな機器の開発とともに手技の標準化あるいは安定化が図られた現在、全国レベルでの質の高い臨床研究の遂行によって長期成績を明らかにすることが求められている。

はじめに

腹腔鏡下手術は1987年胆嚢摘出術に導入されて以来、「key hole surgery」や「Nintendo operation」などと呼ばれ、「痛まず・傷が小さく・早く家に帰れる」手術として注目を集めた。これは、400年前に Ambrois Pare によって始められた近代外科学の歴史のなかで革命的な出来事といっても過言ではない。この腹腔鏡下手術は、患者のQOLを重視する近年の医療、社会のニーズに合致し、「低侵襲手術(Minimally invasive surgery)」というカテゴリーを確立して、この10数年で驚くばかりの急速な発展をとげた。その適応も、当初は胆石症や自然気胸、逆流性食道炎、鼠径ヘルニアなど良性疾患が主体であったが、

1990年代前半より胃癌・大腸癌をはじめとし、肺癌、食道癌、肝癌などの悪性疾患にも拡大されてきた。

本稿では、急速に普及してきた内視鏡外科手術のなかで、悪性疾患に対する腹腔鏡下手術の現況と問題点、さらに将来展望について述べたい。

I. 腹腔鏡下手術の動向

腹腔鏡下手術の動向については、日本内視鏡外科学会の第6回全国アンケート調査結果(2002年実施)から、その適応疾患、術式の種類および実施症例数のいずれもこの10年間に急速に増加していることが分かる(図1)¹⁾。最も症例数の多い胆

大分大学医学部第1外科学教室 講師 *助教授 **教授

Key words : 腹腔鏡下手術/悪性疾患/低侵襲手術/腹腔鏡補助下幽門側胃切除術(Laparoscopy-assisted distal gastrectomy, LADG)/ランダム化比較試験

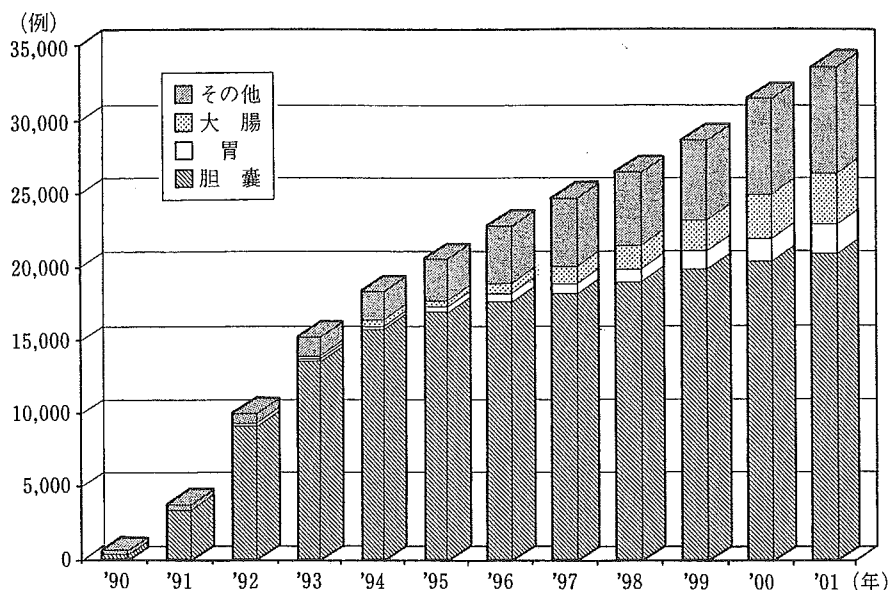


図1 わが国における腹腔鏡下手術の動向
(日本内視鏡外科学会第6回アンケート調査報告)

石症や自然気胸などの良性疾患は、開腹開胸手術に取ってかわり第一選択の術式としてすでに確立されたといえる。胃癌・大腸癌・肺癌などの悪性疾患については、これまで早期癌が対象とされていたが、最近ではその適応が進行癌へと広がっている。肝癌では、凝固壊死療法(RFAやMCT)の普及と相まって肝切除術も次第に普及しつつある。また腹腔鏡下手術は、根治手術はもとより、癌の腹膜播種などの進行度診断や緩和手術においてもその利点が生かされ多くの癌患者に用いられている。

以下、各疾患における腹腔鏡下手術の現況について述べていく。

II. 胃癌に対する腹腔鏡下手術

1. 術式の開発と現況

本邦で発生頻度の高い胃癌に対して、わが国に腹腔鏡手術が導入された翌年の1991年より日本独自の新しい術式が開発されてきた²⁾⁻⁴⁾。大上らの開発した腹腔鏡下胃局所切除術(LWR)は、腹壁と胃壁を貫くT型ファスナーを用いて病変を吊り上げ、自動縫合器を用いて腹腔内にて胃壁を

楔状切除するものである³⁾。術後の軽微な疼痛、早期社会復帰、十分な残胃容量など患者にとって有用な術式である。腹腔鏡下胃内粘膜切除術(IGMR)は、腹腔鏡と鉗子を胃内に進め、病変部の粘膜切除を行う方法である⁴⁾。胃の後壁病変に対して有用な術式であると報告されているが、手技的困難さから症例は限られている。今後、IT(insulation-tipped diathermic)ナイフなどを用いた一括切除可能な内視鏡的粘膜切除(EMR)法の改良と普及によって、リンパ節郭清を伴わないこれら術式の適応症例は次第に減少してゆくものと思われる。一方、D1+ α のリンパ節郭清を伴う腹腔鏡補助下幽門側胃切除術(LADG)は、1991年にわれわれが開発した術式である²⁾。まず、腹腔鏡下操作にて胃周囲のリンパ節郭清と胃の授動を十分に行った後、上腹部に約5cmの小開腹創をおき胃を体外に取り出す。通常の開腹手術同様、直視下に幽門側胃切除術、Billroth I法による再建を行い、吻合部を腹腔内へもどし、手術を終了するものである。D1+ α リンパ節郭清を伴うLADGの現時点での適応は、EMR困難なM癌および高度浸潤例を除いた4cm以下のSM癌としており、その施行症例は年々倍加している状況

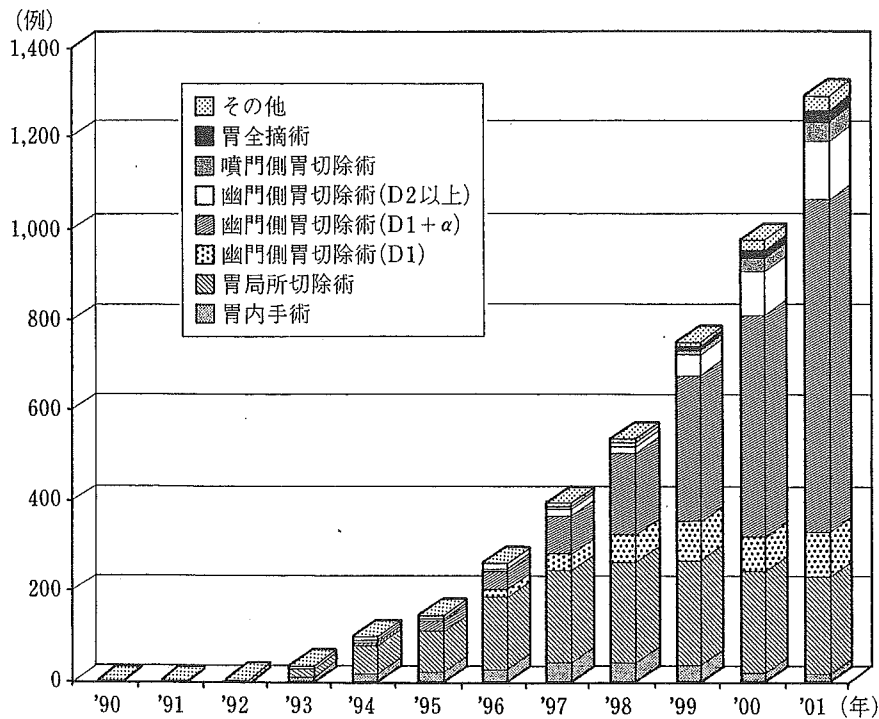


図2 胃癌に対する腹腔鏡下手術
(日本内視鏡外科学会第6回アンケート調査報告)

である(図2)。

2. LADGの有用性の評価

この術式の有用性に関しては、従来の開腹手術との症例対照研究やランダム化比較試験の結果が報告されている。表1にLADGの有用性をまとめた⁵⁾⁻⁸⁾。これらの評価から、LADGは根治性と低侵襲性を兼ね備え、術後QOLの向上や医療経済に貢献する有用な術式といえよう。

III. 大腸癌に対する腹腔鏡下手術

1. 術式の開発と現況

1991年 Jacobs らが世界ではじめて腹腔鏡下大腸切除術を報告し、本邦では、その2年後に初めての施行例が報告された。当初は内視鏡的ポリープ適除の適応外となった大きなポリープや一部の早期癌に対して施行されていたが、手術手技と器具の改良によってリンパ節郭清手技が飛躍的に進歩し、その適応は早期癌から進行癌へと拡がり、

表1 LADGの有用性(開腹手術との比較)

1. ランダム化比較試験(文献8を改変)	
(1)手術	出血量が少ない
(2)術後経過	歩行開始が早い 排ガスまでの期間が短い VASスコア(9POD)が良好 努力肺活量(3POD)が高い
2. 症例対照研究(文献5-7を改変)	
(1)手術	出血量が少ない
(2)術後経過	鎮痛薬の使用量が少ない 排ガスまでの期間が短い 飲水開始日が早い 発熱期間が短い 体重減少が軽度 術後在院日数が短い
(3)血液検査	WBCの上昇が軽度 顆粒球数の上昇が軽度 CRPの上昇が軽度 IL-6の上昇が軽度 Albの低下が軽度
(4)QOL	体重減少の程度が軽い 嚥下困難感が軽い 胸焼けが少ない 他の人に勧められる手術
(5)医療費	看護と病棟・食事に関する費用が少ない

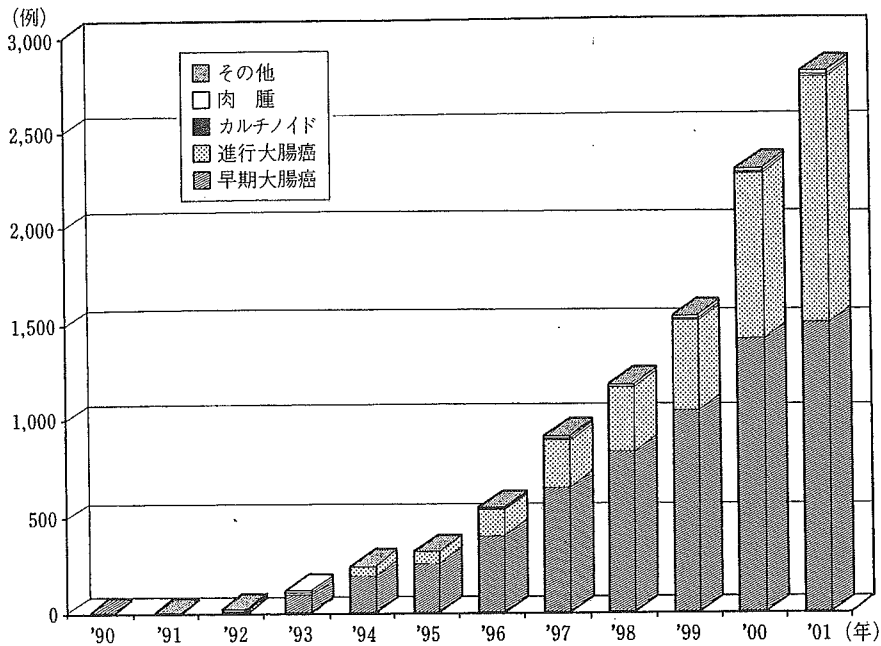


図3 大腸癌に対する腹腔鏡下手術
(日本内視鏡外科学会第6回アンケート調査報告)

外科治療全体に占める割合が急速に増加している(図3)。大腸癌に対する腹腔鏡下手術は、安全な剝離と確実なリンパ節郭清を行うために、さまざまなアプローチ法が開発されてきた⁹⁾。通常の開腹手術と同様に腸管外側から剝離を行い、腸管の授動を十分行った後にリンパ節郭清を行う外側アプローチ法、内側の血管根部をまず処理しリンパ節郭清を行ってから外側の腸管附着部を切離する内側アプローチ法、側腹部から後腹膜を剝離した後腹膜下筋膜の前面と腸間膜の間にスペースを作り血管根部に到達する後腹膜アプローチ法、剝離に先行して後腹膜側に安全なスペースを確保する後腹膜先行アプローチ法など、癌の進行度や施設に応じて選択されている。

2. 大腸癌に対する腹腔鏡下手術の評価

大腸癌に対する腹腔鏡下手術は、短期成績では、ランダム化比較試験の結果、開腹手術と比較して、術後の疼痛が少なく腸管蠕動の回復が早く入院期間の短縮や早期社会復帰が可能など低侵襲で整容性に優れている点で国内外で評価されている¹⁰⁾¹¹⁾。

遠隔成績に関しては、米国(NCI trial)、英国(Classic trial)、オーストラリア、ドイツ、スペイン、ヨーロッパ(COLOR Trial)の研究グループが1990年代後半に大規模な比較試験を開始しているが、その結果を得るにはさらに3~5年を要する。そのなかで、最近、スペインのグループが長期予後に関して、ランダム化比較試験の結果を報告している¹²⁾。対象症例は219例と少ないものの、stage I, IIでは生存率に差はなく、リンパ節転移を認めるstage IIIにおいて、開腹手術よりむしろ腹腔鏡下手術の方が生存率が有意に高いとの結果であった。

国内での長期成績に関するランダム化比較試験は未だ報告されていないが、昨年、厚生労働省が「がんにおける体腔鏡手術の適応拡大に関する研究」班(北野班)において、国内最大規模の大腸癌に対する腹腔鏡下手術の治療成績が報告された¹³⁾。これによると国内12施設より登録された2,036例の大腸癌症例(結腸癌1,495例、直腸癌541例)において、結腸癌は、観察期間の中央値が32ヵ月(最長125ヵ月)で、5年生存率が、

Dukes A : 99.5%, Dukes B : 96.8%, Dukes C : 79.6%, また直腸癌では、観察期間の中央値が25ヵ月(最長102ヵ月)で、Dukes A : 98.7%, Dukes B : 86.2%, Dukes C : 82.8%という結果であった。これは同ステージにおける開腹手術の成績と比較しても劣らず、むしろ Dukes B 結腸癌で腹腔鏡下手術の方が良好な結果が示されている。スペインのグループ¹²⁾やわが国の班研究の結果¹³⁾から腹腔鏡下手術が生存率に良い影響をもたらす可能性が考えられている。この理由として手術侵襲に基づく生体免疫能低下の軽減があげられるが、いまだ明確な結論は得られていない。

今後はわが国における根治性に関する大規模なランダム化比較試験が必要と言えよう。

IV. 肝癌に対する腹腔鏡下手術

1. 術式の開発と現況

1991年 Reich H らの腹腔鏡下肝切除の最初の報告からしばらくはわが国では肝嚢胞や血管腫、腺腫など良性疾患に対する報告がほとんどであった。しかしここ数年、慢性肝炎や肝硬変など併存疾患を伴う原発性肝癌に対しても腹腔鏡下肝切除を積極的に施行する施設が増加してきた。肝癌に対するマイクロ波およびラジオ波凝固壊死療法ともに近年増加傾向にある。

腹腔鏡下手術の適応基準について、術前肝機能は開腹手術と同様である。最も重要な点は腫瘍の局在部位であり、肝表面や外側区域に局在する腫瘍が対象となる。術式では肝部分切除や肝外側区域切除が適応術式であり、脈管先行処理が必要な系統的肝切除症例は現時点では適応外とされている。

手技上の問題点として、肝実質には低圧系の肝静脈が存在するため、腹腔鏡下肝切除において最も危惧されるのは炭酸ガス塞栓である。したがって、われわれの施設では腹壁吊り上げ法併用の工夫にて肝切除を施行している。

2. 肝癌に対する腹腔鏡下手術の評価

腹腔鏡下肝切除の治療成績についてはまだ大規模な臨床研究の報告がなく、積極的にすすめている施設ごとの症例対照研究の報告のみである。当施設において腹腔鏡下肝切除症例20例と同等の開腹切除症例とを比較したところ、腹腔鏡群は開腹群に比べ、出血量が少なく、術後在院日数が短く、合併症発生には差は認めない結果であった。長期成績については、現在までのところ全生存率および無再発生存率において有意な差は認めていない。肝癌においても低侵襲性のメリットが生かされるよう適応症例を選択しながら、凝固壊死療法とともにさらに普及していくものと思われる。

V. 将来展望

1. 適応拡大について

内視鏡外科手術の評価において、術中、術後のメリットについては数多く報告されているが、EBMの観点から満足できるものは少ない。また国内外において、胃癌・大腸癌をはじめ進行癌に対する根治性は未だ明確にされていないのが実状である。われわれは2001年度より、厚生労働省がん研究助成金(北野班)にて、大腸癌・肺癌・食道癌など悪性疾患に対する内視鏡外科手術の適応拡大について研究を行ってきた。この研究班で、これまでに国内最大規模の多施設共同の遠隔成績を含めた臨床データを示し、わが国の大腸癌・肺癌・食道癌に対する腹腔鏡下手術の今後の課題、すなわち進行癌に対する遠隔成績の評価の必要性を明らかにした。さらに、この班研究はこの4月より胃癌、前立腺癌における適応拡大をテーマに新たな研究を展開している。またこれらの研究成果を踏まえて、今年度より新たに厚生労働科学研究費補助金(北野班)による新規プロジェクトを発足させ、日本臨床腫瘍研究グループ(JCOG)に参加し、大腸癌に対するランダム化比較試験(RCT)をすすめている。これらのプロジェクト研究より、わが国から世界に発信しうる質の高い研究成果が得られることを確信している。

2. 内視鏡外科腫瘍学

手術に伴う生体反応や腹腔内の損傷治癒、さらに炭酸ガスの使用が、癌の増殖・浸潤・転移などの生物学的動向にどのように影響を与えるか、未だ十分に解明されていない。現在、国内外で、坦癌動物を用いた基礎実験が行われているが、必ずしも統一した見解が得られていない。われわれも、この新しい分野を「内視鏡外科腫瘍学」¹⁴⁾と位置付け、炭酸ガス気腹が腹膜播種・肝転移・リンパ節転移・創転移へどのような影響を与えるか転移モデルを用いて検討した。その結果、炭酸ガス気腹は開腹に比べ、腫瘍増殖や腹膜播種、肺転移、創転移、リンパ節転移が抑制されることを見出し、一方、肝の血管内皮へのダメージのためか肝転移に関しては促進の可能性があることを明らかにした。内視鏡外科の進歩のためには、臨床研究と基礎研究との両サイドからアプローチしていくことが必要と考えられる。

3. 患者 QOL の評価

多くの臨床研究により、腹腔鏡下手術の低侵襲性が明らかにされているが、患者 QOL に関してはその客観的評価の困難性より必ずしも明確にはされていない。2002年 JAMA に発表された大腸癌におけるランダム化比較試験の結果からは腹腔鏡下手術のメリットはごくわずかであった¹⁵⁾。今後、術式に応じた術後機能障害を中心にわが国の生活様式にあった短期および長期の QOL 評価を進めていく必要がある。

4. 新しい技術や機器の開発

早期癌の治療はいかに根治性を高めるかということから、いかに患者の QOL を向上させるかということに重きを置く方向となっている。Sentinel node navigation surgery (SNNS) によるリンパ節郭清の必要性を術中に判断し、必要のない予防的リンパ節郭清を省くことにより、侵襲をより小さくすることが可能となるであろう。一方、Hand-assist 法を用いて、広汎なリンパ節郭清を比較的容易に行おうとする工夫がなされ、進行癌への適応拡大も試みられている。Robotic surgery の登場によりさらなる手術侵襲の軽減と適応の拡大が進むと考えられる。高度進行癌において、試験開腹を回避するため、病期決定や腹膜播種などの診断を兼ね備えた腹腔鏡観察が有用であり、診断と治療の両面において腹腔鏡下手術が普及していくものと考えられる。

おわりに

悪性疾患に対する外科治療は、大きく変貌しようとしている。これは「患者にやさしい治療」を実践させよう腹腔鏡下手術の登場と患者主体の治療を求める社会のニーズに帰するところが大きい¹⁶⁾。今後、各悪性疾患における腹腔鏡下手術の長期成績や患者 QOL、経済性などについてわが国から国家レベルでの質の高い研究成果を明らかにし、ひとりでも多くの患者が安全な腹腔鏡下手術の恩恵に預かるよう願ってやまない。

文 献

- 1) 日本内視鏡外科学会：内視鏡外科手術に関するアンケート調査 - 第 6 回集計結果報告 -。日鏡外会誌 7: 479-567, 2002.
- 2) Kitano S, Iso Y, Moriyama M, et al: Laparoscopy-assisted Billroth I gastrectomy. Surg. Laparosc. Endosc 4: 146-148, 1994.
- 3) Ohgami M, Kumai K, Otani Y, et al: Laparoscopic wedge resection of the stomach for early gastric cancer using a lesion-lifting method. Dis Surg 11: 64-67, 1994.
- 4) Ohashi S: Laparoscopic Intraluminal (Intragastric) surgery for early gastric cancer, A new concept In laparoscopic surgery. Surg. Endosc 9: 169-171, 1995.
- 5) Adachi Y, Suematsu T, Shiraishi N, et al: Quality of life after laparoscopy-assisted Billroth-I gastrectomy. Ann. Surg 229: 49-54, 1999.
- 6) Adachi Y, Shiraishi N, Shiromizu A, et al: Laparoscopy-assisted Billroth-I gastrectomy compared with conventional open gastrectomy. Arch. Surg 135: 806-810, 2000.
- 7) Kitano S, Shiraishi N, Kakisako K, et al: Laparoscopy-assisted distal gastrectomy (LADG) for Cancer; Our 10 years' experience. Surg. Laparosc. Endosc 12: 204-207, 2002.
- 8) Kitano S, Shiraishi N, Fujii K, et al: A randomized controlled trial comparing an open versus a laparoscopy-assisted distal gastrectomy for the treatment of early gastric cancer; an interim report. Surg 131: 306-311,

- 2002.
- 9) 小西文雄：腹腔鏡下大腸切除－術式の発展・展開と課題。腹腔鏡下大腸手術 アプローチとスタンダードテクニック，腹腔鏡下大腸切除研究会編，医学書院，東京，6-8，2002.
 - 10) Hasegawa H, Kabeshima Y, Watanabe M, et al: Randomized controlled trial of laparoscopic versus open colectomy for advanced colorectal cancer. *Surg. Endosc* 17: 636-640, 2003.
 - 11) Hazebroek EJ; Color Study Group: COLOR: a randomized clinical trial comparing laparoscopic and open resection for colon cancer. *Surg Endosc* 16: 949-953, 2002.
 - 12) Lacy AM, Garcia-Valdecasas JC, Delgado S, et al: Laparoscopy-assisted colectomy versus open colectomy for treatment of non-metastatic colon cancer; a randomized trial. *Lancet* 359: 2224-2229, 2002.
 - 13) 北野正剛，北島政樹，小西文雄ほか：厚生労働省がん研究助成金「がんにおける体腔鏡手術の適応拡大に関する研究」第2回アンケート調査結果報告；大腸がん 29-59, 2002.
 - 14) 北野正剛，白石憲男：内視鏡外科における癌の増殖・進展・転移。日外会誌 101: 526-530, 2000.
 - 15) Weeks JC, Nelson H, Gelber S, Clinical Outcomes of Surgical Therapy (COST) Study Group: Short-term quality-of-life outcomes following laparoscopic-assisted colectomy vs open colectomy for colon cancer: a randomized trial. *JAMA* 287: 321-328, 2002.
 - 16) 北野正剛，猪股雅史：内視鏡外科手術の21世紀への展開。医学のあゆみ 195: 1023-1024, 2000.



and Other Interventional Techniques

Morphological changes in hepatic vascular endothelium after carbon dioxide pneumoperitoneum in a murine model

K. Izumi, K. Ishikawa, H. Shiroshita, Y. Matsui, N. Shiraishi, S. Kitano

Department of Surgery I, Oita University Faculty of Medicine, 1-1 Idaigaoka, Hasama-machi, Oita 879-5593, Japan

Received: 16 April 2004/Accepted: 1 October 2004/Online publication: 10 February 2005

Abstract

Background: Liver metastasis is an important prognostic factor in advanced colorectal cancer. Several studies have demonstrated that carbon dioxide (CO₂) pneumoperitoneum enhances liver metastasis in an animal model. In the present study, we used scanning electron microscopy (SEM) to investigate morphological changes in hepatic vascular endothelium after CO₂ pneumoperitoneum in a murine model.

Methods: Thirty-three male BALB/c mice were randomized to undergo pneumoperitoneum (CO₂, air, or helium), open laparotomy, and anesthesia alone. After each procedure, the animals' livers were excised at days 0, 1, and 3 and examined by SEM.

Results: In the CO₂ pneumoperitoneum group, we observed rough surface and derangement of the hepatic vascular endothelial cells and intercellular clefts on day 1. In the other groups, no major morphologic changes were observed at any time.

Conclusions: Hepatic vascular endothelium changes after CO₂ pneumoperitoneum. Such characteristic changes may play an important role in establishing liver metastasis after CO₂ pneumoperitoneum.

Key words: Laparoscopic surgery — Pneumoperitoneum — Carbon dioxide — Murine model — Scanning electron microscopy — Colorectal cancer — Liver metastasis

Laparoscopic surgery yields favorable short-term clinical outcomes in the management of colorectal malignancies. As a less invasive alternative to open surgery, it has been shown to be technically feasible and to improve patient comfort. There have been few reports, however, on long-term outcomes.

Liver metastasis is the most important prognostic factor in advanced colorectal cancer. Therefore, the effects of pneumoperitoneum on liver metastasis of colorectal cancer have been a matter of concern. Several experimental studies have shown that carbon dioxide (CO₂) pneumoperitoneum enhances liver metastasis [4–7]. Carbon dioxide pneumoperitoneum causes a decrease in portal blood flow [13, 18, 19] and provides favorable conditions for the adherence of free tumor cells, which can then spread into the portal system, to the hepatic vascular endothelium. However, it is uncertain whether morphological changes occur in the hepatic vascular endothelium after surgical procedures such as the CO₂ pneumoperitoneum or open laparotomy.

In the present study, we used a murine pneumoperitoneum model to investigate morphological changes in hepatic vascular endothelium by scanning electron microscopy (SEM).

Materials and methods

Animals

Thirty-three male BALB/c mice weighting 20–24 g and aged 6–8 weeks were used in this study. All animals were kept under standard laboratory conditions (temperature, 20–24°C; relative humidity, 50–60%; 12 h light/dark cycles) and given a standard laboratory diet with free access to water and food. All experiments were performed under the guidelines for animal experimentation of the Oita University Faculty of Medicine.

Procedures

All surgical procedures were performed under general anesthesia induced by diethyl ether inhalation. Thirty-three BALB/c mice were divided into three operative groups; pneumoperitoneum, laparotomy, and anesthesia only (control).

In the pneumoperitoneum group, nine mice underwent CO₂ pneumoperitoneum at 8–10 mmHg for 60 min and were killed after either 0 h ($n = 3$), 24 h ($n = 3$), or 72 h ($n = 3$). In addition, six mice received an air or helium ($n = 3$ each) pneumoperitoneum at 8–10 mmHg for 60 min and were killed after 24 h. The procedure for