

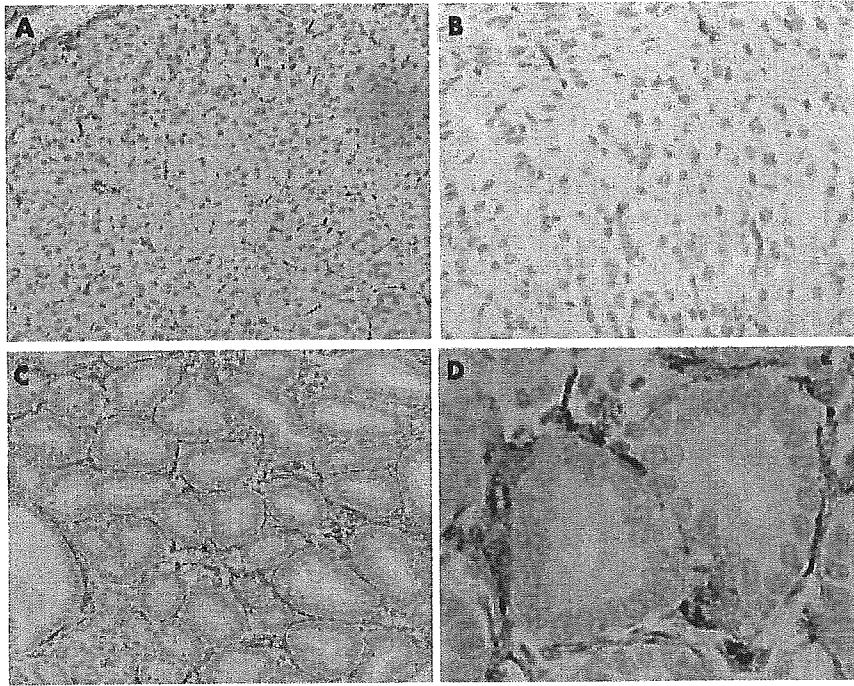Figure 4 Normal and intestinal metaplastic mucosa of the mouse stomach. Immunohistochemical stain for α -smooth muscle actin. Pericryptal fibroblast sheath (PCFS) formed by pericryptal fibroblasts is closely embracing the epithelial cells of the intestinal metaplastic mucosa (C, D) while PCFS is not seen in the normal gastric mucosa (A, B). Magnification $\times 100$ (A, C); $\times 400$ (B, D).

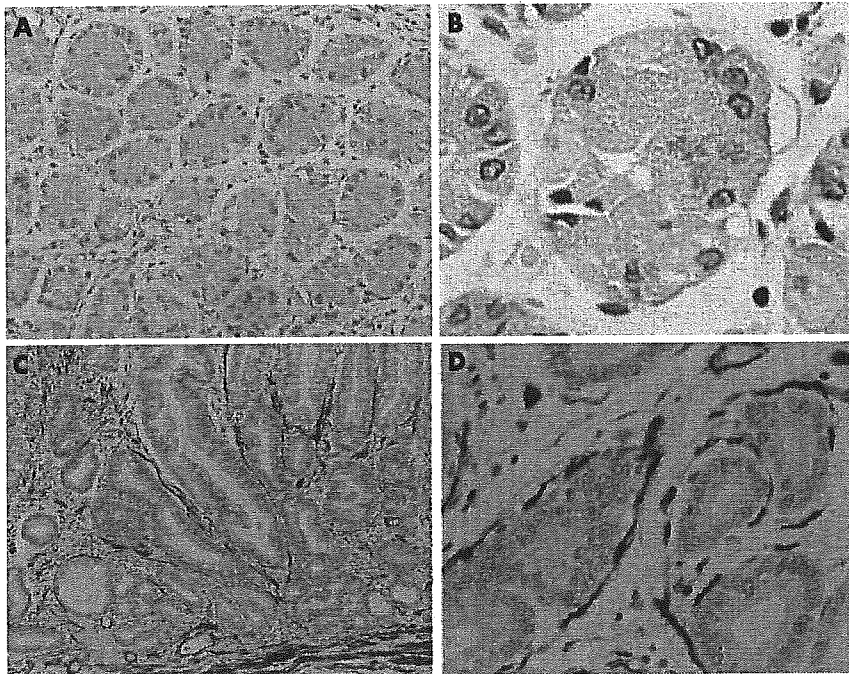


Figure 5 Normal and intestinal metaplastic mucosa of the human stomach. Immunohistochemical stain for α -smooth muscle actin. Pericryptal fibroblast sheath (PCFS) formed by pericryptal fibroblasts is closely embracing the epithelial cells of the intestinal metaplastic mucosa (C, D) while PCFS is not seen in the normal gastric mucosa (A, B). Magnification $\times 100$ (A, C); $\times 400$ (B, D).

adenocarcinoma of both humans and mice (fig 7C, G) while PCFS was easily recognised in the intestinal metaplastic areas (fig 7A, E). PCFS was absent in all 10 Cdx2 transgenic mouse and 10 human intestinal-type adenocarcinomas. Both human and murine gastric carcinomas were classified as intestinal-type according to the criteria of Lauren¹⁴ and as category 5.2 according to the five categories of the Vienna classification.^{15 16} We examined expression of Cdx2 in intestinal metaplasia and adenocarcinoma. Cdx2 staining for the adenocarcinoma lesion (fig 7D, H) was extremely weak

compared with the intestinal metaplastic lesion (fig 7, B and F). The decrease in Cdx2 may explain, in part, the cause of the disappearance of PCFS in the gastric adenocarcinoma. There was no difference in immunoreactivities for Cdx2 and α -SMA in intestinal metaplastic mucosa between 12 and 50 week old Cdx2 transgenic mice (data not shown).

DISCUSSION

Our results demonstrate that intestinal metaplasia is not merely epithelial metaplasia but also affects the underlying

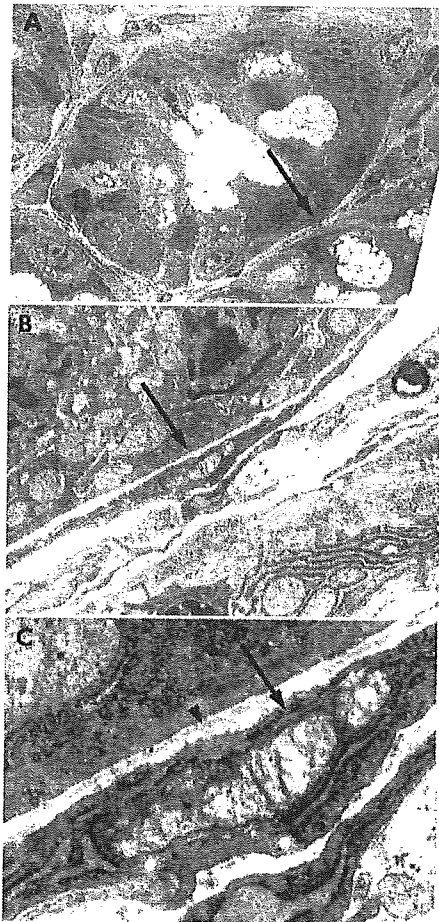


Figure 6 Electron micrograph of intestinal metaplastic mucosa in the Cdx2 transgenic mouse. The fibroblast (arrows) around the epithelial cells of the crypt demonstrates the fusiform shape and broad contact with the epithelial basal lamina (arrowhead) which is typical of the pericryptal fibroblast. The basement membrane is indicated by the arrowhead (C).

mesenchyme. The glands of intestinal metaplastic mucosa induced by a single homeobox gene, Cdx2, in transgenic mouse stomach were surrounded by PCFS via the basement membrane while normal gastric glands were not. PCFS was also seen around the glands of human intestinal metaplastic mucosa. Cdx2 has been reported to induce expression of various types of intestine specific genes that have consensus sequences for Cdx2 directly to bind. That Cdx2 has a pivotal role not only in differentiating intestinal metaplastic mucosal epithelial cells but also in inducing PCFS in the mesenchyme was demonstrated with Cdx2 transgenic mice previously generated by us. To the best of our knowledge, the present study is the first to show that in the intestinal metaplastic mucosa, the epithelium as well as the mesenchyme changes from a gastric-type mucosa to an intestinal-type mucosa through expression of transcription factor Cdx2 in the epithelium. Furthermore, as human intestinal metaplasia is mainly caused by *H. pylori* infection, generation of the PCFS in human intestinal metaplastic mucosa indicates that the epithelium as well as the subjacent mesenchyme is trans-differentiated from the gastric type to the intestinal type by *H. pylori* infection.

The stomach and intestine are derived from the primitive undifferentiated gut tube formed during gastrulation but Cdx2 expression is only activated distal to the gastric-duodenal junction.^{17, 18} Cdx2 haploinsufficiency results in

abnormal differentiation of midgut endoderm.¹⁹ The initial effect of heterozygous Cdx2 knockout mice, apparent in neonates, is seen as patches of forestomach epithelium present in the terminal ileum, caecum, or proximal colon.²⁰ Thus in Cdx2 deficiency, cells which would normally differentiate into caecum and proximal colon follow a default pathway and form the stratified squamous epithelium characteristic of forestomach. In contrast, intestinal metaplastic epithelium was induced from gastric mucosa by expression of Cdx2,⁷ indicating that Cdx2 may be a key regulator for intestinal epithelial cell fate determination and differentiation. The intestinal metaplastic mucosa of Cdx2 transgenic mouse stomach also generated PCFS in the mesenchyme indirectly through expression of Cdx2 in the epithelium. The crypts of intestinal metaplastic mucosa in the human stomach were also embraced by pericryptal fibroblasts via the basement membrane. These results suggest that Cdx2 may have a master function in the coordinate process leading to both epithelial and mesenchymal differentiation during continuous renewal of the intestinal mucosa.

The embryonic gut of vertebrates consists of endodermal epithelium and surrounding mesenchyme. The involvement of epithelial-mesenchymal cell interactions in the control of cell differentiation during intestinal ontogeny and during continuous cell renewal in the mature organ has been demonstrated.^{21, 22} Regional differentiation and morphogenesis of the gut epithelium requires tissue interactions involving instructive effects of mesenchyme and competence of the epithelium receiving them.²³ The importance of the mesenchyme has been shown by in vivo models in which hybrid recombinants composed of fetal or adult mesenchyme associated with epithelial cells are grafted.^{24, 25} The chick embryonic stomach and the fetal rat colon endoderms are induced to achieve a small intestinal morphological and functional cytodifferentiation (induction of *sucrase-isomaltase* gene expression) under the influence of the small intestinal mesenchyme.^{25, 26} In the avian embryonic muscular stomach epithelium (proventriculus), expression of embryonic chick *pepsinogen* gene, which is specific to developing glandular stomach epithelium, is regulated by the instructive influences of the chick glandular stomach mesenchyme.²⁷ These effects of the mesenchyme on the epithelium indicate that mesenchyme is important in morphogenetic processes and in maintenance of the tissular integrity in the gut.

Laminin-1, an extracellular matrix component of the basement membrane, is known to stimulate intestinal cell differentiation.²⁸⁻³¹ The differentiating effect of laminin-1 coatings on Caco2-TC7 cells is accompanied by upregulation of Cdx2,³¹ suggesting that Cdx2 plays a key role in the cascade of events involved in extracellular matrix mediated intestinal cell differentiation. These data indicate that intestinal mesenchyme influences intestinal epithelial differentiation. Conversely, the present results showed that Cdx2 induced intestinal epithelium affected PCFS formation in the mesenchyme. PCFS in intestinal metaplasia of the stomach was formed simply by expressing Cdx2 in gastric mucosal epithelial cells. The results indicate that expression of Cdx2 in epithelial cells directly plays a pivotal role in generating PCFS around Cdx2 expressing glands. It is therefore possible that the intestinal metaplastic mucosa of Cdx2 transgenic mouse stomach results from direct interaction of Cdx2 protein with the promoters of enterocytic differentiation markers as well as from indirect effects of the mesenchyme. Taken together, these observations indicate that reciprocal interactions between epithelium and mesenchyme might be important for the development and differentiation of intestinal mucosa, including both epithelium and mesenchyme.

PCFS has been investigated in colorectal carcinoma by immunohistochemistry employing an antibody against

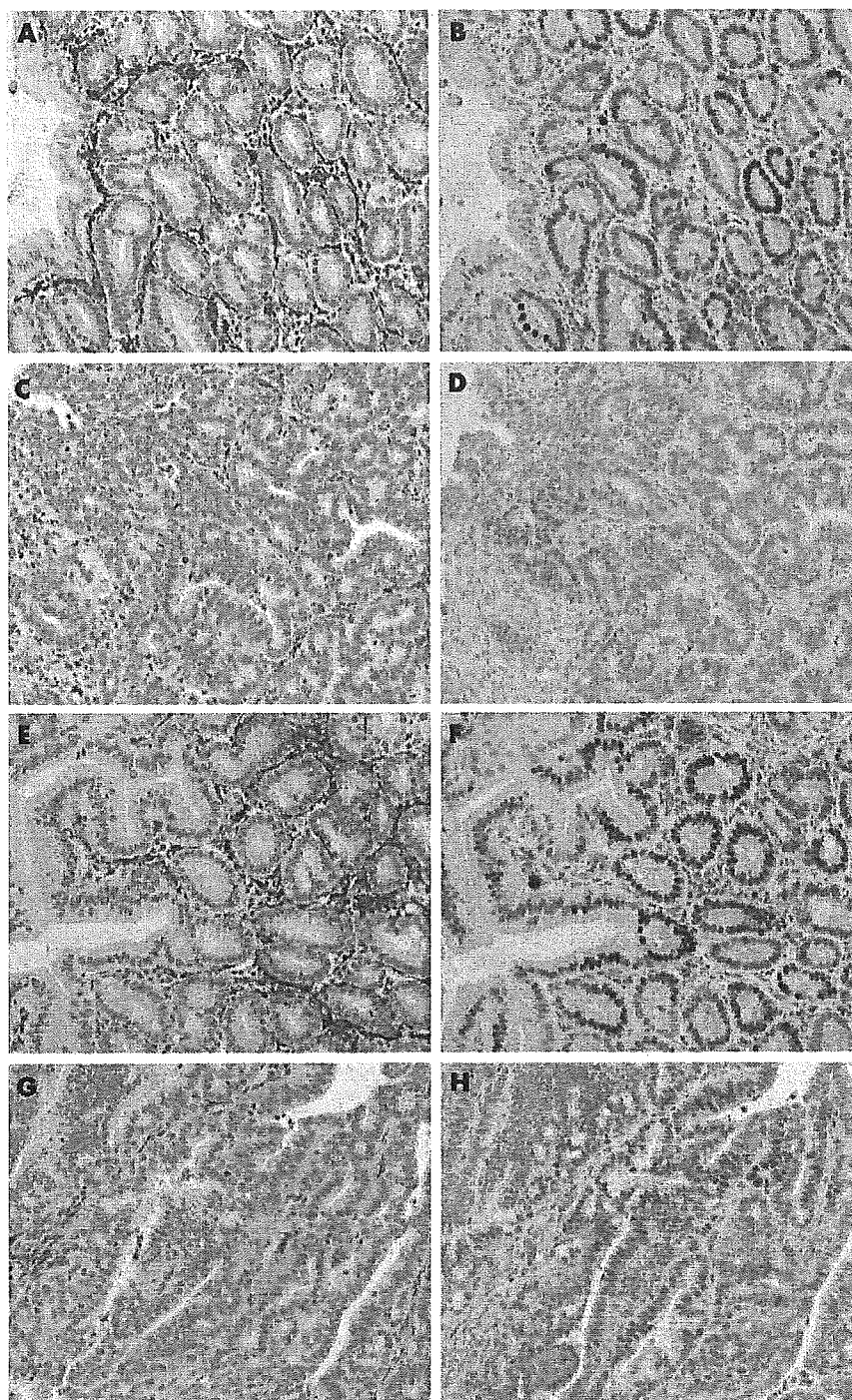


Figure 7 Relationship between Cdx2 and α -smooth muscle actin (α -SMA) positive pericryptal fibroblast sheath (PCFS) in vivo. Gastric intestinal metaplasia of Cdx2 transgenic mice (A, B) and humans (E, F). Gastric adenocarcinoma of Cdx2 transgenic mice (C, D) and humans (G, H). Immunohistochemical staining for α -SMA (A, C, E, G) and Cdx2 (B, D, F, H). Cdx2 expressing intestinal metaplastic epithelial cells are surrounded by α -SMA positive pericryptal fibroblasts in the intestinal metaplastic mucosa (A, B, E, F) while PCFS is not recognised in the adenocarcinoma (C, G). α -SMA positive cells in gastric carcinoma tissue is not histologically PCFS. Cdx2 staining for the adenocarcinoma lesion (D, H) is extremely weak compared with the intestinal metaplastic lesion (B, F). Magnification $\times 200$.

α -SMA.³² The amount of PCFS was reduced significantly in colorectal carcinoma. A significant reverse correlation was seen between the degree of colorectal neoplasia progression and the quantity of neoplastic glands with PCFS.³³ Nakayama *et al* reported the relationship between α -SMA positive stromal cells and gastric carcinoma.³⁴ Their α -SMA positive

stromal cells were high molecular weight caldesmon negative and different from PCFS which is positive for high molecular weight caldesmon.³⁴ The relationship between PCFS and gastric carcinoma has not been investigated to date. In the present study, we have shown that PCFS also disappeared in the gastric carcinoma of both humans and mice, similar to

the colonic carcinoma. Although intestinal-type gastric carcinoma is thought to develop from gastric epithelium that has undergone intestinal metaplasia, intestinal-type gastric carcinoma cells were not surrounded by PCFS, which is different from the intestinal metaplastic mucosa around the gastric carcinoma. The presence of mesenchymal cells or mesenchyme derived extracellular matrix molecules has been shown to play a fundamental role in epithelial cell proliferation and differentiation via epithelial-mesenchymal cell interactions.¹²⁻¹⁵ Mesenchymal cells express important growth factors whose receptors are found on the epithelial cell surface which is exemplified by expression of hepatocyte growth factor/scatter factor and of keratinocyte growth factor which regulate epithelial cell behaviour.³⁶ These instructive actions of the mesenchyme on gastrointestinal tract epithelial cells indicate that the generation and disappearance of PCFS might be closely related to the development of intestinal-type gastric carcinoma.

In conclusion, ectopic expression of Cdx2 in gastric mucosal epithelial cells induced not only intestinal epithelial cell differentiation but also PCFS generation in the mesenchyme, indicating that Cdx2 may be important for intestinal mucosal differentiation involving both the epithelium and mesenchyme. In addition, PCFS in the mesenchyme may be related to the development of gastric carcinoma.

ACKNOWLEDGEMENTS

This work was supported in part by Grants-in-Aid for Scientific Research (B) (12470126 for HM, 13470122 for KS), Grants-in-Aid for Scientific Research (C) (14570501 for HM), and Grants-in-Aid for Exploratory Research (14657134 for KS) from Japan Society for the Promotion of Science. We are grateful for the expert technical assistance provided by H Nagaki and K Sasaki.

Authors' affiliations

H Mutoh, K Satoh, H Osawa, T Tomiyama, H Kita, T Yoshida, K Tamada, H Yamamoto, N Isoda, K Ido, K Sugano, Department of Gastroenterology, Jichi Medical School, Tochigi, Japan
S Sakurai, Department of Pathology, Jichi Medical School, Tochigi, Japan

Conflict of interest: None declared.

REFERENCES

- Correa P. Human gastric carcinogenesis: a multistep and multifactorial process—First American Cancer Society Award Lecture on Cancer Epidemiology and Prevention. *Cancer Res* 1992;52:6735–40.
- Eda A, Osawa H, Yanaka I, et al. Expression of homeobox gene CDX2 precedes that of CDX1 during the progression of intestinal metaplasia. *J Gastroenterol* 2002;37:94–100.
- Satoh K, Mutoh H, Eda A, et al. Aberrant expression of CDX2 in the gastric mucosa with and without intestinal metaplasia: effect of eradication of *Helicobacter pylori*. *Helicobacter* 2002;7:192–8.
- Almeida R, Silva E, Santos-Silva F, et al. Expression of intestine-specific transcription factors, CDX1 and CDX2, in intestinal metaplasia and gastric carcinomas. *J Pathol* 2003;199:36–40.
- Bai YQ, Yamamoto H, Akiyama Y, et al. Ectopic expression of homeodomain protein CDX2 in intestinal metaplasia and carcinomas of the stomach. *Cancer Lett* 2002;176:47–55.
- Mizoshita T, Inada K, Tsukamoto T, et al. Expression of Cdx1 and Cdx2 mRNAs and relevance of this expression to differentiation in human gastrointestinal mucosa—with special emphasis on participation in intestinal metaplasia of the human stomach. *Gastric Cancer* 2001;4:185–91.
- Mutoh H, Hakamata Y, Sato K, et al. Conversion of gastric mucosa to intestinal metaplasia in Cdx2-expressing transgenic mice. *Biochem Biophys Res Commun* 2002;294:470–9.
- Pascal RR, Kaye GI, Lane N. Colonic pericryptal fibroblast sheath: replication, migration, and cytodifferentiation of a mesenchymal cell system in adult tissue. I. Autoradiographic studies of normal rabbit colon. *Gastroenterology* 1968;54:835–51.
- Kaye GI, Lane N, Pascal RR. Colonic pericryptal fibroblast sheath: replication, migration, and cytodifferentiation of a mesenchymal cell system in adult tissue. II. Fine structural aspects of normal rabbit and human colon. *Gastroenterology* 1968;54:852–65.
- Desaki J, Fujiwara T, Komuro T. A cellular reticulum of fibroblast-like cells in the rat intestine: scanning and transmission electron microscopy. *Arch Histol Jpn* 1984;47:179–86.
- Naftalin RJ, Pedley KC. Regional crypt function in rat large intestine in relation to fluid absorption and growth of the pericryptal sheath. *J Physiol* 1999;514:211–27.
- Birchmeier C, Birchmeier W. Molecular aspects of mesenchymal-epithelial interactions. *Annu Rev Cell Biol* 1993;9:511–40.
- Kedinger M, Freund JN, Launary JF, et al. Cell interactions through basement membrane in intestinal development and differentiation. In: Sanderson IR, Walker WA, eds. *Development of the gastrointestinal tract*. London: BC Decker Inc, 1999:83–102.
- Lauren P. The two histological main types of gastric carcinoma: diffuse and so-called intestinal-type carcinoma. *Acta Pathol Microbiol Scand* 1965;64:31–49.
- Schlemper RJ, Riddell RH, Kato Y, et al. The Vienna classification of gastrointestinal epithelial neoplasia. *Gut* 2000;47:251–5.
- Dixon MF. Gastrointestinal epithelial neoplasia: Vienna revisited. *Gut* 2002;51:130–1.
- Silberg DG, Swain GB, Suh ER, et al. Cdx1 and Cdx2 expression during intestinal development. *Gastroenterology* 2000;119:961–71.
- James R, Erler T, Kazenwadel J. Structure of the murine homeobox gene cdx-2. Expression in embryonic and adult intestinal epithelium. *J Biol Chem* 1994;269:15229–37.
- Chawengsaksophak K, James R, Hammond VE, et al. Homeosis and intestinal tumours in Cdx2 mutant mice. *Nature* 1997;386:84–7.
- Beck F, Chawengsaksophak K, Waring P, et al. Reprogramming of intestinal differentiation and intercalary regeneration in Cdx2 mutant mice. *Proc Natl Acad Sci U S A* 1999;96:7318–23.
- Simon-Assmann P, Kedinger M. Heterotypic cellular cooperation in gut morphogenesis and differentiation. *Semin Cell Biol* 1993;4:221–30.
- Simon-Assmann P, Kedinger M, De Arcangelis A, et al. Extracellular matrix components in intestinal development. *Experientia* 1995;51:883–900.
- Yasugi S. Regulation of pepsinogen gene expression in epithelial cells of vertebrate stomach during development. *Int J Dev Biol* 1994;38:273–9.
- Kedinger M, Simon PM, Grenier JF, et al. Role of epithelial-mesenchymal interactions in the ontogenesis of intestinal brush-border enzymes. *Dev Biol* 1981;86:339–47.
- Duluc I, Freund JN, Leberquien C, et al. Fetal endoderm primarily holds the temporal and positional information required for mammalian intestinal development. *J Cell Biol* 1994;126:211–21.
- Haffen KKM, Simon-Assmann P. Cell-contact-dependent regulation of enterocytic differentiation. New York: Raven Press, 1989.
- Fukuda K, Ishii Y, Saiga H, et al. Mesenchymal regulation of epithelial gene expression in developing avian stomach: 5'-flanking region of pepsinogen gene can mediate mesenchymal influence on its expression. *Development* 1994;120:3487–95.
- Hahn U, Stallmach A, Hahn EG, et al. Basement membrane components are potent promoters of rat intestinal epithelial cell differentiation in vitro. *Gastroenterology* 1990;98:322–35.
- Vachon PH, Beaulieu JF. Extracellular heterotrimeric laminin promotes differentiation in human enterocytes. *Am J Physiol* 1995;268:G857–67.
- Basson MD, Turowski G, Emenaker NJ. Regulation of human (Caco-2) intestinal epithelial cell differentiation by extracellular matrix proteins. *Exp Cell Res* 1996;225:301–5.
- Lorentz O, Duluc I, Arcangelis AD, et al. Key role of the Cdx2 homeobox gene in extracellular matrix-mediated intestinal cell differentiation. *J Cell Biol* 1997;139:1553–65.
- Yao T, Tsuneyoshi M. Significance of pericryptal fibroblasts in colorectal epithelial tumors: a special reference to the histologic features and growth patterns. *Hum Pathol* 1993;24:525–33.
- Li A, Hasui K, Yonezawa S, et al. Immunohistochemical analysis of pericryptal fibroblast sheath and proliferating epithelial cells in human colorectal adenomas and carcinomas with adenoma components. *Pathol Int* 1999;49:426–34.
- Nakayama H, Enzan H, Miyazaki E, et al. Alpha smooth muscle actin positive stromal cells in gastric carcinoma. *J Clin Pathol* 2002;55:741–4.
- Simo P, Simon-Assmann P, Arnold C, et al. Mesenchyme-mediated effect of dexamethasone on laminin in cocultures of embryonic gut epithelial cells and mesenchyme-derived cells. *J Cell Sci* 1992;101:161–71.
- Birchmeier C, Meyer D, Riethmacher D. Factors controlling growth, motility, and morphogenesis of normal and malignant epithelial cells. *Int Rev Cytol* 1995;160:221–66.

Cdx2 specifies the differentiation of morphological as well as functional absorptive enterocytes of the small intestine

HIROYUKI MUTOH*, KIICHI SATOH, HIROTO KITA, HIROTSUGU SAKAMOTO, HIROKO HAYAKAWA, HIRONORI YAMAMOTO, NORIO ISODA, KIICHI TAMADA, KENICHI IDO and KENTARO SUGANO

Department of Gastroenterology, Jichi Medical School, Tochigi, Japan

ABSTRACT Many transcription factors are involved in the molecular control of intestinal epithelial cell differentiation. We report in this study that the transcription factor Cdx2 functions to define absorptive enterocytes during intestinal epithelial differentiation. Cdx2 is expressed in the villi of the normal small intestine. Intestinal metaplasia, which expresses Cdx2, occurs as a pathological condition in gastric mucosa. We have previously established Cdx2 transgenic mice expressing Cdx2 exclusively in the gastric epithelium. In this study using Cdx2 transgenic mice, we show that Cdx2 plays a key role in the differentiation of intestinal absorptive enterocytes. The gastric mucosa of Cdx2 transgenic mice was morphologically completely changed into intestinal metaplastic mucosa. Absorptive enterocytes had microvilli which were observed by electron microscope. The intestinal metaplastic mucosa of Cdx2 transgenic mice expressed sucrase and peptide transporter PepT1. Disaccharidase and leucine aminopeptidase activities were observed in the intestinal metaplastic mucosa. Glucose and amino acids were absorbed from Cdx2 transgenic mouse stomach with intestinal metaplasia. Finally we generated mice whose intestine was extensively excised. Cdx2 transgenic mice with intestinal metaplasia survived even after extensive intestinal excision. We successfully demonstrated that Cdx2 induced not only morphological but also functional absorptive enterocytes in the intestinal metaplastic mucosa *in vivo*. Our results suggest that Cdx2 is necessary and sufficient by itself to specify the development of intestinal absorptive enterocytes, whereas other factors which are expressed in the small intestine are not always necessary for the differentiation of functional absorptive enterocytes.

KEY WORDS: Cdx2, absorptive enterocyte, transgenic mouse

Introduction

Cdx2, caudal-related homeobox transcription factor, is selectively localized in the fetal and adult mucosal epithelial nuclei of small and large intestine in both humans and mice (Meyer and Gruss, 1993). Cdx2 is important in the transcriptional regulation of intestinal genes and the differentiation of intestinal cells *in vitro* (Suh *et al.*, 1994) (Suh and Traber, 1996). Inactivation of Cdx2 by homologous recombination results in the development of multiple intestinal polyp-like lesions in pericaecal areas of the midgut of heterozygote mice (Beck *et al.*, 2003). These polyps did not express Cdx2 and consisted of hamartoma containing areas which are similar to keratinizing stratified squamous epithelium found in the mouse forestomach, columnar mucous-secreting cells found in the gastric cardia and parietal cells found in the gastric corpus.

In the progression of chronic gastritis, gastric mucosal cells

deviate from the normal pathway of gastric differentiation to an intestinal phenotype. *Helicobacter pylori* infection is involved in the process of progression from normal gastric mucosa to superficial gastritis, chronic active gastritis, atrophic gastritis and finally to intestinal metaplasia (Correa, 1992). We and others have reported that intestine-specific transcription factor Cdx2 is expressed in human gastric intestinal metaplastic mucosa (Eda *et al.*, 2002) (Satoh *et al.*, 2002) (Almeida *et al.*, 2003) (Bai *et al.*, 2002) (Mizoshita *et al.*, 2001). Furthermore, we established Cdx2 transgenic mice that expressed Cdx2 exclusively in the gastric epithelium (Mutoh *et al.*, 2002). The gastric fundic mucosa of Cdx2 transgenic mice was morphologically completely changed into intestinal metaplastic mucosa. These metaplastic glands were composed of a large number of goblet cells, columnar

Abbreviations used in this paper: BCAA, branched-chain amino acid; PepT, peptide transporter.

*Address correspondence to: Dr. Hiroyuki Mutoh, Department of Gastroenterology, Jichi Medical School, Yakushiji 3311-1, Minamikawachimachi, Kawachigun, Tochigi 329-0498, Japan. Fax: +81-285-44-8297. e-mail: muto@jichi.ac.jp

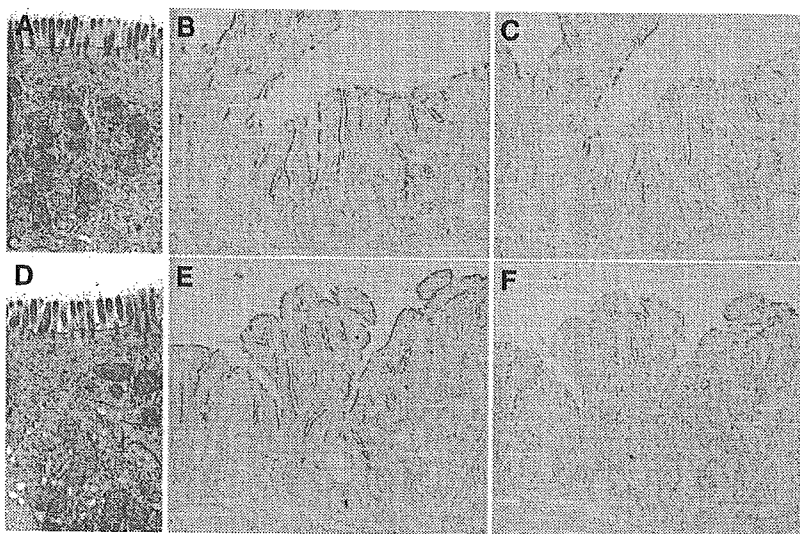


Fig. 1. Absorptive enterocytes. Microvilli (A: 37 days after birth, B: 244 days after birth), sucrose (C: 37 days after birth, D: 244 days after birth) and peptide transporter (PepT1) (E: 37 days after birth, F: 244 days after birth) in intestinal metaplastic mucosa of the Cdx2 transgenic mouse stomach. (A,B) Electron microscopy revealed microvilli on the luminal surface of absorptive enterocytes. (C,D) Sucrose immunoreactivity was observed, which was widely distributed on the luminal surface of intestinal metaplastic epithelial cells. (E,F) PepT1 immunoreactivity was also widely found on the luminal surface of intestinal metaplastic epithelial cells.

intestinal-type epithelial cells and enteroendocrine cells. We evaluated the features of absorptive enterocytes by brush border and alkaline phosphatase activity in the surface of columnar intestinal-type epithelial cells. Currently, it has not been elucidated whether Cdx2 can differentiate absorptive enterocytes with absorptive function. The Cdx2 transgenic mouse is a good model for clarifying whether Cdx2 can differentiate morphological as well as functional absorptive enterocytes *in vivo*.

Findings from the intestinal metaplasia of Cdx2 transgenic mouse stomach and the intestinal polyps of heterozygous Cdx2 knockout mice suggest that Cdx2 might play a key role in intestinal epithelial cell fate determination and differentiation. These findings prompted us to investigate whether Cdx2 is able to differentiate absorptive enterocytes with enzymatic and absorptive functions *in vivo*. We successfully demonstrated that Cdx2 induced not only morphological but also functional absorptive enterocytes in intestinal metaplastic mucosa *in vivo*. The present results suggest that Cdx2 is necessary and is sufficient by itself to specify the development of intestinal absorptive enterocytes, whereas other factors that are expressed in the small intestine are not always necessary for the differentiation of functional absorptive enterocytes.

Results

We had previously established Cdx2 transgenic mice expressing Cdx2 exclusively in gastric epithelium (Mutoh *et al.*, 2002). The gastric mucosa of Cdx2 transgenic mice was morphologically completely changed into intestinal metaplastic mucosa. In order to better characterize the intestinal metaplasia induced by Cdx2,

we examined whether Cdx2 can induce the enterocytes with intestinal absorptive function in addition to morphological intestinal metaplasia in the Cdx2-transgenic mice.

Electron microscopy revealed microvilli on the luminal surface of absorptive enterocytes (Fig. 1 A,B). The sections were stained by the antibodies for sucrose and peptide transporter PepT1 (Fei *et al.*, 1994) in order to characterize the intestinal metaplasia. Sucrase and PepT1 were strongly and widely expressed on the luminal surface of the intestinal metaplastic mucosal epithelial cells (Fig. 1 C-F).

To clarify whether disaccharides are actually digested because sucrase was detected by immunohistochemistry, disaccharides (sucrose, maltose, trehalose) were incubated at 37°C for 60 min with homogenized mucosa of normal stomach, intestinal metaplasia and normal small intestine. Glucose concentrations derived from digested disaccharides (sucrose, maltose, trehalose) increased in the incubations with homogenized mucosa of both small intestine and intestinal metaplasia (Table 1). The glucose con-

centration in homogenized mucosa of intestinal metaplasia was almost equal to that of normal small intestine, whereas the glucose concentration did not increase in homogenized gastric mucosa (Table 1). The finding that Cdx2-induced intestinal metaplastic mucosa is able to digest disaccharides indicates that sucrase, maltase and trehalase are functionally active.

We then examined whether the glucose derived from the digestion of these disaccharides is absorbed by intestinal metaplastic mucosa. Serum glucose concentrations in Cdx2 transgenic mice increased after 0.5 ml of 50 % glucose was administered into the stomach with ligated cardia and pylorus. However, glucose concentrations in normal mice did not increase after glucose administration into the stomach (Fig. 2).

To examine whether there is any activity for digesting peptides in the intestinal metaplastic mucosa, we measured leucine aminopeptidase activity in normal gastric mucosa, intestinal metaplastic mucosa and normal intestinal mucosa. Leucine aminopeptidase activity was found in homogenized intestinal metaplastic mucosa and normal intestine, whereas it was not detected in

TABLE 1

SUCRASE, MALTASE AND TREHALASE ACTIVITIES IN THE NORMAL STOMACH AND SMALL INTESTINE AND INTESTINAL METAPLASTIC MUCOSA

	Normal stomach (mg/dL)	intestinal metaplasia(mg/dL)	small intestine (mg/dL)
sucrose	1±0	115±10	138±7
maltose	25±1	643±30	566±41
trehalose	1±0	120±5	201±30

Values are means ± SE.

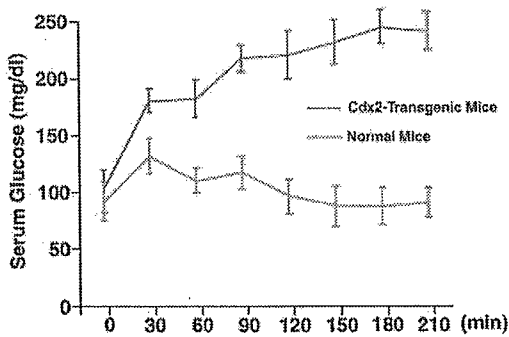


Fig. 2 (Left). Absorption of glucose. Serum glucose levels increased after 0.5 ml of 50 % glucose was administered into Cdx2 transgenic mouse stomach with ligation of the cardia and pylorus, whereas glucose concentrations in the normal ligated mouse stomach did not increase. Ten wild-type and 10 Cdx2 transgenic mice (120 days old) were used. Data are expressed as mean \pm SD.

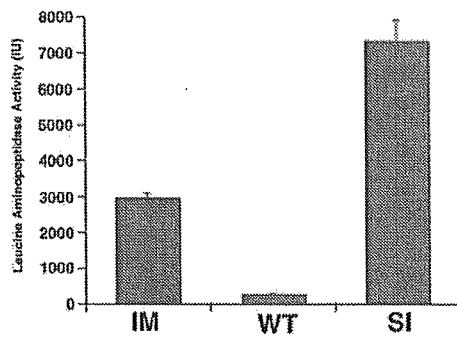


Fig. 3 (Right). Leucine aminopeptidase activity in intestinal metaplastic mucosa (IM), normal gastric mucosa (WT) and normal small intestinal mucosa (SI). Leucine aminopeptidase activity in intestinal metaplastic mucosa and normal small intestinal mucosa was observed, whereas it was not detected in normal gastric mucosa. Ten intestinal metaplastic mucosae, 10 normal gastric mucosae and 10 Cdx2 transgenic mouse gastric mucosae (120 days old) were used. Data are expressed as mean \pm SD.

homogenized normal gastric mucosa (Fig. 3).

We also determined whether amino acids derived from digestion of the peptides are absorbed by intestinal metaplastic mucosa. Amino acids (valine, leucine, isoleucine, tyrosine) were administered into normal and Cdx2 transgenic mouse stomach with ligated cardia and pylorus. The levels of tyrosine and branched-

chain amino acids in the serum increased after amino acid administration, while they did not increase in normal mouse stomach (Fig. 4). The results show that the intestinal metaplastic mucosa has both enzymatic and absorptive functions and indicate that Cdx2 transgenic mice might be able to survive without small intestine.

We then generated mice whose small intestine was extensively excised. Cdx2 transgenic mice with intestinal metaplasia survived more than 1 month after intestinal excision (Fig. 5). On the other hand, normal mice had rapid weight loss after the operation and died within 7 days (Fig. 5).

Discussion

The morphological intestinal metaplastic mucosa induced by transcription factor Cdx2 in the stomach had enzymatic and absorptive function specific to absorptive enterocytes in the small intestine. The present results suggest that Cdx2 is a key regulator for the development and differentiation of absorptive enterocytes in small intestine *in vivo*. We determined that Cdx2 is necessary and sufficient by itself for this development and differentiation, whereas other factors that are expressed in the small intestine are not always necessary for the differentiation of functional absorptive enterocytes.

We have previously shown that Cdx2 transgenic mice developed normally into superficially healthy adults but showed intestinal metaplasia in the stomach up to 12 weeks of age (Mutoh *et al.*, 2002). The gastric mucosa was completely replaced by

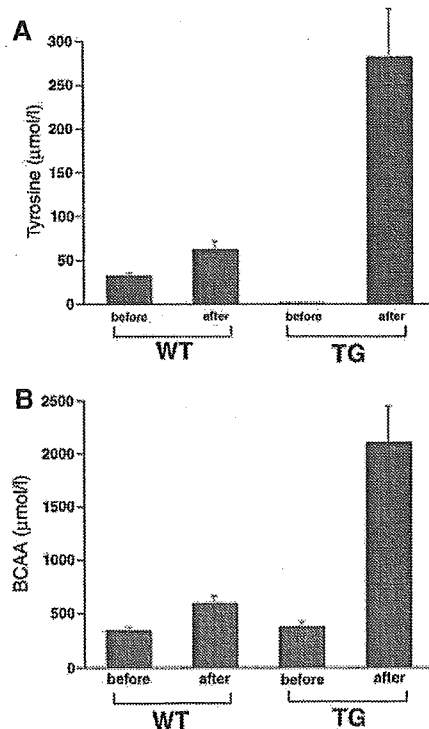


Fig. 4. Absorption of amino acids. The concentration of tyrosine (A) and branched-chain amino acids (BCAA) (B) in the serum increased after amino acids (valine, leucine, isoleucine, tyrosine) were administered into Cdx2 transgenic mouse stomach (TG) with ligation of the cardia and pylorus, while it did not increase in normal mouse stomach (WT). Ten wild-type and 10 Cdx2 transgenic mice (120 days old) were used. Data are expressed as mean \pm SD.

intestinal metaplastic mucosa consisting of terminally differentiated intestinal epithelial cells. Hematoxylin and eosin-stained sections of the intestinal metaplastic mucosa of Cdx2 transgenic mouse stomach showed columnar intestinal-type epithelial cells in addition to a large number of goblet cells and enteroendocrine cells. Absorptive enterocytes are the most important for the intestinal epithelial cells because the main function of the small intestine is to digest food and absorb nutrients. Disaccharidase activities specific to absorptive enterocytes such as sucrase, maltase, trehalase and lactase were reported in human intestinal metaplastic mucosa, using specimens obtained by gastrectomy or endoscopic gastric biopsy (Classen *et al.*, 1968) (Launiala and Siurala, 1968) (Capoferro, 1972) (Kawachi *et al.*, 1974) (Gudmand-Hoyer *et al.*, 1975). Cdx2 has been reported to regulate the expression of various genes specific to absorptive enterocytes in the intestine such as sucrase-isomaltase (Suh and Traber, 1996), lactase-phlorizin hydrolase (Troelsen *et al.*, 1997), calbindin-D9K (Colnot *et al.*, 1998) and carbonic anhydrase I (Drummond

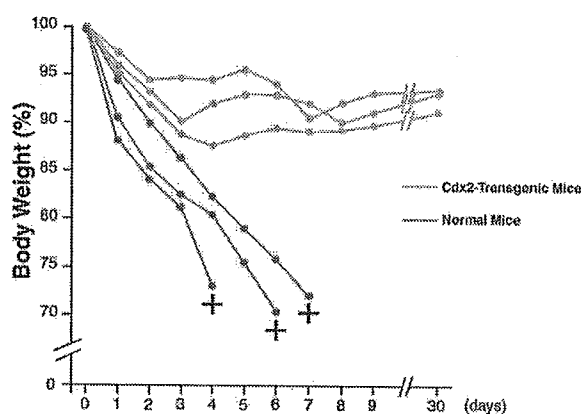


Fig. 5. Survival curve after extensive intestinal excision. The Cdx2 transgenic mice with intestinal metaplasia survived over 1 month after intestinal excision. On the other hand, the normal mice showed rapid weight loss after the operation and died within 7 days.

et al., 1998) *in vitro*, using the immature intestinal cell line, IEC-6. Trans-differentiated epithelial cells in the gastric mucosa of Cdx2 transgenic mice have microvilli specific for intestinal absorptive enterocytes and express alkaline phosphatase, sucrase and peptide transporter (PepT1) extensively. These data suggest that Cdx2 might induce functional intestinal metaplastic mucosa. However, it has not been elucidated whether the absorptive enterocytes induced by Cdx2 have enzymatic and absorptive function characteristic of small intestinal mucosa *in vivo*.

Silberg *et al.* reported that transgenic mice expressing Cdx2 in gastric mucosa used cis-regulatory elements of Foxa3 (Hnf3 γ) (Silberg *et al.*, 2002). The Foxa3/Cdx2 transgenic mice induced intestinal metaplasia in the stomach. However, goblet cells were predominant and the presence of absorptive enterocytes was suggested only by alkaline phosphatase expression. Sucrase was not expressed in the Foxa3/Cdx2 transgenic mice.

Silberg *et al.*, discussed that other factors specific to small intestine might be needed in addition to Cdx2 for the expression of sucrase. Forced expression of Cdx2 in IEC-6 cells has been shown to induce cellular differentiation characterized by microvilli and sucrase-isomaltase gene expression (Suh and Traber, 1996). However, IEC-6 cells are of intestinal origin and might express other factors that cooperate with Cdx2 to induce mature enterocytes. In our study, the intestinal metaplastic mucosa of Cdx2 transgenic mice had absorptive and enzymatic functions characteristic of normal intestinal mucosa. The present results indicate that transcription factor Cdx2 is sufficient for inducing absorptive enterocytes without other intestine-specific factors and that Cdx2 is an important regulator for the development and differentiation of absorptive enterocytes in the gut. The results from Cdx2 transgenic mice substantiate that Cdx2 is a main transcription factor for inducing differentiation of not only morphological but also functional absorptive enterocytes *in vivo*.

Disaccharides and amino acids introduced into the stomach were digested and absorbed from the intestinal metaplastic mucosa. Cdx2 transgenic mice with functional intestinal metaplastic mucosa were able to survive even after extensive small bowel resection. The intestinal metaplastic mucosa with absorptive enterocytes is limited to the fundic region of the stomach. However, the pyloric ring might function as a valve and subsequently elongate the time for the nutrients to pass. Nutrients might be retained in the stomach with intestinal metaplastic mucosa and absorbed from the intestinal metaplastic mucosa due to the presence of the pyloric ring.

In conclusion, the absorptive enterocytes in Cdx2-induced intestinal metaplastic mucosa expressed enzymatic and absorptive functions, indicating that Cdx2 can induce not only morphological but also functional absorptive enterocytes. The present results suggest that Cdx2 plays an essential role for the differentiation of absorptive enterocytes during both intestinal ontogeny and continuous cell renewal in the mature organ.

Materials and Methods

Cdx2 transgenic mice

We used Cdx2 transgenic mice with stomach-specific expression of Cdx2 using the β -subunit gene promoter of rat H⁺/K⁺-ATPase (Mutoh *et al.*, 2002). The gastric mucosa of Cdx2 transgenic mice was completely changed to intestinal metaplastic mucosa (Mutoh *et al.*, 2002).

Immunohistochemistry

Three-micron-thick sections were cut, deparaffinized, rehydrated in PBS, placed in 10 mmol/L citrate buffer (pH 6.0) and heated in an 850-W microwave for 10 minutes. Slides were preincubated with blocking buffer (Vector Laboratories, Burlingame, CA) for 15 minutes at room temperature. Primary antisera, anti-PepT1 (1:500, provided by Dr. K. Miyamoto) and anti-sucrase (1:500, provided by Dr. K. Miyamoto), were diluted in PBS and incubated overnight at 4°C. Slides were then washed in PBS and incubated with Envision (DAKO, Tokyo, Japan). After development with 3, 3'-diaminobenzidine tetrahydrochloride (Vector Laboratories), slides were counterstained with hematoxylin and viewed under a light microscope.

Fixation and preparation of tissue for electron microscopy

Gastric intestinal metaplastic mucosa of Cdx2 transgenic mice was fixed at 4°C in 2% glutaraldehyde in PBS, followed by six washes in PBS

with post fixation in 1 % osmium tetroxide (OsO₄). They were examined by a HITACHI H-7500 scanning electron microscope.

Digestion of disaccharides

The gastric fundic mucosa and small intestinal mucosa of normal mice and the intestinal metaplastic mucosa of Cdx2 transgenic mice were excised and weighed. Following the addition of equal weight of normal saline, the excised specimens were homogenized for 30 seconds in a glass homogenizer in ice water. The homogenized tissues were incubated at 37°C for 1 hour with equal weight of each disaccharide solution (0.1 M) (sucrose, maltose and trehalose). The disaccharidase activities were determined by measuring the concentrations of glucose derived from digested disaccharide. The concentration of glucose was determined by measuring the peroxide produced by the glucose oxidase reaction (Dahlqvist, 1961).

Absorption of glucose and amino acids

Ten wild-type and 10 Cdx2 transgenic mice (120 days old) were denied access to food overnight and then anesthetized with ether. After the abdominal wall was incised, the cardia and the pylorus were ligated. Glucose or amino acids (valine, leucine, isoleucine, tyrosine) were administered into the stomach and the incision was sutured. Blood samples were then collected 1 hour after glucose or amino acid administration. Branched-chain amino acids (valine, leucine, isoleucine) and tyrosine were measured by an enzymatic method (Diacolor-BTR kit, Ono Pharm. Co., Osaka, Japan).

Extensive small intestinal excision

We generated mice whose intestine was extensively excised. The normal and Cdx2 transgenic mice (120 days old) were denied access to food overnight and then anesthetized with ether. After the abdominal wall was incised, the small intestine from the anal side of the duodenal papilla to 2 cm before the end of the ileum on the oral side was removed and the incision was sutured. The operated mice were maintained by feeding with an elemental diet (Elental; Ajinomoto Co., Tokyo, Japan) and the weight of each mouse was measured periodically.

Acknowledgements

This work was supported in part by Grants-in-Aid for Scientific Research (B) (13470122 for KS), Grants-in-Aid for Scientific Research (C) (14570501 for HM) and Grants-in-Aid for Exploratory Research (14657134 for KS) from the Japan Society for the Promotion of Science. We appreciate the expert technical assistance provided by H. Nagaki and K. Sasaki.

References

- ALMEIDA, R., SILVA, E., SANTOS-SILVA, F., SILBERG, D.G., WANG, J., DE BOLOS, C. and DAVID, L. (2003). Expression of intestine-specific transcription factors, cdx1 and cdx2, in intestinal metaplasia and gastric carcinomas. *J Pathol* 199: 36-40.
- BAI, Y.Q., YAMAMOTO, H., AKIYAMA, Y., TANAKA, H., TAKIZAWA, T., KOIKE, M., KENJI YAGI, O., SATOH, K., TAKESHITA, K., IWAI, T. *et al.* (2002). Ectopic expression of homeodomain protein cdx2 in intestinal metaplasia and carcinomas of the stomach. *Cancer Lett* 176: 47-55.
- BECK, F., CHAWENGSAKSOPHAK, K., LUCKETT, J., GIBLETT, S., TUCCI, J., BROWN, J., POULSOM, R., JEFFERY, R. and WRIGHT, N.A. (2003). A study of regional gut endoderm potency by analysis of cdx2 null mutant chimaeric mice. *Dev Biol* 255: 399-406.
- CAPOFERRO, R. (1972). Intestinal metaplasia in experimental atrophic gastritis. Sucrase activity in the gastric mucosa of guinea-pigs after stomach irradiation. *Scand J Gastroenterol* 7: 711-2.
- CLASSEN, M., VON HINUBER, G. and DEMLING, L. (1968). Disaccharidases of the gastric mucosa in chronic atrophic gastritis with intestinal metaplasia. *Digestion* 1: 52-8.
- COLNOT, S., ROMAGNOLO, B., LAMBERT, M., CLUZEAUD, F., PORTEU, A., VANDEWALLE, A., THOMASSET, M., KAHN, A. and PERRET, C. (1998). Intestinal expression of the calbindin-d9k gene in transgenic mice. Requirement for a cdx2-binding site in a distal activator region. *J Biol Chem* 273: 31939-46.
- CORREA, P. (1992). Human gastric carcinogenesis: A multistep and multifactorial process—first american cancer society award lecture on cancer epidemiology and prevention. *Cancer Res* 52: 6735-40.
- DAHLQVIST, A. (1961). Determination of maltase and isomaltase activities with a glucose-oxidase reagent. *Biochem J* 80: 547-51.
- DRUMMOND, F.-J., SOWDEN, J., MORRISON, K. and EDWARDS, Y.H. (1998). Colon carbonic anhydrase 1: Transactivation of gene expression by the homeodomain protein cdx2. *FEBS Letters* 423: 218-22.
- EDA, A., OSAWA, H., YANAKA, I., SATOH, K., MUTOH, H., KIHARA, K. and SUGANO, K. (2002). Expression of homeobox gene cdx2 precedes that of cdx1 during the progression of intestinal metaplasia. *J Gastroenterol* 37: 94-100.
- FEI, Y.J., KANAI, Y., NUSSBERGER, S., GANAPATHY, V., LEIBACH, F.H., ROMERO, M.F., SINGH, S.K., BORON, W.F. and HEDIGER, M.A. (1994). Expression cloning of a mammalian proton-coupled oligonucleotide transporter. *Nature* 368: 565-5.
- GUDMAND-HOYER, E., ASP, N.G. and MOLLMANN, K.M. (1975). Disaccharidase activities in intestinal metaplasia - contribution of lysosomal brush border enzymes. *Scand J Gastroenterol* 10: 653-6.
- KAWACHI, T., KOGURE, K., TANAKA, N., TOKUNAGA, A. and SUGIMURA, T. (1974). Studies of intestinal metaplasia in the gastric mucosa by detection of disaccharidases with «tes-tape». *J Natl Cancer Inst* 53: 19-30.
- LAUNIALA, K. and SIURALA, M. (1968). Disaccharidase activities of the atrophic gastric mucosa with intestinal metaplasia. *Scand J Gastroenterol* 3: 160-2.
- MEYER, B.I. and GRUSS, P. (1993). Mouse cdx-1 expression during gastrulation. *Development* 117: 191-203.
- MIZOSHITA, T., INADA, K., TSUKAMOTO, T., KODERA, Y., YAMAMURA, Y., HIRAI, T., KATO, T., JOH, T., ITOH, M. and TATEMATSU, M. (2001). Expression of cdx1 and cdx2 mRNAs and relevance of this expression to differentiation in human gastrointestinal mucosa—with special emphasis on participation in intestinal metaplasia of the human stomach. *Gastric Cancer* 4: 185-91.
- MUTOH, H., HAKAMATA, Y., SATO, K., EDA, A., YANAKA, I., HONDA, S., OSAWA, H., KANEKO, Y. and SUGANO, K. (2002). Conversion of gastric mucosa to intestinal metaplasia in cdx2- expressing transgenic mice. *Biochem Biophys Res Commun* 294: 470-9.
- SATOH, K., MUTOH, H., EDA, A., YANAKA, I., OSAWA, H., HONDA, S., KAWATA, H., KIHARA, K. and SUGANO, K. (2002). Aberrant expression of cdx2 in the gastric mucosa with and without intestinal metaplasia: Effect of eradication of helicobacter pylori. *Helicobacter* 7: 192-8.
- SILBERG, D.G., SULLIVAN, J., KANG, E., SWAIN, G.P., MOFFETT, J., SUND, N.J., SACKETT, S.D. and KAESTNER, K.H. (2002). Cdx2 ectopic expression induces gastric intestinal metaplasia in transgenic mice. *Gastroenterology* 122: 689-96.
- SUH, E., CHEN, L., TAYLOR, J. and TRABER, P.G. (1994). A homeodomain protein related to caudal regulates intestine-specific gene transcription. *Mol Cell Biol* 14: 7340-51.
- SUH, E. and TRABER, P.G. (1996). An intestine-specific homeobox gene regulates proliferation and differentiation. *Mol Cell Biol* 16: 619-25.
- TROELSEN, J.T., MITCHELMORE, C., SPODSBERG, N., JENSEN, A.M., NOREN, O. and SJOSTROM, H. (1997). Regulation of lactase-phlorizin hydrolase gene expression by the caudal- related homeodomain protein cdx-2. *Biochem J* 322: 833-8.

Received: October 2004

Reviewed by Referees: November 2004

Modified by Authors and Accepted for Publication: April 2005

Edited by: Makoto Asashima

Bleeding polyp in the mid small intestine identified by capsule endoscopy and treated by double-balloon endoscopy

Hiroto Kita, MD, Hironori Yamamoto, MD, Tetsuya Nakamura, MD, Katsuro Shirakawa, MD, Akira Terano, MD, Kentaro Sugano, MD

Tochigi, Japan

The advent of capsule endoscopy has substantially advanced the diagnosis of small-intestinal disorders.¹⁻³ Moreover, the development of a new technique, double-balloon endoscopy, also allows visualization of the entire small bowel.⁴⁻⁷ This system includes an endoscope with a working length of 200 cm and an outer diameter of 8.5 mm. It has a built-in air-insufflation system, which is directly connected to the balloon at the tip of the endoscope. The system also includes a flexible overtube 145 cm in length and 12.2 mm in outer diameter. The endoscope and the overtube are both equipped with soft latex balloons that can be inflated or deflated by means of a balloon-pump controller while monitoring balloon pressure. This report describes a case of GI bleeding in which the diagnosis was made by capsule endoscopy, followed by treatment with the use of double-balloon endoscopy.

CASE REPORT

A 58-year-old woman with cirrhosis from hepatitis B virus was referred because of persistent anemia. She had not received blood transfusions. Laboratory data at admission included the following: Hb, 7.9 g/dL (normal: 13.5-17.6 g/dL); prothrombin time, 14.7 seconds (control, 11.3 seconds); and, international normalized ratio, 1.35 (0.9-1.2). EGD revealed gastric varices, which initially were suspected to be the cause of bleeding. Colonoscopy was negative for a source of bleeding. Barium contrast radiography of the small bowel was not obtained. Although surgery was indicated if the gastric varices were responsible for the anemia, active bleeding was not observed. Thus, it was necessary to rule out other possible sources of bleeding.

Capsule endoscopy identified a bleeding polyp in the mid small intestine, with blood present only in the intestinal segments distal to the polyp (Fig. 1A), findings that suggested that the polyp was responsible for the blood loss. Peroral double-balloon endoscopy disclosed a sessile polyp in the proximal ileum (Fig. 1B). Bleeding was induced by gentle contact between the endoscope and the polyp. Palpation revealed that the polyp was solid, thereby eliminating the possibility that the lesion was a small-bowel varix. After injection of saline solution into the base to elevate the polyp, it was removed by electrosurgical snare polypectomy. The resected polyp was eroded and was not covered by mucosa. Abnormal dilated vessels were present

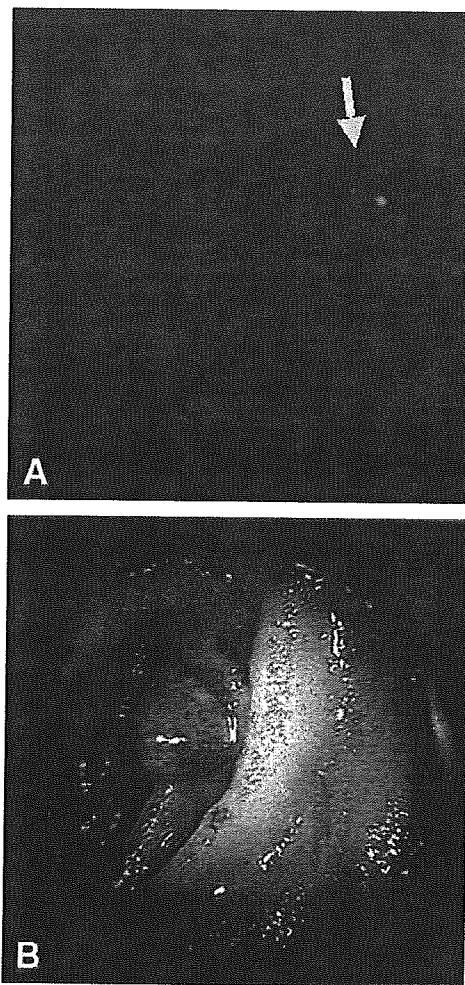


Figure 1. A, Capsule endoscopy image of polyp (arrow) in mid small intestine (arrow). B, Double-balloon enteroscopy image showing polyp with fresh blood nearby.

in the edematous intestinal tissue. Histopathologic evaluation revealed findings that suggested that the polyp was a type of angiodysplasia (Fig. 1C). The course of the patient after polypectomy was uneventful except for an episode of minor bleeding that resolved spontaneously. At 8 months' follow-up, there was no recurrence of the anemia.

DISCUSSION

Capsule endoscopy is a technically simple procedure that is extremely well tolerated by patients. However, tissue samples cannot be obtained with the capsule, which also

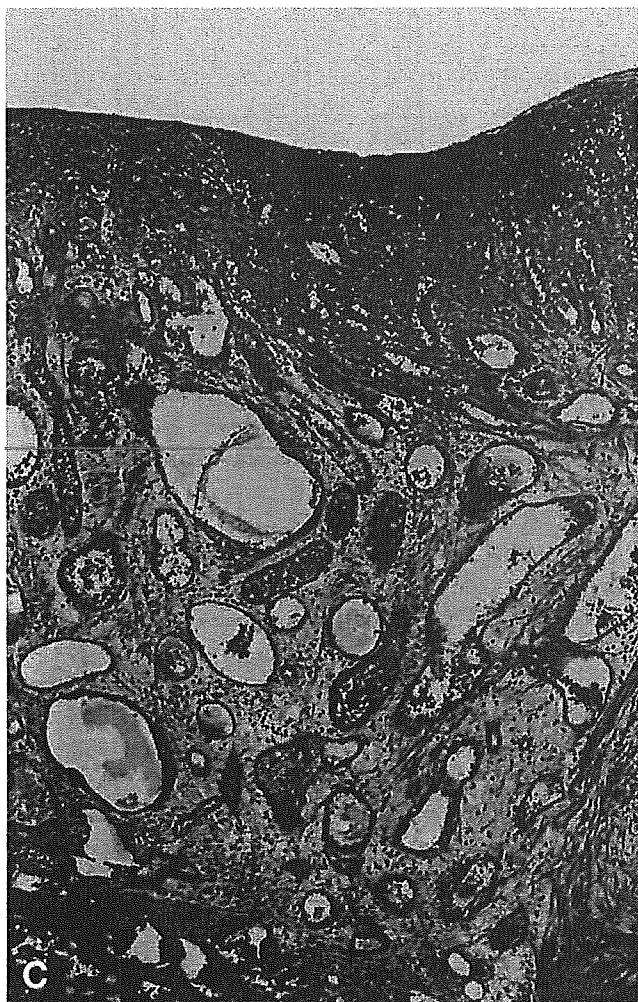


Figure 1. C, Photomicrograph of resected polyp, showing abnormal dilated vessels within edematous intestinal tissue (H&E, orig. mag. $\times 40$).

offers no possibility for therapeutic maneuvers. By contrast, double-balloon endoscopy is more labor intensive, but it enables “to and fro” observation, with controlled movement, tissue sampling, and various endoscopic therapeutic procedures. Thus, capsule endoscopy is suitable as an initial imaging study for small-bowel disorders, whereas double-

balloon endoscopy is desirable for the confirmation of small-bowel diseases, including direct observation in detail, tissue sampling, and therapeutic applications. The combination of capsule endoscopy and double-balloon endoscopy provides a powerful strategy for the diagnosis, as well as treatment of small-bowel diseases. As illustrated by the case presented, these procedures are highly complementary.

REFERENCES

1. Appleyard M, Fireman Z, Glukhovsky A, Jacob H, Shreiver R, Kadiramanathan S, et al. A randomized trial comparing wireless capsule endoscopy with push enteroscopy for the detection of small-bowel lesions. *Gastroenterology* 2000;119:1431-8.
2. Ell C, Remke S, May A, Helou L, Henrich R, Mayer G. The first prospective controlled trial comparing wireless capsule endoscopy with push enteroscopy in chronic gastrointestinal bleeding. *Endoscopy* 2002;34:685-9.
3. Costamagna G, Shah SK, Riccioni ME, Foschia F, Mutignani M, Perri V, et al. A prospective trial comparing small bowel radiographs and video capsule endoscopy for suspected small bowel disease. *Gastroenterology* 2002;123:999-1005.
4. Yamamoto H, Yano T, Kita H, Sunada K, Ido K, Sugano K. New system of double-balloon endoscopy for diagnosis and treatment of small intestinal disorders. *Gastroenterology* 2003;125:1556-7.
5. Yamamoto H, Sugano K. A new method of enteroscopy: the double-balloon method. *Can J Gastroenterol* 2003;17:273-4.
6. Rossini FP, Pennazio M. Small-bowel endoscopy. *Endoscopy* 2002;34:13-20.
7. May A, Nachbar L, Wardak A, Yamamoto H, Ell C. Double-balloon endoscopy: preliminary experience in patients with obscure gastrointestinal bleeding or chronic abdominal pain. *Endoscopy* 2003;35:985-91.

Department of Internal Medicine, Division of Gastroenterology, Jichi Medical School, Minamikawachi, Kawachi, Tochigi, Japan (HK, HY); Department of Endoscopy, Dokkyo University School of Medicine, Mibu, Shimotsuga, Tochigi, Japan (TN, KS); Department of Gastroenterology, Dokkyo University School of Medicine, Mibu, Shimotsuga, Tochigi, Japan (AT); Department of Internal Medicine, Division of Gastroenterology, Jichi Medical School, Minamikawachi, Kawachi, Tochigi, Japan (KS).

Reprint requests: Hiroto Kita, MD, Division of Gastroenterology, Jichi Medical School, Yakushiji, Kawachi, Tochigi 329-0498, Japan.

Copyright © 2005 by the American Society for Gastrointestinal Endoscopy 0016-5107/2005/\$30.00 + 0

PII: S0016-5107(05)00130-6

Gastric ulceration and perforation as a complication of a left ventricular assist device

Jason K. Hou, MD, Howard Hampel, MD, PhD, Frank J. Lukens, MD

Houston, Texas, USA

Left ventricular assist devices (LVAD) are being used increasingly as a bridge to cardiac transplantation for patients with extremely poor left ventricular function.^{1,2} The complications most commonly reported with the use

of this type of device are bleeding as a direct result of surgery, infections, and device failure. A case is presented here of a patient with an LVAD who developed upper-GI bleeding. At EGD, he was found to have a gastric ulcer

Long-Term Outcomes for Patients with Solitary Hepatocellular Carcinoma Treated by Laparoscopic Microwave Coagulation

Chiaki Kawamoto, M.D.^{1,2}

Kenichi Ido, M.D.³

Norio Isoda, M.D.¹

Masanori Hozumi, M.D.¹

Nobuhiko Nagamine, M.D.¹

Kazunori Ono, M.D.¹

Yoshiaki Sato, M.D.¹

Yuko Kobayashi, M.D.¹

Genta Nagae, M.D.¹

Kentaro Sugano, M.D.¹

¹ Division of Gastroenterology, Department of Internal Medicine, Jichi Medical School, Tochigi, Japan.

² The First Department of Internal Medicine, Saitama Medical Center, Saitama Medical School, Saitama, Japan.

³ Department of Endoscopy, Jichi Medical School, Tochigi, Japan.

Address for reprints: Chiaki Kawamoto, M.D., First Department of Internal Medicine, Saitama Medical Center, Saitama Medical School, 1981 Tsujido-machi, Kamoda, Kawagoe-shi, Saitama 350-8550, Japan; Fax: (011) 81-49-225-6649; E-mail: kawamoto@saitama-med.ac.jp, or kawamoto.c@vesta.ocn.ne.jp

Received March 23, 2004; revision received November 17, 2004; accepted November 17, 2004.

BACKGROUND. Although many reports on the treatment of hepatocellular carcinoma (HCC) by microwave coagulation have been published recently, none have incorporated data for the long-term therapeutic efficacy of laparoscopic microwave coagulation (LMC). In the current study, the efficacy of LMC was assessed.

METHODS. The authors performed LMC under local anesthesia in 69 previously untreated patients with solitary HCCs ≤ 4.0 cm in greatest dimension. The maximum diameter for the tumors averaged 22.6 ± 7.4 mm. Long-time survival rate was evaluated according to the size and histologic grade of the tumor.

RESULTS. The 5-year overall cumulative survival rate for the 69 patients was 63.9%. The 5-year overall survival rate for patients with well differentiated HCC was 78.9%, whereas patients with moderately or poorly differentiated HCC had a 5-year overall survival rate of 38.9%. The 5-year cumulative survival rate for patients with HCCs ≤ 2.0 cm in diameter was 76.0%, and 56.3% for patients with HCCs > 2.0 cm. Twelve patients (17.4%) showed local tumor recurrence during the follow-up period. Local tumor recurrence was observed in 6 of 21 patients with moderately or poorly differentiated HCCs (28.6%) and in 6 of 40 patients with well differentiated HCCs (15.0%). The 3-year cancer-free survival rate for patients with well differentiated HCC was 44.4%, whereas it was 12.2% for patients with moderately or poorly differentiated HCC.

CONCLUSIONS. A major factor that influenced outcome in LMC was tumor cell differentiation. LMC procedures were best suited for treatment of well differentiated HCC. *Cancer* 2005;103:985-93. © 2005 American Cancer Society.

KEYWORDS: microwave coagulation, hepatocellular carcinoma, laparoscopy, laparoscopic ultrasonography.

The most frequently used treatments for hepatocellular carcinoma (HCC) are surgical resection, transcatheter arterial embolization (TAE), and percutaneous ethanol injection therapy (PEI).¹ Surgical resection is the major curative therapy, although its indication is limited because of impaired liver function due to underlying cirrhosis.

Recently, laparoscopic and thoracoscopic surgeries have been developed and are being widely used. With the concomitant development of laparoscopic ultrasonography (LUS),² laparoscopic microwave coagulation (LMC) can now be performed both safely and precisely. It has been reported that LMC can be used for HCCs > 2.0 cm in diameter.³ However, there are no available data on the long-term therapeutic efficacy of LMC. Published reports have suggested that tumor cell differentiation is associated closely with tumor recurrence and prognosis.⁴⁻⁹ In the current study, we evaluated the long-

term effect of LMC in patients with solitary HCCs ≤ 4.0 cm, with regard to the size and histologic grade of the tumor.

MATERIALS AND METHODS

Patients

Between December 1993 and February 1999, 87 patients with solitary HCCs ≤ 4.0 cm were admitted to our hospital and enrolled in the study. Eighteen patients were excluded from the study. Reasons for exclusion included adhesions from previous surgeries involving the epigastric area that prevented the LUS probe from being able to access the liver surface ($n = 7$), HCC adherence to the large intestine ($n = 1$), the large blood vessels or bile ducts that prevented the microwave electrode from puncturing the tumor ($n = 9$), and the inability to perform laparoscopic therapy due to subcutaneous emphysema ($n = 1$). LMC was performed successfully on the other 69 patients.

Before the procedure, coagulation parameters were assessed in all patients. Treatment was not performed in patients with a platelet count $< 30,000/\text{mm}^3$ or with $< 40\%$ prothrombin activity.

The study comprised 45 men and 24 women with a mean age of 64.4 ± 8.9 years (range, 44–82 years). LMC was the initial treatment for all 69 patients. All patients had cirrhosis. Thirty-six patients were classified as having Child–Pugh Class A liver function, 28 patients as having Child–Pugh Class B, and 5 patients as having Child–Pugh Class C. Of the 69 patients, 6 patients were positive for the hepatitis B surface antigen (HBsAg), 56 patients were positive for the hepatitis C virus (HCV) antibody, and 2 patients had a combination of both the HBsAg and the HCV antibody. The remaining five patients were negative for both the HBsAg and the HCV antibody.

Fifty-three HCCs were located in the right lobe and 16 HCCs were found in the left lobe. Thirty-nine HCCs were located near the diaphragm in segments 7 and 8, as defined by Couinaud. The segmental locations of the remaining 30 lesions included 7 HCCs located in segment 2, 6 in segment 3, 4 in segment 4, 7 in segment 5, and 6 in segment 6. In 24 of the 69 patients, HCCs were observed on the hepatic surface. In the remaining 45 patients, LUS revealed tumors that were situated deep within the hepatic parenchyma. LUS measurements indicated that the tumors averaged 22.6 ± 7.4 mm in maximum diameter (range, 8–40 mm).

In all 69 patients, ultrasonography (US) and dynamic computed tomography (CT) scans were performed before LMC. US successfully detected all of the tumor nodules. Dynamic CT scans revealed 57 of 69 tumor nodules, but failed to detect 12 HCC nodules. In

these 12 patients, selective hepatic angiography revealed tumor blush in 5 patients, but failed to detect 7 HCC nodules. These 7 patients were diagnosed by biopsy.

Biopsy with a 21-G Majima needle (Top Co., Tokyo, Japan) was used for histologic confirmation of 61 tumors before LMC. Biopsy was not performed in 8 patients in whom CT scan or angiography findings consistently indicated the hallmarks of HCC.

All procedures were explained thoroughly to the patients, and written informed consent was obtained from each patient and one family member.

Microwave Coagulation System

The microwave was generated by a magnetron in a microwave generator (Microtaze OT-110M, HS-15M; Azwell Co., Osaka, Japan). The frequency of the microwave used was 2450 MHz. The probe used for LMC was a percutaneous microwave electrode for deep coagulation (TMD-16CB-10/250; Azwell). The microwave electrode was 1.6 mm thick and 25 cm long. The needle electrode consisted of a stainless steel needle with a 2.0-cm long monopolar electrode at the tip. Microwaves were irradiated between the external and internal electrodes, which resembled magnetic dipoles.

Laparoscopic Microwave Coagulation

We performed LMC with local anesthesia. For premedication, 15 mg pentazocine and 50 mg hydroxyzine were injected intramuscularly. An intravenous route was established and local anesthesia was provided by 0.5% lidocaine hydrochloride (40–60 mg). If pain was reported, 15 mg pentazocine or 5–10 mg diazepam was administered intravenously.

Patients were in a supine position with their heads up. After local anesthesia, pneumoperitoneum was established using the Veres needle technique. Air was used for the pneumoperitoneum and pressure was kept below 8 mmHg with the use of an automatic insufflator (PELVI-PNEU; Wisap, Munich, Germany). The first trocar was inserted into the upper left umbilical region, similar to the procedure for routine laparoscopy. A charge coupled device camera (OTV-SX; Olympus, Tokyo, Japan) was used for visualization of the liver and guidance of the microwave therapy. Using the first trocar, the surface of the liver was examined. After a thorough observation of the entire liver surface by changing the patient's position to view all aspects of the liver, the second trocar was inserted to a point that was one-third of the way between the umbilicus and the right anterosuperior iliac crest.

An LUS probe (REF-704LA; Toshiba Medical, Tokyo, Japan) was inserted through the second trocar.

The LUS probe was linear and the frequency used was 7.5 MHz, and the effective ultrasonic visual field was 30 mm. A real-time linear-array scanner (SSA-260A; Toshiba Medical) was used.

HCCs on the hepatic surface were observed under direct visualization, and the inside of the tumor was examined by LUS. The treatment was performed using both laparoscopic observation and LUS.

For the treatment of deep HCCs, the insertion route for the electrode was predetermined by LUS. Subsequently, a guide needle (Silux Co., Saitama, Japan) was inserted in the vicinity of the tumor under LUS guidance. A 14-G guide sheath (Silux) for the microwave electrode was inserted into the liver using a guide needle. After the inner needle of the guide sheath was removed, the microwave electrode was inserted into the liver through the outer needle of the guide sheath to place the electrode in the tumor area.

Microwave irradiation was administered for 60 seconds at a power setting of 60 W per pulse. During irradiation, the LUS probe was positioned adjacent to the microwave electrode to monitor the effectiveness of the tumor coagulation. Gauze soaked with cold physiologic saline solution was placed at the insertion site to protect the skin against burns caused by microwave irradiation. The microwave electrode was rotated during microwave irradiation to avoid adherence of tissue to the tip of the microwave electrode.

Microwave irradiation was applied initially from the dorsal cephalad site to the ventral caudal site across the entire tumor, including the area approximately 5 mm outside the tumor margin. Care was taken to secure the extension of microwave irradiation to the whole tumor.

When a bile duct and a portal vein are included in the coagulation area, LMC must be done carefully. We maintained a distance of > 8 mm between the electrode and the bile duct or portal vein. We treated HCC that was located along large portal tracts by using a combination of microwave coagulation and local ethanol infusion in the periportal area to prevent complications.

After irradiation, the ultrasound image showed a highly echogenic area with an acoustic shadow. At each session, multiple electrode insertions were performed on the tumor. Using LUS, the electrode was withdrawn and inserted into other areas of the tumor and microwave irradiation was repeated until the entire tumor showed highly echogenic changes. We tracked both changes in the ultrasonograms immediately after coagulation, as well as the distribution of the traces of the routes of needle punctures observed in the ultrasound images of the tumor. Because the diameter of the coagulation area produced by a single

coagulation is known, the needle traces are useful as objective markers for evaluation of the therapeutic effect.

It is difficult to distinguish necrotic lesions from viable residual lesions by means of B-mode ultrasonic images. Therefore, we used color Doppler imaging to determine in real time the extent of tissue necrosis induced by LMC. HCC treatments were judged to be successful if there was disappearance of the blood flow to the HCC.¹⁰

When the electrode and the outer sheath of the guide were removed, microwave irradiation was performed at a setting of 30 W for several seconds to prevent bleeding from the hepatic surface of the puncture track. Hemostasis was confirmed carefully after LMC. Although there has been no clear evidence of the beneficial effect of prophylactic administration of antibiotics for LMC, standard doses of broad-spectrum antibiotics were administered for 3 days postoperatively.

Evaluation of Therapeutic Efficacy and Follow-Up

Postoperative dynamic CT scans confirmed the effectiveness of coagulation. The findings of dynamic CT scans were considered negative if a completely non-enhancing area with a diameter equal to or larger than the treated tumor was shown at the previous site of the tumor. For HCCs that were not previously detectable by CT scans, postoperative selective hepatic angiography was performed within 10 days after LMC. The findings of hepatic angiography were considered negative if all signs of neoplastic vascularization completely disappeared. HCC was considered completely eradicated when the area treated by LMC showed low density and failed to enhance with a contrast CT scan and/or when the tumor blush disappeared on an angiogram.

Serologic values including leukocyte counts, hemoglobin level, biochemical parameters (levels of total bilirubin, alkaline phosphatase, electrolytes, creatinine, and alanine aminotransferase), and prothrombin activity were measured before treatment and at 24 hours, 48 hours, and 1 month posttreatment. The extent of the coagulated area, the activities of daily living after LMC, and the development of complications during and after LMC were recorded.

To detect tumor recurrence as early as possible, the follow-up protocol after LMC included performance of US every 3 months, α -fetoprotein (AFP) and des- γ -carboxy prothrombin determinations every month, and dynamic CT or magnetic resonance imaging scans every 6 months. Tumor nodules that appeared at the margin of treatment or enlargement of the treated tumor were defined as local tumor recur-

rence. Tumor nodules in other locations were considered new.

Causes of death were determined during the follow-up period. Patient death secondary to advanced carcinoma or from cachexia was considered to be a cancer death.

Treatment of Tumor Recurrences

In patients with a single recurrent nodule, we performed local treatments including PEI, microwave coagulation, or radiofrequency ablation (RFA). Patients with multiple recurrent nodules received TAE only or TAE in combination with local treatments.

Statistical Analysis

Data are expressed as the mean \pm standard deviation. Cumulative survival rates and cumulative cancer-free survival rates were calculated from the time of the first treatment using the Kaplan-Meier method. Differences in survival and cancer-free survival were analyzed with the log-rank test. Significant differences in levels of AFP were examined by *t* test. $P < 0.05$ was considered to be statistically significant.

RESULTS

At the time of analysis, the median follow-up time was 54 ± 24.3 months (range, 9–100 months). None of the patients dropped out during the follow-up period.

Treatment Efficacy

Of the 69 patients, 64 were treated successfully with LMC alone. Five patients received a combination of LMC and PEI or laparoscopic ethanol injection (LEI) because the presence of large vessels near the tumor restricted LMC. On average, LMC was administered for 15.8 ± 13.2 minutes (range, 2–61 minutes). The mean number of electrode placements in all patients was 8.4 ± 5.8 times (range, 2–30 times). For HCCs ≤ 2.0 cm in diameter, the number of electrode placements was 4.6 ± 2.2 times (range, 2–11 times). For HCCs > 2.1 cm but ≤ 3.0 cm, the number of electrode placements was 9.7 ± 6.1 times (range, 4–30 times). For HCCs > 3.1 cm but ≤ 4.0 cm, the number of electrode placements was 13.5 ± 5.6 times (range, 9–25 times). All patients began oral intake on the evening of the treatment day, or on the following day. The mean hospital stay after LMC was 9.8 ± 3.7 days (range, 3–22 days). This period included hospitalization for abdominal CT scans and/or angiography, which were performed to evaluate the efficacy of LMC.

Posttreatment dynamic CT scans for all patients showed a completely nonenhancing area, with a diameter equal to or larger than the diameter of the treated tumor in 57 nodules with a positive pretreat-

ment CT scan pattern, and a nonenhancing area in the 12 nodules with a negative pretreatment CT scan pattern. The 5 patients whose pretreatment angiography had shown tumor blush demonstrated disappearance of the tumor blush.

The mean pretreatment AFP concentration was 739.9 ± 2925.0 ng/mL (range, 3–16,490 ng/mL), which decreased to 296.8 ± 1183.0 ng/mL (range, 2–6075 ng/mL) 1 month after LMC ($P = 0.0405$). The pretreatment AFP level was 83.7 ± 124.0 ng/mL (range, 4–453 ng/mL) in patients who had no tumor recurrence or who had a longer disease-free interval, which decreased to 13.5 ± 10.0 ng/mL (range, 4–33 ng/mL) at the most recent follow-up ($P = 0.0466$).

During the follow-up period, 54 patients showed local tumor recurrence or new HCC. AFP levels were elevated in 33 of these 54 patients. In these 33 patients, AFP levels decreased to 48.4 ± 61.2 ng/mL (range, 4–212 ng/mL), before increasing to 1113.1 ± 2886.2 ng/mL (range, 7–14,920 ng/mL) at the time of tumor recurrence ($P = 0.0396$).

Complications during and after Laparoscopic Microwave Coagulation

All patients resumed ambulation on the day after treatment. All patients were febrile with temperatures of approximately 38 °C, but became afebrile 2 or 3 days after LMC.

No fatal or major complications associated with LMC were observed in the current study. Most patients reported a heat sensation in the upper abdominal region. One-half of them reported mild abdominal pain during the microwave irradiation that required analgesia. This pain, however, was transient and not severe. None of the patients refused to continue the LMC. No patients required general anesthesia. Three minor complications occurred and included abdominal wall bleeding, pleural effusion, and subcutaneous emphysema. None of these complications required specific treatment. None of the patients reported any postoperative intraabdominal bleeding.

Survival Rates

The 3 and 5-year overall cumulative survival rates for the 69 patients were 80.0% and 63.9%, respectively (Fig. 1). The cumulative survival rates for patients with Child-Pugh Class A liver function were 88.9% at 3 years and 71.1% at 5 years, 77.8% at 3 years and 61.7% at 5 years for patients with Child-Pugh Class B, and 50.0% at 3 years for patients with Child-Pugh Class C (Fig. 2).

The cumulative survival rates for patients with HCCs ≤ 2.0 cm in diameter were 93.2% at 3 years and 76.0% at 5 years. For patients with HCCs > 2.0 cm, the

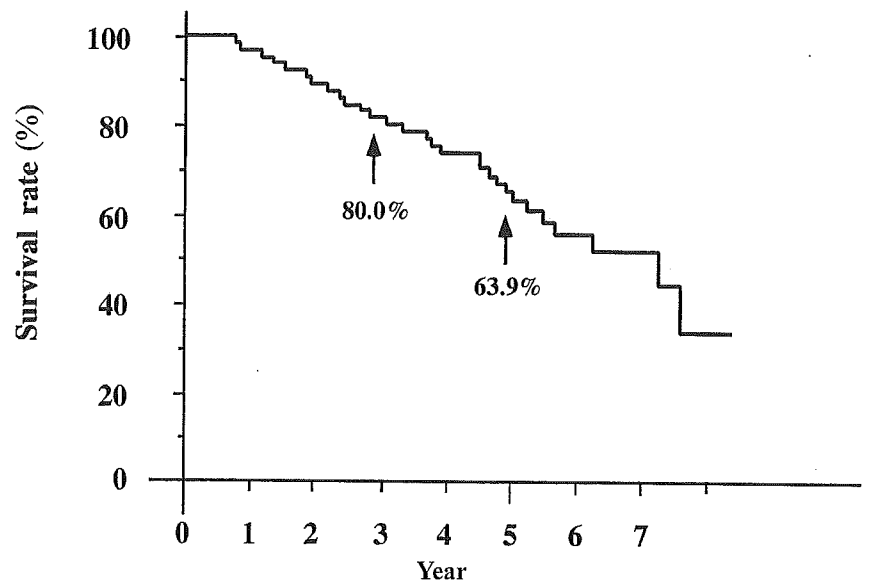


FIGURE 1. The overall cumulative survival rates for the 69 patients were 80.0% at 3 years and 63.9% at 5 years. The mean observation period was 54 ± 24.3 months (range, 9–100 months).

cumulative survival rates were 72.0% at 3 years and 56.3% at 5 years. The difference in cumulative survival rates between the patients with HCCs ≤ 2.0 cm and HCCs > 2 cm was not statistically significant ($P = 0.2108$, Fig. 3).

The 5-year overall survival rate for patients with well differentiated HCCs who received LMC was 78.9%, whereas patients with moderately or poorly differentiated HCCs who received LMC had a 5-year overall survival rate of 38.9%. The difference between the 2 histologic groups was statistically significant ($P = 0.019$, Fig. 4).

Cancer-Free Survival Rates

The overall cancer-free survival rate was 37.4% at 3 years and 17.8% at 5 years. The 3-year cancer-free

survival rate for patients with well differentiated HCC was 44.4%, whereas that for patients with moderately or poorly differentiated HCC was 12.2%. This difference was statistically significant ($P = 0.0043$; Fig. 5).

Tumor Recurrence Rates

During the follow-up period, 12 patients (17.4%) developed local tumor recurrence. The cumulative tumor recurrence rates were 18.9% at 3 years and 20.0% at 5 years. Of 21 patients with moderately or poorly differentiated HCCs, 6 (28.6%) developed local tumor recurrence, and 6 of 40 patients with well differentiated HCCs (15.0%) developed local tumor recurrence. The size of tumors in the 12 patients who developed local tumor recurrence was 25.7 ± 6.6 mm (range,

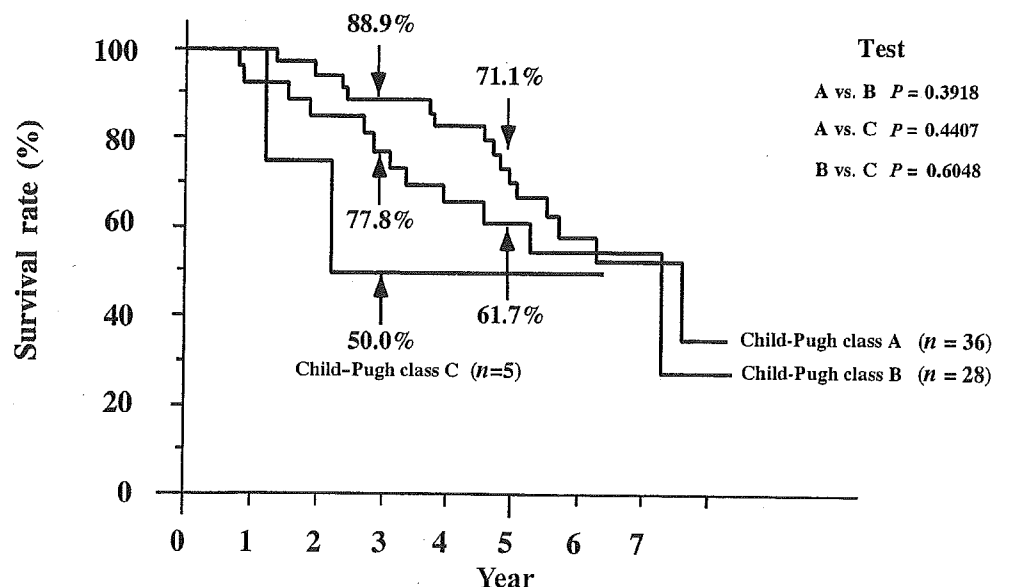


FIGURE 2. The cumulative survival rates for patients with Child-Pugh Class A liver function were 88.9% at 3 years and 71.1% at 5 years, 77.8% at 3 years and 61.7% at 5 years for patients with Child-Pugh Class B liver function, and 50.0% at 3 years for patients with Child-Pugh Class C liver function.

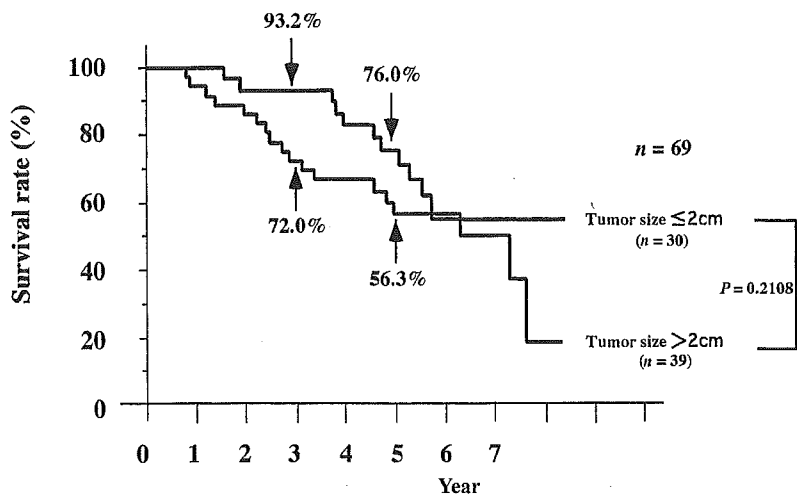


FIGURE 3. Cumulative survival rates according to tumor size. The cumulative survival rates for patients with hepatocellular carcinomas (HCCs) ≤ 2.0 cm were 93.2% at 3 years and 76.0% at 5 years. For patients with HCCs > 2.0 cm, the rates were 72.0% at 3 years and 56.3% at 5 years. The difference between the patients with HCCs ≤ 2 cm and the patients with HCCs > 2 cm was not statistically significant ($P = 0.2108$).

13–34 mm). The tumor size without local tumor recurrence was 21.9 ± 7.4 mm (range, 8–40 mm). The difference in tumor size between these 2 groups was not statistically significant ($P = 0.1084$). Patients with recurrent tumors received LMC ($n = 4$), TAE ($n = 4$), LEI ($n = 1$), RFA ($n = 2$), and hepatectomy ($n = 1$).

Despite the complete eradication of the initial carcinoma in all patients, unfortunately, new HCCs developed in different liver subsegments or in multiple liver subsegments in 49 patients (71.0%). A single tumor developed in 23 patients, 2 tumors in 7 patients, 3 tumors in 4 patients, and > 4 tumors in 15 patients. The cumulative heterotopic recurrence rates in this group were 55.6% at 3 years and 78.3% at 5 years. Twenty-four patients with recurrent tumors received TAE, 11 patients received PEI, 1 patient received LEI, 8 patients received LMC, 2 patients received percutane-

ous microwave coagulation (PMC), 2 patients received RFA, and 1 patient received surgical resection.

Causes of Death

At the most recent follow-up, 40 of the 69 patients were still alive. Of the 29 patients who died, 10 died of hepatic failure secondary to cirrhosis progression 36.4 ± 21.6 months (range, 14–91 months) after LMC, 13 died of HCC progression that involved the entire liver, 3 died as a result of ruptured esophageal varices, 1 died due to ileus, and 2 due to pneumonia. Of the 13 patients who died of HCC progression, 9 had moderately or poorly differentiated HCC.

DISCUSSION

The survival of patients after hepatic resection for HCC has improved over the last decade. Although

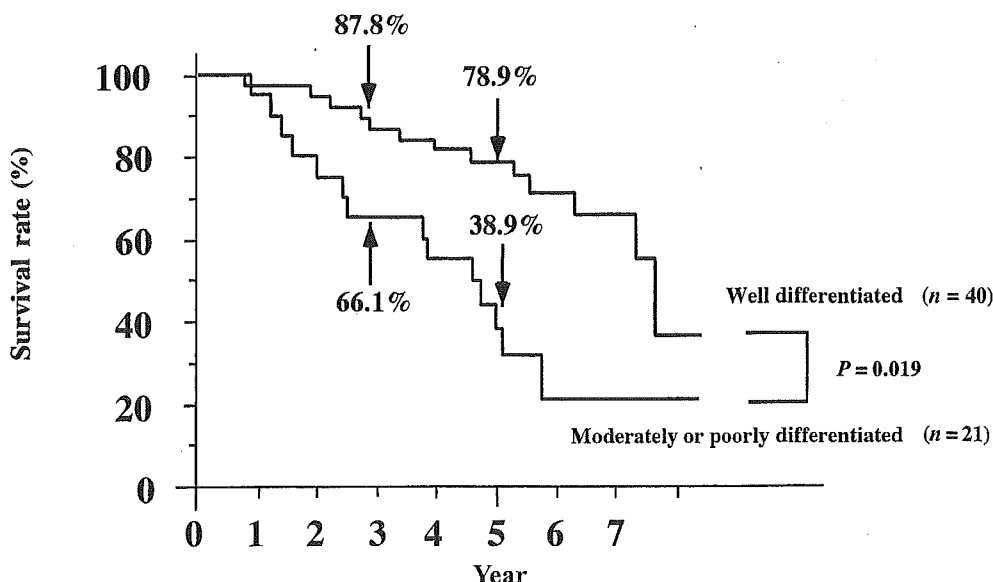
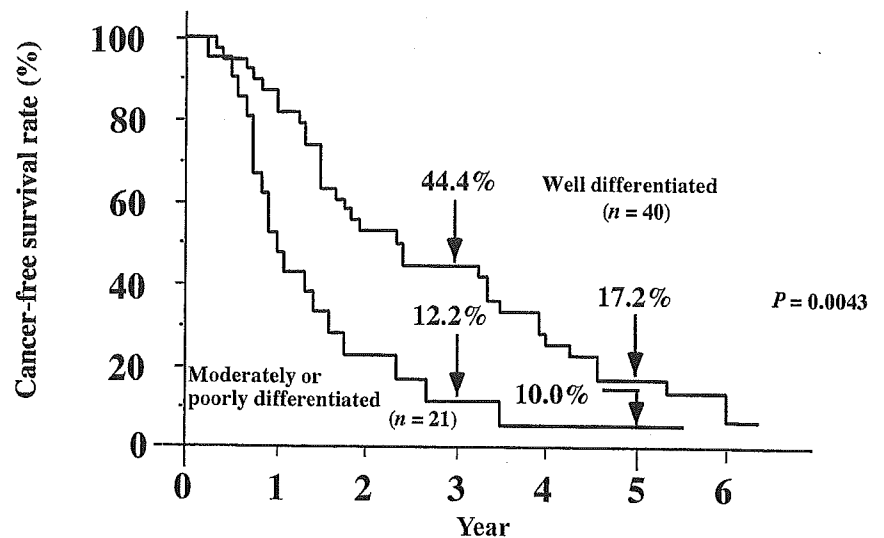


FIGURE 4. Cumulative survival rates according to histologic grade. The 5-year overall survival rate for patients with well differentiated HCC treated with laparoscopic microwave coagulation (LMC) was 78.9%, whereas the 5-year overall survival rate for patients with moderately or poorly differentiated HCC treated with LMC was 38.9%. The difference between the 2 histologic groups was statistically significant ($P = 0.019$).

FIGURE 5. Overall cancer-free survival rates according to histologic grade. The 3-year cancer-free survival rate for patients with well differentiated HCC was 44.4%, whereas that for patients with moderately or poorly differentiated HCC was 12.2%. This difference was statistically significant ($P = 0.0043$).



hepatic resection is the standard treatment for HCC, there are a few problems that limit its efficacy and utility. First, there is a high incidence of postoperative HCC recurrence because of the association between HCC and cirrhosis (for patients who have HCV infection). Second, these encouraging surgical results only can be achieved in patients with preserved liver function. Decompensated patients or patients with moderate liver dysfunction do not benefit from the surgery, and, therefore, PEI, PMC, and RFA¹¹ may be indicated. Furthermore, orthotopic or living-related liver transplantation is an effective treatment for early-stage, unresectable HCC in patients with cirrhosis.¹²

In Japan, PEI generally has been used as a potentially curative treatment and is performed mainly in patients with poor liver function, with ≤ 3 lesions, and with tumors ≤ 3 cm in diameter. According to the latest report by the Liver Cancer Study Group of Japan, the 1, 2, 3, and 5-year survival rates of 21,025 patients treated by hepatectomy were 84.4%, 74.1%, 64.9%, and 47.9%, respectively, whereas the 1, 2, 3, and 5-year survival rates of 3757 patients treated by PEI were 91.7%, 80.1%, 67.2%, and 45.3%, respectively.¹ Patients treated with PEI have long-term survival rates that are comparable to those of patients who receive hepatectomy.

The effectiveness of PEI for small HCCs has been established. However, it is difficult to achieve sufficient tumor necrosis with only one PEI session. The required volume of ethanol for effective treatment may necessitate repeated injections, resulting in long hospital stays.^{13,14} We have been performing LEI, as ethanol can be injected into a wide area of the tumor and the LEI treatments often can be completed in one session.¹⁵ Besides the efficacy of the LEI procedure, an additional advantage is the shortened hospital stay.

Unfortunately, there are significant problems inherent with the PEI and LEI procedures. For example, it is sometimes difficult to achieve complete necrosis when tumors are > 3.0 cm in diameter. The distribution of the ethanol after injection is not homogeneous due to the presence of the capsule and intracapsular septa. In addition, some of the injected ethanol immediately flows into the neighboring vessels.

To overcome the disadvantages of ethanol injection, microwave coagulation therapy was developed to induce more complete tumor necrosis from local treatments.¹⁶ Unlike PEI, microwave coagulation is not affected by the capsule or intracapsular septa. If the electrode reaches the target site, an ovoid area of necrosis will be obtained.¹⁷

Recently, many reports on the treatment of HCC by microwave coagulation have been published. Some reports have shown that intraoperative microwave coagulation with general anesthesia can treat nonresectable HCCs.¹⁸ Microwave coagulation is derived from microwave hepatectomy.¹⁹ Therefore, intraoperative microwave coagulation using a hepatectomy (superficial) electrode is a direct result of this continued development.^{16,18} Generally, however, performing microwave coagulation by laparotomy negates the advantages of microwave coagulation, which is a much less invasive nature. Therefore, we consider that intraoperative microwave coagulation is only justified when percutaneous or endoscopic microwave coagulation is difficult. However, in reality, HCC usually seems to be treated by using open surgery for resectable lesions, combined with microwave coagulation for residual tumors.¹⁸ An advantage of this technique is that the route of the puncture can be selected with considerable freedom.²⁰ Regardless of the treatment that is selected, the tumor recurrence rate of HCC at

other sites is characteristically high. If adhesion develops intraperitoneally after the initial treatment, subsequent laparoscopic procedures become difficult. Therefore, the initial treatment approach must be considered carefully so that as wide a selection as possible is available for any subsequent treatments that are required.

PMC performed with local anesthesia also has been reported.^{17,21} PMC with microwave irradiation at 60 W for 120 seconds was shown to coagulate an elliptic area with maximal and minimal diameters of $2.4 \text{ cm} \pm 0.4 \text{ cm}$ and $1.6 \text{ cm} \pm 0.3 \text{ cm}$,¹⁷ respectively. Because the area of coagulation is limited, complete necrosis is difficult to achieve in a large tumor. Several repetitions of PMC are thus required. Seki et al.¹⁷ performed an average of 2.9 applications (range, 1–4 applications) of PMC on 18 patients with HCCs that had maximal diameters ranging from 9 mm to 20 mm. PMC was effective for the small HCCs, but it could not be applied as a single treatment for HCCs that had maximal diameters $> 2.0 \text{ cm}$. Therefore, the technique reported by Seki et al.¹⁷ should be applied only to tumors $\leq 2.0 \text{ cm}$.

Because the contour of the tumor becomes indistinct immediately after the initial coagulation, repeated PMC may not achieve adequate coagulation of large tumors. Therefore, the therapeutic usefulness of PMC for HCCs $> 2.0 \text{ cm}$ remains controversial.

Conversely LMC can be used to treat HCCs $> 2.0 \text{ cm}$. In a series of studies done by our group, we have found that LMC is very effective even in HCCs that measure 4.0 cm in diameter.³ Although LMC has been used to treat HCC nonsurgically, its efficacy has yet to be adequately evaluated. Therefore, we undertook the goal of assessing the therapeutic usefulness of LMC.

In our study of 69 patients, the results of LMC appear highly satisfactory in comparison to hepatic resection, PEI, or PMC, particularly for patients with Child–Pugh Class A and B liver functions.^{1,22} We found that the 5-year cumulative survival rate in patients with HCCs $> 2.0 \text{ cm}$ was 56.3%. Although the size of the tumor was the important factor affecting survival, LMC was effective for treatment of HCCs $> 2.0 \text{ cm}$ in diameter.

The degree of tumor cell differentiation has been shown to be significantly associated with overall tumor recurrence.²³ There is a significant difference in the cumulative survival rate between patients with well differentiated and with moderately or poorly differentiated HCCs. A well differentiated small HCC is a good indication for use of PEI, PMC, and LMC because of the low incidence of intracapsular or extracapsular invasion, vascular invasion, and intrahepatic metasta-

ses, including microscopic metastatic lesions around the main tumor.^{4,22}

In contrast, moderately or poorly differentiated HCCs have a high incidence of microscopic metastases adjacent to the primary tumor.⁴ Insufficient coagulation can cause disseminated metastasis, thus leading to tumor recurrence.²⁴ We attempted to produce extensive necrosis not only of the tumor lesion but also of the surrounding noncancerous parenchymal margin.

Although tumors can be treated in situ with a minimal loss of surrounding noncancerous parenchyma by inserting the electrode directly into the lesion,^{16,17} our results suggest that occult metastatic lesions persisting in the surrounding parenchyma may lead to an earlier and higher rate of local tumor recurrence. Furthermore, laparoscopic guidance facilitates secure hemostasis due to the ability to directly visualize the puncture site. Conversely, because PMC is performed with extracorporeal US, a confirmation of hemostasis cannot be assured.

The other characteristic of our procedure is that it is performed with LUS.^{2,25} With this technique, not only HCCs on the hepatic surface, but also HCCs located deep within the liver can be treated with a high degree of reliability. In 45 (65.2%) of the 69 patients, treatment would have been impossible without LUS because the HCCs were located deep within the liver. In addition, although all of our patients demonstrated some degree of cirrhosis, no liver failures occurred after treatment, indicating the safety of LMC.

Our technique also allows earlier recovery compared with the recovery time for conventional hepatic resection. The mean period of the postoperative stay (9.8 ± 3.7 days) was similar to that seen after the laparoscopic cholecystectomies that have been performed in our institution.²⁶ The recovery from LMC was also as fast as that documented to occur for laparoscopic cholecystectomy.

In conclusion, LMC can be used as an initial treatment for patients with solitary HCCs $\leq 4.0 \text{ cm}$. However, this technique is better indicated for use in well differentiated HCCs.

Recently, RFA, which was developed in the United States, has been introduced in Japan and a number of facilities are utilizing this therapeutic technique.^{11,27,28} With the appearance of newer RFA devices, the future role of microwave coagulation in treatment protocols is unclear. We believe there is a benefit in using LMC versus percutaneous RFA in the treatment of HCCs $> 3.0 \text{ cm}$ from the point of view that the treatments can be done in only 1 session. However, as with RFA use, there have been similar problems that have occurred when using the LMC approach. Therefore, pro-

spective randomized studies for microwave coagulation and RFA need to be performed using the same approach, to precisely compare these two therapeutic techniques.^{29,30}

REFERENCES

1. The Liver Cancer Study Group of Japan. Survey and follow-up study of primary liver cancer in Japan—Report 14. *Acta Hepatol Jap.* 2000;41:799–811.
2. Ido K, Nakazawa Y, Isoda N, et al. The role of laparoscopic US and laparoscopic US-guided aspiration biopsy in the diagnosis of multicentric hepatocellular carcinoma. *Gastrointest Endosc.* 1999;50:523–526.
3. Ido K, Isoda N, Kawamoto C, et al. Laparoscopic microwave coagulation therapy for solitary hepatocellular carcinoma performed under laparoscopic ultrasonography. *Gastrointest Endosc.* 1997;45:415–420.
4. Kanai T, Hirohashi S, Upton MP, et al. Pathology of small hepatocellular carcinoma. A proposal for a new classification. *Cancer.* 1987;60:810–819.
5. The Liver Cancer Study Group of Japan. Primary liver cancer in Japan. Clinicopathological features and results of surgical treatment. *Ann Surg.* 1990;211:277–287.
6. Arii S, Tanaka J, Yamazoe Y, et al. Predictive factors for intrahepatic recurrence of hepatocellular carcinoma after partial hepatectomy. *Cancer.* 1992;69:913–919.
7. Haratake J, Takeda S, Kasai T, Nakano S, Tokui N. Predictable factors for estimating prognosis of patients after resection of hepatocellular carcinoma. *Cancer.* 1993;72:1178–1183.
8. Kitamoto M, Nakanishi T, Kira S, et al. The assessment of proliferating cell nuclear antigen immunohistochemical staining in small hepatocellular carcinoma and its relationship to histologic characteristics and prognosis. *Cancer.* 1993;72:1859–1865.
9. Yamashita Y, Matsukawa T, Arakawa A, Hatanaka Y, Urata J, Takahashi M. US-guided liver biopsy: predicting the effect of interventional treatment of hepatocellular carcinoma. *Radiology.* 1995;196:799–804.
10. Takeuchi H, Tamura R, Baba T, et al. Real-time evaluation of the effectiveness of microwave coagulation therapy for hepatocellular carcinoma using color Doppler imaging. *Acta Med Okayama.* 1998;52:255–260.
11. Rossi S, Buscarini E, Garbagnati F, et al. Percutaneous treatment of small hepatic tumors by an expandable RF needle electrode. *AJR Am J Roentgenol.* 1998;170:1015–1022.
12. Mazzaferro V, Regalla E, Doci R, et al. Liver transplantation for the treatment of small hepatocellular carcinoma in patients with cirrhosis. *N Eng J Med.* 1996;334:693–699.
13. Shiina S, Tagawa K, Niwa Y, et al. Percutaneous ethanol injection therapy for hepatocellular carcinoma: results in 146 patients. *AJR Am J Roentgenol.* 1993;160:1023–1028.
14. Shiina S, Hata Y, Niwa Y, et al. Multiple-needle insertion method in percutaneous ethanol injection therapy for liver neoplasms. *Gastroenterol Jpn.* 1991;26:47–50.
15. Kawamoto C, Ido K, Isoda N, et al. Prognosis of small hepatocellular carcinoma after laparoscopic ethanol injection. *Gastroenterol Endosc.* 1999;50:214–220.
16. Saitsu H, Mada Y, Taniwaki S, et al. Investigation of microwave coagulo-necrotic therapy for 21 patients with small hepatocellular carcinoma less than 5 cm in diameter [in Japanese with English abstract]. *Nippon Geka Gakkai Zasshi (J Jpn Surg Soc).* 1993;94:359–365.
17. Seki T, Wakabayashi M, Nakagawa T, et al. Ultrasonically guided percutaneous microwave coagulation therapy for small hepatocellular carcinoma. *Cancer.* 1994;74:817–825.
18. Hamazoe R, Hirooka Y, Ohtani S, Katoh T, Kaibara N. Intraoperative microwave tissue coagulation as treatment for patients with nonresectable hepatocellular carcinoma. *Cancer.* 1995;75:794–800.
19. Tabuse K. A new operative procedure of hepatic surgery using a microwave tissue coagulator. *Arch Jpn Chir.* 1979;48:160–172.
20. Sato M, Watanabe Y, Ueda S, et al. Microwave coagulation therapy for hepatocellular carcinoma. *Gastroenterology.* 1996;110:1507–1514.
21. Murakami R, Yoshimatsu S, Yamashita Y, Matsukawa T, Takahashi M, Sagara K. Treatment of hepatocellular carcinoma: value of percutaneous microwave coagulation. *AJR Am J Roentgenol.* 1995;164:1159–1164.
22. Seki T, Wakabayashi M, Nakagawa T, et al. Percutaneous microwave coagulation therapy for patients with small hepatocellular carcinoma. *Cancer.* 1999;85:1694–1702.
23. Kumada T, Nakano S, Takeda I, et al. Patterns of recurrence after initial treatment in patients with small hepatocellular carcinoma. *Hepatology.* 1997;25:87–92.
24. Asahara T, Nakahara H, Fukuda T, et al. Percutaneous microwave coagulation therapy for hepatocellular carcinoma. *Hiroshima J Med Sci.* 1998;47:151–155.
25. Hozumi M, Ido K, Hiki S, et al. Easy and accurate targeting of deep-seated hepatic tumors under laparoscopy with a forward-viewing convex-array transducer. *Surg Endosc.* 2003;17:1256–1260.
26. Ido K, Suzuki T, Kimura K, et al. Laparoscopic cholecystectomy in the elderly: analysis of pre-operative risk factors and post operative complications. *J Gastroenterol Hepatol.* 1995;10:517–522.
27. Rose DM, Allegra DP, Bostick PJ, Foshag LJ, Bilchik AJ. Radiofrequency ablation: a novel primary and adjunctive ablation technique for hepatic malignancies. *Am Surg.* 1999;65:1009–1014.
28. Cuschieri A, Bracken J, Boni L. Initial experience with laparoscopic ultrasound-guided radiofrequency thermal ablation of hepatic tumors. *Endoscopy.* 1999;31:318–321.
29. Okada S. Local ablation therapy for hepatocellular carcinoma. *Semin Liver Dis.* 1999;19:323–328.
30. Ido K, Isoda N, Sugano K. Microwave coagulation therapy for liver cancer: laparoscopic microwave coagulation. *J Gastroenterol.* 2001;36:145–152.