

## 研究成果のまとめ

- 1 練和後経過時間、粉液比、血液の混入、注入充填方法の違いがCPC硬化体の圧縮強度に与える影響について椎体形成術モデルを用いて実験的に調べた。その結果、72時間の硬化時間の確保、高粉液比での使用、血液の混入を避けること、骨腔最深部からの充填が、CPC硬化体の圧縮強度を高く維持する因子であることを確認した。
- 2 従来の正中小切開術式から、更なる低侵襲化を目指した。Biportal transpedicular vertebraloplastyを開発し、臨床応用を開始した。まだ少数例で経過観察期間が短いものの、より低侵襲でありながら従来法に劣らない臨床効果と安全性を確認した。

prove according to the HRQoL questionnaire as well as the disease specific score. While the X-group showed a more pronounced improvement according to SF 36, the D-group showed more favourable results according to ZCQ. Updated results will be presented at the meeting.

**P 39**

**OUTCOME SCORES IN SPINAL SURGERY QUANTIFIED: EXCELLENT, GOOD, FAIR AND POOR IN TERMS OF PATIENT COMPLETED TOOLS**

S Tafazal, P Sell

Department of Orthopaedic Surgery, University Hospitals  
Leicester, Leicester, UK

Outcome scores are very important tools as they allow us to assess treatment effect. The clinical significant importance of a score change is not so clear. Few studies have looked at the minimum clinically important score change.

*Method:* A prospective longitudinal inception cohort study of 199 patients. Inclusion criteria were surgery in the form of discectomy, decompression or a fusion. The patients each completed the Oswestry disability index (ODI), the low back outcome score (LBOS) and the visual analogue score (VAS) pre-operatively and at a minimum of 2 year follow-up. External patient self graded outcome was Excellent, Good, Fair and Poor, commonly termed the Macnab classification.

*Results:* 199 patients underwent a range of spinal operations; 111 discectomies, 65 decompressions, 17 fusions and 6 removal of metalwork. The ODI and LBOS are similar tools. Overall Excellent is a mean improvement of 39 points on the Oswestry, Good 25, Fair 14 and Poor 6.

The meaning of an Excellent outcome is very different for different surgical conditions. In discectomy surgery Excellent is a change of 46 points on the ODI and 5.3 on VAS. In fusion surgery it is 25 ODI and 3.7 VAS. Poor results were an ODI improvement of 5 for discectomy and -1 for fusion. Discectomy has the greatest change, decompression less and fusion the lowest between pre and post op scores.

*Conclusion:* Patient rated outcome measures are of value and we have quantified them in terms of the standard outcome measures completed in spinal surgery. The terms Excellent, Good, Fair and poor now have a cross reference to standard outcome measures that allows early and appropriate evaluation of new treatments. This study clearly defines that the minimum clinically important score change is different for different pathologies and sets a benchmark for further study.

**P 40**

**CALCIUM PHOSPHATE CEMENT VERTEBROPLASTY WITH PEDICLE SCREW FIXATION FOR OSTEOPOROTIC THORACOLUMBAR VERTEBRAL COLLAPSE WITH SPINAL CORD COMPRESSION**

R TAKEMASA, K Kiyasu, T Tani, K Kitaoka, H Yamamoto

Department of Orthopaedic Surgery, Kochi Medical School, Japan

*Introduction:* Osteoporotic vertebral compression fractures sometimes result in progressive vertebral body collapse with spinal cord compression by retropulsion of posterior wall of the vertebral body into the spinal canal. We developed a new less-invasive surgical procedure for such conditions, which is based on vertebroplasty using bioactive calcium phosphate cement (CPC).

*Methods:* Twenty patients with 25 vertebral collapse with retropulsed bony mass causing spinal cord compression in thoracolumbar region were treated with the new procedure. The average age at operation was 76 years, and the follow up was 24 months on

average. There were 10 patients in Frankel grade E, 6 in Frankel D, and 4 in Frankel C, preoperatively. The procedure consists of 3 surgical components. The first is transpedicular injection of CPC into the vertebral body after correcting the wedge deformity. The second is partial laminotomy and posterolateral neural decompression by impacting the retropulsed bony fragments anteriorly for patients with neurological deficits. The last is a short range pedicle screw fixation and posterolateral iliac bone grafting. The CPC was also used to augment the pedicle screw stability by filling the screw hole with it.

*Results:* According to a 10-points pain rating scale, average preoperative back pain was 8.0, and it improved to 0.7 after surgery, and it was 1.2 at the final follow-up. Average kyphosis angle of the fusion segments were 41.5 degrees preoperatively, and it was corrected to 15.9 degrees postoperatively. In 17.2 degrees, the correction was maintained at the final follow-up. The posterolateral fusions were all successfully completed. At the final observation, there were 17 patients in Frankel E and 3 in Frankel D, suggesting excellent neural function recovery. There were no significant complications. The CPC was successfully integrated with the host bone, and there is no radiolucent zone around it.

*Discussion:* This procedure could achieve reconstruction of anterior load sharing mechanism, direct neural decompression, and correction and fusion of kyphotic deformity at the same time through a single posterior approach in a less invasive manner. This can be one of surgical options for osteoporotic vertebral collapse with retropulsed bony fragments causing spinal cord compression.

**P 41**

**FRACTURES OF THE SPINE IN DIFFUSE IDIOPATHIC SKELETAL HYPEROSTOSIS**

M Tanaka, H Ikuma, S Yoshihisa, M Haruo, T Tomoaki

Orthopaedic Surgery, Okayama University Hospital, Japan

*Study Design:* This is a retrospective analysis of ten patients, who were surgically treated with spinal three column fractures in diffuse idiopathic skeletal hyperostosis.

*Objectives:* The authors suggest that spinal fracture with DISH is very unstable, three column fracture, which is one of the main reason for delayed myelopathy or pseudoarthrosis. We evaluated the clinical features of these fractures.

*Summary of Background Data:* Fractures of the spine in diffuse idiopathic skeletal hyperostosis (DISH) have rarely been reported. Less than twenty cases were reported until 2004. There is no consensus on the appropriate indication and treatment of this type of spinal three column fractures with DISH.

*Methods:* Ten consecutive patients, who were treated surgically between 1995 and 2004, were included in this study. There were seven men and three women, aged 40-84 (average 69.8). All patients were assessed for neurological deficits and pain by neurological examination. Computerized tomography, magnetic resonance imaging and myelography were performed in all patients. Neurological recovery was evaluated by Frankel's grade.

*Results:* Fracture sites were one C7, three Th11, two Th11/12, three Th12 and one L1/2. The injuries were seven falls and three motor accidents. Preoperative neurological statuses were 7 nonambulatory, 2 walker gaits.

All patients received spinal instrumentation surgery (nine posterior and one anterior). Nine (90%) of 10 patients obtained complete or substantial resolution of their symptoms, with an average follow up of 25 months. All but one patient had good neurological recovery according to Frankel's grade. There was no nonunion. One patient experienced no significant improvement.

*Conclusions:* Treatment of this rare injury should be early stabilization of the spine using strong instrumentation avoid severe complications of neurological injury.

## Mechanical properties of the femur filled with calcium phosphate cement under torsional loading: a model in rabbits

HIROO MIZOBUCHI<sup>1</sup>, TOSHIKAZU TANI<sup>1</sup>, RYUICHI TAKEMASA<sup>1</sup>, HIROSHI YAMAMOTO<sup>1</sup>, and HIROSHI SONOBE<sup>2</sup>

<sup>1</sup>Department of Orthopaedic Surgery, Kochi Medical School, Kohasu, Oko-cho, Nankoku, Kochi 783-8505, Japan

<sup>2</sup>Second Department of Pathology, Kochi Medical School, Kochi, Japan

**Abstract** We conducted an experimental study using rabbits to determine the effect of injection of calcium phosphate cement (CPC) through a small cortical window on the torsional strength of the long bone. A drill hole created in the femoral shaft and medullary curettage before CPC injection simulates the clinical procedure for managing benign bone tumors. Torsional loading always produced a spiral fracture through the drill hole. The CPC-treated femurs, but not the polymethylmethacrylate-treated femurs, tolerated greater torsional loads and had greater energy absorption to failure at 24 h and 2 weeks postoperatively compared with the contralateral sham-operated femurs. These two parameters, however, were only 54% and 26%, respectively, of those in normal femurs at 24 h, but they were 71% and 51% of those in normal femurs at 12 weeks. Histologic sections demonstrated progressive covering of the drill hole by new bone in the CPC-treated specimens and invagination by newly formed cortical bone into the medullary cavity following sham operation. CPC increases the torsional strength of the long bones immediately after injection, although not sufficiently to preclude the need for external fixation in clinical applications. Better management of the cortical defect is needed to further improve torsional strength.

**Key words** Calcium phosphate cement · Torsional strength · Benign bone tumor

### Introduction

Calcium phosphate cement (CPC) is of considerable interest for use in filling defects in bone. Unlike other bioceramics, CPC can be injected into the defect, with subsequent setting and hardening at a controllable and reproducible rate through a nonexothermic reaction. This injectable nature of CPC, coupled with other

favorable properties, including the ability to be osteoconductive, to be resorbed, and to resist substantial compressive loads, has led us to use it clinically in the treatment of benign bone tumors. In practice, we created a small window in the cortical shell to curette the tumor and fill the osseous defect with CPC, thereby minimizing the reduction in biomechanical strength of the compromised host bone.<sup>16</sup> In such cases, CPC molds itself perfectly to the cavity and is in contact with the thin shell of cortical bone. Therefore, the biologic properties of the cement–cortical bone interface, together with the torsional strength of the bone–cement composite, help maintain the mechanical function of the host long bones postoperatively.

Most previous reports have dealt with histologic evaluation of the cement–cancellous bone interface and the biomechanical properties related to compression and tensile load.<sup>6,8,9,15</sup> This is because the purpose of those studies was to provide a theoretical background for using injectable CPC in comminuted, displaced fractures, such as Colles' fracture, tibial plateau fracture, and vertebral compression fracture.

To determine its applicability to the repair of osseous defects in the long bones after curettage of benign bone tumors, we studied the CPC–cortical bone interface histologically and the torsional strength of the bone–cement composite biomechanically, and we compared the results with those for polymethylmethacrylate (PMMA) cement in rabbits.

### Materials and methods

#### *Calcium phosphate cement*

CPC (Mitsubishi Material Corp., Tokyo, Japan) consists of a dry powder and its diluent. The powder is composed of  $\alpha$ -tricalcium phosphate (75 wt %), tetracalcium phosphate (18 wt %), hydroxyapatite (5 wt %),

Offprint requests to: H. Mizobuchi

Received: February 21, 2002 / Accepted: May 8, 2002

and dicalcium phosphate dihydrate (5 wt %) and the diluent, sodium succinate (12 wt %), sodium chondroitin sulfate (5 wt %), and water (83 wt %). The powder is mixed with the diluent to obtain a paste, which gradually sets and hardens. Upon setting and hardening, precipitation of hydroxyapatite, the mineral in teeth and bones, takes place. Sodium succinate accelerates the setting reaction, and sodium chondroitin sulfate determines the viscosity of the product.<sup>7</sup>

We chose a powder-to-liquid (P/L) ratio of 2.8, which creates a product that is strong and easy to handle. The setting time is 15–20 min at room temperature.

### Animals

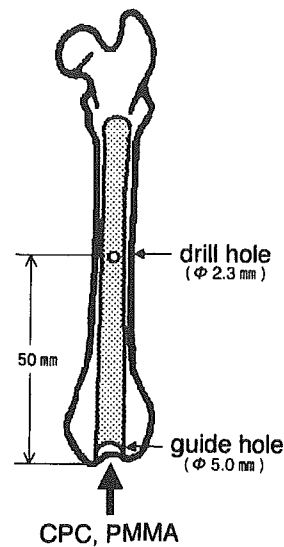
Approval for this study was obtained from the Animal Experimentation Ethics Committee of Kochi Medical School. We used 93 adult Japanese white rabbits (Japan Animals, Osaka, Japan) weighing 2.6–3.4 kg (mean, 3.0 kg). Of these, 6 were excluded because of errors in mechanical testing ( $n = 3$ ), infection ( $n = 2$ ), or fracture ( $n = 1$ ). We analyzed the data from the remaining 87 animals.

The animals were housed individually in the animal care facility of Kochi Medical School under controlled conditions of light (12:12h light-dark cycle), temperature ( $24^{\circ} \pm 2^{\circ}\text{C}$ ), and humidity ( $50\% \pm 20\%$ ), with food (CR-2, CLEA Japan, Tokyo, Japan) and water ad libitum.

Each animal was randomly assigned to treatment with either CPC paste ( $n = 72$ ) or PMMA cement (Surgical Simplex-P, Hawmedica, Rutherford, NJ, USA) ( $n = 10$ ) and alternatively assigned to undergo treatment of either the right or the left hind limb. The remaining five animals had their femurs left intact to measure the torsional strength of the normal femur.

### Surgical preparation

The animals were anesthetized initially with intraperitoneally injected 25% carbamic acid ethyl ester (4 ml/kg body weight), followed by intravenously administered sodium pentobarbital (1.5–3.0 mg/kg) as needed. A 3-cm longitudinal incision was made on the anterolateral aspect of the knee, along the lateral border of the quadriceps tendon, the patella, and the patellar tendon. With the dissection carried through the joint capsule, the patella was retracted medially and the knee was flexed to gain good exposure of the distal end of the femur. A guide-hole 5 mm in diameter was drilled into the site just anterior to the intercondylar notch, through which the medulla of the femur was then thoroughly curetted using a nylon brush 6 mm in diameter. An additional 2-cm incision was made over the lateral aspect of the thigh, developing the plane between the

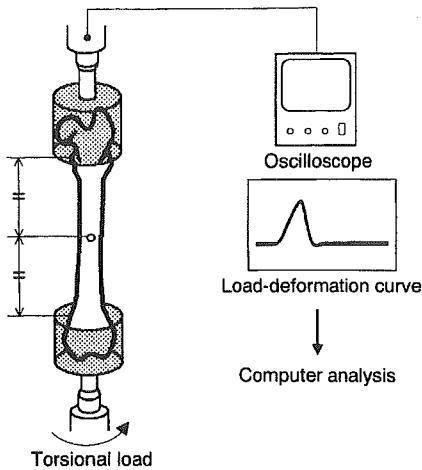


**Fig. 1.** Schematic drawing of the femur, indicating the site of the drill hole in the mid-shaft to simulate a window for curetting tumor and the guide hole in the intercondylar notch for filling the medullary cavity with calcium phosphate cement (CPC) or polymethylmethacrylate (PMMA)

vastus medialis and the gracilis muscles to expose the anterior surface of the femoral shaft. A 2.3-mm diameter hole was drilled through the anterior cortex in the mid-shaft (about 50 mm from the distal end of the femur) to simulate a small window for curettage of the tumor and injection of the CPC paste. In the CPC group, the CPC paste was injected into the intramedullary space through the distal intercondylar hole via a 14-gauge polyethylene tube. The proximal hole in the femoral shaft was closed with the surgeon's fingertip until the CPC completely filled the space (Fig. 1). In the PMMA group, the PMMA cement was inserted manually through the distal intercondylar hole into the femoral defect. In both groups, the procedure was completed by sealing the proximal hole in the femoral shaft with the respective biomaterials. The contralateral femur of each animal underwent an identical procedure but received neither CPC nor PMMA cement injection (sham-operation group), and served as an internal control.

### Mechanical testing

For mechanical testing, 10 animals from the CPC group were sacrificed with an overdose of sodium pentobarbital at 24 h or 2, 4, or 12 weeks postoperatively. The 10 animals treated with PMMA were sacrificed 24 h after surgery. Both femurs from each animal were harvested immediately after death, cleaned of soft tissue, wrapped in physiologic saline-soaked gauze, and stored in a



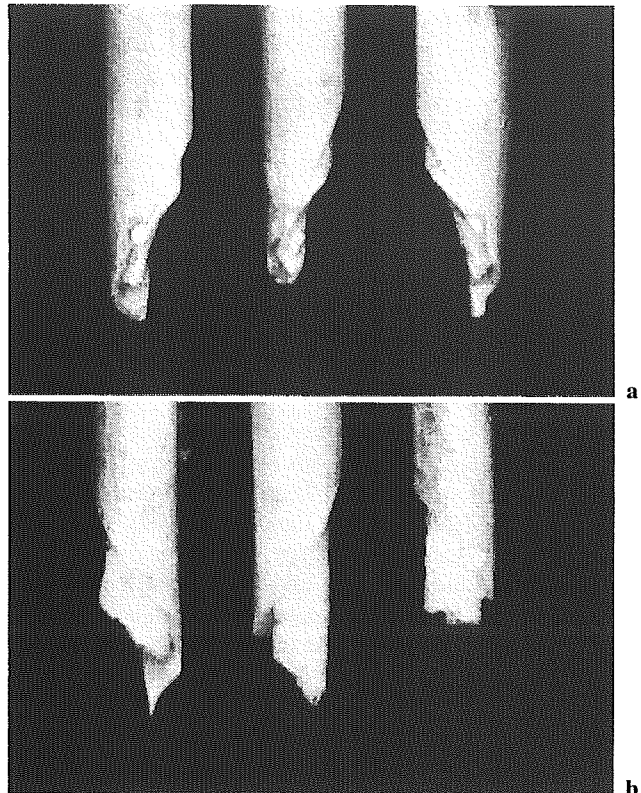
**Fig. 2.** Schematic diagram of the experimental apparatus used for the mechanical testing

freezer at approximately  $-15^{\circ}\text{C}$ . Radiographs were obtained before freezing to ensure that the biomaterial had adequately filled the defects in the bone.

Mechanical testing was performed at room temperature within 1 week of sacrifice. Before testing, the specimens were gradually thawed in running water and kept moist by covering them with polyvinylidene chloride film until testing was completed. The femur was placed in a torsion-testing apparatus (INSTRON1125, Canton, MA, USA) with its distal and proximal ends fixed by dental resin so that proper concentric and axial alignment could be achieved. The distal end was externally rotated at a constant rate of 10rpm until failure, while the proximal end was held fixed. Torque versus angular deformation curves were obtained using a storage type of oscilloscope. The data were collected with an analog-to-digital converter and stored for analysis on a Macintosh personal computer. We calculated the values of ultimate torsional load, torsional stiffness, and energy absorption to failure using a software program (NIH Image 1.59, Bethesda, MD, USA) (Fig. 2). For statistical analysis, we used the Mann-Whitney U-test for unpaired data, considering  $P < 0.05$  to indicate significance.

#### Histologic analysis

For histologic analysis, eight animals from each CPC group were sacrificed at 24h or 2, 4, or 12 weeks postoperatively. At each time point, four animals each were assigned for non-decalcified or decalcified specimen production. The femurs used for nondecalcified tissue specimens were fixed in 20% neutral buffered formalin, embedded with polyester resin, sectioned with glass knives (50–80  $\mu\text{m}$ ), and stained with toluidine blue.



**Fig. 3a,b.** Gross appearance of the specimens after failure. **a** Specimens in the calcium phosphate cement (CPC) group. Fracture of the CPC occurred at the same level as the cortical bone fracture. **b** Specimens in the polymethylmethacrylate (PMMA) group. The PMMA cement and the cortical bone broke at different levels

The femurs used for decalcified specimens were fixed in 20% neutral buffered formalin, decalcified for 7–10 days by adding 10% formic acid, embedded with paraffin, and stained with hematoxylin and eosin. In either case, the transverse sections of the specimens included the drill hole in the femoral shaft. Histologic changes on the cemented side and the sham-operated side were compared.

## Results

#### Biomechanical findings

##### CPC group vs. PMMA group at 24h

Whether the animal was treated with CPC, PMMA, or sham operation, torsional loading always produced a spiral fracture through the drill hole in the femoral shaft. On inspection of the fracture, one fragment tended to be more comminuted than the other. In the less comminuted fragment, the angle between the slope

of the spiral and the long axis of the bone was measured. The angles were similar ( $P = 0.54$ ) in the CPC group ( $31^\circ \pm 2.8^\circ$ ) and the PMMA group ( $32^\circ \pm 2.8^\circ$ ). The spiral fractures in the CPC group occurred at the same level as the cortical bone fracture without interfacial failure (Fig. 3a). In contrast, the PMMA cement and the cortical bone broke at different levels, indicating a failure of the cement–bone interface (Fig. 3b).

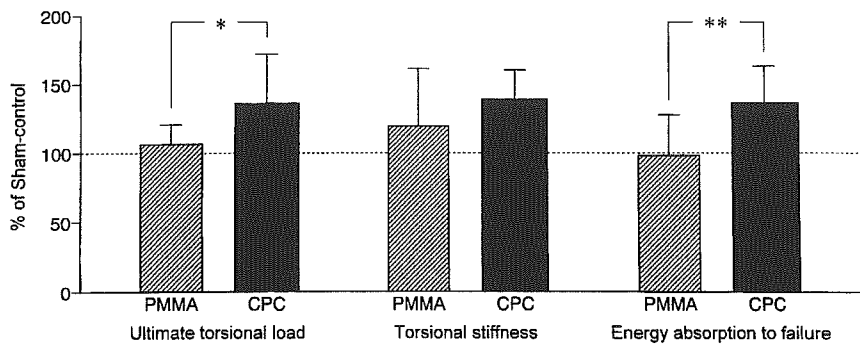
The femurs treated with CPC tolerated a greater ultimate torsional load ( $26.71 \pm 5.92$  MPa vs.  $20.71 \pm 5.72$  MPa;  $P = 0.02$ ), had greater torsional stiffness ( $2.58 \pm 0.42$  MPa vs.  $1.93 \pm 0.47$  MPa;  $P = 0.01$ ), and absorbed more energy to failure ( $1.10 \pm 0.30$  MPa vs.  $0.84 \pm 0.27$  MPa;  $P = 0.01$ ) compared with the sham-operated femurs (Table 1). The values for the CPC-treated specimens, however, were much smaller than those for the 10 normal femurs, averaging only 54% of ultimate torsional load, 53% of torsional stiffness, and 26% of energy absorption to failure. In contrast, there was no difference between the femurs treated with PMMA and the sham-operated femurs in ultimate

torsional load ( $P = 0.88$ ), torsional stiffness ( $P = 0.36$ ), or energy absorption to failure ( $P = 0.50$ ).

To reduce errors associated with individual differences between the animals in comparing the effect of the two biomaterials, we normalized the mechanical test data expressing the values on the cemented side as a percentage of the sham-operated side. The CPC group had a higher ratio than the PMMA group for ultimate torsional load ( $134.60\% \pm 36.78\%$  vs.  $105.38\% \pm 14.74\%$ ;  $P = 0.03$ ) and energy absorption to failure ( $134.46\% \pm 26.53\%$  vs.  $99.06\% \pm 29.17\%$ ;  $P = 0.008$ ), but not for torsional stiffness ( $137.60\% \pm 21.56\%$  vs.  $118.10\% \pm 42.14\%$ ;  $P = 0.41$ ) (Fig. 4).

*Serial changes in the CPC group over time*

The drill hole in the femoral shaft became progressively smaller over time as new bone formed. Twelve weeks postoperatively, the hole was no longer visible in the specimens treated with CPC and was visible as a tiny dimple in the sham-operated specimens. Despite this cortical repair, the spiral fracture line produced by



**Fig. 4.** Comparison of torsional properties 24h after injection of calcium phosphate cement (CPC) or polymethylmethacrylate cement (PMMA). The values are presented as mean percentages of the strength of a sham procedure with no injection. Bars indicate SD. \* $P < 0.05$ , \*\* $P < 0.01$  by Mann-Whitney U-test

**Table 1.** Results of torsional testing of femur

Time after operation	Treatment group	Ultimate torsional load		Torsional stiffness		Energy absorption to failure	
		(MPa)	<i>P</i> value	(MPa)	<i>P</i> value	(MPa)	<i>P</i> value
24 h	PMMA	21.41 ± 5.99	0.88	2.21 ± 0.36	0.36	0.82 ± 0.19	0.5
	Sham	20.90 ± 6.07		2.02 ± 0.74		0.88 ± 0.30	
	CPC	26.71 ± 5.92	0.02*	2.58 ± 0.42	0.01*	1.10 ± 0.30	0.01*
2 weeks	Sham	20.71 ± 5.72		1.93 ± 0.47		0.84 ± 0.27	
	CPC	27.29 ± 7.03	0.03*	2.66 ± 0.66	0.41	1.19 ± 0.30	0.04*
4 weeks	Sham	21.22 ± 4.97		2.50 ± 0.90		0.90 ± 0.21	
	CPC	29.75 ± 6.21	0.71	3.85 ± 0.66	0.45	1.64 ± 0.38	0.02*
12 weeks	Sham	27.58 ± 8.27		3.81 ± 1.05		1.22 ± 0.37	
	CPC	35.24 ± 8.58	0.82	3.60 ± 0.73	0.65	2.16 ± 0.76	0.17
	Normal control	37.46 ± 10.71		3.80 ± 0.75		2.63 ± 0.83	
		49.82 ± 9.68		4.84 ± 0.71		4.25 ± 0.81	

Each group consisted of 10 femurs. Data are means ± SD  
 PMMA, polymethylmethacrylate; CPC, calcium phosphate cement  
 \*  $P < 0.05$  by Mann-Whitney U-test

torsional loading still passed through the drill hole in all specimens. The longer the time after operation, the less comminuted was the fracture that torsional loading produced.

The ultimate torsional load and the energy absorption to failure, but not the torsional stiffness, increased progressively with time after operation. The CPC group showed a greater ultimate torsional load than the sham-operated group at 2 weeks ( $27.29 \pm 7.03$  MPa vs.  $21.22 \pm 4.97$  MPa;  $P = 0.03$ ), but not at 4 or 12 weeks (Fig. 5a). The energy absorption to failure also was greater for the CPC group than for the sham-operated group at 2 weeks ( $1.19 \pm 0.30$  MPa vs.  $0.90 \pm 0.21$  MPa;  $P = 0.04$ ) and at 4 weeks ( $1.64 \pm 0.38$  MPa vs.  $1.22 \pm 0.37$  MPa;  $P = 0.02$ ), but not at 12 weeks (Fig. 5c). In contrast, torsional stiffness was similar in the CPC and the sham-operated groups at all time points after 2 weeks (Fig. 5b).

Compared with normal femurs, the CPC group reached 71% of ultimate torsional load, 74% of torsional stiffness, and 51% of energy absorption to failure at 12 weeks.

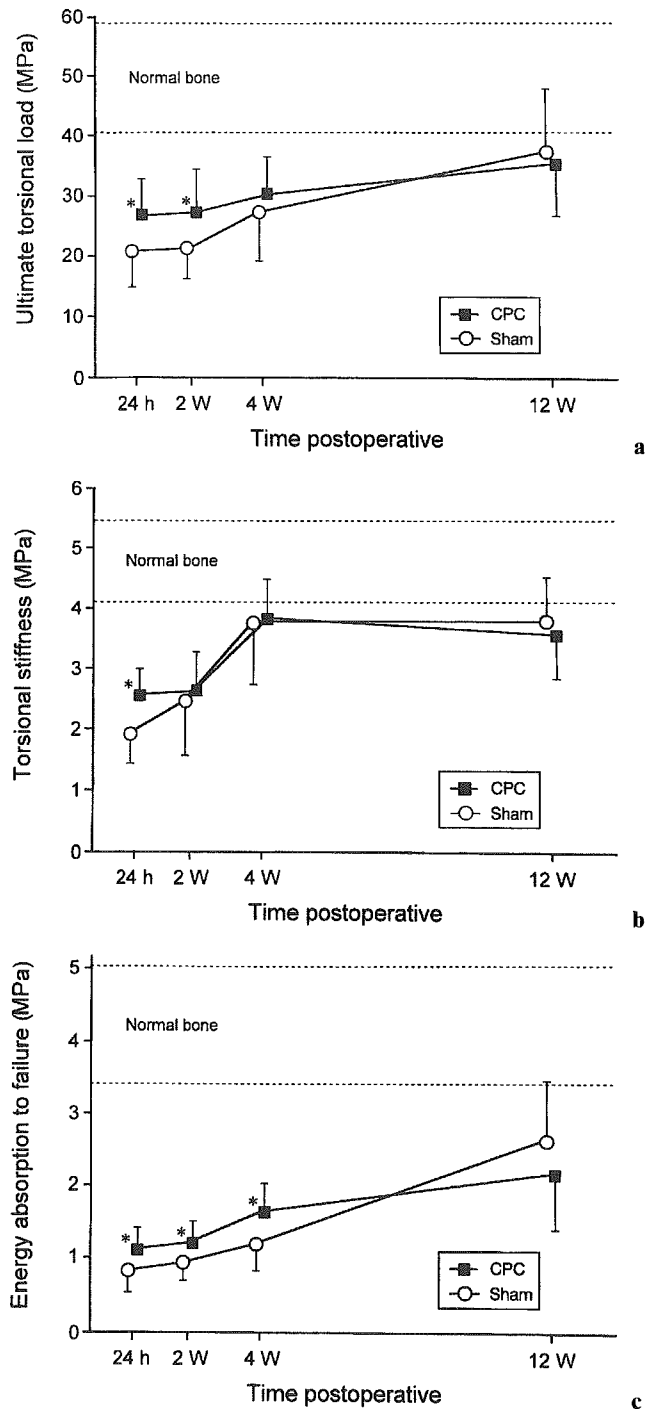
#### Histologic findings

Histologically, the CPC itself remained unchanged, keeping in direct contact with the cortical bone with no fibrous tissue interface throughout the 12-week experiment. Within the cortex, the Haversian systems began to enlarge by 2 weeks (Fig. 6a,b) and had progressively increased in diameter due to vascular fusion by 12 weeks (Fig. 6c,d).

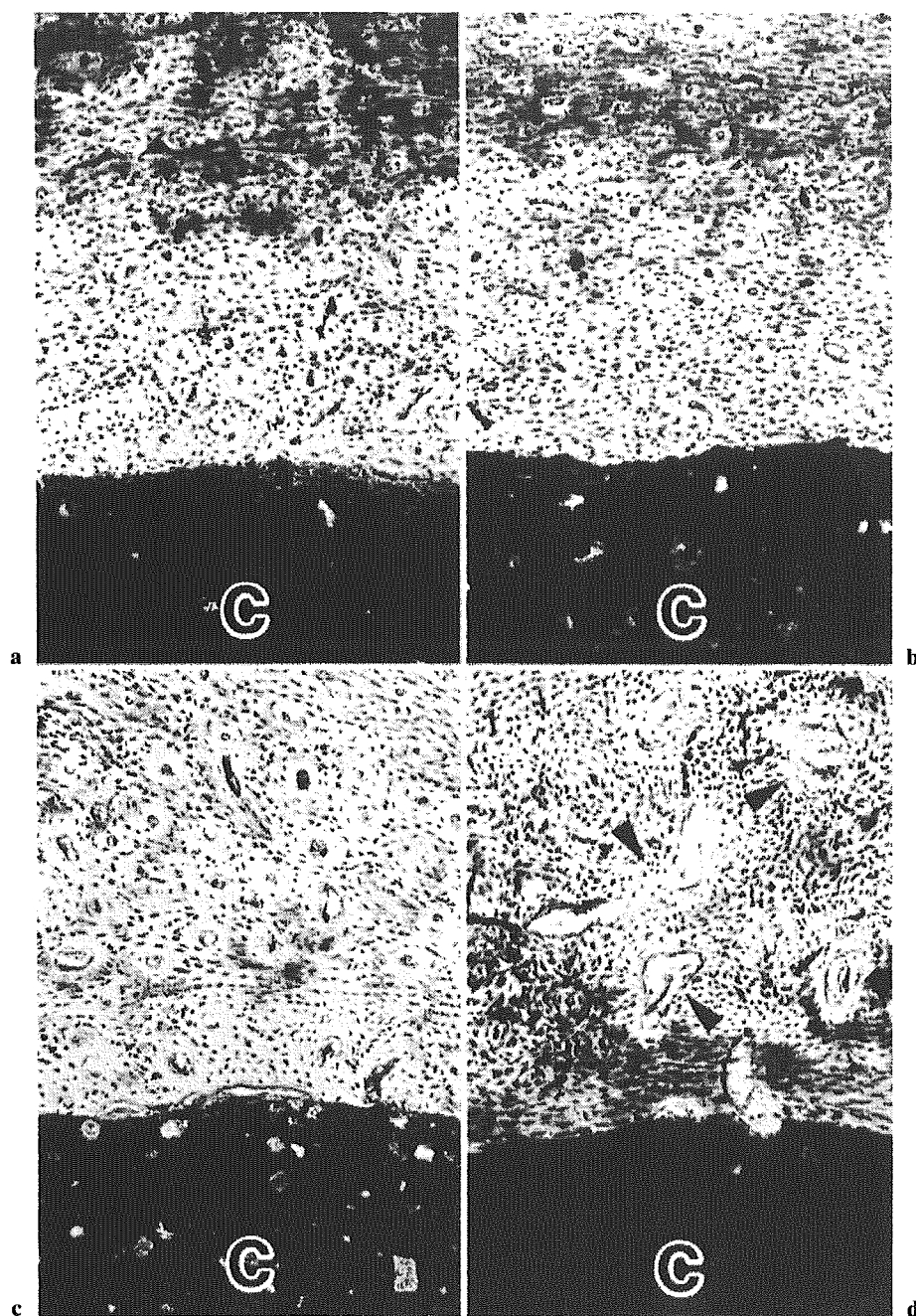
In the CPC-treated specimens, histologic sections through the drill hole demonstrated new bone growth from the surrounding bony rim into the defect by 4 weeks (Fig. 7a), and the hole was completely covered with new bone by 12 weeks (Fig. 7b). In six of the eight sham-operated specimens at 12 weeks, however, the repair of the drill hole was incomplete, with invagination of the newly formed cortical bone into the medullary cavity (Fig. 7c).

#### Discussion

To our knowledge, this is the first study to evaluate the torsional strength of the shaft of a CPC-injected long bone. According to Kurashina et al.,<sup>10</sup> the compressive strength of the CPC itself, when tested in a simulated body fluid after setting with P/L = 2.8, increases progressively to  $24.0 \pm 2.4$  MPa at 24h, reaching a maximal value of  $81.7 \pm 4.0$  MPa at 7 days. However, we are unaware of any study in which its torsional strength has been evaluated. The biomechanical evaluation of CPC-injected long bones after curettage of benign bone



**Fig. 5a-c.** Serial change in torsional strength in the calcium phosphate cement (CPC) group. **a** Ultimate torsional load, **b** Torsional stiffness, **c** Energy absorption to failure. Values are means; bars indicate SD. \* $P < 0.05$  by Mann-Whitney U-test



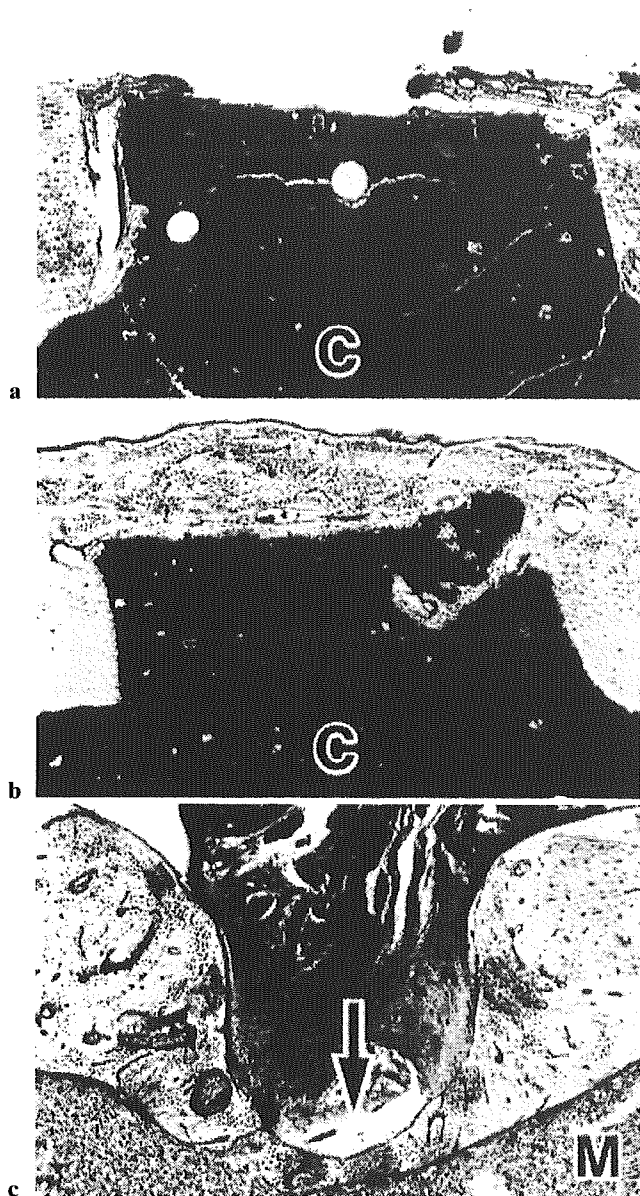
**Fig. 6a-d.** Photomicrographs of the interface between calcium phosphate cement (CPC) and cortical bone. Haversian systems began to enlarge by 2 weeks, then progressively increased in diameter due to vascular fusion (*arrowheads*) by 12 weeks. **a** 24 h postoperative, **b** 2 weeks postoperative, **c** 4 weeks postoperative, **d** 12 weeks postoperative. C indicates CPC; toluidine blue,  $\times 100$

tumors should focus more on the torsional load than the compressive load, because long bone fractures are more likely to result from excessive torsional load.<sup>3,14</sup> Additionally, Brooks et al.<sup>1</sup> have shown that defects in the cortex, such as a surgical window, severely weaken the torsional strength of long bones.

How does CPC injection affect the brittleness in the torsional strength that develops in long bones? First,

we studied torsional strength in the early postoperative period 24 h after surgery. The results indicated that CPC injection increased torsional strength, as reflected by the higher ultimate torsional load and energy absorption to failure compared with the PMMA group and the contralateral sham-operated group, in which the values were similar. The following two factors affected torsional strength in our model: stress concentration at





**Fig. 7a-c.** Photomicrographs of transverse sections through the drill hole. **a** Calcium phosphate cement (CPC) group demonstrates new bone growth 4 weeks postoperatively. **b** The drill hole in the CPC group demonstrates complete covering with new bone 12 weeks postoperatively. **c** Sham-operated specimen shows that new cortical bone has invaginated into the medullary cavity (*arrow*). *C*, CPC; *M*, medullary cavity; toluidine blue,  $\times 50$

the drill hole in the femoral shaft and resistance at the interface between the injected material and the inner surface of the cortical bone; a wider interface with stronger contact results in greater resistance against a torsional load.

Examination of the test material after failure indicated that CPC does not detach from the inner surface of the cortical bone, and that fracture occurs in the CPC and the cortical bone as a unit. In contrast, fracture in the PMMA group occurs after PMMA has detached from the inner surface of the cortical bone. In other words, the detachment of PMMA from the inner surface of the cortical bone occurs at stress levels less than that which causes fracture. This explains why the torsional strength in the PMMA and the sham-operated groups was similar.

Weakness at the PMMA-cortical bone interface probably resulted from difficulties in filling due to the highly viscous nature of PMMA and the decreased contact area due to contraction after hardening. It has been said that PMMA achieves its mechanical strength primarily by virtue of its interdigitation into cancellous bone.<sup>11</sup> Viewed this way, PMMA may be at a disadvantage in terms of torsional strength when used for a relatively smooth osseous surface, such as the experimental model used here, in which cancellous bone is not present.

In contrast, CPC increased the torsional strength of long bones as early as 24h after surgery, even though a biologically active union between CPC and the inner surface of the cortical bone is unlikely to have occurred in such a short period.<sup>15</sup> It should be emphasized, however, that the ultimate torsional load and the energy absorption to failure were only 54% and 26% of those in normal femurs, respectively. Therefore, an external support is still clinically necessary following curettage of benign tumors in the long bones when CPC is used.

The CPC group showed an increase in ultimate load to failure for the first 2 weeks and in energy absorption to failure for 4 weeks after surgery. The absence of any difference thereafter compared to the sham-operated group presumably was because progressive new bone growth repaired the drill hole of the femoral shaft and masked the strengthening effects of CPC. At the final study point, 12 weeks after injection, both groups had achieved only 50%–75% of normal torsional strength, so recovery was incomplete. Burstein et al.<sup>2</sup> also demonstrated in rabbits that the torsional strength of the femur recovered to the level of normal bone 8 weeks after a 2.3-mm-diameter hole was drilled in the mid-shaft. Our sham operation was different from that model in that it included medullary curettage. Thus, the presence of the medulla appears to contribute to torsional strength.<sup>4,12</sup> In fact, histologic examination showed that the sham-operated group did not achieve a normal repair at 12 weeks, suggesting that the cortical defects require the support of medullary tissue for proper healing, and that without support, the result is invagination of newly formed cortical bone, which may compromise torsional strength. It is of interest that this

phenomenon of cortical bone invagination has been reported in clinical cases in which a tumor was curetted from a window without bone grafting.<sup>13</sup>

Unlike the sham-operated group, the CPC group showed a complete cover of new bone over the surface of CPC that had filled the drill hole. However, the new bone layer was relatively thin compared with normal cortical bone, which may have resulted in stress concentration under torsional load. To prevent stress concentration at the drill hole in the early phase, we filled the hole with CPC. Because CPC has osteoconductive properties, it is possible that the hole would have been repaired with cortical bone of normal thickness if the drill hole had not been filled with CPC. This might have resulted in normal strength and merits further investigation.

A potentially adverse effect of CPC injection might be an impairment of intramedullary blood flow resulting from direct contact between the injected CPC and cortical bone. The enlargement of Haversian canals within the cortical bone shown in this study may reflect this possibility, which in turn may have further weakened torsional strength. According to Ebihara et al.,<sup>5</sup> the cavity formation in the cortex observed 6 months after surgery is no longer present at 12 months.

In conclusion, CPC increases the torsional strength of the shaft of long bones in the early phase, but the strength is not adequate to preclude external fixation, and careful monitoring of torsional load is required postoperatively. Postoperative torsional stress is concentrated at the defect in the cortex and is the most important determinant of resistance to fracture. The development of better methods to repair cortical bone defects after CPC injection is needed. Further long-term mechanical and histologic studies are required, including those that examine the effects of CPC injection on intramedullary blood flow.

## References

1. Brooks DB, Burstein AH, Frankel VH, et al. The biomechanics of torsional fractures. The stress concentration effect of a drill hole. *J Bone Joint Surg Am* 1970;52:507-14.
2. Burstein AH, Currey JD, Frankel VH, et al. Bone strength. The effect of screw holes. *J Bone Joint Surg Am* 1972;54:1143-56.
3. Currey JD. Stress concentration in bone. *Q J Microsc Sci* 1962; 103:111-33.
4. Delaere O, Dhem A, Bourgois R. Cancellous bone and mechanical strength of the femoral neck. *Arch Orthop Trauma Surg* 1989;108:72-5.
5. Ebihara A, Morita M, Itoman M. Bone morphometric change at  $\alpha$ -tricalcium phosphate cement and cortical bone interface. *Seitaizairyu (Biomaterials)* 1999;17:5-16 (in Japanese).
6. Frankenburg EP, Goldstein SA, Bauer TW, et al. Biomechanical and histological evaluation of a calcium phosphate cement. *J Bone Joint Surg Am* 1998;80:1112-24.
7. Hirano M, Takeuchi H. Hydraulic calcium phosphate cement composition and cement composition containing hardening liquid. 1992; US Patent No. 5,152,836.
8. Ikenaga M, Hardouin P, Lemaitre J, et al. Biomechanical characterization of a biodegradable calcium phosphate hydraulic cement: a comparison with porous biphasic calcium phosphate ceramics. *J Biomed Mater Res* 1998;40:139-44.
9. Kobayashi M, Nakamura T, Okada Y, et al. Bioactive bone cement: comparison of apatite and wollastonite containing glass-ceramic, hydroxyapatite, and  $\beta$ -tricalcium phosphate fillers on bone-bonding strength. *J Biomed Mater Res* 1998;42:223-37.
10. Kurashina K, Kurita H, Hirano M, et al. Calcium phosphate cement: in vitro and in vivo studies of the  $\alpha$ -tricalcium — dicalcium phosphate dibasic — tetracalcium phosphate monoxide system. *J Mater Sci Mater Med* 1995;6:340-7.
11. Mann KA, Ayers DC, Werner FW, et al. Tensile strength of the cement-bone interface depends on the amount of bone interdigitated with PMMA cement. *J Biomech* 1997;30: 339-46.
12. Medige J, Mindell ER, Doolittle T. Remodeling of large, persistent bone defects. *Clin Orthop* 1982;169:275-90.
13. Noda K, Shimizu T, Shinozaki T, et al. Roentgenographic and computed tomographic observations on benign bone tumor and tumor-like lesions treated by simple curettage without bone grafting. *Nihon Seikeigekagakkai Zasshi (J Jpn Orthop Ass)* 1991;65:689-94 (in Japanese).
14. Sammarco GJ, Burstein AH, Davis WL, et al. The biomechanics of torsional fractures: the effect of loading on ultimate properties. *J Biomech* 1971;4:113-7.
15. Yamamoto H, Niwa S, Hori M, et al. Mechanical strength of calcium phosphate cement in vivo and in vitro. *Biomaterials* 1998; 19:1587-91.
16. Yamamoto H, Mizobuchi H, Sibata T, et al. Clinical evaluation of calcium phosphate bone paste (CPC95) in orthopaedic surgery. *Yakuri To Chiryu (Jpn Pharmacol Ther)* 1998;26:409-429 (in Japanese).

## Enhancement of pedicle screw stability using calcium phosphate cement in osteoporotic vertebrae: in vivo biomechanical study

YOSHIMICHI TANIWAKI, RYUICHI TAKEMASA, TOSHIKAZU TANI, HIROO MIZOBUCHI, and HIROSHI YAMAMOTO

Department of Orthopaedic Surgery, Kochi Medical School, Kohasu, Oko-cho, Nankoku 783-8505, Japan

**Abstract** We conducted an experimental study using female beagles with and without ovariectomy-induced osteoporosis to determine the effect of calcium phosphate cement (CPC) on the mechanical stability of inserted pedicle screws. A drill hole was created from the base of the transverse process to the vertebral body; CPC was injected into the hole, and then a screw was inserted into the same hole. In the presence of osteoporosis evidenced by dual X-ray absorptiometry, the stability of the inserted screw augmented by CPC against pull-out and cephalocaudal forces were significantly greater by 28% and 54% at 1 week after operation, 48% and 71% at 2 weeks, and 56% and 68% at 4 weeks compared with those without CPC. The pull-out strength increased progressively with time after surgery, probably reflecting new-bone growth from the surrounding cancellous bone, which was in direct contact with the CPC, as shown in the histologic study. At each time point the cephalocaudal rigidity was similar and the pull-out strength greater than that for the screws inserted without CPC in nonporotic dogs. These findings suggest that CPC augments the stability of the inserted pedicle screws and increases the stiffness of fixed osteoporotic motion segments using instrumentation.

**Key words** Osteoporosis · Calcium phosphate cement · Pedicle screw · Spine · Biomechanics

### Introduction

The combination system of pedicle screws and plates or rods has been used to stabilize unstable motion segments or to correct spinal deformities. Subsequently, the system has been used for segmental spinal fixation to promote graft incorporation in patients with some degenerative spinal disorders. However, instrumenta-

tion surgeries for the osteoporotic spine have been challenging.

The mechanical stability of inserted pedicle screws is affected by the bone mineral density (BMD).<sup>2,3,15,17,20,22</sup> Rigidity can be compromised and the screws can loosen in patients with osteoporosis. To investigate the stability of inserted pedicle screws, pull-out strength tests have been performed to optimize screw size, screw design, and the insertion depth and direction.<sup>1,8,12,17,20,23</sup> To improve the strength of the screw–bone interface, mechanical tests have been performed with augmentation using cancellous bone, hydroxyapatite (HA) grout, HA stick, and polymethylmethacrylate (PMMA).<sup>11,16,20,21,25</sup>

Calcium phosphate cement (CPC) (Biopex; Mitsubishi Materials, Tokyo, Japan) was developed by Hirano<sup>4</sup> based on the hydration reaction of  $\alpha$ -tricalcium phosphate reported by Monma and Kanazawa<sup>13</sup> in 1976. CPC comes as a powder, the texture of which turns into that of a paste or soft clay when kneaded with liquid. It sets and hardens through a nonexothermic reaction. CPC enhances osteogenesis in the surrounding bone because of its osteoconductivity. In the long term, CPC is expected to be gradually replaced by bone as remodeling progresses.<sup>24</sup> CPC has been used to fill bone defects, and Shibata et al.<sup>19</sup> and Ikeuchi et al.<sup>7</sup> have reported that it increases the compressive strength of the vertebral body when injected into a void space in patients with osteoporosis. The use of CPC with pedicle screws may enhance the strength of the initial fixation, and Iai et al.<sup>6</sup> confirmed that the in vitro pull-out strength of screws can be increased with the use of CPC.

In the present study, the effects of CPC on the in vivo stability of inserted pedicle screws and sequential changes over 4 weeks were investigated using experimental osteoporotic dogs. This study is considered antecedent to the clinical use of CPC.

Offprint requests to: Y. Taniwaki

Received: September 9, 2002 / Accepted: January 6, 2003

## Materials and methods

### CPC

The CPC used in this study was produced using a powder consisting of 75 wt%  $\alpha$ -tricalcium phosphate [ $\alpha$ -TCP;  $\text{Ca}_3(\text{PO}_4)_2$ ], 18 wt% tetracalcium phosphate [TeCP;  $\text{Ca}_4(\text{PO}_4)_2\text{O}$ ], 5 wt% dicalcium phosphate dihydrate (DCPD;  $\text{CaHPO}_4 \cdot 2\text{H}_2\text{O}$ ), 2 wt% HA [ $\text{Ca}_{10}(\text{PO}_4)_6(\text{OH})_2$ ], and a weakly basic hardening liquid consisting of 5 wt% sodium chondroitin sulfate, 12 wt% sodium succinate, and 83 wt% water. The handling and mechanical property of the CPC depend on the powder/liquid weight ratio. In this study, a powder/liquid weight ratio of 2.8 was used to permit easy injection using a syringe while maintaining sufficient strength.

### Animals

Approval for this study was obtained from the Animal Experimentation Ethics Committee of Kochi Medical School. Nine female beagles (Nosan, Yokohama, Japan) aged 7.2–9.0 months (mean  $7.8 \pm 0.6$  months) and weighing 7.9–9.7 kg (mean  $8.7 \pm 0.7$  kg) were treated by transperitoneal bilateral ovariectomy and were fed a 250 g/day low-calcium diet (CLEA Japan, Tokyo, Japan) for 9 months to produce experimental osteoporosis (porotic dogs). At the end of the 9-month feeding period, the mean weight was  $11.7 \pm 1.2$  kg (9.8–14.0 kg). Five female beagles aged 17.9–21.0 months (mean  $19.4 \pm 1.7$  months) and weighing 10.0–11.9 kg (mean  $11.0 \pm 0.9$  kg) that were not subjected to ovariectomy or given a low-calcium diet were used as healthy controls (nonporotic dogs).

### Surgical preparation

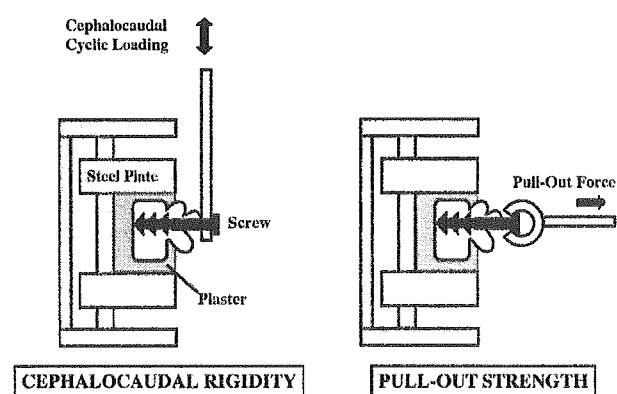
All beagles were anesthetized with isoflurane. Each lamina from the first lumbar vertebra (L1) to the seventh lumbar vertebra (L7) was exposed by the posterior midline approach, and six holes were drilled to a depth of 12 mm from the base of the transverse process to the vertebral body alternately on the right and left sides of L1 to the L6 vertebra using a drill 3.5 mm in diameter. After about 2 min of kneading, CPC paste was injected into three of the six bone holes to fill the space using manual pressure with a syringe whose tip was 3.5 mm outside diameter. A stainless steel cancellous screw 26 mm in length, 12 mm in thread length, and 4.0 mm in major diameter (Stryker Japan, Tokyo, Japan) was then inserted into each hole to the same depth of 12 mm (CPC group). As a control, a screw was inserted into each of the remaining three holes to the same depth without CPC (non-CPC group).

### BMD measurement and mechanical testing

At 1, 2, and 4 weeks after surgery, three porotic dogs and two nonporotic dogs (one nonporotic dog 2 weeks after surgery) were killed, and the spine from L1 to L7 was excised en bloc. In a water tank filled with physiological saline, the bone mineral density (BMD) value was measured on the lateral view of the vertebral body of the L7 vertebra, into which no screw had been inserted, by dual-energy X-ray absorptiometry (QDR-1000; Hologic, Waltham, MA, USA).

A total of 75 vertebrae were available for mechanical testing. The remaining vertebrae in which the screw had penetrated the spinal canal or anterior aspect of the vertebral body were not tested mechanically, but three of them from the CPC group were examined histologically. The vertebrae and screws in L1 to L6 were fixed in a custom-made holder, and mechanical testing was performed using Instron model 4466 (Instron, Canton, MA, USA).

A shank of the screw, 23.3 mm from the tip, was toggled by a specially designed connector of 7.0 mm inside diameter, producing a controlled wagging movement in the cephalocaudal direction. Five cycles of loading were applied perpendicular to the major axis of the screw at a crosshead speed of 3.0 mm/min with a maximal load of 9.8 N, which was within the elastic range of the screw–bone interface. A graph of force (newtons) versus displacement (millimeters) was recorded, and the cephalocaudal rigidity of the screw–bone interface was determined as the slope of the fifth load–deformation curve. The pull-out strength of the screw in the direction of the major axis was tested with a crosshead speed of 10 mm/min (Fig. 1). The cephalocaudal rigidity and pull-out strength in the CPC and non-CPC groups were compared.



**Fig. 1.** Experimental setup. Five cycles of loading were applied perpendicular to the major axis of the screw. The cephalocaudal strength was calculated from the load–deformation curve. The pull-out strength of the screw in the direction of the major axis was tested

### Histological study

Three vertebrae used for histological analysis were from the CPC group obtained 1, 2, and 4 weeks after surgery. The specimens were fixed in 20% neutral buffered formalin, embedded with polyester resin, sectioned along the screw axis using glass knives, and stained with toluidine blue.

### Statistics

The strength between the CPC and non-CPC groups was compared by the Mann-Whitney U-test, and the differences between values 1, 2, and 4 weeks after surgery were compared by the Kruskal-Wallis test. Values were given as means  $\pm$  SD and were considered significant at a probability ( $P$ ) of  $<0.05$ .

## Results

### BMD

The BMD value of L7 was  $0.43 \pm 0.04 \text{ g/cm}^2$  (range  $0.38\text{--}0.48 \text{ g/cm}^2$ ) in the porotic dogs and  $0.59 \pm 0.03 \text{ g/cm}^2$  (range  $0.54\text{--}0.62 \text{ g/cm}^2$ ) in the nonporotic dogs. This difference was significant ( $P < 0.01$ ), indicating that an experimental model of osteoporosis had been produced.

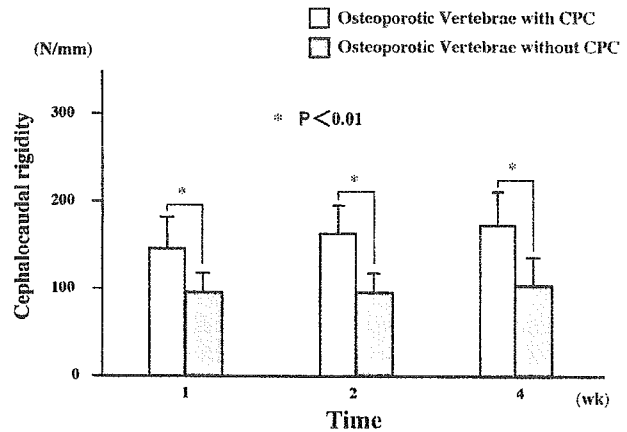
### Biomechanical findings

#### Cephalocaudal rigidity

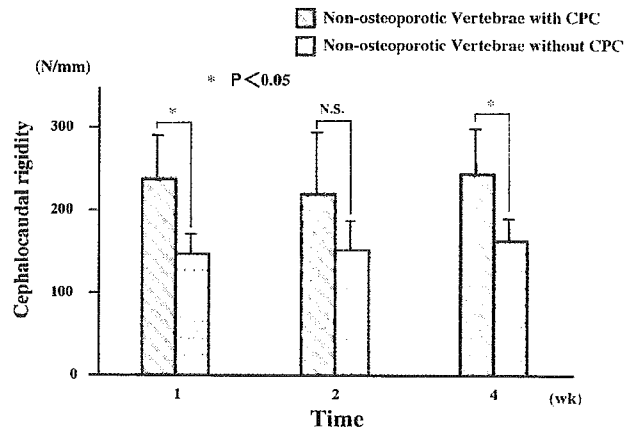
No looseness was observed by repeated loading perpendicular to the major axis of the screw. Load-deformation curves were generated to determine cephalocaudal rigidity.

**Cephalocaudal rigidity in porotic dogs.** The cephalocaudal rigidity in the CPC group of porotic dogs (Fig. 2) was  $144.4 \pm 36.8 \text{ N/mm}$  ( $n = 7$ ) 1 week after surgery,  $163.4 \pm 31.6 \text{ N/mm}$  ( $n = 9$ ) at 2 weeks, and  $172.3 \pm 38.2 \text{ N/mm}$  ( $n = 8$ ) at 4 weeks. The values in the non-CPC group were  $93.8 \pm 23.7 \text{ N/mm}$  ( $n = 9$ ) at 1 week,  $95.6 \pm 21.4 \text{ N/mm}$  ( $n = 9$ ) at 2 weeks, and  $102.7 \pm 32.3 \text{ N/mm}$  ( $n = 8$ ) at 4 weeks, showing no appreciable change. The cephalocaudal rigidity in porotic dogs was significantly higher at 1, 2, and 4 weeks after surgery in the CPC group than in the non-CPC group ( $P < 0.01$ ), and it was higher by 53.9%, 70.9%, and 67.8%, respectively, in the CPC group than in the non-CPC group.

**Cephalocaudal rigidity in nonporotic dogs.** The cephalocaudal rigidity in the CPC group of nonporotic dogs (Fig. 3) was  $234.3 \pm 56.7 \text{ N/mm}$  ( $n = 4$ ) 1 week after



**Fig. 2.** Cephalocaudal rigidity of porotic dogs. Calcium phosphate cement (CPC) significantly enhanced the cephalocaudal rigidity of the screws in all experimental osteoporotic vertebrae examined in this study

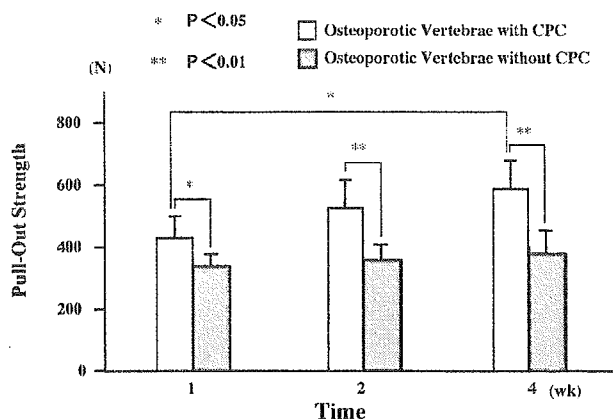


**Fig. 3.** Cephalocaudal rigidity of nonporotic dogs. Note that the rigidity was significantly higher in the CPC group than in the non-CPC group 1 and 4 weeks after surgery

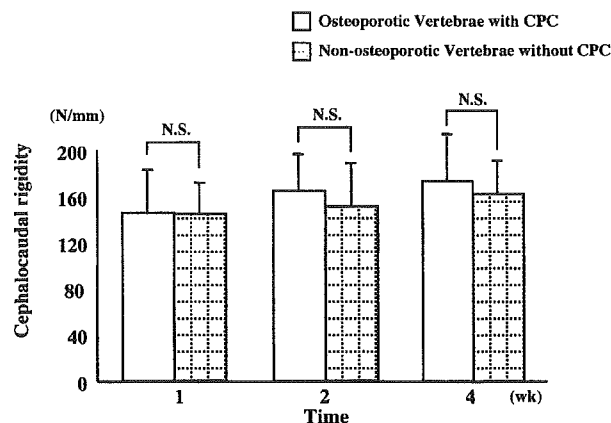
surgery,  $216.4 \pm 78.3 \text{ N/mm}$  ( $n = 3$ ) at 2 weeks, and  $240.8 \pm 58.8 \text{ N/mm}$  ( $n = 6$ ) at 4 weeks. In the non-CPC group it was  $143.4 \pm 27.1 \text{ N/mm}$  ( $n = 4$ ) at 1 week,  $149.2 \pm 37.7 \text{ N/mm}$  ( $n = 3$ ) at 2 weeks, and  $160.4 \pm 28.9 \text{ N/mm}$  ( $n = 5$ ) at 4 weeks. The cephalocaudal rigidity was significantly higher in the CPC group than in the non-CPC group 1 and 4 weeks after surgery ( $P < 0.05$ ) but not at 2 weeks.

#### Pull-out strength

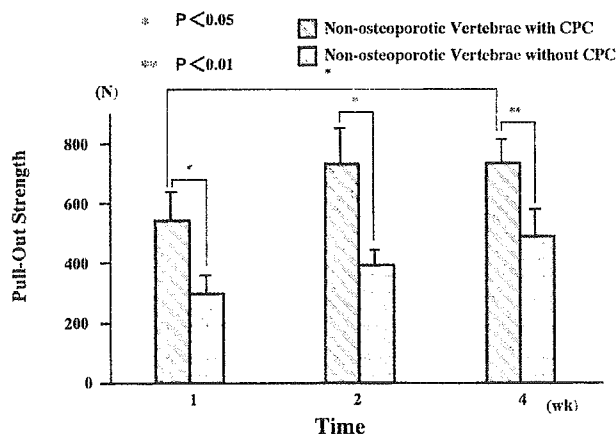
**Pull-out strength in porotic dogs.** The pull-out strength in the CPC group of porotic dogs (Fig. 4) was  $415.4 \pm 69.6 \text{ N}$  ( $n = 7$ ) 1 week after surgery,  $512 \pm 91.2 \text{ N}$  ( $n = 9$ ) at 2 weeks, and  $573.5 \pm 92.1 \text{ N}$  ( $n = 8$ ) at 4 weeks, showing a tendency to increase with time after surgery



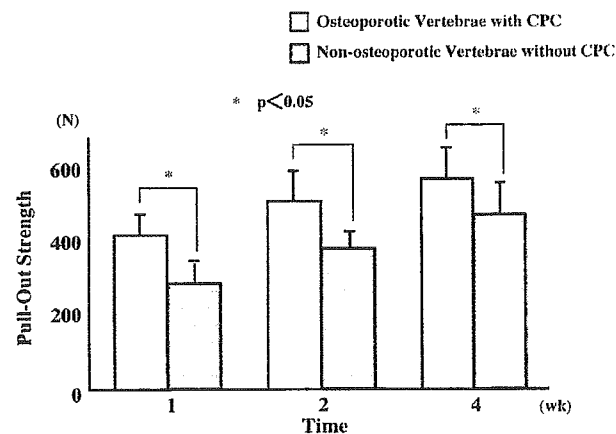
**Fig. 4.** Pull-out strength of porotic dogs. Note that the pull-out strength was gradually enhanced over time after screw insertion with the CPC. The value was significantly higher at 4 weeks than at 1 week



**Fig. 6.** Augmentation effect on cephalocaudal rigidity. Note that the rigidity in the CPC group of porotic dogs was similar to that in the non-CPC group of nonporotic dogs at all time stages



**Fig. 5.** Pull-out strength of nonporotic dogs. Note that the pull-out strength was significantly higher at 1, 2, and 4 weeks after surgery in the CPC group than in the non-CPC group



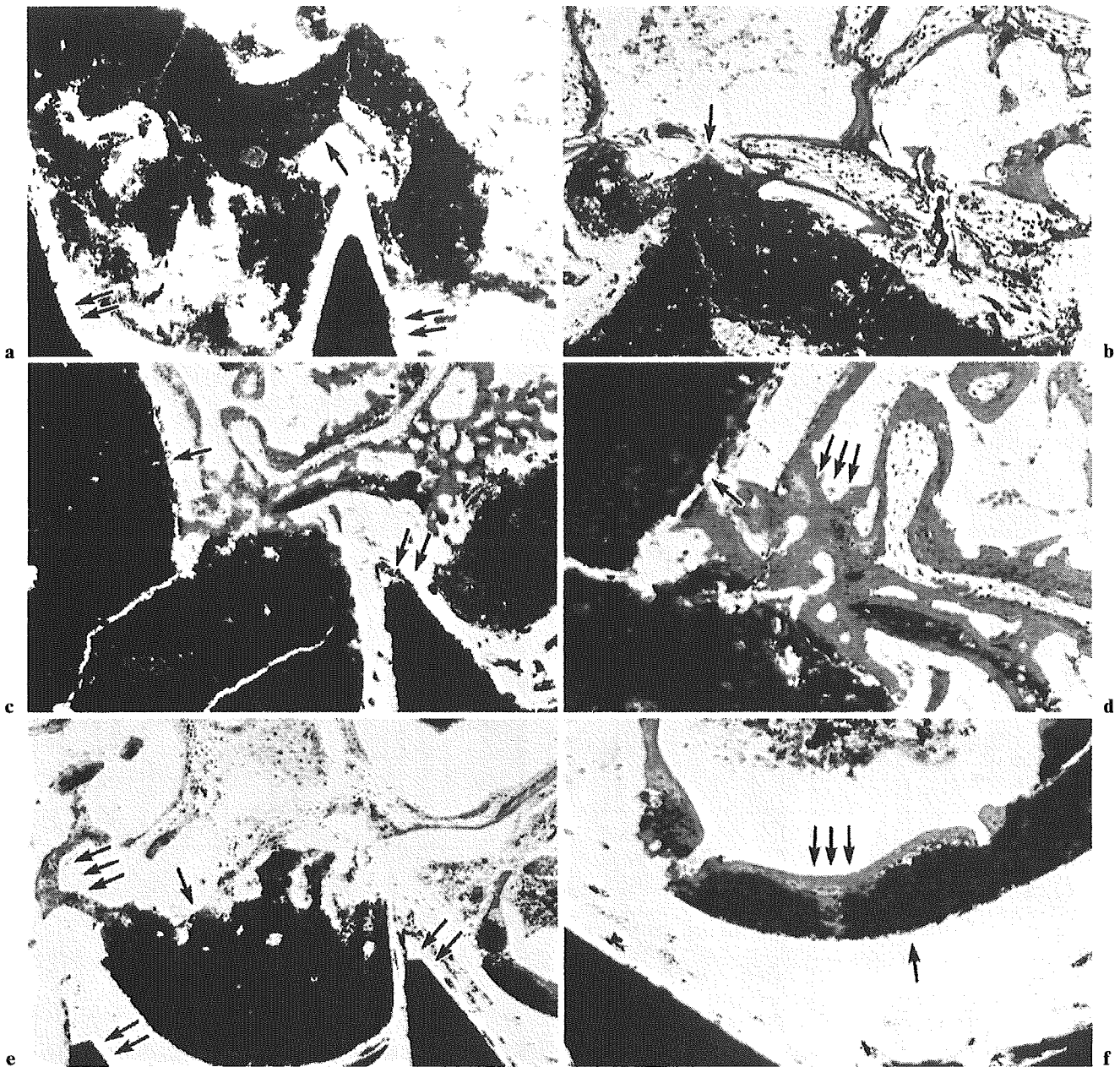
**Fig. 7.** Augmentation effect on pull-out strength. Even with osteoporotic bone, pull-out strength greater than that in normal bone can be achieved using the CPC, and the pull-out strength increases further over time

( $P < 0.05$ ). The pull-out strength was significantly higher at 4 weeks than at 1 week ( $P < 0.01$ ). In the non-CPC group the values were  $324.4 \pm 38.0\text{N}$  ( $n = 9$ ) 1 week after surgery,  $346.0 \pm 49.6\text{N}$  ( $n = 9$ ) at 2 weeks, and  $366.8 \pm 75.0\text{N}$  ( $n = 8$ ) at 4 weeks. These values were similar ( $P > 0.6$ ). The pull-out strength in porotic dogs was significantly higher at 1 week ( $P < 0.05$ ), 2 weeks ( $P < 0.01$ ), and 4 weeks ( $P < 0.01$ ) after surgery in the CPC group than in the non-CPC group; it was higher by 28.1%, 48.1%, and 56.3%, respectively.

Pull-out strength in nonporotic dogs. The pull-out strength in the CPC group of nonporotic dogs (Fig. 5) was  $531.7 \pm 96.2\text{N}$  ( $n = 4$ ) 1 week after surgery,  $720.3 \pm 120.3\text{N}$  ( $n = 3$ ) at 2 weeks, and  $723.2 \pm 79.5\text{N}$  ( $n = 6$ ) at

4 weeks, showing an increase over time, with a significant difference between 1 and 4 weeks ( $P < 0.05$ ). The values in the non-CPC group were  $285.2 \pm 63.1\text{N}$  ( $n = 4$ ) 1 week after surgery,  $381.2 \pm 52.0\text{N}$  ( $n = 3$ ) at 2 weeks, and  $478.2 \pm 90.8\text{N}$  ( $n = 5$ ) at 4 weeks. The CPC group of nonporotic dogs showed a significantly higher pull-out strength at 1 week ( $P < 0.05$ ), 2 weeks ( $P < 0.05$ ), and 4 weeks ( $P < 0.01$ ) after surgery than did the non-CPC group.

Compared to the non-CPC group of nonporotic dogs, the CPC group of porotic dogs had similar cephalocaudal rigidity ( $P > 0.5$ ) and significantly higher pull-out strength at every time point after surgery ( $P < 0.05$ ) (Figs. 6, 7).



**Fig. 8.** Histological findings at 1, 2, and 4 weeks. **a,b** At 1 week after surgery, the CPC (*single arrow*) had infiltrated into the cancellous bone surrounding the screw (*double arrows*). There was no indication of foreign body reaction or intervening fibrous tissues. **c,d** At 2 weeks after surgery, partial osteoid

formation and new bone formation (*triple arrows*) were observed around the CPC. **e,f** At 4 weeks after surgery, osteoid and newly formed bone were noted around the CPC, which had directly bonded to the surrounding bony trabeculae. **a-f** Toluidine blue. **a,c,e**  $\times 50$ ; **b,d,f**  $\times 100$

#### *Histological findings*

Histologically, CPC adequately filled the space between screw threads and remained in direct contact with the bone without a fibrous tissue interface 1 week after surgery (Fig. 8a). Osteoblasts with partial osteoid for-

mation also were observed around the CPC (Fig. 8b). The osteoid layer thickened, and new bone was formed by 2 weeks after operation (Fig. 8c), when a thin layer of mesh-like osteoid with new bone formation filled the space between the CPC and the host bone, reflecting the osteoconductivity of the CPC (Fig. 8d). At 4 weeks after

surgery, the newly formed bone had thickened, and the CPC was directly bonded to the surrounding bony trabeculae (Fig. 8e,f).

## Discussion

Bone mineral density is known to be an important factor affecting the strength of the screw–bone interface.<sup>2,3,5,15,17,22</sup> Insufficient rigidity and loosening of pedicle screws has been troublesome for spinal instrumentation surgery in elderly patients with osteoporosis.

A number of studies have looked at ways to improve the strength of the screw–bone interface. Soshi et al.<sup>20</sup> and Zindrick et al.<sup>26</sup> reported that the use of PMMA significantly increased the pull-out strength of pedicle screws, and Pfeifer et al.<sup>16</sup> found that pedicle screws augmented with PMMA had a 49% increase in pull-out strength. These studies showed that the combination of pedicle screws and PMMA significantly increased the pull-out strength. However, PMMA is a biotolerant material with no affinity for bone and remains an implanted foreign body. Injection of PMMA before screw insertion could injure the nerves by the heat of polymerization if the cement leaks into the spinal canal. In addition, toxicity of PMMA monomer with the use of this agent has been reported.<sup>18</sup>

To solve these problems, carbonated apatite cement (CAC) (Norian SRS; Norian, Cupertino, CA, USA) and HA-coated screws have been applied for this purpose, and mechanical tests have been performed on pedicle screws. Moore et al.<sup>14</sup> examined the pull-out strength of five kinds of reinserted pedicle screw augmented with CAC using human cadaveric vertebrae and found a 102% increase of pull-out strength on average. Yerby et al.<sup>25</sup> obtained a 1.5-fold higher pull-out strength with CAC using 7.0-mm pedicle screws inserted into the pedicles after removing 6.0-mm pedicle screws compared with that using no CAC. Lotz et al.<sup>9</sup> examined the pull-out strength and repeated load in the vertical directions of pedicle screws inserted into tapped holes where CAC had been injected and reported that the pull-out strength increased by 68% and the repeated load by 30%–63%. However, these studies were all based on *in vitro* experiments using cadavers, and the data cannot be directly translated to *in vivo* conditions, where the inserted materials interact with host bone.

Several *in vivo* studies have been reported. Spivak et al.<sup>21</sup> examined the effects of augmentation with HA grout on the screw placed in the lumbar vertebrae in adult mongrel dogs and reported that the pull-out strength of transpedicular screws with a poor initial fit insertion technique using an oversized pilot hole was significantly improved by HA grout at the sixth week. In

mongrel dogs, Matsuzaki et al.<sup>10</sup> measured the twisting force of titanium alloy screws with and without HA coating inserted into the lumbar vertebrae and reported that the twisting force of HA-coated screws was 2.3 times higher than that of uncoated screws 8 weeks after insertion.

Our study differed from these studies in that it not only examined the effects of the newly developed CPC in an experimentally induced osteoporotic condition, it also investigated the time course of the augmentation effects under conditions that allowed interactions between the CPC and host bone.

The CPC used in the present study has been reported to maintain a compressive strength of about 80 MPa from 7 days onward at a powder/liquid weight ratio of 2.8 in *in vitro* simulated body fluid.<sup>4</sup> Moreover, unlike PMMA, it does not generate polymerization heat because it is created by a hydration reaction.

Our results indicate that the stability of the inserted pedicle screw, as demonstrated by the cephalocaudal loading test and the pull-out test, was enhanced by CPC injection into the vertebral body 1 week after insertion and increased further over time. The significant augmentation effect obtained during the early stage was probably due to self-hardening of the CPC that had efficiently infiltrated the cancellous bone surrounding the screws because of the pasty status. The subsequent increase in strength was a consequence of the progression of direct bonding of the CPC to surrounding cancellous bone, as suggested histologically. In fact, the CPC was in direct contact with the cancellous bone without a fibrous tissue interface 1 week after injection, which was followed by new bone formation that bonded the CPC to the surrounding bony trabeculae 4 weeks after injection.

In this study, the non-CPC group of nonporotic dogs simulated ordinary pedicle screwing without augmentation in normal-quality bone. The cephalocaudal rigidity was in the same range in both the CPC group of porotic dogs and the non-CPC group of nonporotic dogs throughout the 4-week experiment (Fig. 6), but the pull-out strength was significantly higher in the CPC group of porotic dogs at all time stages compared with the non-CPC group of nonporotic dogs (Fig. 7). Furthermore, the pull-out strength increased over time in the CPC group of porotic dogs, whereas that in the non-CPC group of nonporotic dogs did not. As these results show, even in osteoporotic bone, the initial stability of the inserted screw that is greater than that in normal bone can be achieved using CPC, and that the stability increases even more over time. Because spinal instrumentation is used for temporal stabilization of motion segments until bony union is completed, permanent fixation strength, which may be essential for fixation of artificial joints, is not required. Therefore, evaluation of



the short-term effects of augmentation on screw stability is sufficient for clinical purposes.

Of course, we cannot extrapolate from the results of a simplified mechanical testing involving only a single pedicle screw to what happens clinically with several screws connected by rods. Nevertheless, our results suggest that the CPC injection could be clinically useful to provide sufficient stability of screws inserted into the pedicle in patients with osteoporosis.

## References

1. Barber JW, Boden SD, Ganey T, et al. Biomechanical study of lumbar pedicle screw: does convergence affect axial pullout strength? *J Spinal Disord* 1998;11:215–20.
2. Coe JD, Warden KE, Herzig MA, et al. Influence of bone mineral density on the fixation of thoracolumbar implants: a comparative study of transpedicular screws, laminar hooks, and spinous process wires. *Spine* 1990;15:902–7.
3. Halvorson TL, Kelley LA, Thomas KA, et al. Effects of bone mineral density on pedicle screw fixation. *Spine* 1994;19:2415–20.
4. Hirano M. Development of  $\alpha$ -TCP based bioactive cement. *New Ceramics* 1993;5:55–9 (in Japanese).
5. Hirano T, Hasegawa K, Takahashi HE, et al. Structural characteristics of the pedicle and its role in screw stability. *Spine* 1997;22:2504–10.
6. Iai H, Yamamoto H, Kamioka Y, et al. An experimental study on the biomechanical effect of TCP cement for the vertebra with osteoporosis. *Orthop Ceramic Implants* 1991;11:43–6 (in Japanese).
7. Ikeuchi M, Yamamoto H, Shibata T, et al. Mechanical augmentation of the vertebral body by calcium phosphate cement injection. *J Orthop Sci* 2001;6:39–45.
8. Kwok AWL, Finkelstein JA, Woodside T, et al. Insertional torque and pull-out strengths of conical and cylindrical pedicle screws in cadaveric bone. *Spine* 1996;21:2429–34.
9. Lotz JC, Hu SS, Chiu DFM, et al. Carbonated apatite cement augmentation of pedicle screw fixation in the lumbar spine. *Spine* 1997;22:2716–23.
10. Matsuzaki H, Numabe T, Tokuhashi Y, et al. Evaluation of hydroxyapatite-coated screws for lumbar spine fixation in dogs. *J Orthop Sci* 1997;2:405–13.
11. Matsuzaki H, Tokuhashi Y, Wakabayashi K, et al. Effects of hydroxyapatite solid granule (HA stick) on pedicle screwing for osteoporotic patients. *Rinsho Seikei Geka(Clin Orthop Surg)* 2001;36:529–34 (in Japanese).
12. McLain RF, Fry MF, Moseley TA, et al. Lumbar pedicle screw salvage: pullout testing of three different pedicle screw designs. *J Spinal Disord* 1995;8:62–8.
13. Monma H, Kanazawa T. The hydration of  $\alpha$ -tricalcium phosphate. *Yogyo-kyokai-shi* 1976;84:209–13 (in Japanese).
14. Moore DC, Maitra RS, Farjo LA, et al. Restoration of pedicle screw fixation with an in situ setting calcium phosphate cement. *Spine* 1997;22:1696–705.
15. Okuyama K, Sato K, Abe E, et al. Stability of transpedicle screwing for the osteoporotic spine: an in vitro study of mechanical stability. *Spine* 1993;18:2240–5.
16. Pfeifer BA, Krag MH, Johnson C. Repair of failed transpedicle screw fixation. *Spine* 1994;19:350–3.
17. Pfeiffer M, Gilbertson LG, Goel VK, et al. Effect of specimen fixation method on pullout tests of pedicle screws. *Spine* 1996;21:1037–44.
18. Rinecker H. New clinico-pathophysiological studies on the bone cement implantation syndrome. *Arch Orthop Trauma Surg* 1980;97:263–74.
19. Shibata T, Yamamoto H, Iai H, et al. A biomechanical strengthening of the vertebra with osteoporosis using hydroxyapatite cement injection. *J Jpn Spine Res Soc* 1995;6:61–9 (in Japanese).
20. Soshi S, Shiba R, Kondo H, et al. An experimental study on transpedicular screw fixation in relation to osteoporosis of the lumbar spine. *Spine* 1991;16:1335–41.
21. Spivak JM, Neuwirth MG, Labiak JJ, et al. Hydroxyapatite enhancement of posterior spinal instrumentation fixation. *Spine* 1994;19:955–64.
22. Wittenberg RH, Shea M, Swartz DE, et al. Importance of bone mineral density in instrumented spine fusions. *Spine* 1991;16:647–52.
23. Yamagata M, Kitahara H, Minami S, et al. Mechanical stability of the pedicle screw fixation systems for the lumbar spine. *Spine* 1992;17:s51–4.
24. Yamamoto H, Niwa S, Hori M, et al. Mechanical strength on calcium phosphate cement in vivo and in vitro. *Biomaterials* 1998;19:1587–91.
25. Yerby SA, Toh E, McLain RF. Revision of failed pedicle screws using hydroxyapatite cement: a biomechanical analysis. *Spine* 1998;23:1657–61.
26. Zindrick MR, Wiltse LL, Widell EH, et al. A biomechanical study of intrapeduncular screw fixation in the lumbosacral spine. *Clin Orthop* 1986;203:99–112.

分担研究報告書

高齢者脊椎圧迫骨折患者の介護およびリハビリテーションプログラムの確立

分担研究者：市村正一 杏林大学医学部整形外科 助教授

A. 研究目的

高齢者の急性腰痛症の主因である骨粗鬆症性椎体骨折は増加傾向にあり、骨折後の早期社会復帰や医療費の効率化を図るうえで早期からの系統的なりハビリや介護が必要である。本骨折の予後は良好とされていたが、近年手術成績の報告が増大している。一方で保存療法について十分な検討がされておらず、質の高い evidence が存在しないのが現状である。今回保存療法例の検討から、骨粗鬆症性椎体骨折の初期治療について検討することが目的である。

B. 研究方法

受傷から2週間以内に来院しX線とMRIにより新鮮骨粗鬆症性椎体骨折と診断され、6か月以上経過観察した64例、男性7例、女性57例、平均75.5(59~90)歳である。初診時にX線、CT、MRI、BMD、骨代謝マーカー(尿中NTX、BGP)を測定し、X線、MRI、尿中NTXは経時的(初診後1、2、4、6か月)に測定した。治療は約2週間のベッド上安静とし、この間も下肢筋力訓練等を行った。安静時痛が消失後硬性型フレームコルセットを装着し起立、歩行を行い骨癒合まで装着した。検討項目は、1.受傷高位、2.骨癒合率(偽関節の有無)、3.X線像の推移、4.MRI(marrow contrast)の推移、5.尿中NTXの推移、6.成績不良因子の検討である。偽関節はX線像上vacuum cleftを認めるものとした。

C. 研究結果

受傷椎体高位は、第1腰椎が最多で胸腰椎移行部と中位腰椎の2峰性を示した。骨癒合群は64例中56例(87.5%)で、偽関節群は64例中8例(12.5%)であった。両群間の年齢、BMDに有意差は

なかった。X線像上の圧縮率の推移は骨癒合群が初診時68.1%、以後68.1%、65.1%、63.7%、63.2%と推移し、偽関節群は初診時74.5%、以後75.2%、71.3%、64.0%、65.0%と推移し両群間に有意差はなかった。Marrow contrastの推移はT1強調像で骨癒合群は初診時低信号を示し、1か月後亢進した後徐々に減少し等信号へ集束した。一方で偽関節群は初診時より低信号化が強く6か月後においても有意に低信号が持続していた。T2強調像においても偽関節群は低信号を示し骨癒合群と比し初診時より有意に低信号であった。尿中NTXは骨癒合群において受傷後2週でピーク値を示し、以後減少し6か月で骨折前値に復帰していた。また偽関節群は初診時より高値を示し6か月時においても骨癒合群と比し有意に高値であった。成績不良因子の検討では多椎体損傷、Ⅲ度骨粗鬆症度、CT像上の後壁損傷例で有意に偽関節の発生が多く予後不良因子であった。一方、胸腰椎移行部損傷は偽関節の不良因子ではなかった。

D. 考察

硬性型フレームコルセットを用いても12.5%に偽関節を生じたが、遅発性神経障害例は認めず適切な初期治療であったと考えられる。しかし、さらに骨癒合率を向上させる方法を検討する必要がある。骨折治療経過のモニターとしてX線像でのvacuum cleft評価は可能である。圧縮率からの予測は困難であったが、骨癒合群に比し偽関節群で圧縮率の増大率は高く不安定性を示す要因と考えられる。MRIによるmarrow contrastは骨髄領域の骨折修復が確認でき骨折予後の判定に有用であった。NTXは、偽関節例において骨代謝亢進の状態が持続しNTX高値が持続し骨折予後モニターとして有用である可能性が示唆された。成績不良因

子の検討では多椎体骨折、Ⅲ度骨粗鬆症、後壁損傷といずれも骨折不安定性を増大させる因子であった。胸腰椎移行部損傷は受傷頻度も高く偽関節発生例は多いが、非胸腰椎部損傷と比し偽関節の発生率に差はなく不良因子にならなかったと考えられる。今後の検討課題は、ギプス固定など他の外固定による治療成績の検討、至適臥床期間の検討、早期リハビリテーションの試みなどにより骨折治癒成績、患者 ADL が向上するよう研究を進める予定である。

#### E. 結論

骨粗鬆症性椎体骨折の初期治療として硬性型フレームコルセットは有用であった。MRI marrow contrast、尿中 NTX は骨折治癒モニターとして有用であった。多椎体骨折、Ⅲ度骨粗鬆症度、後壁損傷例が成績不良因子であった。

#### 健康危険情報

問題なし。

#### F. 研究発表

1. 長谷川雅一, 市村正一, 里見和彦, 寶亀登\*, 児玉隆夫\*, 中川智之\* (杏林大学整形外科, 国立療養所東埼玉病院・整形外科\*) : 骨粗鬆症性脊椎圧迫骨折の保存療法における X 線像の検討 : 第 33 回日本脊椎脊髄病学会. 東京. 日本脊椎脊髄病学会雑誌 Vol 15. No1. p192. 2004.

2. 長谷川雅一, 市村正一, 里見和彦, 寶亀登\*, 中川智之\*, 児玉隆夫\*\* (杏林大学整形外科, 国立療養所東埼玉病院・整形外科\*, さいたま市立病院・整形外科\*\*) : 骨粗鬆症性椎体骨折患者の骨吸収マーカー (NTX) の変化 : 第 19 回日本整形外科学会基礎学術集会. 東京. 日本整形外科学会雑誌 Vol 78. No8. pS1061. 2004.

#### G. 知的財産権の出願・登録状況

予定していない。

腰痛疾患患者に対する新しい QOL 評価法（JLEQ）の開発

分担研究者：藤野 圭司 藤野整形外科 院長

A. 研究目的

近年、EBM(Evidence Based Medicine)の概念が主流になるにつれ、治療のアウトカムをより客観的かつ包括的に評価する必要性が求められている。その中で、QOL(Quality of Life)評価は重要なアウトカム評価の一つであるが、腰痛疾患においてはRoland-Morris Disability Questionnaire (RDQ)が global standard になりつつある。しかし、この評価法はわずかに単純な 24 問の設問に対して回答するものであり、かつ選択枝も「はい」、「いいえ」の二者択一と範囲は狭い。さらに、個々の QOL は国、人種、文化など多彩な要因に影響されるものであり、RDQ が本邦の腰痛疾患患者に直接当てはまるとは言い難い。本報告の目的は、本邦独自の文化・慣習に即し、かつ症状の軽重を問わずに微細な評価が可能な新しい QOL 評価法を開発し、その妥当性と信頼性を検証することである。

B. 研究方法

研究に先立ち、新しい QOL 評価法として JLEQ (Japan Low-back pain Evaluation Questionnaire) を作成した。この QOL 評価法は、本邦の腰痛患者の状態を詳細に把握するために有用で、より具体的な 30 問の設問からなる。症状の軽重、経時的な推移を詳細に把握・評価すべく、回答は各々 5 段階に細かく分類されている。次に、腰痛患者を対象として RDQ と JLEQ を同時に回答させ、JLEQ の妥当性・信頼性検証を施行した。被験者は、インターネットを用いて日本臨床整形外科医学会会員に募集した 100 名（男 64 名、女 36 名；平均年齢 42.5 歳）の腰痛患者である。

C. 研究結果

RDQ と JLEQ の評価に要する実際の時間は、両者

共に同じであり、統計学的有意差は無かった。QOL 評価法としての JLEQ は、RDQ と同程度の信頼性を有し、両者の有用性に統計学的有意差は無かった。一方、RDQ に比し、JLEQ の方がより詳細な腰痛評価が可能であった。

D. 考察

本研究により、JLEQ は本邦における腰痛患者の QOL 特性を極めて鋭敏に、かつ客観的・定量的に反映することが判明した。JLEQ は、RDQ と共に本邦における腰痛患者の QOL 評価として今後頻用され、標準的な評価法となることが期待される。

E. 結論

腰痛疾患患者に対する新しい QOL 評価法（JLEQ）を開発した。本法は日本における腰痛治療の客観的アウトカム評価法として有用と考える。

健康危険情報

問題なし。

F. 研究発表

第 78 回日本整形外科学会. 白土修ほか. 慢性腰痛に対する運動療法の効果. 2005 年 5 月

G. 知的財産権の出願・登録状況

日本整形外科学会. 日本臨床整形外科医会. 日本運動器リハビリテーション学会