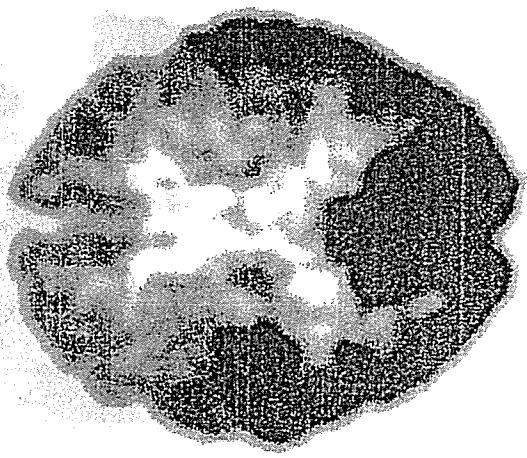
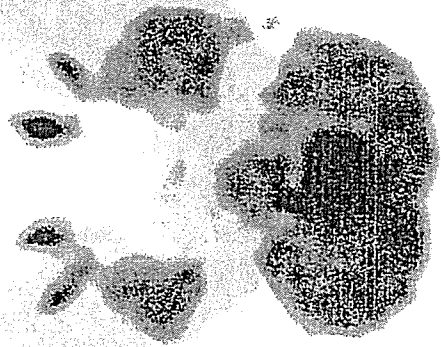
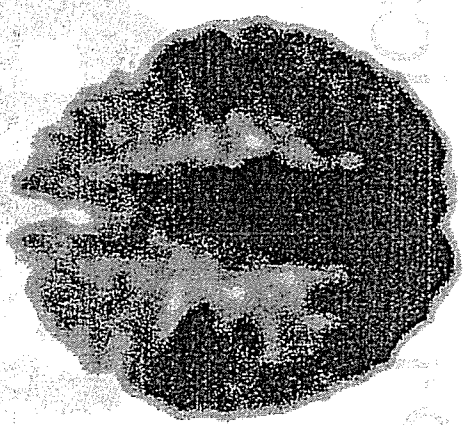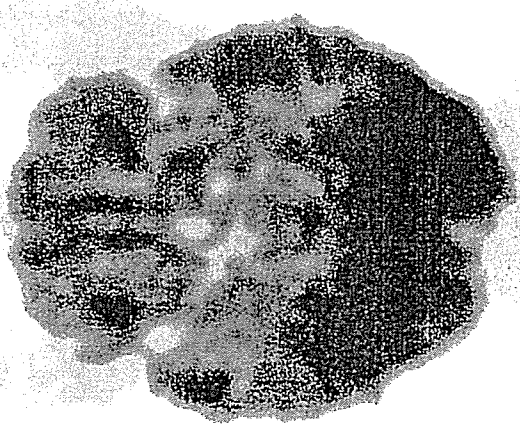
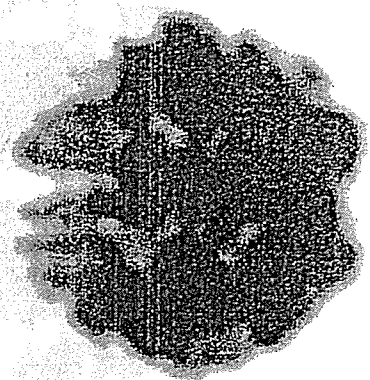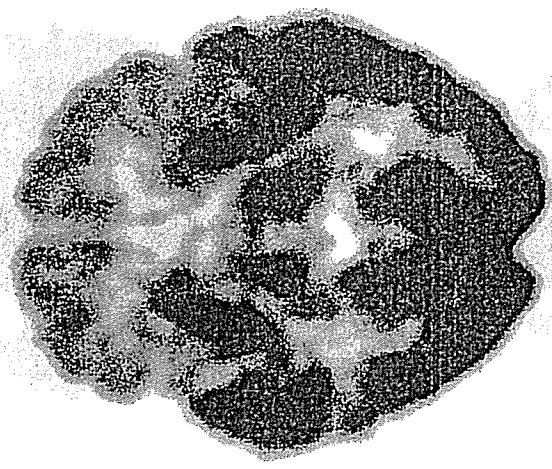


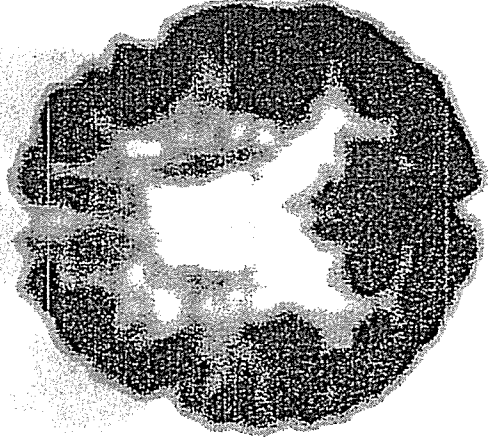
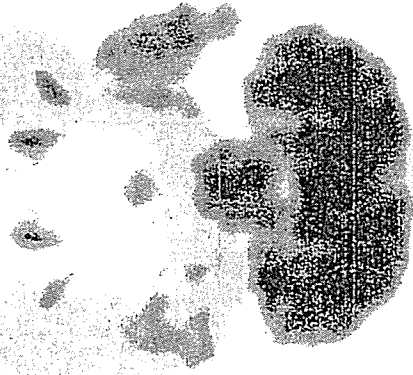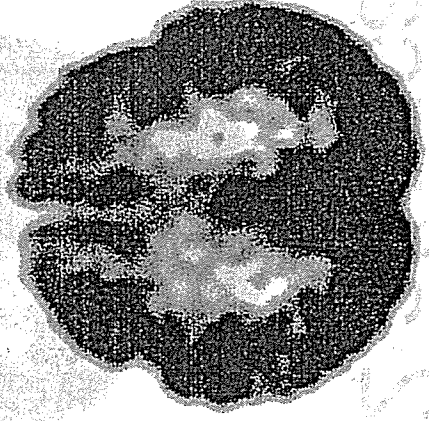
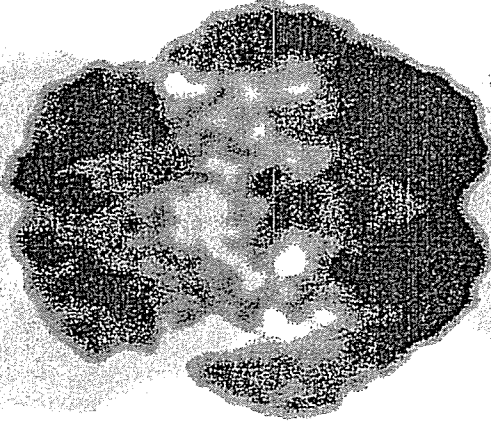
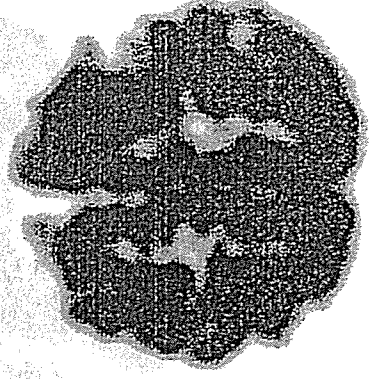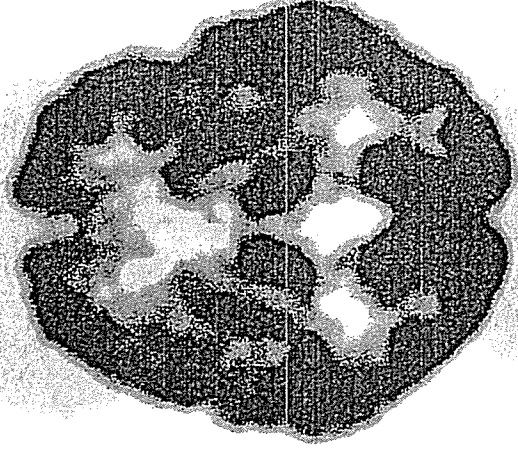
東京都老人研

P2 typical



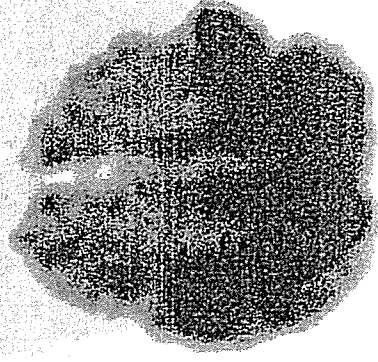
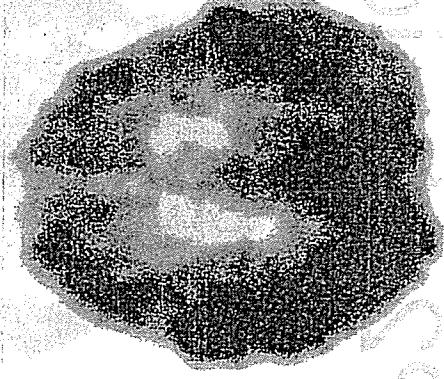
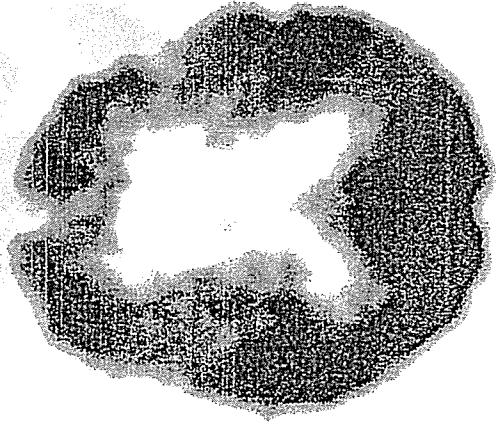
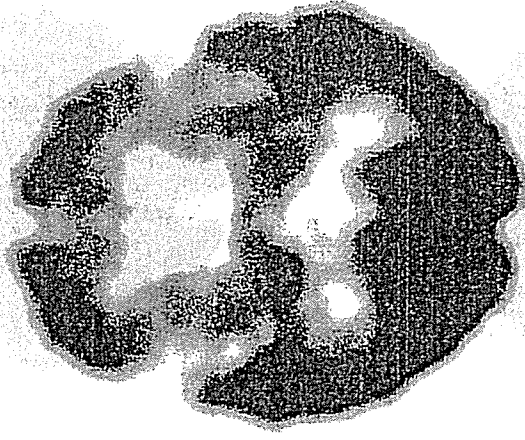
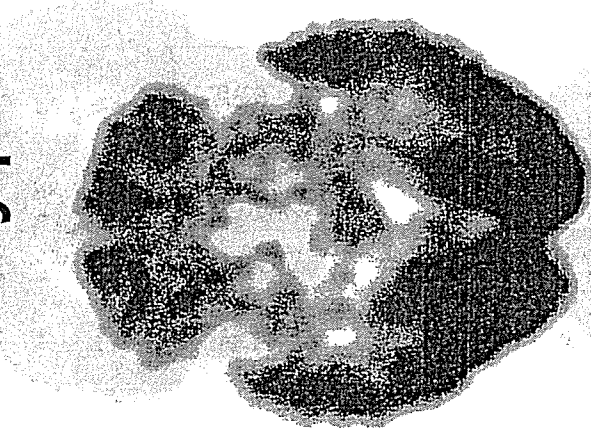
東京都老人研

P2 atypical



東京都老人研

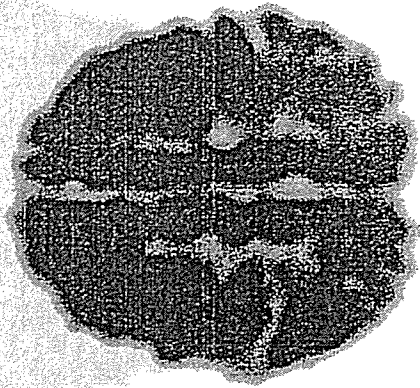
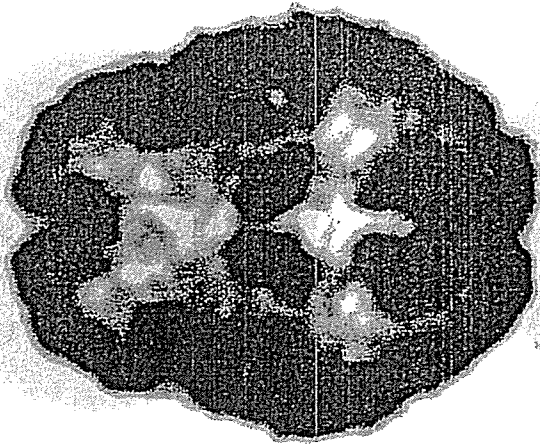
P2 atypical



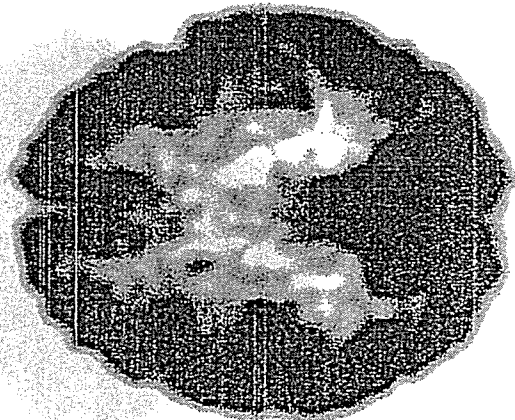
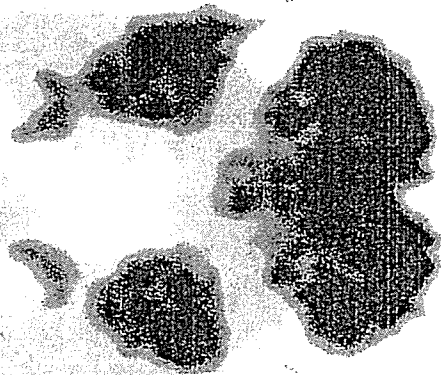
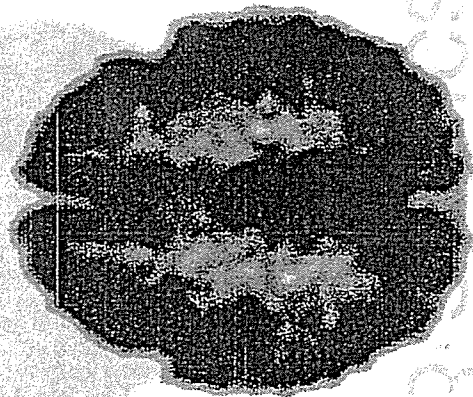

b201003

b201003

東京都老人研

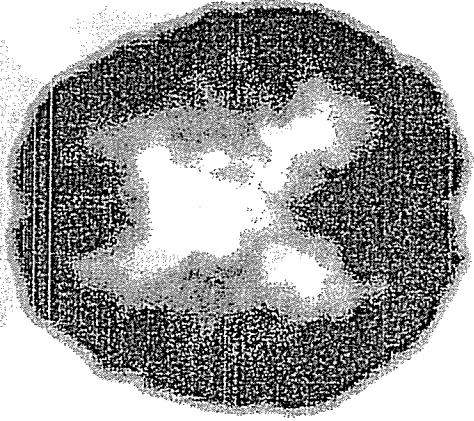
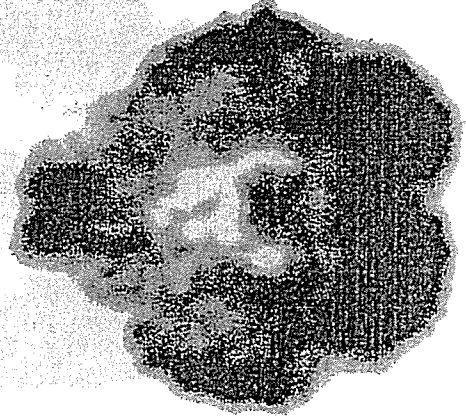
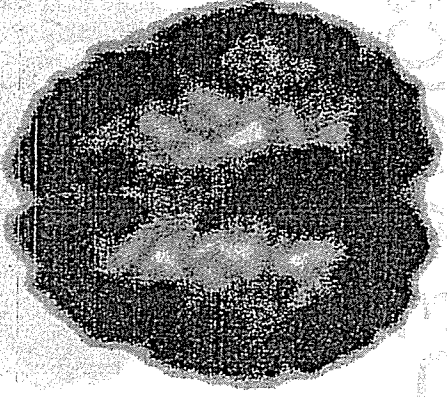
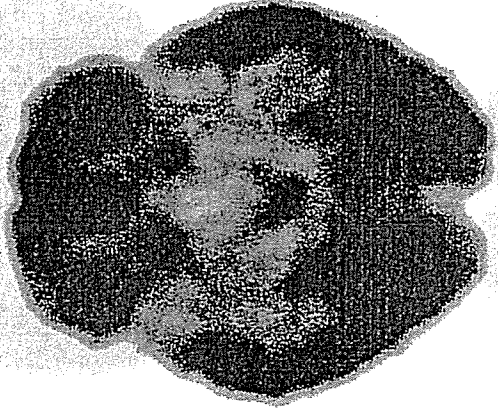

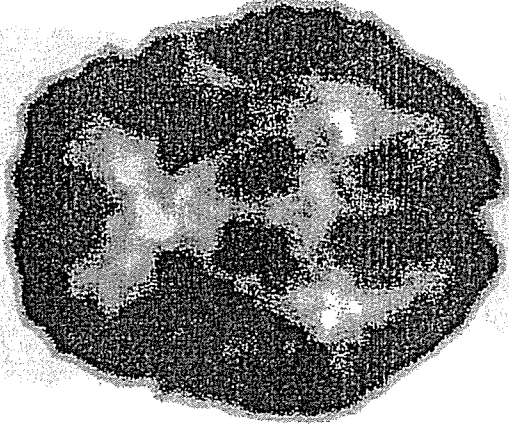


P3 typical


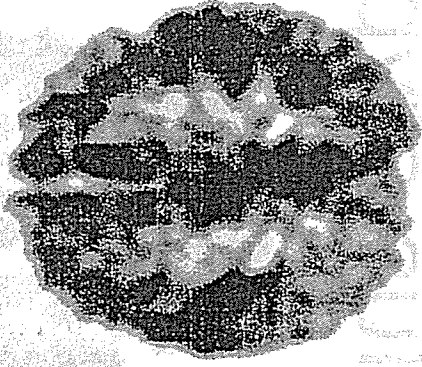
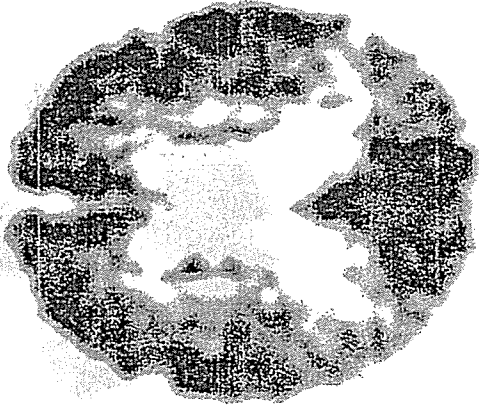
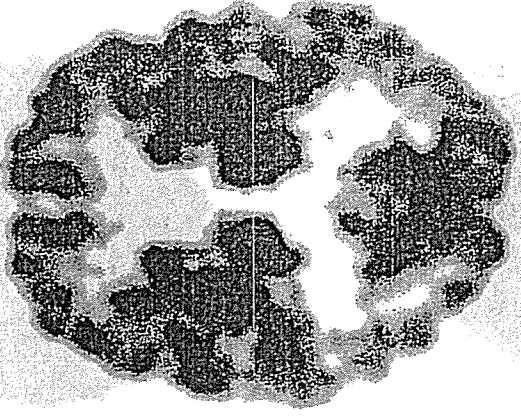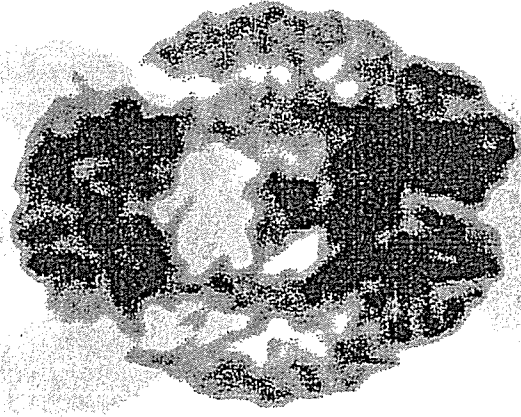



東京都老人研


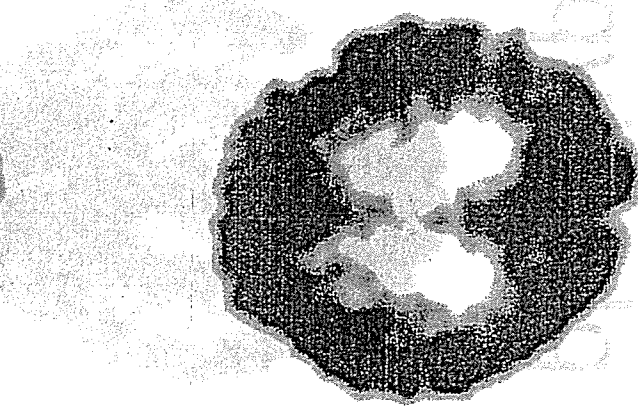
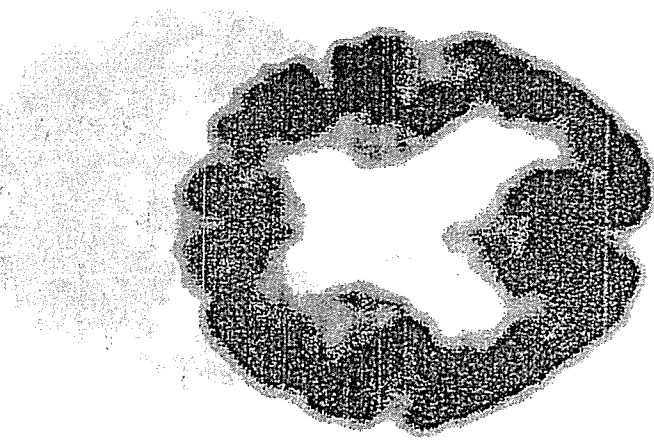
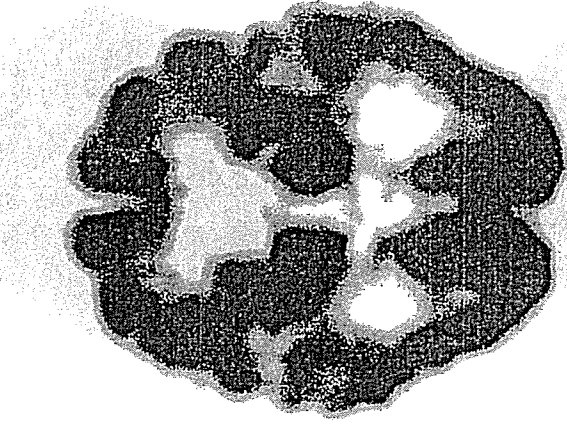
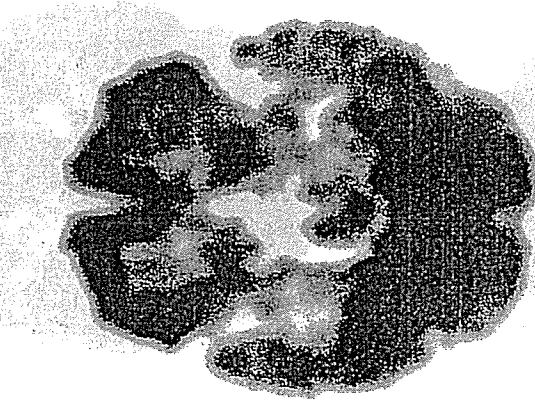
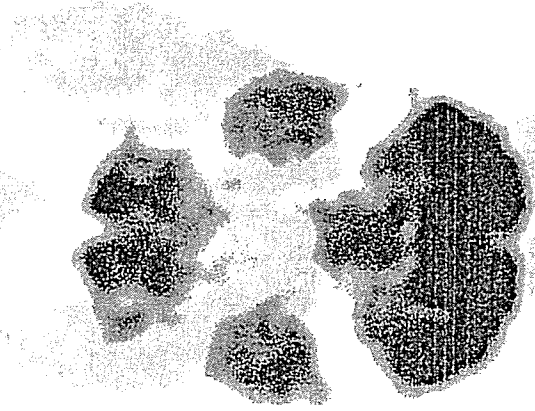
P3 atypical



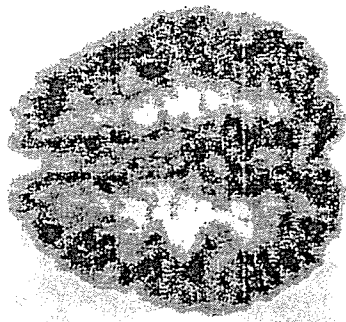
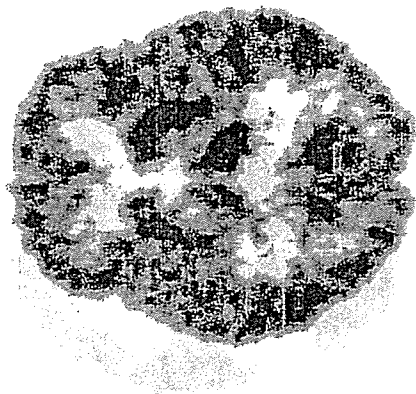
P1 plus typical



P1 plus atypical



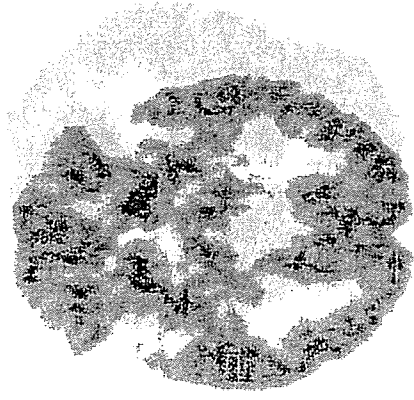
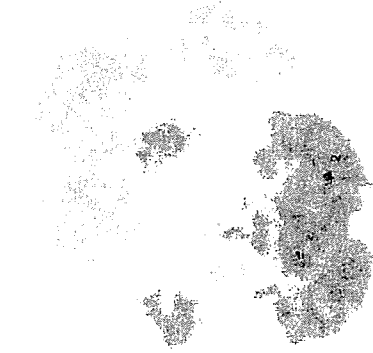


N1 正常型



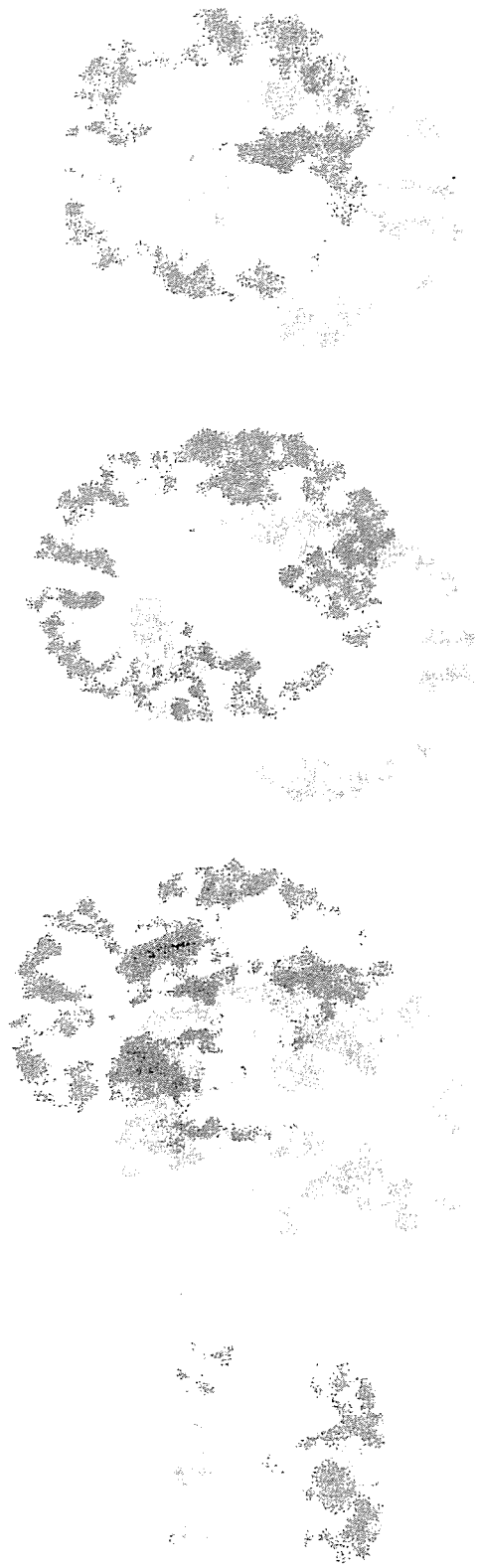67 M Normal

N2 萎縮相応型



77 F Normal

N2 9111V 萎縮相応型



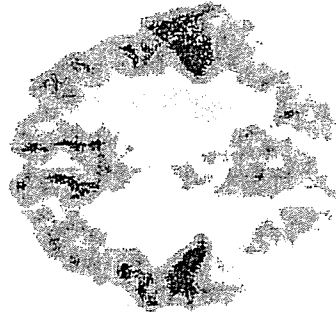
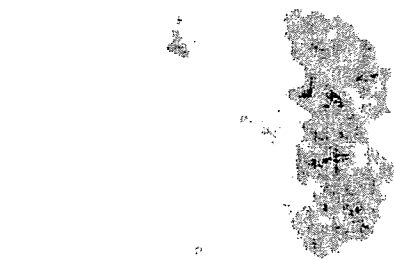
79 F DLB

7D88

兵庫脳研

P1

AD型

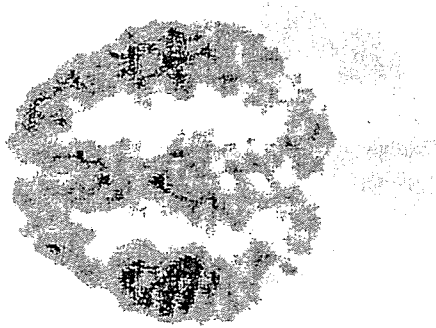
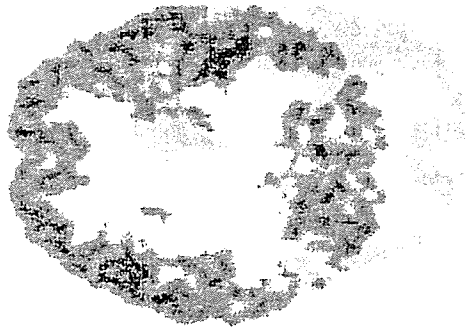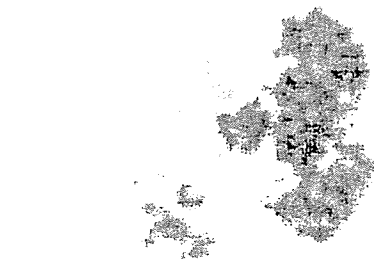


61 FAD

兵庫脳研

P1 21-0692

AD型



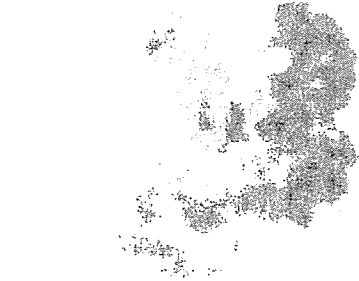63-72 M DLB

131120

210692

P1 + 55 F CBD

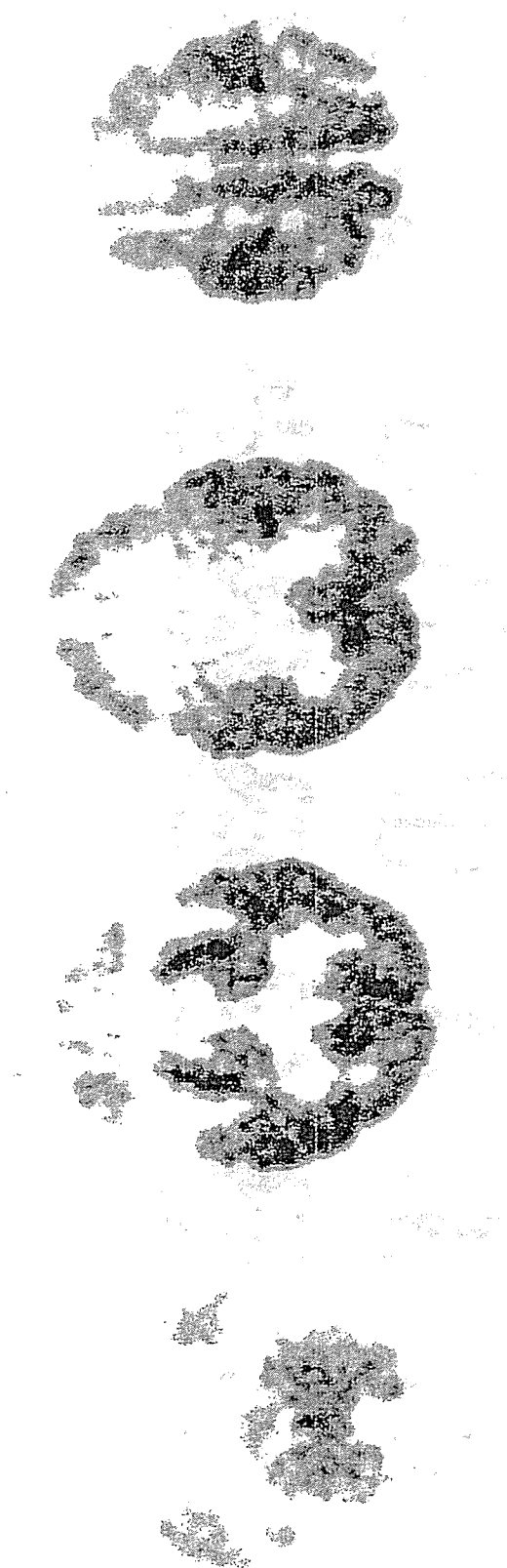AD類似型



55 F CBD

P2

FTD型

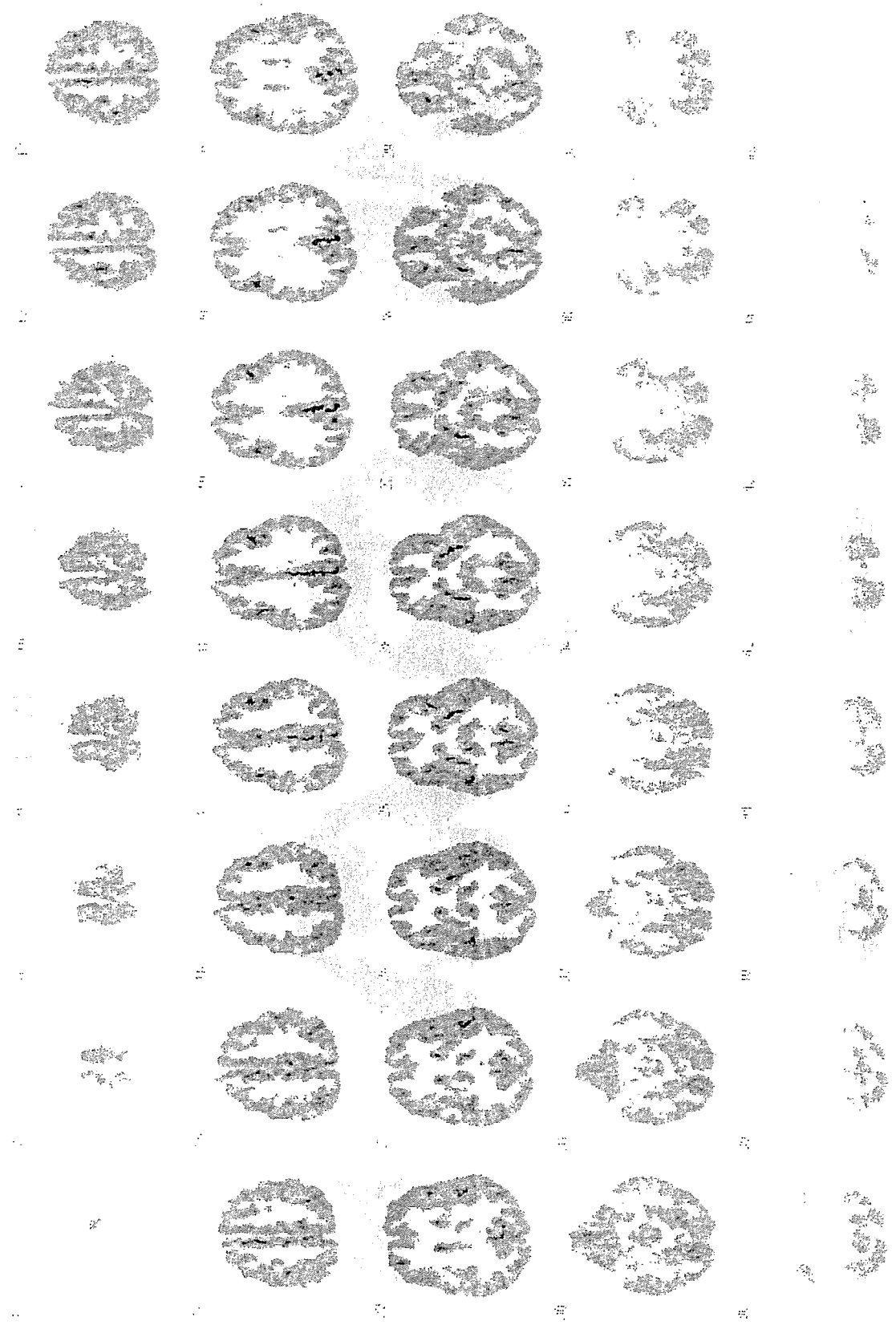


73 F FTD










Figure 1. Coronal sections of the hippocampus in a patient with FTD (case 73 F). The sections show varying degrees of atrophy and dark staining in the hippocampal region.

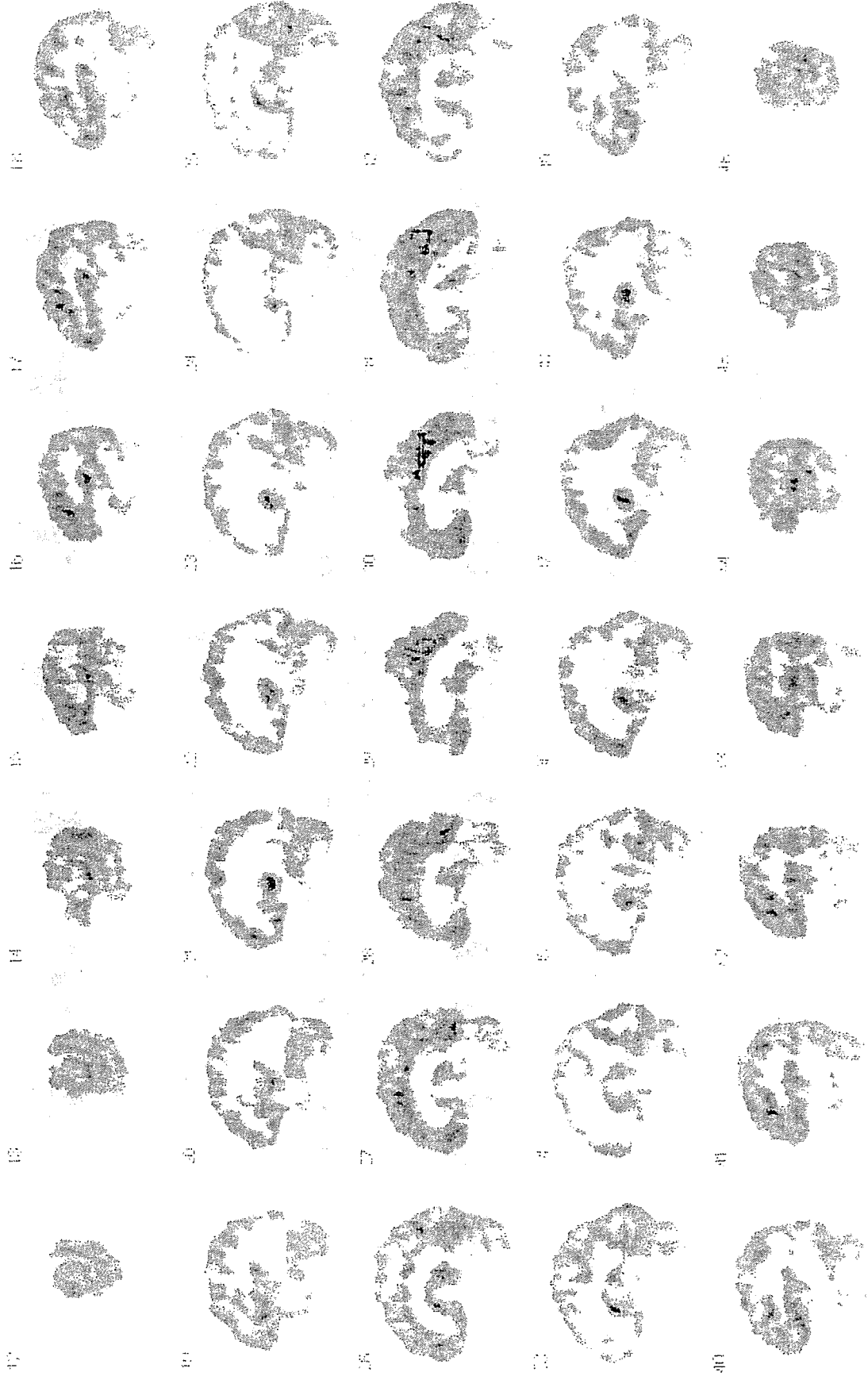
N1 1/3ページ(次のページに続く)

長寿七



長寿七

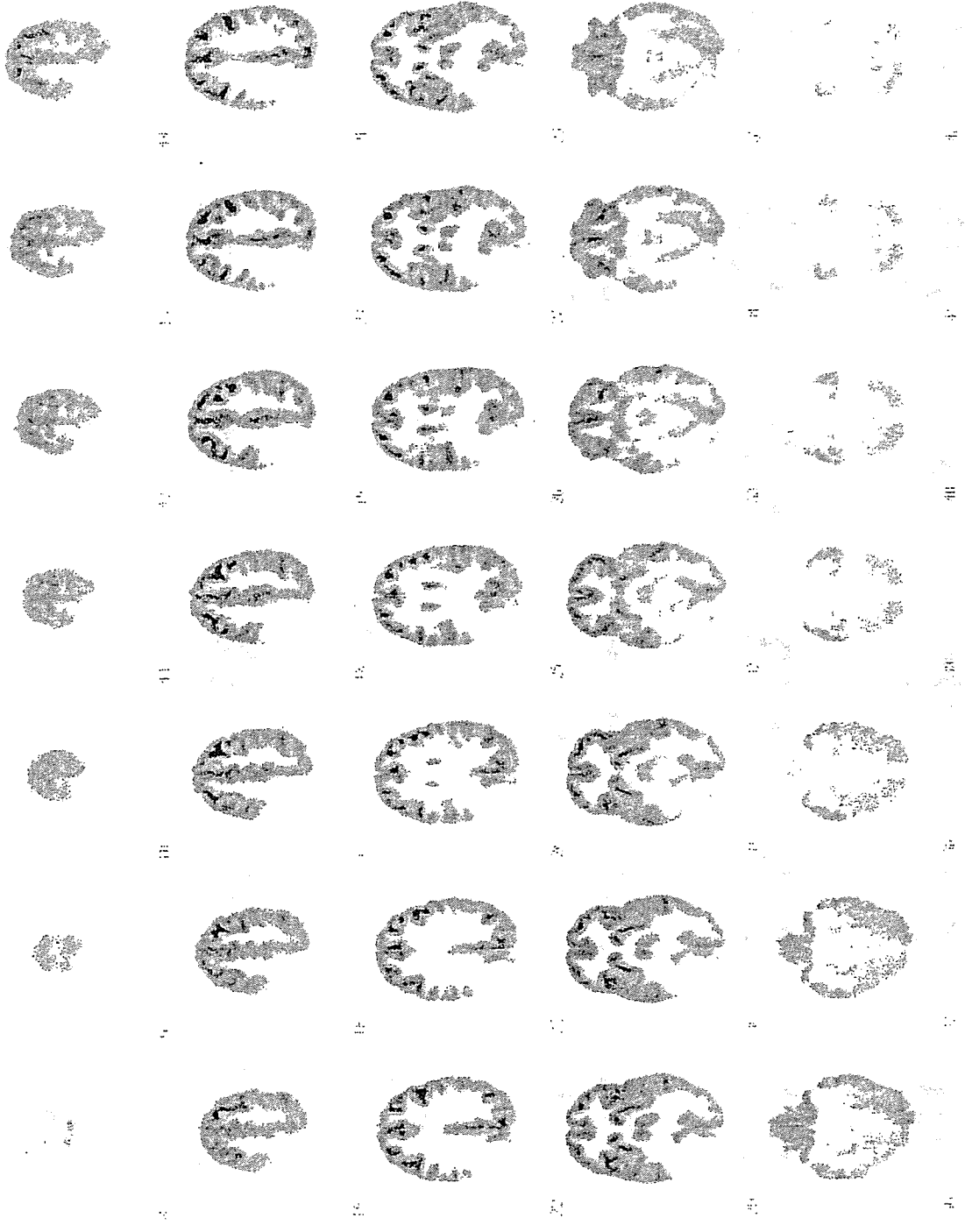




1/3ページ(次のページに続く)

長寿七

N3

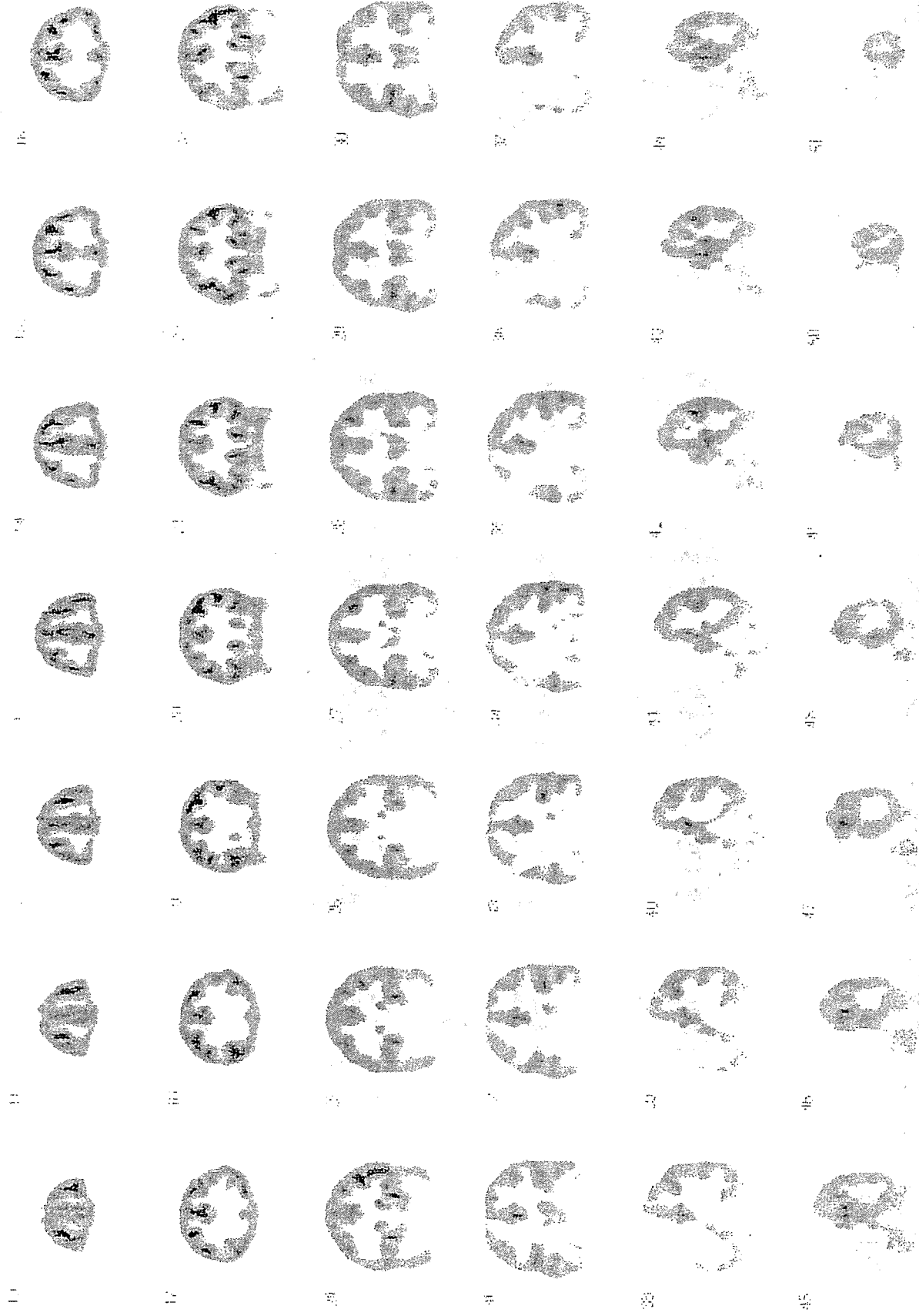


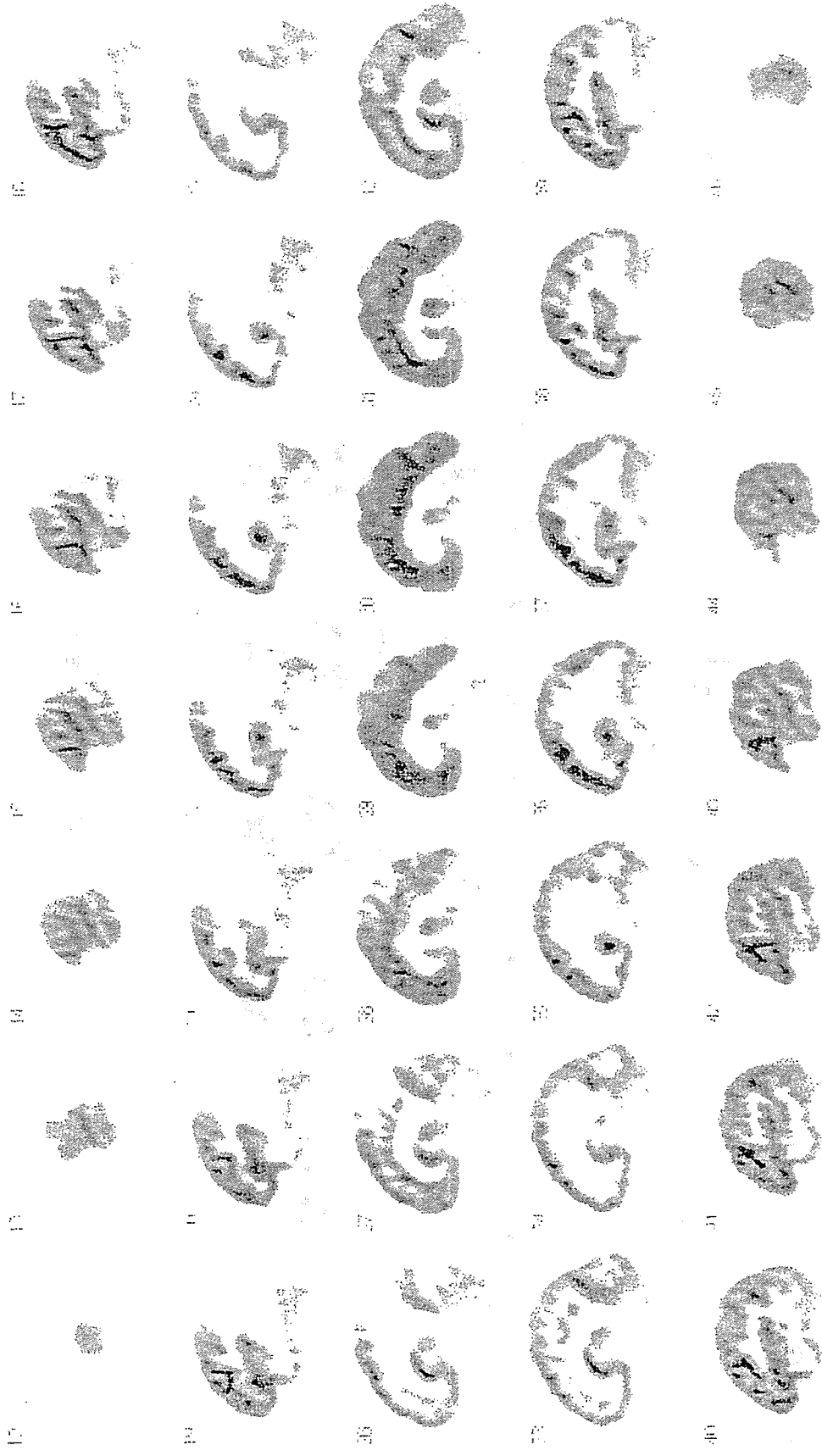
長寿七
一
二
三
四
五
六
七
八
九
十
十一
十二
十三
十四
十五
十六
十七
十八
十九
二十
二十一
二十二
二十三
二十四
二十五
二十六
二十七
二十八
二十九
三十
三十一
三十二
三十三
三十四
三十五
三十六
三十七
三十八
三十九
四十
四十一
四十二

2/3ページ(次のページに続く)

長寿七

N3





Copyright © 2010 by Shogakukan Inc. All rights reserved. This work is published under the Creative Commons Attribution-NonCommercial-ShareAlike license.